



# Diagnostic accuracy of ultrasonography and magnetic resonance imaging for the detection of fetal anomalies: a blinded case–control study

L. F. GONÇALVES\*†, W. LEE‡, S. MODY§, A. SHETTY‡, H. SANGI-HAGHPEYKAR¶  
and R. ROMERO\*\*††‡‡

\*Department of Obstetrics and Gynecology, Division of Fetal Imaging, Oakland University William Beaumont Hospital School of Medicine, Rochester, MI, USA; †Department of Radiology, Division of Pediatric Radiology, Oakland University William Beaumont Hospital School of Medicine, Rochester, MI, USA; ‡Department of Obstetrics and Gynecology, Division of Women's and Fetal Imaging, Baylor College of Medicine, Houston, TX, USA; §Department of Radiology, Division of Pediatric Radiology, Children's Hospital of Michigan, Detroit Medical Center, Detroit, MI, USA; ¶Department of Obstetrics and Gynecology, Division of Maternal-Fetal Medicine, Baylor College of Medicine, Houston, TX, USA; \*\*Perinatology Research Branch, Eunice Kennedy Shriver NICHD/NIH/DHHS, Detroit, MI, USA; ††Department of Obstetrics and Gynecology, University of Michigan, Ann Arbor, MI, USA; ‡‡Department of Epidemiology and Biostatistics, Michigan State University, East Lansing, MI, USA

**KEYWORDS:** 3D; accuracy; fetal MRI; prenatal diagnosis; sensitivity; specificity; ultrasound

## ABSTRACT

**Objectives** To compare the accuracy of two-dimensional ultrasound (2D-US), three-dimensional ultrasound (3D-US) and magnetic resonance imaging (MRI) for the diagnosis of congenital anomalies without prior knowledge of indications and previous imaging findings.

**Methods** This was a prospective, blinded case–control study comprising women with a singleton pregnancy with fetal congenital abnormalities identified on clinical ultrasound and those with an uncomplicated pregnancy. All women volunteered to undergo 2D-US, 3D-US and MRI, which were performed at one institution. Different examiners at a collaborating institution performed image interpretation. Sensitivity and specificity of the three imaging methods were calculated for individual anomalies, based on postnatal imaging and/or autopsy as the definitive diagnosis. Diagnostic confidence was graded on a four-point Likert scale.

**Results** A total of 157 singleton pregnancies were enrolled, however nine cases were excluded owing to incomplete outcome, resulting in 148 fetuses (58 cases and 90 controls) included in the final analysis. Among cases, 13 (22.4%) had central nervous system (CNS) anomalies, 40 (69.0%) had non-CNS anomalies and five (8.6%) had both CNS and non-CNS anomalies. The main findings were: (1) MRI was more sensitive than 3D-US for diagnosing CNS anomalies (MRI, 88.9% (16/18) vs 3D-US, 66.7% (12/18) vs 2D-US,

72.2% (13/18); McNemar's test for MRI vs 3D-US:  $P=0.046$ ); (2) MRI provided additional information affecting prognosis and/or counseling in 22.2% (4/18) of fetuses with CNS anomalies; (3) 2D-US, 3D-US and MRI had similar sensitivity for diagnosing non-CNS anomalies; (4) specificity for all anomalies was highest for 3D-US (MRI, 85.6% (77/90) vs 3D-US, 94.4% (85/90) vs 2D-US, 92.2% (83/90); McNemar's test for MRI vs 3D-US:  $P=0.03$ ); and (5) the confidence of MRI for ruling out certain CNS abnormalities (usually questionable for cortical dysplasias or hemorrhage) that were not confirmed after delivery was lower than it was for 2D-US and 3D-US.

**Conclusions** MRI was more sensitive than ultrasonography and provided additional information that changed prognosis, counseling or management in 22.2% of fetuses with CNS anomalies. False-positive diagnoses for subtle CNS findings were higher with MRI than with ultrasonography. Copyright © 2015 ISUOG. Published by John Wiley & Sons Ltd.

## INTRODUCTION

The first report on the use of fetal magnetic resonance imaging (MRI) was published in 1983<sup>1</sup>. Widespread acceptance into clinical practice occurred in the late 1990s after the introduction of fast MRI sequences, which obviated the need for maternal sedation to reduce fetal movement<sup>2</sup>. Since then, several investigators

Correspondence to: Dr L. F. Gonçalves, Division of Fetal Imaging, Beaumont Hospital, 3601 West 13 Mile Road, Royal Oak, MI 48073, USA (e-mail: luis.goncalves@beaumont.edu)

Accepted: 26 September 2015

have reported on the accuracy of fetal MRI compared with that of ultrasonography (US) in the diagnosis of congenital anomalies<sup>3–42</sup>. More recently, a systematic review summarized the results of previous studies related to the prenatal diagnosis of central nervous system (CNS) anomalies<sup>43</sup>. A common weakness of the studies conducted to date is selection bias that favors a higher diagnostic accuracy for fetal MRI, given prior knowledge of ultrasound findings at the time the MRI scan is performed and interpreted. This bias is difficult to avoid in retrospective studies since, in clinical practice, fetal MRI is performed after an anomaly has been either suspected or diagnosed by US<sup>44</sup>.

The primary objective of our study was to compare the diagnostic accuracy of two-dimensional (2D) US, three-dimensional (3D) US and fetal MRI for the diagnosis of congenital anomalies, using a prospective blinded case–control design. We evaluated examiners' confidence to diagnose or exclude congenital anomalies with each imaging modality and attempted to identify potential advantages, disadvantages and complementary roles of 2D-US, 3D-US and MRI.

## SUBJECTS AND METHODS

This study was approved by the human investigation committees of Beaumont Hospital and Wayne State University, and by the institutional review board of the Eunice Kennedy Shriver National Institute of Child Health and Human Development/NIH/DHHS. All participants signed informed consent prior to participation. The study cohort included pregnant women identified as having congenital abnormalities based on clinical ultrasound examination performed at Beaumont Hospital, Royal Oak, MI, USA. Research volunteers were selected by a single investigator (W.L.) as part of a convenience sample from patients referred to the Fetal Imaging Unit at Beaumont Hospital during a period when 76 823 clinically indicated ultrasound scans were performed. Selection criteria included: (1) willingness and availability of the research subject to be enrolled in both ultrasound and MRI studies; (2) availability of MRI scan time on the same day as the research ultrasound scan; and (3) availability of limited funding resources to cover research imaging costs. An attempt was made to include cases with a variety of representative anatomical anomalies that allowed blinded interpretation by experienced imaging specialists who were not part of the original enrollment process. Research volunteers with uncomplicated singleton pregnancy were invited to participate as a control group. Control subjects were matched by gestational age ( $\pm 1$  week) to those diagnosed with congenital anomalies. Patients with a body mass index  $> 30$  kg/m<sup>2</sup> were excluded. Cardiovascular anomalies were also excluded because specific MRI sequences tailored for fetal heart assessment were not available. 2D-US, 3D-US and fetal MRI were performed between July 2005 and January 2011. The precise number of research volunteers who were invited to participate was not recorded and the characteristics

of those who were enrolled *vs* candidates who declined participation were not studied systematically.

An experienced research sonographer obtained a minimum of two 2D-US digital videoclips of the fetal head, chest, abdomen, extremities (upper and lower) and gender using a standardized approach, and the procedure typically included at least two axial views of these features. The same research sonographer obtained at least two 3D volume datasets of the fetal head, trunk and limbs. The best quality 2D-US videoclips and volume datasets were preselected at the enrollment site to be anonymized and randomized for evaluation by external reviewers (4DView Software, GE Healthcare, Milwaukee, WI, USA). Neurosonography (2D) usually consisted of axial views of the fetal head and were largely based on transabdominal scans. The purpose of the 3D volume datasets, also using transabdominal axial image acquisition, was to provide the reviewers with an opportunity to examine arbitrarily reconstructed cutting planes. Fetal face scans included the following views: coronal on 2D-US; axial and sagittal sweeps on 3D-US; and axial, sagittal and coronal acquisitions using T2-weighted sequences on MRI.

Fetal MRI was usually performed on the same day using a Siemens Sonata 1.5-Tesla MRI machine (Siemens Medical Solutions USA, Malvern, PA, USA). Research subjects completed a safety survey to exclude contraindications to MRI. Most patients were scanned in the supine position, with a few patients scanned in the left lateral decubitus position because of discomfort. A 12-channel phased-array coil was placed anteriorly and the built-in spine coil was used posteriorly. The anterior coil was adjusted to assure proper signal distribution throughout the volume of acquisition. The field-of-view was kept large ( $> 250$  mm) to avoid fold-over artifacts from the maternal abdomen. Sequences were standard USA Food and Drug Administration (FDA) approved pulse sequences provided by the manufacturer. The scan time for individual sequences was tailored to less than 1 min and the cumulative specific absorption rate was kept within FDA guidelines. Balanced gradient echo sequences such as TRUE-FISP (True Fast Induction with Steady State Precession), FSE (Fast Spin Echo), HASTE (Half Fourier Single Shot Turbo Spin Echo) and diffusion-weighted imaging (DWI) were the primary sequences utilized in this study. In addition, T1-weighted 2D-FLASH and TURBO-FLASH were used to assess the presence of blood products. Details of the MRI protocol are provided in Table S1.

## Image interpretation

2D-US videoclips and 3D-US volume datasets were anonymized and archived onto digital media by research personnel. Ultrasound studies were interpreted by one author (L.F.G.) with more than 15 years' experience in the prenatal diagnosis of congenital anomalies. A pediatric radiologist (S.M.) with more than 10 years' experience in fetal MRI and neuroimaging interpreted the fetal MRIs.

Images (2D-US and fetal MRI) and volume datasets (3D-US) were read in random order according to a table of random numbers. 2D-US videoclips and 3D-US volume datasets were also assigned different random numbers and, therefore, 2D-US and 3D-US were never interpreted on the same day. Physicians interpreting the studies were blinded to gestational age, indication for examination, previous findings and pregnancy outcome. Descriptive categorization of findings and completion of a four-point Likert scale, ranging from 1 to 4 based on diagnostic confidence in identifying individual abnormalities (1, not confident (or questionable); 2, mildly confident; 3, moderately confident; 4, confident), or to interpret the fetus as normal were performed.

### Data analysis

Prenatal findings were compared with postnatal diagnostic tests (including X-ray, computerized tomography, ultrasonography, MRI, surgery, pathology and/or autopsy), as dictated by the clinical care required for each case. For control fetuses that did not require additional imaging or surgery after birth, a normal physical examination and neonatal course were used as the gold standard. Measurements of diagnostic conformity (sensitivity and specificity) were calculated for each imaging modality using postnatal diagnosis as the final outcome. Each anomaly was considered individually and compared with individual abnormalities detected after delivery. For example, if a fetus had holoprosencephaly (CNS anomaly) and clubfoot (musculoskeletal anomaly), sensitivity and specificity were calculated by comparing the concordance between prenatal and postnatal diagnosis for each anomaly. The overall accuracy was calculated, as well as the accuracy for CNS and non-CNS anomalies as separate groups. Diagnostic accuracy between techniques was compared by McNemar's test<sup>45</sup>. All statistical analysis was performed using SAS statistical software version 9.3 (SAS Institute Inc., Cary, NC, USA) and two-sided  $P$  of  $< 0.05$  was considered statistically significant.

Fetuses with isolated minor abnormalities (e.g. choroid plexus cysts, persistent right umbilical vein, hydrocele, mild pyelectasis), or placental abnormalities but otherwise normal anatomy, were considered normal.

A *post-hoc* power calculation indicated that a sample size of 90 control subjects had 80% power to detect a difference of 9% in specificity between two diagnostic tests when the proportion of discordant pairs was 10%. Furthermore, a sample size of 58 cases had adequate power (80%) to detect a difference of 14% in sensitivity between two tests when the proportion of discordant pairs was 15%. This procedure was based on a two-sided McNemar's test with a significance level of 0.05.

Physicians' levels of confidence to diagnose or exclude congenital anomalies were compared for each imaging method (2D-US, 3D-US and MRI) by mixed models using Proc Glimmix models in SAS (SAS Institute Inc.). The Glimmix procedure fits generalized linear models and estimates the parameters by maximum likelihood. Tukey's test was used to adjust for multiple comparisons.

### RESULTS

One hundred and fifty-seven singleton pregnancies were enrolled into the study (67 fetuses with anomalies suspected by clinical ultrasonography and 90 control fetuses). Postnatal outcome was not available for nine fetuses; five pregnancies had termination without autopsy and four did not undergo confirmatory postnatal studies. Therefore, the final analysis included 148 singleton fetuses, 58 enrolled as cases and scanned at a mean gestational age of  $26.9 \pm 5.4$  weeks, and 90 enrolled as controls and scanned at a mean gestational age of  $27.2 \pm 4.6$  weeks ( $P = 0.07$ ). Fifty-eight fetuses had at least one major congenital anomaly diagnosed after birth. Among control fetuses, one had unsuspected unilateral schizencephaly and absent cavum septi pellucidi that were first noticed at the time of the research MRI (Case 65). Details of this case have been published elsewhere<sup>46</sup>. Among cases, one fetus had a large pericardial effusion at the time of enrollment, which had resolved completely by the end of pregnancy (Case 150; Figure S1). Therefore, 58 fetuses were born with at least one major congenital anomaly and 90 were considered normal on postnatal examination. Among fetuses with at least one major anomaly detected postnatally, 13 (22.4%) had CNS

**Table 1** Accuracy of two-dimensional ultrasound (2D-US), three-dimensional ultrasound (3D-US) and fetal magnetic resonance imaging (MRI) in diagnosis of fetal congenital anomalies

Body system	2D-US	3D-US	MRI	P*	P†	P‡
All						
Sensitivity (%) ( $n = 58$ )	86.2 (74.6–93.9)	79.3 (66.6–88.8)	84.5 (72.6–92.7)	0.046	0.78	0.44
Specificity (%) ( $n = 90$ )	92.2 (84.6–96.8)	94.4 (87.5–98.2)	85.6 (76.6–92.1)	0.48	0.13	0.03
CNS						
Sensitivity (%) ( $n = 18$ )	72.2 (46.5–90.3)	66.7 (41.0–86.7)	88.9 (65.3–98.6)	0.32	0.18	0.046
Specificity (%) ( $n = 130$ )	100 (97.2–100)	100 (97.2–100)	97.7 (93.4–95.5)	1.00	0.32	0.32
Non-CNS						
Sensitivity (%) ( $n = 45$ )	77.8 (62.9–88.8)	75.6 (60.5–97.1)	80.0 (65.4–90.4)	0.66	0.76	0.59
Specificity (%) ( $n = 103$ )	98.1 (93.2–99.8)	100 (89.7–100)	97.1 (91.7–99.4)	—	0.65	—

Values in parentheses are 95% CI. Diagnostic accuracy of each technique compared using McNemar's test, with  $P < 0.05$  considered statistically significant: \*2D-US vs 3D-US; †2D-US vs MRI; ‡3D-US vs MRI. CNS, central nervous system.

anomalies only, 40 (69.0%) had anomalies involving body systems other than the CNS and five (8.6%) had both CNS and non-CNS anomalies (Tables S2 and S3).

### Sensitivity and specificity of 2D-US, 3D-US and fetal MRI for the diagnosis of congenital anomalies

The sensitivity and specificity of 2D-US, 3D-US and fetal MRI for the diagnosis of congenital anomalies are shown in Table 1. 2D-US and fetal MRI for diagnosing all anomalies had similar sensitivities (86.2% and 84.5%, respectively) and both were more sensitive than was 3D-US (79.3%). However, only the difference between 2D-US and 3D-US reached statistical significance (McNemar's test,  $P=0.046$ ). 2D-US and 3D-US had similar specificities for all anomalies (92.2% and 94.4%, respectively), whereas the specificity of MRI (85.6%) was significantly lower than was that of 3D-US ( $P=0.03$ ). This difference occurred only when all anomalies were analyzed together. No significant difference in specificity was found between the three imaging modalities when CNS and non-CNS anomalies were analyzed separately.

### Sensitivity of 2D-US, 3D-US and fetal MRI for the diagnosis of CNS anomalies

For the diagnosis of CNS anomalies, MRI was more sensitive than were 2D-US and 3D-US, although statistical significance was only achieved when comparing MRI and 3D-US (MRI, 88.9% vs 3D-US, 66.7% vs 2D-US, 72.2%; McNemar's test: MRI vs 3D-US,  $P=0.046$ ; MRI vs 2D-US,  $P=0.18$ ). A more detailed assessment of the cases with CNS anomalies (Table S2) shows that: (1) MRI provided additional information that would have affected prognosis, counseling or management in 22.2% (4/18) of these cases (Cases 65, 82, 112 (Figure 1) and 113 (Figure 2)); (2) 2D-US, 3D-US and MRI provided identical diagnoses in 8/18 (44.4%) cases; (3) 2D-US, 3D-US and MRI provided similar diagnoses in 6/18 (33.3%) cases; and (4) 2D-US diagnosed one case of absent cavum septi pellucidi that was missed by 3D-US and fetal MRI (Case 28). For Cases 65 and 113, even though ultrasonography correctly detected some of the CNS abnormalities, the additional findings on MRI would have been associated with a poorer prognosis (additional schizencephaly in a case of absent cavum septi pellucidi (Case 65) and lissencephaly and cephalocele (Case 113), not seen by ultrasound). In Case 82, ventriculomegaly and callosal dysgenesis were diagnosed correctly by ultrasonography but an open spinal dysraphism was missed. Although the spinal dysraphism could be seen in retrospect, the ultrasound image quality was poor, secondary to decreased amniotic fluid volume and excessive bone shadowing. In Case 112, arachnoid cyst, schizencephaly and polymicrogyria were not seen on ultrasound in the hemisphere close to the transducer.

Among cases for which the diagnoses were not identical between the three imaging modalities, MRI suspected

additional CNS anomalies not confirmed after delivery in six subjects; cortical dysplasia (polymicrogyria in Case 2, questionable prominent sulci in Case 18 and simplified gyral pattern in Case 49), mild ventriculomegaly (Cases 18 and 150), hypoplastic cerebellum (Case 49) and diastematomyelia (Case 82), whereas 2D-US and 3D-US suspected hypoplastic cerebellum in one fetus that was not confirmed after delivery (Case 74).

### Sensitivity of 2D-US, 3D-US and fetal MRI for the diagnosis of non-CNS anomalies

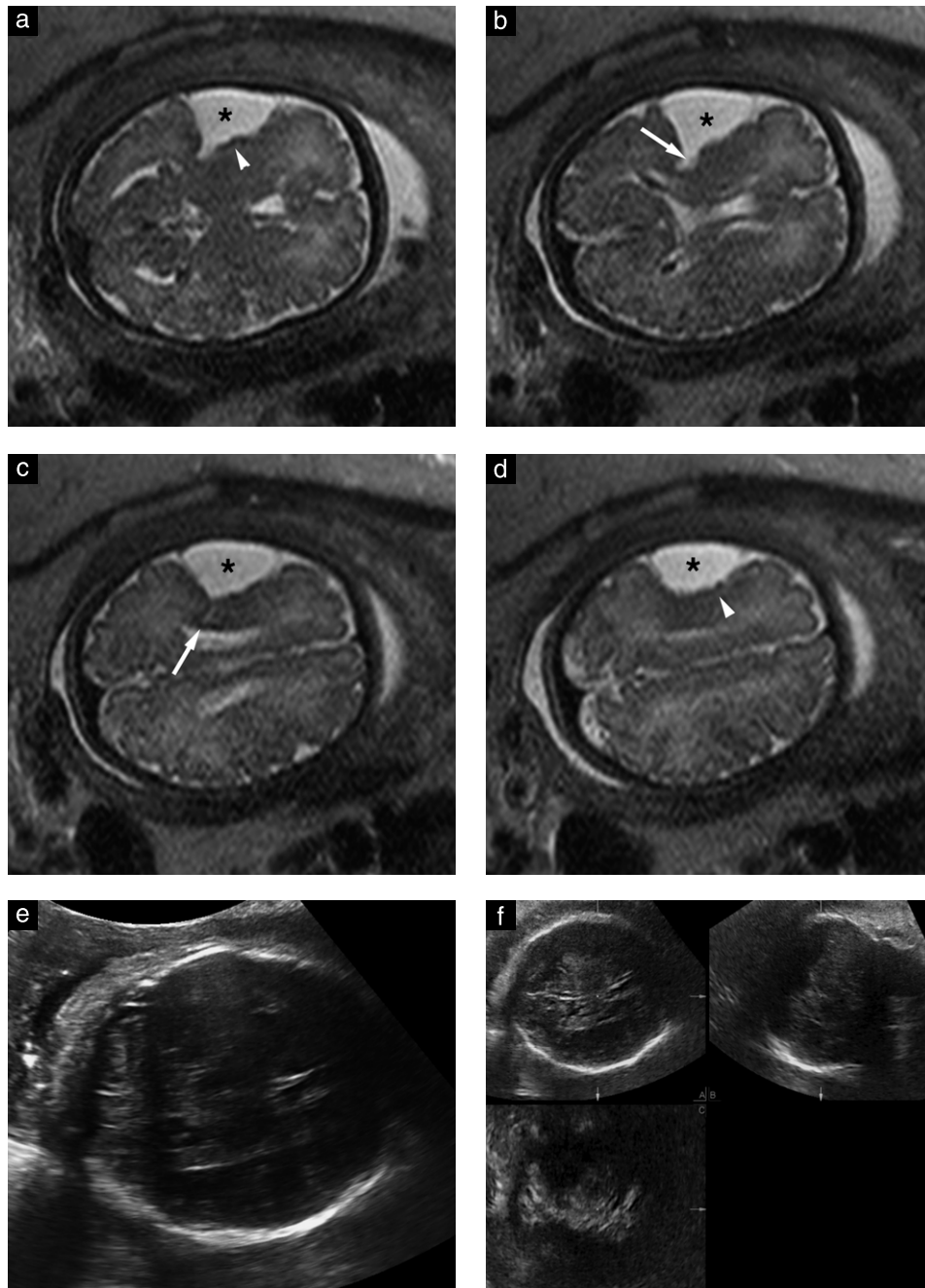
There was no difference in sensitivity between the three imaging modalities for the diagnosis of non-CNS anomalies (2D-US, 77.8% vs 3D-US, 75.6% vs MRI, 80.0%; McNemar's test was not significant for all comparisons). Detailed descriptions of non-CNS anomalies identified by each imaging modality are provided in Table S3.

### Diagnostic confidence of imaging modalities

CNS findings that were interpreted as questionable or with mild confidence, and that turned out to represent false-positive diagnoses, occurred more often with fetal MRI than with 2D-US or 3D-US. On a Likert scale of 1 to 4, the mean examiners' confidence in diagnosing congenital anomalies was similar across all three imaging modalities (3.29 for 2D-US, 3.40 for 3D-US and 3.43 for MRI; Table 2). However, there was less confidence in excluding certain abnormalities by MRI when compared with both 2D-US and 3D-US (mean 3.46 for 2D-US, 3.61 for 3D-US and 2.83 for MRI; Table 2). The information provided in Tables S2 and S3 shows that lower confidence occurred mostly when attempting to exclude subtle brain abnormalities such as cortical dysplasia (polymicrogyria in Case 2 (Likert score 2), questionably prominent cerebral sulci in Case 18 (Likert score 1), simplified gyral pattern in Case 49 (Likert score 2)) and a questionable intracranial hemorrhage based on an abnormal T1 signal in a single sequence (Case 4, Likert score 1). In other cases, exclusive use of subjective assessment led to concern for hypoplastic cerebellum (Case 49, Likert score 1) and mild ventriculomegaly (Case 150, Likert score 2). In Case 150, the examiner provided a comment in the intake database that 'the ventricle was borderline prominent (9–10 mm) and probably normal', but the anomaly was still classified as mild ventriculomegaly, with a Likert score of 2. Case 82 had a false-positive diagnosis of diastematomyelia by MRI (Likert score 2) but was diagnosed correctly by MRI as having spinal dysraphism with associated Chiari II malformation.

## DISCUSSION

This is the first prospective blinded case-control study comparing the sensitivity and specificity of 2D-US, 3D-US and MRI for detecting fetal congenital anomalies. The main findings are: (1) MRI was significantly more sensitive

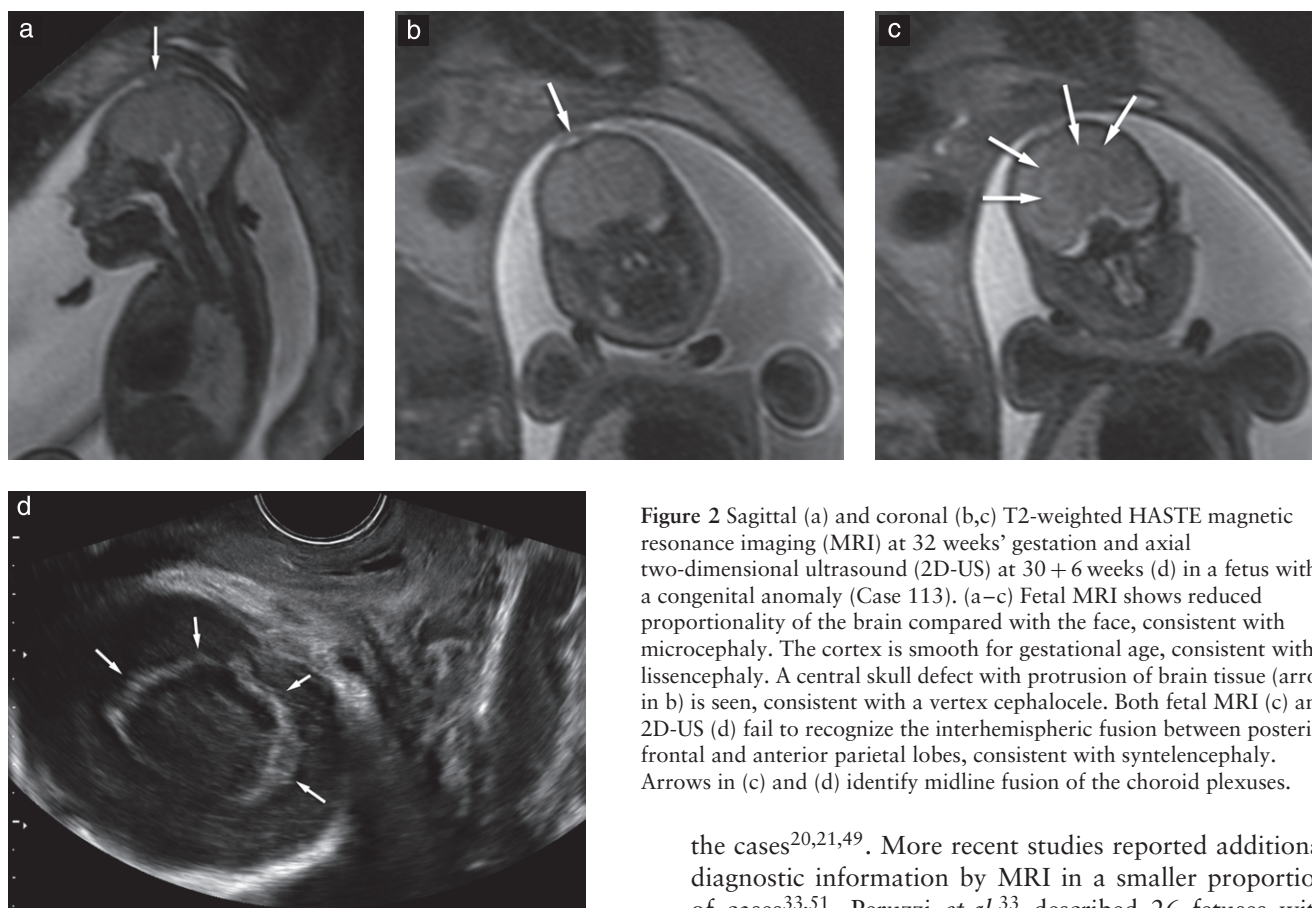


**Figure 1** Axial T2-weighted HASTE magnetic resonance imaging (MRI) (a–d), axial two-dimensional ultrasound (2D-US) (e) and three-dimensional multiplanar ultrasound (3D-US) (f) in a fetus with a congenital anomaly at 35 weeks' gestation (Case 112). (a–d) MRI shows a large hyperintense extra-axial cyst (★) in left frontotemporal region. There is mass effect upon the adjacent cortex with cortical ribbon irregularity, raising concern for polymicrogyria (arrowhead in a and d). A subtle cleft (arrows in b and c) extends to the wall of the lateral ventricle, raising concern for associated schizencephaly. All findings were confirmed postnatally. Axial 2D-US (e) and multiplanar 3D-US (f) fail to demonstrate the anomalies, most probably as a result of reverberation artifacts obscuring the cerebral hemisphere proximal to the transducer.

than 3D-US in diagnosing CNS anomalies ( $P = 0.046$ ); (2) MRI provided additional information that would have changed counseling and/or management in 22.2% (4/18) of cases with CNS anomalies; (3) 2D-US, 3D-US and MRI had similar sensitivity for diagnosing non-CNS anomalies; (4) 3D-US had higher specificity than MRI for diagnosing congenital anomalies; and (5) there was a lower confidence level in excluding subtle abnormal CNS findings by MRI than by ultrasonography.

### CNS anomalies

Several studies have reported a higher accuracy of MRI compared with ultrasonography for diagnosing CNS anomalies<sup>13,20,21,34,39,47</sup>. Others have shown that additional anomalies diagnosed by MRI may lead to a change in counseling and/or management<sup>13,19–21,33,43,48,49</sup>. An exception to this is the study by Malinger *et al.*<sup>50</sup>, who reported higher accuracy for fetal neurosonography in 7/39 (17.9%) cases compared to higher accuracy for



**Figure 2** Sagittal (a) and coronal (b,c) T2-weighted HASTE magnetic resonance imaging (MRI) at 32 weeks' gestation and axial two-dimensional ultrasound (2D-US) at 30 + 6 weeks (d) in a fetus with a congenital anomaly (Case 113). (a–c) Fetal MRI shows reduced proportionality of the brain compared with the face, consistent with microcephaly. The cortex is smooth for gestational age, consistent with lissencephaly. A central skull defect with protrusion of brain tissue (arrow in b) is seen, consistent with a vertex cephalocele. Both fetal MRI (c) and 2D-US (d) fail to recognize the interhemispheric fusion between posterior frontal and anterior parietal lobes, consistent with syntelencephaly. Arrows in (c) and (d) identify midline fusion of the choroid plexuses.

**Table 2** Comparison of examiners' confidence in diagnosing congenital anomalies by two-dimensional ultrasound (2D-US), three-dimensional ultrasound (3D-US) and fetal magnetic resonance imaging (MRI)

Diagnosis	Mean confidence*			P†	P§	P¶
	2D-US (n = 148)	3D-US (n = 148)	MRI (n = 148)			
All	3.39	3.53	3.07	0.39	0.0025	<0.0001
Normal	3.46	3.61	2.83			
Abnormal	3.29	3.40	3.43			
P†	0.87	0.69	0.0017			

\*Confidence measured on Likert scale, ranging from 1 (not confident) to 4 (very confident). Confidence of each technique compared by mixed models using Proc Glimmix (SAS), adjusted for multiple comparisons, with  $P < 0.05$  considered statistically significant: †normal vs abnormal; ‡2D-US vs 3D-US; §2D-US vs MRI; ¶3D-US vs MRI.

MRI in 3/39 (7.7%) cases. A recent systematic review<sup>43</sup>, which included 13 articles and 710 fetuses, found that: (1) MRI provided additional information in 22.1% of cases (mainly midline anomalies); (2) the false-positive rate for MRI was 2.5% (including ventriculomegaly, hemorrhage, midline anomalies, neuronal migration anomalies and cell-proliferation disorders); and (3) ultrasonography was more accurate than MRI in 2.0% of cases. In three articles included in the systematic review, MRI diagnoses were different enough to change management in 30.2% of

the cases<sup>20,21,49</sup>. More recent studies reported additional diagnostic information by MRI in a smaller proportion of cases<sup>33,51</sup>. Peruzzi *et al.*<sup>33</sup> described 26 fetuses with CNS anomalies diagnosed after delivery for which MRI modified the diagnosis and changed management in two (7.7%) cases. Paladini *et al.*<sup>51</sup> reported on 126 fetuses examined by 2D-US, 3D-US and MRI. MRI and ultrasound results were discordant in 12.7% (16/126), with additional diagnostic information provided by MRI in 7.9% (10/126) of cases.

In our study, the higher sensitivity of fetal MRI in diagnosing CNS anomalies occurred at the expense of a higher number of false-positive diagnoses, including questionable cortical dysplasia (Cases 2, 18 and 49) and intracranial hemorrhage (Case 4; Table S2). Other false-positive diagnoses, such as hypoplastic cerebellum, could have been avoided by using objective criteria (transverse cerebellar diameter measurement). These observations underscore the importance of having clinical information available at the time of examination (e.g. gestational age, which would have allowed the use of objective criteria) and of being cautious in prospectively diagnosing malformations of cortical development or intracranial hemorrhage when subtle irregularities in cortical mantle or abnormal signal intensities in the brain are not consistently and confidently identified in all sequences and/or planes.

### Non-CNS anomalies

The sensitivities of fetal MRI, 2D-US and 3D-US for the diagnosis of non-CNS anomalies were not significantly different (80.0%, 77.8% and 75.6%, respectively). A more detailed assessment of the cases described in

Table S3 shows that ultrasound performed better than did MRI for the diagnosis of skeletal anomalies (Cases 8, 92, 103) whereas MRI performed better than did ultrasound in a case of congenital lung mass (Case 100). MRI missed one case of unilateral cleft lip and palate (Case 22) that was diagnosed correctly by 2D-US and 3D-US. In Cases 38 and 58, mandibular hypoplasia and cleft lip were diagnosed correctly by MRI but missed by 2D-US and 3D-US. Regarding the diagnosis of facial clefts, recent work from Arangio *et al.*<sup>52</sup> suggests that MRI adds diagnostic information in cases of facial clefts diagnosed by both 2D-US and 3D-US. In their study, MRI corrected the ultrasonographic diagnosis for 11/28 cases with facial clefts.

### Strengths and limitations of the study

The strengths of the current study are: (1) the blinded and randomized image review by experienced examiners; (2) specific comparison of diagnostic confidence rates between examiners; and (3) interpretation bias was minimized by not having access to patient history, indication for referral or findings from prior diagnostic imaging studies.

One of the limitations of this study was the reliance on patient availability and willingness to participate. The ideal scenario would have been to scan consecutive cases presenting for prenatal diagnosis, but this was not logistically possible. The second limitation (paradoxically also a strength of the study) was the blinded case-control design, which did not allow examiners to access patient history, indication for referral or findings from prior imaging studies. Although this avoided interpretation bias, it may also have contributed to a lower diagnostic accuracy than expected in actual clinical practice for the three imaging modalities. In addition, sonographers and MRI technologists obtained the images, therefore physicians interpreting the studies did not have a chance to participate in image acquisition, as would normally occur. The study also lacked data that would permit an analysis of factors, such as high maternal body mass index, oligohydramnios and uterine scarring, which could provide MRI with a diagnostic advantage over 2D-US and 3D-US. A body mass index of  $> 30 \text{ kg/m}^2$  was an exclusion criterion, and data regarding oligohydramnios or uterine scarring were not collected prospectively.

Lastly, several technological advances in fetal MRI, which are currently not considered standard in clinical practice, were not evaluated in this study. These include higher strength static magnetic fields (3 Tesla), diffusion tensor imaging spectroscopy and the recently reported use of susceptibility weighted imaging to evaluate fetal bones<sup>53</sup>. Likewise, fetal Doppler was not systematically used, unless a vascular anomaly or an anomaly that required vascular information for characterization was present (e.g. vein of Galen aneurysm and lung sequestration).

### Conclusions

Fetal MRI had a higher sensitivity for diagnosing CNS anomalies than did 2D-US and 3D-US. The additional information provided by fetal MRI would have led to a change in counseling and/or management in approximately 22% of the cases. The higher sensitivity of MRI came at the expense of a higher number of false-positive diagnoses, usually for subtle CNS findings considered questionable or diagnosed with mild confidence. In clinical practice, ultrasonography and MRI should be combined to maximize sensitivity and minimize false-positive diagnoses.

### ACKNOWLEDGMENTS

We acknowledge the expert work of Melissa Powel, R.D.M.S., Renee Rustile R.T, Vivian Churchill, R.T, Ralph Gentry, R.T, and Ms Beverley McNie, without whom this work would not have been possible. This research was supported (in part) by the Perinatology Research Branch, Division of Intramural Research, Eunice Kennedy Shriver National Institute of Child Health and Human Development, NIH, DHHS. R. Romero contributed to this work as part of his official duties as an employee of the United States Federal Government.

### REFERENCES

1. Smith FW, Adam AH, Phillips WD. NMR imaging in pregnancy. *Lancet* 1983; 1: 61–62.
2. Stehling MK, Mansfield P, Ordidge RJ, Coxon R, Chapman B, Blamire A, Gibbs P, Johnson IR, Symonds EM, Worthington BS, *et al.* Echo-planar magnetic resonance imaging in abnormal pregnancies. *Lancet* 1989; 2: 157.
3. McCarthy SM, Filly RA, Stark DD, Callen PW, Golbus MS, Hricak H. Magnetic resonance imaging of fetal anomalies in utero: early experience. *AJR Am J Roentgenol* 1985; 145: 677–682.
4. Dinh DH, Wright RM, Hanigan WC. The use of magnetic resonance imaging for the diagnosis of fetal intracranial anomalies. *Childs Nerv Syst* 1990; 6: 212–215.
5. Garden AS, Weindling AM, Griffiths RD, Martin PA. Fast-scan magnetic resonance imaging of fetal anomalies. *Br J Obstet Gynaecol* 1991; 98: 1217–1222.
6. Wenstrom KD, Williamson RA, Weiner CP, Sipes SL, Yuh WT. Magnetic resonance imaging of fetuses with intracranial defects. *Obstet Gynecol* 1991; 77: 529–532.
7. D'Ercole C, Girard N, Boubli L, Potier A, Chagnon C, Raybaud C, Blanc B. Prenatal diagnosis of fetal cerebral abnormalities by ultrasonography and magnetic resonance imaging. *Eur J Obstet Gynecol Reprod Biol* 1993; 50: 177–184.
8. Yuh WT, Nguyen HD, Fisher DJ, Tali ET, Gao F, Simonson TM, Kao SC, Weiner CP. MR of fetal central nervous system abnormalities. *AJNR Am J Neuroradiol* 1994; 15: 459–464.
9. Levine D, Barnes PD, Madsen JR, Li W, Edelman RR. Fetal central nervous system anomalies: MR imaging augments sonographic diagnosis. *Radiology* 1997; 204: 635–642.
10. Sonigo PC, Rypens FF, Carteret M, Delezoide AL, Brunelle FO. MR imaging of fetal cerebral anomalies. *Pediatr Radiol* 1998; 28: 212–222.
11. Levine D, Barnes PD, Madsen JR, Abbott J, Mehta T, Edelman RR. Central nervous system abnormalities assessed with prenatal magnetic resonance imaging. *Obstet Gynecol* 1999; 94: 1011–1019.
12. Poutamo J, Vanninen R, Partanen K, Kirkinen P. Diagnosing fetal urinary tract abnormalities: benefits of MRI compared to ultrasonography. *Acta Obstet Gynecol Scand* 2000; 79: 65–71.
13. Simon EM, Goldstein RB, Coakley FV, Filly RA, Broderick KC, Musci TJ, Barkovich AJ. Fast MR imaging of fetal CNS anomalies in utero. *AJNR Am J Neuroradiol* 2000; 21: 1688–1698.
14. Whitby E, Paley MN, Davies N, Sprigg A, Griffiths PD. Ultrafast magnetic resonance imaging of central nervous system abnormalities in utero in the second and third trimester of pregnancy: comparison with ultrasound. *BJOG* 2001; 108: 519–526.
15. Ismail KM, Ashworth JR, Martin WL, Chapman S, McHugo J, Whittle MJ, Kirby MD. Fetal magnetic resonance imaging in prenatal diagnosis of central nervous system abnormalities: 3-year experience. *J Matern Fetal Neonatal Med* 2002; 12: 185–190.
16. Levine D, Barnes PD, Robertson RR, Wong G, Mehta TS. Fast MR imaging of fetal central nervous system abnormalities. *Radiology* 2003; 229: 51–61.
17. Matsuoka S, Takeuchi K, Yamanaka Y, Kaji Y, Sugimura K, Maruo T. Comparison of magnetic resonance imaging and ultrasonography in the prenatal diagnosis of congenital thoracic abnormalities. *Fetal Diagn Ther* 2003; 18: 447–453.

18. Cassart M, Masseur A, Metens T, Rypens F, Lambot MA, Hall M, Avni FE. Complementary role of MRI after sonography in assessing bilateral urinary tract anomalies in the fetus. *AJR Am J Roentgenol* 2004; **182**: 689–695.
19. Frates MC, Kumar AJ, Benson CB, Ward VL, Tempany CM. Fetal anomalies: comparison of MR imaging and US for diagnosis. *Radiology* 2004; **232**: 398–404.
20. Whitby EH, Paley MN, Sprigg A, Rutter S, Davies NP, Wilkinson ID, Griffiths PD. Comparison of ultrasound and magnetic resonance imaging in 100 singleton pregnancies with suspected brain abnormalities. *BJOG* 2004; **111**: 784–792.
21. Blaicher W, Prayer D, Mittermayer C, Weninger M, Birnbacher R, Deutinger J, Bernaschek G. The clinical impact of magnetic resonance imaging in fetuses with central nervous system anomalies on ultrasound scan. *Ultraschall Med* 2005; **26**: 29–35.
22. Glenn OA, Goldstein RB, Li KC, Young SJ, Norton ME, Busse RF, Goldberg JD, Barkovich AJ. Fetal magnetic resonance imaging in the evaluation of fetuses referred for sonographically suspected abnormalities of the corpus callosum. *J Ultrasound Med* 2005; **24**: 791–804.
23. von Koch CS, Glenn OA, Goldstein RB, Barkovich AJ. Fetal magnetic resonance imaging enhances detection of spinal cord anomalies in patients with sonographically detected bony anomalies of the spine. *J Ultrasound Med* 2005; **24**: 781–789.
24. Wang GB, Shan RQ, Ma YX, Shi H, Chen LG, Liu W, Qiu XL, Wei YL, Guo L, Qu L, Li HH. Fetal central nervous system anomalies: comparison of magnetic resonance imaging and ultrasonography for diagnosis. *Chin Med J (Engl)* 2006; **119**: 1272–1277.
25. Benacerraf BR, Shipp TD, Bromley B, Levine D. What does magnetic resonance imaging add to the prenatal sonographic diagnosis of ventriculomegaly? *J Ultrasound Med* 2007; **26**: 1513–1522.
26. Barseghyan K, Jackson HA, Chmait R, De Filippo RE, Miller DA. Complementary roles of sonography and magnetic resonance imaging in the assessment of fetal urinary tract anomalies. *J Ultrasound Med* 2008; **27**: 1563–1569.
27. Limperopoulos C, Robertson RL Jr, Khwaja OS, Robson CD, Estroff JA, Barnewolt C, Levine D, Morash D, Nemes L, Zaccagnini L, du Plessis AJ. How accurately does current fetal imaging identify posterior fossa anomalies? *AJR Am J Roentgenol* 2008; **190**: 1637–1643.
28. Papadiaz A, Miller C, Martin WL, Kilby MD, Sgouros S. Comparison of prenatal and postnatal MRI findings in the evaluation of intrauterine CNS anomalies requiring postnatal neurosurgical treatment. *Childs Nerv Syst* 2008; **24**: 185–192.
29. Rajeswaran R, Chandrasekharan A, Joseph S, Venkata Sai PM, Dev B, Reddy S. Ultrasound versus MRI in the diagnosis of fetal head and trunk anomalies. *J Matern Fetal Neonatal Med* 2009; **22**: 115–123.
30. Abdelazim IA, Abdelrazak KM, Ramy AR, Mounib AM. Complementary roles of prenatal sonography and magnetic resonance imaging in diagnosis of fetal renal anomalies. *Aust N Z J Obstet Gynaecol* 2010; **50**: 237–241.
31. Alamo L, Laswad T, Schnyder P, Meuli R, Vial Y, Osterheld MC, Gudinchet F. Fetal MRI as complement to US in the diagnosis and characterization of anomalies of the genito-urinary tract. *Eur J Radiol* 2010; **76**: 258–264.
32. Behairy NH, Talaat S, Saleem SN, El-Raouf MA. Magnetic resonance imaging in fetal anomalies: What does it add to 3D and 4D US? *Eur J Radiol* 2010; **74**: 250–255.
33. Peruzzi P, Corbitt RJ, Raffel C. Magnetic resonance imaging versus ultrasonography for the in utero evaluation of central nervous system anomalies. *J Neurosurg Pediatr* 2010; **6**: 340–345.
34. Santos XM, Papanna R, Johnson A, Cass DL, Olutoye OO, Moise KJ Jr, Belleza-Bascon B, Cassidy CI. The use of combined ultrasound and magnetic resonance imaging in the detection of fetal anomalies. *Prenat Diagn* 2010; **30**: 402–407.
35. Yin S, Na Q, Chen J, Li-Ling J, Liu C. Contribution of MRI to detect further anomalies in fetal ventriculomegaly. *Fetal Diagn Ther* 2010; **27**: 20–24.
36. Amini H, Wikström J, Ahlström H, Axelsson O. Second trimester fetal magnetic resonance imaging improves diagnosis of non-central nervous system anomalies. *Acta Obstet Gynecol Scand* 2011; **90**: 380–389.
37. Kul S, Korkmaz HA, Cansu A, Dinc H, Ahmetoglu A, Guven S, Imamoglu M. Contribution of MRI to ultrasound in the diagnosis of fetal anomalies. *J Magn Reson Imaging* 2012; **35**: 882–890.
38. Capito C, Belarbi N, Paye Jaouen A, Leger J, Carel JC, Oury JF, Sebag G, El-Ghoneimi A. Prenatal pelvic MRI: additional clues for assessment of urogenital obstructive anomalies. *J Pediatr Urol* 2014; **10**: 162–166.
39. Garcia-Flores J, Recio M, Uriel M, Canamares M, Cruceyra M, Tamarit I, Carrascoso J, Espada M, Sainz de la Cuesta R. Fetal magnetic resonance imaging and neurosonography in congenital neurological anomalies: supplementary diagnostic and postnatal prognostic value. *J Matern Fetal Neonatal Med* 2013; **26**: 1517–1523.
40. Wang G, Shan R, Zhao L, Zhu X, Zhang X. Fetal cleft lip with and without cleft palate: comparison between MR imaging and US for prenatal diagnosis. *Eur J Radiol* 2011; **79**: 437–442.
41. Verburg B, Fink AM, Reidy K, Palma-Dias R. The contribution of MRI after fetal anomalies have been diagnosed by ultrasound: correlation with postnatal outcomes. *Fetal Diagn Ther* 2015; **38**: 186–194.
42. Kandula T, Fahey M, Chalmers R, Edwards A, Shekleton P, Teoh M, Clark J, Goergen SK. Isolated ventriculomegaly on prenatal ultrasound: what does fetal MRI add? *J Med Imaging Radiat Oncol* 2015; **59**: 154–162.
43. Rossi AC, Prefumo F. The additional value of fetal magnetic resonance imaging in the prenatal diagnosis of central nervous system anomalies: a systematic review of the literature. *Ultrasound Obstet Gynecol* 2014; **44**: 388–393.
44. Malinge G, Lev D, Lerman-Sagie T. Fetal central nervous system: MR imaging versus dedicated US – need for prospective, blind, comparative studies. *Radiology* 2004; **232**: 306; author reply 306–307.
45. Lachenbruch PA, Lynch CJ. Assessing screening tests: extensions of McNemar's test. *Stat Med* 1998; **17**: 2207–2217.
46. Lee W, Comstock CH, Kazmierczak C, Wilson J, Gonçalves LF, Mody S, Yeo L, Romero R. Prenatal diagnostic challenges and pitfalls for schizencephaly. *J Ultrasound Med* 2009; **28**: 1379–1384.
47. Griffiths PD, Porteous M, Mason G, Russell S, Morris J, Fanou EM, Reeves MJ. The use of in utero MRI to supplement ultrasound in the foetus at high risk of developmental brain or spine abnormality. *Br J Radiol* 2012; **85**: e1038–1045.
48. Salomon LJ, Ouahba J, Delezoide AL, Vuillard E, Oury JF, Sebag G, Garel C. Third-trimester fetal MRI in isolated 10- to 12-mm ventriculomegaly: is it worth it? *BJOG* 2006; **113**: 942–947.
49. Twickler DM, Magee KP, Caire J, Zaretsky M, Fleckenstein JL, Ramus RM. Second-opinion magnetic resonance imaging for suspected fetal central nervous system abnormalities. *Am J Obstet Gynecol* 2003; **188**: 492–496.
50. Malinge G, Ben-Sira L, Lev D, Ben-Aroya Z, Kidron D, Lerman-Sagie T. Fetal brain imaging: a comparison between magnetic resonance imaging and dedicated neurosonography. *Ultrasound Obstet Gynecol* 2004; **23**: 333–340.
51. Paladini D, Quarantelli M, Sglavo G, Pastore G, Cavallaro A, D'Armierto MR, Salvatore M, Nappi C. Accuracy of neurosonography and MRI in clinical management of fetuses referred with central nervous system abnormalities. *Ultrasound Obstet Gynecol* 2014; **44**: 188–196.
52. Arangio P, Manganaro L, Pacifici A, Basile E, Cascone P. Importance of fetal MRI in evaluation of craniofacial deformities. *J Craniofac Surg* 2013; **24**: 773–776.
53. Robinson AJ, Blaser S, Vladimirov A, Drossman D, Chitayat D, Ryan G. Foetal “black bone” MRI: utility in assessment of the foetal spine. *Br J Radiol* 2015; **88**: 20140496.

## SUPPORTING INFORMATION ON THE INTERNET

The following supporting information may be found in the online version of this article:



**Table S1** Typical workflow for fetal magnetic resonance imaging protocol used in the study

**Table S2** Descriptive categorization of findings on two-dimensional ultrasound (2D-US), three-dimensional ultrasound (3D-US) and fetal magnetic resonance imaging (MRI) and the definitive postnatal diagnosis in cases with major central nervous system (CNS) anomalies

**Table S3** Descriptive categorization of findings on two-dimensional ultrasound (2D-US), three-dimensional ultrasound (3D-US) and fetal magnetic resonance imaging (MRI) and the definitive postnatal diagnosis, in cases with major anomalies involving body systems other than the central nervous system (CNS)

**Figure S1** (a) Two-dimensional ultrasound (2D-US) with four-chamber view in a fetus (Case 150) at 20 + 1 weeks' gestation, showing large anechoic fluid collection surrounding the heart, consistent with pericardial effusion, displacing the lungs posteriorly. (b) Similar findings were seen on multiplanar three-dimensional ultrasound 3D-US in axial (panel A), sagittal (panel B) and coronal (panel C) planes. (c) Axial T2-weighted fetal magnetic resonance imaging shows bilateral hyperintense fluid surrounding the heart. (d) 2D-US at 31 + 3 weeks shows spontaneous resolution of the pericardial effusion. F, fluid; H, heart; L, lung.