

# Sonographically Guided Posterior Subtalar Joint Injections via the Sinus Tarsi Approach

Jay Smith, MD, Eugene Maida, MB, ChB, Naveen S. Murthy, MD, Eugene Y. Kissin, MD, Jon A. Jacobson, MD

Received February 10, 2014, from the Departments of Physical Medicine and Rehabilitation (J.S.), Radiology (J.S., N.S.M.), and Anatomy (J.S.), Mayo Clinic College of Medicine, Rochester, Minnesota USA; Department of Physical Medicine and Rehabilitation, McMaster University, Hamilton, Ontario, Canada (E.M.); Division of Rheumatology, Boston University School of Medicine, Boston, Massachusetts USA (E.Y.K.); and Department of Radiology, University of Michigan, Ann Arbor, Michigan USA (J.A.J.). Revision requested February 28, 2014. Revised manuscript accepted for publication May 4, 2014.

We thank the Opus Imaging Research Facility at the Mayo Clinic for assisting with the computed tomographic scanning, the staff of the Mayo Clinic Procedural Skills Laboratory, and the noble generosity of the Mayo Clinic's whole-body donors whose altruistic gift made this study possible. This work was supported by Mayo Clinic Institutional Funds from the Departments of Physical Medicine and Rehabilitation and Radiology and the Mayo Clinic Sports Medicine Center.

Address correspondence to Jay Smith, MD, Department of Physical Medicine and Rehabilitation, Mayo Clinic College of Medicine, Mayo Building, 200 First St SW, 14th Floor, Rochester, MN 55905 USA.

E-mail: smith.jay@mayo.edu

## Abbreviations

ASTJ, anterior subtalar joint; BMI, body mass index; CT, computed tomographic; PSTJ, posterior subtalar joint

doi:10.7863/ultra.34.1.83

**Objectives**—To determine the feasibility and accuracy of sonographically guided posterior subtalar joint (PSTJ) injections performed through the sinus tarsi.

**Methods**—A single experienced operator completed 10 sonographically guided PSTJ injections via the sinus tarsi on 10 unembalmed cadaveric ankle-foot specimens. Injections were performed using a 17–5-MHz linear transducer, a 25-gauge, 50-mm needle, and an out-of-plane, anterior-to-posterior needle trajectory parallel to the calcaneal surface. Sonographic assessment for fluid in the posterior and lateral PSTJ recesses, sinus tarsi, and peroneal tendon sheath was performed before and after injections of 2 and 4 mL of tap water. Two additional specimens were injected with a contrast agent: 1 via the sonographically guided approach and another by a computed tomographically guided approach.

**Results**—All 10 sonographically guided PSTJ tap water injections were accurate, distending both the posterior and lateral PSTJ recesses. In addition, all 10 specimens showed posterior recess distension by 2 mL, whereas only 2 specimens (20%) showed lateral recess distension at this volume. By 4 mL, both recesses were clearly distended in all specimens. Both contrast agent injections produced similar PSTJ computed tomographic arthrograms and patterns of recess distension similar to the sonographically guided tap water injections. No sonographically guided PSTJ injection placed fluid in the peroneal tendon sheath.

**Conclusions**—Sonographically guided PSTJ injections via the sinus tarsi can accurately and specifically deliver injectate into the PSTJ while monitoring injectate flow within the posterior recess. The sinus tarsi approach may be used as an alternative technique to perform sonographically guided PSTJ injections when clinically appropriate.

**Key Words**—ankle; injection; musculoskeletal ultrasound; sinus tarsi; sonography; subtalar

The posterior subtalar joint (PSTJ) is a well-documented source of ankle and hindfoot pain and may result in considerable disability.<sup>1–10</sup> The role of diagnostic and therapeutic PSTJ injections has been firmly established in clinical practice.<sup>1,2,8,9,11–13</sup> Due to the complex and often pathologically distorted anatomy of the PSTJ, image guidance is commonly recommended to ensure accurate needle placement within the PSTJ.<sup>1,2,9,14,15</sup> Although computed tomographic (CT) and fluoroscopic guidance has been successfully used for this purpose, 3 sonographically guided PSTJ injection techniques have recently been described and validated in cadaveric investigations.<sup>5,9,10,14–17</sup> Despite the fact that sonography provides the advantages of portability, procedural

flexibility, and lack of ionizing radiation, published sonographically guided PSTJ techniques are not without limitations.<sup>5,10,18,19</sup> The posteromedial approach requires needle passage in close proximity to the tibial neurovascular bundle.<sup>5</sup> The posterolateral approach may be technically challenging due to the ergonomics of targeting the deeply located posterior PSTJ recess and may result in inadvertent puncture of the flexor hallucis longus tendon sheath.<sup>5</sup> Although the anterolateral approach targeting the lateral PSTJ recess was preferred by the authors of the previous study and has been successful in clinical practice, the narrow acoustic window for needle passage may render the described out-of-plane needle approach challenging in some clinical circumstances.<sup>5,10</sup> It is also noteworthy that prior authors have highlighted the fact that image-guided injections targeting the lateral PSTJ recess may be impeded by congenital (eg, fibular overhang), degenerative (eg, osteophytes and narrowing) or postsurgical (eg, hardware) changes in this region.<sup>6,9,10</sup>

The sinus tarsi is a cone-shaped opening in the anterolateral ankle located between the talar neck and anterosuperior calcaneus.<sup>7,8,13,20–22</sup> The sinus tarsi extends posteromedially, where it transitions into the tarsal canal and eventually exits above the sustentaculum tali.<sup>8,13</sup> The contents of the sinus tarsi include fibrofatty tissue containing a fine neurovascular network and several ligamentous structures that function to control talocalcaneal motion and stability: the cervical ligament, interosseous talocalcaneal ligament, and medial and intermediate roots of the inferior extensor retinaculum.<sup>7,8,13,20,23</sup> The sinus tarsi is bordered posteriorly on its calcaneal side by the PSTJ, which is separated from the sinus tarsi by a capsule and in more than 95% of cases a relatively thick ( $1.4 \pm 0.4$  mm) anterior capsular ligament.<sup>20</sup> Although the sinus tarsi is typically discussed in the context of sinus tarsi syndrome, subtalar instability, or periarticular ganglion cysts, it also provides potential access to the PSTJ for diagnostic or therapeutic injections. However, to our knowledge, techniques to inject the PSTJ via the sinus tarsi have not been formally described.

The primary purpose of this investigation was to describe and validate a technique for sonographically guided PSTJ injections performed via the sinus tarsi. On the basis of the known regional anatomy and our preliminary cadaveric and clinical experience, we hypothesized that the PSTJ could be injected with 100% accuracy through the sinus tarsi, as demonstrated in a cadaveric model. Validating the sonographically guided PSTJ injection technique via the sinus tarsi approach would have 2 important clinical implications: (1) provide an alternative route for accurate PSTJ injections when more traditional PSTJ injection approaches

are either not feasible or undesirable; and (2) provide the opportunity for combined PSTJ and sinus tarsi injections using a single needle when clinically indicated.

## Materials and Methods

### General Design

The study consisted of 2 parts, a sonographic component and a CT component. For the sonographic component, the primary investigator (J.S.) performed sonographically guided PSTJ injections via the sinus tarsi approach on 10 unembalmed cadaveric ankle-foot specimens while monitoring PSTJ recess distension sonographically. All 10 injections were completed in the Mayo Clinic Procedural Skills Laboratory, and the primary investigator had more than 8 years of experience in diagnostic and interventional musculoskeletal sonography at the time of the investigation. For the second part of the study, 2 additional specimens were injected in the Mayo Clinic Opus Imaging Research Facility, where CT scanning was available. On the first specimen, the primary investigator performed a single sonographically guided PSTJ injection via the sinus tarsi using a diluted iodinated contrast agent. On the second, a study coinvestigator (N.S.M.), a board-certified, musculoskeletal fellowship-trained radiologist with experience in CT-guided ankle-foot injections, performed a CT-guided PSTJ contrast agent injection from a lateral approach.<sup>16</sup> Contrast flow patterns were assessed with CT. All anatomic specimens for both parts of the investigation were obtained through the Department of Anatomy's Mayo Foundation Bequest Program, were fully thawed at room temperature immediately before use, and were free of signs of surgery, trauma, or major deformity around the foot and ankle region. This research was approved by the Mayo Clinic's Bio-Specimens Subcommittee of the Institutional Review Board.

### Anatomic Specimens

A total of 12 unembalmed cadaveric ankle-foot specimens were used for this investigation. Age, sex, body mass index (BMI), and side (left, right, or both) were recorded for each donor. Specimens were obtained on the basis of availability and therefore were not necessarily paired (ie, left and right ankle-foot specimens from the same donor). In addition, no specific measures were taken to ensure an equal number of left and right ankle-foot specimens.

### Equipment

The 10 primary sonographically guided PSTJ injections performed in the Procedural Skills Laboratory were completed using an iU22 ultrasound machine and a 17–5-MHz

linear array transducer (Philips Healthcare, Bothell, WA). The sonographically guided PSTJ injection performed for CT validation was completed using a CX50 portable ultrasound machine and a 12–3-MHz linear array transducer (Philips Healthcare). The CT-guided PSTJ injection and the CT scans after both the sonographically guided and CT-guided injections were performed using a Sensation 64 scanner (GE Healthcare, Waukesha, WI) with the following parameters: collimation, 12 × 0.3 mm; pitch, 0.8; reconstruction slice and increment, 0.4 to 0.6 and 0.2 to 0.6 mm; tube voltage, 140 kV (peak); and tube current, 250 mA. All injections were performed using 25-gauge, 38- or 50-mm stainless steel needles.

### ***Sonographically Guided PSTJ Injections via the Sinus Tarsi***

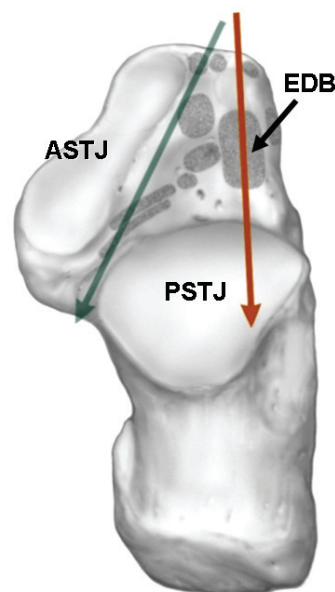
The primary investigator (J.S.) completed all sonographically guided PSTJ injections during this investigation. Although traditional sinus tarsi injections direct the needle parallel to the sinus tarsi and tarsal canal, from anterolateral to posteromedial, a preliminary investigation determined that this trajectory was not reliable for PSTJ access.<sup>4,21</sup> An anterior-to-posterior trajectory maintaining the needle parallel and superjacent to the calcaneus was subsequently determined to optimally direct the needle through the anterior aspect of the PSTJ and was therefore used for this study (Figure 1).

The procedure for the sonographically guided PSTJ injection via the sinus tarsi is shown in Figure 2. To perform the PSTJ injection, the ankle-foot specimen was first placed in a relaxed position of plantar flexion and inversion. The posterior PSTJ recess, lateral PSTJ recess, and peroneal tendon sheath were imaged using light transducer pressure to document any baseline fluid. Thereafter, the sinus tarsi was either directly palpated or identified by scanning proximally from the third intermetatarsal space, as previously described.<sup>21</sup> In either case, the bony calcaneal and talar margins were visualized with the transducer in a coronal oblique plane at the level of the sinus tarsi. Thereafter, the transducer was repositioned and the image adjusted to provide the best view of the sinus tarsi's depth and its lateral calcaneal margin. The presence of any baseline fluid was recorded. A 25-gauge, 50-mm stainless steel needle attached to a 12-mL syringe was then advanced using an out-of-plane, anterior-to-posterior approach into the sinus tarsi. The needle trajectory was chosen to pass the needle just superficial and parallel to the superior aspect of the calcaneus. Once the needle advanced to the depth, the tip often became challenging to visualize. Although tip visualization could be obtained via fine trans-

ducer manipulation in the out-of-plane view or by switching to an in-plane view, it was deemed unnecessary, as bone contact typically occurred as needle tip visualization deteriorated. At this point, the needle tip was directed through the anterior capsule of the PSTJ, and the capsular penetration was generally easily perceived.

Once the needle penetrated the anterior PSTJ capsule, 2 mL of normal tap water was injected under low pressure, followed by rescanning of the recesses, sinus tarsi, and peroneal tendon sheath using light transducer pressure. The presence of any fluid-induced distension was assessed qualitatively by visually determining whether the recess had enlarged relative to baseline. Thereafter, without changing the needle position, an additional 2 mL of normal tap water were injected (for a total of 4 mL). At this point, the recesses, sinus tarsi, and peroneal tendon sheath were rescanned and results recorded. In addition, distension of

**Figure 1.** Anatomic drawing of the superior calcaneal surface viewed from above after removal of the talus, showing the calcaneal facets contributing to the PSTJ and ASTJ. The ASTJ consists of middle and anterior facets, which are continuous (as depicted in this drawing). The sinus tarsi and tarsal canal separate the ASJT and PSTJ. The green arrow depicts the typical anterolateral-to-posteromedial needle trajectory used for a sinus tarsi injection. This trajectory approximates the direction of the tarsal canal and may therefore miss the PSTJ. The red arrow depicts the anterior-to-posterior needle trajectory used in this investigation to inject the PSTJ via the sinus tarsi. Note the expected needle passage through the extensor digitorum brevis (EDB) en route to the anterior aspect of the PSTJ. Additional shaded areas represent attachments of ligamentous structures associated with the sinus tarsi region. Bottom is posterior; left, medial; right, lateral; and top, anterior.



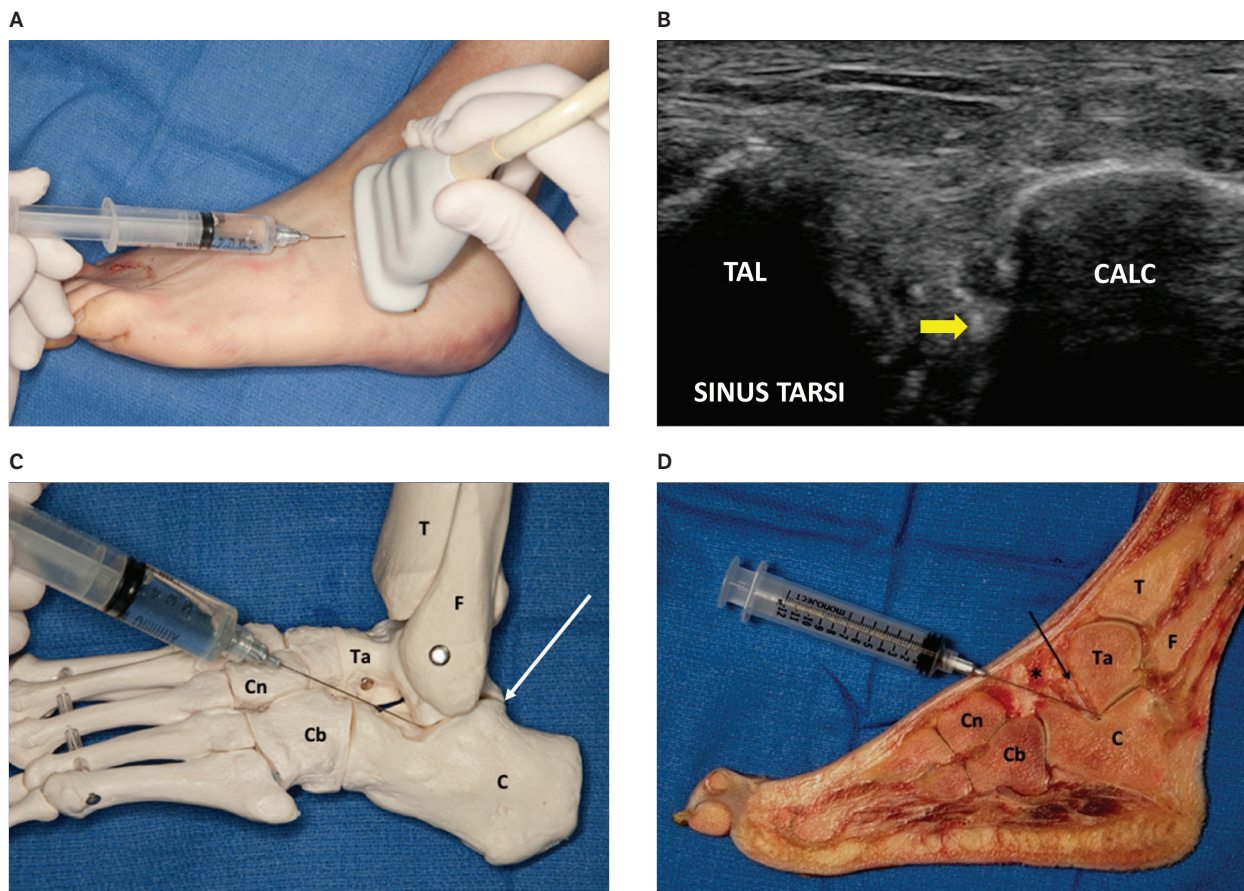


the middle facet of the anterior subtalar joint (ASTJ) was sonographically assessed as a control. The ASTJ, also known as the talocalcaneonavicular joint, is separated from the PSTJ by the sinus tarsi and tarsal canal (Figure 1). Although the ASTJ, sinus tarsi contents, and PSTJ combine to form the subtalar or talocalcaneal joint complex, the ASTJ is anatomically distinct from the PSTJ; therefore, injectate placed into the PSTJ would not be expected to appear in the ASTJ.

### Computed Tomographic Assessment of PSTJ Injection

For the CT portion of the investigation, 2 additional cadaveric specimens were used. In the first specimen, the primary investigator (J.S.) completed a sonographically guided PSTJ injection using the technique described above combined with extension tubing to inject 20% diluted iohexol (Omnipaque 300; GE Healthcare) into the PSTJ. Computed tomographic scanning was performed before injection and after 2- and 4-mL total volume injections.

**Figure 2.** **A**, Setup for sonographically guided PSTJ injection via the sinus tarsi approach. The transducer is placed across the sinus tarsi, bridging between the talar neck and the superior calcaneus. The needle is advanced using an out-of-plane, anterior-to-posterior approach, keeping the needle on the calcaneal side of the sinus tarsi. **B**, Corresponding sonographic view of a PSTJ injection via the sinus tarsi. The funnel-shaped opening of the sinus tarsi is bordered by the calcaneus (CALC) and talus (TAL). The yellow arrow identifies the echogenic tip of the 25-gauge stainless steel needle en route to the anterior aspect of the PSTJ. Note that the needle tip courses just adjacent to the calcaneal surface. The needle is advanced along this trajectory until encountering bone, which represents the entry point into the PSTJ. Bottom is deep/posterior; left, superior/dorsal; right, inferior/plantar; and top, superficial/anterior. **C**, Depiction of the needle trajectory relative to sonographically identifiable bony acoustic landmarks. Once again, note the needle passage adjacent and superficial to the superior calcaneal surface. The needle tip has been placed into the PSTJ. The white arrow indicates the posterior aspect of the PSTJ, formed by the posterior process of the talus and the superior calcaneal surface. Distension of the posterior recess in this region can be used to confirm accurate needle placement (see “Materials and Methods,” “Discussion,” and Figure 3). Compare with A and D. C indicates calcaneus; Cb, cuboid; Cn, cuneiform; F, fibula; T, tibia; and Ta, talus. **D**, Sagittal anatomic specimen correlating with **C**. The asterisk indicates the sinus tarsi. The needle has been placed into the PSTJ via the sinus tarsi. The black arrow represents the medial root of the inferior extensor retinaculum.



The purpose of these injections was to show via CT arthrography that the PSTJ injection via the sinus tarsi produces a typical PSTJ CT arthrogram.

In the second specimen, an experienced study coinvestigator (N.S.M.) completed a single CT-guided PSTJ injection in an additional specimen using a lateral approach, as described by Saifuddin and colleagues.<sup>16</sup> The hindfoot was placed with the medial side down on the CT scanner table and the plantar surface of the foot positioned parallel to the side of the scanner table. A preliminary scan was taken through the hindfoot with an overlying skin marker to precisely identify the lateral opening of the PSTJ. The CT scanner table was brought to the exact position where the PSTJ was best seen in the CT images and marked on the skin surface using the laser crossbeam. A 25-gauge, 38-mm stainless steel needle was then advanced into the lateral aspect of the PSTJ using CT guidance. Once the needle position was confirmed, a 12-mL syringe with short extension tubing containing a 20% dilution of Omnipaque 300 was injected into the PSTJ at 2-mL increments until a total volume of 6 mL had been injected. Although the average volume of the native PSTJ has been estimated to range from 3 to 5 mL, we intentionally completed a 6-mL total volume injection to maximally distend all recesses in this single specimen.<sup>8,9,13</sup> During the injection sequence, as was the case for the sonographically guided PSTJ contrast agent injection, CT images were obtained to document contrast flow after each 2-mL incremental injection. The purpose of this injection was to prove that the PSTJ CT arthrogram obtained using a well-accepted CT-guided approach is similar to that obtained using the sonographically guided sinus tarsi approach.

### Assessment

The accuracy of the 10 primary sonographically guided PSTJ injections completed by the primary investigator in the Procedural Skills Laboratory was assessed by sonographic documentation of distension of the posterior and lateral PSTJ recesses. Posterior and lateral PSTJ recess distension was documented at baseline and after the 2- and 4-mL total volume injections. In addition, the presence of fluid in the peroneal tendon sheath and sinus tarsi was determined for each condition. Finally, the presence of fluid within the middle facet of the ASTJ was assessed after the 4-mL total volume injection.

The sonographically guided and CT-guided PSTJ contrast agent injections performed in the Opus Imaging Research Facility were assessed by the coinvestigator for contrast flow within the PSTJ, distension of the posterior and lateral PSTJ recesses, contrast flow within the sinus

tarsi (ie, distension of the anterior recess), and contrast flow to regions outside the PSTJ. Assessment was performed for both the sonographically guided and CT-guided PSTJ injections at baseline and after the 2- and 4-mL total volume injections and again after the 6-mL total volume CT-guided injection.

### Statistics

Descriptive statistical analyses were performed to describe donor age, sex, and BMI for all specimens used during the investigation. For the 10 primary sonographically guided PSTJ injections performed via the sinus tarsi approach, descriptive statistics were used to describe: (1) PSTJ accuracy as determined by distension of the posterior and lateral PSTJ recesses; (2) the frequency of posterior and lateral PSTJ recess distension after the 2- and 4-mL total volume injections; (3) the frequency of peroneal tendon sheath fluid after the 2- and 4-mL total volume injections; (4) the frequency of fluid within the sinus tarsi after the 2- and 4-mL total volume injections; and (5) the frequency of fluid within the middle facet of the ASTJ after the 4-mL total volume injection.

For the sonographically guided and CT-guided PSTJ contrast agent injections, CT images were interpreted at each incremental injection volume to assess injection accuracy, as determined by the appearance of a typical PSTJ arthrogram. In addition, posterior PSTJ recess distension, lateral PSTJ recess distension, and the presence of contrast in the peroneal tendon sheath were assessed after the 2- and 4-mL total volume injections. A final assessment of contrast flow was completed on the specimen receiving a CT-guided injection after the 6-mL total volume injection.

### Results

A total of 10 sonographically guided PSTJ tap water injections via the sinus tarsi were completed on 10 unembalmed cadaveric ankle-foot specimens (6 right and 4 left) obtained from 6 male donors with a mean age of 81.7 years (range, 72–92 years) and an average BMI of 25.7 kg/m<sup>2</sup> (range, 15.7–38.4 kg/m<sup>2</sup>). Preinjection scanning showed no appreciable fluid within the PSTJ recesses, sinus tarsi, peroneal tendon sheath, or middle facet of the ASTJ. No technical limitations were encountered during these injections. All 10 PSTJ injections were accurate, as demonstrated by distension of both the posterior and lateral PSTJ recesses after the 4-mL total volume injection. All 10 specimens (100%) had also showed unequivocal posterior recess distension by the end of the 2-mL injection, whereas only 2 specimens (20%) showed lateral recess distension at this injection vol-

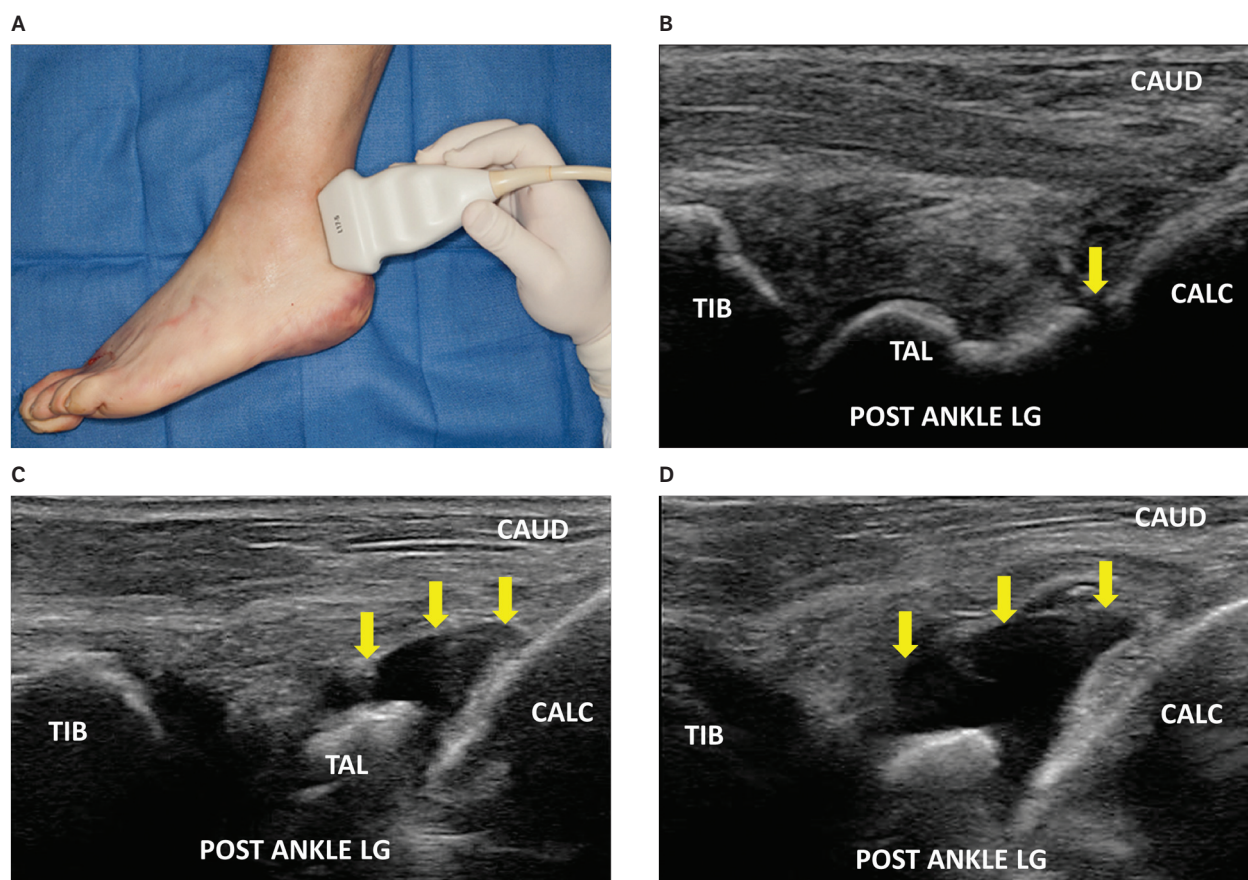


ume (Figures 3 and 4). Although no specimen showed fluid in the sinus tarsi at 2 mL, by 4 mL, all 10 specimens (100%) showed fluid emerging from the depth on the calcaneal side of the sinus tarsi and displacing the sinus tarsi contents superficially (Figure 5). No fluid was seen in the peroneal tendon sheath or middle facet of the ASTJ in any specimen at any injection volume. In summary, by the time 2 mL had been injected, fluid was visualized in the posterior recess 100% of the time but in the lateral recess only 20% of the time. By the 4-mL total injection volume, both the posterior and lateral recesses were clearly distended in

all specimens (the posterior recess being distended to a greater degree in all specimens), and fluid had also appeared in the depth of the sinus tarsi on the calcaneal side in all specimens. No fluid was visualized in the peroneal tendon sheath or middle facet of the ASTJ in any specimen at any volume.

The single sonographically guided PSTJ contrast agent injection via the sinus tarsi approach was completed on a left ankle-foot specimen obtained from a 77-year-old male donor with a BMI of 23.5 kg/m<sup>2</sup>. Preinjection CT scanning showed no appreciable fluid within the PSTJ

**Figure 3.** **A**, Transducer position for assessing distension of the posterior recess of the PSTJ during sonographically guided PSTJ injection via the sinus tarsi. Note the necessary angulation of the transducer to direct the ultrasound beam toward the posterior recess. Underlying bony anatomy is as shown in Figure 2C. **B**, Correlative sonogram of a cadaveric specimen before injection obtained with the transducer positioning shown in **A**. The echogenic bony surfaces of the posterior calcaneus (CALC), talus (TAL), and tibia (TIB) are clearly shown. The yellow arrow indicates the nondistended posterior recess of the PSTJ. Bottom is deep/anterior; left, cephalad; right, caudad (CAUD); and top, superficial/posterior. POST ANKLE LG indicates posterior longitudinal view of the ankle region. **C**, Same specimen after injection of 2 mL of normal tap water using the sinus tarsi approach to the PSTJ. After needle placement, the transducer is repositioned over the posterolateral ankle region, as shown in **A**. Light transducer pressure is mandatory. At 2 mL, all specimens showed clear posterior recess distension, as shown here, whereas only 2 of 10 specimens showed lateral recess distension (see Figure 4). Orientation and labels are as in **B**. **D**, Same specimen after a 4-mL total volume injection. There is marked posterior recess distension but no evidence of capsular rupture. At this injectate volume, all 10 specimens also showed lateral recess distension (see Figure 4). Orientation and labels are as in **B**.



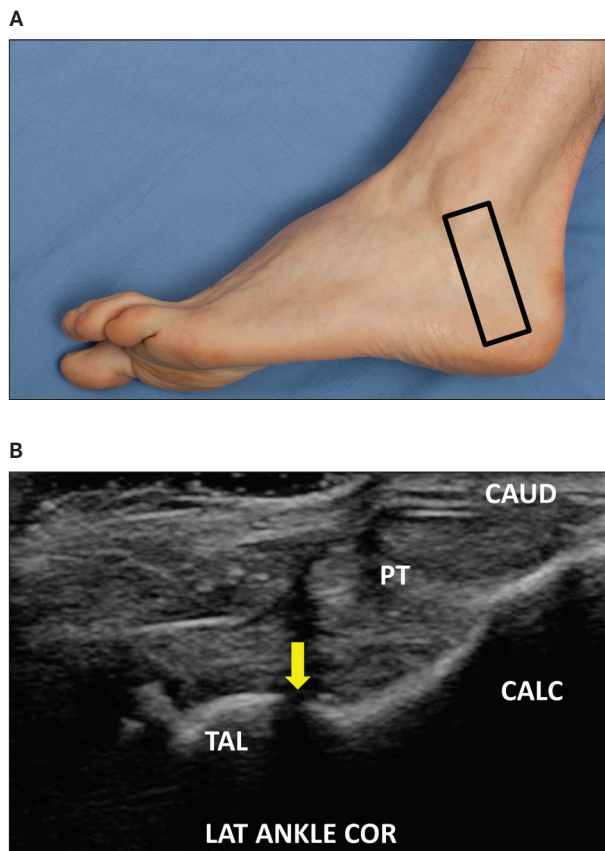
recesses, sinus tarsi, peroneal tendon sheath, or middle facet of the ASTJ. No technical limitations were encountered during this injection. The CT contrast pattern for this injection paralleled that for the sonographically guided PSTJ tap water injections (Figure 6). By 2 mL, a PSTJ CT arthrogram was visualized, accompanied by clear distension of the posterior PSTJ recess but minimal distension of the lateral PSTJ recess. At 4 mL, the lateral PSTJ recess was also clearly distended, although the extent of posterior PSTJ recess distension was still greater. In addition, at 4 mL, contrast clearly distended the anterior aspect of the PSTJ and flowed into the calcaneal side of the sinus tarsi, as had been shown on the sonographically guided tap water injections (Figures 5 and 6C). No contrast was seen in the peroneal tendon sheath or ASTJ (middle facet and talonavicular joint, the latter of which was also visualized by CT; Figure 6C).

The single CT-guided PSTJ contrast agent injection via the lateral approach was completed on a right ankle-foot specimen obtained from an 84-year-old male donor with a BMI of 26.1 kg/m<sup>2</sup>. Preinjection CT scanning showed no appreciable fluid within the PSTJ recesses, sinus

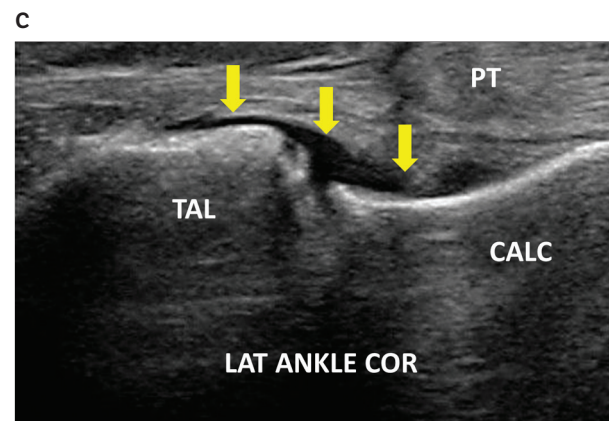
tarsi, peroneal tendon sheath, or middle facet of the ASTJ. No technical limitations were encountered during this injection. The CT findings during this injection matched those of the sonographically guided PSTJ contrast agent injection at both 2 and 4 mL, with the exception of the observation that by 4 mL, contrast was noted in the peroneal tendon sheath (Figure 7A). At 6 mL, disruption of the posterior PSTJ recess and anterior capsule of the PSTJ was evident, as shown by irregular contrast flow into the Kager fat pad and sinus tarsi, respectively (Figure 7B). Despite the presumed PSTJ capsuloligamentous rupture, no contrast was visualized in the ASTJ (middle facet and talonavicular joint), confirming the previously noted anatomic discontinuity between the ASTJ and PSTJ of the subtalar joint complex (Figure 7A).

### Discussion

The primary finding of this investigation was that sonographically guided PSTJ injections via the sinus tarsi approach are feasible and can accurately and specifically deliver injectate into the PSTJ, as demonstrated in this



**Figure 4. A**, Transducer position (box) for assessing distension of the lateral recess of the PSTJ. The transducer is placed across the PSTJ approximately parallel to the calcaneofibular ligament (not shown) and anterior to the fibula. Similar to the posterior recess, light transducer pressure is mandatory. **B**, Correlative sonogram of the lateral recess (LAT ANKLE COR) after a 2-mL tap water injection into the PSTJ via the sinus tarsi. Despite the use of light transducer pressure, there is no clear distension (yellow arrow). Only 2 of 10 specimens showed appreciable lateral recess distension at 2 mL, suggesting that the lateral recess is not as sensitive as the posterior recess for detecting PSTJ distension during injection. Bottom is deep/medial; left, cephalad; right, caudad (CAUD); and top, superficial/lateral. CALC indicates calcaneus; PT, peroneal/fibular tendons; and TAL, talus. **C**, Same specimen after a 4-mL PSTJ injection. Lateral recess distension is clearly visible, as was the case in all 10 specimens at the 4-mL injection volume. Orientation and labels are as in **B**.



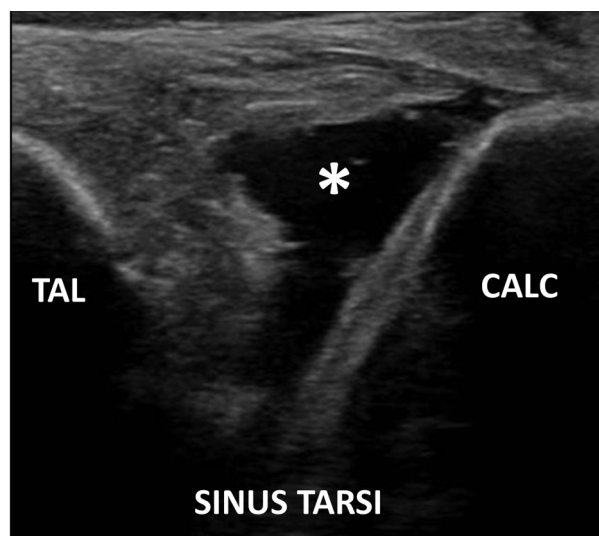
cadaveric model. Despite the fact that direct sonographic needle visualization within the PSTJ can be challenging using this approach, distension of the posterior PSTJ recess can be used to confirm accurate needle placement.

Several technical considerations are worthy of discussion with respect to the sinus tarsi approach to the PSTJ. First, the needle trajectory should be anterior to posterior and pass just superficial and adjacent to the superior surface of the calcaneus. The PSTJ lies on the calcaneal side of the sinus tarsi, and a posteromedial needle trajectory (as used for traditional “sinus tarsi” injection) will be less likely to enter the PSTJ.<sup>4,21</sup> In addition, keeping the needle close to the superior calcaneal surface reduces the likelihood of the needle hitting the anterior talar facet rather than passing between the talus and calcaneus (Figure 2, C and D). Second, as previously stated, accurate needle placement can be confirmed by the development of posterior PSTJ recess distension at a 2-mL injection volume (Figures 3, A–D, and 6, A and B). After observing the sensitivity of posterior recess distension in our first 5 specimens, the primary investigator elected to dynamically monitor the posterior recess during the subsequent 5 injections. In all 5 specimens, posterior recess distension was clearly evident between the 1- and 2-mL injection volumes. It cannot be overemphasized that during this assessment, the operator must use light transducer pressure to increase the ability to visualize the developing posterior recess effusion. Anchoring the caudad end of the transducer on the posterolateral calcaneus and floating the cephalad end over the soft tissues can assist in this regard. Although not examined as part of this investigation, in clinical practice, the anterior recess of the tibiotalar joint should also be assessed for distension when performing PSTJ anesthetic injection for arthrodesis preoperative planning, as the tibiotalar joint communicates with the PSTJ in up to 20% of the population.<sup>8,24</sup> Determining the complete distribution of an anesthetic injection is important in this scenario to identify the source of pain, as this information can be used to predict the site of a successful arthrodesis.<sup>17</sup> Third, although some operators are challenged by out-of-plane needle approaches, it is our opinion that the relatively large working space of the sinus tarsi provides greater opportunity to identify the needle tip, readjust as necessary, and appropriately track it to the target. The lack of major neurovascular structures within the sinus tarsi may also be reassuring to operators less experienced with out-of-plane injection techniques such as described herein (Figures 1 and 2B).<sup>21</sup> Nonetheless, in the primary investigator’s experience, the sonographically guided PSTJ injection via the sinus tarsi can be performed using an in-plane approach

with the transducer positioned in the axial plane at the level of the superior calcaneal surface and directed medially. The needle trajectory is the same as that used for the described out-of-plane approach (Figure 8). In our opinion, the choice of using an out-of-plane or in-plane approach for the injection described herein may largely be a matter of practitioner preference and patient-specific factors. Further experience and research pertaining to each approach may provide further clarification in this regard.

Although we did not directly compare the sinus tarsi approach to the previously published sonographically guided PSTJ techniques, accessing the PSTJ through the sinus tarsi provides several potential advantages. The sinus tarsi approach does not place the needle near major neurovascular structures as does the posteromedial approach and may be less likely to be impeded by congenital, post-traumatic, or postoperative anatomic changes than the anterolateral and posterolateral approaches.<sup>5,10</sup> Furthermore, as most patients with systemic polyarthritis involving the PSTJ will also have synovitis in the sinus tarsi, it may be desirable to access the sinus tarsi and PSTJ with a single needle for patient comfort and procedural efficiency.<sup>25</sup> This consideration may also be the case when treating patients with combined PSTJ pain and sinus tarsi syn-

**Figure 5.** Sonogram of the sinus tarsi in a cadaveric specimen using the transducer positioning shown in Figure 2, A and B. After a 4-mL PSTJ injection, fluid is shown emerging from the depth on the calcaneal side of the sinus tarsi (asterisk). This fluid is thought to represent distension of the anterior capsule of the PSTJ and suggests that PSTJ effusions may be visualized sonographically in the sinus tarsi. Bottom is deep/posterior; left, superior/dorsal; right, inferior/plantar; and top, superficial/anterior. CALC indicates calcaneus; and TAL, talus.





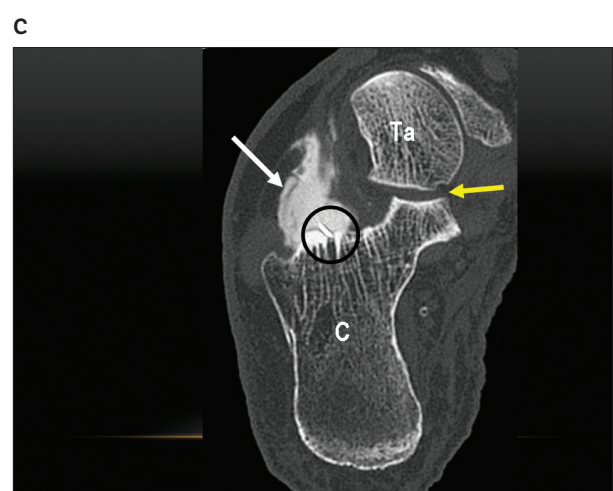
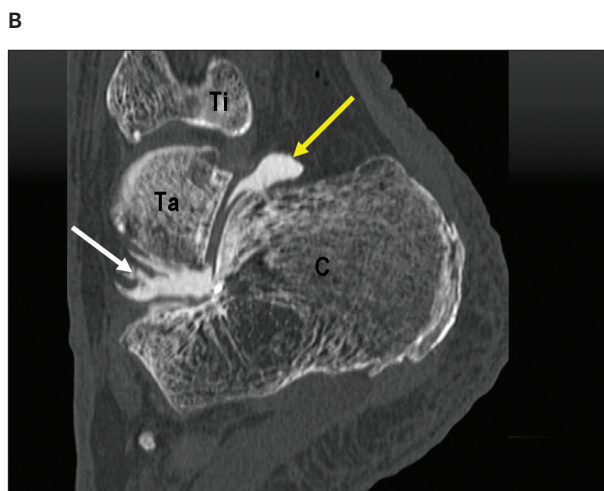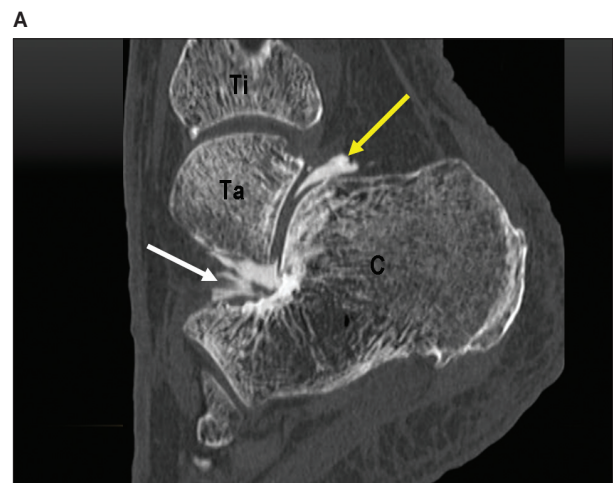drome or aspirating sinus tarsi ganglion cysts and injecting their joint of origin, which is typically the PSTJ.<sup>13,21,25</sup>

The use of CT during this investigation validated and reinforced our sonographic findings by allowing us to globally visualize contrast flow patterns after sonographically guided and CT-guided injections. Although executed through different approaches, the sonographically guided and CT-guided PSTJ contrast agent injections produced excellent and equivalent PSTJ arthrograms (Figures 3, C and D, and 6, A and B). Furthermore, the CT arthrograms showed a pattern of posterior-greater-than-lateral recess distension that paralleled the distension observed during the sonographically guided PSTJ tap water injections. Finally, CT confirmed the sonographic observation that accurately placed PSTJ injections do not flow into the

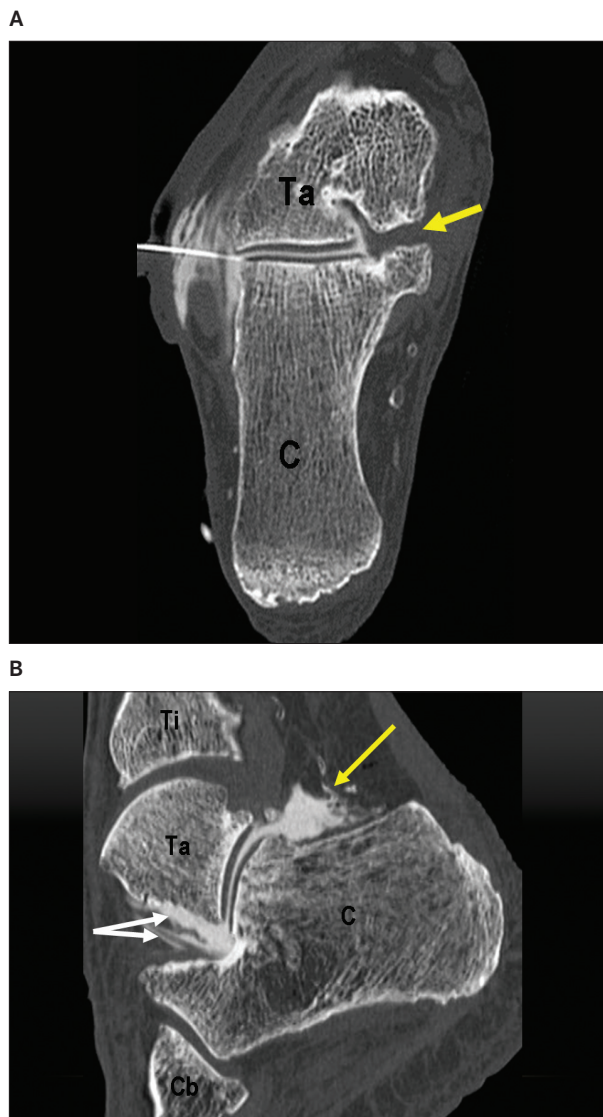
ASTJ under normal circumstances, confirming that these regions are anatomically distinct. This separation continued even during the 6-mL CT-guided contrast agent injection, which resulted in anterior and posterior PSTJ capsular ruptures (Figures 1, 6C, and 7A).

There are several potential study limitations that should be considered when interpreting the results of this investigation. First, operators should use appropriate caution when extrapolating our results in a relatively small number of normal cadaveric specimens to clinical populations. Reassuringly, the primary author has used the sinus tarsi approach on several patients with 100% accuracy, as demonstrated by posterior and lateral PSTJ recess distension. Second, a single experienced operator performed all sonographically guided injections during this study. The use

**Figure 6. A.** Sagittal postarthrographic CT scan of an anatomic specimen after sonographically guided PSTJ injection via the sinus tarsi with 2 mL of the diluted contrast agent. Clear distension of the posterior recess is shown (yellow arrow), correlating with Figure 3C. In addition, some contrast is also shown at the depth within the sinus tarsi (white arrow), although sinus tarsi distension was not appreciated sonographically at the 2-mL volume. Bottom is caudad; left, anterior; right, posterior; and top, cephalad. C indicates calcaneus; Ta, talus; and Ti, tibia. **B.** Same anatomic specimen after a total 4-mL diluted contrast agent injection. Compared with **A**, the posterior recess distension has increased, as has the presence of fluid within the sinus tarsi. These findings correlate sonographically with Figures 3D and 5. Orientation and labels are as in **A**. **C.** Axial oblique CT scan of the same specimen at the 4-mL contrast agent injection volume. From this perspective, the needle tip is shown in the anterior aspect of the PSTJ (black circle). White arrow indicates distension of the anterior aspect of the PSTJ emerging into the calcaneal portion of the sinus tarsi (compare with **B** and Figure 5); and yellow arrow, middle facet of the ASTJ devoid of contrast. Bottom is posterior; left, lateral; right, medial; and top, anterior. Labels are as in **A**.



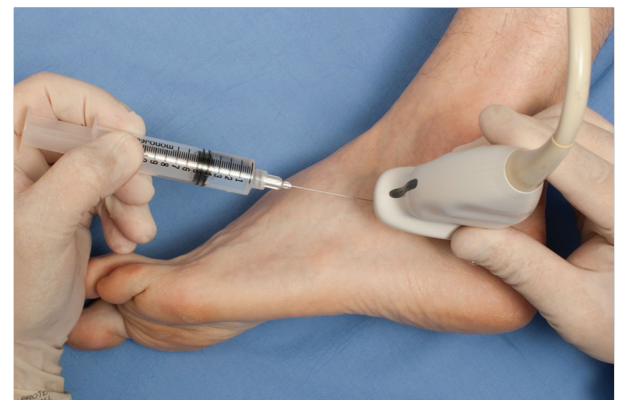**Figure 7. A,** Coronal oblique CT arthrogram showing the needle positioning for the CT-guided PSTJ injection performed using a lateral approach. After a 6-mL diluted contrast agent injection, contrast has appeared in the peroneal tendon sheath. However, no contrast is visualized in the middle facet of the ASTJ (yellow arrow) despite the large volume injection. Bottom is caudad/posterior; left, lateral; right, medial; and top, cephalad/anterior. C indicates calcaneus; and Ta, talus. **B,** Sagittal CT image of same anatomic specimen after the CT-guided 6-mL diluted contrast agent injection into the PSTJ. At 6 mL, there is disruption of the posterior capsule of the PSTJ with contrast extravasation into the Kager fat pad (yellow arrow). In addition, contrast is visualized extending to the surface of the sinus tarsi (top white arrow) and also surrounding the medial root of the inferior extensor retinaculum (bottom white arrow). These findings are suggestive of anterior capsular rupture. Despite the damage to the PSTJ capsule, contrast did not appear in the middle facet of the PSTJ, as shown in **A**. Bottom is caudad; left, anterior; right, posterior; and top, cephalad. Cb indicates cuboid; and Ti, tibia; other labels are as in **B**.



of a single operator was intentional to ensure technical consistency. Although the sinus tarsi approach may be more technically challenging for some operators, we believe that accuracy can be ensured by monitoring posterior recess distension, as previously discussed. Third, we did not assess for iatrogenic injury to the sinus tarsi structures as part of this investigation. Both image-guided and nonguided sinus tarsi injections have been performed for many years without reported complications. In our opinion, the sinus tarsi approach to the PSTJ described herein should not offer a different risk profile compared to the palpation- and image-guided sinus tarsi injections that have been performed for decades. Nonetheless, we typically use Doppler imaging during sinus tarsi procedures to avoid large vessels when possible.

In conclusion, sonographically guided PSTJ injections via the sinus tarsi can accurately and specifically deliver injectate into the PSTJ while monitoring injectate flow within the posterior recess. The sinus tarsi approach may be used as an alternative technique for performing sonographically guided PSTJ injections when clinically appropriate.

**Figure 8.** Setup for the in-plane approach for the PSTJ injection performed via the sinus tarsi. The transducer is placed in an anatomic axial plane parallel and just cephalad to the superior border of the anterior process of the calcaneus. The needle is advanced using an in-plane, anterior-to-posterior approach along a trajectory similar to Figure 2C. Note that the trajectory of the needle is slightly caudad in an anterior-to-posterior direction.



## References

- Cahill AM, Cho SS, Baskin KM, et al. Benefit of fluoroscopically guided intraarticular, long-acting corticosteroid injection for subtalar arthritis in juvenile idiopathic arthritis. *Pediatr Radiol* 2007; 37:544–548.
- Remedios D, Martin K, Kaplan G, Mitchell R, Woo P, Rooney M. Juvenile chronic arthritis: diagnosis and management of tibio-talar and subtalar disease. *Br J Rheumatol* 1997; 36:1214–1217.
- Tasto JP. Arthroscopy of the subtalar joint and arthroscopic subtalar arthrodesis. *Instr Course Lect* 2006; 55:555–564.
- Pisani G, Pisani PC, Parino E. Sinus tarsi syndrome and subtalar joint instability. *Clin Podiatr Med Surg* 2005; 22:63–77.
- Henning T, Finnoff JT, Smith J. Sonographically guided posterior subtalar joint injections: anatomic study and validation of 3 approaches. *PMR* 2009; 1:925–931.
- Kirk KL, Campbell JT, Guyton GP, Schon LC. Accuracy of posterior subtalar joint injection without fluoroscopy. *Clin Orthop Relat Res* 2008; 466:2856–2860.
- Lee KB, Bai LB, Song EK, Jung ST, Kong IK. Subtalar arthroscopy for sinus tarsi syndrome: arthroscopic findings and clinical outcomes of 33 consecutive cases. *Arthroscopy* 2008; 24:1130–1134.
- Resnick D. Radiology of the talocalcaneal articulations: anatomic considerations and arthrography. *Radiology* 1974; 111:581–586.
- Ruhoy MK, Newberg AH, Yodlowski ML, Mizel MS, Trepman E. Subtalar joint arthrography. *Semin Musculoskelet Radiol* 1998; 2:433–437.
- Smith J, Finnoff JT, Henning PT, Turner NS. Accuracy of sonographically guided posterior subtalar joint injections: comparison of 3 techniques. *J Ultrasound Med* 2009; 28:1549–1557.
- Beaudet F, Dixon AS. Posterior subtalar joint synoviography and corticosteroid injection in rheumatoid arthritis. *Ann Rheum Dis* 1981; 40:132–135.
- Bilstrom E, O'Rourke K, Deodhar A. Injection of the subtalar joint and sinus tarsi. *J Musculoskelet Med* 2008; 25:29–30.
- Lektrakul N, Chung CB, Lai YM, et al. Tarsal sinus: arthrographic, MR imaging, MR arthrographic, and pathologic findings in cadavers and retrospective study data in patients with sinus tarsi syndrome. *Radiology* 2001; 219:802–810.
- Lucas PE, Hurwitz SR, Kaplan PA, Dussault RG, Maurer EJ. Fluoroscopically guided injections into the foot and ankle: localization of the source of pain as a guide to treatment—prospective study. *Radiology* 1997; 204:411–415.
- Mitchell MJ, Bielecki D, Bergman AG, Kursunoglu-Brahme S, Sartoris DJ, Resnick D. Localization of specific joint causing hindfoot pain: value of injecting local anesthetics into individual joints during arthrography. *AJR Am J Roentgenol* 1995; 164:1473–1476.
- Saifuddin A, Abdus-Samee M, Mann C, Singh D, Angel JC. CT guided diagnostic foot injections. *Clin Radiol* 2005; 60:191–195.
- Khoury NJ, el-Khoury GY, Saltzman CL, Brandser EA. Intraarticular foot and ankle injections to identify source of pain before arthrodesis. *AJR Am J Roentgenol* 1996; 167:669–673.
- Smith J, Finnoff JT. Diagnostic and interventional musculoskeletal ultrasound, part 2: clinical applications. *PMR* 2009; 1:162–167.
- Smith J, Finnoff JT. Diagnostic and interventional musculoskeletal ultrasound, part 1: fundamentals. *PMR* 2009; 1:64–75.
- Jotoku T, Kinoshita M, Okuda R, Abe M. Anatomy of ligamentous structures of the tarsal sinus and canal. *Foot Ankle Int* 2006; 27:533–538.
- Wisniewski SJ, Smith J, Patterson DG, Carmichael SW, Pawlina W. Ultrasound-guided versus nonguided tibiotalar and sinus tarsi injections: a cadaveric study. *PMR* 2010; 2:277–281.
- Thacker P, Mardis N. Ligaments of the tarsal sinus: improved detection, characterisation and significance in the paediatric ankle with 3-D proton density MR imaging. *Pediatr Radiol* 2013; 43:196–201.
- Lee KB, Bai LB, Park JG, Song EK, Lee JJ. Efficacy of MRI versus arthroscopy for evaluation of sinus tarsi syndrome. *Foot Ankle Int* 2008; 29:1111–1116.
- Jacobson JA, Andersen R, Jaovisidha S, et al. Detection of ankle effusions: comparison study in cadavers using radiography, sonography, and MR imaging. *AJR Am J Roentgenol* 1998; 170:1231–1238.
- Maillefert JF, Dardel P, Cherasse A, Mistrh R, Krause D, Tavernier C. Magnetic resonance imaging in the assessment of synovial inflammation of the hindfoot in patients with rheumatoid arthritis and other polyarthritis. *Eur Radiol* 2003; 47:1–5.