

group and in all 8 patients in the control group. One implant from the control/cleft palate group failed before loading, while the rest of the implants were loaded successfully and remained stable at six months. The patients who did not receive implants were re-treated with autogenous block bone graft. Conclusion: The ability of stem cells to treat large alveolar defects is safe, yet, their ability to completely reconstitute large alveolar defects is limited, hence requiring further optimization.

Accepted Article

SCHOLARONE™
Manuscripts

This is the author manuscript accepted for publication and has undergone full peer review but has not been through the copyediting, typesetting, pagination and proofreading process, which may lead to differences between this version and the [Version record](#). Please cite this article as [doi:10.1111/cid.12506](https://doi.org/10.1111/cid.12506).

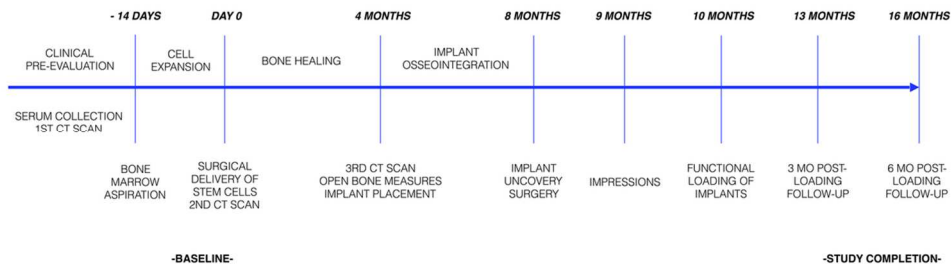


Figure 1. Trial profile. (a) Consort Diagram of patient distribution, (b) Study timeline.

108x81mm (300 x 300 DPI)

Accep

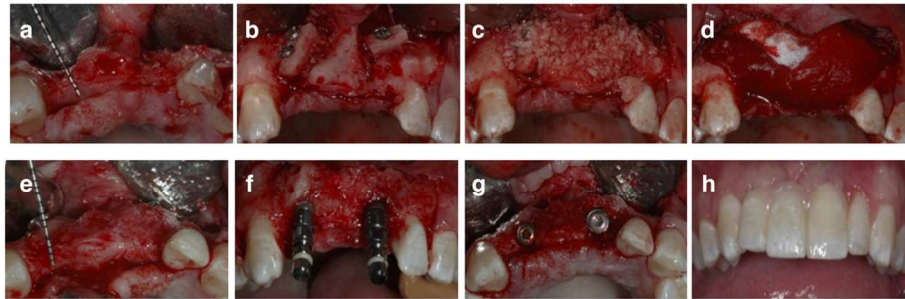


Figure 2. Control case. (a) Horizontal alveolar ridge deficiency in the anterior maxilla. (b) A block graft harvested from the symphysis was fixed with titanium screws (c) The block graft was covered with particulate allograft. (d) The augmented site was further protected with a collagen membrane. (e) Upon re-entry at 4 months the occlusal view clearly demonstrates the horizontal gain of bone width. (f,g) Two implants placed in a correct oro-facial position. (h) Final prosthesis delivery

108x81mm (300 x 300 DPI)

ACCF

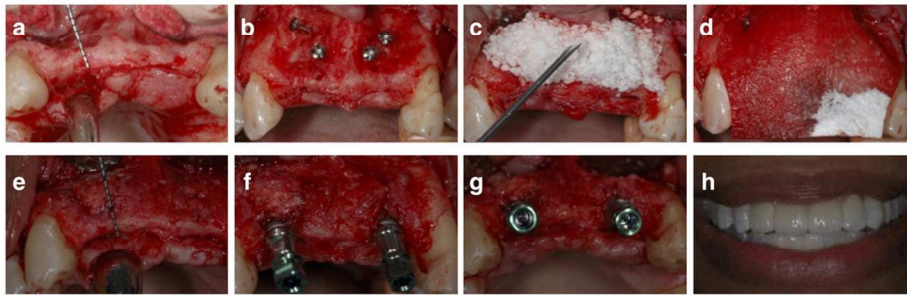


Figure 3. Stem cell therapy case (a) Defect of the anterior alveolar ridge (b) Titanium screws in place. (c,d) Ixmyelocel-t mixed with β -TCP and covered with collagen membrane. (e) Clinical situation at 4 month re-entry. (f,g) Dental implants placed into grafted bone. (h) Final prosthesis delivery

108x81mm (300 x 300 DPI)

Acce]

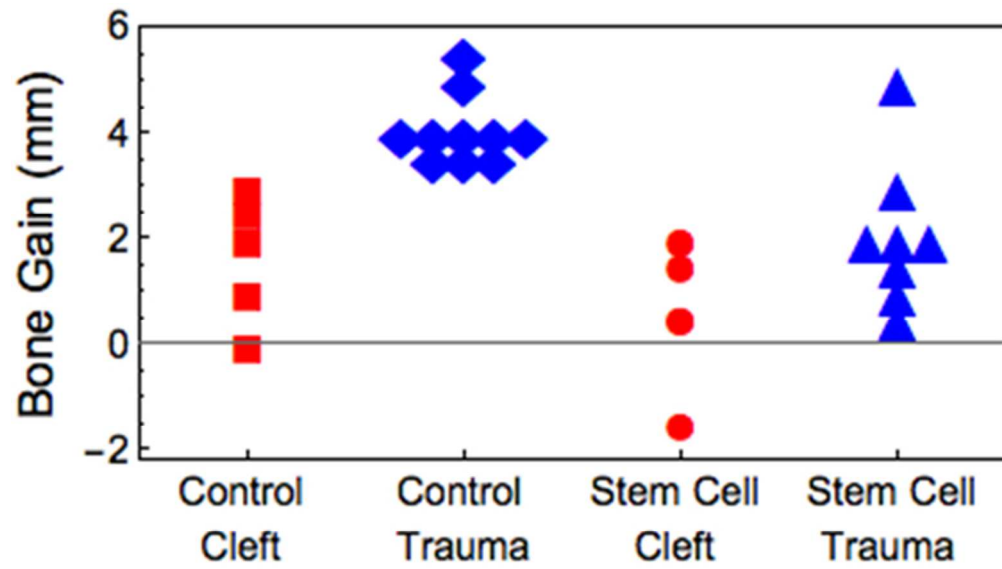


Figure 4. Changes in alveolar ridge width in patients with a history of cleft palate and traumatic injury

254x160mm (72 x 72 DPI)

Accept

Table 1. Patient characteristics/demographics

	Control	Stem cell therapy
Total number of patients	8	9
Number of patients (Trauma/Cleft palate)	5/3	5/4
Mean age (Range)	31 (19-54)	27 (18-42)
Gender (Male/Female)	5/3	7/2
Ethnicity		
Caucasian	6	7
Hispanic	1	1
African American	1	1

Accepted

Table 2. Number and location of sites (n=28) to be augmented per patient (n=17)

Number of sites	n patients	n sites	Location: n sites
One site	7	7	Maxilla, anterior (incisors, canines): 5 Mandible, anterior (incisors, canines): 2
Two sites	9	18	Maxilla, anterior (incisors, canines): 14 Mandible, anterior (incisors, canines): 2 Maxilla, posterior (premolars, molars): 2
Three sites	1	3	Maxilla, anterior (incisors, canines): 3
Total	17	28	Maxilla, anterior (incisors, canines): 22 Maxilla, posterior (premolars, molars): 2 Mandible, anterior (incisors, canines): 4

Accepted Article

Table 3. History of previous surgeries in the area of graft in patients with cleft palate

	Control	Stem cell therapy
Number of previous surgeries related to cleft palate (mean)	5	8
Number of previous bone grafts (mean)	2	2
Source of previous bone graft	Iliac crest, tibia, alveolar bone	Iliac crest, alveolar bone

Accepted Article

Table 4. Frequency distribution of adverse events

Adverse event	Control (Cleft)	Control (Trauma)	Stem cell therapy (Cleft)	Stem cell therapy (Trauma)
Wound dehiscence	1		1	
Infection			1	
Incision line opening				3
Membrane exposure			1	
Localized erythema		1	1	
Localized edema			2	1
Tooth sensitivity				1
Pain and dysesthesia in donor site		1		
Early suture removal (subject chewing on surgical site)		1		
Early implant failure	1			
Implant supported bridge came off		1	1	1
Abutment screw fracture			1	

Table 5: Clinical measurements of alveolar ridge width in mm

Ridge width in mm (mean ± SD)	Control Cleft	Control Trauma	Control ALL	Stem cell therapy Cleft	Stem cell therapy Trauma	Stem cell therapy ALL
Baseline width	5±1.1	2.9±1.3	3.6±1.6	2.6±1.6	3.1±1.1	2.9±1.3
Re-entry width	6.7±1.6	7±1.2	6.9±1.3	3.2±1.7	5.3±1.5	4.5±1.8
Gain of crest width	1.7 ±1.2	4.1±0.7	3.3±1.4	0.6±1.3	2.1±1.4	1.5±1.5

Accepted A

Table 6: Clinical outcomes

Outcome	Control (Cleft)	Control (Trauma)	Cell therapy (Cleft)	Cell therapy (Trauma)
Patients requiring re-grafting with block grafts	0 of 3	0 of 5	3 of 5	2 of 5
Patients reconstructed with implants	3 of 3	5 of 5	2 of 5	3 of 5
Patients requiring additional grafting at implant placement	0 of 3	2 of 5	2 of 2	1 of 3

Accepted Article

Supplementary Table S1. Adverse event summary

Group TX or C (control)	Subject	Description	Severity	Related to study	Related to cell treatment	Serious Y/N
C/Trauma	1	Localized erythema #6/#7	Mild	Definitely Related	Not Related	N
C/Trauma	2	Pain and dyesthesia in donor site	Mild	Definitely Related	Not Related	N
C/Trauma	4	Subject chewing on surgical site; sutures removed early	Mild	Definitely Related	Not Related	N
C/Trauma	4	Left knee pain	Moderate	Not Related	Not Related	N
C/Trauma	4	Self-diagnosed inflamed rotator cuff	Mild	Not Related	Not Related	N
TX/Trauma	5	Incision line opening; resutured site	Mild	Definitely Related	Possibly Related	N
TX/Trauma	5	Inflammation of wrist; steroid injection	Moderate	Not Related	Not Related	N
TX/Trauma	5	Wound dehiscence caused by early suture removal, flap was re-approximated	Mild	Definitely Related	Unlikely Related	N
TX/Trauma	5	Implant #12 in sinus; implant removed	Moderate	Definitely Related	Not Related	N

Group TX or C (control)	Subject	Description	Severity	Related to study	Related to cell treatment	Serious Y/N
TX/Trauma	6	Broke tooth #13 while eating; restoration recommended	Mild	Not Related	Not Related	N
TX/Trauma	6	Incision line opening after bone graft	Mild	Definitely Related	Unlikely Related	N
TX/Trauma	7	Incision line opening;	Moderate	Definitely Related	Possibly Related	N
TX/Trauma	7	Tooth sensitivity	Mild	Probably Related	Unlikely Related	N
TX/Trauma	7	Rash on neck and chest	Mild	Unlikely Related	Unlikely Related	N
TX/Trauma	7	Torn ligament in ankle	Mild	Not Related	Not Related	N
TX/Cleft	9	Wisdom teeth impactions (4)	Moderate	Not Related	Not Related	N
TX/Cleft	9	Streptococcal pharyngitis	Mild	Not Related	Not Related	N
TX/Cleft	9	Maxillary Mucosa erythema and edema	Mild	Possibly Related	Not Related	N
C/Trauma	10	Implant supported bridge came off; recemented	Moderate	Definitely Related	Not Related	N
C/Trauma	10	Unrelated bone graft procedure #18-19 area	Mild	Not Related	Not Related	N

Group TX or C (control)	Subject	Description	Severity	Related to study	Related to cell treatment	Serious Y/N
TX/Cleft	11	Abutment screw broke with piece in implant	Mild	Definitely Related	Not Related	N
TX/Cleft	11	Implant crown came off; recemented	Mild	Definitely Related	Not Related	N
TX/Cleft	11	Swelling; unilateral upper lip from extended lip retraction	Mild	Definitely Related	Not Related	N
TX/Trauma	12	Skin rash a few days following taking Amoxicillin	Mild	Not Related	Not Related	N
TX/Trauma	12	Moderate swelling in area of cheek/right nostril	Mild	Definitely Related	Unlikely Related	N
TX/Trauma	12	Implant supported FPD came off (#7-#10); recemented	Mild	Definitely Related	Not Related	N
C/Cleft	14	3mm wound dehiscence; inflamed labial flap	Mild	Definitely Related	Not Related	N
C/Cleft	14	Several ulcers adjacent to #10 area on labial mucosa	Mild	Unlikely Related	Not Related	N

Group TX or C (control)	Subject	Description	Severity	Related to study	Related to cell treatment	Serious Y/N
TX/Cleft	15	Implant #7 failing due to bone loss (non-study implant)	Mild	Not Related	Not Related	N
TX/Cleft	15	Hernia	Moderate	Not Related	Not Related	N
TX/Cleft	15	Car accident; subject hospitalized for 3 days	Severe	Not Related	Not Related	Y
C/Cleft	17	Pain on left side radiating to the joint (TMJ); ongoing sensitivity which could be associated with pain; sinus infections	Severe	Possibly Related	Not Related	N
C/Cleft	17	Implant failure #10; not osseointegrated	Moderate	Definitely Related	Not Related	N
C/Cleft	17	No bone root surface #9; extracted	Moderate	Definitely Related	Not Related	N
TX/Cleft	18	Membrane exposed/flap mobility	Mild	Definitely Related	Unlikely Related	N
TX/Cleft	19	Suppuration at wound site; wound dehiscence	Mild	Definitely Related	Not Related	N

Stem cell therapy for reconstruction of alveolar cleft and trauma defects in adults: A randomized controlled, clinical trial

Mona Bajestan, DDS ¹; Archana Rajan, DDS ¹; Sean P. Edwards, DDS, MD ²; Sharon Aronovich, DMD ²; Lucia H.S. Cevidanes, PhD, DDS ¹; Angeliki Polymeri, DDS ³; Suncica Travan, DDS ³; Darnell Kaigler, PhD, DDS ^{3,4}

¹Department of Orthodontics and Pediatric Dentistry, School of Dentistry, University of Michigan; Ann Arbor, Michigan, USA

²Department of Oral and Maxillofacial Surgery, School of Dentistry, University of Michigan; Ann Arbor, Michigan USA

³Department of Periodontics and Oral Medicine, School of Dentistry, University of Michigan; Ann Arbor, Michigan USA

⁴Department of Biomedical Engineering, College of Engineering, University of Michigan; Ann Arbor, Michigan USA

Mona Bajestan and Archana Rajan contributed equally to this work.

The authors report no conflict of interest.

Author Contributions:

Mona Bajestan and Archana Rajan: study concept/design, data collection, data analysis/interpretation, drafting article, statistics, critical revision of article, article approval

Sean P. Edwards: study concept/design, data collection, data analysis/interpretation, critical revision of article, article approval, funding

Sharon Aronovich: study concept/design, data collection, data analysis/interpretation, critical revision of article, article approval

Lucia H.S. Cevidanes: data collection, data analysis, critical revision of article, article approval

Angeliki Polymeri: data analysis/interpretation, drafting article, critical revision of article, article approval

Suncica Travan: data collection, data analysis/interpretation, critical revision of article, article approval

Darnell Kaigler: study concept/design, data collection, data analysis/interpretation, drafting article, statistics, critical revision of article, article approval, funding

Corresponding Author: Darnell Kaigler, 1011 N. University St, Ann Arbor MI, 48109, USA
Tel: +1-734-615-4023, Email: dkaigler@umich.edu

Key Words: trauma, cleft, stem cells, reconstruction, bone regeneration, cell therapy, dental implants, clinical trial

ABSTRACT

Background: Stem cell therapy with bone marrow-derived mesenchymal stem cells is a promising tissue engineering strategy to promote regeneration of craniofacial bone.

Purpose: To determine whether cell therapy with ex vivo expanded stem cell populations would be safe and efficacious in the regeneration of large alveolar defects in patients with a history of cleft palate or craniofacial trauma.

Materials and Methods: 18 patients (10 patients with traumatic injury and 8 patients with cleft palate) presenting with missing teeth associated with horizontal alveolar bone deficiencies were included in this randomized controlled clinical trial. Patients were randomized to receive either conventional autogenous block grafts or stem cell therapy. After a healing period of 4 months the treated sites were re-entered and the bone width re-assessed prior to implant placement. Implant stability was evaluated through torque testing of the implant upon insertion and at 6 months post-loading.

Results: The mean gain in bone width was 1.5 ± 1.5 mm in the stem cell therapy group and 3.3 ± 1.4 mm in the control group. Overall, bone gain was higher in trauma patients as compared to patients with cleft palate, for both the control and the stem cell therapy groups. Most postoperative complications were wound dehiscences and incision line openings. Implants were placed successfully in 5 out of 10 patients in the stem cell therapy group and in all 8 patients in the control group. One implant from the control/cleft palate group failed before loading, while the rest of the implants were loaded successfully and remained stable at six months. The patients who did not receive implants were re-treated with autogenous block bone graft. **Conclusion:** The ability of stem cells to treat large alveolar defects is safe, yet, their ability to completely

reconstitute large alveolar defects is limited. This approach requires further optimization to meet the outcomes seen using current methods to treat large defects, particularly those resultant of cleft palate.

INTRODUCTION

Oral and craniofacial bone defects secondary to congenital diseases (e.g. orofacial clefts) and trauma are very common and represent a significant health care burden.¹ Clefts of the lip and palate represent the most common congenital malformations of the head and neck, with approximately 7,000 infants born with orofacial clefts in the U.S. annually. The prevalence of cleft lip with or without cleft palate is 10.89 per 10,000 live births, and that of cleft palate is 6.45 per 10,000 live births.² Patients with clefts of the maxillary alveolus are frequently missing teeth, typically the lateral incisors, either unilaterally or bilaterally.³ Regarding trauma, the vast majority of facial traumatic injuries are attributed to motor vehicle accidents, falls, assaults, recreational and sports injuries⁴. Edentulous areas with large alveolar defects are also observed in trauma related injuries of the orofacial complex. 4.1% of all emergency room visits are attributed to primary traumatic injuries to the head and neck region; injuries to teeth and dental structures are quite common in these patients.⁵

In such cases of severe alveolar deficiencies, implant-prosthetic treatment involving advanced bone grafting techniques is generally indicated to restore optimum function and improve compromised esthetics. Currently, autogenous block bone grafts from intraoral (ramus, mandibular symphysis) or extraoral sites (iliac crest, tibia) represent the standard-of-care for alveolar grafting in cleft palate and trauma patients.⁶ However, harvesting bone from an additional donor site has several potential disadvantages including longer surgical time,

prolonged recovery, and morbidity at the donor site including pain and neurosensory disturbances.

In an effort to overcome the limitations of current bone augmentation procedures, cell therapy by means of cell transplantation has emerged as a possible strategy to regenerate alveolar bone. Recently, there have been several clinical reports evaluating the use of stem cells as a promising alternative approach for the reconstruction of alveolar bone defects.⁷⁻¹¹ We have previously demonstrated that the use of autologous mixed cell populations containing stem cells enhance and accelerate healing and regeneration of bone.⁹ Due to success in regenerating localized bone defects, the aim of this study was to evaluate this approach for larger, more challenging alveolar defects.

This phase 1/2 feasibility trial had two objectives. The first was to examine the safety and efficacy of an autologous cell therapy using a mixed population of expanded autologous progenitor and stem cells (ixmyelocel-t, Aastrom Biosciences, Inc.) to regenerate alveolar bone in patients with alveolar defects resultant of cleft palate or trauma. The second objective was to determine whether ixmyelocel-t therapy could regenerate bone sufficient to enable the stable installation of dental implants.

METHODS

Study design, patient selection, and randomization

After US Food and Drug Administration and University of Michigan Institutional Review Board (IRB) approval, 20 (twenty) subjects who had horizontal alveolar ridge atrophy secondary to clefts (n=10) or trauma (n=10), were selected to participate in this phase 1/2 randomized, controlled clinical trial. This sample size was chosen for feasibility rather than statistical

precision. Patients were fully informed about the surgical procedures and treatment alternatives and signed an informed consent. Following the screening examination performed by an examiner, if the subjects met all inclusion and exclusion criteria, they were enrolled by the study coordinator (*Supplemental study protocol document*). A computer-generated randomization schedule was used to randomly assign eligible subjects from each of the two groups (cleft or trauma) to receive one of two possible treatments, either traditional autogenous bone grafting or stem cell therapy (ixmylocel-t) (*Figure 1a*). Due to the nature of the stem cell therapy group requiring bone marrow aspiration, patient and surgeon blinding was not possible. Preoperative analyses included a complete medical history, blood draw for lab studies (liver/renal panel, CBC), a clinical and radiographic examination of the stomatognathic system and a thorough evaluation of the implant-recipient site with a cone-beam computed tomography (CBCT) scan. The study timeline is outlined in *Figure 1b*. The primary outcome of the study was the change in ridge width at re-entry which was assessed clinically with open bone measures and radiographically with CBCT. The measures were calculated between the baseline bone width and the bone width of the healed ridge. Secondary outcomes included: (i) the number of patients who required re-grafting, (ii) the short-term implant survival, and (iii) patient centered outcomes-life quality assessment.

Ixmylocel-t production

In the study participants who were designated to be in the stem cell therapy group, 12-14 days before initial surgical treatment, 30-50 ml of bone marrow was aspirated from the posterior iliac crest under conscious sedation and local anesthesia. Cell processing for generation of the autologous cell product, ixmylocel-t (Aastrom Biosciences Inc., Ann Arbor, MI, USA), has

been previously described.¹² Briefly, the collected marrow was transferred to a sterile blood bag and bone marrow mononuclear cells (BMMNC) were purified by Ficoll density gradient centrifugation. BMMNC were then inoculated into a bioreactor, which is a proprietary computer-controlled, automated cell-processing unit, the Aastrom Replicell System (Aastrom Biosciences). This system incorporates single-pass perfusion in which fresh medium flows slowly over the cells without retention of waste metabolites or differentiating cytokines. The culture medium consists of Iscove's modified Dulbecco's medium (IMDM), 10% fetal bovine serum, 10% horse serum, and 5 mM hydrocortisone. After cultivation for 12 days at 37°C, 5% CO₂, with a ramped continuous medium perfusion schedule, the Ixmylocel-t product was harvested by trypsinization, washed in a physiologic buffer, and collected into a sterile bag, where it was stored until the time of transplantation. The final cell composition was composed of a mixture of bone marrow-derived cells, including different concentrations of expanded CD90+ mesenchymal stem cells, CD14+ monocytes/ macrophages, and mononuclear cells from the original bone marrow aspirate. The final cell product was suspended in Isolyte and 0.5 % human serum albumin, and transported in a sterile bag to the surgical suite.

Bone regenerative procedure

12-14 days after the bone marrow aspiration, alveolar grafting was performed with the cell therapy (ixmylocel-t) or an autogenous bone block harvested from an intraoral site (*Figures 2 and 3*). In all patients, the surgery was performed under conscious sedation as well as local anesthesia. Two surgeons performed all the surgeries. All cleft surgeries were performed by the same surgeon while all trauma surgeries were performed by the same surgeon. Full thickness mucoperiosteal flaps were raised on the facial and palatal/lingual aspects of the bone defects.

The alveolar crest width was measured with a vernier caliper to the nearest half of a millimeter, 3 mm below the crest (baseline width). Using a small round bur, the facial cortex was decorticated to open up the bone marrow spaces in the defect site to facilitate graft integration.

In the control sites, a cortico-cancellous block bone graft was harvested from the mandibular ramus or symphysis region. The size of the graft was based on the size of the alveolar bone defect. Once the graft was sized appropriately for ideal bone contact, fixation was achieved with positional bone screws. Voids around the block graft were filled with allogeneic particulate bone graft (either freeze dried bone allograft or Puros cortical allograft, Zimmer). The particulate graft was stabilized in the site with a collagen barrier membrane (CollaTape, Zimmer). For the stem cell therapy group, a unit dose¹ of Ixmyelocel-T (10 ml) was mixed with a commercially available β -TCP (beta tricalcium phosphate; Cerasorb), which was used as a carrier to deliver the cells. The number of cells mixed per unit volume of β -TCP was within the optimum range as determined in preclinical studies (15×10^6 - 44×10^6 Ixmyelocel-T /ml). The amount of β -TCP used ranged from 2.0-5.0 cc for each patient. The total amount of β -TCP used depended on the number of Ixmyelocel-T grafted, with the final dosage being 15 - 44×10^6 Ixmyelocel-T/cc β -TCP. A resorbable cross-linked collagen membrane (ConForm; ACE surgical) was placed for graft containment and secured with membrane tacks or screws. The labial flap was mobilized via periosteal scoring incisions and supra-periosteal dissection. The flaps were then repositioned and approximated with bioabsorbable sutures in a tension-free manner. Primary closure was obtained in all cases.

¹ A unit dose of IXMYELOCEL-T is the cells produced from a single run patient batch derived from an inoculum of 255×10^6 cells into a standard AastromReplicell Cell Cassette processed in the current version of the AastromReplicell System.

Post-Operative Care

Oral hygiene instructions included 0.12% Chlorhexidine mouth rinses and no brushing in the surgical area for 2 weeks, to reduce the risk of oral infection. Patients were prescribed oral antibiotics (Amoxicillin 500 mg every 8h for 7 days), and ibuprofen 600 mg (every 6 hours for 3 days). Follow-up examinations were performed at two weeks and at 4 weeks following surgery. Patients were next seen for re-entry and implant placement at 4 months.

Re-entry

Re-entry procedures of the grafted sites were performed at 4 months post-grafting. Prior to re-entry, another CBCT was recorded for surgical planning of the implant placement to evaluate the extent of augmentation. Following mucoperiosteal flap elevation and debridement, the healed crest width was measured again with a caliper (re-entry width). Dental implants (Straumann, Nobel Biocare, Implant Direct, Zimmer) of appropriate size were placed in the regenerated sites only in cases where sufficient bone was present and primary implant stability could be achieved. If primary stabilization of an implant could not be achieved, additional grafting was performed using the same standard of care procedure as in the control group and the area was allowed to heal for an additional 4 month period, before being re-entered for implant installation. In cases where primary stability was achieved but residual bone deficiencies remained at the time of implant placement causing implant thread exposure, additional bone grafting was performed with freeze dried bone allograft (FDBA) in combination with a collagen membrane (conForm, ACE).

Short-term implant survival

The ability of the dental implant fixtures to remain stable was evaluated at six months post-loading. Implants were considered failures if they did not osseointegrate in the regenerated bone prior to loading with the final prosthesis or if they developed fibrous encapsulation following loading. Osseointegration was evaluated based on clinical implant stability (primary stability upon implant placement, as well as torque testing) and radiographic examination.

Statistical analyses

Descriptive statistics were used to summarize and describe the data. No statistical test was implemented to evaluate differences in bone gain between the groups due to the small sample size. Additionally, no direct comparison of adverse events among the groups was performed.

Values are presented as means \pm s.d.

RESULTS

A total of 18 patients were enrolled and 17 completed the study. Based on the compromised clinical outcomes observed in patients who received the cell therapy in the cleft group, enrollment was held to 8 patients for this cohort. The baseline demographic characteristics of all study participants are displayed in **Table 1**. In each patient, from one to three sites were treated; as such, a total of 28 sites were grafted (**Table 2**). **Table 3** illustrates the previous surgical procedures that were performed in the cleft palate patients. Note that in the cleft cohort, only 8 of the originally planned 10 patients were enrolled because the compromised clinical outcomes seen in the treatment group (cell therapy) relative to the control group in this cohort contraindicated additional participant accrual.

No serious, study related adverse events were reported in examination of comprehensive safety assessments during the trial (**Table 4**). Most postoperative complications were wound

dehiscences and this occurred in 2 patients (one from control/cleft group, and one from cell therapy/cleft group), with symptoms of infection present in the cell therapy/cleft patient. In three patients from the stem cell therapy trauma group the surgical site had to be re-sutured because of incision line opening. In one patient who received a symphysis graft, mild pain and dyesthesia of the donor site were reported after the procedure and the symptoms resolved within one week. Other postoperative complications included mild edema and erythema in the surgical site, tooth sensitivity and prosthesis related complications. The complete description of each reported adverse event is presented in **Supplementary Table S1**.

Pre-operative ridge dimensions and changes for the different groups are presented in **Table 5**. The mean width of the initial alveolar ridge was 3.6 ± 1.6 mm for the control group and 2.9 ± 1.3 mm for the stem cell therapy group. At re-entry, the healed augmented alveolar crest had a mean width of 6.9 ± 1.3 mm for the control group and 4.5 ± 1.8 mm for the stem cell therapy group. The mean calculated gain of horizontal ridge augmentation was 3.3 ± 1.4 mm and 1.5 ± 1.5 mm for the control and cell therapy group respectively. One patient with cleft palate who received the stem cell therapy presented with 1.5 mm loss of alveolar bone width at re-entry. All the other patients with cleft palate who received the ixmylocel-t gained from 0.5 to 2 mm of bone width. The respective gain in bone width for the patients with trauma was from 0.5 to 5 mm. The mean bone gain was higher in trauma patients as compared to cleft palate patients for both the control and stem cell therapy group (**Fig. 4**).

Augmented sites allowed for proper implant placement in all eight patients of the control group and in five out of ten patients of the stem cell therapy group. Two of those five patients of the stem cell therapy group who received implants belonged to the cleft palate group and the remaining three belonged to the trauma group. The patients who did not receive implants were

re-treated with autogenous block bone graft and were allowed to heal for an additional period of 4 months (**Table 6**). Among the patients that received implants additional bone augmentation procedures were performed in two control patients and three Ixmyelocel-T patients. The additional bone augmentation procedures included the use of either autogenous bone chips or freeze dried bone allograft (FDBA) in combination with a collagen membrane (conForm, ACE or Zimmer).

One implant from the control/cleft palate group did not achieve osseointegration and had to be removed. The rest of the implants were loaded successfully and remained stable at three and six months post loading. The abutments were well adapted to the implant fixture and the restorations were functional.

In order to assess whether the cell transplantation treatment affected the quality of life of the patients, all subjects were asked to complete a questionnaire at the end of the study (**Supplementary table S2**). Two patients from the control group reported that the procedure resulted in significant discomfort and another two that the procedure interfered with the daily activities. The results were similar in the stem cell therapy group where two patients reported that the procedure resulted in significant discomfort and another two that the procedure interfered with the daily activities. Subjects from both groups reported that they were satisfied with the outcome of the procedure, would recommend this procedure to other individuals, and would do it again if necessary.

DISCUSSION

Our clinical trial was designed to evaluate the safety and efficacy of an autologous stem cell therapy for the regeneration of large, complex alveolar bone defects. Though the prospect of stem cell therapies offers significant advantages over traditional approaches for oral and

craniofacial reconstruction, there has been very limited translation of this work toward clinical applications. One of the major limitations lies in the inadequate characterization, as well as the variability in the methods of isolation and *ex vivo* expansion of the cell populations.⁹ A defining element of ixmylocel-t therapy is the ability to employ reproducible cell isolation and expansion protocols that can predictably yield consistent cell populations, characterized by the presence of CD90+ mesenchymal stem cells, CD14+ monocytes/ macrophages, and mononuclear cells.⁸

Bone marrow osteoprogenitor cell delivery via local injection has been used in orthopedics for a number of years for the treatment of non-union and critical-sized segmental defects.¹³ Besides the local injection of SSCs into the site of injury, other methods of cell transplantation include the use of various carriers such as demineralized bone matrix or hydroxyapatite scaffolds.¹⁴ *Ex vivo* expanded SSCs loaded onto resorbable scaffolds have been successfully used in the treatment of idiopathic osteonecrosis of the femoral head, “critical-sized” long bone defects, spinal fusion and total hip arthroplasty.¹⁵⁻¹⁷ Outside of orthopaedics, there are limited reports of bone marrow derived mesenchymal stem cells being used for the treatment of craniofacial bone defects arising from trauma and congenital defects,^{7, 10, 18}; yet, no randomized controlled clinical trial involving implant therapy has been reported.

The results of the current clinical study showed that this cell therapy is capable of osseous regeneration, confirming the results of our previous randomized controlled clinical studies where ixmylocel-t therapy was evaluated in bone regeneration of extraction sockets and bone reconstruction of maxillary sinuses.^{8, 9, 11} In the present study however, the ability of these cells to completely reconstitute a large craniofacial defect was limited, particularly in the patients with cleft palate. It is well-established that in patients with large cleft lip and palate deformities, sufficient mucosa of adequate vascularity is typically missing owing to the nature of the defect

itself or to scarring from prior surgical procedures.^{19,20} Scar tissue may have a poor blood supply with low oxygen tension, and when it is used to cover a bone graft, healing can be compromised.^{21,22} These are important considerations in the cleft palate cohort of this study. All of the patients with a history of alveolar clefting had already undergone at least five prior surgical procedures at the defect site, and in some instances more than eight hard or soft tissue surgical procedures (*Table 3*). These sites exhibited palatal and labial mucosal scarring, along with dense fibrous and hypovascular submucosal tissue. These variables created significant surgical challenges and ultimately impacted the clinical outcomes of the bone grafting procedures.

Success of the bone augmentation procedure is defined as the ability to place implants with adequate primary stability. In our study, horizontal bone augmentation was successful in three of five patients who received cell therapy for the treatment alveolar defects secondary to trauma. The cell therapy for treatment of alveolar cleft was successful in two out of five subjects.

One of the other important factors for successful bone tissue regeneration is the ability to maintain space over the grafted bone, which allows the formation of an undisturbed blood clot and healing.²³ Several techniques that have been used to maintain the space in non-containing large alveolar defects include the use of graft materials such as autogenous block grafts or mineralized particulate bone grafts, as well as titanium tenting screws.²⁴⁻²⁶ In the present study the carrier for stem cells was β -TCP in a granular form, of which 90% has been shown to resorb in 3 months.^{27,28} This matrix carrier may be suitable for smaller more localized defects but for larger defects, may not be suitable due to collapse within the defect, leading to a suboptimal regenerative outcome in the stem cell treatment group. Our goal was to compare the efficacy of the cell transplantation therapy using particulate β -TCP as a carrier to the standard of care

procedure for the regeneration of large alveolar defects. Therefore, our control treatment did not include the carrier alone (β -TCP), but the use of autologous block bone graft which is considered the standard of care for large alveolar defects.⁶

Another limitation of predictable bone regeneration in these challenging defects might be due to the inability to “tailor” the delivery of cells to the shape variability of patient-specific defects. Pre-clinical studies using human bone marrow mononuclear cells or human bone marrow derived mesenchymal stem cells have shown that the seeding efficacy on β -TCP is generally high and cells stay attached to β -TCP for 3 weeks although differences exist between various HA/TCP ratios.^{29, 30} To our knowledge no preclinical studies have assessed the adhesion of the ixmyelocel-t cells on β -TCP. It is therefore possible that the cells may have migrated out of the defect and therefore not have contributed to regeneration. Alternatively, an ideal approach would be one that is standardized enough to be reproducible, yet adaptable enough to be patient- and defect-specific. Future studies should consider stem cell transplantation on 3-dimensional (3-D) printed scaffolds produced in the morphological dimensions of patient-specific craniofacial defects.^{31, 32}

Post-operative evaluation time is another element that has a great variation in different studies. Generally, healing time for large guided bone regeneration procedures has been reported to be between 5 and 13 months.³³⁻³⁶ The rationale for our choosing the 4-month time point for re-entry was based on the results of previous study on using autologous cell therapy for reconstruction of localized craniofacial defect.⁸ In that study it was shown that autologous cell therapy therapy accelerates wound repair in extraction sockets, however, in larger defects, these processes may require longer healing periods with this approach.

Besides evaluating the safety and efficacy of this new approach, we also aimed to acquire information relative to the treatment protocol from the patient perspective. This quality-of-life assessment is often overlooked or not reported when trying to determine the initial feasibility of emerging therapies; yet, if the therapy is deemed effective, these factors could underscore the acceptance and widespread use of these procedures. Our study found that the acceptance of the cell therapy is similar to the acceptance of the conventional treatment with autogenous block graft. Most patients reported that the procedures involved did not result in significant discomfort and did not significantly impact their daily life activities. All participants from both groups reported that they were satisfied with the final outcome and that if necessary, they would undergo them again. This is in contrast with other studies reporting that most patients would not elect to undergo bone regeneration procedures with autogenous grafts again if necessary because of the associated postoperative pain and distress.³⁷

CONCLUSIONS

Our study demonstrated that transplantation of autologous stem cells can be used safely for the reconstruction of large craniofacial defects. Although the ability of ex-vivo expanded autologous stem cells to completely reconstitute a large alveolar defect in adults is limited, these cells are capable of osseous regeneration. This study provided insight into factors that are critical for successful bone regeneration. Considerations for future investigations would include longer post-operative evaluation time periods, different scaffold material, and mode of delivery techniques which could potentially utilize customized scaffold/matrix designs. Larger multi-center randomized controlled clinical trials are necessary for the widespread use of this approach to enhance bone regeneration in large alveolar and craniofacial defects.

ACKNOWLEDGEMENTS

The authors attest that there are no conflicts of interest associated with this work. This study was funded by a Career Award for Medical Scientists from the Burroughs Wellcome Fund, the Oral-Maxillofacial Surgery Foundation, and the Michigan Institute for Clinical Health Research (MICHR) Clinical Trials Pilot Program (UL1TR000433; University of Michigan). The authors would like to acknowledge Drs. Feng Wang (ITI scholar), Alejandro Lanis (ITI scholar), and Benjamin Cornwall for their clinical support and Drs. Sunil Kapila and Scott Conley for their intellectual contributions. Additionally, the authors would like to acknowledge MICHR and the University of Michigan School of Dentistry's Clinical Research Core for their regulatory, administrative, and technical support.

FIGURE LEGENDS

Figure 1. Trial profile. (a) Consort Diagram of patient distribution, (b) Study timeline.

Figure 2. Control case. (a) Horizontal alveolar ridge deficiency in the anterior maxilla. (b) A block graft harvested from the symphysis was fixed with titanium screws (c) The block graft was covered with particulate allograft. (d) The augmented site was further protected with a collagen membrane. (e) Upon re-entry at 4 months the occlusal view clearly demonstrates the horizontal gain of bone width. (f,g) Two implants placed in a correct oro-facial position. (h) Final prosthesis delivery

Figure 3. Stem cell therapy case (a) Defect of the anterior alveolar ridge (b) Titanium screws in place. (c,d) Ixmyelocel-t mixed with β -TCP and covered with collagen membrane. (e) Clinical

situation at 4 month re-entry. (f,g) Dental implants placed into grafted bone. (h) Final prosthesis delivery

Figure 4. Changes in alveolar ridge width in patients with a history of cleft palate and traumatic injury

Bibliography

1. Jin LJ, Lamster I, Greenspan JS, Pitts N, Scully C, Warnakulasuriya S. Global burden of oral diseases: emerging concepts, management and interplay with systemic health. *Oral Dis* 2015.
2. Parker SE, Mai CT, Canfield MA, et al. Updated National Birth Prevalence estimates for selected birth defects in the United States, 2004-2006. *Birth Defects Res A Clin Mol Teratol* 2010; **88**: 1008-1016.
3. Al Jamal GA, Hazza'a AM, Rawashdeh MA. Prevalence of dental anomalies in a population of cleft lip and palate patients. *Cleft Palate Craniofac J* 2010; **47**: 413-420.
4. Glendor U. Aetiology and risk factors related to traumatic dental injuries--a review of the literature. *Dent Traumatol* 2009; **25**: 19-31.
5. Sethi RK, Kozin ED, Fagenholz PJ, Lee DJ, Shrimme MG, Gray ST. Epidemiological survey of head and neck injuries and trauma in the United States. *Otolaryngol Head Neck Surg* 2014; **151**: 776-784.
6. Esposito M, Grusovin MG, Felice P, Karatzopoulos G, Worthington HV, Coulthard P. Interventions for replacing missing teeth: horizontal and vertical bone augmentation techniques for dental implant treatment. *Cochrane Database Syst Rev* 2009: Cd003607.
7. Behnia H, Khojasteh A, Soleimani M, Tehranchi A, Atashi A. Repair of alveolar cleft defect with mesenchymal stem cells and platelet derived growth factors: a preliminary report. *J Craniomaxillofac Surg* 2012; **40**: 2-7.
8. Kaigler D, Pagni G, Park CH, et al. Stem cell therapy for craniofacial bone regeneration: a randomized, controlled feasibility trial. *Cell Transplant* 2013; **22**: 767-777.
9. Kaigler D, Avila-Ortiz G, Travan S, et al. Bone Engineering of Maxillary Sinus Bone Deficiencies Using Enriched CD90+ Stem Cell Therapy: A Randomized Clinical Trial. *J Bone Miner Res* 2015; **30**: 1206-1216.
10. Meijer GJ, de Bruijn JD, Koole R, van Blitterswijk CA. Cell based bone tissue engineering in jaw defects. *Biomaterials* 2008; **29**: 3053-3061.
11. Rajan A, Eubanks E, Edwards S, et al. Optimized cell survival and seeding efficiency for craniofacial tissue engineering using clinical stem cell therapy. *Stem Cells Transl Med* 2014; **3**: 1495-1503.

12. Gastens MH, Goltry K, Prohaska W, et al. Good manufacturing practice-compliant expansion of marrow-derived stem and progenitor cells for cell therapy. *Cell Transplant* 2007; **16**: 685-696.
13. Connolly JF. Clinical use of marrow osteoprogenitor cells to stimulate osteogenesis. *Clin Orthop Relat Res* 1998: S257-266.
14. Quarto R, Mastrogiacomo M, Cancedda R, et al. Repair of large bone defects with the use of autologous bone marrow stromal cells. *N Engl J Med* 2001; **344**: 385-386.
15. Hernigou P, Pariat J, Queinnec S, et al. Supercharging irradiated allografts with mesenchymal stem cells improves acetabular bone grafting in revision arthroplasty. *Int Orthop* 2014; **38**: 1913-1921.
16. Kawate K, Yajima H, Ohgushi H, et al. Tissue-engineered approach for the treatment of steroid-induced osteonecrosis of the femoral head: transplantation of autologous mesenchymal stem cells cultured with beta-tricalcium phosphate ceramics and free vascularized fibula. *Artif Organs* 2006; **30**: 960-962.
17. Marcacci M, Kon E, Moukhachev V, et al. Stem cells associated with macroporous bioceramics for long bone repair: 6- to 7-year outcome of a pilot clinical study. *Tissue Eng* 2007; **13**: 947-955.
18. Warnke PH, Springer IN, Wiltfang J, et al. Growth and transplantation of a custom vascularised bone graft in a man. *Lancet* 2004; **364**: 766-770.
19. Carmichael RP, Sandor GK. Use of dental implants in the management of cleft lip and palate. *Atlas Oral Maxillofac Surg Clin North Am* 2008; **16**: 61-82.
20. Matsui Y, Ohta M, Ohno K, Nagumo M. Alveolar bone graft for patients with cleft lip/palate using bone particles and titanium mesh: A quantitative study. *J Oral Maxillofac Surg* 2006; **64**: 1540-1545.
21. Kim YK, Yeo HH, Kim SG. Use of the tongue flap for intraoral reconstruction: a report of 16 cases. *J Oral Maxillofac Surg* 1998; **56**: 716-719; discussion 720-711.
22. Sandor GK, Carmichael RP, Brkovic BM. Dental implants placed into alveolar clefts reconstructed with tongue flaps and bone grafts. *Oral Surg Oral Med Oral Pathol Oral Radiol Endod* 2010; **109**: e1-7.
23. Wang HL, Boyapati L. "PASS" principles for predictable bone regeneration. *Implant Dent* 2006; **15**: 8-17.
24. Buser D, Dula K, Belser U, Hirt HP, Berthold H. Localized ridge augmentation using guided bone regeneration. 1. Surgical procedure in the maxilla. *Int J Periodontics Restorative Dent* 1993; **13**: 29-45.
25. Buser D, Dula K, Belser UC, Hirt HP, Berthold H. Localized ridge augmentation using guided bone regeneration. II. Surgical procedure in the mandible. *Int J Periodontics Restorative Dent* 1995; **15**: 10-29.
26. Mellonig JT, Nevins M. Guided bone regeneration of bone defects associated with implants: an evidence-based outcome assessment. *Int J Periodontics Restorative Dent* 1995; **15**: 168-185.
27. Artzi Z, Weinreb M, Givol N, et al. Biomaterial resorption rate and healing site morphology of inorganic bovine bone and beta-tricalcium phosphate in the canine: a 24-month longitudinal histologic study and morphometric analysis. *Int J Oral Maxillofac Implants* 2004; **19**: 357-368.
28. Hak DJ. The use of osteoconductive bone graft substitutes in orthopaedic trauma. *J Am Acad Orthop Surg* 2007; **15**: 525-536.
29. Bajpai I, Kim DY, Kyong-Jin J, Song IH, Kim S. Response of human bone marrow-derived MSCs on triphasic Ca-P substrate with various HA/TCP ratio. *J Biomed Mater Res B Appl Biomater* 2015.
30. Henrich D, Verboket R, Schaible A. Characterization of bone marrow mononuclear cells on biomaterials for bone tissue engineering in vitro. 2015; **2015**: 762407.

31. Ballyns JJ, Bonassar LJ. Image-guided tissue engineering. *J Cell Mol Med* 2009; **13**: 1428-1436.
32. Park CH, Rios HF, Taut AD, et al. Image-based, fiber guiding scaffolds: a platform for regenerating tissue interfaces. *Tissue Eng Part C Methods* 2014; **20**: 533-542.
33. Buser D, Dula K, Hirt HP, Schenk RK. Lateral ridge augmentation using autografts and barrier membranes: a clinical study with 40 partially edentulous patients. *J Oral Maxillofac Surg* 1996; **54**: 420-432; discussion 432-423.
34. da Costa CE, Pelegrine AA, Fagundes DJ, Simoes Mde J, Taha MO. Use of corticocancellous allogeneic bone blocks impregnated with bone marrow aspirate: a clinical, tomographic, and histomorphometric study. *Gen Dent* 2011; **59**: e200-205.
35. Dickinson BP, Ashley RK, Wasson KL, et al. Reduced morbidity and improved healing with bone morphogenetic protein-2 in older patients with alveolar cleft defects. *Plast Reconstr Surg* 2008; **121**: 209-217.
36. Pelegrine AA, da Costa CE, Correa ME, Marques JF, Jr. Clinical and histomorphometric evaluation of extraction sockets treated with an autologous bone marrow graft. *Clin Oral Implants Res* 2010; **21**: 535-542.
37. Myeroff C, Archdeacon M. Autogenous bone graft: donor sites and techniques. *J Bone Joint Surg Am* 2011; **93**: 2227-2236.

Accepted Article