

# The epidemiology of pseudallescheriasis complicating transplantation: Nosocomial and community-acquired infection

## Die Epidemiologie der Pseudallescheriasis als Komplikation von Organtransplantationen: Nosokomial- und Umgebungsinfektion

T. F. Patterson, V. T. Andriole, M. J. Zervos, D. Therasse and Carol A. Kauffman

Departments of Medicine and Laboratory Medicine, Yale University School of Medicine, New Haven, Connecticut, USA

Department of Medicine, University of Michigan School of Medicine and Ann Arbor Veterans Administration Medical Center, Ann Arbor, Michigan, USA

**Key words.** *Pseudallescheria boydii*, pseudallescheriasis, transplant patients, nosocomial infection, antimycotic chemotherapy, miconazole, ketoconazole, itraconazole.

**Schlüsselwörter.** *Pseudallescheria boydii*, Pseudallescheriasis, Transplantationspatienten, nosokomiale Infektionen, antimykotische Chemotherapie, Miconazol, Ketoconazol, Itraconazol.

**Summary.** The epidemiology of two cases of pseudallescheriasis in organ transplant patients are described and the disease in that population is reviewed. Disseminated hospital-acquired infection occurred in a liver transplant recipient and was fatal despite therapy with miconazole. A heart transplant recipient developed localized disease following soil contamination of soft tissue trauma which was cured with surgical resection and miconazole therapy. Itraconazole showed *in vitro* activity against *Pseudallescheria boydii* and should be evaluated in pseudallescheriasis. *P. boydii* infections are important complications of transplantation and should be considered in the differential diagnosis of community-acquired as well as nosocomial fungal infections in this population.

**Zusammenfassung.** Es werden zwei Fälle von Pseudallescheriasis bei Transplantationspatienten beschrieben, und die Literatur hierüber wird zusammenfassend gewichtet. Eine disseminierte Hospitalinfektion wurde an einem Lebertransplantationspatienten beobachtet, die trotz Miconazol-Therapie tödlich ausging. Ein Herztransplantationspatient entwickelte eine Lokalinfection nach einer Erdbodenkontamination bei einem Weichteiltrauma, die durch Resektion und Miconazolgaben geheilt werden konnte. Itraconazol erwies sich *in vitro* als aktiv gegen *P. boydii* und sollte bei Pseudallescheriasis geprüft werden. *P. boydii*-Infektionen stellen wichtige Komplikationen bei Organtransplantationen dar und sollten differentialdiagnostisch bei Umgebungsinfekten wie bei nosokomialen Infek-

**tionen dieser Patientengruppe in Erwägung gezogen werden.**

## Introduction

*Pseudallescheria boydii* is an ubiquitous soil fungus that most commonly causes mycetomas [1]. The most common non-mycetoma site of isolation is the lung [2]. Disseminated disease is rare but occurs in immunocompromised hosts [3, 4]. The resistance of this organism to many antifungal agents including amphotericin B complicates therapy [5, 6]. *In vitro* sensitivity to miconazole and ketoconazole has been demonstrated but susceptibility data to those agents [3, 7] and newer azole compounds is limited. The most common route of soft tissue infection is through skin inoculation [8]; pulmonary infection occurs through inhalation of spores and occurs primarily in immunocompromised hosts [4, 9]. However, pseudallescheriasis is not usually considered as a potential etiology of hospital-acquired fungal infections [9]. In this report we describe two organ transplant patients with pseudallescheriasis, including one infection which was nosocomial in origin. In addition, we review the epidemiology of pseudallescheriasis in transplantation and evaluate the *in vitro* susceptibilities of the isolates.

## Patients

*In vitro* susceptibility methods. All specimens were inoculated onto Sabouraud's 2 % dextrose agar and the isolates identified on the basis of morphological features [10]. *In vitro* susceptibilities were performed by agar dilution replicate plate assay as previously described [11, 12]. Briefly, ketoconazole and miconazole (Janssen Pharmaceutica, Inc., Piscataway, NJ, USA) were dissolved in 100 % dimethylsulfoxide (DMSO), itraconazole (Janssen Pharmaceutica) was dissolved in 85 % ethyl alcohol in 1N HCl, fluconazole (Pfizer Central Research,

Groton CT) was dissolved in sterile water, amphotericin B (E. J. Squibb & Sons, Inc., Princeton, NJ, USA) was dissolved in 100 % DMSO, and flucytosine (Hoffmann-La Roche, Inc. Nutley, NJ, USA) was dissolved in distilled water to achieve a stock solution of 1,000 µg/ml for each drug. Further dilutions were made in distilled water to give final concentrations from 0.006 to 50 µg/ml in the agar plates. The agar used for ketoconazole, miconazole, itraconazole, and fluconazole was Kimmig agar (E. Merck, Darmstadt, FRG), for amphotericin B antibiotic medium #3 in purified agar (Difco, Inc. Detroit, MI, USA) was used, and for flucytosine, yeast nitrogen base agar (Difco, Inc.) was used. The inoculum used was  $5 \times 10^4$  organisms/ml inoculated with a Steers replicator, which delivered 0.003 ml of each organism giving a final inoculum of  $1.5 \times 10^2$  organisms. After 48 h at 25 °C, the plates were read for growth with the minimal inhibitory concentration (MIC) defined as the lowest concentration of drug with no visible fungal growth.

*Case 1.* A 22-year-old man had been well until 7 weeks prior to admission when a depressed skull fracture from a motor vehicle accident required phenytoin prophylaxis. He developed hepatic failure secondary to phenytoin hepatitis and in August, 1985 he was admitted to the University of Michigan Medical Center for liver transplantation. After liver transplantation, he was immunosuppressed with methylprednisolone and cyclosporine. Seven days post-operatively he developed abdominal fascia infection and peritonitis and was treated with multiple antibiotics including tobramycin, vancomycin, clindamycin, and cefotaxime. One week post-transplantation, a liver biopsy showed acute rejection and he was given additional steroids and antithymocyte globulin.

On day 25 post-transplant, 37 days after admission, a chest radiograph revealed a new left upper lobe pulmonary nodule and a transthoracic needle biopsy was done. Periodic acid Schiff (PAS) stain of the

specimen revealed hyphal elements on microscopic examination. Amphotericin B was begun for presumed *Aspergillus* infection and other antibiotics were discontinued. The biopsy specimen and sputum were inoculated onto Sabouraud's 2% dextrose agar. Two days later both cultures grew *P. boydii* as identified on the basis of morphological features [10]. *In vitro* susceptibilities performed by agar dilution replicate plate assay are shown in Table 1. Oral ketoconazole 400 mg/day was added to the amphotericin B. A serum ketoconazole level was measured at 4 µg/ml. Because of progressive pulmonary lesions, ketoconazole and amphotericin B were discontinued after 12 days of therapy and intravenous miconazole was begun at a dose of 600 mg every 8 h. The nodular pulmonary densities stabilized but a lower lobe infiltrate developed on chest radiograph. Sputum cultures grew *Enterobacter aerogenes* and piperacillin and tobramycin were begun. He developed progressive renal insufficiency, respiratory failure, and disseminated intravascular coagulation. He died 43 days post-transplant. Autopsy revealed cavitory lesions in both lungs and a 3 x 3 cm cavitory brain lesion in the right parietal area. All lesions had fungal hyphae seen on microscopic examination.

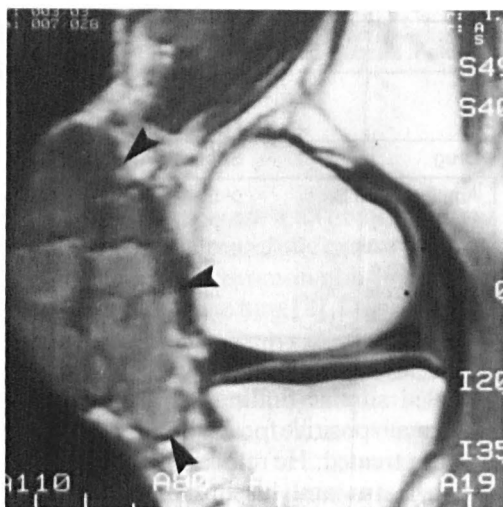
**Case 2.** A 58-year-old man, admitted to Yale New Haven Hospital, underwent cardiac transplantation for idiopathic cardiomyopathy in March, 1986, and was immunosuppressed with prednisone, azathioprine, and cyclosporine. He did well until June, 1986, when his right knee became swollen after a bicycle fall, but there was no break in skin integrity. The knee swelling resolved, but two weeks following the injury, he sustained superficial breaks in the skin while working under a house. In August, 1986, he presented with knee pain and swelling. Examination revealed a warm, tender, fluctuant prepatellar region with no adenopathy or sinus tracts detected. The prepatellar bursa was aspirated and contained thick purulent material that later grew *P. boydii* on culture. The following day a second bursa aspiration

**Table 1.** Susceptibilities of clinical *P. boydii* isolates

Drug	Minimal Inhibitory Concentration (µg/ml)	
	Strain 1	Strain 2
Amphotericin B	> 50	50.0
Flucytosine	> 50	> 50
Ketoconazole	1.56	3.12
Miconazole	0.20	0.20
Fluconazole	50.0	50.0
Itraconazole	6.25	6.25

revealed similar findings and the cultures were again positive for *P. boydii*. The patient was not treated. He returned to his previous active status and his immunosuppression was continued unchanged. Over a course of 4 months, cystic lesions developed over the medial aspect of his right knee and he was admitted to Yale New Haven Hospital in December, 1986. Examination was normal except for multiple cystic lesions on the medial aspect of the right knee. The largest cyst was 2 cm x 3 cm in size. No joint fluid was apparent. The peripheral white blood cell count was 6,300/mm<sup>3</sup> with 83% polymorphonuclear neutrophils. The cystic lesion was aspirated and the fluid contained 290,000 white blood cells/mm<sup>3</sup>, 95% were polymorphonuclear neutrophils. The cystic fluid glucose was 22 mg/dl, with a serum glucose of 109 mg/dl. PAS stain of the fluid showed multiple branching septate hyphae and the culture grew *P. boydii*. *In vitro* susceptibilities are shown in Table 1. Radiographs showed no bone involvement and a magnetic resonance study confirmed the lesions to be in the prepatellar bursa and superficial to the joint space (Fig. 1).

He was treated with miconazole using a dose of 600 mg every 8 h. Three days after antifungal therapy was begun he underwent surgical debridement of all the cystic lesions. Surgical findings confirmed the lesions to be superficial to the joint space and resection of the entire cystic structures was performed. No granules were detected at the time of resection. Antifungal therapy was continued for 2 weeks post-operatively for a total



**Figure 1.** Pseudallescheriasis. Magnetic resonance scan of right knee from patient 2. Arrows demonstrate the cystic lesions in the pre-patellar bursa.

miconazole dose of 30 g. He tolerated therapy well. His cyclosporine levels did not rise. After 2 years of follow-up, he had no recurrence.

## Discussion

These cases illustrate important epidemiologic and diagnostic aspects of *Pseudallescheria boydii* infections in organ transplantation which are particularly critical in the successful diagnosis and treatment of infection in these hosts. Patient 1 demonstrates the difficulty in diagnosing *Pseudallescheria* infection by histopathology alone. Both *Aspergillus* spp. and *P. boydii* can appear in tissue sections as branched septate hyphae. The diagnosis can be particularly difficult since both organisms can present as cavitory or nodular pulmonary disease in immunocompromised patients. Because aspergillosis is more common, that disease is often diagnosed empirically and therapy begun with amphotericin B, as was done in patient 1. Most isolates of *P. boydii* show *in vitro* resistance to amphotericin B [6], as was the case in both of these patients. Thus, while

tissue biopsy is needed to prove invasive disease, isolation in culture of the organism from tissue specimens is needed to confirm *Pseudallescheria* infection [14].

In addition, patient 1 emphasizes the importance of considering the diagnosis of pseudallescheriasis in immunocompromised patients even when they have been hospitalized for an extended period of time. Previous cases of pseudallescheriasis have been diagnosed several weeks after admission to the hospital [14, 15]. However, the nosocomial occurrence of infection in those previous transplant patients was not discussed. Previously reported patients were immunocompromised prior to admission to the hospital. In those cases *P. boydii* infection could represent either infection from the patient's endogenous flora and be considered hospital-associated or it could have been a true hospital-acquired infection [16]. Patient 1 was not likely to be colonized or infected on admission as he was immunocompetent until admission to the hospital and received a liver transplant. Thus, his nosocomial infection likely represented true hospital-acquired disease.

In contrast, the soft tissue infection in patient 2 most likely resulted from inoculation of the fungus from soil into the previously traumatized knee. Most often inoculation in that fashion results in the mycetoma form of the disease with sinus tract and granule formation. While his indolent course is compatible with a mycetoma-like disease, sinus tract formation was not present and no granules were noted. Bone and soft tissue infections have been not successfully treated with a combined medical and surgical approach. Our patient was successfully treated with complete surgical removal of the lesion combined with a two week course of miconazole, but optimal duration of therapy is not known. In a similar cystic *Pseudallescheria* infection in a non-compromised patient, complete surgical removal combined with 4 months of ketoconazole was effective [8]. In cases where surgical removal of the lesions is

not possible or is incomplete, prolonged antifungal therapy may be necessary [5, 17].

*Pseudallescheria boydii* infections have been previously reported in at least four transplant recipients [7, 13–15]. Fatal disseminated disease that included central nervous system involvement has been reported from three transplant patients. One heart transplant patient developed pseudallescheriasis after a prolonged course of amphotericin B for pulmonary aspergillosis which may have predisposed her to resistant *Pseudallescheria* infection; she was unsuccessfully treated with miconazole [13]. A kidney transplant patient was unsuccessfully treated with amphotericin B and flucytosine [15]. A bone marrow recipient developed disseminated disease while on ketoconazole for fungal prophylaxis and was treated unsuccessfully with empiric amphotericin B, with disseminated *P. boydii* detected on autopsy [14]. Another heart transplant recipient had nodular pulmonary disease that was treated with an extended course of ketoconazole and responded without surgical intervention [7].

*In vitro* susceptibilities have shown resistance of *P. boydii* to amphotericin B and to flucytosine, as noted in both our patients [3]. *In vivo* response to those agents is poor, as was seen in our patient 1. Reported MICs of miconazole to *P. boydii* are close to 0.2 µg/ml, as noted with both of our isolates [3, 7]. Achievable peak serum levels of miconazole exceed 1 µg/ml with intravenous doses of ≥ 9 mg/kg [3]. Miconazole has been successfully used in pseudallescheriasis [5], including our patient 2 [5]. Ketoconazole offers the advantage of prolonged oral therapy but MICs of ketoconazole to *P. boydii* are higher than those of miconazole and often exceed achievable serum concentrations. In our isolates the MICs were close to the levels achieved with administration of 400 mg of ketoconazole. However, *in vitro* susceptibilities to ketoconazole do not always correlate with clinical response as successful therapy has been reported in patients with strains showing *in vitro* resistance [7]. Use

of miconazole and ketoconazole in transplant recipients is further complicated because these agents can increase serum cyclosporine levels and in liver transplant recipients may not be properly metabolized [18]. Itraconazole showed *in vitro* activity against both isolates although the MIC was slightly higher than that of ketoconazole. Since itraconazole may interfere less with cyclosporine metabolism, it could be an alternative drug to use in transplant patients with *Pseudallescheria* infection. Significantly less *in vitro* activity of fluconazole against *P. boydii* was noted, but the correlation between susceptibility results and *in vivo* response for fluconazole is particularly poor [19].

These two cases show that *Pseudallescheria* infections can occur as disseminated or localized disease in transplant recipients. In addition, these cases emphasize that while soil inoculation is the usual route of soft tissue infection, nosocomial infection with *P. boydii* can occur and should be considered in the differential diagnosis of hospital acquired fungal infections in the transplant population. Disseminated disease is often fatal despite maximal therapy but localized disease may be cured with combined medical and surgical therapy even with necessary continuation of severe immunosuppression in these patients. Itraconazole was found to have *in vitro* activity against *P. boydii* and may afford another option for prolonged therapy of pseudallescheriasis.

### Acknowledgements

This research was supported in part by a Hull Cancer Research Award from the New Haven Foundation and Yale Comprehensive Cancer Center. Dr Patterson is a Daland Fellow of the American Philosophical Society and is a recipient of a National Foundation for Infectious Diseases/Janssen Pharmaceutica Fellowship for Medical Mycology.

## References

- 1 Green, W. O. & Adams, T. E. (1964) Mycetoma in the United States. A review and report of seven additional cases. *Am. J. Clin. Pathol.* **42**, 755-91.
- 2 Seale, J. P. & Hudson, J. A. (1986) Successful medical treatment of pulmonary petriellidiosis. *South. Med. J.* **78**, 473-476.
- 3 Lutwick, L. I., Galgiani, J. J., Johnson, R. H. & Stevens, D. A. (1976) Visceral fungal infections due to *Petriellidium boydii* (*Allescheria boydii*). *Am. J. Med.* **61**, 632-640.
- 4 Winston, D. J., Jordan, M. C. & Rhodes, J. (1977) *Allescheria boydii* infections in the immunocompromised host. *Am. J. Med.* **63**, 830-835.
- 5 Lutwick, L. I., Rytel, M. W., Yanez, J. P., Galgiani, J. N. & Stevens, D. A. (1979) Deep infections from *Petriellidium boydii* treated with miconazole. *J. Am. Med. Assoc.* **241**, 272-273.
- 6 Nielson, H. S. (1967) Effects of amphotericin B in vitro on perfect and imperfect strains of *Allescheria boydii*. *Appl. Microbiol.* **15**, 86-91.
- 7 Galgiani, J. N., Stevens, D. A., Graybill, J. R., Stevens, D. L., Tillinghast, A. J. & Levine, H. B. (1984) *Pseudallescheria boydii* infections treated with ketoconazole. *Chest* **86**, 219-224.
- 8 Sheftel, T. G., Mader, J. T. & Cierney, G. (1987) *Pseudallescheria boydii* soft tissue abscesses. *Clin. Ortho.* **215**, 212-216.
- 9 Weber, D. J. & Rutala, W. (1988) Epidemiology of nosocomial fungal infections. In: McGinnis, M. R. (ed.), *Current Topics in Medical Mycology*. Volume 2. New York: Springer-Verlag, 305-377.
- 10 McGinnis, M. R., D'Amato, R. F. & Land, G. A. (1982) *Pictorial handbook of medically important fungi and aerobic actinomycetes*. New York: Praeger.
- 11 Kauffman, C. A., Jones, P. G., Bergman, A. G. & McAuliffe, L. S. (1983) Effect of prophylactic ketoconazole and nystatin on fungal flora. *Mykosen* **27**, 165-172.
- 12 Shadomy, S., Dixon, D. M. & May, R. (1982) A comparison of bifonazole (BAY H 4502) with clotrimazole in vitro. *Sabouraudia* **20**, 313-323.
- 13 Alsip, S. G. & Cobbs, C. G. (1986) *Pseudallescheria boydii* infection of the central nervous system in a cardiac transplant recipient. *South. Med. J.* **79**, 383-384.
- 14 Gumbart, C. H. (1983) *Pseudallescheria boydii* infection after bone marrow transplantation. *Ann. Intern. Med.* **99**, 193-194.
- 15 Walker, D. H., Adamec, T. & Krigman, M. (1978) Disseminated petriellidiosis (allescheriosis). *Arch. Pathol. Lab. Med.* **102**, 158-160.
- 16 Walsh, T. F. & Pizzo, P. A. (1988) Nosocomial fungal infections: a classification for hospital-acquired fungal infections and mycoses arising from endogenous flora or reactivation. *Ann. Rev. Microbiol.* **42**, 517-545.
- 17 Travis, L. B., Roberts, G. D. & Wilson, W. R. (1985) Clinical significance of *Pseudallescheria boydii*: A review of 10 years' experience. *Mayo Clin. Proc.* **60**, 531-537.
- 18 Brown, M. W., Maldonado, A. L., Meridith, C. G. & Speeg, K. V. (1985) Effect of ketoconazole on hepatic oxidative drug metabolism. *Clin. Pharmacol. Ther.* **37**, 290-297.
- 19 Patterson, T. F., Minitzer, P. & Andriole, V. T. (1990) Efficacy of fluconazole in experimental invasive aspergillosis. *Rev. Infect. Dis.* **12**, 281-285.

Correspondence: Dr T. F. Patterson, Yale University School of Medicine, Department of Medicine, Section of Infections Diseases, 333 Cedar Street - LCI 201, New Haven, CT 06510, USA.