

Kubo Tateki (Orcid ID: 0000-0003-1402-5383)

Jejunal Flap Transfer with Anterior Mediastinal Tracheostomy

## **Free Jejunal Flap Transfer Containing Multiple Vascular Pedicles for Pharyngoesophageal Reconstruction in Conjunction with Anterior Mediastinal Tracheostomy**

(Running Head: Jejunal Flap **Transfer** with Anterior Mediastinal Tracheostomy)

**Tateki Kubo, MD, PhD<sup>1</sup>, Tomoyuki Kurita, MD<sup>2</sup>, Hiroki Tashima, MD<sup>2</sup>, Shien Seike, MD<sup>1</sup>, Takashi Fujii, MD<sup>3</sup>, Masahiko Yano, MD, PhD<sup>4</sup>, Makoto Yamasaki, MD, PhD<sup>5</sup>, Yuichiro Doki, MD, PhD<sup>5</sup>, Ko Hosokawa, MD, PhD<sup>1</sup>**

<sup>1</sup>Department of Plastic Surgery, Osaka University Graduate School of Medicine, Osaka, Japan

<sup>2</sup>Department of Plastic and Reconstructive Surgery, Osaka Prefectural Hospital Organization, Osaka International Cancer Institute, Osaka, Japan

<sup>3</sup>Department of Head and Neck Surgery, Osaka Prefectural Hospital Organization, Osaka International Cancer Institute, Osaka, Japan

<sup>4</sup>Department of Gastroenterological Surgery, Osaka Prefectural Hospital Organization, Osaka International Cancer Institute, Osaka, Japan

<sup>5</sup>Department of Gastroenterological Surgery, Osaka University Graduate School of Medicine, Osaka, Japan

**Correspondence to:** Tateki Kubo, M.D., Ph.D.

Department of Plastic Surgery, Osaka University Graduate School of Medicine,

**This is the author manuscript accepted for publication and has undergone full peer review but has not been through the copyediting, typesetting, pagination and proofreading process, which may lead to differences between this version and the [Version of Record](#). Please cite this article as doi: [10.1002/micr.30359](https://doi.org/10.1002/micr.30359)**

2-2-C11 Yamadaoka, Suita-shi, Osaka 565-0871, Japan

E-mail: tateki@psurg.med.osaka-u.ac.jp

Tel: +81-6-6879-6056 **FAX:** +81-6-6879-6059

Author Manuscript

## Free Jejunal Flap Transfer Containing Multiple Vascular Pedicles for Pharyngoesophageal Reconstruction in Conjunction with Anterior Mediastinal Tracheostomy

(Running Head: Jejunal Flap Transfer with Anterior Mediastinal Tracheostomy)

### Abstract

**Background:** When pharyngoesophagectomy is performed in conjunction with anterior mediastinal tracheostomy, reconstructing both the trachea and alimentary tract is extremely difficult. We developed a novel one-stage reconstructive procedure using a single free jejunal flap containing multiple vascular pedicles to decrease postoperative morbidity and mortality. Free jejunal flap transfer with multiple vascular pedicles could offer a viable option for reducing associated life-threatening complications.

**Methods:** We performed a retrospective review of 34 patients who underwent free jejunal flap transfer with multiple vascular pedicles in anterior mediastinal tracheostomy and pharyngoesophagectomy due to lesions involving both the airway and esophagus. In all cases, one-stage reconstruction of the digestive tract and trachea was performed. Technical details and outcomes were analyzed.

**Results:** All 34 jejunal flaps (100%) survived. Major morbidity classified as Clavien–Dindo grades III and IV occurred in 10 (29.4%) and 0 (0%) patients, respectively

during hospitalization. With regard to common complications, anastomotic leakage from transferred jejunal flaps and surgical site infections occurred in 0 (0%) and 7 (20.6%) patients, respectively. Five (14.7%) patients experienced tracheal stoma dehiscence. Donor site morbidity was observed in 2 (5.9%) patients. The overall in-hospital mortality rate was 2.9%.

**Conclusions:** Our one-stage reconstruction procedure achieved low morbidity and low mortality rates following anterior mediastinal tracheostomy and pharyngoesophagectomy. Only one jejunal flap transfer is needed to simultaneously reconstruct the trachea and alimentary tract in a safe and reliable manner with this procedure.

## Introduction

Anterior mediastinal tracheostomy is a challenging procedure in which a tracheostomy stoma is constructed with the intrathoracic trachea to establish an airway,<sup>1</sup> and is associated with high mortality rates ranging from 5% to 19%.<sup>2,3</sup> This procedure is performed to treat extensive cervicothoracic malignancies and recurrence of laryngeal cancer at the stoma site.<sup>1, 2, 4-7</sup> Moreover, patients with extensive involvement of the proximal esophagus also require pharyngoesophagectomy and reconstruction. However, since resection and reconstruction of the trachea and esophagus each presents with a unique set of challenges, the difficulty and risk of combined tracheal and esophageal reconstruction rise exponentially.<sup>8</sup> Not only the complexities of tracheal reconstruction but also difficulties associated with digestive tract reconstruction (e.g., anastomotic leakage from the reconstructed digestive tract) inevitably increase the incidence of mediastinitis and mortality.<sup>9</sup> Ghali et al. reported that the goals of reconstruction for combined tracheal and esophageal defects are (1) to provide a secure airway, (2) to achieve reliable coverage of major blood vessels, and (3) to restore the continuity of the digestive tract. The third goal is sometimes achieved by performing two-stage reconstruction, as combined tracheal and esophageal reconstruction is quite complex.<sup>10</sup> To achieve all three goals in one stage **and** decrease postoperative morbidity and mortality, we developed a novel reconstructive procedure **involving** free

jejunal flap transfer. In this procedure, we harvest a long segment of jejunum containing multiple vascular pedicles and voluminous mesentery and transfer it as a free flap. Jejunal flaps with multiple vascular pedicles have high flap survival rates, since two or three pairs of arteries and veins are anastomosed to reduce the incidence of jejunal flap loss. This procedure also reduces postoperative complications such as major vessel rupture and surgical site infections (SSIs), as the redundant mesentery of the flap could be used as a mesenteric flap to protect major vessels and fill in dead space. Here we report on the usefulness of jejunal flaps containing multiple pedicles for pharyngoesophageal reconstruction combined with anterior mediastinal tracheostomy.

### **Patients and Methods**

This retrospective study was approved by the Ethics Committees of Osaka University Hospital (approval number 17124-2) and Osaka International Cancer Institute (approval number 1708215155). A total of 34 patients including 29 men and 5 women (mean age,  $63.7 \pm 5.9$  years; age range, 52-77 years) underwent free jejunal flap transfer for pharyngoesophageal reconstruction in conjunction with anterior mediastinal tracheostomy due to lesions involving both the airway and esophagus. Primary diagnoses were made from August 2003 to July 2017 and included esophageal cancer (25 patients) and hypopharyngeal cancer (6) which requires to

divide the high retrosternal trachea, and recurrent laryngeal cancer with cervical esophageal invasion (3). Sixteen patients received preoperative chemotherapy and radiotherapy, 4 patients received preoperative radiotherapy, and one patient received preoperative chemotherapy. In all cases, one-stage reconstruction of the digestive tract and trachea was performed with jejunal transfer and anterior mediastinal tracheostomy after resection of the trachea and pharyngoesophagectomy with (32 patients) or without (2) laryngectomy. Five patients with esophageal cancer involving the cervical and thoracic esophagus also required total esophagectomy with construction of a gastric tube, which was pulled up to the level of the manubrium and anastomosed to the distal side of the transferred jejunal flap at the same time. All patients were examined for postoperative morbidity and mortality during hospitalization using the Clavien–Dindo grading system.<sup>11</sup> Influence of preoperative radiotherapy on the occurrence of major postoperative complications classified as Clavien–Dindo grades III, IV, and V was assessed. Rates of early postoperative complications were also examined, specifically, SSIs, tracheal stoma dehiscence, any salivary leakage from the flap anastomotic site, and donor site morbidity, which are particularly common in pharyngoesophageal reconstruction and tracheostoma creation. In addition, we assessed postoperative enteric stricture and swallowing function.

## Surgical Procedure

**Free Jejunal Flap with Multiple Vascular Pedicles.** The jejunum was exposed through an upper midline abdominal incision. A loop of the bowel roughly 20 cm distal to the ligament of Treitz was selected. A long jejunum segment roughly 80-120 cm in length was harvested with the second, third, and fourth jejunal vessels, and occasionally with the fifth vessel or a branch of the first jejunal vessel (mean number of jejunal vessels per flap,  $2.6 \pm 0.7$ ; range, 2 - 4) (Figs. 1a and 1b). As the jejunal vessels are typically proximal to each other, flexibility of vessels was achieved by dividing or removing the mesentery between pedicles, while carefully preserving the intactness of the arcade vessel, to ease later vascular anastomoses. The length of proximal and distal pedicles was roughly 20 cm when three pedicles were harvested. This helped vascular pedicles reach either side of the neck and even the chest, thereby providing more options for the choice of recipient vessels when performing multiple anastomoses (Table 1). The exteriorized monitoring flap (i.e., the intestinal segment), originally reported by Katsaros J et al.<sup>12</sup> and Dionyssopoulos A et al.<sup>13</sup>, was prefabricated on both pharyngeal and esophageal sides (Fig. 1b); the side to be used as the monitoring flap was subsequently determined based on the position of recipient vessels. The distal side of the jejunum was trimmed, and jejunoesophagostomy was performed in an end-to-end manner, followed by trimming of the proximal side of the jejunum and pharyngojejunosostomy in an end-to-end manner. In two patients who



Author Manuscript

didn't undergo laryngectomy, the proximal side of the jejunum was trimmed and sutured to the pharynx in an end-to-end manner, as in the cases of 32 patients who underwent laryngectomy. In five patients who underwent combined gastric pull-up, the gastric tube was pulled through the posterior mediastinum to the level of the manubrium and anastomosed to the distal side of the transferred jejunum. Multiple pairs of jejunal arteries and veins were anastomosed under the microscope using microvascular anastomotic couplers for end-to-end venous anastomoses. The redundant mesentery was set to fill in dead space, protect major vessels, and cover the intestinal anastomotic area. Special attention was paid to locate the mesentery between the tracheal stump and innominate artery to prevent innominate artery rupture. To close the donor site, abdominal closure and small bowel anastomosis were performed by general surgeons. In uneventful cases, the exteriorized intestinal segment was tied and excised under local anesthesia in the operating room, followed by skin closure.

**Anterior Mediastinal Tracheostomy.** Anterior mediastinal tracheostomy was performed as previously described.<sup>5, 6, 14</sup> Briefly, the manubrium, the medial third or half of the clavicle, and the adjacent first rib on both sides were resected for proper neostoma construction. Division of the second costal cartilage and sternal division at or below the sternomanubrial junction were performed if it was anticipated that very

distal division of the trachea would be required. The tracheal stump was relocated to the right side of the innominate artery in all but three patients. The innominate vein was divided to create a sufficient space for the mediastinal stoma, if necessary. The tracheal stump was sutured to the native chest skin as an anterior mediastinal tracheostoma.

**Statistical analysis.** Differences between groups were determined by Fisher's exact test.  $P < 0.05$  was considered statistically significant. Statistical analysis was performed using Excel 2007 (Microsoft, USA) with Statcel2 (OMS, Saitama, Japan).

## Results

All 34 jejunal flaps (100%) survived without any partial necrosis, and no patients had flap congestion/ischemia requiring emergent revision/thrombectomy. The highest-grade complication was reviewed for each patient using the Clavien–Dindo grading system. The overall complication rate was 70.6% (Table 2). Major morbidity classified as Clavien–Dindo grades IIIa, IIIb, and IV occurred in 7 (20.6%), 3 (8.8%), and 0 (0%) patients, respectively. Specifically, grade IIIa complications included pleural effusion (8), pneumothorax (1), mild stenosis of the jejunoesophagostomy site (1), and hematoma in the neck (1) (Table 3). Grade IIIb complications included thoracic empyema (1), intraabdominal abscess (1), hemorrhage from the intercostal

muscle (1), dehiscence of the remnant larynx (1), and partial necrosis of the trachea (1). There was one postoperative death (Clavien–Dindo grade V). In this patient, innominate artery rupture occurred on the 23rd postoperative day and graft replacement of the innominate artery and pectoralis muscle and deltopectoral flap transfer were performed. However, the patient died of an unknown cause (presumably from innominate artery re-rupture) on the 48th postoperative day. The overall in-hospital mortality was 2.9%. Regarding the influence of preoperative radiotherapy, the occurrence of major postoperative complications was significantly higher ( $p < 0.05$ ) in irradiated patients (Table 4).

With regard to common complications, salivary leakage from the flap anastomotic site and SSIs occurred in 0 (0%) and 7 (20.6%) patients, respectively. Among the 7 patients with SSIs, 5 (14.7%) required reopening of the incision site for wound drainage, and the remaining 2 (5.9%) were treated with antibiotics. Five (14.7%) patients experienced tracheal stoma dehiscence; 4 were managed conservatively, and the other was managed by re-suturing after debridement under general anesthesia. Donor site morbidity was observed in 2 (5.9%) patients and included intraabdominal abscess and wound dehiscence, without any nutritional absorption disorder.

We assessed postoperative enteric stricture and swallowing function, excluding 4 with inadequate follow-up, in-hospital death or early tumor recurrence. Enteric

stenosis occurred in 7 (23.3%) of 30 patients. Anastomotic stenosis was successfully treated with dilatation therapy in most patients. In the evaluation of swallowing function, twenty nine (96.7%) tolerated an oral diet, whereas one (3.3%) were dependent on an oral diet supplemented by tube feeding.

### **Representative Case**

A 62-year-old man with cervical esophageal cancer with tracheal invasion underwent pharyngoesophagectomy with laryngectomy and bilateral neck dissection (Fig. 2a). Immediate reconstruction was performed using a 120-cm jejunal flap with four vascular pedicles (second, third, and fourth jejunal vessels and a branch of the first jejunal vessel). The jejunum was anastomosed to the pharynx and thoracic esophagus (Fig. 2b). The second jejunal artery was anastomosed to the right superior thyroid artery, and the branch of the first jejunal vein to the right common facial vein. The fourth jejunal artery was anastomosed to the left transverse cervical artery, and the fourth jejunal vein to the left internal mammary vein. The redundant mesentery was used to separate the trachea and innominate artery, fill in dead space, protect major vessels, and cover the intestinal anastomotic area (Fig. 2c). Finally, the remnant trachea was sutured to the native chest skin (Fig. 2d).

### **Discussion**

Anterior mediastinal tracheostomy following resection of extensive cervicothoracic tumors is a challenging procedure associated with high morbidity and mortality. This procedure was introduced by Waddell et al.<sup>15</sup> in 1959 and Sisson et al.<sup>7</sup> in 1962, with reported mortality rates of 33-50%.<sup>16</sup> Although only a few reports have described the postoperative course after anterior mediastinal tracheostomy since 1980,<sup>1-3, 5, 6, 14, 17-22</sup> advances in operative techniques and patient care have dramatically reduced mortality rates to 5-19%.<sup>2, 3</sup> Innominate artery rupture is the main cause of mortality and is associated with pressure necrosis of the innominate artery caused by tension on the tracheostoma resulting from a short remnant trachea. Therefore, well-vascularized tissue is interposed between the remnant trachea and innominate artery (e.g., pectoralis major flap,<sup>1, 3, 5, 16, 19, 20</sup> omental flap,<sup>17, 22, 23</sup> and latissimus dorsi flap).<sup>5, 10</sup>

Following pharyngoesophagectomy, alimentary tract reconstruction is performed using visceral (e.g., stomach, jejunum, and colon), musculocutaneous, or fasciocutaneous flaps in order to restore the continuity of the digestive tract.<sup>6, 24</sup> In particular, the use of free jejunal flaps has been considered reliable due to low complication rates and low donor site morbidity,<sup>25, 26</sup> with high overall success rates of 92-97%.<sup>24, 25, 27-31</sup> We aimed to achieve restoration of digestive tract continuity in conjunction with anterior mediastinal tracheostomy using a novel one-stage technique to reconstruct both the trachea and alimentary tract, although two-stage

reconstruction is sometimes used given the complexity of combined tracheal and esophageal reconstruction<sup>10</sup>. This technique uses a long segment of jejunum containing multiple pedicles as a free flap. This flap is much longer than ordinary jejunal flaps (Figs. 1b and 1c) and contains a redundant mesentery after trimming the unnecessary intestinal portion. The redundant mesentery can be used as a mesenteric flap to separate the remnant trachea and innominate artery during anterior mediastinal tracheostomy. Furthermore, this redundant mesentery has additional advantages; it can protect other major vessels such as the innominate vein, subclavicular and carotid arteries, and the internal jugular vein, fill in dead space, and cover the intestinal anastomotic area, thereby decreasing postoperative complications such as major vessel rupture, SSIs, and pharyngoesophageal fistula formation, which are also linked to innominate artery rupture.<sup>5</sup> Generally, SSIs occur in head and neck cancer surgery with flap reconstruction at a rate of 8.1 to 40.6%.<sup>32-34</sup> In this report, the rate of SSIs was 20.6%, and only 8.8% required re-opening of the incision for pus drainage. These rates are not so high considering the invasiveness of surgery. With respect to fistula formation, Pazza et al.<sup>35</sup> reported an occurrence rate of 12% among 1014 cases using jejunal flaps in ordinary pharyngoesophageal reconstruction. Although the number of cases was limited, no intestinal anastomotic leakage was observed in our patients. These findings suggest that jejunal flap transfer with multiple vascular pedicles is a safe and reliable procedure. Yamamoto et al. used the

mesenteric part of a jejunal flap to protect the innominate artery in combination with omental and pectoralis major flaps in three cases.<sup>36</sup> Our method differs largely in that we harvested a long (80-120 cm) segment of jejunum containing multiple vascular pedicles with a redundant mesentery, as compared to a 30-cm segment with one vascular pedicle in the previously reported cases. Moreover, our jejunal flaps have voluminous mesenteries which do not require transfer of the second flap, and one flap transfer is sufficient even for such complex reconstruction.

To prevent arterial rupture, tissue is interposed between the trachea and innominate artery, commonly with a pectoralis major flap,<sup>1, 3, 5, 16, 19, 20</sup> omental flap,<sup>17, 22, 23</sup> or latissimus dorsi flap<sup>5, 10</sup>. In particular, pectoralis major flaps are used most frequently for their feasibility (i.e., easy to elevate) and close location in the operative field. However, muscle flaps are known to atrophy over the postoperative course due to denervation.<sup>37, 38</sup> Yamaguchi *et al.* reported that muscle volume decreased to 50% in 12 months,<sup>38</sup> and therefore, muscle flaps possibly lose the thickness required to prevent pressure necrosis of the innominate artery. On the other hand, fat volume is resistant to postoperative atrophy as long as patients remain disease-free, and may even exhibit a propensity to increase postoperatively in some patients.<sup>38</sup> In fact, one of our patients showed maintained fat volume on CT 11 months postoperatively (Fig. 3). Therefore, our procedure may be superior to the method that uses a pectoralis major muscle flap, although a long-term follow-up study will be necessary given the

relatively poor prognosis of anterior mediastinal tracheostomy and pharyngoesophagectomy.

A recent study reported the use of microsurgical free flaps as a clinically safe reconstructive procedure in the head and neck region, with success rates exceeding 95%.<sup>39</sup> However, once total flap loss occurs due to anastomosed vessel thrombosis, it is apparently life-threatening given the nature and invasiveness of this type of surgery. Moreover, occlusion of anastomosed vessels and subsequent total flap loss are unavoidable even for skilled surgeons. Therefore, we developed a procedure for multiple anastomoses with the aim of reducing the incidence of total jejunal flap loss, since anastomosing multiple pairs of arteries and veins ensures flap survival. We harvested a long jejunum segment preserving the intactness of the arcade vessel so that one pair of vascular anastomosis is sufficient to perfuse the entire flap. That is, even if one vessel is thrombosed, another vessel can supply blood to the whole jejunal flap through the arcade vessel in the mesentery, thereby achieving a nearly 0% total flap loss rate. We started off with flaps containing two vascular pedicles and then switched to those containing more pedicles over time. Currently, our standard procedure requires flaps with three pedicles. Furthermore, vascular pedicles used in our procedure are longer than ordinary jejunal flaps, and can reach either side of the neck and chest. This feature increases options for the choice of recipient vessels (Table 1) and likely contributes to increased flap success rates. Numajiri et al.



previously reported 5 cases of doubly vascularized jejunal flap transfer,<sup>40</sup> which is similar to our procedure using two jejunal root vessels. The major difference is that we harvest a long (80-120 cm) jejunum segment with a redundant mesentery, as compared to 30 cm in their cases. Therefore, our jejunal flaps have voluminous mesenteries covering major blood vessels, with fewer life-threatening complications such as innominate rupture despite SSIs.

Our postoperative stricture rate was 23.3%, as compared to previously reported rates of 0-30%.<sup>29,30,35,41-44</sup> Our patients also demonstrated good swallowing function, with 96.7% tolerating an oral diet with no need for tube feeding, compared to 65-83% in previous reports,<sup>29,45</sup> although our sample size was rather small.

Although it is more time-consuming to harvest a long jejunum segment and dissect multiple vascular pedicles compared to ordinary jejunal harvest, a two-team approach is possible during tumor excision. With this approach, flap harvesting itself would not consume any additional operating time other than the time required for anastomosing additional vessels. Anastomoses of vessels reportedly require 22 min (arterial anastomosis) or 25 min (venous anastomosis) by manual suture, and can be reduced to 5 minutes using an anastomotic venous coupling device.<sup>46-48</sup> That is, this procedure requires an additional 47 minutes with manual suture, or 27 minutes with a coupling device to complete the anastomosis of an additional artery and vein. In fact, at our institution, anastomosis of an additional artery and vein required an average of

42 minutes in 15 recent cases. However, we consider that the extra time is acceptable, given that a 0% flap failure rate can be achieved.

## Conclusion

Our one-stage reconstruction procedure achieved low morbidity and low mortality rates following anterior mediastinal tracheostomy and pharyngoesophagectomy. Only one flap transfer is made to simultaneously reconstruct the trachea and alimentary tract in this procedure. Moreover, with multiple vascular pedicle anastomoses, the rate of flap loss is reduced. Therefore, our procedure can be performed safely and reliably following anterior mediastinal tracheostomy and pharyngoesophagectomy.

## References

1. Maipang T, Singha S, Panjapiyakul C, Totemchokchyakarn P. Mediastinal tracheostomy. *Am J Surg* 1996;171:581-586.
2. Conti M, Benhamed L, Mortuaire G, Chevalier D, Pincon C, Wurtz A. Indications and results of anterior mediastinal tracheostomy for malignancies. *Ann Thorac Surg* 2010;89:1588-1595.
3. Chan YW, Yu Chow VL, Lun Liu LH, Ignace Wei W. Manubrial resection and anterior mediastinal tracheostomy: friend or Foe? *Laryngoscope* 2011;121:1441-1445.
4. Grillo HC. Terminal or mural tracheostomy in the anterior mediastinum. *J Thorac Cardiovasc Surg* 1966;51:422-427.
5. Berthet JP, Garrel R, Gimferrer JM, Paradela M, Marty-Ane CH, Molins L, Gomez-Caro A. Anterior mediastinal tracheostomy as salvage operation. *Ann Thorac Surg* 2014;98:1026-1033.
6. Orringer MB. Anterior mediastinal tracheostomy with and without cervical exenteration. *Ann Thorac Surg* 1992;54:628-636; discussion 636-637.
7. Sisson GA, Straehley CJ, Jr., Johnson NE. Mediastinal dissection for recurrent cancer after laryngectomy. *Laryngoscope* 1962;72:1064-1077.
8. Ng T. Who is your plastic surgeon? The importance of an experienced reconstructive surgical colleague. *J Thorac Cardiovasc Surg* 2015;150:1266-1267.
9. Chow VL, Chan JY, Wei WI. Salvage surgery for recurrent carcinoma of the cervical esophagus postesophagectomy. *Head Neck* 2015;37:1170-1175.
10. Ghali S, Chang EI, Rice DC, Walsh GL, Yu P. Microsurgical reconstruction of combined tracheal and total esophageal defects. *J Thorac Cardiovasc Surg* 2015;150:1261-1266.
11. Dindo D, Demartines N, Clavien PA. Classification of surgical complications: a new proposal with evaluation in a cohort of 6336 patients and results of a survey. *Ann Surg* 2004;240:205-213.

12. Katsaros J, Banis JC, Acland RD, Tan E. Monitoring free vascularised jejunum grafts. *Br J Plast Surg* 1985;38:220-222.
13. Dionyssopoulos A, Odobescu A, Foroughi Y, Harris P, Karagergou E, Guertin L, Ferraro P, Danino AM. Monitoring buried jejunum free flaps with a sentinel: a retrospective study of 20 cases. *Laryngoscope* 2012;122:519-522.
14. Bagheri R, Rahim MB, Majidi M, Tabari A, Akhlaghi S, Tabari A. Anterior mediastinal tracheostomy for malignancy: analysis of 12 cases. *Asian Cardiovasc Thorac Ann* 2013;21:187-192.
15. Waddell WR, Cannon B. A technic for subtotal excision of the trachea and establishment of a sternal tracheostomy. *Ann Surg* 1959;149:1-8.
16. Terz JJ, Wagman LD, King RE, Brown P, Neifeld JP, Lawrence W, Jr. Results of extended resection of tumors involving the cervical part of the trachea. *Surgery, gynecology & obstetrics* 1980;151:491-496.
17. Grillo HC, Mathisen DJ. Cervical exenteration. *Ann Thorac Surg* 1990;49:401-408; discussion 408-409.
18. Kato H, Tachimori Y, Watanabe H, Nakatsuka T, Mashima K, Ebihara S, Harii K. Mediastinal tracheostomy during esophagectomy for cervicothoracic esophageal carcinoma invading the proximal trachea. *J Surg Oncol* 1994;55:78-83.
19. Sisson GA, Goldman ME. Pectoral myocutaneous island flap for reconstruction of stomal recurrence. *Arch Otolaryngol* 1981;107:446-449.
20. Biller HF, Krespi YP, Lawson W, Baek SM. A one-stage flap reconstruction following resection for stomal recurrence. *Otolaryngol Head Neck Surg* 1980;88:357-360.
21. Neifeld JP, Theogaraj SD, Mehrhof AI. Reconstruction after mediastinal tracheostomy. *Am J Surg* 1984;148:505-508.
22. Kuwabara Y, Sato A, Mitani M, Shinoda N, Hattori K, Suzuki T, Fujii Y. Use of omentum for mediastinal tracheostomy after total laryngoesophagectomy. *Ann Thorac Surg* 2001;71:409-413.
23. Mathisen DJ, Grillo HC, Vlahakes GJ, Daggett WM. The omentum in the

- management of complicated cardiothoracic problems. *J Thorac Cardiovasc Surg* 1988;95:677-684.
24. Hsieh MH, Yang YT, Tsai YJ, Kuo YR, Lin PY. Comparison of the outcomes of free jejunal flap reconstructions of pharyngoesophageal defects in hypopharyngeal cancer and corrosive injury patients. *Microsurgery* 2016.
  25. Okazaki M, Asato H, Okochi M, Suga H. One-segment double vascular pedicled free jejunum transfer for the reconstruction of pharyngoesophageal defects. *J Reconstr Microsurg* 2007;23:213-218.
  26. Razdan SN, Albornoz CR, Matros E, Paty PB, Cordeiro PG. Free Jejunal Flap for Pharyngoesophageal Reconstruction in Head and Neck Cancer Patients: An Evaluation of Donor-Site Complications. *J Reconstr Microsurg* 2015;31:643-646.
  27. Nakatsuka T, Harii K, Asato H, Ebihara S, Yoshizumi T, Saikawa M. Comparative evaluation in pharyngo-oesophageal reconstruction: radial forearm flap compared with jejunal flap. A 10-year experience. *Scand J Plast Reconstr Surg Hand Surg* 1998;32:307-310.
  28. Nakatsuka T, Harii K, Asato H, Takushima A, Ebihara S, Kimata Y, Yamada A, Ueda K, Ichioka S. Analytic review of 2372 free flap transfers for head and neck reconstruction following cancer resection. *J Reconstr Microsurg* 2003;19:363-368; discussion 369.
  29. Yu P, Lewin JS, Reece GP, Robb GL. Comparison of clinical and functional outcomes and hospital costs following pharyngoesophageal reconstruction with the anterolateral thigh free flap versus the jejunal flap. *Plast Reconstr Surg* 2006;117:968-974.
  30. Chan YW, Ng RW, Liu LH, Chung HP, Wei WI. Reconstruction of circumferential pharyngeal defects after tumour resection: reference or preference. *J Plast Reconstr Aesthet Surg* 2011;64:1022-1028.
  31. Sugiyama N, Takao S, Suzuki E, Kimata Y. Risk factors of thrombosis in a single method of microsurgical head and neck reconstruction: A multi-institutional study of 773 reconstructions with a free jejunal graft after total

- pharyngolaryngoesophagectomy for hypopharyngeal cancer. *Head Neck* 2016;38:1688-1694.
32. Simons JP, Johnson JT, Yu VL, Vickers RM, Gooding WE, Myers EN, Pou AM, Wagner RL, Grandis JR. The role of topical antibiotic prophylaxis in patients undergoing contaminated head and neck surgery with flap reconstruction. *Laryngoscope* 2001;111:329-335.
  33. Karakida K, Aoki T, Ota Y, Yamazaki H, Otsuru M, Takahashi M, Sakamoto H, Miyasaka M. Analysis of risk factors for surgical-site infections in 276 oral cancer surgeries with microvascular free-flap reconstructions at a single university hospital. *J Infect Chemother* 2010;16:334-339.
  34. Kamizono K, Sakuraba M, Nagamatsu S, Miyamoto S, Hayashi R. Statistical analysis of surgical site infection after head and neck reconstructive surgery. *Annals of surgical oncology* 2014;21:1700-1705.
  35. Piazza C, Taglietti V, Nicolai P. Reconstructive options after total laryngectomy with subtotal or circumferential hypopharyngectomy and cervical esophagectomy. *Curr Opin Otolaryngol Head Neck Surg* 2012;20:77-88.
  36. Yamamoto Y, Minakawa H, Fukuda S, Furuta Y, Yagi K, Okushiba S, Motohara T. Reconstruction following total laryngopharyngoesophagectomy and extensive resection of the superior mediastinum. *Plast Reconstr Surg* 1997;99:506-510.
  37. Hallock GG. Long-term superiority of composite versus muscle-only free flaps for skull coverage. *Ann Plast Surg* 2004;52:507-510; discussion 510-511.
  38. Yamaguchi K, Kimata Y, Onoda S, Mizukawa N, Onoda T. Quantitative analysis of free flap volume changes in head and neck reconstruction. *Head Neck* 2012;34:1403-1407.
  39. Kubo T, Matsuda K, Kiya K, Hosokawa K. Behavior of anastomozed vessels and transferred flaps after anastomosed site infection in head and neck microsurgical reconstruction. *Microsurgery* 2016;36:658-663.
  40. Numajiri T, Sowa Y, Nishino K, Fujiwara H, Nakano H, Shimada T, Nakai S, Hisa Y. Double vascular anastomosis in the neck for reliable free jejunal

transfer. *Br J Oral Maxillofac Surg* 2010;48:511-514.

41. Oniscu GC, Walker WS, Sanderson R. Functional results following pharyngolaryngoesophagectomy with free jejunal graft reconstruction. *Eur J Cardiothorac Surg* 2001;19:406-410.
42. Nyquist GG, Hier MP, Dionisopoulos T, Black MJ. Stricture associated with primary tracheoesophageal puncture after pharyngolaryngectomy and free jejunal interposition. *Head Neck* 2006;28:205-209.
43. Hanson RP, Chow TK, Feehan E, Eadie PA, Timon CT, Keogh S. Analysis of functional results and quality of life following free jejunal flaps for reconstruction after upper aerodigestive neoplastic resection: the St James's experience. *J Plast Reconstr Aesthet Surg* 2007;60:577-582.
44. Kadota H, Fukushima J, Nakashima T, et al. Comparison of salvage and planned pharyngolaryngectomy with jejunal transfer for hypopharyngeal carcinoma after chemoradiotherapy. *Laryngoscope* 2010;120:1103-1108.
45. Coleman JJ, 3rd, Tan KC, Searles JM, Hester TR, Nahai F. Jejunal free autograft: analysis of complications and their resolution. *Plast Reconstr Surg* 1989;84:589-595.
46. Zeebregts C, Acosta R, Bolander L, van Schilfgaarde R, Jakobsson O. Clinical experience with non-penetrating vascular clips in free-flap reconstructions. *Br J Plast Surg* 2002;55:105-110.
47. Grewal AS, Erovic B, Strumas N, Enepekides DJ, Higgins KM. The utility of the microvascular anastomotic coupler in free tissue transfer. *Can J Plast Surg* 2012;20:98-102.
48. Rozen WM, Whitaker IS, Acosta R. Venous coupler for free-flap anastomosis: outcomes of 1,000 cases. *Anticancer Res* 2010;30:1293-1294.

### Figure Legends

Figure 1. (a) A long segment of jejunum is harvested based on the second, third, and fourth jejunal vessels. (b) After removal of excess intestinal portions. Black arrows show the short segment of jejunum used as an exteriorized monitoring flap. (c) An ordinary jejunal flap with one vascular pedicle.

Figure 2. Intraoperative view. (a) The defect after total pharyngolaryngoesophagectomy and bilateral neck dissection, and relocation of the trachea (white arrow) below the innominate artery (white arrowhead). (The top of each photograph in Figure 2 corresponds to the cephalic direction, and the bottom corresponds to the caudal direction.) (b) The jejunum (black arrow) was anastomosed to the pharynx and esophagus. (c) The redundant mesentery was used to separate the trachea (white arrow) and innominate artery (white arrowhead), fill in dead space, and cover the intestinal anastomotic area. Black arrow indicates the jejunum. (d) Skin closure was performed. White arrow shows a short segment of the jejunum externalized to monitor perfusion.

Figure 3. Postoperative CT scan shows non-atrophied mesenteric fat (black arrowhead) separating the innominate artery (white arrowhead) and trachea (white arrow) 11 months postoperatively.





## Table Legends

Table 1. Recipient vessels used for anastomoses.

Table 2. Overall complications.

Table 3. Major complications classified as Clavien–Dindo grades IIIa, IIIb, and V.

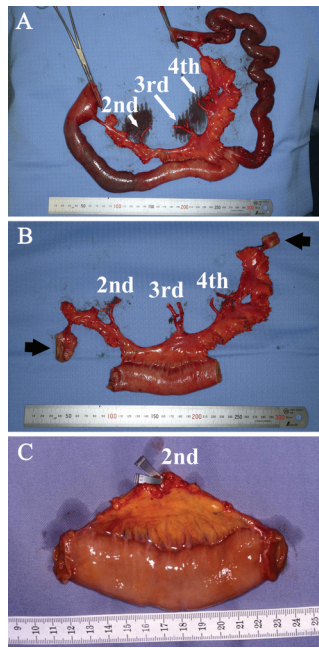
**Table 4. Influence of preoperative radiotherapy on the occurrence of major complications classified as Clavien–Dindo grades IIIa, IIIb, and V.**

## Note

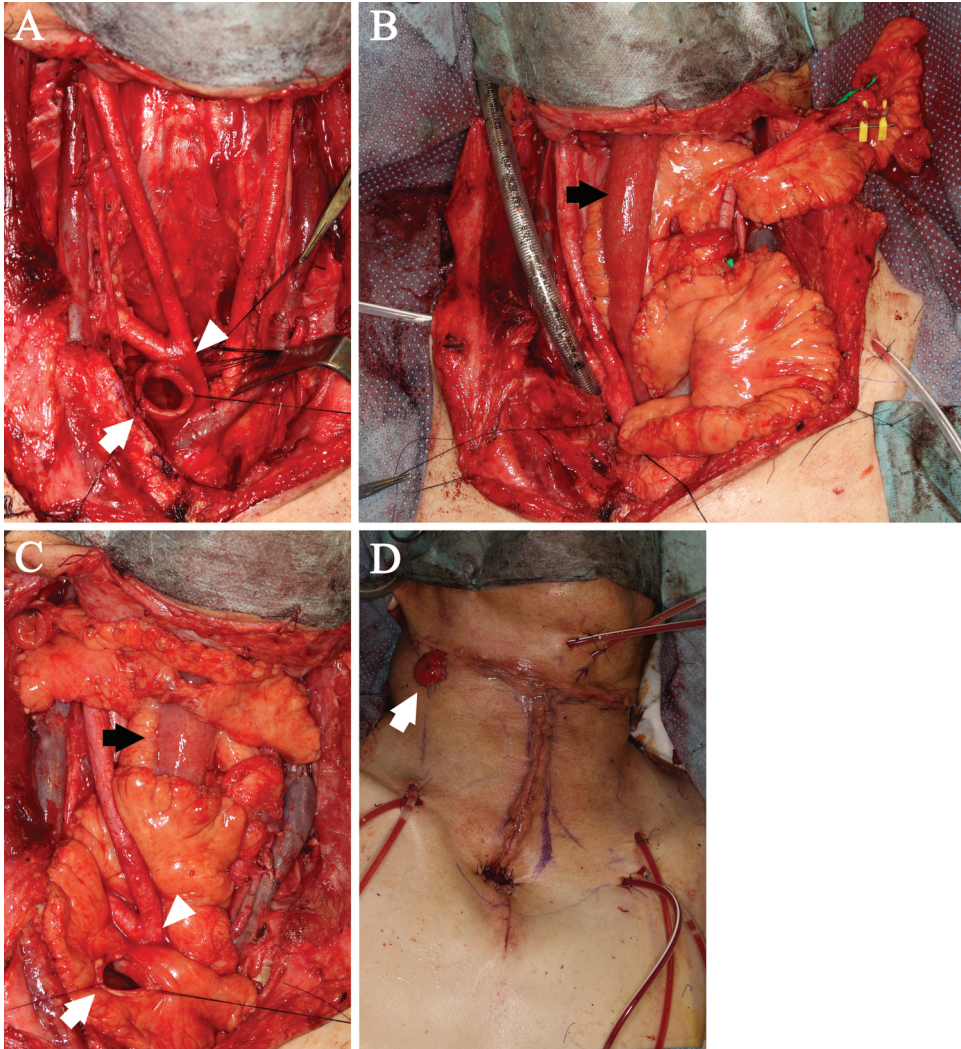
This paper was presented at the 9th Congress of World Society for Reconstructive Microsurgery (WSRM 2017), Seoul, Korea, 2017.

## Conflict of Interest

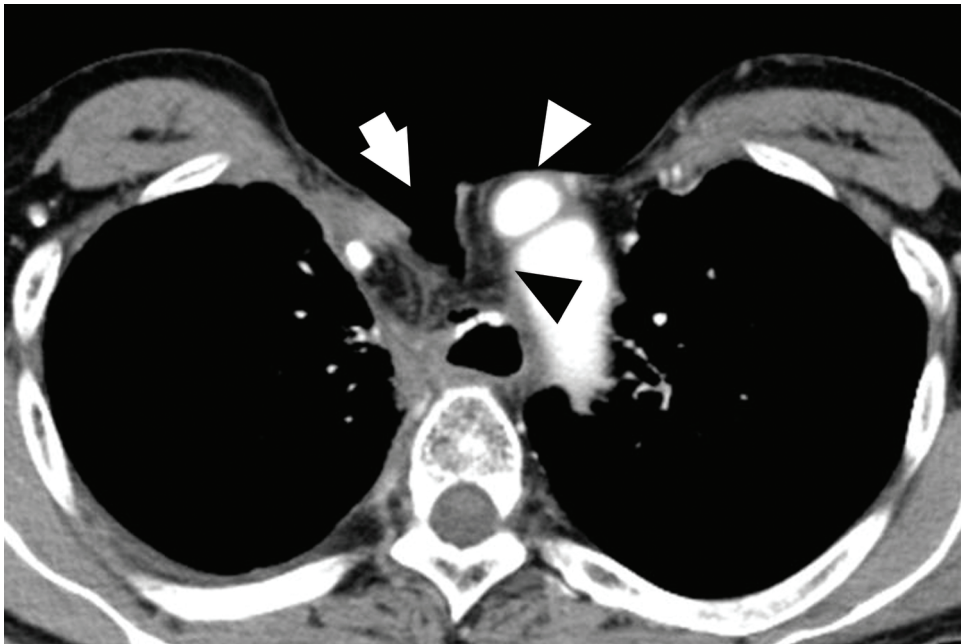
The authors report no conflicts of interest. The authors alone are responsible for the content and writing of the paper.



micr-18-0098-File002.tif



micr-18-0098-File003.tif



micr-18-0098-File004.tif

**Table 1** Recipient vessels used for anastomoses

Artery	Number	Vein	Number
Transverse cervical	30	External jugular	21
Superior thyroid	30	Common facial	14
Internal mammary	9	Transverse cervical	12
Inferior thyroid	1	Internal mammary	9
Thoracoacromial	1	Internal jugular	4
		Middle thyroid	3
		Superior thyroid	2
		Anterior jugular	2
		Anterior vertebral	1
		Thoracoacromial	1

**Table 2** Overall complications

Clavien–Dindo grade	Patients
Grade I	4 (11.8%)
Grade II	9 (26.5%)
Grade IIIa	7 (20.6%)
Grade IIIb	3 (8.8%)
Grade IVa	0 (0%)
Grade IVb	0 (0%)
Grade V	1 (2.9%)

**Table 3** Major complications classified as Clavien–Dindo grades IIIa, IIIb, and V

Complications	Number
Grade IIIa	
Pleural effusion	8
Pneumothorax	1
Mild stenosis of jejunoesophagostomy site	1
Hematoma in the neck	1
Grade IIIb	
Thoracic empyema	1
Intraabdominal abscess	1
Hemorrhage from the intercostal muscle	1
Dehiscence of remnant larynx	1
Partial necrosis of the trachea	1
Grade V	
Innominate artery rupture	1



**Table 4** Influence of preoperative radiotherapy on the occurrence of major complications classified as Clavien–Dindo grades IIIa, IIIb, and V

Patient group	Major complications	
	Yes	No
Irradiated	10	10
Non-irradiated	1	13