

**Pediced Iliac Crest Bone Flap Transfer for the Treatment of
Upper Femoral Shaft Fracture Nonunion: An Anatomic Study
and Clinical Applications**

Dewei Zhao, M.D., Ph.D.,¹ Meng Cao, M.D.,¹ Tienan Wang, M.D.,¹
Benjie Wang, M.D., Ph.D.,¹ Baoyi Liu, M.D., Ph.D.,¹
William C. Lineaweaver, M.D.²

¹ Department of Orthopedic Surgery, Zhongshan Hospital of
Dalian University, Dalian, China

² JMS Burn and Reconstructive Center, Jackson, Mississippi

Corresponding author: Dewei Zhao, M.D., Ph.D.

Zhongshan Hospital, Dalian University

6 Jiefang Street

Dalian, Liaoning 116001

P.R. China

Email: zhaodewei2016@163.com

Running title: Treatment for The Upper Femoral Shaft Fracture
Nonunion

This is the author manuscript accepted for publication and has undergone full peer review but has not been through the copyediting, typesetting, pagination and proofreading process, which may lead to differences between this version and the [Version record](#). Please cite this article as [doi:10.1002/micr.30278](https://doi.org/10.1002/micr.30278).

Pediced Iliac Crest Bone Flap Transfer for the Treatment of Upper Femoral Shaft Fracture Nonunion: An Anatomic Study and Clinical Applications

Abstract

Purpose: We present the results of a study on the anatomy of the ascending branch of the lateral circumflex femoral artery (AB-LCFA) and the use of the pediced iliac bone flap transfer perfused by AB-LCFA combined with external fixation for the treatment of the nonunion of upper femoral shaft fractures.

Methods: The orientation, diameter, length and distribution of the AB-LCFA from 40 lower limbs of adult cadavers were dissected and measured. From 2000 to 2012, 13 patients with nonunion of upper femoral shaft fractures underwent pediced iliac bone flap transfer perfused by the AB-LCFA combined with external fixation. The time of bone fracture union was recorded based on X-ray examination. The functional results of the femoral shaft were evaluated by the Klemm classification.

Results: The lateral circumflex femoral artery (LCFA) divided into ascending, transverse, and descending branches in 32 specimens (80%). The diameter of the AB-LCFA at the origin was 3.15 ± 0.9 mm and the length of the AB-LCFA was 8.51 ± 3.06 cm. The postoperative course of the procedure was uneventful in all 13 patients. The average follow-up was 15 months. Bone union was achieved in all patients and the average union time was 5.3 months. 12 patients achieved excellent or good functional results based on the Klemm classification.

Conclusion: The AB-LCFA has a consistent orientation and abundant blood flow. The transfer of the iliac crest bone flap perfused by the AB-LCFA while combined with external fixation could be an option for treating the nonunion of upper femoral shaft fractures.

Keywords: Femoral fracture nonunion, Anatomy, Ascending branch, Lateral circumflex femoral artery, Pediced bone flap.

Introduction

The US Food and Drug Administration defines a nonunion as a fractured bone that has not completely healed within 9 months of injury and that has not shown progression towards healing over 3 consecutive months on serial radiographs.¹ Along with a deeper understanding of human biomechanics and the optimized design of implants, the cure rate of femoral shaft fractures is steadily increasing. However, nonunion of femoral shaft fractures occurs frequently, producing severe consequences. The incidence of nonunion remains high despite secondary surgery, and the long-term prognosis is poor.²⁻⁵ Currently, the treatment for nonunion of femoral shaft fractures includes replacement of the intramedullary nail, external fixation, plate fixation, electric or ultrasound stimulation, autogenous or heterogeneous bone grafting, and the administration of bone morphogenetic proteins (BMPs).⁴ Autogenous bone grafting is considered standard for the nonunion of bone fractures,⁶ although it is still controversial.⁷⁻¹⁰ Autogenous bone grafting has been extensively used in treating the nonunion of fractures due to its osteogenic advantages. The iliac crest has been the major source of bone grafting for abundant mass and structural support.¹¹

With the rapid development of surgical techniques, pedicled bone flap transfer has become an important reconstructive option. In cases of intractable nonunion, pedicled bone grafts are desirable.¹² The procedure can achieve quick restoration of the graft blood supply, which facilitates osseointegration at the nonunion of the fracture and improves the functional recovery of the reconstructive extremity.¹³⁻¹⁹

In this report, we present the results of a study on the anatomy of the AB-LCFA and the use of a pedicled iliac crest bone flap transfer perfused by the AB-LCFA combined with external fixation for treating the nonunion of upper femoral shaft fractures in a series of 13 patients.

Materials and Methods

Anatomic Study

In this study, lower limb specimens were investigated in 40 adult cadavers, of which 18 were male and 22 were female. The ages of the specimens were between 26 and 57 years. The cadavers were perfused with red latex via the femoral artery for one week. After the lower limbs had been dissected, the femoral and deep femoral artery were exposed and the origin of LCFA was studied for variations. The orientation, diameter, length and distribution of the AB-LCFA to the iliac crest were recorded. Data were analyzed using SPSS[®] version 16.0 and presented as the means and standard deviations.

Clinical Application

Between January 2000 and June 2012, 13 patients (8 males and 5 females) underwent external fixation combined with pedicled iliac bone flap transfer perfused by the AB-LCFA in the Affiliated Zhongshan Hospital Joint Center of Dalian University due to the nonunion of upper femoral shaft fractures. The patients were between 19 and 58 years of age, with an average age of 35 years and an average preoperative course of 16 months (ranging 8 to 25 months). The cause of the fracture was trauma for all patients. Imaging examinations revealed sclerotic fracture edges, the absence of bone trabeculae crossing the fracture site, persistent fracture lines, and the lack of progressive change towards union on serial radiographs.²⁰

Surgical Technique

Epidural anesthesia was administered in the supine position, with the nonunion side elevated 30 degrees. Along the line connecting the anterior superior iliac spine and the outer margin of the patella, double S-shaped incisions approximately 10 cm in length were made from 1 cm superior to the anterior superior iliac crest to the distal end (Fig. 1A). The trunk of the LCFA was isolated under the fascia (Fig. 1B). An iliac bone block was raised from the iliac crest using an osteotome, approximately 4×3 cm in size (Fig. 1C). The pedicle was isolated anaclinally along the distribution of the AB-LCFA to its origin, to avoid damaging the thin branches and to ensure abundant blood flow to the bone flap, much muscle of the tensor fascia lata were attached. The raised bone flap was wrapped in saline gauze.

The internal fixation from the previous surgery was removed and the fracture site of the bone was exposed (Fig. 1D). The periosteum around the broken ends was carefully protected when clearing the granulation tissues, and the sclerotic bone of the broken ends was removed using a pendulum saw, the medullary cavity was unblocked and the lower limb alignment was corrected with an external fixator. Based on the size of the bone flap, a bone window was made crossing the fracture line. The pedicled bone flap was transferred via a subcutaneous tunnel (Fig. 1E), partially inserted into the bone window, and fixed with two Kirschner wires (Fig. 1F). Autogenous bone grafting was performed in conjunction if necessary. The muscle, fascia, subcutaneous tissue, and skin were sutured layer-by-layer and an indwelling drainage tube was placed (Fig. 1).

Antibiotics and anti-coagulants were administered postoperatively. Rehabilitation exercises were arranged from the first day after surgery. Kirschner wires were removed 2 weeks postoperatively. After discharge, the patients had an X-ray re-examination to evaluate bone union every 3 months. The time for out-of-bed rehabilitation began at 3 months postoperatively. The external fixator was removed when the bone union was confirmed. The time of the bone fracture union was recorded based on X-ray examination. The functional results of the femoral shaft were evaluated by the Klemm classification at the last follow-up examination.²¹

Results

Anatomic Findings

The LCFA was found to arise from the deep femoral artery in 38 specimens (95%) and from the femoral artery in 2 specimens (5%) (Fig. 2). The origin and branching of the LCFA were divided into 4 types. In type I, the LCFA arose from the deep femoral artery and divided into ascending, transverse, and descending branches in 32 specimens (80%). In type II, the LCFA arose from the femoral artery and divided into the ascending, transverse, and descending branches in 2 specimens (5%). In type III, the ascending branch arose from the femoral artery and the LCFA arose from the deep femoral artery and divided into transverse and descending branches in 2 specimens (5%). In type IV, the LCFA arose from the femoral artery and divided into the ascending and transverse branches, while the descending branch arose directly from the deep femoral artery in 4 specimens (10%).

The distribution of the ascending, transverse, and descending branches of the LCFA is shown in Fig. 3. The outer diameter of the AB-LCFA at the origin was 3.15 ± 0.9 mm. The trunk of the AB-LCFA passed through the deep surface of the rectus femoris and ran superolaterally until reaching the medial surface of the tensor fascia lata, where the artery divided into the iliac crest, middle gluteal, and tensor fasciae lata branches. The AB-LCFA was 8.51 ± 3.06 cm in length.

Clinical Results

The postoperative course of the procedure was uneventful in all 13 patients. All patients were followed-up. The follow-up duration ranged from 10 to 24 months, with an average of 15 months. All of the patients achieved bony union between 3 and 9 months postoperatively, with an average of 5.3 months. According to the Klemm classification, 8 patients achieved excellent results without any complications, 4 patients achieved good results with a slight loss of hip motion or angular deformity less than 5° , and 1 patient had a fair outcome as the affected limb shortened 2.4 cm. The outcomes of the repair of fracture nonunion in all patients are shown in Table 1.

Case Report

A 58-year-old male patient suffered from fracture of the right upper femoral shaft (Fig. 4A) by falling and underwent internal fixation with a dynamic hip screw plate (Fig. 4B). The internal fixator was removed 20 months after surgery. The femoral shaft fracture recurred 1 month after the removal of the fixator (Fig. 4C) and a secondary internal fixation procedure was performed using a compression plate along with autogenous bone grafting (Fig. 4D). The plate was found to be loose 28 days postoperatively (Fig. 4E), and a third internal fixation was performed using a

lock plate with autogenous bone grafting (Fig. 4F). The plate was broken for the second time due to load-bearing 3 months postoperatively (Fig. 4G). Thus, pedicled iliac crest bone flap transfer perfused by the AB-LCFA combined with the external fixator were performed to treat the fracture nonunion (Fig. 4H). X-ray examinations at 1, 3, 5 and 12 months postoperatively showed bone healing with indistinct fracture lines and the formation of a continuous callus (Figs. 4I, J, K, L). The patient achieved a good functional outcome based on the Klemm classification.

Discussion

Nonunion of femoral shaft fractures remains a clinical challenge. In a recent review, Crowley et al. recognized that despite the fact that plating has reached near equivocal rates of success, exchange nailing for the treatment of a femoral nonunion remains the standard of treatment.²²

It has been shown that the blood supply for bone fracture healing is crucial. After one or more internal fixation treatments, the inner or outer periosteum is damaged around the broken ends, and the use of reamed intramedullary nails will damage the blood supply of the endosteum.^{4,23} Investigations have shown that the blood supply of the endosteum is most affected during the first reaming given the specific anatomy of the operative site.^{23,24} An external fixator can avoid damaging the blood supply of the endosteum while allowing for micromovement of the fracture site, thus stimulating osteogenesis.²⁵

Autologous bone grafting has more favorable biologic and mechanical properties than allograft bone and other bone materials.²⁶ Flier et al. reported the prognosis and incidence of complications after bone grafting for the nonunion of long bone fractures in 182 patients compared with other groups (heterogeneous bone grafting and BMP administration), showing that autologous bone grafting achieved a shorter time to bone union and a lower incidence of postoperative infections.¹⁰

Compared with autologous bone grafting alone, the pedicled bone flap provides a constant blood supply and stable biologic function. Leung PC reported the first case of bony reconstruction using the iliac crest graft pedicled with the deep circumflex iliac artery in 1983,²⁷ and they collected over 40 cases with large femoral bone defects over 20 years, most large bone gaps showed rapid bone healing with rare complications.²⁸ **A multicenter study of 2190 patients showed the pedicled iliac bone flap transfer could arrest the osteonecrosis progress for the patients of osteonecrosis of the femoral head.**²⁹ The use of a pedicled bone flap has been proposed as a technique with an indication for intractable femoral nonunion.^{12,30} However, the use of a pedicled iliac crest bone flap transfer for treating the nonunion of upper femoral shaft fractures has not been reported.

Different patterns of the origin of the LCFA and its branches have been described in recent reports, and variations have been noted between the two legs of the same individual.³¹⁻³³ In our study, the percentage of the LCFA origins from the deep femoral artery (95%) and the femoral

artery (5%) was similar to the study of Samarawickaina et al. (population of Sri Lanka, 92.3% and 7.7%),³¹ but was different from the average percentage reported by Uzel et al. (Turkish population, 77.3% and 19.1%)³² and Prakash et al. (Indian population, 81.25% and 18.75%),³³ which may be related to racial differences.³⁴ We observed the origins and branches of the LCFA and classified the patterns of the anatomical variation of the LCFA into 4 types, which was different from the 6 types reported by Fukuda, which was according to the origin of the LCFA only.^{32,35} The outer diameter at the origin was 4.95 ± 1.35 mm, which was similar to the results reported by Uzel 4.7 mm.³² Many researchers have measured the distance between the mid-inguinal point and the branching point of the LCFA to facilitate body surface localization;^{32,36} instead, we measured the length of the AB-LCFA as 8.51 ± 3.06 cm.

Although all of the patients achieved radiographic healing at the end of the follow-up period and the clinical success rate was higher, the average bone healing time was longer than other reports, including those by Emara et al. (4.8 ± 1.15 months),³⁷ Shroeder et al. (4 months),³⁸ Roetman et al. (5 months),³⁹ and Steinberg et al. (4.5 months).⁴⁰ In addition, the surgical procedure may cause damage to the tensor fascia lata, and the use of external fixation could delay postoperative out-of-bed rehabilitation, thus leading to the loss of hip or knee motion, but appropriate rehabilitation exercises for patients could recover these functions and achieve good outcomes. In our 13 cases, 1 patient had a fair outcome due to the longer disease course, although the bone fracture healed 5 months postoperatively, the affected limb was shortened by 2.4 cm due to the considerable bone defect. This patient had mild limping when walking.

Based on anatomic findings of cadaver specimen dissections and the results of clinical applications, pedicled iliac bone flap perfused by the AB-LCFA showed that the anatomy of the pedicle was consistent and the flap could reach the upper femoral shaft after full dissection. Kinking and twisting of the pedicle should be prevented during the bone flap transfer. The femoral nerve and branches should also be protected when isolating LCFA and its branches. Postoperative rehabilitation exercises should receive more attention.

In conclusion, the anatomy of the AB-LCFA is consistent. The iliac crest bone flap perfused by the AB-LCFA could be raised without technical difficulties. The transfer of the pedicled iliac crest bone flap perfused by the AB-LCFA combined with external fixation could be an option for treating the nonunion of upper femoral shaft fractures.

References

- [1] Brinker MR. Skeletal trauma: basic science management, and reconstruction, ed 3. Philadelphia, PA: Saunders; 2003. 507-604 p.
- [2] Hak DJ. Management of aseptic tibial nonunion. *J Am Acad Orthop Surg.* 2011; 19: 563-573.

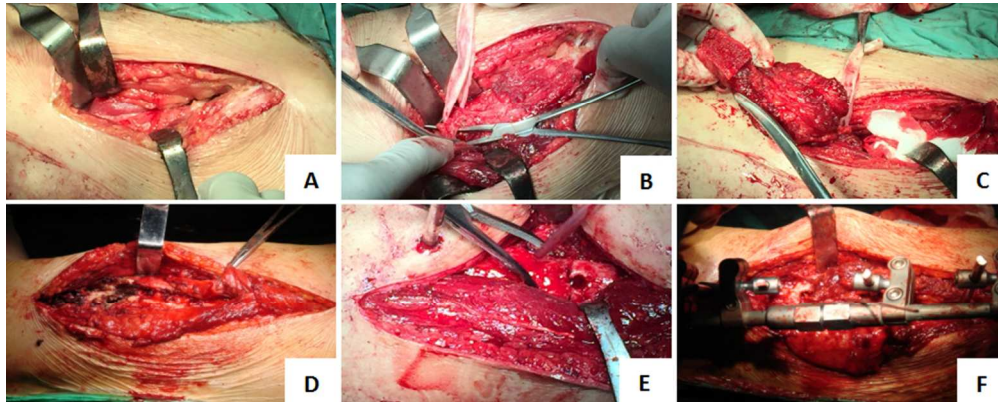
- [3] Tzioupis C, Giannoudis PV. Prevalence of long-bone non-unions. *Injury*. 2007; 38: 3-9.
- [4] Lynch JR, Taitsman LA, Barei DP, Nork SE. Femoral nonunion: risk factors and treatment options. *J Am Acad Orthop Surg*. 2008; 16: 88-97.
- [5] Kanakaris NK, Giannoudis PV. The health economics of the treatment of long-bone nonunions. *Injury*. 2007; 38: 77-84.
- [6] Giannoudis PV, Dinopoulos HT. Autologous bone graft: when shall we add growth factors. *Foot Ankle Clin*. 2010; 15: 597-609.
- [7] Sen MK, Miclau T. Autologous iliac crest bone graft: should it still be the gold standard for treating nonunions. *Injury*. 2007; 38: 75-80.
- [8] Kanakaris NK, Paliobeis C, Nlanidakis N, Giannoudis PV. Biological enhancement of tibial diaphyseal aseptic non-unions: the efficacy of autologous bone grafting, BMPs and reaming by-products. *Injury*. 2007; 38: 65-75.
- [9] Giannoudis PV, Dinopoulos HT. BMPs: Options, indications, and effectiveness. *J Orthop Trauma*. 2010; 24: 9-16.
- [10] Flierl MA, Smith WR, Mauffrey C, et al. Outcomes and complication rates of different bone grafting modalities in long bone fracture nonunions: a retrospective cohort study in 182 patients. *J Orthop Surg Res*. 2013; 8: 33.
- [11] Marino JT, Ziran BH. Use of solid and cancellous autologous bone graft for fractures and nonunions. *Orthop Clin North Am*. 2010; 41: 15-26.
- [12] Yoshida A, Yajima H, Murata K, et al. Pedicled vascularized bone graft from the medial supracondylar region of the femur for treatment of femur nonunion. *J Reconstr Microsurg*. 2009; 25: 165-170.
- [13] Shaffer JW, Davy DT, Field GA, Bensusan JS, Kellis GJ. The superiority of vascularized compared to nonvascularized rib grafts in spine surgery shown by biological and physical methods. *Spine*. 1988; 13: 1150-1154.
- [14] Cutting CB, McCarthy JG. Comparison of residual osseous mass between vascularized and nonvascularized onlay bone transfers. *Plast Reconstr Surg*. 1983; 72: 672-675.
- [15] Willems WF, Larsen M, Friedrich PF, Bishop AT. Cell lineage in vascularized bone transplantation. *Microsurgery*. 2014; 34: 37-43.

- [16] Henry M. Genicular corticoperiosteal flap salvage of resistant atrophic non-union of the distal radius metaphysis. *Hand Surg.* 2007; 12: 211-215.
- [17] Malizos KN, Dailiana ZH, Innocenti M, Mathoulin CL, Mattar R Jr, Sauerbier M. Vascularized bone grafts for upper limb reconstruction: defects at the distal radius, wrist, and hand. *J Hand Surg Am.* 2010; 35: 1710-1718.
- [18] Korompilias AV, Paschos NK, Lykissas MG, Kostas-Agnantis I, Vekris MD, Beris AE. Recent updates of surgical techniques and applications of free vascularized fibular graft in extremity and trunk reconstruction. *Microsurgery.* 2011; 31: 171-175.
- [19] Kakar S, Duymaz A, Steinmann S, Shin AY, Moran SL. Vascularized medial femoral condyle corticoperiosteal flaps for the treatment of recalcitrant humeral nonunions. *Microsurgery.* 2011; 31: 85-92.
- [20] Somford MP, van den Bekerom MP, Kloen P. Operative treatment for femoral shaft nonunions, a systematic review of the literature. *Strategies Trauma Limb Reconstr.* 2013; 8: 77-88.
- [21] Klemm KW, Borner M. Interlocking nailing of complex fractures of the femur and tibia. *Clin Orthop Relat Res.* 1986; 212: 89-100.
- [22] Crowley DJ, Kanakaris NK, Giannoudis PV. Femoral diaphyseal aseptic nonunions: is there an ideal method of treatment? *Injury* 2007; 38: 55–63.
- [23] Kessler SB, Hallfeldt KK, Perren SM, Schweiberer L. The effects of reaming and intramedullary nailing on fracture healing. *Clin Orthop Relat Res.* 1986; 212: 18-25.
- [24] Whiteside LA, Ogata K, Lesker P, Reynolds FC. The acute effects of periosteal stripping and medullary reaming on regional bone blood flow. *Clin Orthop Relat Res.* 1978; 131: 266-272.
- [25] Basbozkurt M, Kurklu M, Yurttas Y, Demiralp B, Koca K, Kilic C, Yildiz C. Ilizarov external fixation without removal of plate or screws: effect on hypertrophic and oligotrophic nonunion of the femoral shaft with plate failure. *J Orthop Trauma.* 2012; 26: 123-128.
- [26] Pape HC, Evans A, Kobbe P. Autologous bone graft: properties and techniques. *J Orthop Trauma.* 2010; 24: 36-40.
- [27] Leung PC. Reconstruction of a large femoral defect using a vascularised pedicle iliac graft. *J Bone Joint Surg [Am].* 1983; 65:1179-1180.

- [28] Leung PC. Pedicled iliac graft-twenty years experience. *Int Orthop*. 2003; 27: 323-325.
- [29] Zhao D, Xie H, Xu Y, Wang Y, Yu A, Liu Y, Wang A, He W, Wang X, Li Z, Sun W, Tian S, Wang B, Liu B. Management of osteonecrosis of the femoral head with pedicled iliac bone flap transfer: A multicenter study of 2190 patients. *Microsurgery*. 2017; Aug 14. doi: 10.1002/micr.30195. [Epub ahead of print]
- [30] Kiyoshige Y. The application of vascularized periosteal and corticoperiosteal grafts. *J Jpn SRM*. 1999; 162-166.
- [31] Samarawickrainna MB, Nanayakkana BG, Wimalagunarathna KWR, Nishantha DG, Walawage UB. Branching pattern of the femoral artery at the femoral triangle: a cadaver study. *Gaelle Medical J*. 2009; 4: 31-34.
- [32] Uzel M, Tanyeli E, Yildirim M. An anatomical study of the origins of the lateral circumflex femoral artery in the Turkish population. *Folia Morphol*. 2008; 67: 209-212.
- [33] Prakash, Kumari J, Bhardwaj AK, Jose BA, Yadav SK, Singh G. Variations in the origins of the profunda femoris medial and lateral femoral circumflex arteries: a cadaver study in the Indian population. *Rom J Morphol Embryol*. 2010; 51: 167-170.
- [34] Williams GD, Martin CH, McIntire LR. Origins of the deep and circumflex group of arteries. *Anat Rec*. 1934; 60:189-196.
- [35] Fukuda H, Ashida M, Ishii R, Abe S, Ibukuro K. Anatomical variants of the lateral femoral circumflex artery: an angiographic study. *Surg Radiol Anat*. 2005; 27: 260-264.
- [36] Manjappa T, Prasanna LC. Anatomical variations of the profunda femoris artery and its branches- a cadaveric study in south Indian population. *Indian J Surg*. 2014; 76: 288-292.
- [37] Emara KM, Allam MF. Intramedullary fixation of failed plated femoral diaphyseal fractures: are bone grafts necessary. *J Trauma*. 2008; 65: 692-697.
- [38] Shroeder JE, Mosheiff R, Khoury A, Liebergall M, Weil YA. The outcome of closed, intramedullary exchange nailing with reamed insertion in the treatment of femoral shaft non-unions. *J Orthop Trauma*. 2009; 23: 653-657.
- [39] Roetman B, Scholz N, Muhr G, Mollenhoff G. Augmentive plate fixation in femoral non-unions after intramedullary nailing. Strategy after unsuccessful intramedullary nailing of the femur. *Z Orthop Unfall*. 2008; 146: 586-590.

[40] Steinberg EL, Keynan O, Sternheim A, Drexler M, Luger E. Treatment of diaphyseal non-union of the femur and tibia using an expandable nailing system. *Injury*. 2009; 40: 309–314.

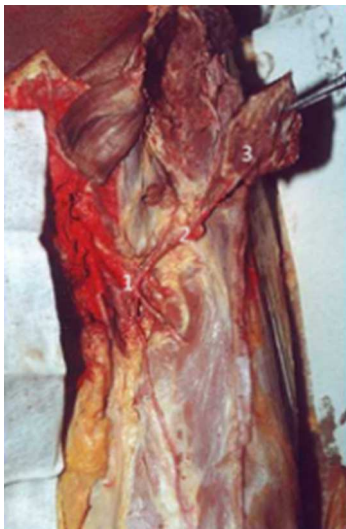Accepted Article



(A) An incision was made superiorly from the anterior superior iliac crest; (B) The trunk of the LCFA was isolated first and tagged with rubber; (C) The iliac bone block was harvested with an osteotome, and the pedicle was isolated anaclinally to the origin of the AB-LCFA; (D) The fracture site was exposed and the lower limb alignment was corrected with an external fixator after the fracture site was handled; (E) The pedicled flap was transferred to the broken ends via a subcutaneous tunnel; (F) The bone flap was fixed with two Kirschner wires.

253x101mm (96 x 96 DPI)

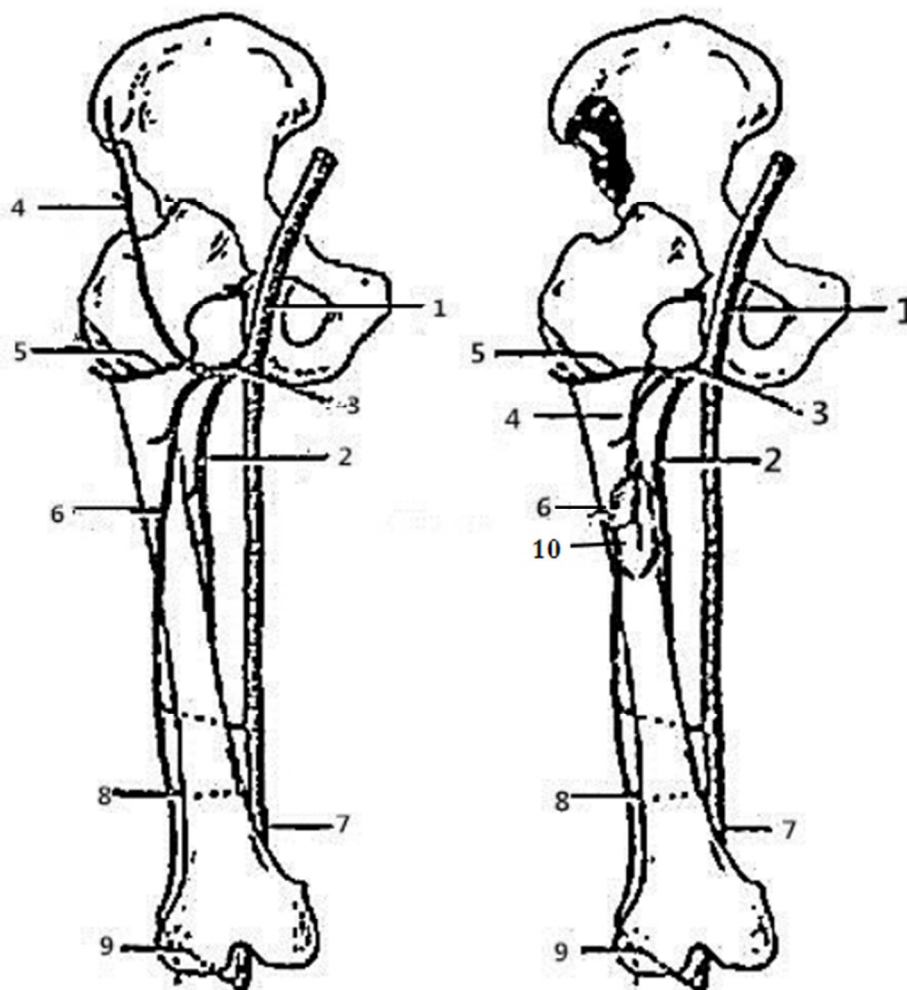
Accepted



The distribution of the LCFA in specimens. (1) The trunk of the LCFA; (2) The AB-LCFA; (3) The iliac bone flap perfused by the AB-LCFA.

45x69mm (96 x 96 DPI)

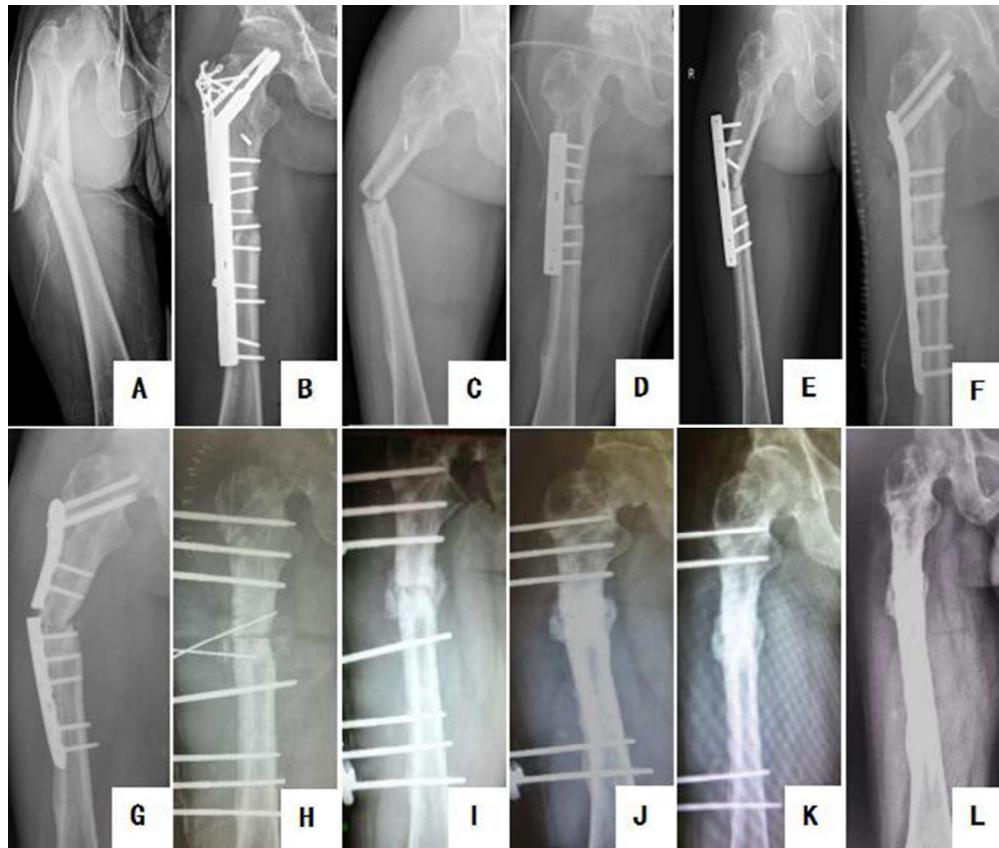
Accepted



A schematic diagram of the distribution of the ascending, transverse, and descending branches of the LCFA. (1) The femoral artery; (2) The deep femoral artery; (3) The LCFA; (4) The AB-LCFA; (5) The transverse branch; (6) The descending branch; (7) The popliteal artery; (8) The superior genicular artery; (9) The inferior genicular artery; (10) The transferred iliac bone flap perfused by the AB-LCFA.

156x159mm (96 x 96 DPI)

A



(A) The right upper femoral shaft was injured; (B) Internal fixation with a DHS plate; (C) Re-fracture of the femoral shaft; (D) Internal fixation with a compression steel plate plus autogenous bone grafting; (E) Loosening of the plate; (F) Internal fixation with a lock plate plus autogenous bone grafting; (G) Broken plate; (H) External fixation plus autogenous bone grafting and a pedicled iliac crest bone flap transfer perfused by the AB-LCFA; (I, J, K, L) An indistinct fracture line and the formation of a continuous callus at 1, 3, 5 and 12 months postoperatively.

164x138mm (96 x 96 DPI)

Acc

Table 1. The information and outcomes of 13 patients

Patient number	Gender	Age (years)	Cause of fracture	Primary treatment	Secondary treatment	Third treatment	Preoperative course (months)	Postoperative course	Time to union (months)	Follow-up length (months)	Final functional outcomes	Functional Results (Klemm classification)
1	Male	51	Trauma	Plate	-	-	10	uneventful	6.4	24	Slight loss of hip motion	Good
2	Female	40	Trauma	Nailing	-	-	12	uneventful	6.2	18	NC	Excellent
3	Male	28	Trauma	Plate	-	-	13	uneventful	3.3	10	NC	Excellent
4	Female	25	Trauma	Nailing	Plate	-	8	uneventful	3	12	NC	Excellent
5	Male	43	Trauma	Plate	-	-	23	uneventful	5	15	Slight loss of hip motion	Good
6	Male	28	Trauma	Nailing	Plate	-	16	uneventful	5.7	16	Angular deformity approximately 4°	Good
7	Male	19	Trauma	Nailing	Plate	-	20	uneventful	3.5	12	NC	Excellent
8	Female	30	Trauma	Nailing	-	-	25	uneventful	5	14	Affected limb shorten 2.4 cm	Fair
9	Male	31	Trauma	Nailing	Plate	-	18	uneventful	6	20	NC	Excellent
10	Female	29	Trauma	Nailing	-	-	9	uneventful	3.9	13	NC	Excellent
11	Male	58	Trauma	Plate	Plate and bone graft	Plate and bone graft	25	uneventful	6.5	12	NC	Excellent
12	Male	40	Trauma	Nailing	Plate	-	15	uneventful	9	15	Angular deformity	Good

Accepted Article

13	Female	33	Trauma	Nailing	-	-	14	uneventful	5.4	14	approximately 5° NC	Excellent
----	--------	----	--------	---------	---	---	----	------------	-----	----	---------------------------	-----------

NC- No complication.