

## Original Communications

### **Microsurgical anatomy of the superior wall of the mandibular canal and surrounding structures: Suggestion for new classifications for dental implantology**

Joe Iwanaga<sup>1-3</sup>, Mahindra Kumar Anand<sup>4</sup>, Mitesh N Jain<sup>5</sup>, Mizuki Nagata<sup>6</sup>, Yuki Matsushita<sup>6</sup>,  
Soichiro Ibaragi<sup>7</sup>, Jingo Kusukawa<sup>2</sup>, R. Shane Tubbs<sup>1, 8</sup>

1. Seattle Science Foundation, 550 17th Avenue, Suite 600, Seattle, WA 98122, USA
2. Dental and Oral Medical Center, Kurume University School of Medicine, 67 Asahi-machi, Kurume, Fukuoka 830-0011, Japan
3. Division of Gross and Clinical Anatomy, Department of Anatomy, Kurume University School of Medicine, Kurume, Fukuoka 830-0011, Japan
4. Department of Anatomy, G S Medical College & Hospital, Hapur, UP, India
5. Department of Oral Pathology, MGM Dental College & Hospital, Navi Mumbai, Maharashtra, India
6. University of Michigan School of Dentistry, 1011 N. University, Ann Arbor, MI 48109, USA
7. Department of Oral and Maxillofacial Surgery, Okayama University Graduate School of Medicine, Dentistry and Pharmaceutical Sciences, Okayama, Japan

This is the author manuscript accepted for publication and has undergone full peer review but has not been certified for publication. Department of Anatomical Sciences, St. George's University, St. George's, Grenada, which may lead to differences between this version and the Version of Record. Please cite this article as doi: [10.1002/ca.23456](https://doi.org/10.1002/ca.23456)

**Running title:** Microsurgical anatomy of superior wall of the mandibular canal

**Corresponding author:** Joe Iwanaga, DDS, PhD

**Address:** Seattle Science Foundation, 550 17th Avenue, Suite 600, Seattle, WA 98122, USA

**E-mail:** iwanagajoeca@gmail.com

**Tel:** 2067326500

**Fax:** 2067326599

The authors have nothing to disclose.

## Original Communications

### **Microsurgical anatomy of the superior wall of the mandibular canal and surrounding structures: Suggestion for new classifications for dental implantology**

Joe Iwanaga<sup>1-3</sup>, Mahindra Kumar Anand<sup>4</sup>, Mitesh N Jain<sup>5</sup>, Mizuki Nagata<sup>6</sup>, Yuki Matsushita<sup>6</sup>,  
Soichiro Ibaragi<sup>7</sup>, Jingo Kusukawa<sup>2</sup>, R. Shane Tubbs<sup>1, 8</sup>

1. Seattle Science Foundation, 550 17th Avenue, Suite 600, Seattle, WA 98122, USA
2. Dental and Oral Medical Center, Kurume University School of Medicine, 67 Asahi-machi, Kurume, Fukuoka 830-0011, Japan
3. Division of Gross and Clinical Anatomy, Department of Anatomy, Kurume University School of Medicine, Kurume, Fukuoka 830-0011, Japan
4. Department of Anatomy, G S Medical College & Hospital, Hapur, UP, India
5. Department of Oral Pathology, MGM Dental College & Hospital, Navi Mumbai, Maharashtra, India
6. University of Michigan School of Dentistry, 1011 N. University, Ann Arbor, MI 48109, USA
7. Department of Oral and Maxillofacial Surgery, Okayama University Graduate School of

Medicine, Dentistry and Pharmaceutical Sciences, Okayama, Japan

8. Department of Anatomical Sciences, St. George's University, St. George's, Grenada

**Running title:** Microsurgical anatomy of superior wall of the mandibular canal

**Corresponding author:** Joe Iwanaga, DDS, PhD

**Address:** Seattle Science Foundation, 550 17th Avenue, Suite 600, Seattle, WA 98122, USA

**E-mail:** iwanagajoeca@gmail.com

**Tel:** 2067326500

**Fax:** 2067326599

The authors have nothing to disclose.

## **Abstract**

### *Objective*

Our goal was to clarify the relationship between the superior wall of the mandibular canal and the presence of teeth. We also sought to study the structural changes of the mandibular canal after tooth loss.

### *Methods*

Twenty sides from ten dry mandibles derived from six males and four females were used for this study. The age of the specimens at the time of death ranged from 57 to 91 years. The mandibles

were cut in the midline resulting in twenty hemi-mandibles. The presence of teeth (from the second premolar to the third molar) was recorded for each hemi-mandible. The mandibular canal in the body of the mandible was divided into four areas, i.e., areas 1-4. The superior wall of the mandibular canal and a cancellous bone pattern above the mandibular canal were observed. Next, the mandibular canal was horizontally cut at its center and the superior wall of the mandibular canal observed inferiorly.

### *Results*

A total of 75 areas (20 dentulous areas and 55 edentulous areas) were produced. The distal view was classified into three groups, type I (trabecular pattern), type II (osteoporotic pattern), and type III (dense/irregular pattern). The type I pattern was found in 60.0% (12/20) of the dentulous areas and 32.7% of the edentulous areas. While the type II pattern was found in 15.0% (23/55) of the dentulous areas and 41.8% of the edentulous areas. The inferior view was classified into four groups depending on the surface of the superior wall of the mandibular canal, i.e., class I (trabecular pattern), class II (osteoporotic pattern), class III (dense/irregular pattern), and class IV (smooth). The class I pattern was seen most frequently (55.0%) in dentulous areas and the class IV pattern (45.5%) most frequently in edentulous areas.

### *Conclusions*

Based on these results, we conclude that the superior wall of the mandibular canal could change following tooth loss.

**Key words**

Mandibular canal; inferior alveolar nerve; osteoporosis; edentulous; mandible; cadaver;  
anatomy; dentistry, implants

## Introduction

In implant dentistry, outlining the mandibular canal, especially the superior wall of the canal, is extremely important for assessing what strategy of implantation should be used in order to avoid injury to the inferior alveolar neurovascular bundles. The bone quality of the superior wall of the mandibular canal has been reported to be more often trabecular than cortical (Misch, 1990; Başa and Dilek, 2011). Others have reported not observing a superior wall on periapical and panoramic radiographic views due to the absence of the cortical line of the canal and superimposition of surrounding anatomical structures (Fishel et al., 1976; Rosenquist, 1996; Misch, 2008). For these reasons, it is often difficult to clearly visualize the mandibular canal on imaging. Additionally, digital panoramic radiography does not improve the visibility of the mandibular canal (Naitoh et al., 2009). Even cone-beam computed tomography (CBCT) images are unable to detect the outline of the mandibular canal. Lastly, visible and invisible parts of the mandibular canal might exist in the same mandible (Fig. 1).

Oliveira-Santos et al. (2011) reported that the mandibular canal was visualized in 62.9-87.9% of patients on their CBCT study. According to Takahashi et al. (2013), up to 82% of mandibular canals can be detected using paraxial and panoramic views obtained from CBCT data and using the “Outlining the Mandibular Canal in the Panoramic View” software function. A study by Lofthag-Hansen et al. (2008) showed that the mandibular canal was visualized in only 33% (10/30) of cases when using paraxial views, however, it was visible in 87% (26/30) when using a

combination of paraxial, sagittal, and axial images. Jacobs et al. (2002) detected the mandibular canal on paraxial views in 98% of cases with invisibility or poor visibility of its course in 20%. Miles et al. (2016) identified the mandibular canal in 56% of examined sites using CBCT and concluded that visibility differs between age, sex, and area examined.

Başa and Dilek (2011) measured the thickness of the superior wall of the mandibular canal at the premolar and molar regions in all patients (from ninety-nine CT images). Noma et al. (2010) described that the superior wall of the mandibular canal becomes evident after tooth loss as the dental branches of the inferior alveolar neurovascular bundles disappear and the apertures in the superior wall become filled with bone. Histologically, Bertl et al. (2014) found that the mandibular canal was surrounded by trabecular bone.

Thus, descriptions of the structure of the mandibular canal, especially its superior wall, are still unclear and debatable. Most recent studies on the mandibular canal are based on CBCT images, and, to our knowledge, gross anatomical observations have not been conducted in order to define and clarify this region as well as the structural changes associated with tooth loss. Therefore, this study was conducted to clarify the relationships between the superior wall of the mandibular canal and the presence or absence of the overlying teeth.

## **Materials and methods**



Twenty sides from ten dry mandibles derived from six males and four females were used for this study. The age of the specimens at the time of death ranged from 57 to 91 with a mean of 73.7 years.

In this study the mandibular canal was investigated along its course in the body of the mandible (from the mental foramen to the anterior border of the ramus).

*Preparation (initial bone cutting)*

The mandibles were cut in the midline (at the mental spine) resulting in twenty hemi-mandibles. The presence of teeth (from the second premolar to the third molar) was recorded for each hemi-mandible. The mandibular canal in the body of the mandible was divided into four areas by forming two vertical lines along the inferior border of the mandible drawn from the mental foramen and junction between the body and ramus of the mandible. Next, the area between these two vertical lines was separated into four equal areas, i.e., areas 1-4, using an electric bone saw (Pathology Bone Band Saw, IMEB Inc., San Marcos, CA) (Fig. 2). Areas 1, 2, 3, and 4 were considered to be adjacent to the second premolar, first molar, second molar, and third molar, respectively.

*Observation of the mandibular canal from a distal view*

A total of 80 areas were created. The distal view of the axial section of the mandibular canal and surrounding bone was observed for each area (Fig. 3). The superior wall of the mandibular canal and the cancellous bone pattern above the mandibular canal were observed.

*Mandibular canal preparation (second bone cut)*

The mandibular canal was cut horizontally at its center (Fig. 4).

*Observation of the mandibular canal from an inferior view*

The superior wall of the mandibular canal was observed inferiorly (Fig. 5).

Prior to each observation, bone dust was carefully cleaned away with compressed air. Mandibles with any pathology, obvious scar, or anatomical variations (e.g., retromolar foramen or accessory mental foramen) were excluded from further study. A history of a root canal was not recorded in this study.

Observations were performed using a surgical microscope (OPMI CS NC31, Carl Zeiss, Oberkochen, Germany). Two clinical anatomists (JI and RST) performed all preparations and observations. The present study protocol did not require approval by an internal review board. The study was performed in accordance with the requirements of the Declaration of Helsinki (64th WMA General Assembly, Fortaleza, Brazil, October 2013).

## Results

A total of 75 areas (20 dentulous areas and 55 edentulous areas) were available and 5 areas were not available due to damage during preparation. Out of 75 areas, there were no area 4 regions with adjacent teeth i.e., there were no wisdom teeth.

### *Distal view*

The distal view was classified into three groups based on the cancellous bone patterns, type I (trabecular pattern), type II (osteoporotic pattern), and type III (dense/irregular pattern). These were further classified into two subtypes, i.e., a-with visible superior wall) and b-with an unclear superior wall (Fig. 6). Type I (30 areas) patterns were found in 60.0% of the dentulous areas and 32.7% of the edentulous areas. Type II (26 areas) patterns were found in 15.0% of the dentulous and 41.8% of the edentulous areas. Type III (19 areas) patterns were found in 25.0% of the dentulous and 25.5% of the edentulous areas (Table 1).

### *Correlation of types and sex related with tooth presence in distal view*

The most common type that dentulous areas in males had was type I (9/14: 64.2%) (Table 2).

The most common type that edentulous areas in females had was type II (16/26: 61.5%) (Table 3).

### *Subtypes*

Subtypes a and b were found in 41.3% (31/75) and 58.7% (44/75) of specimens, respectively.

### *Inferior view*

The inferior view was classified into four groups depending on the surface of the superior wall of the mandibular canal, i.e., class I (trabecular pattern), class II (osteoporotic pattern), class III (dense/irregular pattern), and class IV (smooth pattern) (Fig. 7). Class I was most frequent (55.0%) in dentulous areas and class IV (45.5%) in edentulous areas (Table 4).

### *Correlation of the Classes and sex related with tooth presence in inferior view*

The most common class that dentulous areas in females had was class I (5/6: 83.3%) (Table 5).

The most common class that edentulous areas in female had was class IV (14/26: 53.8%) (Table 6).

## **Discussion**

As CBCT has developed and gained popularity in implant surgery, evaluation of mandibular bone density has been considered an important part of the preoperative diagnosis and surgical planning. In this regard, many researchers have investigated the location of the mandibular canal (Koivisto et al., 2016; Promma et al., 2017). The present study focused on two different aspects

of the mandible. The first was the cancellous pattern of the mandible above the mandibular canal. Secondly, the superior wall of the mandibular canal was observed distally and inferiorly.

### *Cancellous pattern of the mandible*

Lekholm and Zarb (1985) classified bone into four types depending on the thickness of the cortical and trabecular bone. Misch introduced a classification based on “Hand Fill Resistance (1990)” and “Hounsfield Units (1999).” These classifications have been used for a long time and have made a great contribution to the development of dental implantology. In this study, we demonstrated the different patterns of cancellous bone from previous studies. Types I and II might have been diagnosed using CBCT correctly, however, type III might have been diagnosed as the thickening of the cortical bone which could be erroneous. Interestingly, type I was found most frequently (60.0%) in dentulous specimens and type II most frequently (41.8%) in edentulous specimens. Type III was found in 25.0% dentulous and 25.5% edentulous mandibles, respectively. This might indicate that type III does not change depending on the presence or absence of the tooth. Also, the dentulous areas in males were most likely to have a type I pattern and edentulous areas in females were most likely to have a type II pattern. Based on these results, we hypothesized that the cancellous pattern above the mandibular canal in adult human mandibles originally has type I patterns and this changes to a type II pattern occurs after tooth loss. Type III patterns might be considered a pathological condition (Fig. 8). Lastly, based on our findings, sex might be another factor that should be considered.

### *Superior wall of the mandibular canal*

Visualization of the superior wall of the mandibular canal on CBCT images is mandatory for avoiding injury to the inferior alveolar neurovascular bundles. In a study by Shokri et al. (2014), the mandibular canal was detected on 89.6% of right sides and 84.7% of left sides using CBCT. On cross-sectional and reconstructed panoramic images, the corticalized mandibular canal was observed in 56.3%. In 43.7%, the mandibular canal was not corticalized (Shokri et al., 2014). Kubilius et al. (2016) classified visibility of the mandibular canal into 1 (not visible) to 5 (good visibility) using panoramic radiography. As mentioned above, visibility of the mandibular canal varies in studies and might be due to variant trabecular patterns or tooth presence (Noma et al., 2010). To our knowledge, there has been no prior anatomical evidence to support such data from CBCT studies.

From a distal view, the superior wall of the mandibular canal was not visible in 58.7% (44/75) of specimens and for these, there was no significant difference between dentulous and edentulous specimens. Thus, the superior wall of the mandibular canal from a distal view can be absent as demonstrated in types Ib, IIb, and IIIb. When the mandibular canal has a type IIb superior wall, it might be difficult to detect its location on CBCT. In types Ib and IIIb, it is easy to locate the mandibular canal on CBCT as there is an obvious space for the neurovascular bundles. This is probably why previous studies had a lower detection rate of the superior wall (Miles et al., 2016).

Başa and Dilek (2011) reported the thickness of the superior wall to be 0.87 mm in the premolar region and 0.86 mm in the molar region. However, this study did not mention cases in which the superior wall was not visible. In the present study, measurement of the thickness of the superior wall was not applicable because the superior wall was not visible in the majority of cases (58.7%).

We also observed the superior wall of the mandibular canal inferiorly and classified them into four groups (classes I to IV). Even CBCT images might not be able to visualize these fine structural differences. This view gave us a new insight and understanding of this structure. The concept of the structural change in the superior wall of the mandibular canal from class I trabecular pattern (class I in the present study) to a smooth pattern (class IV in the present study) when the tooth loss occurs due to the loss of the dental branches was introduced by Noma et al., 2010. As our results showed (Table 4), the most frequent pattern in the dentulous areas was class I (55.0%) and in edentulous areas this was class IV (45.5%). This supports Noma et al.'s theory (2010) that the superior wall of the mandibular canal becomes evident after tooth loss as the dental branches of the inferior alveolar neurovascular bundles disappear and the apertures in the superior wall become filled with bone. In addition, we found other patterns which we classified into classes II and III. The number of class I specimens decreased in edentulous areas compared to dentulous areas, and the number of class II and IV increased in edentulous areas

Author Manuscript

compared to dentulous areas. Class III was found in 9-10% and in both dentulous and edentulous areas. Also, the edentulous areas in females most likely have class IV. Based on this result, we hypothesized that the superior wall of the mandibular canal in adult human mandibles originally had class I patterns and changed to class IV patterns after tooth loss, and with aging and osteoporosis, became class II patterns. Class III patterns might be a pathological condition which is reversible (Fig. 9). Sex might be another factor that should be considered in regard to the class of the mandibular canal.

#### *Application to Implant surgery*

According to Başa and Dilek (2011), the average bone density around the mandibular canal corresponded to D3 using Misch's classification (1988; 1990), which is in the 375-750 Hounsfield unit intervals that correspond to trabecular bone. This indicates poor resistance of the bone against drilling when preparing an implant bed. The type II pattern in our study might correspond to D3-D4 in Misch's classification. For this type of bone, clinicians who drill/insert an implant might feel no resistance and the drill might encroach into the canal and result in injury to the inferior alveolar neurovascular bundles.

Also, some clinicians believe that resistance is felt when the tip of the drill touches the superior wall of the mandibular canal before penetration because they believe the superior wall of the mandibular canal is surrounded by cortical bone. The resistance of the superior wall should be



different depending on whether it is type a or b based on our study. Even in type I or III, which is more dense than type II, the resistance of the superior wall might not be felt if it is a subtype “b.”

### **Conclusions**

Based on these results, we conclude that the superior wall of the mandibular canal could change following tooth loss. We also suggest two new classifications regarding the cancellous pattern of the mandible above the mandibular canal and the superior wall of the mandibular canal.

### **Limitations**

There are some limitations on this study. We did not observe any obvious pathological mandibles but did not know if there are any small lesions such as apical lesion. The time from tooth loss to death was unknown. As each specimen had four areas, severe bony change, e.g., huge bone absorption, could affect all of four areas on ipsilateral side.

### **Acknowledgements**

The authors would like to thank those who donated their body for the advancement of medical education and research. All the authors have read the manuscript and have approved this submission.

### **Conflict of interest**

The authors received no funding or grants for this work from any organization or foundation.

The authors declare that they have no conflicts of interest.

## References

- Başa O, Dilek OC. 2011. Assessment of the risk of perforation of the mandibular canal by implant drill using density and thickness parameters. *Gerodontology* 28:213-220.
- Bertl K, Heimel P, Reich KM, Schwarze UY, Ulm C. 2014. A histomorphometric analysis of the nature of the mandibular canal in the anterior molar region. *Clin Oral Investig* 18:41-47.
- Fishel D, Buchner A, Hershkowith A, Kaffe I. 1976. Roentgenologic study of the mental foramen. *Oral Surg Oral Med Oral Pathol* 41:682-686.
- Jacobs R, Mraiwa N, vanSteenberghe D, Gijbels F, Quirynen M. 2002. Appearance, location, course, and morphology of the mandibular incisive canal: an assessment on spiral CT scan. *Dentomaxillofac Radiol* 31:322-327.
- Koivisto T, Chiona D, Milroy LL, McClanahan SB, Ahmad M, Bowles WR. 2016. Mandibular Canal Location: Cone-beam Computed Tomography Examination. *J Endod* 42:1018-1021.
- Kubilius M, Kubilius R, Varinauskas V, Žalinkevičius R, Tözüm TF, Juodžbalys G. 2016. Descriptive study of mandibular canal visibility: morphometric and densitometric analysis for digital panoramic radiographs. *Dentomaxillofac Radiol* 45:20160079.

- Lekholm U, Zarb GA. 1985. Patient selection and preparation. Tissue integrated prostheses: osseointegration in clinical dentistry. Chicago: Quintessence Publishing Company.
- Lofthag-Hansen S, Gröndahl K, Ekestubbe A. 2009. Cone-beam CT for preoperative implant planning in the posterior mandible: visibility of anatomic landmarks. *Clin Implant Dent Relat Res* 11:246-255.
- Miles MS, Parks ET, Eckert GJ, Blanchard SB. 2016. Comparative evaluation of mandibular canal visibility on cross-sectional cone-beam CT images: a retrospective study. *Dentomaxillofac Radiol* 45:20150296.
- Misch CE. 1988. Bone character: second vital implant criterion. *Dent Today* 7:39-40.
- Misch CE. 1990. Density of bone: effect on treatment plans, surgical approach, healing, and progressive boen loading. *Int J Oral Implantol* 6:23-31.
- Misch CE. 1999. Contemporary implant dentistry 2<sup>nd</sup> edn. St. Louis, MO: Mosby.
- Misch CE. 2008. Procedures to Identify the Mandibular Canal. *Contemporary Implants Dentistry*. 3rd edn. . St. Louis: Mosby.
- Naitoh M, Katsumata A, Kubota Y, Hayashi M, Ariji E. 2009. Relationship between cancellous bone density and mandibular canal depiction. *Implant Dent* 18:112-118.

- Noma H, Sasaki K YY. 2010. Disturbance and Regeneration of the Inferior Alveolar Nerves & Lingual Nerves 2<sup>nd</sup> ed. Tokyo: Ishiyaku Publisher, Inc. .
- Oliveira-Santos C, Capelozza AL, Dezzoti MS, Fischer CM, Poleti ML, Rubira-Bullen IR. 2011. Visibility of the mandibular canal on CBCT cross-sectional images. *J Appl Oral Sci* 19:240-243.
- Promma L, Sakulsak N, Putiwat P, Amarttayakong P, Iamsaard S, Trakulsuk H, Hirunyakorn K, Suarbua S, Wattanaraeungchai Y. 2017. Cortical bone thickness of the mandibular canal and implications for bilateral sagittal split osteotomy: a cadaveric study. *Int J Oral Maxillofac Surg* 46:572-577.
- Rosenquist B. 1996. Is there an anterior loop of the inferior alveolar nerve? *Int J Periodontics Restorative Dent* 16:40-45.
- Shokri A, Shakibaei Z, Langaroodi AJ, Safaei M. 2014. Evaluation of the mandibular canal visibility on cone-beam computed tomography images of the mandible. *J Craniofac Surg* 25:e273-277.
- Takahashi A, Watanabe H, Kamiyama Y, Honda E, Sumi Y, Kurabayashi T. 2013. Localizing the mandibular canal on dental CT reformatted images: usefulness of panoramic views. *Surg Radiol Anat* 35:803-809.



## Figure legends

### Figure 1

Visible (red arrow) and invisible (white arrow) parts of the mandibular canal in the same mandible.

### Figure 2

Four areas between the mental foramen and ramus of the mandible

### Figure 3

Distal view of an axial section (areas 1 to 4) of the mandible

### Figure 4

Horizontal separation of the mandibular canal

a: before cutting

b: after cutting

### Figure 5

Inferior observation of the superior wall of the mandibular canal

Figure 6

Classification of the cancellous pattern and superior wall of the mandibular canal (distal view)

Figure 7

Classification of the superior wall of the mandibular canal (inferior view)

Figure 8

Hypothesis of bony change of the mandibular canal after tooth loss (distal view)

Figure 9

Hypothesis of bony change after tooth loss, aging, and osteoporosis (inferior view)



## Tables

Table 1. Incidence of Types

	Dentulous	Edentulous
Type I	<b>60.0% (12/20)</b>	32.7% (18/55)
Type II	15.0% (3/20)	<b>41.8% (23/55)</b>
Type III	25.0% (5/20)	25.5% (14/55)
Total	100.0% (20/20)	100.0% (55/55)

Table 2. Correlation of types and sex in dentulous area

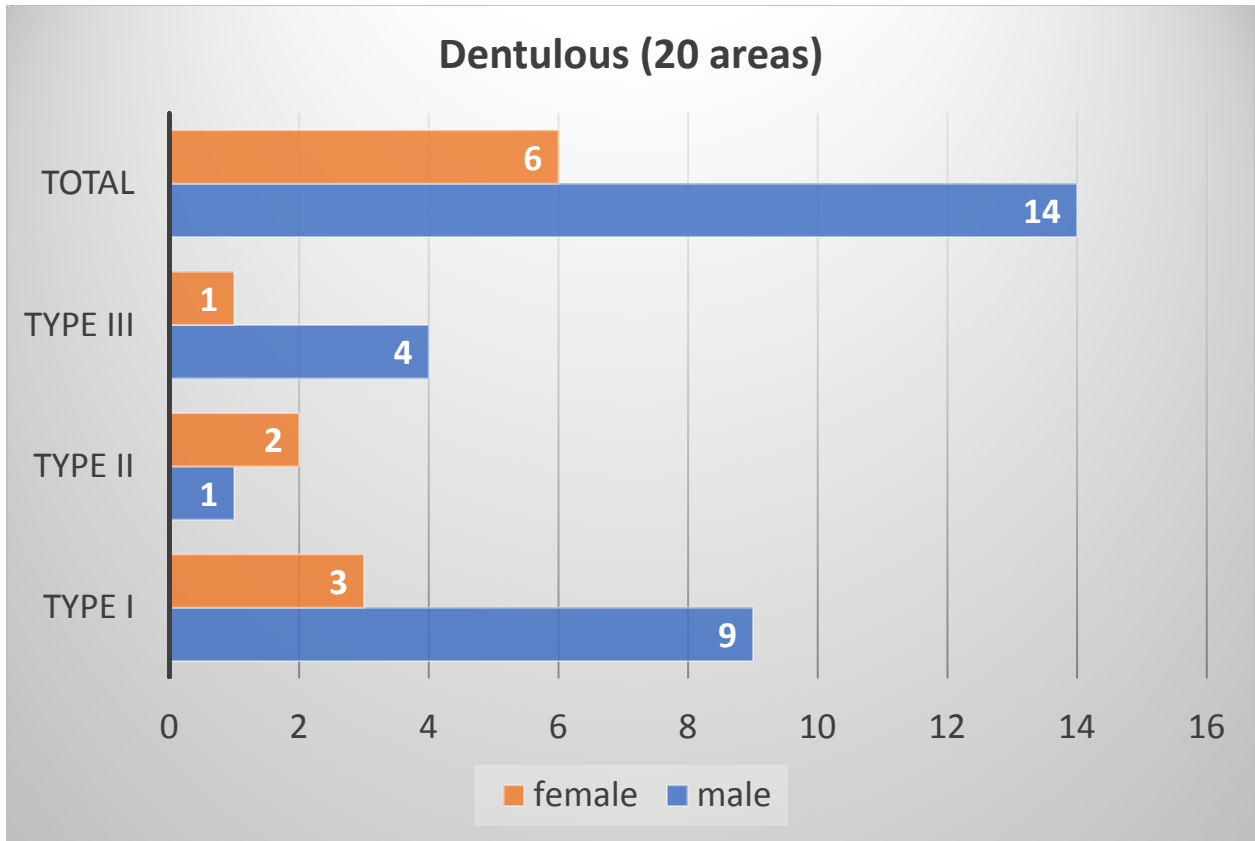


Table 3. Correlation of types and sex in edentulous area

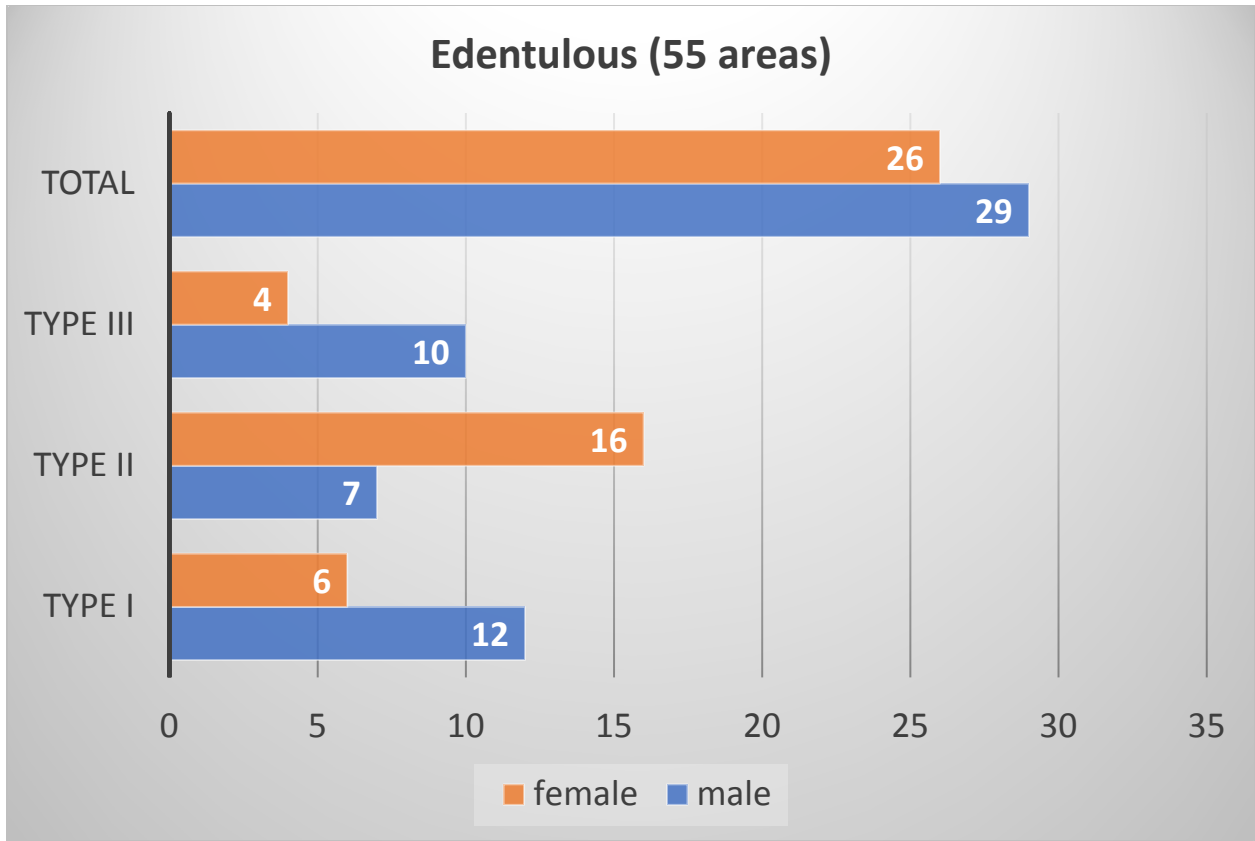


Table 4. Incidence of Classes

	Dentulous	Edentulous
Class I	<b>55.0% (11/20)</b>	27.2% (15/55)
Class II	0.0% (0/20)	18.2% (10/55)
Class III	10.0% (2/20)	9.1% (5/55)
Class IV	35.0% (7/20)	<b>45.5% (25/55)</b>

Total

100.0% (20/20)

100.0%(55/55)

Table 5. Correlation of the Classes and sex in dentulous area

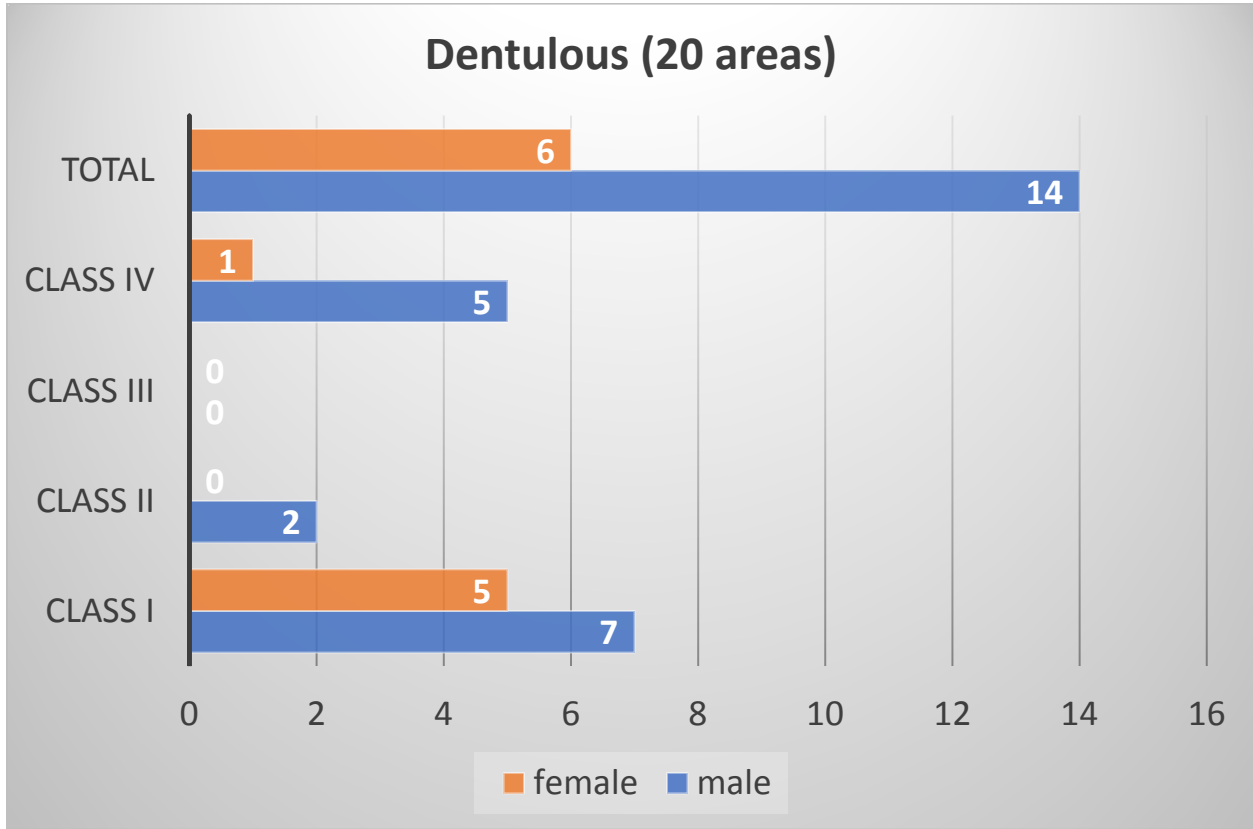
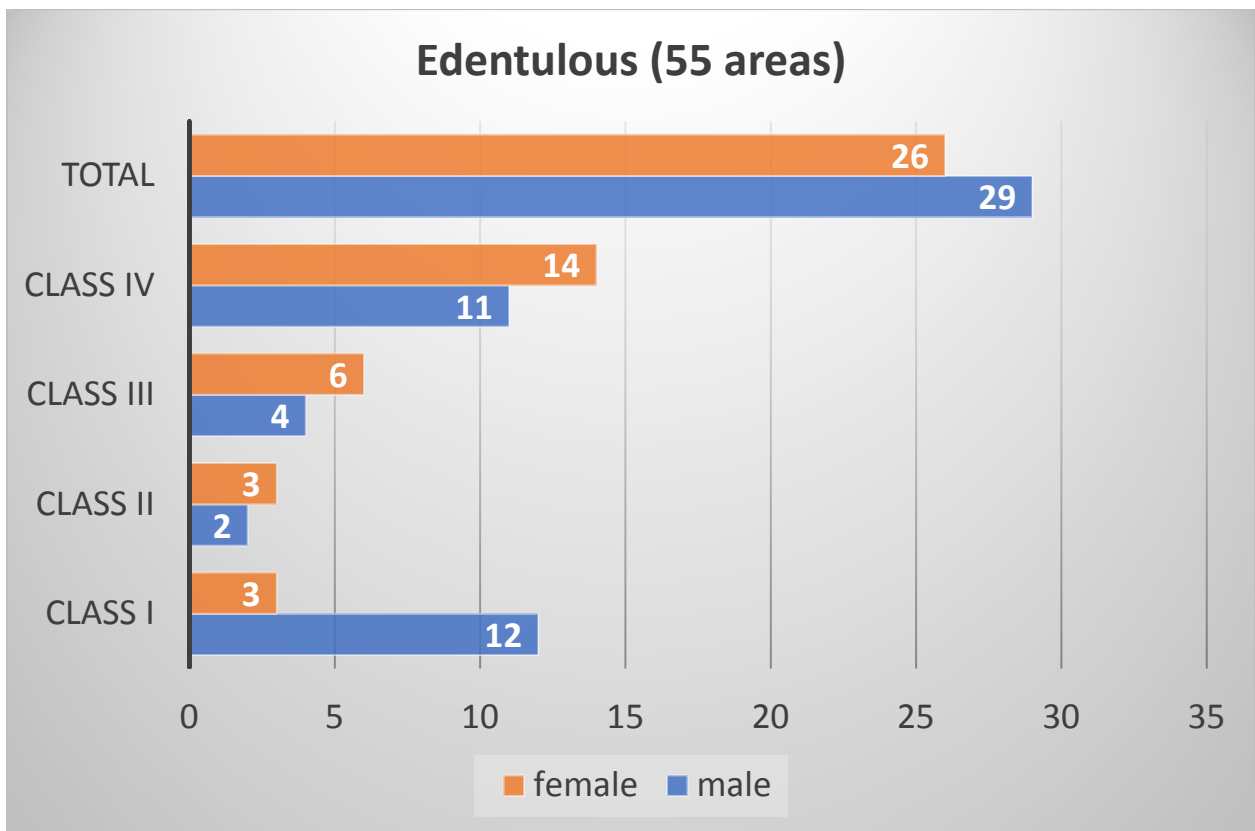
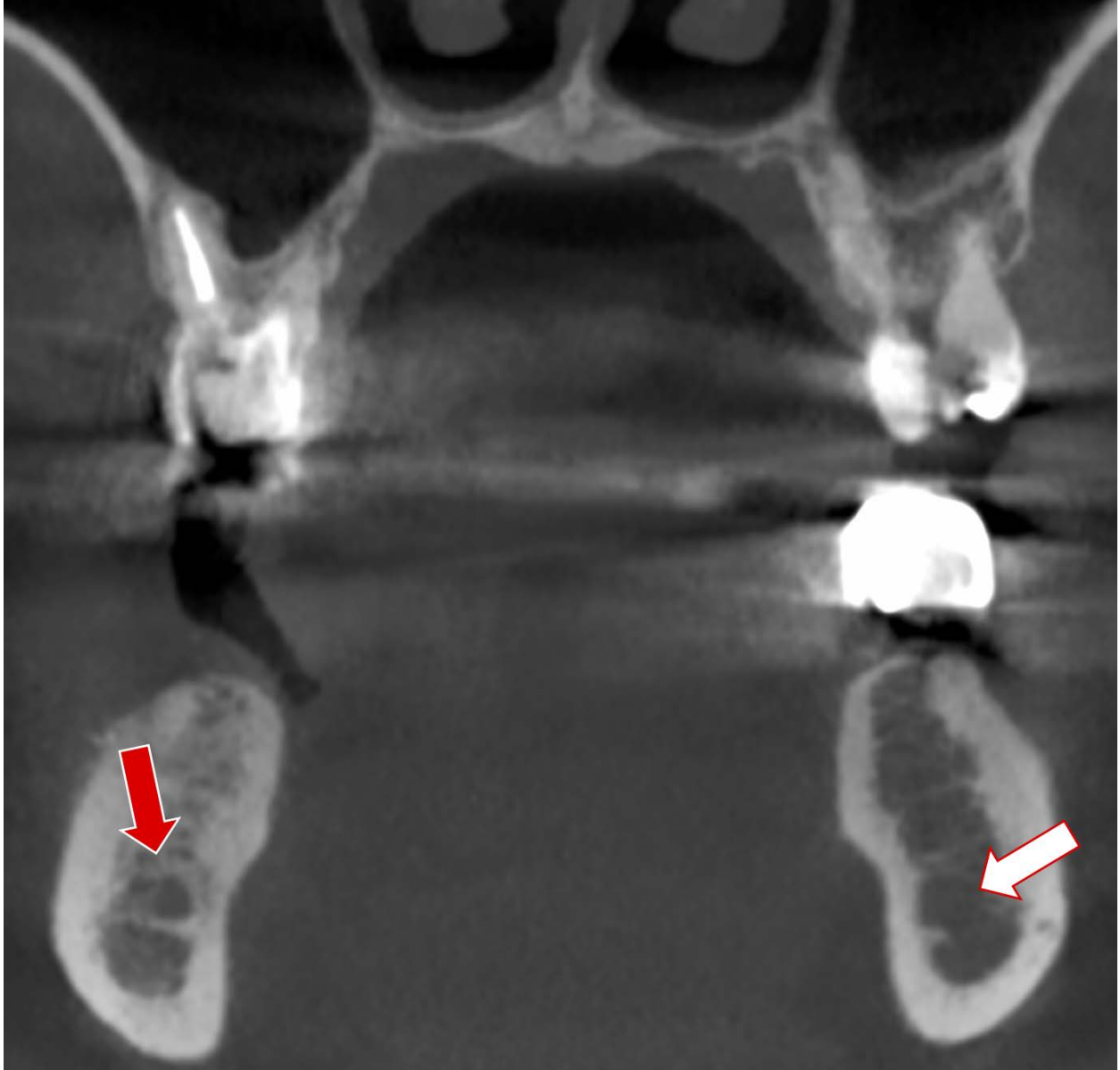
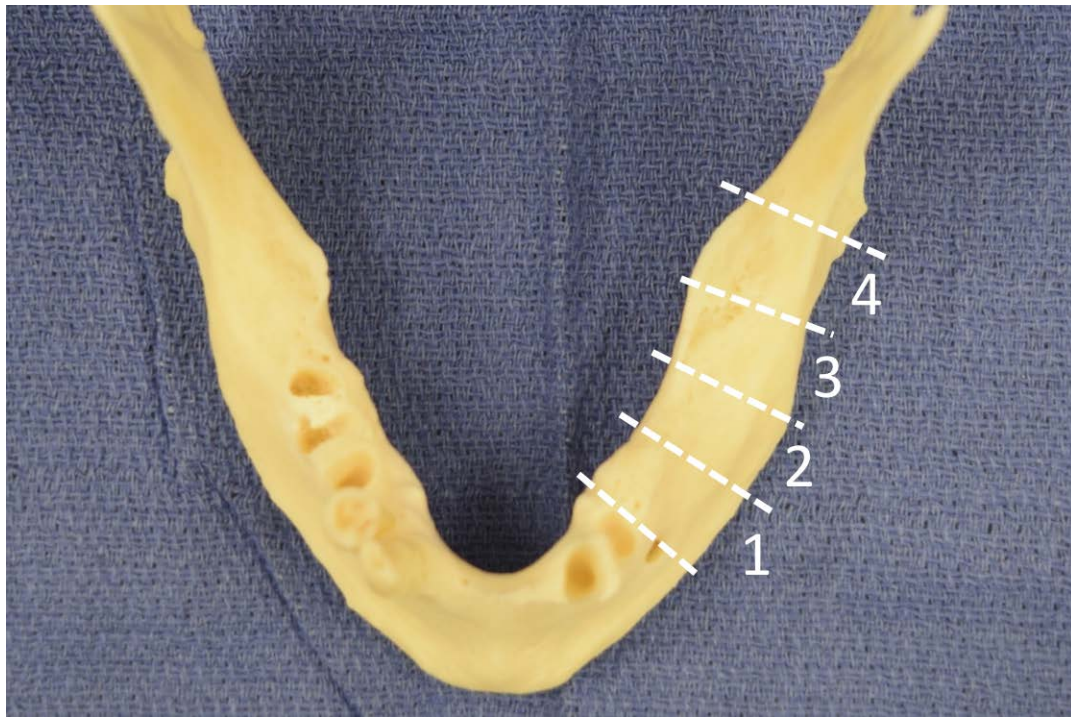
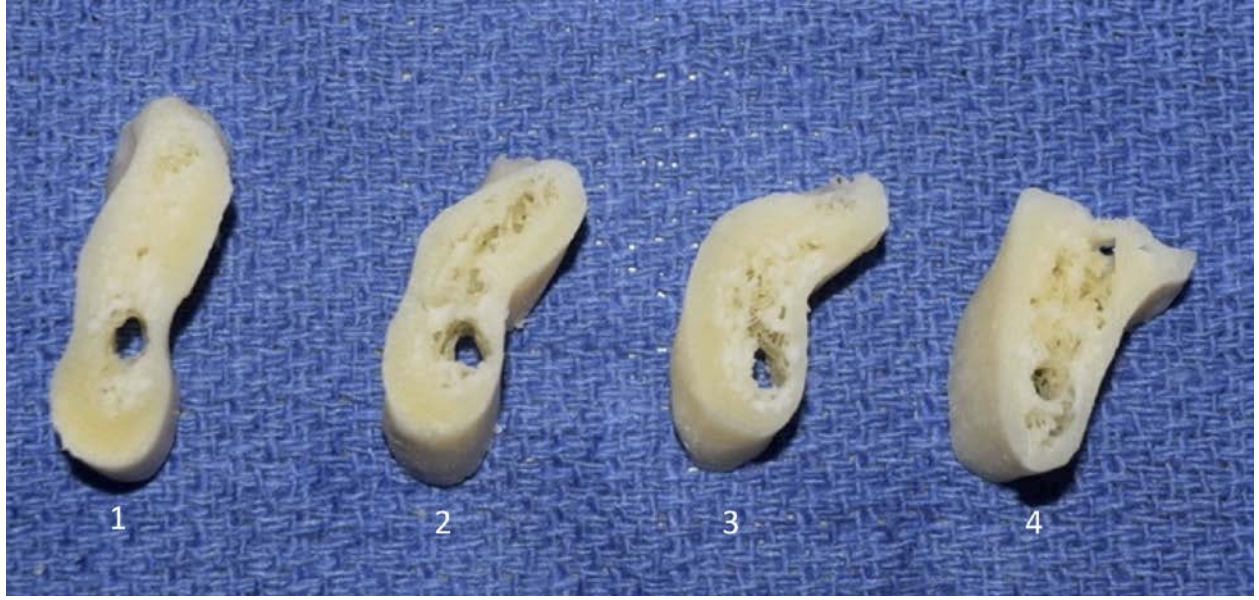

Table 6. Correlation of the Classes and sex in edentulous area



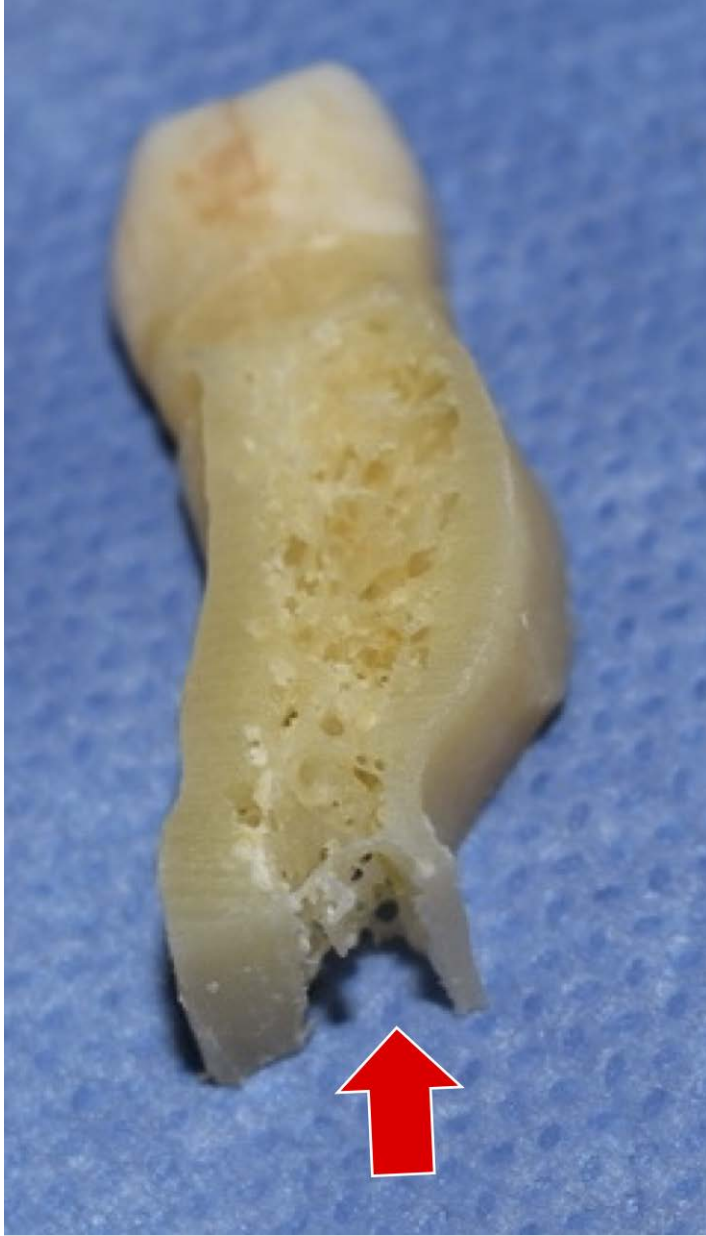




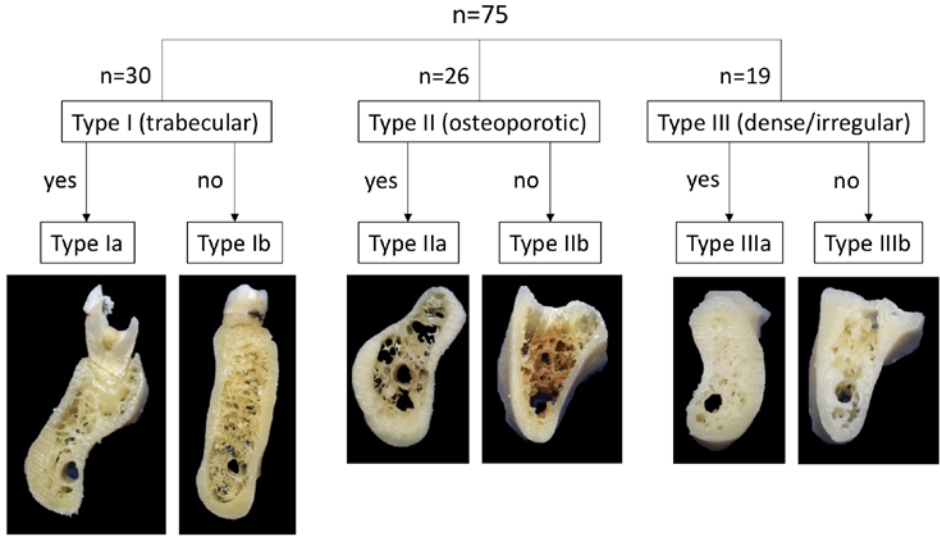


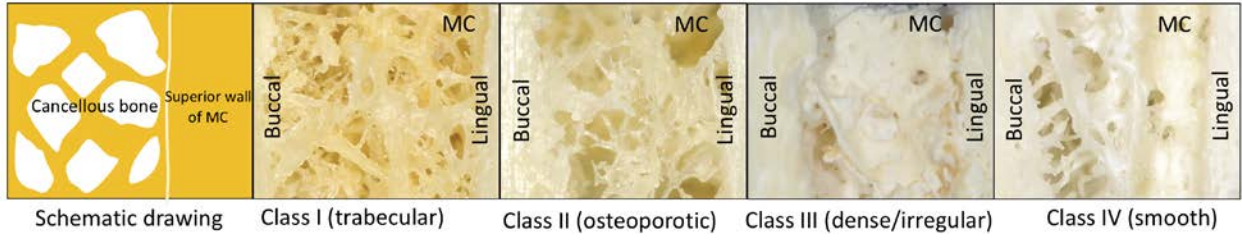


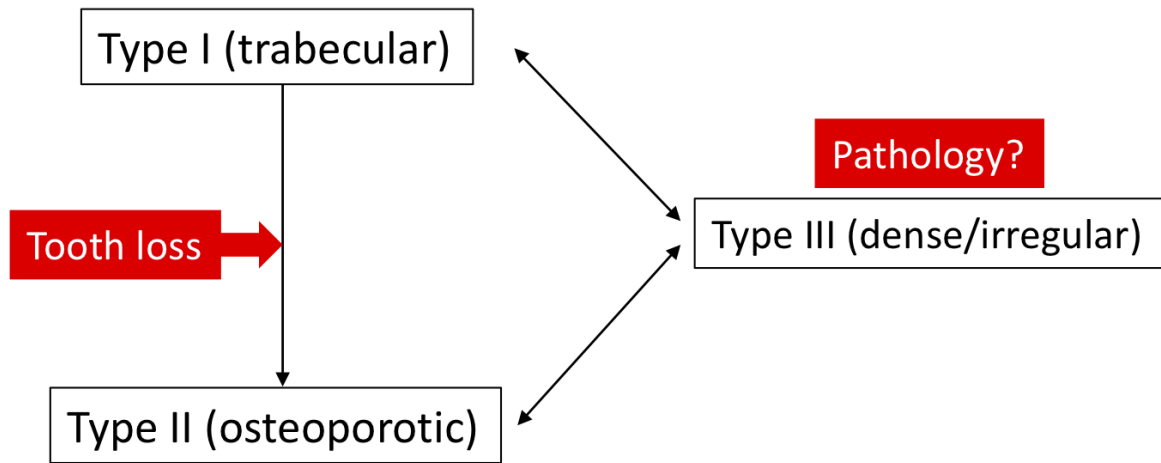


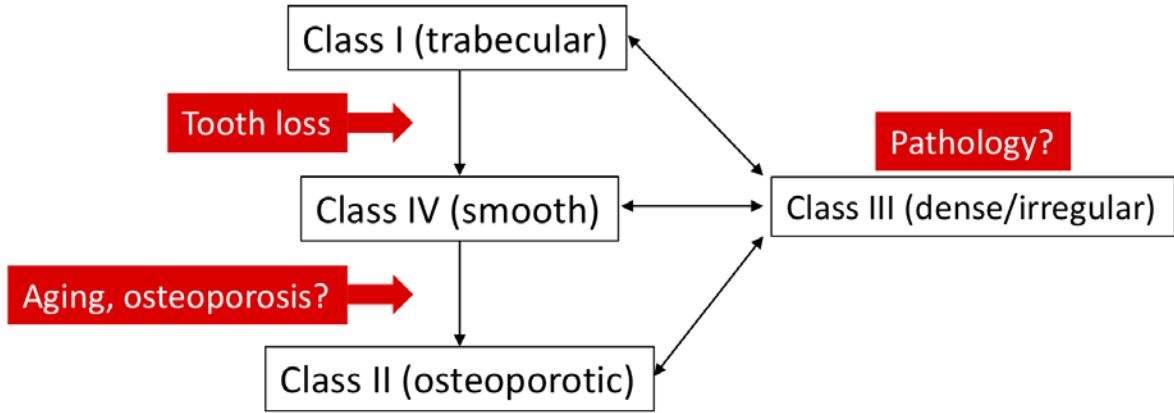


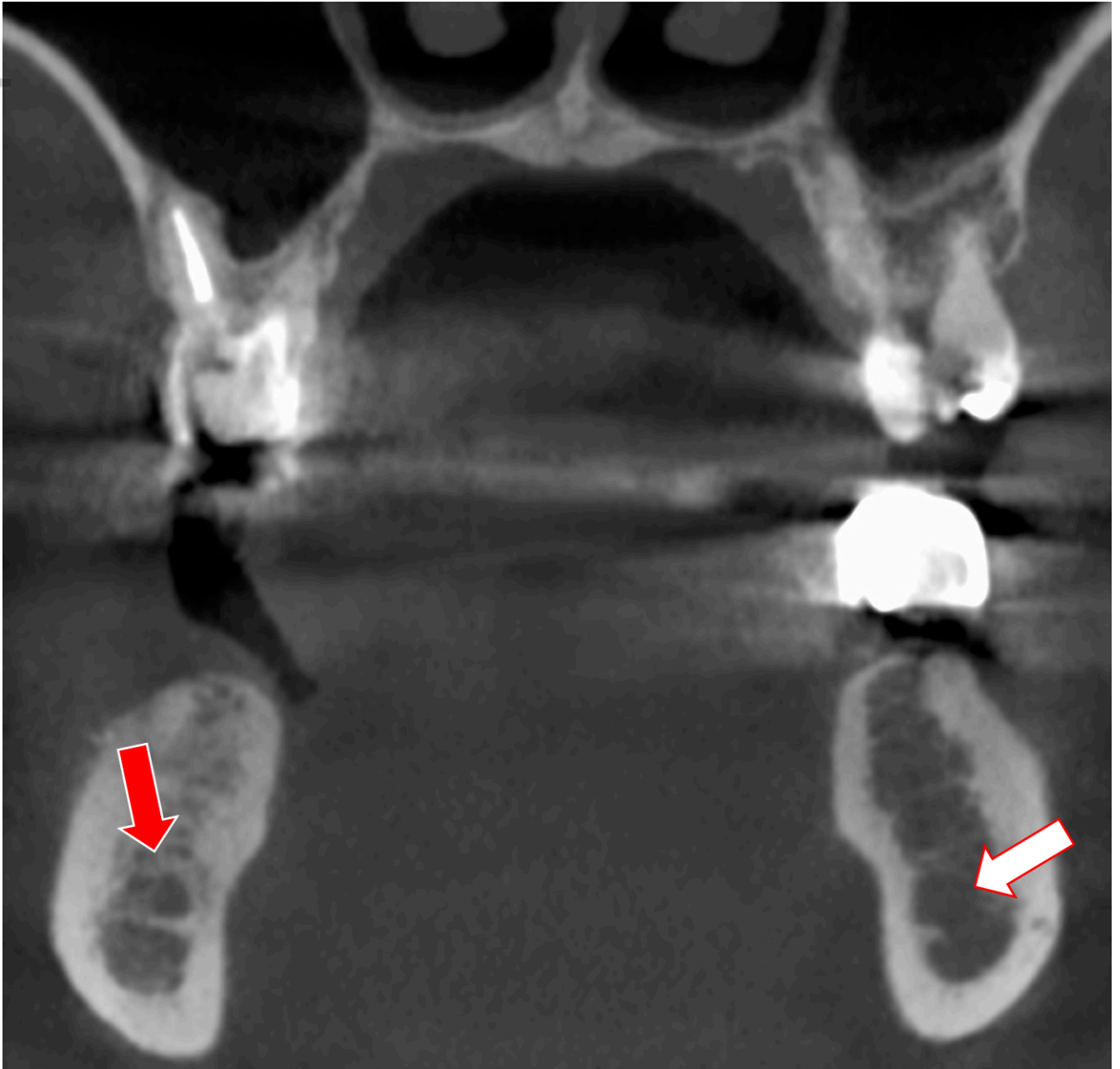
Type (cancellous pattern)  
Visibility of superior wall of MC



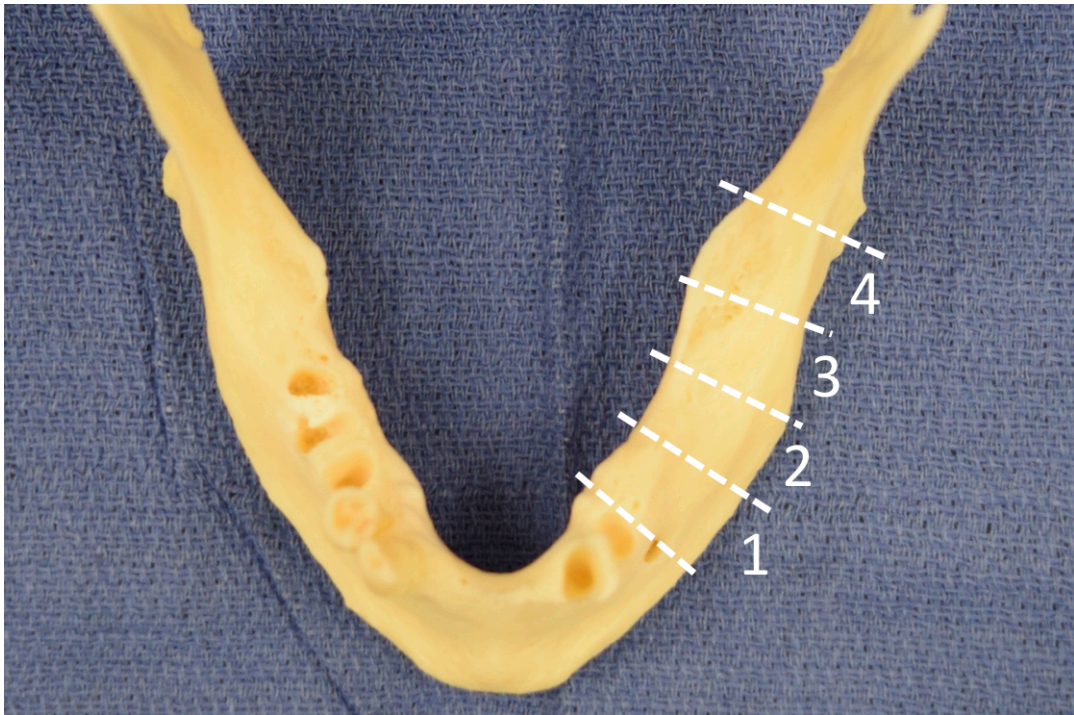






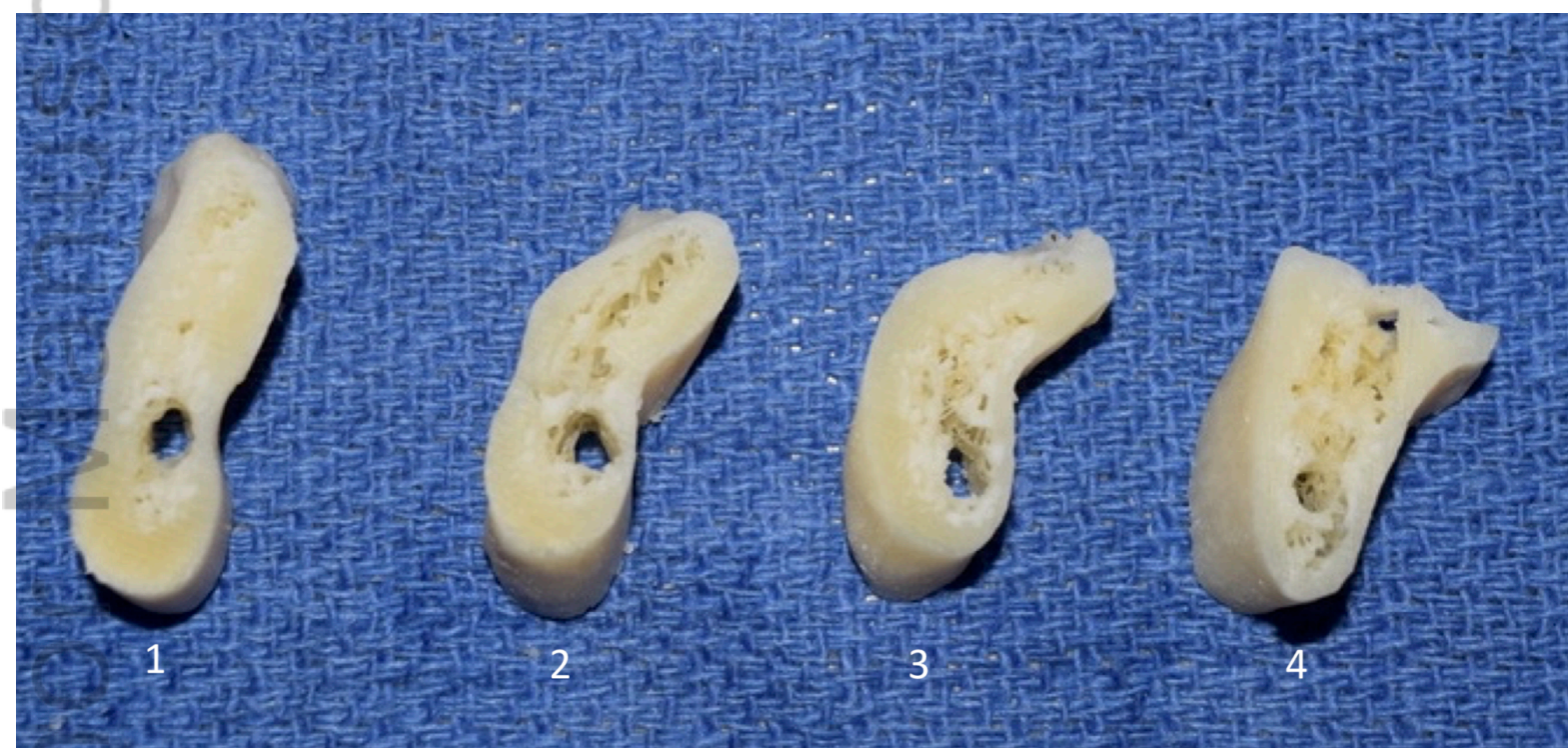

CA\_23456\_figure 1.tiff




CA\_23456\_figure 2.tiff

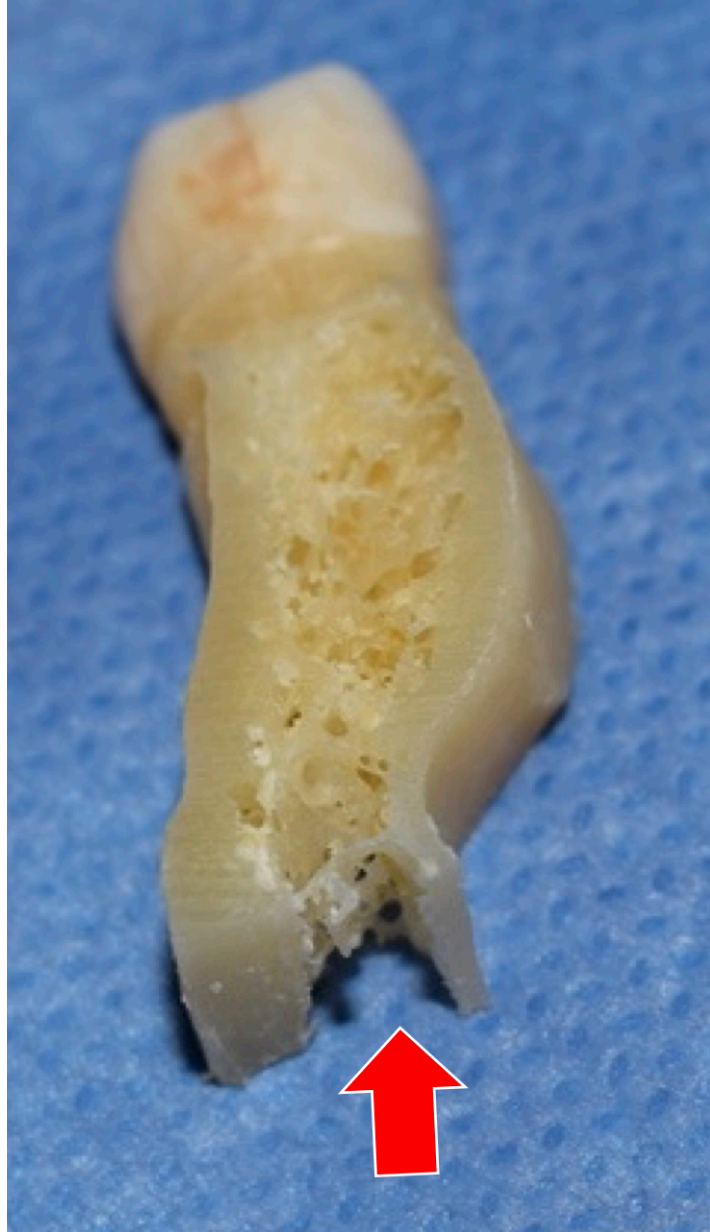



CA\_23456\_figure 3.tiff

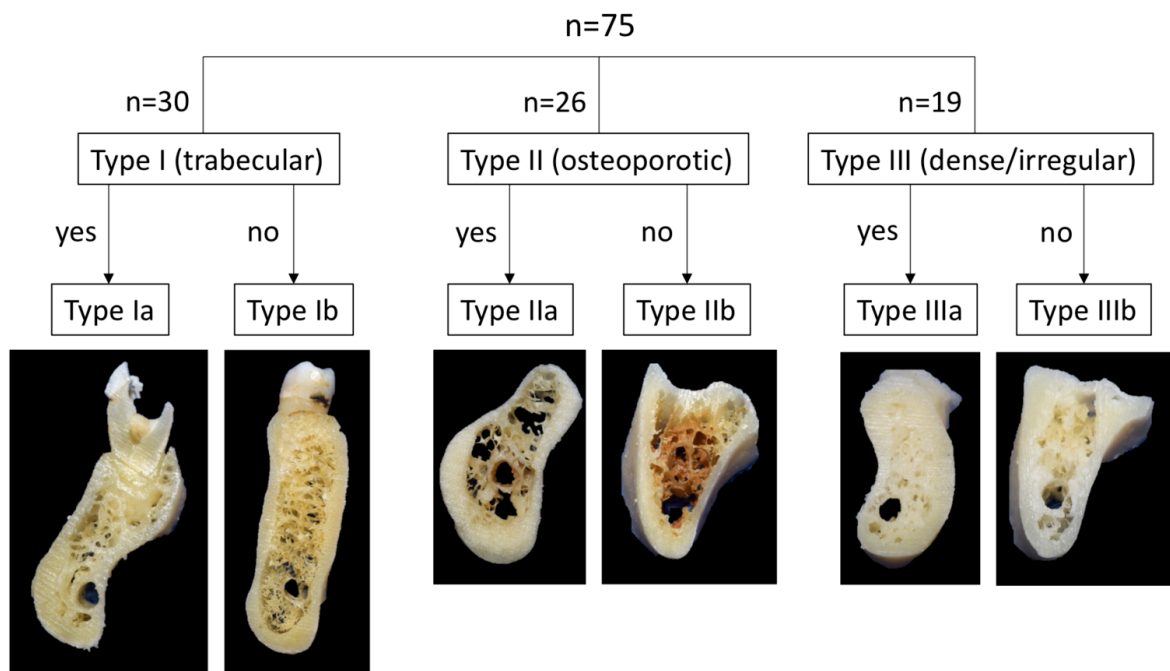


CA\_23456\_figure 4.tiff

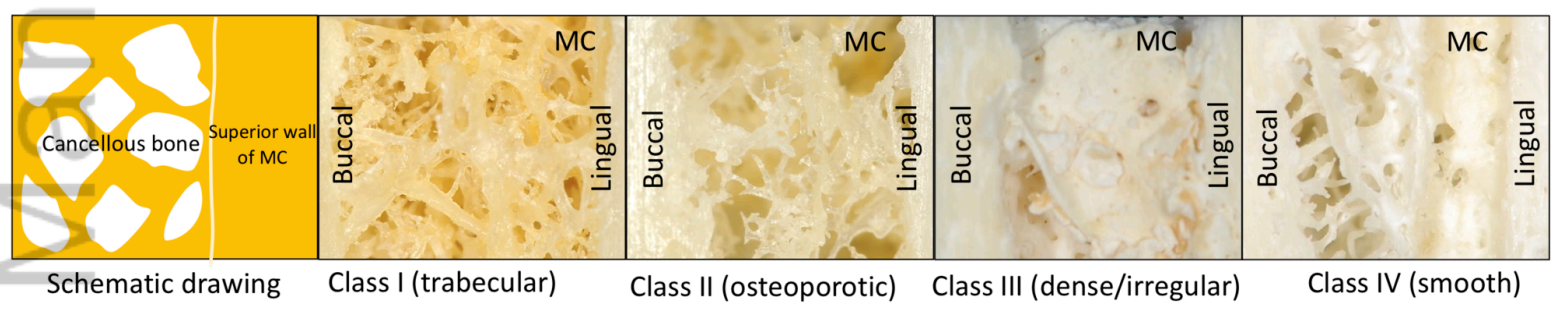


CA\_23456\_figure 5.tiff

Type (cancellous pattern)  
Visibility of superior wall of MC



CA\_23456\_figure 6.tiff



Schematic drawing

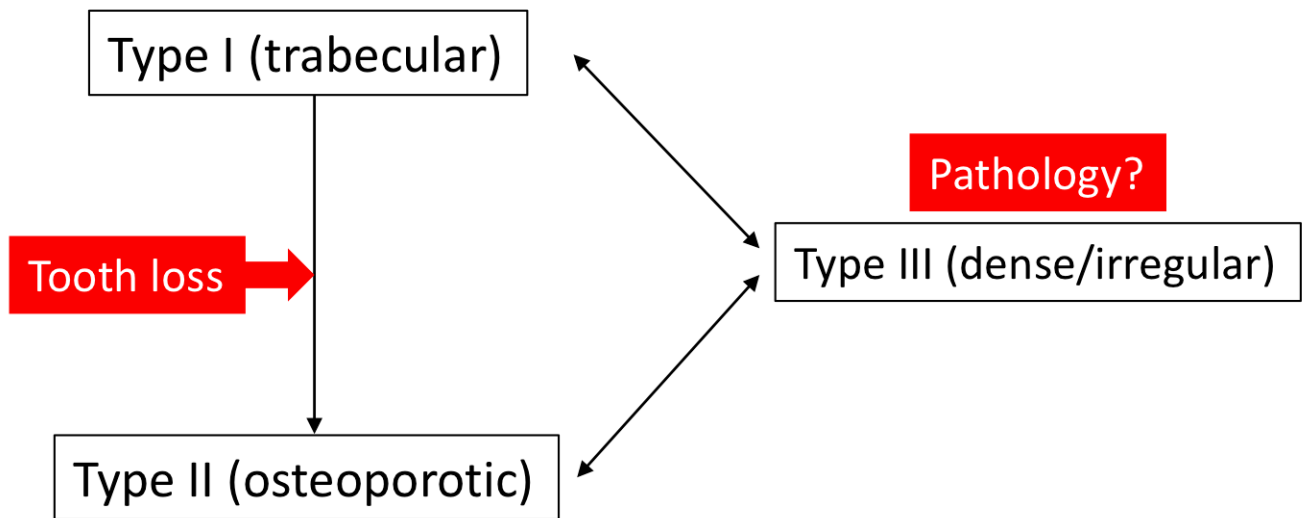
Class I (trabecular)

Class II (osteoporotic)

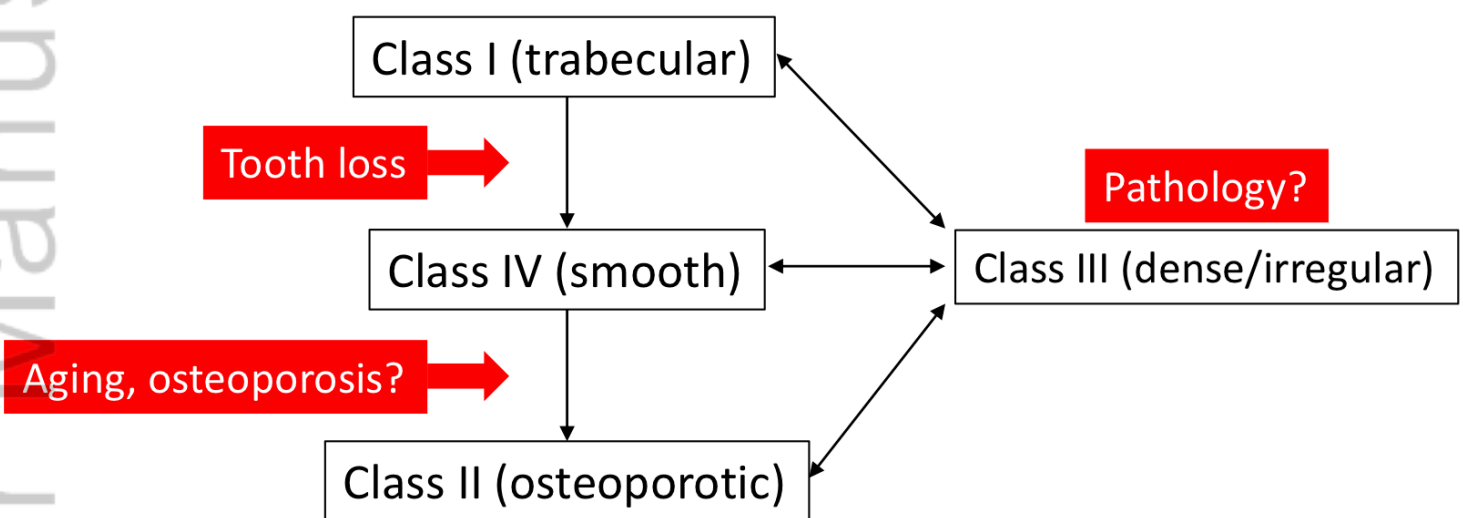
Class III (dense/irregular)

Class IV (smooth)

CA\_23456\_figure 7.tiff



CA\_23456\_figure 8.tiff



CA\_23456\_figure 9.tiff