

Hanks John (Orcid ID: 0000-0002-3433-1874)
Kovatch Kevin (Orcid ID: 0000-0002-4750-2521)
Ali Syed (Orcid ID: 0000-0001-7922-4426)
Smith Joshua (Orcid ID: 0000-0002-2076-7589)

1

Title: Cranial Nerve Outcomes in Regionally Recurrent Head & Neck Melanoma After Sentinel Lymph Node Biopsy

Running Head: HNCM Nodal Recurrence & CN Injury After SLNB

Authors:

John E. Hanks, MD¹; Pratyusha Yalamanchi, MD, MBA¹; Kevin J. Kovatch, MD¹; S. Ahmed Ali, MD¹; Joshua D. Smith, MD¹; Alison B. Durham, MD²; Carol R. Bradford, MD MS^{1,3}; Kelly M. Malloy, MD¹; Scott A. McLean, MD PhD¹

- 1) University of Michigan Department of Otolaryngology, Head & Neck Surgery
Michigan Medicine
Ann Arbor, MI 48109, United States of America
- 2) University of Michigan Department of Dermatology
Michigan Medicine
Ann Arbor, MI 48109, United States of America
- 3) University of Michigan Medical School
Ann Arbor, MI 48109, United States of America

Corresponding Author:

John E. Hanks, MD
Department of Otolaryngology-Head & Neck Surgery
Michigan Medicine
1500 East Medical Center Drive
Ann Arbor, MI 48109, United States of America
Phone: Phone: 734-936-5730
Email: hanksj@med.umich.edu

Funding: None

Conflict of Interests: The authors have no financial relationships relevant to this article to disclose.

Meeting Information: Podium presentation at the Triological Society Meeting, Coronado, CA. January 24, 2019.

Acknowledgements: We thank Nisha Meireles for database and data management

This is the author manuscript accepted for publication and has undergone full peer review but has not been through the copyediting, typesetting, pagination and proofreading process, which may lead to differences between this version and the [Version of Record](#). Please cite this article as doi: [10.1002/lary.28243](https://doi.org/10.1002/lary.28243)

Contributor Statement:

All of the authors above have made substantial contributions to this project including contributions to conception and design, or acquisition of data, or analysis and interpretation of data. All authors were involved in drafting the manuscript or revising it critically for important intellectual content. All authors have given final approval of the manuscript as submitted for publication and take responsibility for content. The authors agree to be accountable for all aspects of the work in ensuring that questions related to the accuracy or integrity of any part of the work are appropriately investigated and resolved.

Abstract:

Objective: Characterize long-term cranial nerve (CN) outcomes following sentinel lymph node biopsy (SLNB) based management for head and neck cutaneous melanoma (HNCM).

Methods: Longitudinal review of HNCM patients undergoing SLNB from 1997-2007

Results: 356 patients were identified, with mean age 53.5+/-19.0 years, mean Breslow depth 2.52+/-1.87mm, and 4.9 years median follow-up. 105(29.4%) patients had SLNB mapping to the parotid basin. 18 patients had positive parotid SLNs and underwent immediate parotidectomy/iCLND, with 6 possessing positive parotid NSLNs. 52 of 356 (14.6%) patients developed delayed regional recurrences, including 20 total intraparotid recurrences: 5 following false negative (FN) parotid SLNB, 3 following prior immediate superficial parotidectomy, 2 following iCLND without parotidectomy, and the remaining 12 parotid recurrences had negative extraparotid SLNBs. Parotid recurrences were multiple (4.9 mean recurrent nodes) and advanced (n=4 extracapsular extension), and all required salvage dissection including parotidectomy. Immediate parotidectomy/iCLND led to no permanent CN injuries. Delayed regional HNCM macrometastasis precipitated 16 total permanent CN injuries in 13 patients: 10 CN VII, 5 CN XI, and 1 CN XII deficits. 50% (n=10) of parotid recurrences caused ≥ 1 permanent CN deficits.

Conclusions: Regional HNCM macrometastases and salvage dissection confer marked CN injury risk, whereas early surgical intervention via SLNB+/-iCLND+/-immediate parotidectomy yielded no CN injuries. Further, superficial parotidectomy performed in parotid-mapping HNCM does not obviate delayed intraparotid recurrences, which increase risk of CN VII injury. Despite lack of a published disease specific survival advantage in melanoma, early disease control in cervical and parotid basins is paramount to minimize CN complications.

Key Words: melanoma, sentinel lymph node biopsy, head and neck cutaneous melanoma, cranial nerve

Abbreviations:

CN	Cranial nerve
iCLND	Immediate completion lymph node dissection
CLND	Completion lymph node dissection
DFS	Disease free survival
HNCM, H&N	Head and neck cutaneous melanoma, Head and neck
MSLT	Multicenter Selective Lymphadenectomy Trial
MSS	Melanoma specific survival
NSLN	Non-sentinel lymph node
OS	Overall survival
SLNB, SLN	Sentinel lymph node biopsy, Sentinel Lymph Node
FN	False negative

Level of Evidence: 4 (retrospective case series)

Introduction:

The crucial importance of regional nodal metastasis for prognostication, disease recurrence, and survival in melanoma is well-supported with prospective data reflected by AJCC staging and NCCN treatment guidelines [1-5]. Sentinel lymph node biopsy (SLNB) is recommended for cN0 T2-T4 and select T1b melanomas, and until recently immediate completion lymph-node dissection (iCLND) was recommended following all positive SLNBs [2, 6-8]. The initial Multicenter Selective Lymphadenectomy Trial (MSLT-I) demonstrated that SLNB followed by iCLND among patients with regionally metastatic melanoma confers prolonged disease free survival (DFS) and melanoma specific survival (MSS) over observation [9-13]. SLNB+/-iCLND-based treatment was subsequently proven effective, safe, prognostic, and accurate for head and neck cutaneous melanoma (HNCM) [12].

Despite improved DFS over observation, failure of MSLT-II [7] and DeCOG-SLT [8] to establish overall survival (OS) and MSS benefits for iCLND over observation following positive SLNB has led opponents to argue that potential iCLND complications (predominantly truncal or extremity lymphedema) unquestionably outweigh its DFS benefits [7, 8]. Consequently, MSLT-II concluded that

iCLND is “unlikely to benefit” patients with positive non-sentinel lymph nodes (NSLN) [7], leading to dispute regarding the necessity and timing of CLND among patients with microscopically positive NSLNs [4, 5, 7].

Asserting that lymphedema is prohibitive to iCLND’s DFS benefits is problematic and questionably relevant to HNCM, as H&N lymphedema is not reported in MSLT-II and rarely encountered in large HNCM SLNB cohorts [7, 12, 14-19]. Rather, uncontrolled HNCM behaves more aggressively than other sites and enacts unique complications, namely cranial nerve (CN) and carotid injuries [6, 12, 14, 20, 21]. Conversely, SLNB+/-iCLND’s safety has been compellingly demonstrated in HNCM cohorts [12, 14, 20-24]. Delayed excision of macroscopically positive NSLN’s may alternatively negate benefits of iCLND risk-avoidance by heightening complications and lengthening hospitalizations [25]. Specifically, intraparotid disease control is paramount in stage III HNCM, as nodal recurrence in an undissected deep parotid lobe is associated with a 42% CN VII injury risk [26, 27]. Challenges for surgeons and patients arising from salvage interventions and palliation of uncontrolled regional disease in HN malignancies [28] provide further support for iCLND. Locoregionally-advanced HNCM and/or associated cranial neuropathies may threaten function and quality of life years ahead of disease-specific mortality [28], lending DFS and regional disease control pivotal importance for HNCM.

We evaluate CN outcomes following SLNB+/-CLND-based management for HNCM including FN SLNB and in-field recurrences following iCLND. Here, we test the hypothesis that regional HNCM recurrence and/or ensuing salvage dissection will lead to poorer CN outcomes. Finally, we evaluate the effects of parotidectomy-timing and -extent on recurrence-related CN injuries by comparing immediate superficial parotidectomy, intraparotid recurrences following FN SLNB, and published total parotidectomy rates [26, 29].

Materials and Methods:

This study was conducted with University of Michigan Institutional Review Board approval. Longitudinal review was performed of the prospectively collected database of 356 HNCM patients who underwent WLE and SLNB+/-iCLND from 1997 to 2007 based on NCCN guidelines [27]. Following a positive SLNB, iCLND was recommended with consideration for adjuvant therapies. Patients with negative SLNB were monitored clinically, and salvage dissection was recommended for treatable macroscopic recurrences [12]. Surgical techniques, lymphatic mapping and SLN localization techniques, and histopathologic analysis for this cohort are previously described [12]. Relevant patient data was collected including SLNB outcomes, basins dissected and NSLN-involvement during iCLND, patterns and characteristics of locoregional recurrence, extent of salvage dissection, and CN injury presence and severity. Data acquisition was performed via medical record review, patient telephone interview, communication with referring provider(s), and Social Security Death Index. CN outcomes and

recurrences were primary measures. Regional recurrence patterns, clinical follow-up, time-to-recurrence, cause of death, and time-to-mortality were tabulated where applicable.

Two distinct patient populations were examined in this study following post-SLNB regional recurrence: 1) false negative (FN) SLNB who sustained regional nodal basin recurrence and 2) patients with true positive SLNB who underwent iCLND but subsequently developed regional nodal basin recurrence. Both subsets were offered surgical therapy following regional recurrence when appropriate. Nodal observation +/- serial ultrasound was neither within this study's treatment intent nor explicitly offered to patients following positive SLNB. The term "delayed completion lymph node dissection" is reserved for reference to treatment strategies in which clinical observation was explicitly stated as an intended treatment regimen, such as after WLE in lieu of SLNB or following positive SLNB in lieu of iCLND [7, 30]. In this analysis, delayed regional lymph node dissection following FN SLNB or failed iCLND is termed "salvage dissection."

Results:

Patient Demographics and Tumor Characteristics

356 eligible HNCM patients underwent WLE/SLNB from 1997 to 2007 with mean age 53.5 ± 19 years, 26.6% female, and mean Breslow depth 2.52 ± 1.87 mm. Median follow-up was 4.9 years. A study population flow diagram including SLNB sites and histopathologic status, patterns of recurrence, and CN outcomes is shown in **Figures 1A/1B**.

Regional recurrence:

52 (14.6%) patients recurred regionally following SLNB+/-iCLND-based management, which translates to 85.4% long-term regional disease control. 73 of 75 (97.3%) patients with positive SLNB underwent iCLND, and 20 showcased positive NSLNs. 21 (28.8%) patients recurred following iCLND in regional HN basins (Levels I-VI, suboccipital, and/or parotid basin), including 10 patients with positive NSLN's at the time of iCLND. Ten patients with post-iCLND regional recurrences showcased nodal positivity during salvage dissection including eight nodal recurrences in previously dissected basins during iCLND. One patient recurred in a previously dissected external jugular basin but declined salvage dissection due to concurrent distant metastasis prior to suffering recurrence-related CN XI injury. 12.3% (n=9) of iCLND's failed to achieve long-term regional nodal control among immediately dissected basins. SLNB+/-iCLND failed to identify melanoma-containing nodal basins in 20 (5.6%) total patients (18 FN SLNB and 2 nodal recurrences outside of basins dissected during iCLND).

Parotid-mapping SLNB:

105 patients (29.4%) had at least one parotid-mapping SLN. Primary sites with at least one parotid SLN were most frequently the ipsilateral ear (27%), cheek (15%), and temple (9%). **Figure 2** showcases primary site distribution for parotid-localizing SLNBs. Mean Breslow depth among parotid-

mapping sites was 2.23 ± 1.52 mm. Mean 2.94 SLNs were extracted (median 2) from an average of two lymphatic basins.

Positive Parotid Basin SLNB and Immediate Parotidectomy:

Of 75 positive SLNB's, 19 patients had positive intraparotid or periparotid SLNBs. In total 20 patients underwent superficial parotidectomy as part of iCLND, including seven specimens containing positive intraparotid NSLNs.

False Negative SLNB, Parotid False Negative SLNB:

Of 18 total FN SLNBs, four patients had at least one negative intraparotid SLN and later sustained ipsilateral parotid bed macrometastasis. Additionally, one patient had a negative intraparotid SLN but positive jugulodigastric SLNs, prompting ipsilateral iCLND, including cervical levels I-V without parotidectomy. These five cumulative intraparotid FN SLNBs translate to a 5.8% intraparotid false omission rate (5 FN/(5 FN + 81 TN)).

Intraparotid Recurrences, Salvage Parotidectomy

Following SLNB+/-iCLND+/-superficial parotidectomy, twenty patients sustained delayed intraparotid recurrences. The majority (17/20) of patients with intraparotid recurrences had not previously undergone parotidectomy prior to the first parotid recurrence. Three patients suffered delayed intraparotid recurrences following immediate superficial parotidectomy, which translates to a 15% recurrence rate after immediate superficial parotid dissection. Two of the immediate superficial parotidectomy specimens contained no additional intraparotid NSLNs, whereas one possessed a single intraparotid NSLN.

All patients with delayed intraparotid recurrences underwent salvage dissection, at minimum including ipsilateral parotidectomy. Four patients' nodal recurrences exhibited extracapsular extension, and salvage specimens for intraparotid recurrences contained 4.87 average total positive lymph nodes.

CN Outcomes

No CN injuries were noted following any combination of SLNB, immediate superficial parotidectomy, and/or iCLND. However, 13 patients (25.0%) with regional recurrences developed 16 total permanent CN injuries. Recurrence-related CN outcomes included 10 CN VII deficits (3 complete- and 7 partial-distribution deficits), five CN XI/SCM deficits, and one CN XII deficit. Ten of sixteen CN deficits involved paresis resulting from neural dissection during salvage surgery, implying that nerve function was at least partially preserved in all salvage dissections in which nerve sacrifice was not oncologically required. The remaining six injuries arose from neural tumor invasion including two CN paresis and four CN paralyzes with or without oncologically-mandated nerve sacrifice.

Among 18 total FN SLNB, seven (38.9%) developed permanent recurrence-related CN injuries with a mean time-to-CN-injury of 3.45 ± 2.04 years. Moreover, six (28.6%) patients sustained recurrence-related permanent CN injuries despite prior iCLND+/-superficial parotidectomy for SLN-positivity with 3.11 ± 2.71 years mean time-to-CN-injury.

The large predominance of cumulative CN injuries (13 of 16) occurred secondary to delayed intraparotid recurrences. 10 of 20 (50%) delayed parotid recurrences developed permanent CN VII injuries. Further, three intraparotid recurrences yielded multiple cranial neuropathies. Recurrence-related CN VII injuries were frequent among the few patients who recurred in a previously mapped and/or dissected parotid basin, including four of five (80%) FN parotid-mapping SLNB's and two of three (66%) intraparotid recurrences following immediate superficial parotidectomy.

A complete description of patients suffering permanent cranial neuropathies following regional HNCM recurrence is showcased in **Table 1**.

Discussion:

The current study affirms that HNCM management combining SLNB +/- iCLND (including immediate parotidectomy when indicated) is safe and highly efficacious with long-term follow-up. However, the few delayed regional HNCM recurrences following SLNB-guided management are often advanced with considerable morbidity, including substantial CN-injury-risk not seen with iCLND. Therefore, early regional disease control in HNCM is vital to minimize recurrence-related CN complications, particularly within the parotid basin. Further, at-risk parotid basins addressed with superficial parotidectomy alone remain susceptible to intraparotid recurrences, which imposes risk of potentially multiple CN injuries. Therefore, surgeons should consider total parotidectomy in at-risk parotid basin management. Overall, our 25% incidence of CN injury following delayed regional macrometastases after SLNB-guided management argues against the MSLT-II authors' advocacy for delayed excision of post-observation regional recurrences [7]. Instead we contend that iCLND should be performed for at-risk basins whenever possible in HNCM. Furthermore, we assert that the risks of SLNB+/-iCLND for HNCM are not sufficient to forgo the DFS benefits and potential to improve CN outcomes, irrespective of iCLND's effects on MSS.

Despite persuasive evidence supporting early regional disease control among affected patients in landmark trials, opponents of iCLND posit that surgical toxicities in unaffected patients unequivocally outweigh iCLND's DFS benefit, improved regional disease control, and added staging benefits [31]. Although a secondary endpoint, MSLT-II showcased improved DFS following iCLND compared to observation for SLN-positivity, including 69% fewer regional recurrences [7, 8]. A 2010 MSLT-I interim analysis also demonstrated increased complication frequency and severity following observation/delayed CLND compared to SLNB/iCLND with resultant lengthened post-operative hospitalizations [25]. Recognizing the majority of complications reported in MSLT-II (i.e. lymphedema) as "mild," "transient," and limited to the extremities [7, 32] renders the argument to forgo iCLND's DFS

benefit [31] inapplicable to HNCM. HNCM's well-established uniquely aggressive behavior is associated with historically poorer prognosis and higher mortality than other sites, poorly predictable lymphatic mapping and recurrence patterns, and a distinct complication profile [12, 14, 22, 26, 33-40]. Unlike the trunk and extremities, HNCM iCLND complications rarely include lymphedema due to watershed H&N lymphatic drainage [22]. We have previously reported only a single case of mild lymphedema following iCLND in this cohort, resolving spontaneously within 4 weeks [41]. Moreover, HNCM was historically viewed as sufficiently unique to evoke intense skepticism prior to SLNB's widespread adoption [12-14, 21, 22, 34, 35, 40, 42-51]. Likewise, our study suggests that MSLT-II's conclusions similarly warrant intense scrutiny before abandoning H&N iCLND, which may increase CN injury frequency and severity [7]. Unfortunately, a sufficiently-powered prospective HNCM study examining the efficacy of SLNB with immediate NSLN excision versus observation is unlikely [6]. However, our study shows that SLNB-guided regional nodal management of cN0 HNCM is highly efficacious, evidenced by 85.4% regional disease control with 4.9 years of median follow-up. Additionally, while parotid dissection was historically viewed as technically challenging and potentially dangerous [23, 52], we demonstrate a low long-term intraparotid false omission rate of 5.8%, which favorably compares to prior studies [30, 35, 40, 46, 47, 51-67] and is notably superior to the 6.4% long-term false omission rate for the entire study cohort [41].

The extent of regional surgical dissection in at-risk HN lymphatic basins represents another important question regarding DFS and resultant CN injury risk. Historically, two CN XI injuries in the Sunbelt Melanoma Trial provoked safety concerns regarding dissection near CN VII and CN XI and reticence to perform SLNB in HNCM [14, 20, 22]. Subsequently, large exclusively HNCM cohorts in high-volume cutaneous oncology centers have overwhelmingly demonstrated the safety of SLNB+/-iCLND in HNCM, without permanent CN or clinically significant vascular injuries despite over one-in-four HNCM SLNBs mapping to the parotid [12, 14, 20-24]. Our results reiterate the safety of SLNB (n=356) and iCLND (n=73) by showcasing zero SLNB- or iCLND-related permanent CN injuries. Our study also demonstrates that even with SLNB+/-iCLND's high efficacy and safety that the expense of relatively few delayed regional recurrences in HNCM is potentially immense, with 25% (n= 13 of 52) of regional recurrences at all HNCM sites resulting in at least one permanent CN injury. Likewise, while limited by the sensitivity of SLNB and iCLND, our findings support early accurate diagnosis of micrometastases and swift surgical management of affected HNCM basins whenever possible. This is perhaps most apparent when examining the 33% (6/18) of FN SLNB's of the H&N who developed permanent cranial neuropathies upon regional recurrence. Acknowledging that our study enrollment closed over 10 years ago, interval advances such as the development of SPECT/CT, growing expertise in SLNB for HNCM, and establishment of high-volume multidisciplinary cutaneous oncology centers may further improve already highly accurate, efficacious, and prognostic SLNB-guided therapy in HNCM [12, 20, 68-71]. These advances may translate to improved recurrence rates and thereby improved CN outcomes.

High-level surgical expertise in HNCM cultivated over the last 3 decades has begun to shift fear from surgical complications to fear of CN injury from insufficient nodal dissection by permitting recurrence in previously undissected or underdissected at-risk HN basins [26]. The risk of uncontrolled

locregional disease arising from undissected at-risk NSLNs poses immense risks of cranial neuropathy and therefore poses risk to patient function, identity, and quality of life that are distinct from other primary sites and may occur independently of MSS [28]. Particularly, CN VII injury following intraparotid recurrence imposes an immense quality of life impairment. The recurrence rate of stage III melanoma following superficial parotidectomy has been reported at rates of 7%-13% [26, 72]. Conversely, null recurrence following total parotidectomy for HNCM has repeatedly been reported [26, 29] without a significant difference in surgical CN VII injury between primary superficial versus total parotidectomy [26, 27]. Notably, among 129 stage III HNCM patients with either macro- or micrometastatic parotid involvement, Wertz, et al reported superior recurrence rates and CN VII outcomes following total parotidectomy versus superficial parotidectomy in stage III HNCM, prompting the NCCN to endorse consideration of total parotidectomy for intraparotid stage III HNCM [26]. Among recurrences in previously undissected deep parotid lobes, there was a 42% risk of permanent CN VII injury [26]. In our cohort, three patients suffered delayed intraparotid recurrences after immediate superficial parotidectomy (15%), and an additional five sustained intraparotid recurrence after a FN parotid SLNB. Intraparotid recurrence following SLNB, regardless of histopathologic status, imparted CN VII injury risk. Specifically, macrometastatic recurrence in a previously undissected total parotid basin (n=4 of 5, 80%) following falsely negative SLNB and/or undissected deep parotid lobe (n=2 of 3, 66%) following immediate superficial parotidectomy accounted for a cumulative 50% (n=10 of 20) permanent CN VII injury rate among all parotid recurrences in this cohort.

Moreover, in our small 13-patient subset with 16 cumulative permanent CN injuries, all 10 injuries from neural dissection during salvage surgery maintained at least partially-preserved long-term nerve function. Alternatively, an increasing degree of motor neuropathy was cumulatively observed involving the six CN injuries arising from tumor invasion or oncologic nerve sacrifice in HNCM, including three total-distribution CN (VII or XI) paralyzes and one upper division CN VII division paralysis. Therefore, while salvage surgery for regional HNCM macrometastases imposes its own CN injury risk, prompt surgical salvage in well-selected patients may facilitate fewer CN injuries with less severe motor dysfunction compared to uncontrolled disease progression. Delayed intraparotid recurrence was encountered in at least one instance in which parotid SLNB was negative whereas SLNB in other cervical basins was positive. In this case, iCLND was performed without immediate parotidectomy prior to intraparotid recurrence and CN VII injury. Therefore, SLN-positivity in any basin merits iCLND-consideration encompassing all SLN-containing basins, including basins yielding only negative SLNs.

Limitations of this study include the few patients on which conclusions have been based. Thankfully, SLNB-guided management's long-term safety and fidelity at high-volume centers make both regional recurrences and associated CN injuries rare events. We argue that iCLND should be favored over observation in HNCM to potentially prevent even rare recurrence-related cranial neuropathies, given neck dissection's excellent safety profile [41]. Conversely, no existing evidence supports clinical observation as sufficiently sensitive to prevent delayed CN injury as a presenting manifestation of recurrence. This study's interventions precede recently-approved systemic molecularly-targeted and

immune therapeutics for stage III/IV melanoma, which promise to markedly enhance advanced HNCM outcomes. In addition to established DFS benefits and potential CN injury risk-avoidance, iCLND's NSLN histopathologic data may allow adjuvant therapy risk-stratification [73-81]. High-risk NSLN-positive strata defined by iCLND may justify early systemic treatment (e.g. immunotherapy) in well-selected patients and perhaps avoid severe, potentially lethal toxicities (e.g. bowel perforation, hepatotoxicity, hypophysitis, pneumonitis, cardiac myositis, arrhythmias, etc.) [82] in low-risk patients.

Conclusions:

SLNB-guided HNCM management remains highly accurate and prognostic with excellent long term regional disease control, but even rare HNCM regional recurrences impart substantial CN injury risk. Conversely, SLNB +/- iCLND (including immediate parotidectomy when indicated) is safe, yielding no CN injuries. For intraparotid SLN-positivity, surgeons should consider deep parotid lobe dissection. For delayed macrometastatic HNCM recurrences, prompt salvage surgery for amenable recurrences may facilitate fewer CN injuries with less severe motor neuropathies. The high incidence of cranial neuropathy following regional HNCM recurrence argues in favor of iCLND following positive SLNB in attempt to gain early regional melanoma control. iCLND-mediated DFS and CN injury benefits likely endure in HNCM regardless of its influence on MSS.

References:

1. Balch, C.M., et al., *Final version of 2009 AJCC melanoma staging and classification*. J Clin Oncol, 2009. **27**(36): p. 6199-206.
2. *National Comprehensive Cancer Network. Clinical Practice Guidelines in Oncology, Cutaneous Melanoma. V.1.2019*. 2018 [cited 2019 January 23, 2019].
3. Balch, C.M., et al., *Multivariate analysis of prognostic factors among 2,313 patients with stage III melanoma: comparison of nodal micrometastases versus macrometastases*. J Clin Oncol, 2010. **28**(14): p. 2452-9.
4. Reintgen, M., et al., *Evidence for a better nodal staging system for melanoma: the clinical relevance of metastatic disease confined to the sentinel lymph nodes*. Ann Surg Oncol, 2013. **20**(2): p. 668-74.
5. Leung, A.M., et al., *Staging of regional lymph nodes in melanoma: a case for including nonsentinel lymph node positivity in the American Joint Committee on Cancer staging system*. JAMA Surg, 2013. **148**(9): p. 879-84.
6. Schmalbach, C.E. and C.R. Bradford, *Completion lymphadenectomy for sentinel node positive cutaneous head & neck melanoma*. Laryngoscope Investig Otolaryngol, 2018. **3**(1): p. 43-48.
7. Faries, M.B., et al., *Completion Dissection or Observation for Sentinel-Node Metastasis in Melanoma*. N Engl J Med, 2017. **376**(23): p. 2211-2222.

8. Leiter, U., et al., *Complete lymph node dissection versus no dissection in patients with sentinel lymph node biopsy positive melanoma (DeCOG-SLT): a multicentre, randomised, phase 3 trial*. *Lancet Oncol*, 2016. **17**(6): p. 757-767.
9. Morton, D.L., et al., *Final trial report of sentinel-node biopsy versus nodal observation in melanoma*. *N Engl J Med*, 2014. **370**(7): p. 599-609.
10. Gershenwald, J.E., et al., *Multi-institutional melanoma lymphatic mapping experience: the prognostic value of sentinel lymph node status in 612 stage I or II melanoma patients*. *J Clin Oncol*, 1999. **17**(3): p. 976-83.
11. Morton, D.L., et al., *Improved long-term survival after lymphadenectomy of melanoma metastatic to regional nodes. Analysis of prognostic factors in 1134 patients from the John Wayne Cancer Clinic*. *Ann Surg*, 1991. **214**(4): p. 491-9; discussion 499-501.
12. Erman, A.B., et al., *Sentinel lymph node biopsy is accurate and prognostic in head and neck melanoma*. *Cancer*, 2012. **118**(4): p. 1040-7.
13. Leong, S.P., et al., *Impact of sentinel node status and other risk factors on the clinical outcome of head and neck melanoma patients*. *Arch Otolaryngol Head Neck Surg*, 2006. **132**(4): p. 370-3.
14. Chao, C., et al., *Sentinel lymph node biopsy for head and neck melanomas*. *Ann Surg Oncol*, 2003. **10**(1): p. 21-6.
15. Mayrovitz, H.N., S. Ryan, and J.M. Hartman, *Usability of advanced pneumatic compression to treat cancer-related head and neck lymphedema: A feasibility study*. *Head Neck*, 2018. **40**(1): p. 137-143.
16. Rockson, S.G., *Lymphedema in Head and Neck Cancer*. *Lymphat Res Biol*, 2016. **14**(4): p. 197.
17. Ridner, S.H., et al., *Biomarkers Associated with Lymphedema and Fibrosis in Patients with Cancer of the Head and Neck*. *Lymphat Res Biol*, 2018.
18. Doke, K.N., et al., *Quantitative clinical outcomes of therapy for head and neck lymphedema*. *Adv Radiat Oncol*, 2018. **3**(3): p. 366-371.
19. Pigott, A., et al., *Head and neck lymphedema management: Evaluation of a therapy program*. *Head Neck*, 2018. **40**(6): p. 1131-1137.
20. Schmalbach, C.E. and C.R. Bradford, *Is sentinel lymph node biopsy the standard of care for cutaneous head and neck melanoma?* *Laryngoscope*, 2015. **125**(1): p. 153-60.
21. Carlson, G.W., et al., *Sentinel lymph node biopsy in the management of cutaneous head and neck melanoma*. *Plast Reconstr Surg*, 2005. **115**(3): p. 721-8.
22. Schmalbach, C.E., et al., *Reliability of sentinel lymph node mapping with biopsy for head and neck cutaneous melanoma*. *Arch Otolaryngol Head Neck Surg*, 2003. **129**(1): p. 61-5.
23. Picon, A.I., et al., *Sentinel Lymph Node Biopsy for Cutaneous Head and Neck Melanoma: Mapping the Parotid Gland*. *Ann Surg Oncol*, 2016. **23**(Suppl 5): p. 9001-9009.
24. Wells, K.E., et al., *Parotid selective lymphadenectomy in malignant melanoma*. *Ann Plast Surg*, 1999. **43**(1): p. 1-6.
25. Faries, M.B., et al., *The impact on morbidity and length of stay of early versus delayed complete lymphadenectomy in melanoma: results of the Multicenter Selective Lymphadenectomy Trial (I)*. *Ann Surg Oncol*, 2010. **17**(12): p. 3324-9.
26. Wertz, A.P., et al., *Total versus superficial parotidectomy for stage III melanoma*. *Head Neck*, 2017. **39**(8): p. 1665-1670.

27. *National Comprehensive Cancer Network: Melanoma*. May 29, 2018].
28. Shuman, A.G., J.J. Fins, and M.E. Prince, *Improving end-of-life care for head and neck cancer patients*. *Expert Rev Anticancer Ther*, 2012. **12**(3): p. 335-43.
29. Thom, J.J., et al., *The Role of Total Parotidectomy for Metastatic Cutaneous Squamous Cell Carcinoma and Malignant Melanoma*. *JAMA Otolaryngol Head Neck Surg*, 2014. **140**(6): p. 548-54.
30. Morton, D.L., et al., *Sentinel-node biopsy or nodal observation in melanoma*. *N Engl J Med*, 2006. **355**(13): p. 1307-17.
31. Coit, D., *The Enigma of Regional Lymph Nodes in Melanoma*. *N Engl J Med*, 2017. **376**(23): p. 2280-2281.
32. Sarnaik, A.A., J.S. Zager, and V.K. Sondak, *Point: Surgical Management of Lymph Node Basin in Sentinel Lymph Node-Positive Melanoma*. *Oncology (Williston Park)*, 2016. **30**(10): p. 891-2, 895.
33. O'Brien, C.J., et al., *Prediction of potential metastatic sites in cutaneous head and neck melanoma using lymphoscintigraphy*. *Am J Surg*, 1995. **170**(5): p. 461-6.
34. Willis, A.I. and J.A. Ridge, *Discordant lymphatic drainage patterns revealed by serial lymphoscintigraphy in cutaneous head and neck malignancies*. *Head Neck*, 2007. **29**(11): p. 979-85.
35. Carlson, G.W., et al., *Regional recurrence after negative sentinel lymph node biopsy for melanoma*. *Ann Surg*, 2008. **248**(3): p. 378-86.
36. Kaveh, A.H., et al., *Aberrant lymphatic drainage and risk for melanoma recurrence after negative sentinel node biopsy in middle-aged and older men*. *Head Neck*, 2016. **38 Suppl 1**: p. E754-60.
37. McMasters, K.M., et al., *Sentinel lymph node biopsy for melanoma: how many radioactive nodes should be removed?* *Ann Surg Oncol*, 2001. **8**(3): p. 192-7.
38. Jensen, J.D., et al., *Can lymphatic drainage of head and neck melanoma be predicted?* *J Surg Oncol*, 2011. **103**(8): p. 751-5.
39. Shpitzer, T., et al., *Sentinel node guided surgery for melanoma in the head and neck region*. *Melanoma Res*, 2004. **14**(4): p. 283-7.
40. Parrett, B.M., et al., *Long-term prognosis and significance of the sentinel lymph node in head and neck melanoma*. *Otolaryngol Head Neck Surg*, 2012. **147**(4): p. 699-706.
41. Hanks, J., Kovatch, KJ,; Ali, SA, Roberts, E, Durham, AB, Smith, JD, Bradford, CR, Malloy, KM, Boonstra, PS, McLean, SA., *Long-Term Outcomes, Prognostic Value, and Accuracy of Sentinel Lymph Node Biopsy in Head and Neck Melanoma*. *Oral Presentation. AAO-HNSF Meeting 2018. Atlanta, GA. October 10 2018*. 2018.
42. Bostick, P., et al., *Intraoperative lymphatic mapping for early-stage melanoma of the head and neck*. *Am J Surg*, 1997. **174**(5): p. 536-9.
43. CJ, F.S.O.B., *Head and Neck Melanoma*, in *Cutaneous Melanoma*, H.A. Balch CM, Sober AJ, Soong SJ, Editor. 1998, Quality Medical Publishing, Inc: St. Louis. p. 163–74.
44. de Bree, E. and R. de Bree, *Implications of the MSLT-1 for sentinel lymph node biopsy in cutaneous head and neck melanoma*. *Oral Oncol*, 2015. **51**(7): p. 629-33.
45. de Rosa, N., et al., *Sentinel node biopsy for head and neck melanoma: a systematic review*. *Otolaryngol Head Neck Surg*, 2011. **145**(3): p. 375-82.

46. Doting, E.H., et al., *Does sentinel lymph node biopsy in cutaneous head and neck melanoma alter disease outcome?* J Surg Oncol, 2006. **93**(7): p. 564-70.
47. Evrard, D., et al., *Sentinel lymph node biopsy in cutaneous head and neck melanoma.* Eur Arch Otorhinolaryngol, 2018. **275**(5): p. 1271-1279.
48. Kelly, J., K. Fogarty, and H.P. Redmond, *A definitive role for sentinel lymph node mapping with biopsy for cutaneous melanoma of the head and neck.* Surgeon, 2009. **7**(6): p. 336-9.
49. Patuzzo, R., et al., *Accuracy and prognostic value of sentinel lymph node biopsy in head and neck melanomas.* J Surg Res, 2014. **187**(2): p. 518-24.
50. Saltman, B.E., et al., *Prognostic implication of sentinel lymph node biopsy in cutaneous head and neck melanoma.* Head Neck, 2010. **32**(12): p. 1686-92.
51. Teltzrow, T., J. Osinga, and V. Schwipper, *Reliability of sentinel lymph-node extirpation as a diagnostic method for malignant melanoma of the head and neck region.* Int J Oral Maxillofac Surg, 2007. **36**(6): p. 481-7.
52. Ollila, D.W., et al., *Parotid region lymphatic mapping and sentinel lymphadenectomy for cutaneous melanoma.* Ann Surg Oncol, 1999. **6**(2): p. 150-4.
53. Fincher, T.R., et al., *Patterns of recurrence after sentinel lymph node biopsy for cutaneous melanoma.* Am J Surg, 2003. **186**(6): p. 675-81.
54. Estourgie, S.H., et al., *Review and evaluation of sentinel node procedures in 250 melanoma patients with a median follow-up of 6 years.* Ann Surg Oncol, 2003. **10**(6): p. 681-8.
55. Vuylsteke, R.J., et al., *Clinical outcome of stage I/II melanoma patients after selective sentinel lymph node dissection: long-term follow-up results.* J Clin Oncol, 2003. **21**(6): p. 1057-65.
56. Yee, V.S., et al., *Outcome in 846 cutaneous melanoma patients from a single center after a negative sentinel node biopsy.* Ann Surg Oncol, 2005. **12**(6): p. 429-39.
57. Leong, S.P., et al., *Clinical significance of occult metastatic melanoma in sentinel lymph nodes and other high-risk factors based on long-term follow-up.* World J Surg, 2005. **29**(6): p. 683-91.
58. Nowecki, Z.I., et al., *Survival analysis and clinicopathological factors associated with false-negative sentinel lymph node biopsy findings in patients with cutaneous melanoma.* Ann Surg Oncol, 2006. **13**(12): p. 1655-63.
59. Cascinelli, N., et al., *Sentinel and nonsentinel node status in stage IB and II melanoma patients: two-step prognostic indicators of survival.* J Clin Oncol, 2006. **24**(27): p. 4464-71.
60. Kettlewell, S., et al., *Value of sentinel node status as a prognostic factor in melanoma: prospective observational study.* Bmj, 2006. **332**(7555): p. 1423.
61. Corrigan, M.A., et al., *Sentinel lymph node biopsy: is it possible to reduce false negative rates by excluding patients with nodular melanoma?* Surgeon, 2006. **4**(3): p. 153-7.
62. Emery, R.E., et al., *Sentinel node staging of primary melanoma by the "10% rule": pathology and clinical outcomes.* Am J Surg, 2007. **193**(5): p. 618-22; discussion 622.
63. Riber-Hansen, R., et al., *Quantitative real-time RT-PCR in sentinel lymph nodes from melanoma patients. Detection of melanocytic mRNA predicts disease-free survival.* Apmis, 2008. **116**(3): p. 199-205.
64. Testori, A., et al., *Clinical considerations on sentinel node biopsy in melanoma from an Italian multicentric study on 1,313 patients (SOLISM-IMI).* Ann Surg Oncol, 2009. **16**(7): p. 2018-27.

65. Scoggins, C.R., et al., *Factors associated with false-negative sentinel lymph node biopsy in melanoma patients*. *Ann Surg Oncol*, 2010. **17**(3): p. 709-17.
66. Veenstra, H.J., et al., *Less false-negative sentinel node procedures in melanoma patients with experience and proper collaboration*. *J Surg Oncol*, 2011. **104**(5): p. 454-7.
67. Jones, E.L., et al., *Long-term follow-up and survival of patients following a recurrence of melanoma after a negative sentinel lymph node biopsy result*. *JAMA Surg*, 2013. **148**(5): p. 456-61.
68. Stoffels, I., et al., *Association between sentinel lymph node excision with or without preoperative SPECT/CT and metastatic node detection and disease-free survival in melanoma*. *Jama*, 2012. **308**(10): p. 1007-14.
69. Doepker, M.P., et al., *Comparison of Single-Photon Emission Computed Tomography-Computed Tomography (SPECT/CT) and Conventional Planar Lymphoscintigraphy for Sentinel Node Localization in Patients with Cutaneous Malignancies*. *Ann Surg Oncol*, 2017. **24**(2): p. 355-361.
70. Trinh, B.B., et al., *SPECT/CT Adds Distinct Lymph Node Basins and Influences Radiologic Findings and Surgical Approach for Sentinel Lymph Node Biopsy in Head and Neck Melanoma*. *Ann Surg Oncol*, 2018. **25**(6): p. 1716-1722.
71. Rosko, A.J., et al., *Contemporary Management of Early-Stage Melanoma: A Systematic Review*. *JAMA Facial Plast Surg*, 2017. **19**(3): p. 232-238.
72. Bron, L.P., et al., *Primary and metastatic cancer of the parotid: comparison of clinical behavior in 232 cases*. *Laryngoscope*, 2003. **113**(6): p. 1070-5.
73. Schadendorf, D., et al., *Melanoma*. *Lancet*, 2018. **392**(10151): p. 971-984.
74. Kandel, M., et al., *Update of survival and cost of metastatic melanoma with new drugs: Estimations from the MelBase cohort*. *Eur J Cancer*, 2018. **105**: p. 33-40.
75. Polkowska, M., et al., *Efficacy and safety of BRAF inhibitors and anti-CTLA4 antibody in melanoma patients-real-world data*. *Eur J Clin Pharmacol*, 2018.
76. Smith, M.J.F., et al., *The impact of effective systemic therapies on surgery for stage IV melanoma*. *Eur J Cancer*, 2018. **103**: p. 24-31.
77. Carreau, N.A. and A.C. Pavlick, *Nivolumab and ipilimumab: immunotherapy for treatment of malignant melanoma*. *Future Oncol*, 2018.
78. Long, G.V., et al., *Adjuvant Dabrafenib plus Trametinib in Stage III BRAF-Mutated Melanoma*. *N Engl J Med*, 2017. **377**(19): p. 1813-1823.
79. Eggermont, A.M., et al., *Prolonged Survival in Stage III Melanoma with Ipilimumab Adjuvant Therapy*. *N Engl J Med*, 2016. **375**(19): p. 1845-1855.
80. Eggermont, A.M.M., et al., *Adjuvant Pembrolizumab versus Placebo in Resected Stage III Melanoma*. *N Engl J Med*, 2018. **378**(19): p. 1789-1801.
81. Weber, J., et al., *Adjuvant Nivolumab versus Ipilimumab in Resected Stage III or IV Melanoma*. *N Engl J Med*, 2017. **377**(19): p. 1824-1835.
82. Linardou, H. and H. Gogas, *Toxicity management of immunotherapy for patients with metastatic melanoma*. *Ann Transl Med*, 2016. **4**(14): p. 272.

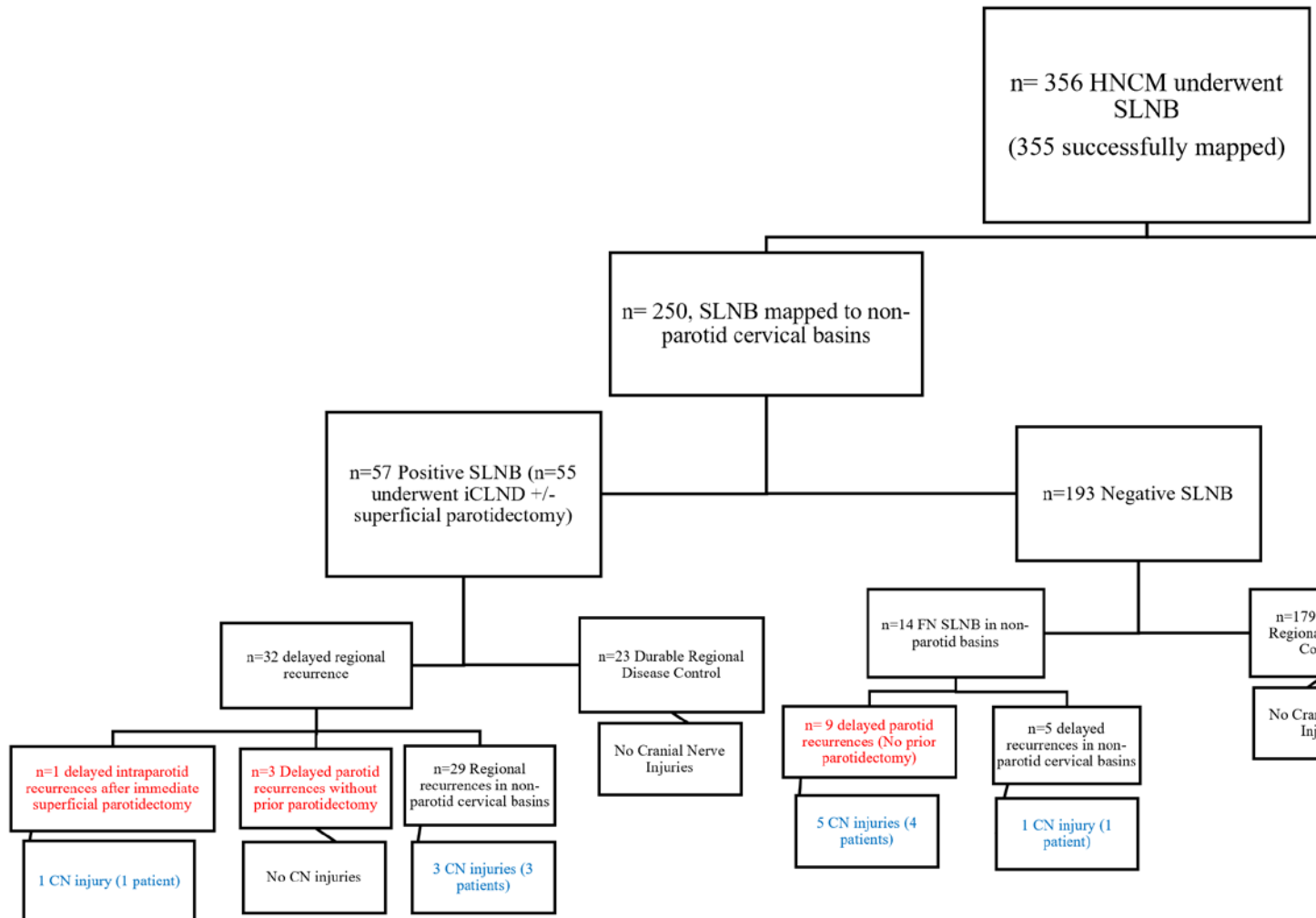
Figure Legends:

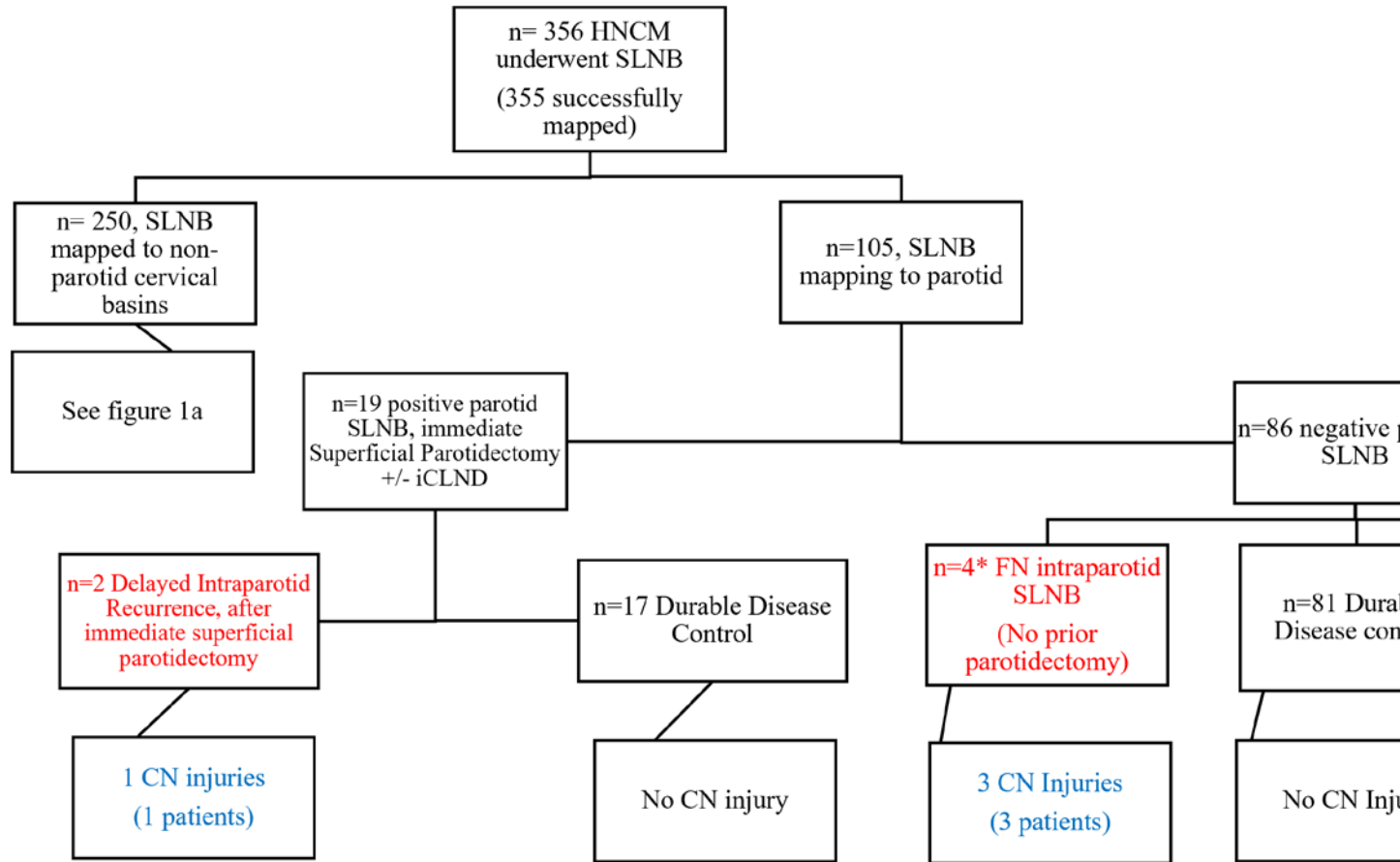
Figure 1A and 1B. Study population flow diagrams sorted by SLNB mapping to parotid or non-parotid cervical basins, SLNB result, presence and location of regional recurrence if applicable, and presence of CN injury if applicable. Intraparotid recurrences are denoted by red text, and CN injuries are denoted by blue text. Key: HNCM, head and neck cutaneous melanoma; SLNB, sentinel lymph node biopsy; iCLND, immediate completion lymph node dissection; CN, cranial nerve; FN, False Negative.

Figure 2: Head and Neck Melanoma Primary Sites with Sentinel Node Mapping to Parotid

Table 1: Summary of permanent cranial neuropathies following regional HNCM recurrence

Figure 1A and 1B. Study population flow diagrams sorted by SLNB mapping to parotid or non-parotid cervical basins, SLNB result, presence and location of regional recurrence if applicable, and presence of CN injury if applicable. Intraparotid recurrences are denoted by red text, and CN injuries are denoted by blue text. Key: HNCM, head and neck cutaneous melanoma; SLNB, sentinel lymph node biopsy; iCLND, immediate completion lymph node dissection; CN, cranial nerve; FN, False Negative.





Head and Neck Melanoma Primary Sites with Sentinel Node Mapping to Parotid

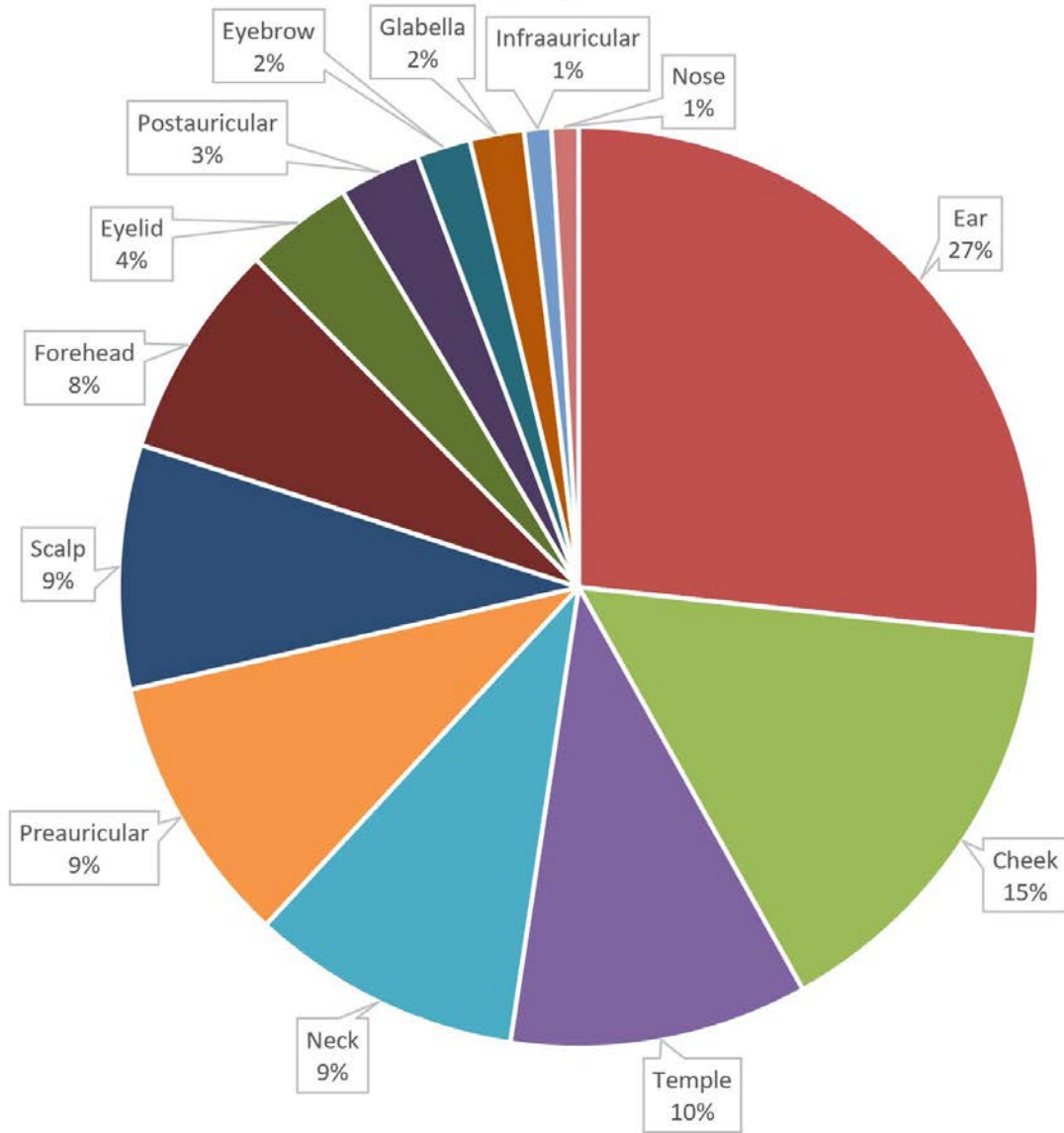


Table 1: Summary of permanent cranial neuropathies following regional HNCCM recurrence

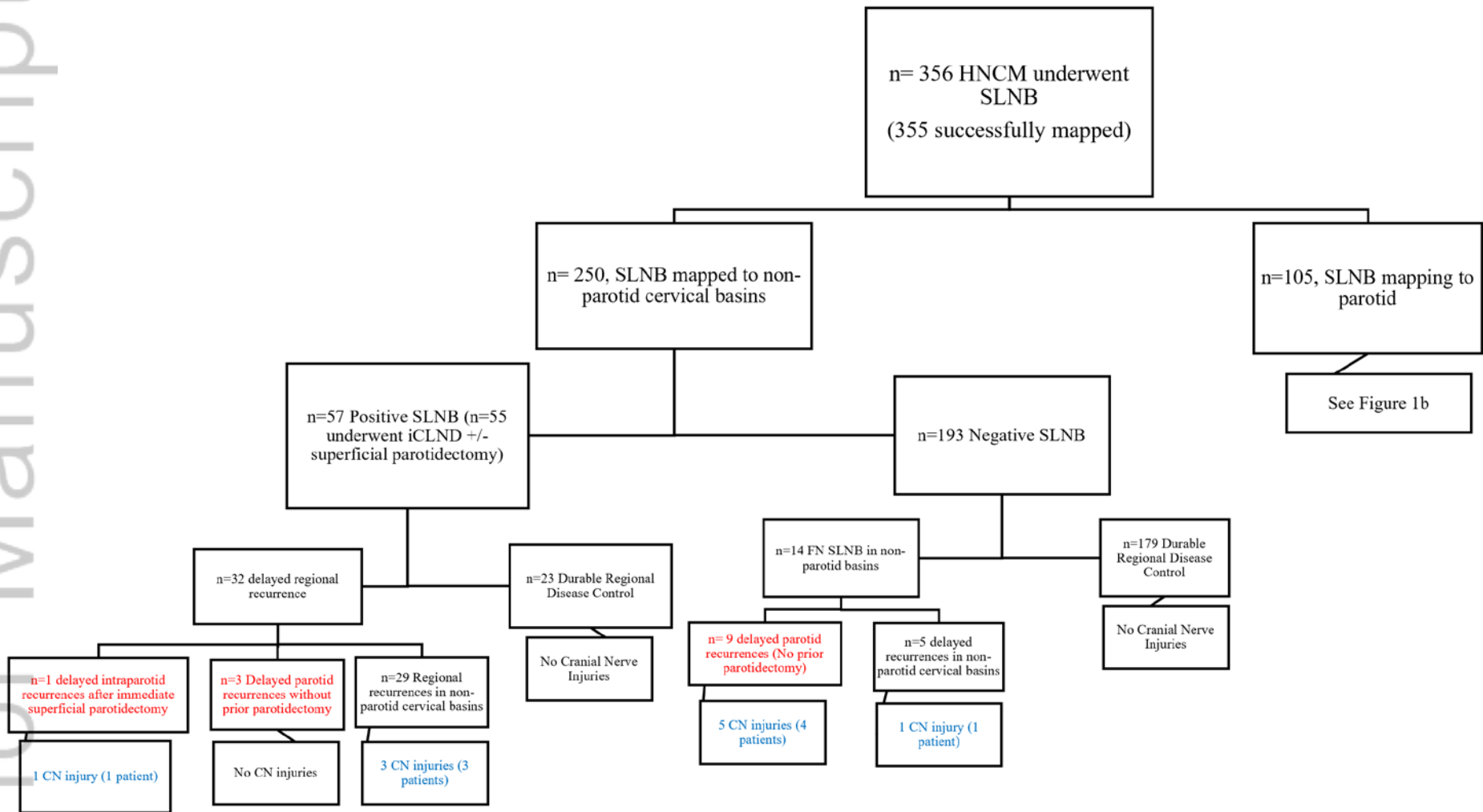
Patient	Primary Site	Breslow (mm)	SLNB (Cervical Basins, + positive)	iCLND (Cervical Basins)	NSLN (+ positive)	First Regional Recurrence	Salvage Dissection (Cervical Basins)	Cranial Nerve Injury	Facial Nerve Branches Affected	Paresis vs Paralysis/Etiology (CN Affected)
1	Scalp	2.95	Right Neck	None	None	Right Parotid	Right Parotidectomy, Right I-V	VII, XI	Marginal Mandibular Branch	Paresis from Salvage Dissection (VII), Paralysis from Surgical Sacrifice (CN XI and SCM)
2	Left Postauricular	5	Left Occipital, Left Jugulodigastric	None	None	Left Postauricular, Left Parotid Tail	Left Parotidectomy, Left I-V	VII, XI	Marginal Mandibular Branch	Paresis from Salvage Dissection (VII and XI)

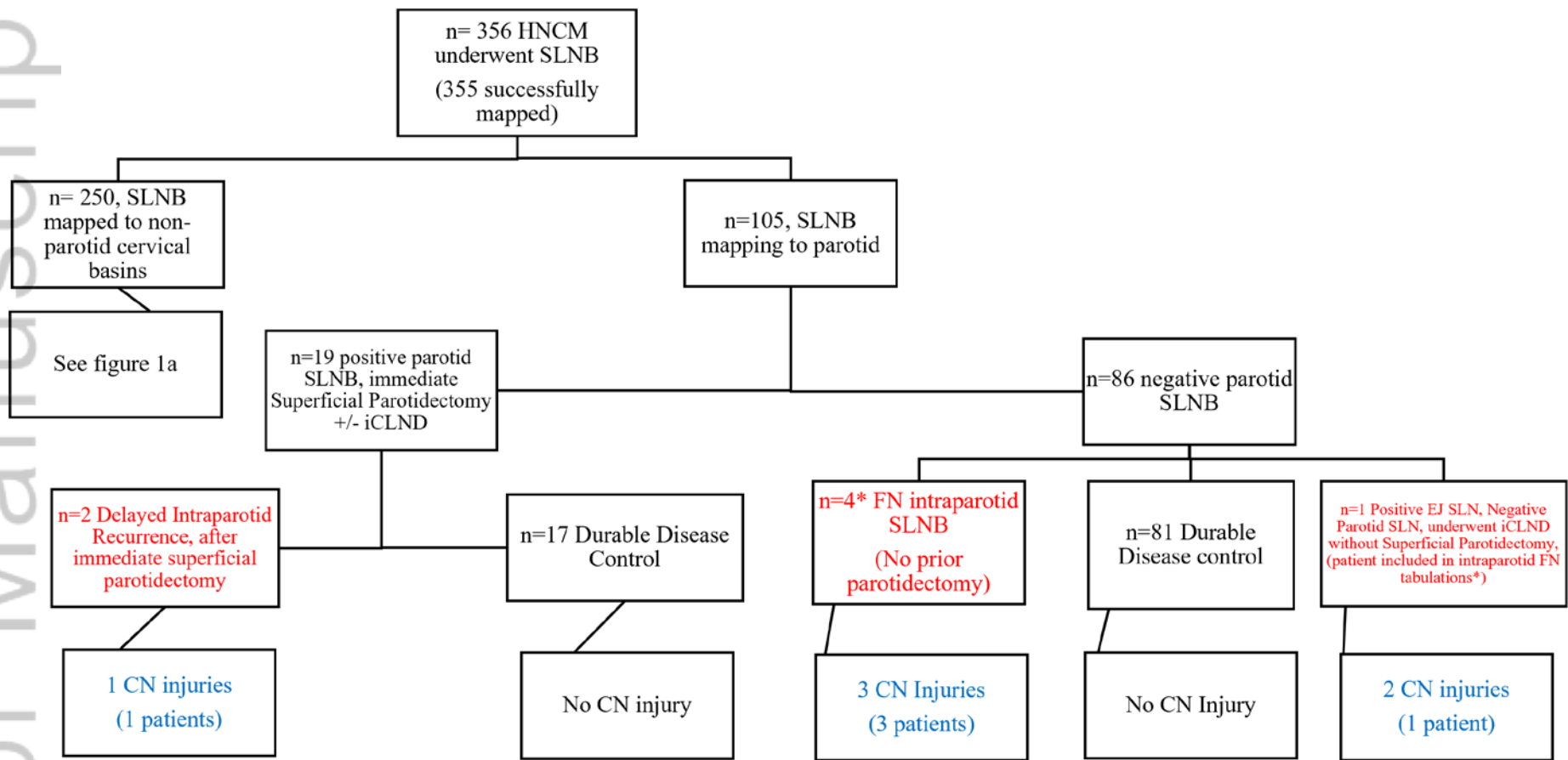
3	Left Conchal Bowl	1.7	Left External Jugular(+), Left Parotid Tail	Left I-V	Left III(+), IV(+)	Multiple Satellite Metastases, Cartilaginous External Auditory Canal	Left Auriculectomy, Left Lateral Temporal Bone Resection, Left Total Parotidectomy, Left Suboccipital Dissection	VII, XII	Marginal Mandibular Branch	Paresis from Salvage Dissection (VII and XII)
4	Right Parietal Scalp	2.1	Right Postauricular (+), Right Preauricular (+), Right External Jugular	Right Superficial Parotidectomy, Right I-V	Right V(+)	Right Parotid	Right Parotidectomy	VII	All Branches	Paralysis from Tumor Invasion (VII)
5	Right Preauricular	1.95	Right Parotid	None	None	Right Parotid Tail	Right Parotidectomy	VII	All Branches	Paralysis from Tumor Invasion/Surgical Sacrifice (VII)
6	Right Inferior Ear	1.8	Right Parotid (+)	Right Superficial Parotidectomy, Right I-V	Right Superficial Parotid (+)	Right Neck	Radical Resection Only	VII	All Branches	Paresis from Tumor Invasion (VII)

7	Right Temporal Scalp	1.84	Right Level II (+), V (+)	Right Levels I-V	None	Right Preauricular, Right Postauricular, Right Mandibular Border	Right Parotidectomy, Lateral Temporal Bone Resection, CN VII Sacrifice	VII	Upper Division	Upper Division Paralysis from Tumor Invasion/Surgical Sacrifice, Grafted intraoperatively (VII)
8	Left Neck	3.25	Left Level III	None	None	Left Parotid	Left Parotidectomy, Left I-VI	VII	Marginal Mandibular Branch	Paresis from Salvage Dissection (VII)
9	Left Ear	1.74	Left Parotid	None	None	Left Postauricular	Left Parotidectomy, Modified Radical Neck Dissection	VII	Marginal Mandibular Branch	Paresis from Salvage Dissection (VII)
10	Right Forehead	2.15	Right Parotid	None	None	Right Parotid	Right Parotidectomy, Right I-II	VII	Marginal Mandibular Branch	Paresis from Salvage Dissection (VII)
11	Scalp	5	Right Neck (+) and Left Neck (+)	Bilateral Neck	None	Right Superior Neck, Near Right	Right Extended Posterior Neck Dissection	XI	N/A	Paresis from Salvage Dissection (XI)

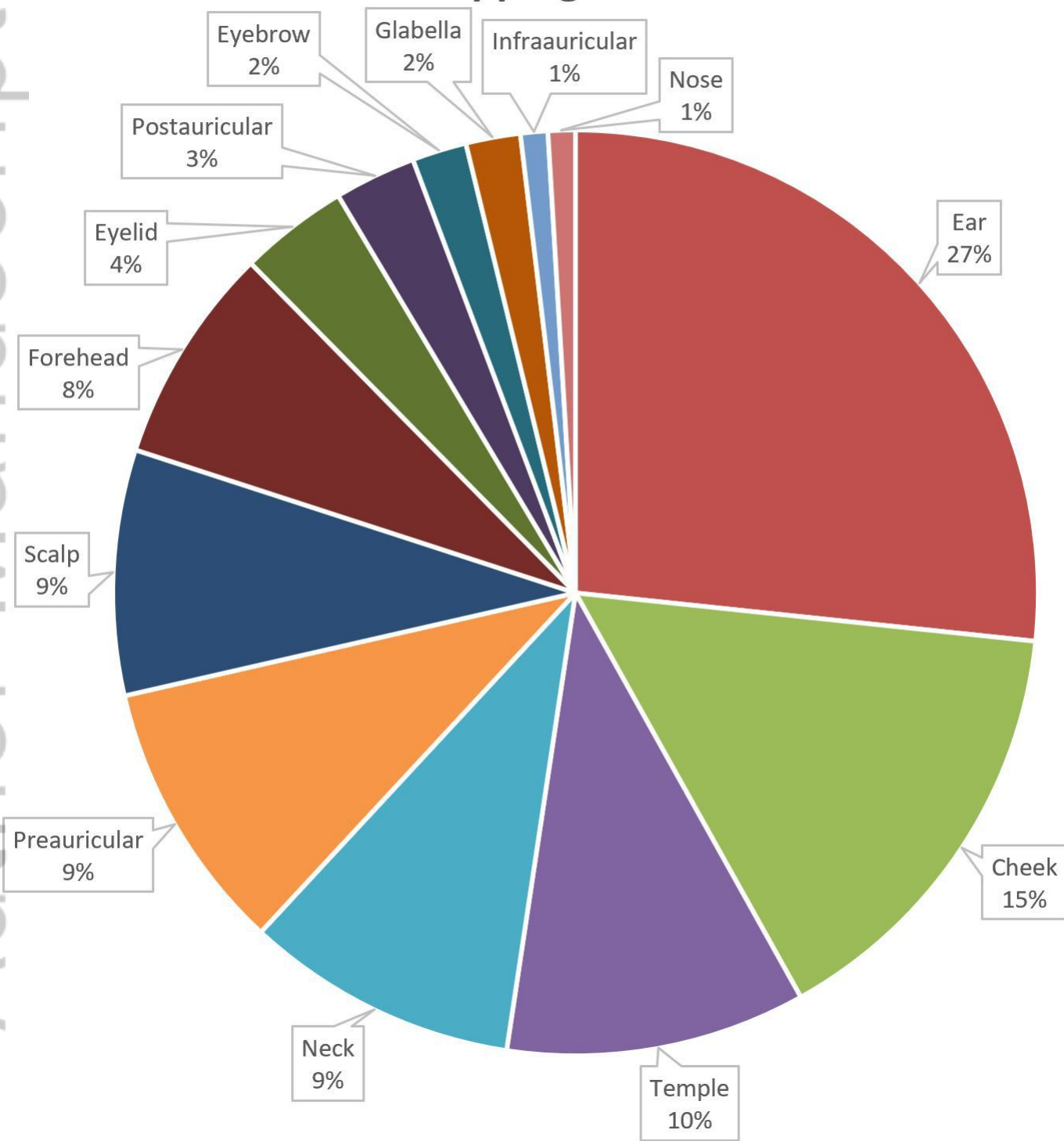
						Trapezius				
12	Left Posterior Neck	1.53	Left Postauricular (+), Left Jugulodigastric (+)	Left Occipital, Left I-V	None	Left External Jugular	Declined	XI	N/A	Paresis from Tumor Invasion (XI)
13	Right Neck	1.17	Right External Jugular	None	None	Right V	Radical Resection Only	XI	N/A	Paresis from Salvage Dissection (XI)

Figure 1A and 1B. Study population flow diagrams sorted by SLNB mapping to parotid or non-parotid cervical basins, SLNB result, presence and location of regional recurrence if applicable, and presence of CN injury if applicable. Intraparotid recurrences are denoted by red text, and CN injuries are denoted by blue text. Key: HNCM, head and neck cutaneous melanoma; SLNB, sentinel lymph node biopsy; iCLND, immediate completion lymph node dissection; CN, cranial nerve; FN, False Negative.





Head and Neck Melanoma Primary Sites with Sentinel Node Mapping to Parotid



LARY_28243_Figure 2.JPG

Table 1: Summary of permanent cranial neuropathies following regional HNCM recurrence

Patient	Primary Site	Breslow (mm)	SLNB (Cervical Basins, + positive)	iCLND (Cervical Basins)	NSLN (+ positive)	First Regional Recurrence	Salvage Dissection (Cervical Basins)	Cranial Nerve Injury	Facial Nerve Branches Affected	Paresis vs Paralysis/Etiology (CN Affected)
1	Scalp	2.95	Right Neck	None	None	Right Parotid	Right Parotidectomy, Right I-V	VII, XI	Marginal Mandibular Branch	Paresis from Salvage Dissection (VII), Paralysis from Surgical Sacrifice (CN XI and SCM)
2	Left Postauricular	5	Left Occipital, Left Jugulodigastric	None	None	Left Postauricular, Left Parotid Tail	Left Parotidectomy, Left I-V	VII, XI	Marginal Mandibular Branch	Paresis from Salvage Dissection (VII and XI)
3	Left Conchal Bowl	1.7	Left External Jugular(+), Left Parotid Tail	Left I-V	Left III(+), IV(+)	Multiple Satellite Metastases, Cartilaginous External Auditory Canal	Left Auriculectomy, Left Lateral Temporal Bone Resection, Left Total Parotidectomy, Left Suboccipital Dissection	VII, XII	Marginal Mandibular Branch	Paresis from Salvage Dissection (VII and XII)

4	Right Parietal Scalp	2.1	Right Postauricular (+), Right Preauricular (+), Right External Jugular	Right Superficial Parotidectomy, Right I-V	Right V(+)	Right Parotid	Right Parotidectomy	VII	All Branches	Paralysis from Tumor Invasion (VII)
5	Right Preauricular	1.95	Right Parotid	None	None	Right Parotid Tail	Right Parotidectomy	VII	All Branches	Paralysis from Tumor Invasion/Surgical Sacrifice (VII)
6	Right Inferior Ear	1.8	Right Parotid (+)	Right Superficial Parotidectomy, Right I-V	Right Superficial Parotid (+)	Right Neck	Radical Resection Only	VII	All Branches	Paresis from Tumor Invasion (VII)
7	Right Temporal Scalp	1.84	Right Level II (+), V (+)	Right Levels I-V	None	Right Preauricular, Right Postauricular, Right Mandibular Border	Right Parotidectomy, Lateral Temporal Bone Resection, CN VII Sacrifice	VII	Upper Division	Upper Division Paralysis from Tumor Invasion/Surgical Sacrifice, Grafted intraoperatively (VII)
8	Left Neck	3.25	Left Level III	None	None	Left Parotid	Left Parotidectomy, Left I-VI	VII	Marginal Mandibular Branch	Paresis from Salvage Dissection (VII)

9	Left Ear	1.74	Left Parotid	None	None	Left Postauricular	Left Parotidectomy, Modified Radical Neck Dissection	VII	Marginal Mandibular Branch	Paresis from Salvage Dissection (VII)
10	Right Forehead	2.15	Right Parotid	None	None	Right Parotid	Right Parotidectomy, Right I-II	VII	Marginal Mandibular Branch	Paresis from Salvage Dissection (VII)
11	Scalp	5	Right Neck (+) and Left Neck (+)	Bilateral Neck	None	Right Superior Neck, Near Right Trapezius	Right Extended Posterior Neck Dissection	XI	N/A	Paresis from Salvage Dissection (XI)
12	Left Posterior Neck	1.53	Left Postauricular (+), Left Jugulodigastric (+)	Left Occipital, Left I-V	None	Left External Jugular	Declined	XI	N/A	Paresis from Tumor Invasion (XI)
13	Right Neck	1.17	Right External Jugular	None	None	Right V	Radical Resection Only	XI	N/A	Paresis from Salvage Dissection (XI)