





SHORT REPORT

Genital verruciform xanthoma: lessons from a contemporary multi-institutional series

Grace Wang,^{1,2,*} Mark C Mochel,^{1,2,*}  M Barry Randall,^{3,4} Jatin S Gandhi,⁴ Aaron M Udager,⁵ May P Chan,⁵  Rajiv M Patel,⁵ Mahul B Amin,⁴ Adeboye O Osunkoya⁶  & Steven C Smith^{1,7} 

¹Department of Pathology, VCU School of Medicine, ²Department of Dermatology, VCU School of Medicine, Richmond, VA, ³Department of Dermatology, University of Tennessee Health Sciences Center, ⁴Department of Pathology and Laboratory Medicine, University of Tennessee Health Sciences Center, Memphis, TN, ⁵Department of Pathology, Michigan Medicine, University of Michigan, Ann Arbor, MI, ⁶Departments of Pathology and Urology, Emory University School of Medicine, Atlanta, GA, and ⁷Division of Urology, Department of Surgery, VCU School of Medicine, Richmond, VA, USA

Date of submission 7 May 2020

Accepted for publication 25 June 2020

Published online Article Accepted 29 June 2020

Wang G, Mochel MC, Randall MB, Gandhi JS, Udager AM, Chan MP, Patel RM, Amin MB, Osunkoya AO & Smith SC. (2020) *Histopathology* 77, 841–846. <https://doi.org/10.1111/his.14198>

Genital verruciform xanthoma: lessons from a contemporary multi-institutional series

Aims: Verruciform xanthoma (VX) is an uncommon lesion, seen in the oral mucosa and rarely occurring at cutaneous genital sites. Reports of exceptional VX presentations dominate the literature; herein, we assess the clinical and histological features of a cohort of routine, consecutive cases.

Methods and results: Clinicopathological features of genital VXs from four academic centres were reviewed. A cohort of 25 lesions from 24 patients (22 male, two female; median age = 62 years), occurred on the scrotum (84%), penis (8%) and perineum/vulva (8%). VX was never suspected clinically; considerations ranged from fibroepithelial polyps to squamous cell carcinoma. Classic diagnostic criteria were

present at least focally in each lesion, including verrucous architecture, prominent wedge-shaped parakeratosis extending between exophytic epidermal projections and neutrophils in the stratum corneum. Xanthomatous cells were present in all cases, but scattered to rare in 24%.

Conclusions: Consecutive genital VXs reliably exhibited classic histopathological features, although the essential finding of xanthomatous cells may be scarce. Our comparison to meta-analyses of published cases found relatively fewer penile and vulvar examples. Additionally, the median age was older than in published series, which have emphasised syndromic associations.

Keywords: Verruciform xanthoma, xanthoma, genital skin, xanthoma

Introduction

Verruciform xanthoma (VX) is an uncommon, benign mucocutaneous lesion that most commonly affects

the oral mucosa of middle-aged adults.¹ The classic histopathology of VX consists of a verrucous squamous proliferation, with compact parakeratosis and foamy macrophages within the dermal papillae, as reviewed recently.² Beyond the oral cavity, VX also occurs on the extremities, anal and genital sites.³ Due to the rarity of VX in the anogenital region, VX may be misclassified as one of the more commonly encountered warty lesions in this area, particularly

Address for correspondence: S C Smith, Director of Genitourinary Pathology, VCU School of Medicine, 1200 East Marshall Street, PO Box 980622, Richmond, VA 23298, USA.

e-mail: steven.c.smith@vcuhealth.org

^aCo-first authors.

condyloma acuminatum, or for larger lesions, verrucous carcinoma and other variants of squamous cell carcinoma. Case reports of unusual VX presentations, pitfalls and rare syndromic associations (as well as meta-analyses thereof) dominate the literature, such that from the standpoint of prospective routine diagnosis the spectrum of expected clinical and histological features are uncertain. Herein, reviewing the experience of multiple centres with contemporary consecutive cases, we provide a clinicopathological reappraisal of 25 VXs, detailing histopathological features including some not previously emphasised, and correlating our findings with a recent comprehensive meta-analysis³ of the published literature.

Methods

After Institutional Review Board approval at each institution, clinicopathological features of VXs of genital sites from four academic centres were identified and reviewed retrospectively. Clinical information was collected from the medical record, including demographics (ages greater than 89 years deidentified as ≥ 89 years), lesion location, size, co-existing dyslipidaemias, genital dermatitides and systemic conditions. Each case was reviewed by both genitourinary pathology and dermatopathology subspecialists to confirm the diagnosis and qualitatively evaluate a series of histopathological features. These features included low magnification architecture, presence and configuration of parakeratosis, presence of intra-corneal neutrophils, presence of surface organisms, degree and type of lichenoid and dermal inflammation and relative quantity of xanthomatous macrophages. If evaluable, the adjacent skin was assessed for the presence of concomitant pathologies. Whole-slide imaging was performed (Leica/Aperio AT2 and Hamamatsu NanoZoomer), with white balance, contrast adjustment and white space histological artefacts removed (spot tools, Adobe Photoshop CS3) from non-lesional areas to provide clear low-power images.

Results

A total of 25 VXs of genital sites from 24 patients (22 male, two female) were identified and reviewed. Median age was 62 years (range = 37 to ≥ 89 years), with lesions located most frequently on the scrotum (21; 84%) compared to the penis or perineum/vulva (two each; 8%). The usually (23 of 24; 96%) solitary lesions ranged in size from 0.2 to 2.5 cm, with a

median greatest dimension of 0.6 cm. Clinical considerations documented ranged from wart to benign vascular lesions, fibroepithelial polyps, seborrheic keratoses and squamous cell carcinomas. A specific, co-existing genital dermatitis was documented with one specimen, that of mild radiation dermatitis from radiotherapy for penile squamous cell carcinoma; history of eczema, tinea cruris and xerosis was documented in three additional cases). In no case was any syndromal dyslipidaemia documented, and in no case was the VX submitted with concern for cutaneous manifestation of systemic dyslipidaemia. Clinical features, including incidental comorbidities, are detailed in Table S1.

Architecturally, VXs exhibited variable exophytic verrucous architecture (Figure 1), correlating with a frequent clinical impression of a papule (Figure 2A). Histologically, prominent wedge-shaped parakeratosis, extension of compact eosinophilic keratotic scale between epidermal projections and neutrophils in the stratum corneum were present in all cases (Figure 2B,C); neutrophils were abundant in 88% and focal in 12%. Surface and intracorneal bacterial organisms were identified in 24 (96%), albeit only focally in 32% (Figure 2D). Xanthomatous macrophages were abundant in 19 cases (76%), scattered in four cases (16%) and scarce in two cases (8%) (Figure 2E,F). While mild perivascular lymphoplasmacytic inflammation was present in all cases, a lichenoid arrangement of inflammatory cells was present in eight (32%). Significant keratinocyte atypia was absent, with the exception of mild atypia in one case; koilocytosis was absent in all cases.

Discussion

Verruciform xanthoma (VX) is a benign squamous proliferation that presents clinically as a well-circumscribed white, yellow or erythematous papule or plaque with a verrucous surface and a flat or pedunculated base.^{3,4} Lesions arising in the oral cavity are most common, and have been described in significant numbers in some series.^{4,5} However, an infrequent subset arises at cutaneous sites,⁶ often involving the genitals,⁷ where they can pose diagnostic challenges clinically as well as histopathologically.

The definitive pathogenetic mechanism for VX remains unknown. While subsets of cases have been loosely associated with dermatological and systemic conditions in male patients, there appears to be a stronger association with lichenoid dermatitides in female patients,⁸ a setting in which eight of 10

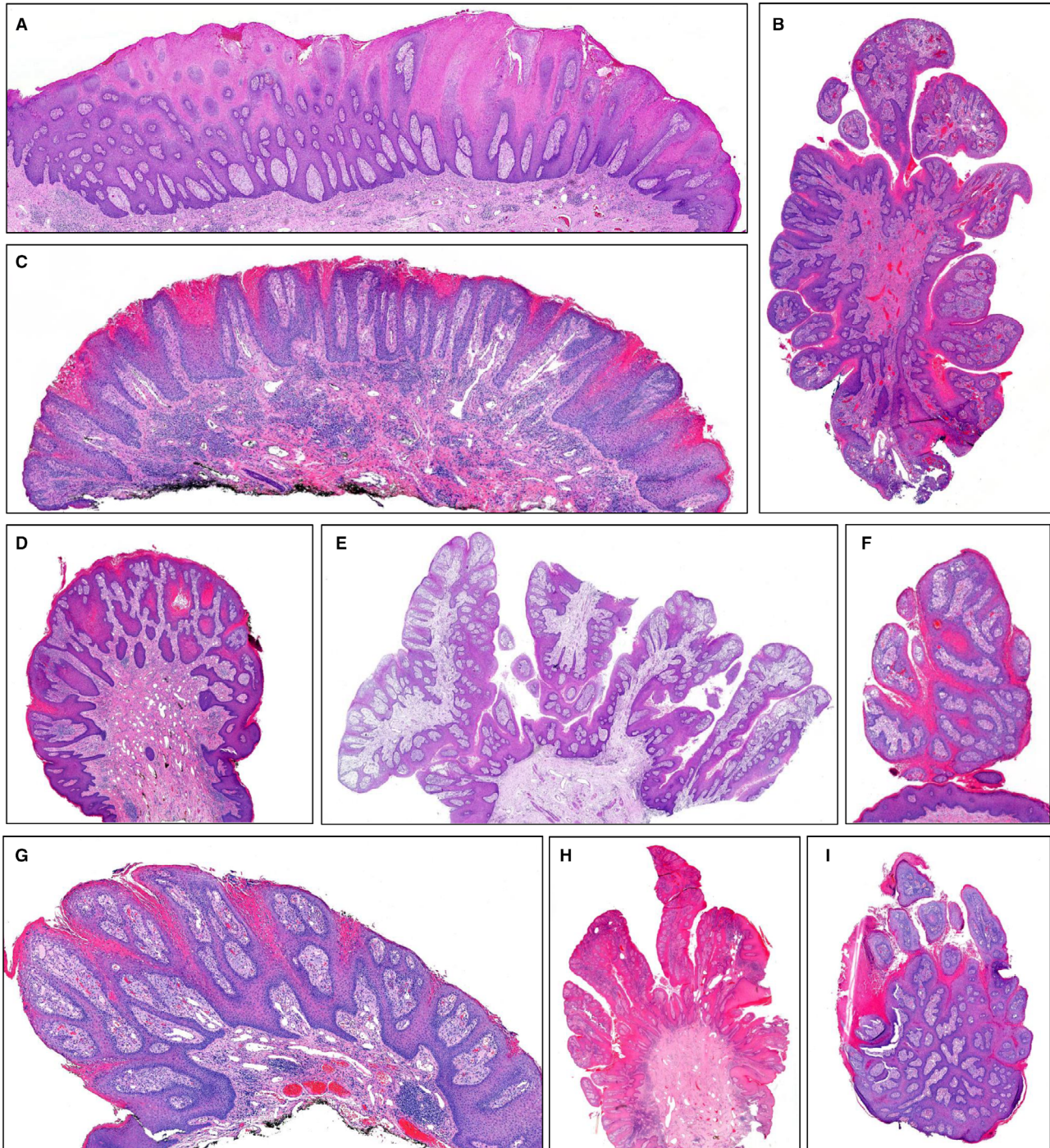


Figure 1. At low power, all verruciform xanthoma (VX) cases encountered were exophytic, with varying degrees of plaque-like, to frondular/papillary, to pedunculated growth. Those depicted include (A) 2.1-cm vulvar lesion from a 77-year-old; (B) 1.3-cm left anterior scrotal lesion from a 71-year-old; (C) 0.6-cm right scrotal lesion from a ≥ 89 -year-old; (D) 0.5-cm left scrotal lesion from a 67-year-old; (E) 1.8-cm scrotal lesion of an 86-year-old; (F) 0.5-cm right scrotal lesion of a 68-year-old; (G) 0.6-cm right scrotal lesion of a 78-year-old; (H) 1.6-cm right scrotal lesion of a 79-year-old; (I) 0.6-cm right lateral scrotal lesion of a 62-year-old. [Colour figure can be viewed at wileyonlinelibrary.com]

vulvar VXs were associated with lichen sclerosus et atrophicus or lichen planus in one study.⁹ Although HPV infection has been detected and postulated to be

the aetiological agent,^{10,11} HPV detection is infrequent,^{7,12} and has been interpreted overall as superinfection² with a prevalent human pathogen.

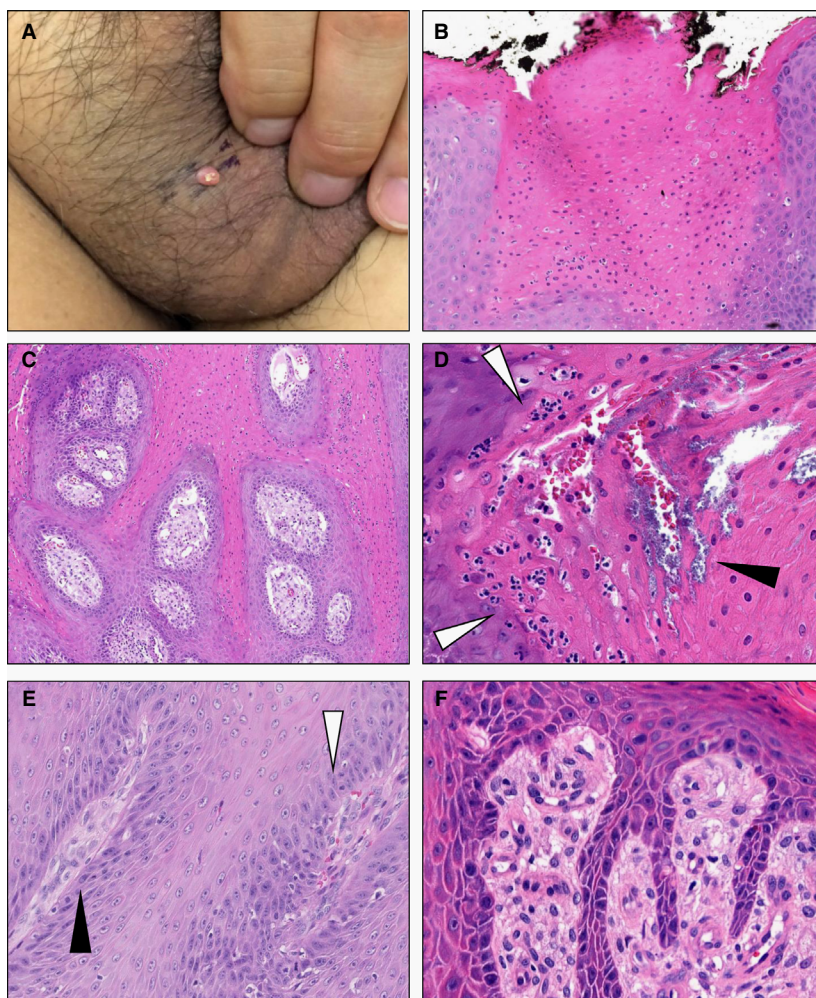


Figure 2. Clinically, verruciform xanthoma (VX) cases presented most frequently as small scrotal papules, with variable scale crust (A). Key histological features present in all cases included parakeratosis, often prominent and wedge-shaped (B), extending inward between papillary projections (C). Within parakeratosis (D), neutrophils were present in all cases (open arrowheads), with superficial bacterial colonies present in nearly all cases (black arrowhead). A subset of cases (24%) showed scattered or scarce xanthoma cells (E), often alternately present in the stroma of some (black arrowhead) but not all (open arrowhead) dermal papillae. Most cases, however, showed readily identified xanthoma cells filling the papillary dermis (F). [Colour figure can be viewed at wileyonlinelibrary.com]

Bacterial colonisation has been described, particularly among lesions of the oral cavity,^{7,13,14} with multiple bacterial types detected.¹⁵ To the authors' knowledge, this histological feature has not been previously studied in large numbers of cutaneous VXs or observed in small series,⁷ prior to our multi-institutional contemporary review. We have interpreted the presence of superficial bacteria as colonisation secondary to altered barrier function; however, we must note that chronic bacterial infections are associated with a number of xanthomatous/xanthogranulomatous lesions in the genitourinary area (e.g. malakoplakia), such that further study is needed. Overall, for VX, most authors favour a chronic inflammatory aetiology, involving keratinocyte damage, neutrophilic infiltration, and induction of proliferation into a verrucoid lesion, with reactive xanthomatous accumulation in the papillary dermis.^{3,7,16}

While case reports and meta-analyses thereof have constituted much of the literature concerning VX,

our study represents the largest multi-institutional, retrospective study of consecutive cases of sporadic VXs. An excellent, recent, comprehensive review of published genital VXs by Stiff *et al.*³ provides a resource for comparison with our findings. We found that the overwhelming majority of VXs (92%) occur in males, which is close to the proportion documented (85%) by Stiff *et al.* Our experience suggests that in terms of sites, published case reports have somewhat over-represented (although not statistically significantly; $P > 0.3$) the less prevalent penile (8% versus 16%) and vulvar cases (8% versus 14%), compared to the most common site of the scrotum. While cases with inverted, endophytic or cystic features have been described,^{3,7,17–19} all those we encountered were polypoid and exophytic.

The main difference, however, between our series and those reported previously, pertains to the median age, which was 51 years in the cases presented by Stiff *et al.* compared to our 62 years ($P < 0.01$,

U-test). This difference relates, at least in significant part, to the emphasis in the published literature of the association of VX with congenital hemidysplasia with ichthyosiform nevus and limb defects (CHILD) syndrome,^{20–22} a genetic disease that almost exclusively manifests in females due to its X-linked dominant mode of inheritance and lethality in males. In patients with CHILD syndrome, VXs appear as multiple papules or nodules arranged in linear streaks with midline demarcation.²³ Of particular note, mutations involving the gene encoding NSDHL (NADP dependent steroid dehydrogenase-like) have been identified not only in CHILD syndrome, but also reported in a subset of apparently sporadic VXs.²⁴

Beyond comparing reported versus consecutive clinical features, we also endeavoured to assess the prevalence and reliability of the classic diagnostic criteria in an unselected consecutive cohort from diverse institutions. We note that, in our series, the entity of VX, given its rarity, was not documented in the clinical differential diagnosis of any of our cases, emphasising the key role of histopathology in its recognition and diagnosis. In this regard, our focus on histopathological features can provide some guidance. We would particularly emphasise the low magnification configurations of these lesions which, in our opinion, have not been well depicted or in significant numbers in prior case reports and small series. Examples ranged from broad, plaque-like configurations, whether of coalescent papillae or widened rete (Figure 1A,C, respectively), to more polypoid papular proliferations (Figure 1D,F,G) to lesions with discrete frond-like papillae (Figure 1B,E,H) overlying ectatic basal vessels and variable chronic inflammation. However variable the lesional silhouette, the higher-magnification histopathological features of VX (Figure 2) were quite consistent and reliable among all demographics, regardless of gender, age of onset and anatomical site. VX frequently displays wedge-shaped, dense parakeratosis with an orange hue which commonly extends to fill the space between the epidermal papillomatous fronds. Additionally, the neutrophilic infiltrate in the parakeratotic stratum corneum represents a uniform characteristic feature, which is generally abundant and nearly always associated with bacterial colonies, at least focally. Consistent with anecdotal experience and prior teaching² that diagnostic xanthomatous macrophages may be infrequent or scarce, we observed they were only scattered or scarce in 24% of VXs, necessitating recognition of ancillary features to prompt careful inspection for these cells. Interestingly, a subset (32%) of our cohort demonstrated lichenoid inflammation, which was

characteristically mild. No clear association with a specific dermatological or systemic comorbidity was identified, although not unexpectedly, given the older age range of this cohort, many comorbidities were documented upon chart review. Nonetheless, we stipulate that one limitation of the series is that all cases studied were identified initially by searches for unequivocal diagnosis of VX, such that morphological outliers or atypical/equivocal lesions would not have been included.

In summary, our experience suggests that beyond unusual case reports and published pitfalls, in routine practice genital VX is predominantly a solitary lesion of the scrotum of middle-aged to older men. Classical features, including the lack of significant cytological atypia and koilocytosis, the abundance of neutrophils within the stratum corneum and the usually prominent, even wedge-shaped parakeratosis between epidermal projections, are consistent characteristic findings in VX. These, in conjunction with xanthoma cells (which may be subtle) in the dermal papillae, should be helpful in distinguishing VX from its malignant and premalignant mimics.

Acknowledgments

MCM, MBA, and SCS designed the study. MCM, GW, and SCS wrote the paper. MCM, GW, MBR, JSG, AMU, MPC, RMP, MBA, AOO, and SCS performed the research, collected and/or analysed data, and edited and approve the manuscript.

Conflict of interest

The authors report that there are no conflicts of interest regarding this work.

References

1. Hegde U, Doddawad VG, Sreeshyla H *et al.* Verruciform xanthoma: a view on the concepts of its etiopathogenesis. *J. Oral Maxillofac. Pathol.* 2013; 17: 392–396.
2. Chan MP. Verruciform and condyloma-like squamous proliferations in the anogenital region. *Arch. Pathol. Lab. Med.* 2019; 143: 821–831.
3. Stiff KM, Cohen PR. Vegas (verruciform genital-associated) xanthoma: a comprehensive literature review. *Dermatol. Ther.* 2017; 7: 65–79.
4. Belknap AN, Islam MN, Bhattacharyya I *et al.* Oral verruciform xanthoma: a series of 212 cases and review of the literature. *Head Neck Pathol.* 2020; 14(3): 742–748.
5. Philipsen HP, Reichart PA, Takata T *et al.* Verruciform xanthoma – biological profile of 282 oral lesions based on a literature survey with nine new cases from Japan. *Oral Oncol.* 2003; 39: 325–336.

6. Al-Nafussi AI, Azzopardi JG, Salm R. Verruciform xanthoma of the skin. *Histopathology* 1985; **9**: 245–252.
7. Mohsin SK, Lee MW, Amin MB et al. Cutaneous verruciform xanthoma: a report of five cases investigating the etiology and nature of xanthomatous cells. *Am. J. Surg. Pathol.* 1998; **22**: 479–487.
8. Santa Cruz DJ, Martin SA. Verruciform xanthoma of the vulva. Report of two cases. *Am. J. Clin. Pathol.* 1979; **71**: 224–228.
9. Fite C, Plantier F, Dupin N et al. Vulvar verruciform xanthoma: ten cases associated with lichen sclerosus, lichen planus, or other conditions. *Arch. Dermatol.* 2011; **147**: 1087–1092.
10. Khaskheli NM, Uezato H, Kamiyama T et al. Association of human papillomavirus type 6 with a verruciform xanthoma. *Am. J. Dermatopathol.* 2000; **22**: 447–452.
11. Iamaroon A, Vickers RA. Characterization of verruciform xanthoma by in situ hybridization and immunohistochemistry. *J. Oral Pathol. Med.* 1996; **25**: 395–400.
12. Erşahin C, Szpadarska AM, Foreman K et al. Verruciform xanthoma of the penis not associated with human papillomavirus infection. *Arch. Pathol. Lab. Med.* 2005; **129**: e62–e64.
13. Zegarelli DJ, Zegarelli-Schmidt EC, Zegarelli EV. Verruciform xanthoma. A clinical, light microscopic, and electron microscopic study of two cases. *Oral Surg. Oral Med. Oral Pathol.* 1974; **38**: 725–734.
14. Shafer WG. Verruciform xanthoma. *Oral Surg. Oral Med. Oral Pathol.* 1971; **31**: 784–789.
15. Palestine RF, Winkelmann RK. Verruciform xanthoma in an epithelial nevus. *Arch. Dermatol.* 1982; **118**: 686–691.
16. Cumberland L, Dana A, Resh B et al. Verruciform xanthoma in the setting of cutaneous trauma and chronic inflammation: report of a patient and a brief review of the literature. *J. Cutan. Pathol.* 2010; **37**: 895–900.
17. Poblet E, McCaden ME, Santa Cruz DJ. Cystic verruciform xanthoma. *J. Am. Acad. Dermatol.* 1991; **25**: 330–331.
18. Hara M, Kato Y, Kaku Y et al. Verruciform xanthoma accompanying a cystic growth: a case report. *J. Cutan. Pathol.* 2020; **47**(5): 475–478.
19. Lomas-García J, Miguélez-Simón A, Cuesta A et al. Cystic verruciform xanthoma of the breast: an undescribed location of an uncommon lesion. *Am. J. Dermatopathol.* 2014; **36**: 276–278.
20. Gantner S, Rütten A, Requena L et al. CHILD syndrome with mild skin lesions: histopathologic clues for the diagnosis. *J. Cutan. Pathol.* 2014; **41**: 787–790.
21. Xu XL, Huang LM, Wang Q et al. Multiple verruciform xanthomas in the setting of congenital hemidysplasia with ichthyosiform erythroderma and limb defects syndrome. *Pediatr. Dermatol.* 2015; **32**: 135–137.
22. Getz GI, Parag-Sharma K, Reside J et al. Identification of NSDHL mutations associated with CHILD syndrome in oral verruciform xanthoma. *Oral Surg. Oral Med. Oral Pathol. Oral Radiol.* 2019; **128**: 60–69.
23. Ko CJ, Atzmony L, Lim Y et al. Review of genodermatoses with characteristic histopathology and potential diagnostic delay. *J. Cutan. Pathol.* 2019; **46**: 756–765.
24. Mehra S, Li L, Fan CY et al. A novel somatic mutation of the β -hydroxysteroid dehydrogenase gene in sporadic cutaneous verruciform xanthoma. *Arch. Dermatol.* 2005; **141**: 1263–1267.

Supporting Information

Additional Supporting Information may be found in the online version of this article:

Table S1. Full clinical details.