


# Immediate and partial neural dysfunction after thyroid and parathyroid surgery: Need for recognition, laryngeal exam, and early treatment

**Vaninder K. Dhillon MD<sup>1</sup>**  | **Gregory W. Randolph MD<sup>2</sup>** |  
**Brendan C. Stack Jr MD<sup>3</sup>**  | **Brenessa Lindeman MD<sup>4</sup>** | **Gary Bloom<sup>5</sup>** |  
**Catherine F. Sinclair MBBS, BSc, MD<sup>6</sup>** | **Gayle Woodson MD<sup>7</sup>** |  
**Jennifer A. Brooks MD, MPH<sup>8</sup>** | **Lesley F. Childs MD<sup>9</sup>** |  
**Nazanene H. Esfandiari MD<sup>10</sup>** | **Lisa Evangelista CscD, CCC-SLP<sup>11</sup>** |  
**Elizabeth Guardiani MD<sup>12</sup>** | **Lourdes Quintanilla-Dieck MD<sup>13</sup>** |  
**Matthew R. Naunheim MD, MBA<sup>2</sup>** | **Maisie Shindo MD<sup>13</sup>** |  
**Michael Singer MD<sup>14</sup>**  | **Neil Tolley MB, BCh, MD<sup>15</sup>** |  
**Peter Angelos MD, PhD<sup>16</sup>** | **Robbi Kupfer MD<sup>17</sup>** |  
**Victoria Banuchi MD<sup>18</sup>** | **Whitney Liddy MD<sup>19</sup>** |  
**Ralph P. Tufano MD, MBA<sup>20</sup>**

<sup>1</sup>Department of Otolaryngology-Head and Neck Surgery, Johns Hopkins University National Capital Region, Bethesda, Maryland

<sup>2</sup>Department of Otolaryngology-Head and Neck Surgery, Massachusetts Eye and Ear Infirmary, Harvard Medical School, Boston, Massachusetts

<sup>3</sup>Department of Otolaryngology-Head and Neck Surgery, Southern Illinois University School of Medicine, Springfield, Illinois

<sup>4</sup>Department of General Surgery, Surgical Oncology, University of Alabama, Birmingham, Alabama

<sup>5</sup>ThyCa: Thyroid Cancer Survivors' Association, Inc., Olney, Maryland

<sup>6</sup>Department of Otolaryngology-Head and Neck Surgery, Mount Sinai West Hospital, New York, New York

<sup>7</sup>Department of Otolaryngology-Head and Neck Surgery, Drexel University, Philadelphia, Pennsylvania

<sup>8</sup>Department of Otolaryngology and Communication Enhancement, Boston Children's Hospital, Harvard Medical School, Boston, Massachusetts

<sup>9</sup>Department of Otolaryngology-Head and Neck Surgery, University of Texas Southwestern Medical Center, Dallas, Texas

<sup>10</sup>Department of Internal Medicine, Metabolism, Endocrinology & Diabetes (MEND), University of Michigan, Ann Arbor, Michigan

<sup>11</sup>Department of Otolaryngology-Head and Neck Surgery, University of California, Davis Medical Center, California

<sup>12</sup>Department of Otolaryngology-Head and Neck Surgery, University of Maryland, Baltimore, Maryland

<sup>13</sup>Department of Otolaryngology-Head and Neck Surgery, Oregon Health and Science University, Oregon, Portland

<sup>14</sup>Department of Otolaryngology-Head and Neck Surgery, Henry Ford Health System, Detroit, Michigan

<sup>15</sup>Department of Otolaryngology-Head and Neck Surgery, Imperial College NHS Trust, London, UK

<sup>16</sup>Department of Surgery, University of Chicago School of Medicine, Chicago, Illinois

<sup>17</sup>Department of Otolaryngology-Head and Neck Surgery, University of Michigan, Ann Arbor, Michigan

<sup>18</sup>Department of Otolaryngology-Head and Neck Surgery, Weill Cornell School of Medicine, New York, New York

<sup>19</sup>Department of Otolaryngology-Head and Neck Surgery, Northwestern University, Chicago, Illinois

<sup>20</sup>Department of Otolaryngology-Head and Neck Surgery, Johns Hopkins University, Baltimore, Maryland

**Correspondence**

Vaninder K. Dhillon, MD, 6420 Rockledge Drive Suite 4920; Bethesda, Maryland 20817.  
Email: vdhillon2@jhmi.edu

**Abstract**

**Background:** Laryngeal dysfunction after thyroid and parathyroid surgery requires early recognition and a standardized approach for patients that present with voice, swallowing, and breathing issues. The Endocrine Committee of the American Head and Neck Society (AHNS) convened a panel to define the terms “immediate vocal fold paralysis” and “partial neural dysfunction” and to provide clinical consensus statements based on review of the literature, integrated with expert opinion of the group.

**Methods:** A multidisciplinary expert panel constructed the manuscript and recommendations for laryngeal dysfunction after thyroid and parathyroid surgery. A meta-analysis was performed using the literature and published guidelines. Consensus was achieved using polling and a modified Delphi approach.

**Results:** Twenty-two panelists achieved consensus on five statements regarding the role of early identification and standardization of evaluation for patients with “immediate vocal fold paralysis” and “partial neural dysfunction” after thyroid and parathyroid surgery.

**Conclusion:** After endorsement by the AHNS Endocrine Section and Quality of Care Committee, it received final approval from the AHNS Council.

**KEYWORDS**

immediate vocal fold paralysis, laryngeal exam, partial neural dysfunction, recurrent laryngeal nerve, superior laryngeal nerve

## 1 | INTRODUCTION

Thyroid and parathyroid surgery requires early recognition and meticulous dissection to preserve neurophysiologic function of the recurrent laryngeal nerve (RLN) and its branches. The complex anatomy and physiology of the larynx can be altered after thyroid surgery with a significant impact on quality of life<sup>1,2</sup>. Laryngeal dysfunction can occur from direct injury to the RLN causing vocal fold immobility. Additionally, injury to the small branches of the RLN may result in neural dysfunction with or without recognizable motion impairment. Injury presents along a diverse spectrum of symptomatic clinical complaints that may be associated with minimal or no identifiable abnormality on routine laryngeal examination.

The reported rates of vocal fold paralysis (VFP) after thyroidectomy are a significant underestimate of its true incidence.<sup>3</sup> A systematic review of 25 000 patients reported temporary and permanent VFP rates of 9.8% and 2.3%, respectively. It also reported a range of overall postoperative VFP as 2.3% to 26% depending on the method of laryngeal examination.<sup>4</sup>

The 2017, 5th National Audit of the British Association of Thyroid and Endocrine Surgeons reported a

postoperative VFP rate of 7.8% for first-time thyroid surgery.<sup>3</sup> The exact timeframe for the first postoperative laryngeal examination varies.

In total thyroidectomy, transient and permanent bilateral vocal fold paralysis (BVFP) rates of 0.7% and 0.3% have been reported.<sup>5</sup> In a French study, the incidence of tracheostomy was 0.36% and 30% in patients sustaining BVFP.<sup>6</sup> A retrospective review of 106 773 thyroidectomy patients in California reported a 1.62% tracheostomy rate.<sup>7</sup>

With an increased awareness of the true scale of VFP following thyroidectomy comes an appreciation of its associated morbidity and mortality. A national database study of 43 515 patients revealed that VFP doubled the risk of hospital admission for pneumonia, which led to over three times the risk of dysphagia and a 20-fold risk of gastrostomy or tracheostomy. Studies also revealed that long-term mortality from VFP lessened with early diagnosis and treatment, but never returned to a normal baseline in matched pair analysis.<sup>8</sup>

Recognizing VFP as a significant complication, requiring early diagnosis and intervention, is vital to minimizing associated morbidity and maintaining an optimal patient-doctor relationship. There is significant

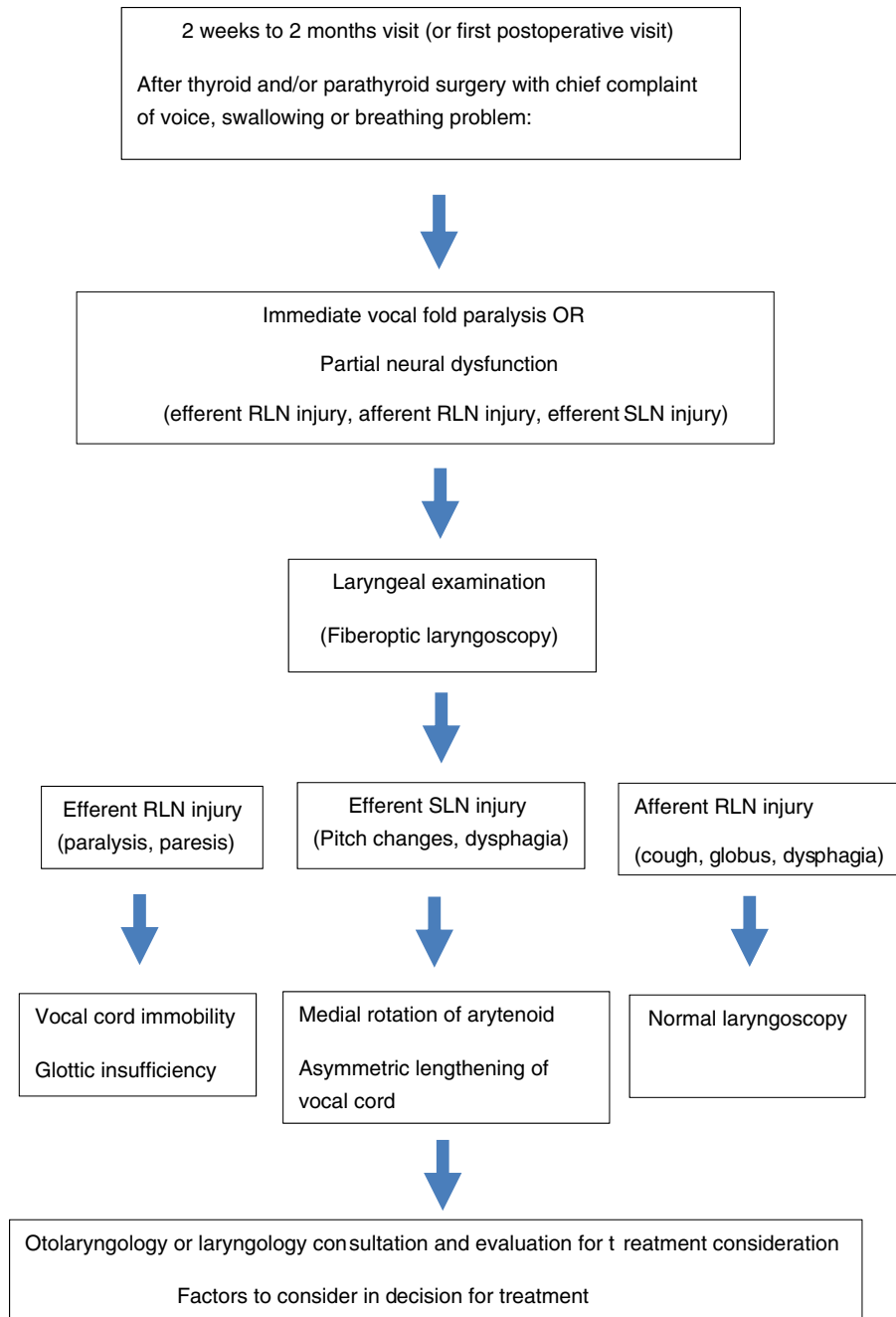
psychosocial morbidity with VFP that can contribute to frustration, isolation, fear, and altered self-identity for patients.<sup>9</sup> Failure to communicate and manage this complication adequately will engender greater patient mistrust and dissatisfaction, leading to both increased complaints and litigation.<sup>10</sup>

It is also important to recognize that laryngeal dysfunction is more complex than just VFP. Laryngeal dysfunction encompasses sensory and motor dysfunction that can lead to symptoms of cough, globus sensation,

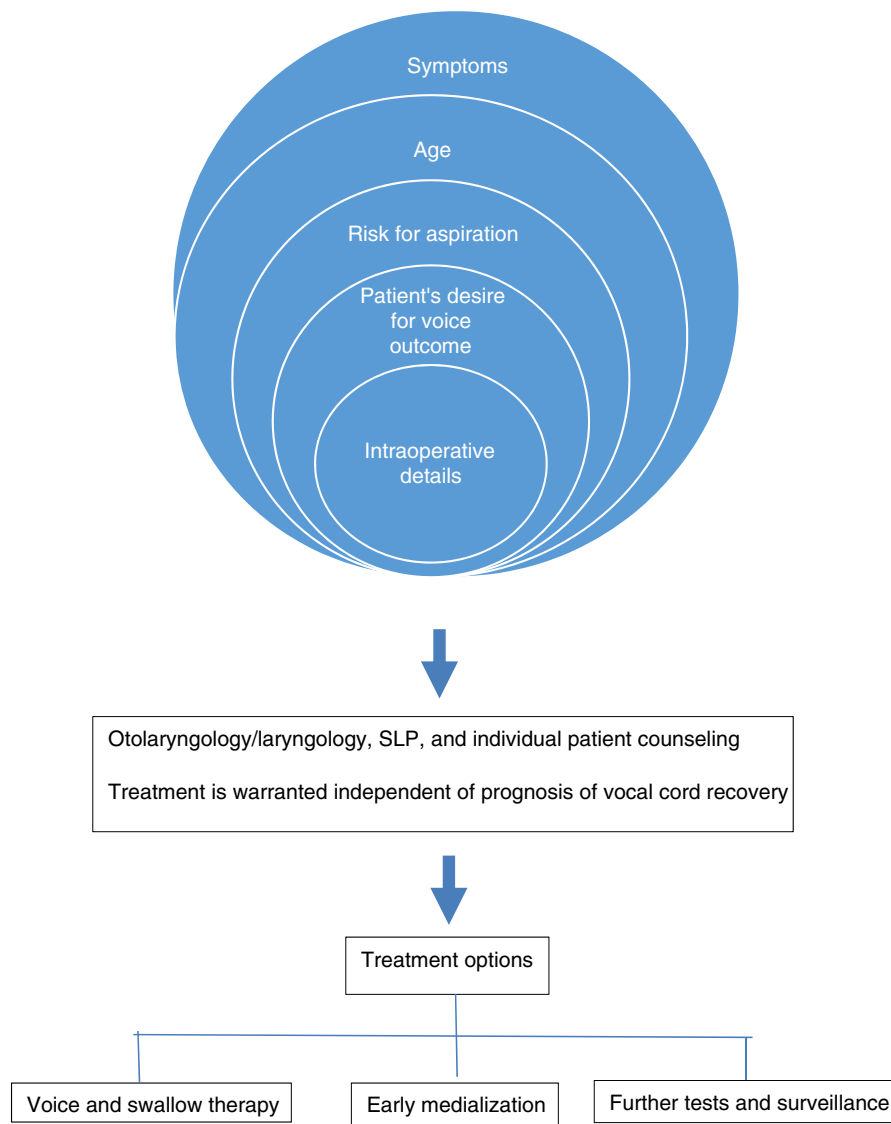
and dysphagia. In line with early diagnosis of VFP, recognition of the varying states of laryngeal dysfunction in the presence or absence of VFP will improve patient satisfaction and decrease morbidity.

### 1.1 | Immediate vocal fold paralysis

The currently used definitions for VFP, as “temporary and permanent,” are antiquated clinical concepts when



**FIGURE 1** Overview of identification of immediate vocal fold paralysis and partial neural dysfunction to treatment [Color figure can be viewed at [wileyonlinelibrary.com](http://wileyonlinelibrary.com)]



**FIGURE 1** (Continued)

managing patients with postoperative laryngeal dysfunction and VFP today. We introduce the definition of “immediate VFP” in order to encourage and guide early identification and intervention, which can improve morbidity, and have a significant psychosocial impact for the patient. Early evaluation and counseling in the “immediate” timeframe is warranted for the aforementioned reason independent of prognosis of vocal fold recovery. Patients with subjective voice complaints in the immediate postoperative period should be considered for Otolaryngology-Head and Neck Surgery and Speech Language Pathology evaluation within the first postoperative visit. The laryngeal examination can take the form of fiberoptic laryngoscopy and/or stroboscopy.

Furthermore, identification of “immediate VFP” optimizes the surgeon's learning curve, allowing us to learn best if we are aware of *all* cases in which our surgery

resulted in *any* neural dysfunction even if it resolves overtime. Early identification of immediate unilateral VFP allows for earlier counseling and treatment. If pathology is identified, a careful analysis of associated risk factors such as patient's age, symptoms, patient's desire to get assistance, risk of aspiration, mechanism of injury, and intraoperative electrophysiological data should be collected to determine the need for treatment. There is strong evidence that early treatment for unilateral VFP improves outcomes from a voice and aspiration prevention standpoint<sup>8,11-13</sup> (Figure 1).

## 1.2 | Partial neural dysfunction

RLN and superior laryngeal nerve (SLN) injury are not an “all or none” phenomenon, since multiple states of

dysfunction can be recognized by symptomatology. The efferent and afferent pathways involved in partial neural dysfunction (PND) include partial RLN dysfunction and partial or complete SLN dysfunction. These pathologies can lead to persistent voice and nonvoice-related symptoms exclusive of VFP, including cough, globus sensation, and dysphagia. Stroboscopy should be considered when fiberoptic laryngoscopy does not reconcile these symptoms if they occur after surgery. These states of partial, nuanced, dysfunction will require more in-depth and targeted evaluation, as well as counseling and surveillance, and it is our task to promptly recognize their existence. An experienced Otolaryngologist-Head and Neck Surgeon and Speech Language Pathologist can consider treatment options, upon an analysis of risk factors and discussion with the patient.

In this article, we will define the terms “immediate postoperative laryngeal dysfunction” and “partial neural dysfunction” in an attempt to identify subgroups of patients and optimize evaluation and treatment for patients with voice, swallowing, and breathing issues after thyroid and parathyroid surgery.

## 2 | METHODS

### 2.1 | Expert panel construction and process

Panel members were selected to represent endocrine surgeons from both Otolaryngology-Head and Neck Surgery and General Surgery, Laryngologists, Endocrinologists and Speech Language Pathologists from North America and the United Kingdom. Organizations represented include the American Head and Neck Society Endocrine Section (AHNS-ES), American Academy of Otolaryngology-Head and Neck Surgery (AAOHNS), American Association of Endocrine Surgeons (AAES), American Thyroid Association (ATA), American Association of Clinical Endocrinologists (AACE), and American Laryngological Association (ALA), as well as the American Bronchoesophagological Association (ABEA) and British Association of Endocrine and Thyroid Surgeons (BAETS).

The specific goals of the Clinical Consensus Statement in outline were reviewed with the entire group. The initial three panel members (VKD, RPT, and GWR) defined the terms that would undergo consensus development. Candidate statements were proposed in alignment with the Institute of Medicine's principles of healthcare quality, with the goal of addressing safety, access, appropriateness, efficiency, effectiveness, and patient centeredness.

### 2.2 | Literature review

Computerized and manual searches were performed to identify relevant data. Definitions and refinements for the proposed statements were drawn from guidelines produced by the AAO, ATA, and AHNS-ES. Literature searches were performed to identify relevant articles in multiple databases between the years 1972 and 2020, including the Cochrane Library, EMBASE, PubMed, Infobase, the Cochrane Central Register of Controlled Trials (CENTRAL), and MEDLINE. Exclusion criteria included articles that reviewed thyroid or parathyroid surgery without the mention of voice, swallow, or dyspnea. Search terms included thyroidectomy, parathyroidectomy, voice, larynx, VFP, RLN, SLN, flexible laryngoscopy, thyroid surgery, thyroid cancer, stroboscopy, medialization, injection laryngoplasty, speech language pathology, dysphonia, dysphagia, dyspnea, voice therapy, swallow therapy, FEES, modified barium swallow, VHI-10, and EAT-10.

Five sections of the Clinical Consensus Statement outline were divided into subgroups of authors. Their first phase comprised of a literature review, and communication between a section lead author and coauthors. The lead author (VKD) collated all submitted sections into a draft, which was sent to the wider author group for commentary.

The second phase consisted of two rounds of consensus assessment using the modified Delphi method. The final recommendation statements and manuscript were then distributed to members of the AHNS Endocrine Section leadership for further feedback. After endorsement by the Endocrine Section, it was reviewed by the AHNS Quality of Care Committee. Once the recommendations from the Quality of Care Committee were incorporated into the manuscript, it received final approval from the AHNS Council.

### 2.3 | Modified Delphi method and data analysis

The modified Delphi method, a previously described and established method to systematically establish consensus, was utilized to determine which statements achieved consensus, near-consensus, or non-consensus.<sup>14-16</sup> Through this method, each expert on the panel expressed his or her opinion for each proposed statement using a survey. Survey content was developed based on edits to the initial statement drafts and vetted by three members of the panel (VKD, RPT, and GWR).

Consensus was achieved in two rounds. In the first round, the entire expert panel rated six statements. The

first author (VKD) sent the link to an online survey ([www.qualtrics.com](http://www.qualtrics.com)) containing candidate statements and brief instructions to panel members through email. Members of the expert panel reviewed proposed statements and independently rated their level of agreement or disagreement with each, using a Likert scale ranging from 1 (*Strongly Disagree*) 9 (*Strongly Agree*) with five representing “Neutral” response. Converse statements were included within the first round survey to serve as internal controls for participant responses whereby each statement was followed by its counter statement in the survey. Panelists could also provide free-text comments for further discussion, which were recorded. Survey results were tracked, summarized, and interpreted at each stage.

During a subsequent teleconference, panel members discussed the results, focusing on statements that had engendered comments, a desire for more detail, or suggestions for statement refinement. Discussion revealed varying interpretations of and suggestions for rewording five statements. Consequently, the first author (VKD) modified the statements for review in a second survey. The results were shared in a subsequent telephone

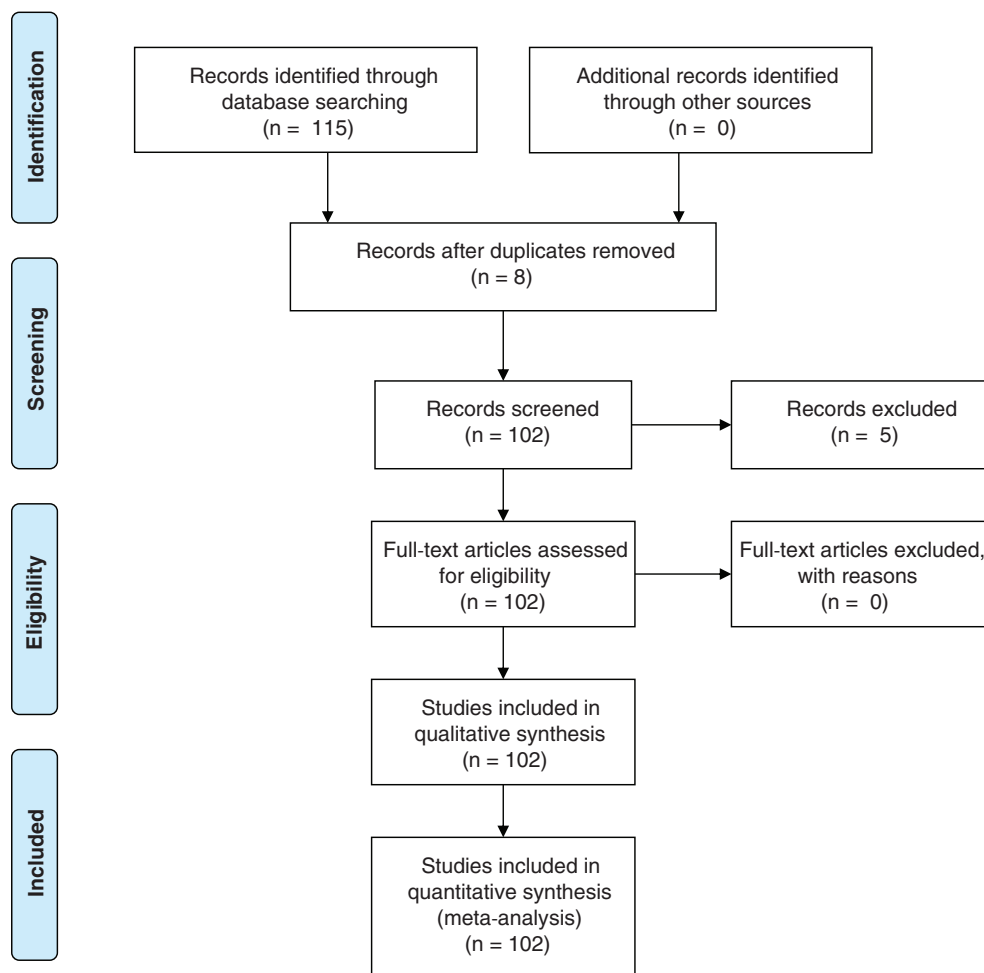
conference call, and the final list of statements was included within the article.

Statements were defined as achieving consensus if there was a mean score of 7.00 or greater and 1 or fewer outlier responses were returned. Near-consensus was defined as statements with a mean of 6.50 to 6.99 with two or fewer outliers. No consensus was the default if these criteria were not met. The basis for achieved consensus with a score of 7 or more is based on Rosenfield et al.<sup>17</sup> Outliers were defined as any rating at least 2 Likert points away from the mean. Statistical analysis was performed utilizing Stata 12.0 (College Station, Texas). Mean, SD, median, and interquartile range were calculated according to their standard definitions.

### 3 | RESULTS

#### 3.1 | Systematic review

A total of 115 articles were reviewed. Eight duplicate articles were removed. Five articles were excluded upon screening, leaving 102 articles involved in the final meta-



**FIGURE 2** Preferred Reporting Items for Systematic Reviews and Meta-Analyses (PRISMA) diagram [Color figure can be viewed at [wileyonlinelibrary.com](http://wileyonlinelibrary.com)]

**TABLE 1** Results of panel ratings

Statement number (#)	Statement verbiage round 1	Mean	Outlier	Statement verbiage round 2	Mean	Outlier
1	The terms transient and permanent vocal fold paralysis are no longer sufficient to define varying states of laryngeal function after thyroid and parathyroid surgery. Early identification, visualization and treatment of immediate postoperative vocal cord immobility may allow for improved patient outcomes.	8.18	2	The terms transient and permanent vocal fold paralysis do not capture all varying states of laryngeal dysfunction that can occur after thyroid and parathyroid surgery. Laryngeal dysfunction is complex and involves more than just motion impairment. A comprehensive evaluation in the immediate postoperative setting is important if there is concern for any neural dysfunction.	8.95	0
2	It is appropriate to consider identification of immediate vocal fold paralysis within 2 weeks and 2 months postoperatively, or even earlier if there is knowledge or concern for vocal fold paralysis intraoperatively.	8.22	2	Early identification, visualization, and treatment of immediate postoperative neural dysfunction of the vocal fold, including motion impairment, may allow for improved patient outcomes. Vocal fold examination should be performed in the immediate postoperative period, which generally occurs within 2 weeks to 2 months.	8.90	0
3	Nerve injury can effect afferent and efferent pathways along a spectrum of dysfunction and may be partial but still may lead to postoperative morbidity. Such partial neural dysfunction can be challenging to diagnose.	8.82	0	Laryngeal nerve injury can affect afferent and efferent pathways, resulting in a spectrum of dysfunction. Partial neural dysfunction includes nonvoice complaints and therefore may be underdiagnosed. Clinicians should have a high index of suspicion for partial neural dysfunction and involve otolaryngology and speech language pathology colleagues who may perform a voice and nonvoice evaluation, as well as direct visualization of the larynx if symptoms do not resolve within 2 weeks to 2 months postoperatively.	8.82	0
4	Partial neural dysfunction of the larynx is underdiagnosed and should be identified through symptom assessment that includes voice and nonvoice evaluation, we well as direct visualization of the larynx if symptoms do not resolve within 2 weeks to 2 months postoperatively	8.5	0	A standardized approach in the workup for patients with immediate vocal fold paralysis and partial neural dysfunction should include an objective voice and swallow evaluation through validated questionnaires, direct visualization of the larynx as well as further testing if indicated. Such testing may include videostroboscopy, laryngeal electromyography, and modified barium swallow evaluation.	8.95	0

(Continues)

TABLE 1 (Continued)

Statement number (#)	Statement verbiage round 1	Mean	Outlier	Statement verbiage round 2	Mean	Outlier
5	A standardized approach in the work up for patients with immediate vocal fold paralysis and partial neural dysfunction should include an objective voice and swallow evaluation through validated questionnaires, direct visualization of the larynx, and further testing if indicated.	8.73	0	Videostroboscopy provides important information for patients with immediate vocal fold paralysis and partial neural dysfunction. This may apply to those whose voice evaluation and symptom assessment are discordant from preliminary laryngoscopy findings, as well as those with documented neural dysfunction with or without voice complaints, including states of SLN dysfunction.	9.00	0
6	Videostroboscopy provides important information and allows for improved patient counseling and treatment planning for patients with immediate VFP whose voice evaluation and symptom assessment are not consistent with fiberoptic laryngoscopy findings, as well as those with documented partial neural dysfunction who have no voice complaints.	8.23	4			

analysis and inclusion within the article (Figure 2). There are no previously published consensus statements or clinical practice guidelines with the same search terms.

### 3.2 | Modified Delphi results

Twenty-two panelists completed both rounds of surveys. In the first round, consensus was achieved on three statements, near consensus was achieved on two statements and no consensus was achieved on one statement. At the completion of the second round, consensus was achieved on all five revised statements. Table 1 provides the results of both rounds of panel ratings.

#### 3.2.1 | Statement 1: immediate vocal fold paralysis

The terms transient and permanent VFP do not capture all varying states of laryngeal dysfunction that can occur after thyroid and parathyroid surgery. Laryngeal dysfunction is complex and involves more than just vocal fold motion impairment. A comprehensive evaluation in the immediate postoperative setting is important if there is

concern for any neural dysfunction. We therefore introduce the term “immediate” vocal fold paralysis.

VFP that occurs in the immediate postoperative setting has clinical implications regardless of prognosis for recovery.<sup>8</sup> Impaired glottic closure caused by unilateral VFP in the immediate postoperative period can lead to significant functional deficits including communication impairment, dyspnea, and dysphagia. Bilateral VFP in the immediate postoperative period can lead to airway compromise and the need for emergent intervention (Table 2).

The manifestations of unilateral VFP cause immediate impairment of patients' basic life functions and have a substantial impact on quality of life.<sup>9</sup> Dysphonia is the most common symptom, with rates of voice disturbance following thyroidectomy ranging from 30% to 87%.<sup>18</sup> Dysphagia has been reported in 55% to 69% of patients with VFP,<sup>11-13</sup> resulting in aspiration pneumonia in up to 6%.<sup>11</sup> Although less well recognized, dyspnea is also a common symptom in unilateral VFP, with a reported prevalence as high as 76%.<sup>18</sup> Proposed causes of dyspnea include hyperventilation<sup>19</sup> and passive medialization of the flaccid vocal fold with inspiration resulting from laryngeal airflow and turbulence.<sup>20-23</sup> For athletes, musicians including singers, and those with high exertional



**TABLE 2** Rationale for Immediate VFP definition

- It is our ethical obligation to provide the best patient care—we need to ask and know what deficits our patients' experience, and address them.
- As surgeons, it is important to identify and address complications and improve on our outcomes.
- Nerve injury is more optimally treated when diagnosed early.
- If we address VFP in the early postoperative period, we can reduce morbidity and improve quality of life.
- It is clinically pertinent to substantiate the neural dysfunction for VFP especially if bilateral, as this diagnosis can indicate observation in the form of humidified air, racemic epinephrine, steroids, Heliox, and other supportive treatment versus need for tracheostomy.

activity, this outcome would be debilitating. The psychosocial impact of VFP and its associated symptoms has been shown to lead to decreased quality of life for patients. Patients are more likely to file for short-term disability and experience frustration, isolation, and altered self-identity as a result of their inability to effectively communicate.<sup>9,24,25</sup>

The identification of an immediate VFP enables early intervention in the form of patient counseling, voice therapy, and early medialization procedures if indicated. For those who undergo treatment, several studies have demonstrated improvement of both dysphagia and dysphonia with early initiation of speech therapy, as well as injection laryngoplasty.<sup>13,26-31</sup> Injection laryngoplasty significantly reduces the rate of aspiration, returning patients to a regular diet.<sup>32-39</sup> Patients with unilateral VFP who undergo early injection laryngoplasty are less likely to require long-term medialization procedures in the form of thyroplasty than those who did not receive early injection laryngoplasty.<sup>40</sup> Investigations of treatments, like nimodipine in the acute period of VFP, are promising but requires further evaluation before being widely adopted.<sup>41,42</sup> The early involvement of an Otolaryngologist-Head and Neck Surgeon and Speech Language Pathologist is key in the decision-making process for early intervention.

### 3.2.2 | Statement 2: early identification

Early identification, visualization, and treatment of immediate post-operative neural dysfunction of the vocal fold, including vocal fold motion impairment, may allow for improved patient outcomes. Vocal fold examination in all of these patients should be performed in the immediate postoperative period, which generally occurs within 2 weeks to 2 months.

In the early postoperative period, a high clinical suspicion for unilateral VFP is important if the patient complains of a weak voice or has an audible breathy quality to the voice. It is also important to consider that voice changes may become more apparent after laryngeal edema improves within a few days of extubation.

The following intraoperative scenarios are consistently associated with immediate VFP and should be confirmed and documented by flexible laryngoscopy: (a) known transection or sacrifice of the RLN, or (b) no response to stimulation of the vagus or RLN with the use of nerve monitoring at the end of surgery. The specificity of electromyography loss of signal in postoperative VFP detection is 99.9%.<sup>43</sup>

Patients with known or suspected VFP, independent of symptoms, should undergo immediate evaluation and intervention even while admitted following thyroid or parathyroid surgery. Direct visualization of immediate VFP assists in (a) identification and documentation of the VFP, (b) intervention in a prompt fashion, and (c) counseling of patients with or without symptoms.

Bilateral VFP following thyroidectomy requires early identification and if necessary, intervention, due to the risk of airway obstruction. Any patient with stridor following a thyroidectomy requires immediate airway evaluation. Patients with bilateral VFP on direct visualization and more subtle airway symptoms may be managed conservatively with temporizing measures such as humidified air, racemic epinephrine, corticosteroids, and Heliox, while patients with more severe symptoms may require a tracheostomy or a vocal fold lateralization procedure in the early period. The long-term care of patients with bilateral VFP may not require surgical intervention but involves initial and close follow-up once diagnosed.

### 3.3 | Preoperative laryngeal examination considerations for patients undergoing thyroid and parathyroid surgery

Various national<sup>44</sup> and international guidelines<sup>45,46</sup> recommend preoperative laryngeal evaluation in certain circumstances—namely, when there are preoperative voice changes, in high-risk patients such as those with prior neck or chest surgery, or in cases of thyroid malignancy.<sup>18</sup> One recent paper looked retrospectively at nearly 6000 patients, and found preoperative VFP in 41 patients (0.68%). Certain clinical parameters were found to be clinically significant indicators of VFP and were recommended as part of a selective approach to preoperative laryngoscopy.<sup>47</sup>

*Preoperative laryngeal examination* may be considered in *all* patients undergoing thyroid and parathyroid surgery for a number of reasons: (a) There is significant divergence between voice symptoms and objective vocal

fold function. The sensitivity of voice change in predicting VFP ranged from 33% to 68% in two studies.<sup>48,49</sup> (b) Preoperative recognition of VFP is essential for surgical planning, such that there may be an incidental vocal fold anomaly that could worsen after surgery. In one study, almost 60% of patients who underwent preoperative laryngeal evaluation showed an abnormality (though none had a full paralysis).<sup>50</sup> Finally, (c) preoperative vocal fold function is necessary before

assuming responsibility for paralysis found after surgery, from a medicolegal standpoint.

### 3.3.1 | Statement 3: partial neural dysfunction

Laryngeal nerve injury can affect afferent and efferent pathways, resulting in a spectrum of dysfunction. Partial neural dysfunction includes non-voice complaints and therefore may be underdiagnosed. Clinicians should have a high index of suspicion for partial neural dysfunction and involve Otolaryngology-Head and Neck Surgery and Speech Language Pathology colleagues if symptoms persist within 2 weeks to 2 months postoperatively, who may perform a voice and nonvoice evaluation, as well as direct visualization of the larynx.

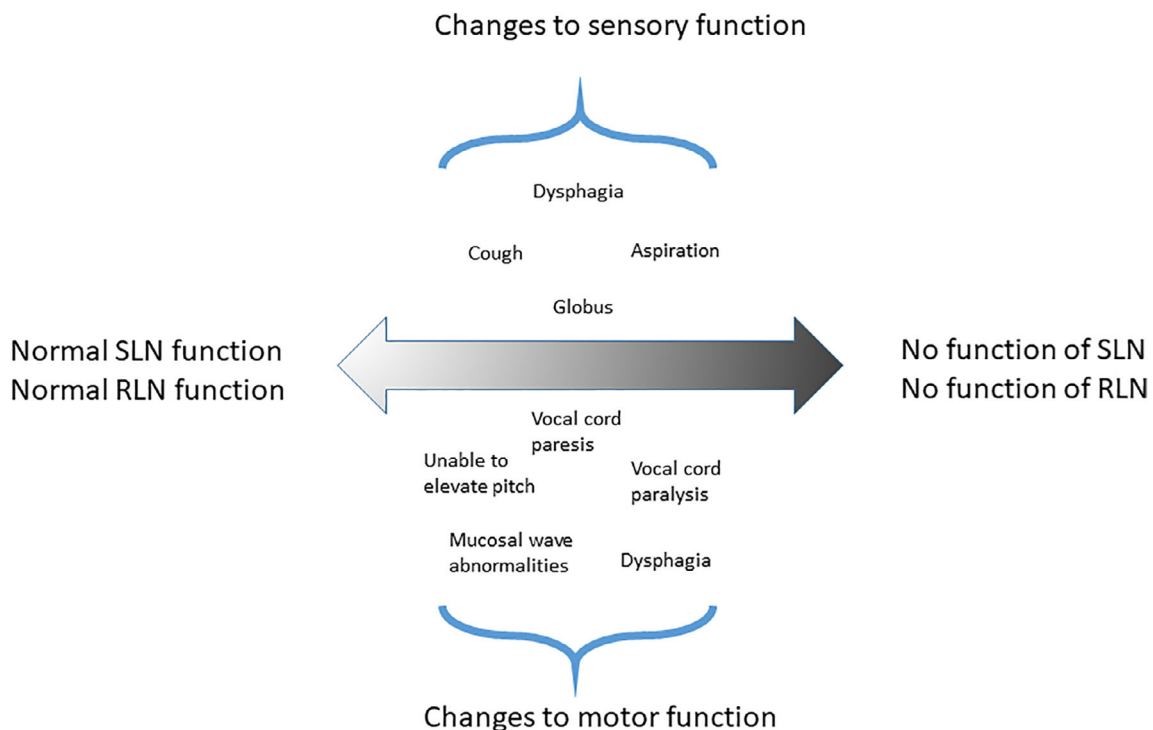
Patients with partial neural dysfunction may present with perceived changes to swallowing or voicing, even in the absence of vocal fold immobility.<sup>51-53</sup> We define these as disorders of efferent or afferent pathways of the RLN or SLN exclusive of VFP seen on preliminary laryngoscopy, all of which may be clinically symptomatic.

Partial neural dysfunction can be into either efferent (motor) or afferent (sensory) nerve dysfunction, related to the RLN or SLN nerve fibers (Table 3). Figure 3 demonstrates the biocontinuum for which these afferent and efferent fibers can lead to related symptoms.

**TABLE 3** Partial neural (motor and sensory) dysfunction after thyroid surgery (clinical signs and symptoms)

Motor dysfunction	Sensory dysfunction
<ul style="list-style-type: none"> <li>• RLN—paresis, loss of tone, change in mucosal wave, paradoxical motion/laryngospasm, medial rotation of the arytenoid</li> <li>• SLN (external branch)—change in pitch elevation, fine tuning of voice</li> <li>• Pharyngeal plexus—dysphagia, loss of cricopharyngeal tone, globus sensation</li> </ul>	<ul style="list-style-type: none"> <li>• RLN—loss of cervical esophageal sensation, dysphagia, cough</li> <li>• <sup>a</sup>SLN (internal branch)—cough, globus sensation</li> </ul>

<sup>a</sup>The internal branch of the SLN (IBSLN) is not typically at direct risk during thyroid or parathyroid surgery except for a few exceptions.



**FIGURE 3** Biocontinuum of states of partial neural dysfunction [Color figure can be viewed at wileyonlinelibrary.com]

Damage to the efferent or afferent nerves that supply the larynx and pharynx can be hard to quantify, and motor and sensory problems often coexist. There is no clear documentation of incidence in the literature, and partial neural dysfunction may be widely underdiagnosed.

### 3.4 | Motor Dysfunction

Efferent dysfunction of the RLN can cause motor abnormalities such as VFP in addition to more subtle clinical changes to nerve function resulting in *paresis*, defined as a hypomobile vocal fold due to a neurogenic etiology.<sup>54</sup> Literature on vocal fold paresis underscores that there is a spectrum of possible vocal fold motion impairment. Therefore, subtle changes due to axonal damage may not always be immediately evident on laryngeal examination, but repetitive phonation often reveals sluggish motion of the affected fold or a perceived asymmetry between vocal folds on abduction and adduction.<sup>55,56</sup>

The symptoms associated with vocal fold paresis, like paralysis, consist of a breathy voice quality and/or vocal fatigue,<sup>57</sup> as well as impaired cough and aspiration due to incomplete glottic closure, which can significantly impact quality of life.<sup>58</sup> It should be noted that not all motor dysfunction of the larynx is related to a reduced or absent motion; laryngospasm, paradoxical vocal fold motion, and airway obstruction have also been described.<sup>21,22</sup>

Efferent dysfunction of the external branch of the SLN (EBSLN) primarily affects the cricothyroid muscle, which is classically thought to be the only muscle innervated by the SLN. Although the external SLN may contribute efferent fibers to other intrinsic laryngeal muscles,<sup>59-61</sup> the primary effect of damage to the SLN's external branch is loss of cricothyroid muscle function, which causes decreased vocal range and loss of higher pitches.<sup>62-64</sup>

Efferent function to the muscles of the pharynx, upper esophagus, and strap muscles can also be impacted after thyroidectomy causing varying degrees of dysphagia, throat tightness, or globus sensation. It is known that many patients experience subjective and objective swallowing impairment.<sup>61,65,66</sup> There can be objective stasis of food in the oropharynx and hypopharynx,<sup>67</sup> which may also relate to afferent function, and esophageal motility and upper esophageal pressure are also impaired in some patients.<sup>68</sup>

### 3.5 | Sensory dysfunction

Both the RLN and internal branch of the superior laryngeal nerve (IBSLN) have afferent branches to the larynx, pharynx and cervical esophagus. The IBSLN is purely a

sensory nerve, which is not typically at direct risk during thyroid or parathyroid surgery except in a minority of cases that may include large goiters extending into the parapharyngeal space or ectopic parathyroid disease. However, injury to the afferent fibers of the RLN injury can lead to decreased sensory function, which predisposes patients to coughing, aspiration, irritable throat sensation, and loss of sensation of the cervical esophagus leading to dysphagia.<sup>67-72</sup> It is also important to consider sensory abnormalities from the afferent fibers in patients unilateral VFP. For example, patients with unilateral VFP do not usually aspirate unless there is also a sensory deficit.

#### 3.5.1 | Statement 4: standardized approach

A standardized approach in the work up for patients with immediate VFP and partial neural dysfunction should include an objective voice and swallow evaluation through validated questionnaires, direct visualization of the larynx as well as further testing if indicated. Such testing may include videostroboscopy, laryngeal electromyography, and a modified barium swallow evaluation.

Visualization of the larynx and pharynx is a critical next step in evaluation of partial neural dysfunction. Stroboscopy is useful in the evaluation of voice complaints or cough related to paresis and glottic insufficiency, as well as possible EBSLN injury<sup>73,74</sup> (see section IV). Laryngeal electromyography (LEMG) has been suggested as useful in patients with voice complaints<sup>57,58</sup> especially when glottic configuration on laryngoscopy and stroboscopy appears normal but weakness is suspected.<sup>74</sup> It should be noted, however, that LEMG is not a reliable indicator of RLN injury, and EMG abnormalities are not common across the population.<sup>35,75,76</sup>

#### *Implications and logistics of the laryngeal examination*

Per the current guidelines by the American Thyroid Association,<sup>44</sup> as well as the American Academy of Otolaryngology and AHNS,<sup>18,77</sup> the timeline suggested in assessment of immediate voice complaints is between 2 weeks to 2 months after surgery. Within this recommendation, voice assessment should include subjective patient reporting and an objective assessment of voice by an Otolaryngologist-Head and Neck Surgeon and Speech Language Pathologist. A more practical approach, and one that would allow intervention for patients with immediate VFP and symptoms of partial neural dysfunction, would be to recommend a laryngeal exam generally within 2 weeks to 2 months, unless there is suspicion for neural dysfunction before 2 weeks' time.

### Objective voice and swallow evaluation

A standardized assessment approach is invaluable to assess immediate dysphonia and dysphagia following surgery.

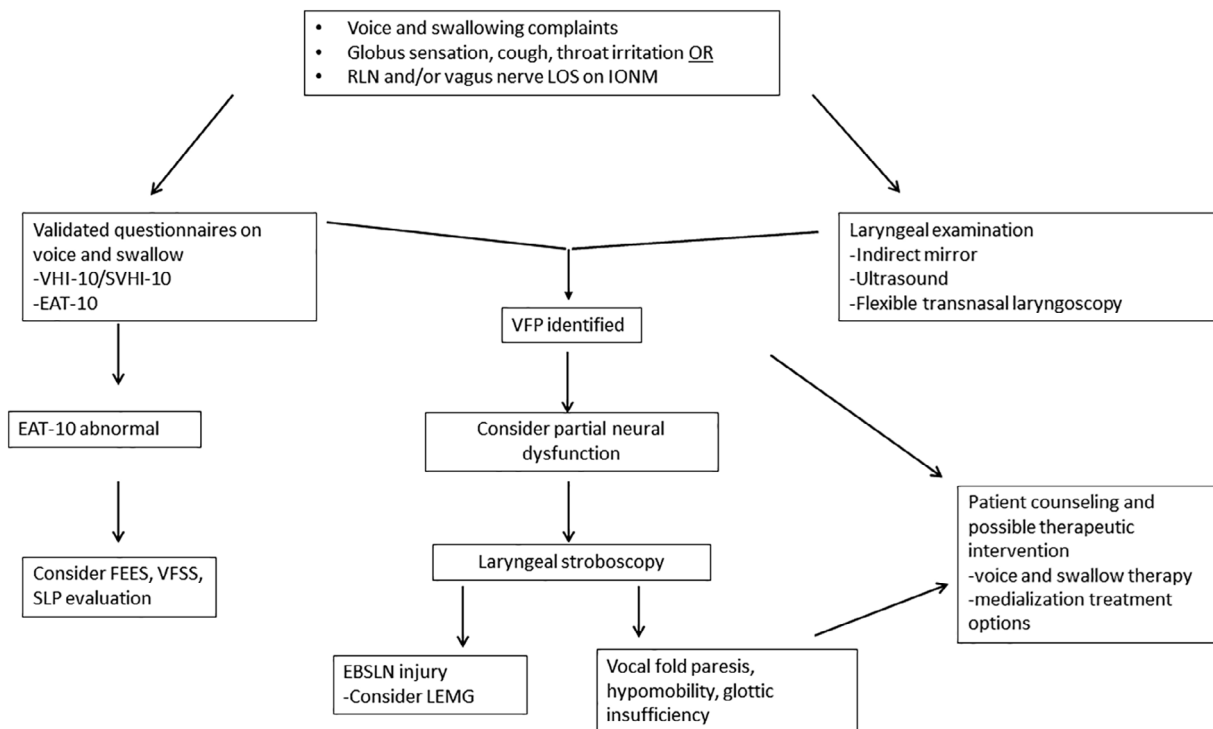
Phonatory dysfunction is heterogeneous based on the range of possible injuries to the RLN or EBSLN as well as the patient's individual voice use and standards (Figure 3).<sup>63,78,79</sup> The Voice Handicap Index (VHI-10) is a validated questionnaire used to measure vocal handicap in the adult population<sup>80</sup> and can be used in post-thyroidectomy and parathyroidectomy patients with dysphonia. We propose initial screening with the VHI-10 questionnaire for suspected EBSLN dysfunction. If patients do not feel their symptoms are adequately assessed via the provided screening questions, we propose selected additional questions to clarify possible symptoms, adopted from the validated Singing Voice Handicap Index-10 (SVHI-10, Figure 4).<sup>81</sup> Patients with VHI-10 scores of 11 or greater,<sup>82</sup> or positive answers to one or more of our adjunctive EBSLN questions, warrant referral to an Otolaryngologist-Head and Neck Surgeon and Speech Language Pathologist for further vocal assessment.

While the reported immediate postoperative rates of dysphagia are as high as 80%, approximately 17% of patients will have persistent dysphagia complaints at

6-months after surgery.<sup>83</sup> The Eating Assessment Tool (EAT-10) is a symptom-specific outcome instrument for dysphagia that can screen patients following thyroidectomy or parathyroidectomy for swallow dysfunction.<sup>84-86</sup> In addition to symptom questionnaires, instrumental diagnostics allow for evaluation of the structural composition and physiologic integrity of the swallowing mechanism. Such diagnostics include fiberoptic endoscopic evaluation of swallowing (FEES) and videofluoroscopic swallow studies (VFSS). FEES can evaluate for premature spillage, laryngeal penetration, aspiration, and retention of material in the oropharynx and hypopharynx,<sup>67,87</sup> as well as allow for real-time counseling on compensatory strategies and maneuvers to improve swallow safety.<sup>87,88</sup> VFSS uses barium in varying consistencies and volumes, to allow for 2D anatomical and physiologic kinematic assessment of the oral preparatory, oral, pharyngeal, and upper esophageal phases of the swallow.<sup>89</sup>

### 3.5.2 | Statement 5: videostroboscopy

Videostroboscopy provides important information for patients with immediate VFP and partial neural dysfunction. This may apply to those whose voice evaluation and



**FIGURE 4** Algorithm for objective assessment of voice and swallowing complaints after thyroid and parathyroid surgery. EAT-10, Eating Assessment Tool; EBSLN, external branch superior laryngeal nerve; FEES, fiberoptic endoscopic evaluation of swallowing; IONM, Intraoperative neuromonitoring; LEMG, laryngeal electromyography; LOS, loss of signal; SVHI, Singing Voice Handicap Index; VFSS, Videofluoroscopic Swallow Study; VFP, vocal fold paralysis; VHI, Voice Handicap Index; SLP, speech language pathology

symptom assessment are discordant from preliminary laryngoscopy findings, as well as those with documented neural dysfunction with or without voice complaints, including states of SLN dysfunction.

### *Laryngeal examination*

There are four contemporary techniques available that can be performed in the clinic setting for routine anatomical assessment of the larynx. These include indirect “mirror” laryngoscopy, laryngeal ultrasound, transnasal fiberoptic laryngoscopy, and stroboscopy. Performance of all these approaches necessitates some degree of training.

Transnasal fiberoptic laryngoscopy is the most reliable approach for observing laryngeal function, and is recognized as the most appropriate means for direct visualization of the larynx.<sup>90-92</sup> Fiberoptic laryngoscopy uses a halogen light source and allows for direct visualization of any mass/lesions as well as abduction and adduction of the vocal folds. It is typically easy to perform and well tolerated by most patients.

Laryngeal stroboscopy can provide information on vocal fold function that may not be reconciled with laryngoscopy alone. By using a synchronized flashing light, stroboscopy creates a pseudo-slow motion examination of the mucosal wave and vocal fold vibrations.<sup>56,93</sup> This enables increased insight into subtle pathological findings such as mucosal wave abnormalities, lesions along the medial edge of the vocal fold, vocal fold paresis, or mild asymmetries in abduction and adduction of the vocal fold and incomplete glottis closure.

One survey of post-fellowship-trained laryngologists suggests that 72% rely on stroboscopy to diagnose vocal fold paresis, favoring it over other forms of laryngoscopy or LEMG.<sup>94,95</sup> In paresis, common stroboscopic findings include vocal fold bowing (70%), incomplete closure (62%), and increased vibratory amplitude (38%).<sup>96</sup> Isolated EBSLN denervation may result in deviation of the epiglottic petiole to the side of cricothyroid muscle weakness during high-pitched voice production, or as vocal fold bowing and shortening, vocal process height asymmetry, and ipsilateral hyperadduction of the false vocal fold.<sup>3,73,97,98</sup> Furthermore, patients with complaints such as cough, globus, or dysphagia with or without voice complaints should undergo stroboscopy to evaluate for partial neural dysfunction that may include EBSLN dysfunction.

A comprehensive laryngeal examination is important to assess laryngeal dysfunction over an extended period of time, with the use of task specific exercises. This can involve a multidisciplinary team led by an Otolaryngologist-Head and Neck Surgeon and a Speech Language Pathologist.

### *Patient counseling and importance of patient outcomes*

For patients with VFP or paresis, counseling often focuses on prognosis for improvement and treatment options for voice handicap. Of those who will recover motion, 85% will have recovered within 6 months and 95% will have recovered within 9 months of onset.<sup>73</sup> However, as demonstrated by one study, voice outcomes did not necessarily equate to recovery of VFP.<sup>97</sup> The laryngology-specific follow-up of the patients in this study may have led to improved voice outcomes simply by provision of patient counseling. This study also reinforces the role of correlating voice outcomes with visualization of the vocal fold in order to prevent a false sense of vocal fold recovery if dysfunction was documented postoperatively.

Early recognition of laryngeal dysfunction, whether it be RLN or SLN injury, and whether it be a VFP or partial neural dysfunction, leads to improved patient counseling with the appropriate specialists in Otolaryngology-Head and Neck Surgery as well as Speech Language Pathology.<sup>8,51,99-102</sup> Patient counseling is beneficial and independent of the need for further treatment. Close follow-up or decided upon treatment options can mitigate delays in care and unnecessary reduction in patient quality of life.<sup>77</sup>

## 4 | CONCLUSION

The terms “immediate” vocal fold paralysis and “partial neural dysfunction” are important when identifying laryngeal dysfunction after thyroid and parathyroid surgery. Partial neural dysfunction is equally as important as immediate IVFP because both the efferent and afferent pathways of the RLN and efferent fibers of the SLN (EBSLN) can lead to persistent and treatable voice and non-voice related symptoms. Objective assessment of symptoms and laryngeal examination in the form of laryngoscopy is a recommended starting point, with consideration of stroboscopy when preliminary laryngoscopy does not explain the patient’s symptoms. The role of an experienced and trained Otolaryngologist-Head and Neck Surgeon and Speech Language Pathologist is crucial in the assessment, counseling, and consideration of treatment options.

### ORCID

Vaninder K. Dhillon  <https://orcid.org/0000-0001-7551-3634>

Brendan C. Stack Jr  <https://orcid.org/0000-0003-2896-1615>

Michael Singer  <https://orcid.org/0000-0002-8673-2637>

## REFERENCES

- Rosow D, Sulica L. Laryngoscopy of vocal fold paralysis: evaluation of consistency of clinical findings. *Laryngoscope*. 2010;120:1376-1382.
- Scerrino G, Tudisca C, Bonventre S, et al. Swallowing disorders after thyroidectomy: what we know and where we are. A systematic review. *International Journal of Surgery*. 2017;41:S94-S102.
- Chadwick R. *Kinsman*. BAETS Fifth National Audit Report: Walton; 2017.
- Jeannon J-P, Orabi AA, Bruch GA, et al. Diagnosis of recurrent laryngeal nerve palsy after thyroidectomy: a systematic review. *Intern J Clin Pract*. 2009;63(4):624-629D.
- Friedrich T, Hansch U, Eichfeld U, et al. Therapeutic management of postoperatively diagnosed bilateral recurrent laryngeal nerve paralysis. *Zentralblatt Fur Chirurgie*. 2000;125(2):137-143.
- Lacoste L, Montaz N, Bernit A-F, et al. Airway complications in thyroid surgery. *Ann Otol Rhinol Laryngol*. 1993;102:441-446.
- Weiss A, Parina RP, Tang JA, Brumund KT, Chang DC, Bouvet M. Outcomes of thyroidectomy from a large California state database. *Am J Surg*. 2015;210(6):1170-1177.
- SAR Nouraei J, Allen HK, Middleton SE, et al. Vocal palsy increases the risk of lower respiratory tract infection in low-risk low-morbidity patients undergoing thyroidectomy for benign disease: a big data analysis. *Clin Otolaryngol*. 2017;42(6):1259-1266.
- Francis DO, Sherman AE, Hovis KL, et al. Life experience of patients with unilateral vocal fold paralysis. *JAMA Otolaryngol Head Neck Surg*. 2018;144(5):433-439.
- Regenbogen SE, Veenstra CM, Hawley ST, et al. The effect of complications on the patient-surgeon relationship after colorectal cancer surgery. *Surgery*. 2014;155(5):841-850.
- Schiedermayer B, Kendall KA, Stevens M, Ou Z, Presson AP, Barkmeier-Kraemer JM. Prevalence, incidence, and characteristics of dysphagia in those with unilateral vocal fold paralysis. *Laryngoscope*. 2019;130(10):2397-2404.
- Zhou D, Jafri M, Husain I. Identifying the prevalence of dysphagia among patients diagnosed with unilateral vocal fold immobility. *Otolaryngol Head Neck Surg*. 2019;160(6):955-964.
- Ollivere B, Duce K, Rowlands G, Harrison P, O'Reilly BJ. Swallowing dysfunction in patients with unilateral vocal fold paralysis: aetiology and outcomes. *J Laryngol Otol*. 2006;120(1):38-41.
- Dalkey NC. *The Delphi method: an experimental study of group opinion*. Rand Cororation: Santa Onica, CA; 1969.
- Dalkey NC, Helmer O. An experimental application of the Delphi method to the use of experts. *Manag Sci*. 1963;9:458-4672.
- Setzen G, Ferguson BJ, Han JK, et al. Clinical consensus statement: appropriate use of computed tomography for paranasal sinus disease. *Otolaryngol Head Neck Surg*. 2012;147:808-816.
- Rosenfield RM, Nnacheta LC, Corrigan MD. Clinical consensus statement development manual. *Otolaryngol Head Neck Surg*. 2015;153(2S):S1-S4.
- Sinclair CF, Bumpous JM, Haugen BR, et al. Laryngeal examination in thyroid and parathyroid surgery: an American Head and Neck Society consensus statement: AHNS consensus statement. *Head Neck*. 2016;38(6):811-819.
- Bequignon E, Dang H, Zerah-Lancner F, Coste A, Boyer L, Papon JF. Unilateral recurrent laryngeal nerve palsy post-thyroidectomy: looking for hyperventilation syndrome. *Eur Ann Otorhinolaryngol Head Neck Dis*. 2019;136(5):373-377.
- Asik MB, Karasimav O, Birkent H, Merati AL, Gerek M, Yildiz Y. Airway and respiration parameters improve following vocal fold Medialization: a prospective study. *Ann Otol Rhinol Laryngol*. 2015;124(12):972-977.
- Nelson JL, Woodson GE. Airway obstruction due to unilateral vocal fold paralysis. *Laryngoscope*. 2013;123(4):969-974.
- Wani MK, Woodson GE. Paroxysmal laryngospasm after laryngeal nerve injury. *Laryngoscope*. 1999;109(5):694-697.
- Kashima H. Documentation of upper airway obstruction in unilateral vocal cord paralysis: flow-volume loop studies in 43 subjects. *Laryngoscope*. 1984;94:923-37.
- Cohen SM, Dupont WD, Courey MS. Quality-of-life impact of non-neoplastic voice disorders: a meta-analysis. *Ann Otol Rhinol Laryngol*. 2006;115(2):128-134.
- Cohen SM, Kim J, Roy N, Asche C, Courey M. The impact of laryngeal disorders on work-related dysfunction. *Laryngoscope*. 2012;122(7):1589-1594.
- Schindler A, Bottero A, Capaccio P, Ginocchio D, Adorni F, Ottaviani F. Vocal improvement after voice therapy in unilateral vocal fold paralysis. *J Voice*. 2008;22(1):113-118.
- D'Alatri L, Galla S, Rigante M, Antonelli O, Buldrini S, Marchese MR. Role of early voice therapy in patients affected by unilateral vocal fold paralysis. *J Laryngol Otol*. 2008;122(9):936-941.
- Yung KC, Likhterov I, Courey MS. Effect of temporary vocal fold injection medialization on the rate of permanent medialization laryngoplasty in unilateral vocal fold paralysis patients. *Laryngoscope*. 2011;121:2191-2194.
- Verma SP, Dailey SH. Office-based injection laryngoplasty for the management of unilateral vocal fold paralysis. *J Voice*. 2014;28:382-386.
- Prendes BL, Yung KC, Likhterov I, Schneider SL, Al-Jurf SA, Courey MS. Long-term effects of injection laryngoplasty with a temporary agent on voice quality and vocal fold position. *Laryngoscope*. 2012;122:2227-2233.
- Hashemian M, Khorasani B, Tarameshlu M, Haghani H, Ghelichi L, Nakhostin Ansari N. Effects of dysphagia therapy on swallowing dysfunction after Total thyroidectomy. *Iran J Otorhinolaryngol*. 2019;31(107):329-334.
- Cates DJ, Venkatesan NN, Strong B, Kuhn MA, Belafsky PC. Effect of vocal fold Medialization on dysphagia in patients with unilateral vocal fold immobility. *Otolaryngol Head Neck Surg*. 2016;155(3):454-457.
- Zuniga S, Ebersole B, Jamal N. Improved swallow outcomes after injection laryngoplasty in unilateral vocal fold immobility. *Ear Nose Throat J*. 2018;97(8):250-256.
- Reder L, Bertelsen C, Angajala V, O'Dell K, Fisher L. Hospitalized patients with new-onset vocal fold immobility warrant inpatient injection Laryngoplasty. *Laryngoscope*. 2020. <https://doi.org/10.1002/lary.28606>.
- Zalvan CH, Yuen E, Thomas AM, Benson BE. Laryngeal electromyographic findings in a cohort of recalcitrant chronic

- neurogenic cough patients. *J Voice*. 2020. <http://dx.doi.org/10.1016/j.jvoice.2020.01.024>.
36. Friedman AD, Burns JA, Heaton JT, Zeitels SM. Early versus late injection medialization for unilateral vocal cord paralysis. *Laryngoscope*. 2010;120(10):2042-2046.
  37. Anderson TD, Mirza N. Immediate percutaneous medialization for acute vocal fold immobility with aspiration. *Laryngoscope*. 2001;111(8):1318-1321.
  38. Litts JK, Fink DS, Clary MS. The effect of vocal fold augmentation on cough symptoms in the presence of glottic insufficiency. *Laryngoscope*. 2018;128(6):1316-1319.
  39. Graboyes EM, Bradley JP, Meyers BF, Nussenbaum B. Efficacy and safety of acute injection laryngoplasty for vocal cord paralysis following thoracic surgery. *Laryngoscope*. 2011;121(11):2406-2410.
  40. Vila PM, Bhatt NK, Paniello RC. Early-injection laryngoplasty may lower risk of thyroplasty: a systematic review and meta-analysis. *Laryngoscope*. 2018;128(4):935-940.
  41. Lin RJ, Klein-Fedyshin M, Rosen CA. Nimodipine improves vocal fold and facial motion recovery after injury: a systematic review and meta-analysis. *Laryngoscope*. 2019;129(4):943-951.
  42. Rosen CA, Smith L, Young V, Krishna P, Muldoon MF, Munin MC. Prospective investigation of nimodipine for acute vocal fold paralysis. *Muscle Nerve*. 2014;50(1):114-118.
  43. Randolph GW, Kamani D. Intraoperative electrophysiologic monitoring of the recurrent laryngeal nerve during thyroid and parathyroid surgery: experience with 1,381 nerves at risk. *Laryngoscope*. 2017;127(1):280-286.
  44. Haugen BR, Alexander EK, Bible GM, et al. 2015 American Thyroid Association management guidelines for adult patients with thyroid nodules and differentiated thyroid cancer: the American Thyroid Association guidelines task force on thyroid nodules and differentiated thyroid cancer. *Thyroid*. 2016;26(1):1-133.
  45. Palazzo F. Pre and post-operative laryngoscopy in thyroid and parathyroid surgery. British Association of Endocrine and Thyroid Surgeons. *Consensus Statement*. 2010. Retrieved from [http://www.baets.org.uk/pages/Vocal\\_cord\\_check\\_consensus\\_document\\_2010\\_final.pdf](http://www.baets.org.uk/pages/Vocal_cord_check_consensus_document_2010_final.pdf). Accessed June 4, 2010.
  46. Haddad RI, Nasr C, Bischoff L, et al. NCCN guidelines insights: thyroid carcinoma, version 2.2018. *J Natl Compr Canc Netw*. 2018;16(12):1429-1440.
  47. Maher D, Goare S, Forrest E, Grodski S, Serpell JW, Lee JC. Routine preoperative laryngoscopy for thyroid surgery is not necessary without risk factors. *Thyroid*. 2019;29(11):1646-1652.
  48. Randolph GW, Kamani D. The importance of preoperative laryngoscopy in patients undergoing thyroidectomy: voice, vocal cord function, and the preoperative detection of invasive thyroid malignancy. *Surgery*. 2006;139:357-362.
  49. Farrag TY, Samlan RA, Lin FR, Tufano RP. The utility of evaluating true vocal fold motion before thyroid surgery. *Laryngoscope*. 2006;116:235-238.
  50. Sir VB, Lott DG, SCC A, Olimpia Cid M, Vera-Cruz PS, Zagalo C. Preoperative voice characteristics in thyroid patients. *J Voice*. 2020. <https://doi.org/10.1016/j.jvoice.2019.12.024>.
  51. Lombardi CP, Raffaelli M, D'Alatri L, et al. Voice and swallowing changes after thyroidectomy in patients without inferior laryngeal nerve injuries. *Surgery*. 2006;140(6):1026-1032. discussion 1032-1034.
  52. Park YM, Oh KH, Cho J-G, et al. Changes in voice- and swallowing-related symptoms after thyroidectomy: one-year follow-up study. *Ann Otol Rhinol Laryngol*. 2018;127(3):171-177.
  53. Randolph GW, Sritharan N, Song P, Franco R, Kamani D, Woodson G. Thyroidectomy in the professional singer-neural monitored surgical outcomes. *Thyroid*. 2015;25(6):665-671.
  54. Rosen CA, Mau T, Remacle M, et al. Nomenclature proposal to describe vocal fold motion impairment. *Eur Arch Otorhinolaryngol*. 2016;273(8):1995-1999.
  55. Cummings C, Flint P. Neurologic disorders of the larynx. In: Cummings CW, ed. *Cummings Otolaryngology—Head and Neck Surgery*. 4th ed. Pennsylvania: Mosby, Inc; 2005:854-859.
  56. Wu AP, Sulica L. Diagnosis of vocal fold paresis: current opinion and practice. *Laryngoscope*. 2015;125(4):904-908.
  57. Syamal MN, Benninger MS. Vocal fold paresis: a review of clinical presentation, differential diagnosis, and prognostic indicators. *Curr Opin Otolaryngol Head Neck Surg*. 2016;24(3):197-202.
  58. Harris G, O'Meara C, Pemberton C, et al. Vocal fold paresis - a debilitating and underdiagnosed condition. *J Laryngol Otol*. 2017;131(S2):S48-S52.
  59. Hydman J, Mattsson P. Collateral reinnervation by the superior laryngeal nerve after recurrent laryngeal nerve injury. *Muscle Nerve*. 2008;38(4):1280-1289.
  60. Mu L, Sanders I, Wu BL, Biller HF. The intramuscular innervation of the human interarytenoid muscle. *Laryngoscope*. 1994;104(1 Pt 1):33-39.
  61. Björck G, Margolin G, Måbäck GM, Persson JKE, Mattsson P, Hydman J. New animal model for assessment of functional laryngeal motor innervation. *Ann Otol Rhinol Laryngol*. 2012;121(10):695-699.
  62. Jansson S, Tisell L-E, Hagne I, Sanner E, Stenborg R, Svensson P. Partial superior laryngeal nerve (SLN) lesions before and after thyroid surgery. *World J Surg*. 1988;12(4):522-526.
  63. Neri G, Castiello F, Vitullo F, De Rosa M, Ciammetti G, Croce A. Post-thyroidectomy dysphonia in patients with bilateral resection of the superior laryngeal nerve: a comparative spectrographic study. *Acta Otorhinolaryngol Ital*. 2011;31(4):228-234.
  64. Teitelbaum BJ, Wenig BL. Superior laryngeal nerve injury from thyroid surgery. *Head Neck*. 1995;17(1):36-40.
  65. Jung SP, Kim SH, Bae SY, et al. A new subfascial approach in open thyroidectomy: efficacy for postoperative voice, sensory, and swallowing symptoms. A randomized controlled study. *Ann Surg Oncol*. 2013;20(12):3869-3876.
  66. Lombardi CP, Raffaelli M, De Crea C, et al. Long-term outcome of functional post-thyroidectomy voice and swallowing symptoms. *Surgery*. 2009;146(6):1174-1181.
  67. Arakawa-Sugueno L, Ferraz AR, Morandi J, et al. Videoendoscopic evaluation of swallowing after thyroidectomy: 7 and 60 days. *Dysphagia*. 2015;30(5):496-505.
  68. Scerrino G, Inviati A, Di Giovanni S, et al. Esophageal motility changes after thyroidectomy; possible associations with postoperative voice and swallowing disorders: preliminary results. *Otolaryngol Head Neck Surg*. 2013;148(6):926-932.
  69. Sengupta JN. An overview of esophageal sensory receptors. *Am J Med*. 2000;108(Suppl 4a):87S-89S.

70. Pereira JA, Girvent M, Sancho JJ, Parada C, Sitges-Serra A. Prevalence of long-term upper aerodigestive symptoms after uncomplicated bilateral thyroidectomy. *Surgery*. 2003;133(3):318-322.
71. Wu Y, Fang Q, Xu C, Li H. Association between postoperative cough and thyroidectomy: a prospective study. *BMC Cancer*. 2019;19:754.
72. de Araújo LF, Lopes LW, POC S, VJF P, de Farias VLL, EHM A. Sensory symptoms in patients undergoing thyroidectomy. *CoDAS*. 2017;29(3):e20150294.
73. Mau T, Pan H-M, Childs LF. The natural history of recoverable vocal fold paralysis: implications for kinetics of reinnervation. *Laryngoscope*. 2017;127(11):2585-2590.
74. De Virgilio A, Chang M-H, Jiang R-S, et al. Influence of superior laryngeal nerve injury on glottal configuration/function of thyroidectomy-induced unilateral vocal fold paralysis. *Otolaryngol Head Neck Surg*. 2014;151(6):996-1002.
75. Malmgren LT, Gacek RR. Histochemical characteristics of muscle fiber types in the posterior cricoarytenoid muscle. *Ann Otol Rhinol Laryngol*. 1981;90(5 Pt 1):423-429.
76. Malmgren LT, Jones CE, Bookman LM. Muscle fiber and satellite cell apoptosis in the aging human thyroarytenoid muscle: a stereological study with confocal laser scanning microscopy. *Otolaryngol Head Neck Surg*. 2001;125(1):34-39.
77. Chandrasekhar SS, Randolph GW, Seidman MD, et al. Clinical practice guideline: improving voice outcomes after thyroid surgery. *Otolaryngol Head Neck Surg*. 2013;148(Suppl. 6):S1-S37.
78. Kandil E, Mohamed S, Deniwar A, et al. Electrophysiologic identification and monitoring of the external branch of the superior laryngeal nerve during thyroidectomy. *Laryngoscope*. 2015;125:1996-2000.
79. Kim SW, Kim ST, Park SH, et al. Voice examination in patients with decreased high pitch after thyroidectomy. *Indian J Head Neck Surg*. 2012;64(2):120-130.
80. Rosen C, Lee AS, Osborne J, Zullo T, Murray T. Development and validation of the voice handicap Index-10. *Laryngoscope*. 2004;114(9):1549-1556.
81. Cohen SM, Statham M, Rosen C, Zullo T. Development and validation of singing voice Handicap-10. *Laryngoscope*. 2009;119:1864-1869.
82. Arffa R, Krishna P, Gartner-Schmidt J, Rosen C. Normative values for the voice handicap index- 10. *J Voice*. 2012;26(4):462-465.
83. Krekeler B, Wendt E, Macdonald C, et al. Patient-reported dysphagia after thyroidectomy: a qualitative study. *JAMA Otolaryngol Head Neck Surg*. 2018;144(4):342-348.
84. Belafsky PC, Mouadeb D, Rees C, et al. Validity and reliability of the eating assessment tool (EAT-10). *Ann Oto Rhinol Laryn*. 2008;117(12):919-924.
85. Cheney DM, Siddiqui T, Litts JK, Kuhn MA, Belafsky PC. The ability of the 10-item eating assessment tool (EAT-10) to predict aspiration risk in persons with dysphagia. *Ann Oto Rhinol Laryn*. 2015;124(5):351-354.
86. Kaspar, Kala, and Olle Ekberg. Identifying vulnerable patients: role of the EAT-10 and the multidisciplinary team for early intervention and comprehensive dysphagia care. *Stepping stones to living well with dysphagia*. Vol 72, Karger Publishers, 2012. 19-31.
87. Langmore SE, Kenneth SM, Olsen N. Fiberoptic endoscopic examination of swallowing safety: a new procedure. *Dysphagia*. 1988;2(4):216-219.
88. Patel KN, Yip L, Lubitz CC, et al. The American Association of Endocrine Surgeons Guidelines for the definitive surgical Management of Thyroid Disease in adults. *Ann Surg*. 2020;271(3):e21-e93.
89. Palmer JB, Kuhlemeier KV, Tippett DC, Lynch C. A protocol for the videofluorographic swallowing study. *Dysphagia*. 1993;8(3):209-214.
90. Haugen BR, Sawka AM, Alexander EK, et al. American Thyroid Association guidelines on the Management of Thyroid Nodules and Differentiated Thyroid Cancer Task Force Review and recommendation on the proposed renaming of encapsulated follicular variant papillary thyroid carcinoma without invasion to noninvasive follicular thyroid neoplasm with papillary-like nuclear features. *Thyroid*. 2017;27(4):481-483.
91. Kaszuba SM, Garrett CG. Stroboscopedaryngoscopy and laboratory voice evaluation. *Otolaryngol Clin North Am*. 2007;40(5):991-1001. vi.
92. Krausert CR, Olszewski AE, Taylor LN, McMurray JS, Dailey SH, Jiang JJ. Mucosal wave measurement and visualization techniques. *J Voice*. 2011;25(4):395-405.
93. Bless DM, Hirano M, Feder RJ. Videostroboscopic evaluation of the larynx. *Ear Nose Throat J*. 1987;66(7):289-296.
94. Simpson CB, Cheung EJ, Jackson CJ. Vocal fold paresis: clinical and electrophysiologic features in a tertiary laryngology practice. *J Voice*. 2009;23(3):396-398.
95. Tsai V, Celmer A, Berke GS, Chhetri DK. Videostroboscopic findings in unilateral superior laryngeal nerve paralysis and paresis. *Otolaryngol Head Neck Surg*. 2007;136(4):660-662.
96. Roy N, Smith ME, Houtz DR. Laryngeal features of external superior laryngeal nerve denervation: revisiting a century-old controversy. *Ann Oto Rhinol Laryn*. 2011;120(1):1-8.
97. Husain S, Sadoughi B, Mor N, Sulica L. Time course of recovery of iatrogenic vocal fold paralysis. *Laryngoscope*. 2019;129(5):1159-1163.
98. Husson O, Haak HR, Oranje WA, Mols F, Reemst PH. Van de poll-Franse, LV. Health-related quality of life among thyroid cancer survivors: a systematic review. *Clin Endocrinol (Oxf)*. 2011;75(4):544-554.
99. Jones SM, Carding PN, Drinnan MJ. Exploring the relationship between severity of dysphonia and voice-related quality of life. *Clin Otolaryngol*. 2006;31(5):411-417.
100. Wilson JA, Deary IJ, Millar A, Mackenzie K. The quality of life impact of dysphonia. *Clin Otolaryngol Allied Sci*. 2002;27(3):179-182.
101. Lee JC, Breen D, Scott A, et al. Quantitative study of voice dysfunction after thyroidectomy. *Surgery*. 2016;160(6):1576-1581.
102. Minuto MN, Reina S, Monti E, Ansaldo GL, Varaldo E. Morbidity following thyroid surgery: acceptable rates and how to manage complicated patients. *J Endocrinol Invest*. 2019;42(11):1291-1297.

**How to cite this article:** Dhillon VK, Randolph GW, Stack BC Jr, et al. Immediate and partial neural dysfunction after thyroid and parathyroid surgery: Need for recognition, laryngeal exam, and early treatment. *Head & Neck*. 2020;42:3779-3794. <https://doi.org/10.1002/hed.26472>