

Massive organized intrapericardial hematoma mimicking constrictive pericarditis

Thomas E. Dunlap, M.D., Richard P. Sorokin, M.D.,
Kurt W. Mori, M.D., and Kishor D. Popat, M.D.
Westland, Mich.

Blunt and penetrating chest trauma as a cause of hemopericardium with subsequent cardiac tamponade and/or constrictive pericarditis due either to the presence of intrapericardial clotted blood or chronic inflammation has been well described.¹⁻³ We describe here an unusual patient who presented with massive organized intrapericardial hematoma with the hemodynamic characteristics of chronic constrictive pericarditis 4 years after suffering blunt chest trauma. The diagnostic studies, including two-dimensional echocardiography and cardiac CT scan which aided in establishing the preoperative diagnosis of the etiology of the constriction, are demonstrated.

A 25-year-old man with a 7-month history of ankle swelling and a 2-month history of abdominal swelling was admitted for evaluation. Four years prior to admission, the patient was involved in a motor vehicle accident in which he suffered chest trauma from the steering wheel. No chest x-ray examination was obtained at that time. He described hemoptysis associated with that incident. During the 3-½ year interim he denied any subsequent chest trauma. His major symptom at the time of admission was dyspnea on exertion. On physical examination he appeared chronically ill. There was marked jugular venous distention with prominent x and y descent. An early diastolic sound was present on cardiac examination, and the point of maximal intensity was only faintly palpable in the sixth intercostal space at the anterior axillary line. There was marked tense ascites, the liver was palpable 13 cm below the right costal margin and was not pulsatile, and trace pretibial edema was present.

An ECG demonstrated sinus tachycardia and low voltage. Chest x-ray examination revealed bilateral costophrenic angle blunting and cardiomegaly. The left heart border was markedly irregular and "tented" (Fig. 1). Cardiac catheterization revealed elevated end-diastolic pressures with equalization of diastolic pressures between the right atrium, right ventricle, and left ventricle. The intracardiac pressures were (mm Hg): right atrium (mean 15), right ventricle (30/15) with characteristic diastolic dip and plateau, pulmonary artery (30/19), and pulmonary artery wedge (mean 19). No significant (greater than 10 mm Hg) respiratory variation in pressures was noted. Cineangiography by contrast injection into the low right

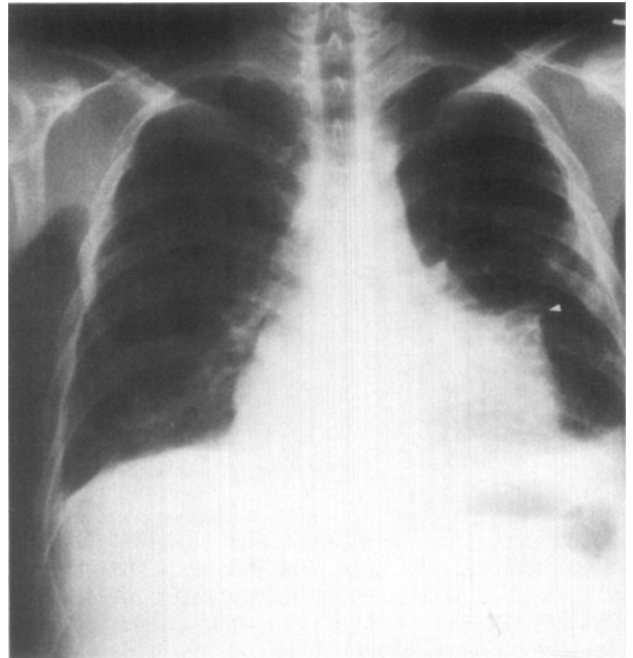


Fig. 1. Chest x-ray. Posteroanterior view showing cardiomegaly with "tenting" (arrowhead) of the left cardiac border.

atrium showed a dilated inferior vena cava, straightening of the right atrial border, and restriction of contrast flow into the right ventricle. Contrast passed almost directly from the right atrium to the right ventricular outflow tract (Fig. 2). Left ventricular cineangiography revealed an akinetic left heart border which was distant from the left ventricular chamber. The left ventricular chamber was small and contracted normally (Fig. 3).

A two-dimensional echocardiogram demonstrated an echolucent mass that was larger than the heart and posterior to the left ventricle. It extended beyond the apex of the left ventricle (Fig. 4) and appeared to compress the left and right ventricles. During real time viewing, expansion of the left ventricle and right ventricle appeared to be restricted. A CT scan was performed. A non-enhancing low density (20 Hn units) mass was demonstrated arising within a thickened pericardium lateral and inferior to the left ventricle (Fig. 5). A layer of epicardial fat was identified between the myocardium and pericardium. The density and morphologic appearance of the lesion were suggestive of pericardial hematoma. Other diagnostic possibilities compatible with the CT appearance were less likely, but included pericardial cyst,⁴ pseudoaneurysm of the left ventricle with closure,⁵ and neoplasm arising in the pericardium.

Following the above evaluation, midline sternotomy was performed. An 8 × 10 cm semiorganized hematoma of the pericardium was found. It extended from the anterolateral aspect of the left ventricle to the cardiac apex, and was adherent to the left ventricle and parietal pericardium. The pericardium was slightly thickened but did not

From the Division of Cardiology, Department of Internal Medicine, and the Department of Radiology, The University of Michigan and Wayne County General Hospital.

Received for publication June 23, 1981; accepted July 10, 1981.

Reprint requests: Thomas E. Dunlap, M.D., 1111 Sonoma Ave., Santa Rosa, CA 95405.

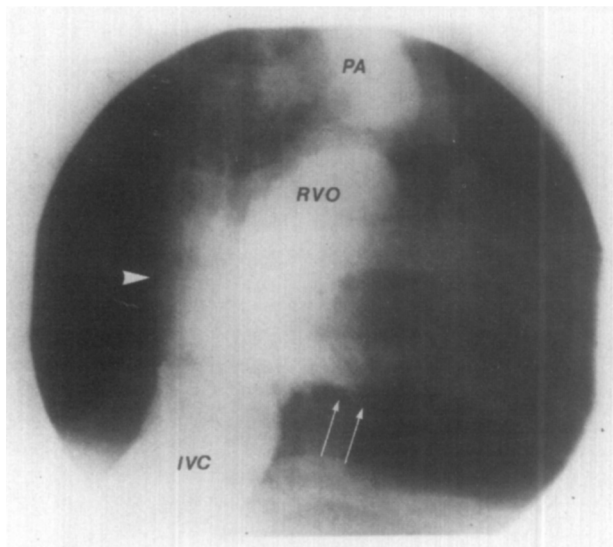


Fig. 2. Cineangiogram with contrast injection into the low right atrium; the right heart border is straightened (*arrowhead*). The right ventricle does not fill (*arrows*) and contrast passes into the right ventricular outflow tract; the inferior vena cava is dilated. IVC = inferior vena cava; PA = main pulmonary artery; RVO = right ventricular outflow tract.

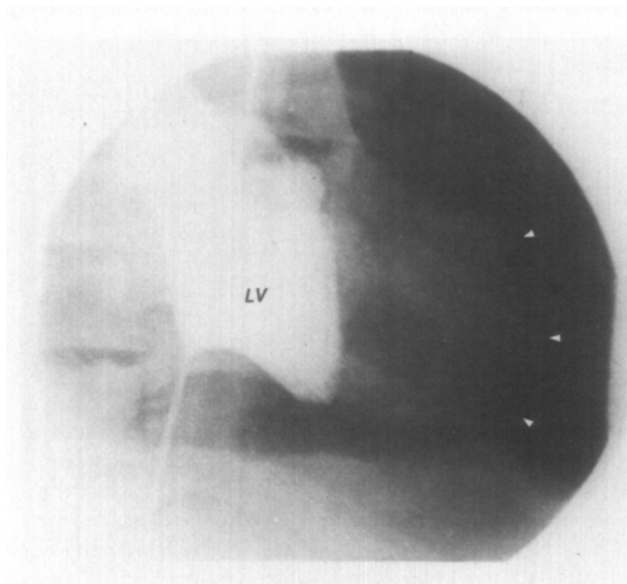


Fig. 3. Cineangiogram with contrast injection into the left ventricle. Note the distance from the lateral wall and apex of the left ventricle to the left edge of the cardiac silhouette (*arrowheads*). LV = left ventricle.

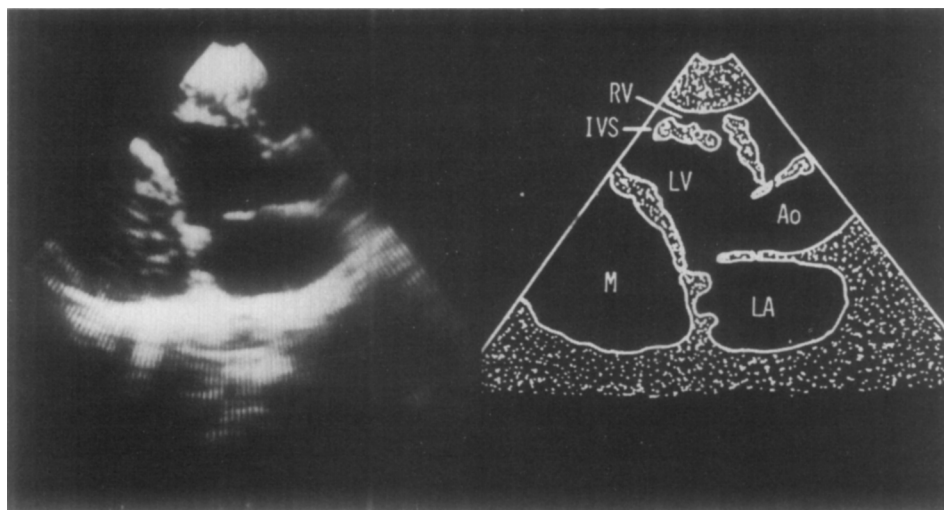


Fig. 4. Two-dimensional echocardiogram in the parasternal long-axis view showing a large mass posterior to the left ventricle, distorting the left and right ventricles. Ao = aorta; IVS = intraventricular septum; LA = left atrium; LV = left ventricle; M = mass; RV = right ventricle.

appear to be constrictive. Overall heart size was normal and ventricular wall motion appeared normal. Gross examination of the surgical specimen demonstrated laminated fibrous tissue. The surface was covered with a fibrin meshwork and the cut surface was yellow. Microscopic examination revealed fibrosis with hemosiderin laden macrophages. The entire study was consistent with organized hematoma.

Review of previous case reports of nonpenetrating cardiac trauma do not cite massive intrapericardial hematoma as a possible late complication.^{6,7} This unusual case demonstrates that intrapericardial hematoma several years following chest trauma can present as a pericardial mass with clinical features resembling constrictive pericarditis. The evaluation of a mediastinal mass contiguous with the heart presents diagnostic difficulties. The etiology

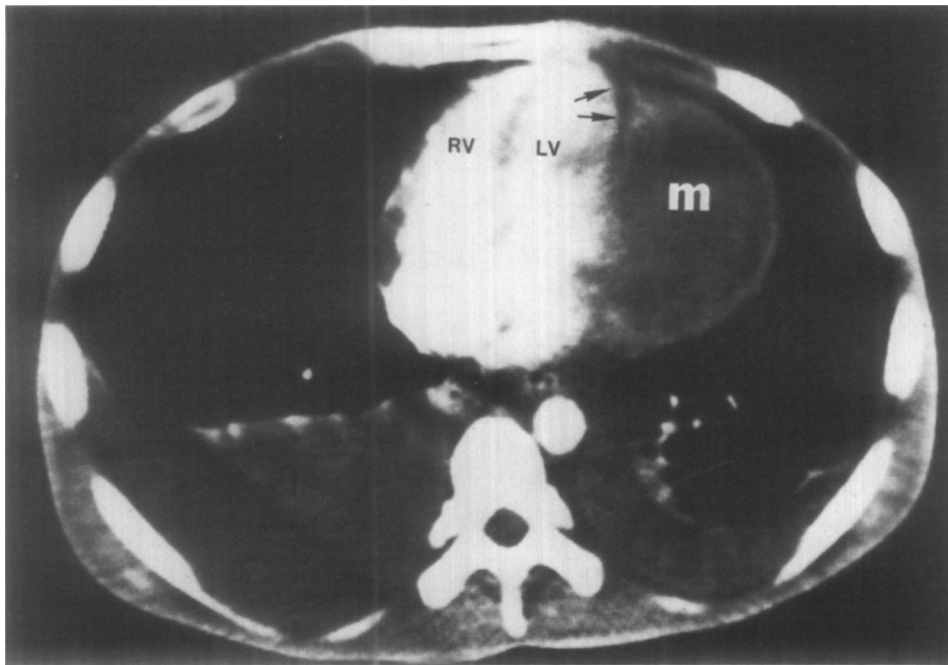


Fig. 5. CT scan showing a 1 cm thick axial slice from a series of rapid sequence slices through the heart. A nonenhancing mass lesion of low density (20 HN units) is seen. Note the layer of epicardial fat (arrows) between the mass and the heart anteriorly. Bilateral pleural effusions are also present. *LV* = left ventricle; *m* = mass; *RV* = right ventricle.

gy of the mass, its relation to contiguous structures, and its effect on those structures can be difficult to assess. Percutaneous needle biopsy can give a tissue diagnosis but requires a high degree of technical expertise and has the potential for significant morbidity.

The diagnostic studies presented here allowed us to make several important preoperative judgments. The two-dimensional echocardiogram showed in real time the characteristics of the mass and its relation to other cardiac structures and its effect on function, revealing that the mass compressed the ventricles, resulting in the signs and symptoms of constrictive pericarditis. The cardiac CT scan added significant information to the evaluation. CT radiography has been shown to be valuable in defining graft patency in problems involving coronary artery bypass grafts,⁸ in evaluating congenital heart lesions, and in demonstrating areas of myocardium involved in myocardial infarction.⁹ This case extends the clinical utility of cardiac CT scanning to the evaluation of a cardiac mass. The demonstration that the mass was intrapericardial, separated from the myocardium by subepicardial fat, suggested that it was not due to a tumor of the myocardium. The density of the mass on CT suggested a pericardial hematoma; although other diagnostic possibilities compatible with the CT appearance including pericardial cyst, pseudoaneurysm with closure, and neoplasm arising in the pericardium were considered, they were felt to be less likely. Cardiac catheterization and ventriculography confirmed the diagnosis of cardiac constriction and the

presence of a mass but were less useful than the CT scan in establishing the exact location and size of the mass. The noninvasive information allowed the surgical team to plan an optimal approach to excising the mass. Although cardiac CT scanning in the evaluation of a cardiac mass is as yet limited, the clinical experience presented in this report suggests that CT scanning may provide unique information for this purpose.

REFERENCES

1. Ehrenhaft JI, Taber RE: Hemopericardium and constrictive pericarditis. *J Thorac Surg* **24**:355, 1952.
2. Shabetai R: The pathophysiology of cardiac tamponade and constriction. *Cardiovasc Clin* **76**:67, 1976.
3. Little WC: Clotted hemopericarditis with the hemodynamic characteristics of constrictive pericarditis. *Am J Cardiol* **45**:386, 1980.
4. Pugatch RD, Braxer JH, Robbins AH, Faling LJ: CT diagnosis of pericardial cyst. *Am J Roentgenol* **131**:515, 1978.
5. Vix VA, Killen DA: Traumatic pseudoaneurysm of the left ventricle. *Am J Roentgenol* **104**:413, 1968.
6. Liedtke AJ, DeMuth WE: Nonpenetrating cardiac injuries; a collective review. *AM HEART J* **86**:687, 1973.
7. Jackson DH, Murphy GW: Nonpenetrating cardiac trauma. *Mod Concepts Cardiovasc Dis* **45**:123, 1976.
8. Brundage BH, Lipton MJ, Herfkens RS, Benninger WH, Redington RW, Chatterjee K, Carlsson E: Detection of patent coronary bypass grafts by computed tomography. *Circulation* **61**:826, 1980.
9. Huber DJ, Lapray JF, Hessel SJ: In vivo evaluation of experimental myocardial infarcts by ungated computed tomography. *Am J Roentgenol* **136**:469, 1981.