

## Short communication

# CEREBRAL BIGEMINY: ALTERNATING PERIODIC EPILEPTIFORM DISCHARGES<sup>1</sup>

MICHAEL S. ALDRICH<sup>2</sup> and JAMES E. PUGH

*Department of Neurology, University of Michigan Medical Center, Ann Arbor, MI 48109 (U.S.A.)*

(Accepted for publication: March 1, 1985)

**Summary** The EEG of a patient in coma after an anoxic event showed brief episodes in which two distinct epileptiform discharges of different amplitudes alternated with each other at regular intervals of approximately 1 sec. We have used the term 'cerebral bigeminy' to describe this pattern because its electrographic appearance is similar to cardiac bigeminy. The pattern was present for only part of the entire tracing and was not seen on earlier or later EEGs. This finding suggests that under appropriate circumstances periodic EEG events can occur as a result of reciprocal excitation of spike generators.

**Keywords:** EEG — periodic EEG — periodic lateralized epileptiform discharges (PLEDs) — cerebral bigeminy

Periodic or pseudoperiodic EEG patterns are characterized by bursts of high voltage slow waves, with sharp waves, spikes, or combinations of these, against a background of relatively low amplitude activity. They can occur in a number of disease states including but not limited to subacute sclerosing panencephalitis, Creutzfeldt-Jakob disease, acute viral encephalitis and anoxic encephalopathy. Unilateral pseudoperiodic discharges have been described by a number of terms including periodic lateralized epileptiform discharges (PLEDs) (Chatrjian et al. 1964), pseudoperiodic lateralized paroxysmal discharges (Markand and Daly 1971), and can be seen in a variety of pathologic processes including vascular insults, brain tumors, and hypoxic injury, but the pathophysiology underlying the discharges and their periodicity remains unknown. Bilateral independent PLEDs have also been described (De la Paz and Brenner 1981) but reports of periodic discharges of alternating morphology or amplitude are scarce. Periodic discharges of alternating morphology limited to a 20 sec epoch are shown in Fig. 4 of Cobb's report (1979) on the serial EEG findings of a patient with herpes simplex encephalitis. An earlier EEG from the same patient was reported to have 'two phase-locked foci,' one in the right anterior temporal region and one more posteriorly. In 1 of the 5 patients with seizures after anoxia described by Madison and Niedermeyer (1970), two similar but distinct spike-and-slow-wave complexes occurred alternately for several seconds and are shown in Fig. 6 of that paper. Except for these 2 cases, we have found no descriptions of alternating periodic discharges in the literature; several large series of lateralized

periodic discharges make no mention of this phenomenon (Chatrjian et al. 1964; Markand and Daly 1971; Schwartz et al. 1973; Dauben and Adams 1977; Erkulvrawatr 1977; Porecha and Reilly 1977; Kuroiwa and Ceesia 1980; De la Paz and Brenner 1981). The phenomenon may be more common than is realized, however, since its transient nature may result in its presence being overlooked.

In this paper, we report a patient whose EEG demonstrates pseudoperiodic epileptiform discharges of alternating larger and smaller amplitude, and we suggest that this alternating rhythm, which we term cerebral bigeminy, may help elucidate the mechanisms responsible for periodic EEG discharges.

## Report of a case

A 53-year-old white male was admitted to the Ann Arbor Veterans Administration Medical Center in June 1982 with cavitating pneumonia and fever. On addition his neurologic examination was normal. Over the next 2 weeks low grade fever and hemoptysis continued despite antimicrobial medications. On the twentieth hospital day he had a prolonged generalized tonic-clonic seizure followed by coma and intermittent clonic movements of the right arm and right side of the face. He received phenytoin, phenobarbital, and diazepam after which the clonic movements stopped but the patient remained in coma.

During the next several hours he had frequent tonic-clonic seizures involving either or both arms and his face. Between the seizures, the eyes were in midposition with bilateral rhythmic upward jerks occurring about once/sec, followed by slow return to midline; these eye movements were associated with bilateral low amplitude clonic movements of the orbicularis oculi. Corneal and pupillary reflexes were present but oculovestibular reflexes were absent. Muscle tone was flaccid with

<sup>1</sup> Presented in part at the American EEG Society Meeting, New Orleans, LA, October 21, 1983.

<sup>2</sup> Address all correspondence and reprint requests to: Michael S. Aldrich, M.D., Department of Neurology, University of Michigan Medical Center, 1405 East Ann St., N1729 APH-1 Box M011, Ann Arbor, MI 48109, U.S.A.

hypoactive reflexes and no plantar responses. Cerebrospinal fluid and brain CT examinations were unremarkable. An EEG was markedly abnormal: spikes, polyspikes, and spike-and-slow waves occurred throughout the recording over both hemispheres with a right hemisphere predominance. There were occasional 1–2 sec periods of extremely low voltage activity. During the next 24 h intermittent eye movements continued, but the neurologic examination was otherwise unchanged. A repeat EEG showed episodes of periodic epileptiform discharges of alternating larger and smaller amplitude (Fig. 1), which were not associated with any clinical phenomena.

The paroxysmal discharges are seen throughout both hemispheres but are lateralized to the right. A spike or polyspike-and-slow-wave discharge ( $A_1$ ) occurs with greatest amplitude over the right front-temporal region. A second polyspike-and-slow-wave discharge ( $A_2$ ) has similar morphology but is somewhat lower in amplitude than the  $A_1$  discharge. For 3–4 min of the recording the  $A_1$ - $A_2$  and  $A_2$ - $A_1$  intervals are remarkably consistent at 1150–1250 msec and 850–950 msec respectively (measured from the negative peak of the initial spike of each discharge). This alternating periodicity is interrupted occasionally by 1–2 sec periods of generalized suppression. The alternating pattern is present for only a few minutes of the total recording time. During the remainder of the recording, the  $A_1$  pseudoperiodic discharge continued and the  $A_2$  discharge of the recording was present intermittently and was not time-locked to the  $A_1$  discharge.

Four hours after the second EEG the patient had a prolonged generalized tonic-clonic seizure. An EEG 2 days later displayed low voltage delta activity with occasional 2 sec periods of voltage attenuation but no epileptiform activity. Pulmonary function deteriorated over the next several days and the patient died on the 30th hospital day, 10 days after the onset of coma. Pathologic examination demonstrated extensive

organizing pneumonia in the left lung with scattered abscesses. Examination of the brain showed evidence of severe bihemispheric cortical and subcortical hypoxic injury, and 3 small infarcts in the left hemisphere. There were no brain-stem infarcts.

### Comment

We believe that the EEG characteristics seen in our case have enough in common with the electrocardiographic pattern of cardiac ventricular bigeminy to justify calling the phenomenon *cerebral bigeminy*, and we believe that there may be similar pathogenetic mechanisms underlying these analogous cardiac and cerebral rhythms. Cardiac ventricular bigeminy is a heart rhythm in which the sinus beat alternates with a premature ventricular contraction; it is usually seen in patients with either digitalis intoxication or structural heart disease. Ventricular bigeminy probably results from the phenomenon of re-entry excitation in which there is slowed conduction and unidirectional block of a portion of the myocardium, instability of a ventricular ectopic pacemaker, and enhanced depolarization of the ectopic focus by the preceding beat (Sobel and Braunwald 1977).

An analogous mechanism in the brain could explain the pattern we have observed and would be consistent with hypotheses about the origin of periodic EEG patterns (Gloor et al. 1968; Cobb 1979) as well as hypotheses about the role of recurrent excitation in epileptogenesis (Traub and Wong 1983). Gloor et al. (1968) noted that periodic discharges were found with diffuse grey matter disease and with combined grey and white matter disease. He proposed that the periodicity was due to an abnormal functional state of the CNS such that easy generalization of neuronal discharges from synchronous affer-

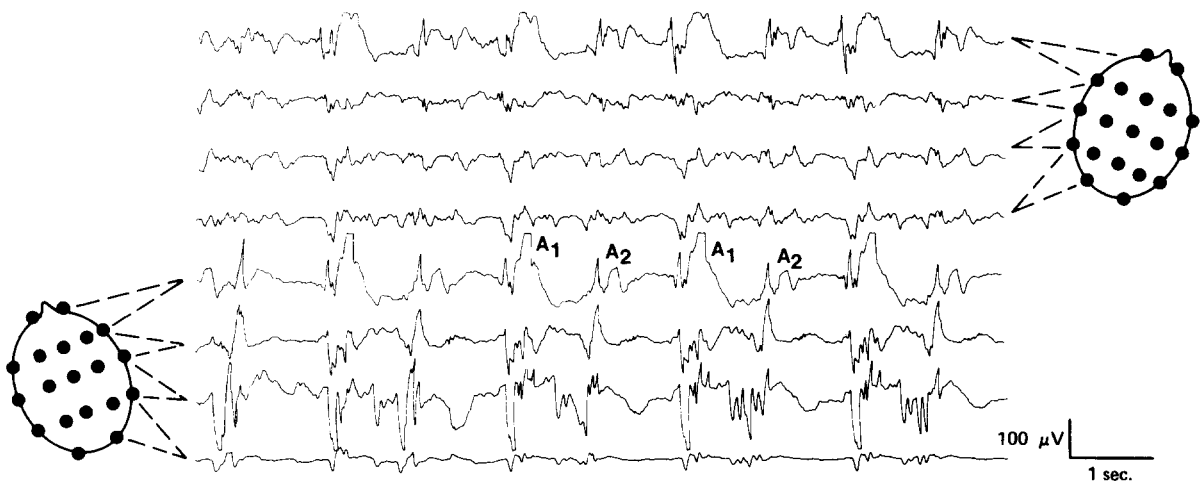


Fig. 1. Two distinct polyspike and slow-wave discharges ( $A_1$ ,  $A_2$ ) occur alternately at regular intervals. The  $A_1$ - $A_2$  interval averages 1200 msec while the  $A_2$ - $A_1$  interval averages 900 msec.

ent bombardment is followed by a prolonged refractory period. Cobb (1979) suggested that periodicity represents the time constant of recovery of an electrochemical process at the cellular level. He proposed that groups of affected cells firing at an abnormally slow recruit others with a tendency to fire at the same or longer interval.

Alternating periodic discharges could result in a similar way if a large area of cerebral injury resulted in suppression of intrinsic rhythms and an increase in the refractory period of neuronal circuits, thereby allowing the expression of two ectopic (epileptic) foci or two alternate pathways from one focus. Each focus could then reciprocally excite the other while other neuronal circuits remained refractory. The alternating discharges would continue only as long as the re-entrant pathways were not interrupted by other neuronal activity, or until the speed of conduction exceeded the refractory intervals of the alternate focus. Our observations of alternating periodic discharges with consistent interpeak intervals are consistent with the hypothesis that under appropriate circumstances periodic EEG events can occur as a result of reciprocal excitation of spike generators. Studies on additional patients showing this phenomenon, or on experimental models of periodic epileptiform activity, may help to substantiate this hypothesis.

### Résumé

*Bigéminie cérébrale: décharges épileptiformes périodiques alternantes*

L'EEG d'un patient en coma après un accident anoxique a montré de brefs épisodes au cours desquels alternaient à intervalles réguliers d'environ 1 sec, deux types de décharges épileptiformes distinctes, d'amplitude différente. Nous avons utilisé le terme de 'bigéminie cérébrale' pour décrire ce pattern dont l'apparence électrographique est semblable à la bigéminie cardiaque. Ce pattern n'était présent que dans une portion du tracé et n'était pas observé sur des EEG plus précoces ou plus tardifs. Ce résultat suggère que dans des circonstances appropriées, des événements EEG périodiques peuvent résulter d'une excitation réciproque des générateurs de pics.

### References

Chatrian, G.E., Shaw, C.M. and Leffman, H. The significance of periodic lateralized epileptiform discharges in EEG: an

- electrographic, clinical and pathological study. *Electroenceph. clin. Neurophysiol.*, 1964, 17: 177-193.
- Cobb, W.A. Evidence on the periodic mechanism in herpes simplex encephalitis. *Electroenceph. clin. Neurophysiol.*, 1979, 46: 345-350.
- Dauben, R.D. and Adams, A.H. Periodic lateralized epileptiform discharge in EEG: a review with special attention to etiology and recurrence. *Clin. Electroenceph.*, 1977, 8: 116-124.
- De la Paz, D. and Brenner, R.P. Bilateral independent periodic lateralized epileptiform discharges. Clinical significance. *Arch. Neurol. (Chic.)*, 1981, 38: 713-715.
- Erkulvratr, S. Occurrence, evolution and prognosis of periodic lateralized epileptiform discharges in EEG. *Clin. Electroenceph.*, 1977, 8: 89-99.
- Gloor, P., Kalabay, O. and Giard, N. The electroencephalogram in diffuse encephalopathies: electroencephalographic correlates of grey and white matter lesions. *Brain*, 1968, 91: 779-802.
- Kuroiwa, Y. and Celesia, G.G. Clinical significance of periodic EEG patterns. *Arch. Neurol. (Chic.)*, 1980, 37: 15-20.
- Madison, D. and Niedermeyer, E. Epileptic seizures resulting from acute cerebral anoxia. *J. Neurol. Neurosurg. Psychiat.*, 1970, 33: 381-386.
- Markand, O.N. and Daly, D.D. Pseudoperiodic lateralized paroxysmal discharges in electroencephalogram. *Neurology (Minneapolis)*, 1971, 21: 975-981.
- Porecha, H.P. and Reilly, E.L. Clinical correlations of periodic lateralized epileptiform discharges. *Clin. Electroenceph.*, 1977, 8: 191-202.
- Schwartz, M.S., Prior, P.F. and Scott, D.F. The occurrence and evolution in the EEG of a lateralized periodic phenomenon. *Brain*, 1973, 96: 613-622.
- Sobel, B.E. and Braunwald, E. Cardiac dysrhythmias. In: G.W. Thorn, R.D. Adams, E. Braunwald, K.J. Isselbacher and R.G. Petersdorf (Eds.), *Harrison's Principles of Internal Medicine*, 8th edition. McGraw-Hill, New York, 1977: 1200-1201.
- Traub, R.D. and Wong, R.K.S. Synaptic mechanisms underlying interictal spike initiation in a hippocampal network. *Neurology (Minneapolis)*, 1983, 33: 257-266.