

Hypersensitivity and streptokinase

SIR,—A natural experiment is underway in the widespread treatment of patients with streptokinase (SK) to produce thrombolysis after acute myocardial infarction. The SK enzymes present in commercial products are derived from cultures of *Streptococcus equisimilis* (Lancefield group C), and the side-effects now being reported are relevant to research on streptococcal diseases.

Dr Callan and others (Jan 13, p 106) describe delayed hypersensitivity reactions after SK therapy. The illness in such patients features a diffuse vasculitis with rash, fever, arthralgia, proteinuria, haematuria, and sometimes impaired renal function. Immediate hypersensitivity reactions are more common than delayed reactions after SK therapy but they may be suppressed by hydrocortisone.¹ In ten patients studied by Dr Argent and Dr Adams (Jan 13, p 106) symptomless proteinuria and haematuria associated with coarse granular casts in the urine occurred in all cases 4 h after SK administration, clearing by 48 h. Antibodies to SK develop in most patients treated with SK, as reported by Dr Jalihal and Mr Morris but their role in the above complications is not yet clear.

A variant SK enzyme with special affinity for the glomerular basement membrane, nephritis strain-associated protein (NSAP), is a strong contender as the pathogenic agent in glomerulonephritis developing after *Strep pyogenes* infection.² Endostreptosin (ESS), another candidate,³ is thought to be an intracellular precursor of NSAP. These substances are thought to be deposited on the basement membrane with subsequent coating by antibody and complement, leading to the derangement of glomerular function; high levels of antibody to NSAP, ESS, and SK are found in patients with acute post-streptococcal nephritis.^{4,5} It is not known whether pre-existing antibody would protect against the development of nephritis but prospects for a vaccine have been discussed.⁶ Recent isolates of Lancefield group C and G streptococci from patients with nephritis have been shown to produce ESS or molecular variants of NSAP.^{6,7} In an intriguing case-report severe crescentic glomerulonephritis with cutaneous purpura developed in a patient 33 days after SK therapy for acute myocardial infarction in 13 days after an intercurrent group G streptococcal pharyngitis,⁸ perhaps SK-induced antibody worsened the situation in this patient.

The "dose" of SK received by the patient in natural streptococcal infection is likely to be much less, and delivered more slowly, than it is in SK therapy. These factors, together with the different biological properties of SK enzymes, might lead to different patterns of injury to the vessel walls and glomerulus. The hypersensitivity effects after therapeutic injection of SK might also throw some light on the relation between streptococci and skin diseases such as acute guttate psoriasis, erythema multiforme, and urticaria; streptococcal products inducing vasculitis, such as SK, might play a part in triggering these rashes.

Department of Microbiology,
Harrogate General Hospital,
Harrogate HG2 7ND, UK

MICHAEL BARNHAM

- Payne ST, Hosker HSR, Allen MB, Bradbury H, Page RL. Transient impairment of renal function after streptokinase therapy. *Lancet* 1989; ii: 1398.
- Johnston KH, Zabriskie JB. Purification and partial characterization of the nephritis strain-associated protein from *Streptococcus pyogenes*, group A. *J Exp Med* 1986; **163**: 697-712.
- Cronin W, Deol H, Azadegan A, Lange K. Endostreptosin: isolation of the probable immunogen of acute post-streptococcal glomerulonephritis. *Clin Exp Immunol* 1989; **76**: 198-203.
- Ohkuni H, Friedman J, van de Rijn I, Fischetti VA, Poon-King T, Zabriski JB. Immunological studies of post-streptococcal sequelae: serological studies with an intracellular protein associated with nephritogenic streptococci. *Clin Exp Immunol* 1983; **54**: 185-93.
- Domnisoru L, Ionescu M, Donea E, Ploeanu G, Tirjoianu E. The dynamics of antistreptokinase and serum complement in poststreptococcal glomerulonephritis. *Med Interne* 1975; **27**: 359-64.
- Barnham M, Thornton TJ, Lange K. Nephritis caused by *Streptococcus zooepidemicus* (Lancefield group C). *Lancet* 1983; i: 945-48.
- Gnann JW, Gray BM, Griffin FM, Dismukes WE. Acute glomerulonephritis following group G streptococcal infection. *J Infect Dis* 1987; **156**: 411-12.
- Murray N, Lyons J, Chappell M. Crescentic glomerulonephritis: a possible complication of streptokinase treatment for myocardial infarction. *Br Heart J* 1986; **56**: 483-85.

Cyclosporin wash for oral lichen planus

SIR,—Cyclosporin, when used systemically, has proved helpful in lichen planus.^{1,2} Unfortunately, when given by this route, cyclosporin has adverse effects that limit its use in skin diseases.³ Lichen planus affecting the oral cavity is especially difficult to treat and remissions are short-lived even when systemic corticosteroids and retinoids are used. Most topical agents are little more than palliative. We have been exploring the value of topical cyclosporin in patients with oral lichen planus.

Five women and one man aged 44-76 (mean 54) years with biopsy proven oral lichen planus were enrolled. They had had the disease for 2 years on average (range 3 months to 5 years). Topical medication was halted 2 weeks, and systemic medications 4 weeks, before the start of the study. The patients gave informed consent and the study was approved by the University of Michigan institutional review board.

In an open study patients used cyclosporin 100 mg/ml (the standard formulation for oral systemic administration). They were told to swish 5 ml (500 mg) in the oral cavity and to spit it out after 5 min. No eating or drinking was then permitted for 30 min. The treatment was repeated three times daily for 8 weeks. The same physician evaluated the patient before therapy and then in weeks 1, 2, 3, 4, 6, and 8 on a scale from 0 (no clinical disease) to 3 (severe disease). Erythema, and reticulation were assessed on this scale for every lesion erosion. A mean erosion score was calculated by summing erosion scores and dividing by the number of lesions with erosion. This was done for erythema and reticulation also. The patients graded their symptoms on a scale of 0 (no pain) to 3 (severe discomfort).

Whole blood cyclosporin levels were measured by high performance liquid chromatography (HPLC) 1-4 h after swishing and expectorating and routine laboratory tests were done at every visit. Representative lesions were photographed at baseline, after 4 weeks of therapy, and upon completion of the study. In four patients, 4 mm punch biopsies were done on affected buccal mucosa before and at the end of cyclosporin treatment. Immunoperoxidase staining⁴ of 5 µm cryostat sections was performed with a 'Vectastain ABC' kit (Vector Laboratories) and the following panel of monoclonal antibodies: RR 1/1 (from Dr T. Springer, Dana Farber Cancer Institute, Boston) for ICAM-1; L243 (Becton Dickinson) for HLA-DR; Leu10 (Becton Dickinson) for HLA-DQ; and T11 (Coulter Immunology) for CD2.

All patients improved in all categories. Erythema scores fell from 2.0 (0.2) at baseline to 0.1 (0.0) after 8 weeks of topical cyclosporin ($p=0.03$); erosion scores fell from 2.4 (0.5) to 0.3 (0.2) (not significant, $n=4$ only), and reticulation scores decreased from 1.7 (0.2) to 0.7 (0.2) ($p=0.03$). All six patients experienced significant discomfort before therapy with an average pain score of 2.2 (0.2). After treatment the pain score was only 0.1 (0.1) ($p=0.03$) with complete relief noted by four patients. All six noted transient burning of the mucosal surfaces while swishing the medication. Four reported slight precipitation, resulting in waxy particles which could easily be spat out.

In four patients, cyclosporin levels in whole blood were undetectable (less than 20 ng/ml) or low (30-60 ng/ml); in the other two peaks of 176 and 184 ng/ml were recorded, but in only one of these were moderate concentrations (60-90 ng/ml) persistent. Cyclosporin levels did not correlate with clinical response. Laboratory results did not change significantly.

Before cyclosporin therapy keratinocytes of oral lichen planus expressed both ICAM-1 and HLA-DR but not HLA-DQ. In keratinocytes at the end of cyclosporin treatment ICAM-1 expression was virtually undetectable with HLA-DR expression was moderately reduced. The CD2 T-lymphocyte infiltrate in the epidermis (by more than half) and in the dermis (by about one-third) was much reduced, and HLA-DR expression by T-lymphocytes in epidermis and dermis decreased in proportion.

5 months after completion of the study five patients were re-examined. No new lesions were detected and old lesions that had not completely resolved with cyclosporin remained unchanged. All six patients expressed a preference for the oral swish method over topical steroids applied previously. Spontaneous remissions in oral

ulcerative lichen planus is rare⁵ and we are confident that the clearing of active lesions in these six patients represents a response to cyclosporin.

Grattan et al treated four patients with cutaneous hypertrophic lichen planus with topical cyclosporin under occlusion and reported flattening of lesions,⁶ and in another study, four patients with oral lichen planus who applied cyclosporin to lesions with their fingers obtained partial resolution of their ulcers.⁷ However, absorption of drug through the skin is likely to be much less than absorption through oral mucosa. The mechanism of action of cyclosporin in lichen planus is unknown. However, it selectively inhibits production of interferon- γ , a lymphokine thought to be critical in the pathogenesis of lichen planus. Produced by activated T lymphocytes, interferon- γ induces the expression of ICAM-1 and HLA-DR by keratinocytes.⁸ These surface molecules and their interaction with interferon- γ trigger an influx of T lymphocytes to the skin where an inflammatory reaction is established with subsequent tissue destruction.⁹

Supported in part by the Babcock Dermatologic Endowment to the University of Michigan and the British Association of Dermatologists' Dowling travelling fellowship (C. E. M. G.). Cyclosporin drug donated by Sandoz Research Institute.

Dermatopharmacology Unit,
Department of Dermatology,
and Department of Pathology,
University of Michigan
Medical Center,
Ann Arbor,
Michigan 48109, USA

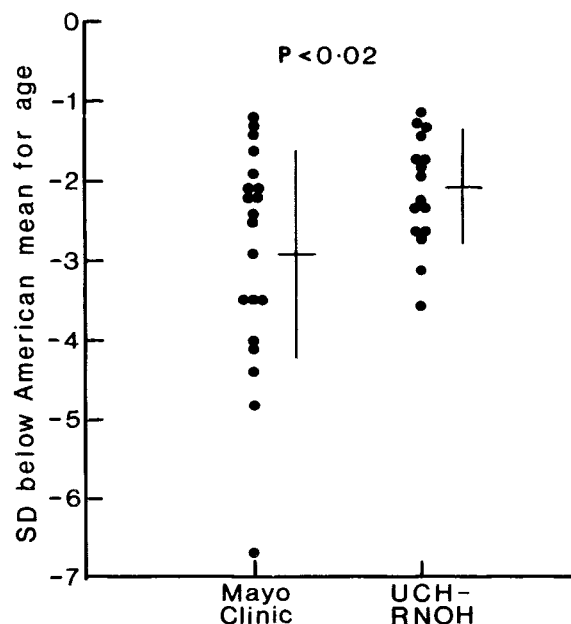
DRORE EISEN
CHRISTOPHER E. M. GRIFFITHS
CHARLES N. ELLIS
BRIAN J. NICKOLOFF
JOHN J. VOORHEES

1. Brown MD, Ellis CN, Voorhees JJ. Cyclosporine A: a review of its dermatologic applications. *Sem Dermatol* 1987; 6: 2-9.
2. Ho VC, Gupta AK, Ellis CN, Nickoloff BJ, Voorhees JJ. Therapy of severe lichen planus with cyclosporine A. *J Am Acad Dermatol* (in press).
3. Biren CA, Barr RJ. Dermatologic applications of cyclosporine. *Arch Dermatol* 1986; 122: 1028-32.
4. Griffiths CEM, Voorhees JJ, Nickoloff BJ. Characterization of intracellular adhesion molecule and HLA-DR expression in normal and inflamed skin: modulation by recombinant gamma interferon and tumor necrosis factor. *J Am Acad Dermatol* 1989; 20: 617-29.
5. Andreason JO. Oral lichen planus I: a clinical evaluation of 115 cases. *Oral Surg* 1968; 25: 31-42.
6. Grattan CEH, Boon AP, Gregory J. A preliminary open study of topical cyclosporine for hypertrophic lichen planus. *J Dermatol Treatment* 1989; 1: 39-41.
7. Frances C, Boismic S, Etienne S, Szpirglas H. Effect of the local application of cyclosporin A on chronic erosive lichen planus of the oral cavity. *Dermatologica* 1988; 177: 194-95.
8. Nickoloff BJ. Role of interferon-gamma in cutaneous trafficking of lymphocytes with emphasis on molecular and cellular adhesion events. *Arch Dermatol* 1988; 124: 1835-43.
9. Shiohara T, Moriya N, Toraka Y. Immunopathological study of lichenoid skin diseases: correlation between HLA-DR positive keratinocytes or Langerhans cells and epidermotropic T cells. *J Am Acad Dermatol* 1988; 18: 67-74.

Hypophosphataemic rickets and final height

SIR,—Professor Stickler and Dr Morgenstern (Oct 14, p 902) suggest that treatment of X-linked hypophosphataemic rickets with vitamin D (or one of its active derivatives) in pharmacological doses does not affect ultimate height and that clinical trials should therefore be undertaken. Our experience differs.

We had stricter diagnostic criteria than theirs (which may have included other forms of metabolic rickets) and we reported from University College Hospital the adult height of 8 patients whose vitamin D treatment was supervised by us.¹ With Stickler and Morgenstern's² American criteria, this value was 2.10 (SD 0.69) standard deviations below the mean. A further 8 patients, all with positive family histories, who had been under our supervision since before the age of 5 years, are now adults. Their mean height is 2.08 (0.76) SD below the American value (figure). The difference between our patients and those of Stickler and Morgenstern is probably an underestimate since heights of healthy British men and women on the 50th centile³ are, respectively, 1.7 and 0.5 cm (0.37 and 0.08 American SD) below those of Americans. The mean heights of our 10 men and 6 women (161.9 [SD 4.2] cm and 150.3 [5.7] cm, respectively) are almost on the 3rd (British) centile. Only 6



Adult height of patients treated continuously at the Mayo Clinic (from Stickler and Morgenstern) and at UCH/RNOH.

of our 16 patients received phosphate supplements, for a mean of 5.7 years, without detectable change in growth rate.

7 of 10 children aged 3-13 years currently under follow-up had known family histories at birth and were diagnosed and receiving treatment by the age of 20 months. All 7 are now on or above the 25th centile.

Our 16 adults have had a total of 4 osteotomies, compared with 88 osteotomies among 34 patients in the Mayo Clinic series (Chi-squared test, $p < 0.001$). Only 2 of our 10 children, who were diagnosed late, may eventually need osteotomy.

Differences between the results of "vitamin D treatment" in the two groups can be explained either by greater severity of the disease in the USA or by differences in management and therefore of patient selection. We agree that occasionally male patients may be only mildly affected for uncertain reasons which could include variable deletions in the short arm of the X chromosome. But in most patients X-linked rickets needs careful tailoring of pharmacological vitamin D (or calcitriol or alfalcidol) dose to individual requirements from the earliest possible age until growth ceases—on the basis of growth, radiographic appearances, serum calcium, and alkaline phosphatase.¹ Stickler and Morgenstern may have shown only that serious delay in diagnosis and/or less stringent medical management is not much better than no treatment at all. Any controlled trial of vitamin D therapy such as they seek would, at the least, pose serious ethical questions.

Metabolic Unit,
Royal National Orthopaedic Hospital,
Stanmore, Middlesex HA7 4LP, UK

TREVOR STAMP
A. J. GOLDSTEIN

1. Dent CE, Round JM, Stamp TCB. Treatment of sex-linked hypophosphataemic rickets (SLHR). In: Frame B, Parfitt AM, Duncan H, eds. Clinical aspects of metabolic bone disease. Amsterdam: Excerpta Medica, 1973: 427-32.
2. United States Department of Health, Education and Welfare. NCHS growth curves for children: birth-18 years: United States. *Vital Health Stat* 1977; 11: 44-45.
3. Tanner JM, Whitehouse RH. Height and weight standard charts (1975). Hertford: Castlemead Publications, 1975.

SIR,—Professor Stickler and Dr Morgenstern's retrospective study of 52 patients with X-linked hypophosphataemic rickets, treated with high doses of vitamin D, vitamin D plus phosphate supplements, or calcitriol plus phosphate, or untreated, shows that final height was not affected by the treatment regimen or sex. A significant negative correlation was observed with the number of osteotomies. Vitamin D intoxication led to irreversible severe renal failure in 3 patients. Stickler and Morgenstern conclude that "until a treatment is established as effective in controlled trials, it may be better that these patients remain untreated".