

## CLINICAL INVESTIGATIONS

---

### Dynamic QRS complex and ST segment vectorcardiographic monitoring can identify vessel patency in patients with acute myocardial infarction treated with reperfusion therapy

Reperfusion therapy has lowered the mortality in patients suffering acute myocardial infarction. Failure to reperfuse is associated with significantly higher risk of short- and long-term mortality. Detection of reperfusion is thus important. In a prospective pilot study, we used continuous on-line computerized vectorcardiography to monitor 21 patients with acute myocardial infarction treated with reperfusion therapy to noninvasively detect coronary patency. By using trend analysis of QRS vector difference, we were able to correctly blindly identify 15 of 16 patients with a perfused infarct-related artery and four of six patients with a persistently occluded artery at an early angiogram. The present results are based on a limited number of patients, but suggest that QRS complex and ST segment monitoring with continuous on-line vectorcardiography has substantial potential for monitoring patients with acute myocardial infarction treated with reperfusion therapy. (AM HEART J 1991;122:943.)

Mikael Dellborg, MD, Eric J. Topol, MD,<sup>a</sup> and Karl Swedberg, MD.  
*Göteborg, Sweden, and Ann Arbor, Mich.*

Reperfusion therapy has lowered the mortality in patients suffering acute myocardial infarction.<sup>1-3</sup> The beneficial effect seems related to reperfusion of the ischemic myocardium. Accordingly, failure to reperfuse is associated with significantly higher risk of short- and long-term mortality.<sup>4-7</sup> Early therapeutic interventions such as rescue angioplasty after failed thrombolytic therapy may be targeted to these patients. Detection of reperfusion is thus important. In a previous double-blind study of recombinant tissue plasminogen activator (rt-PA) versus placebo in

acute myocardial infarction,<sup>8</sup> we used continuous vectorcardiography to monitor infarct development. A specific pattern of rapid QRS vector development was observed among 37% of patients treated with rt-PA versus a 4% incidence in the placebo group.<sup>8</sup> The present report discloses the findings from a prospective pilot study to evaluate the use of continuous on-line computed vectorcardiography to noninvasively detect coronary patency after reperfusion therapy for acute myocardial infarction.

#### METHODS

**Continuous on-line vectorcardiography.** The method has been described in detail elsewhere.<sup>9</sup> We used a computerized system, the MIDA-system (MIDA 1000, Ortivus Medical, Täby, Sweden) for on-line dynamic analysis of QRS complex and ST segment changes. In short, with the use of eight electrodes placed according to the method of Frank,<sup>10</sup> the three orthogonal leads X, Y, and Z are continuously monitored and analyzed. The signals are averaged

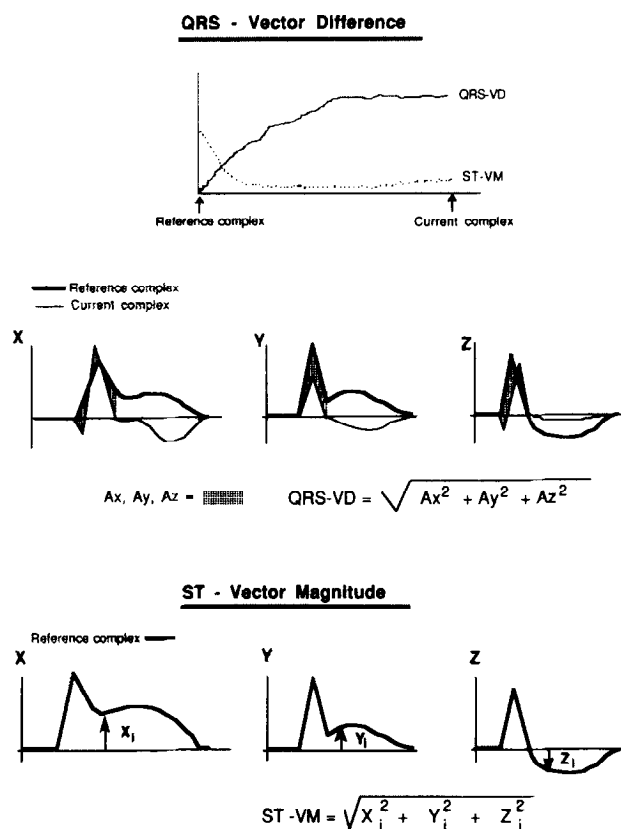
From the Department of Medicine, Östra Hospital, University of Göteborg; and <sup>a</sup>Department of Medicine, University of Michigan.

Supported by a grant from AFA, the Labour Market Insurance Company, Stockholm, Sweden.

Received for publication Sept. 4, 1990; accepted May 5, 1991.

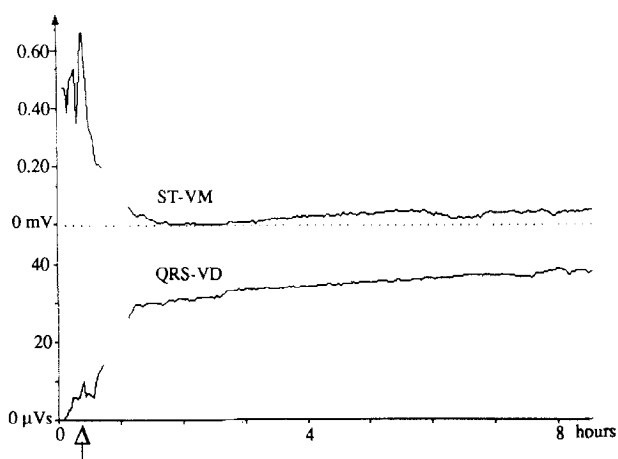
Reprint requests: Mikael Dellborg, MD, Department of Medicine, Östra Hospital, University of Göteborg, 416 85 Göteborg, Sweden.

4/1/31114



**Fig. 1.** Upper panel shows a trend curve with time on the horizontal axis and QRS vector difference and ST vector magnitude on the vertical axis. A trend curve from a patient with an acute myocardial infarction is illustrated, with a slow evolution of electrocardiographic changes. The reference mean QRS complex and current mean QRS complex are shown plotted above each other. The hatched area ( $A_x, A_y, A_z$ ) is the QRS vector difference in lead X, Y, and Z, respectively, added according to the formula to form the total QRS vector difference. Lower panel, Arrows indicate the deviation from baseline of the ST segment 20 msec after the termination of the QRS complex in each of the three leads—termed  $X_i, Y_i,$  and  $Z_i$ . These terms added according to the formula constitute the ST vector magnitude, illustrated by the initial ST vector magnitude on the trend curve above. *QRS-VD*, QRS vector difference; *ST-VM*, ST vector magnitude.

over 2-minute periods to form mean vectorcardiographic complexes. All calculations are done in real time and the result is presented on a computer screen. In every individual patient changes are related to the initial 2-minute mean complex for that patient. The results are presented as continuously updated trend curves on the computer screen. The two vectorcardiographic parameters studied were QRS vector difference and ST vector magnitude (Fig. 1). The QRS vector difference can be described as the total change within the QRS complex and the ST vector magnitude is the deviation of the ST segment 20 msec after termination of the QRS complex, measured and added in all three leads. After a brief introduction and training session,



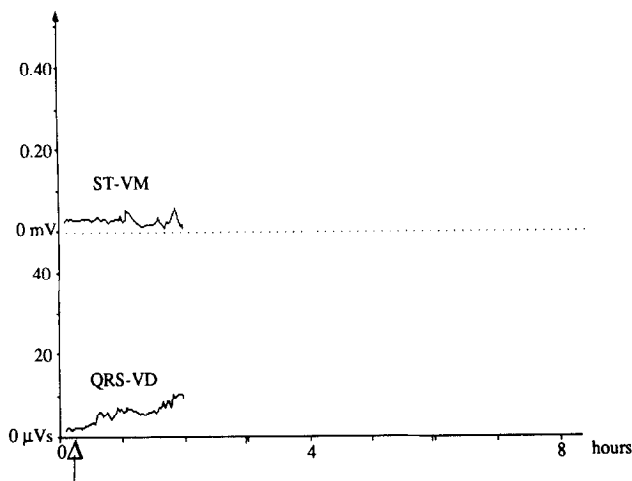
**Fig. 2.** Pharmacologic reperfusion. Print-out directly from the computer screen of a trend curve showing changes in the ST vector magnitude and in the QRS vector difference over time. The patient has an acute inferior myocardial infarction. Acute coronary angiography was performed after 25 minutes of vectorcardiographic monitoring and showed TIMI grade 3 flow of the right coronary artery. Arrow indicates first injection of contrast medium.

the MIDA-system was completely handled by the attending research nurse in the coronary catheterization laboratory.

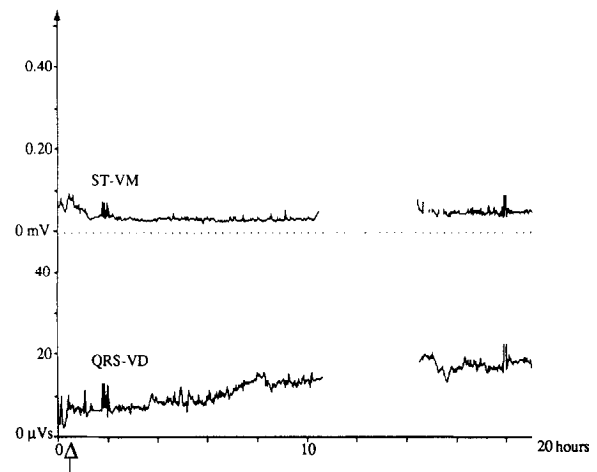
**Patient series.** Patients with suspected acute myocardial infarction were eligible for inclusion if they were treated with thrombolytic drugs and/or angioplasty. Routine emergency catheterization was performed on all such patients and emergency angioplasty was performed if the infarct-related artery was found to be occluded. Angioplasty was performed if the patient had a remaining severe stenosis of the infarct-related artery. At least 15 minutes of vectorcardiographic monitoring preceded acute angiography that had to be performed within 5 hours of the onset of chest pain.

There were 24 patients monitored, 21 of whom on final analysis fulfilled the inclusion criteria (three patients were excluded because of vectorcardiographic monitoring <15 minutes before angiography). Fifteen of these 21 patients were treated with intravenous urokinase or rt-PA; another four patients had an occluded infarct-related artery after thrombolysis and were subsequently treated with angioplasty; two patients had emergency angioplasty alone.

**Trial procedure.** All patients were treated at the University of Michigan Medical Center. Patients eligible for inclusion were monitored by continuous vectorcardiography for the initial 8 hours. In some cases monitoring was terminated prematurely, but it was always conducted for at least 15 minutes before catheterization and throughout the catheterization procedure. The vectorcardiographic recording was stored on floppy disks and was sent to Göteborg for analysis. A simple form with the name, sex, and age of the patient and with the times of onset of symptoms, initiation of therapy, first injection of contrast material,



**Fig. 3.** Persistent occlusion. Print-out directly from the computer screen of a trend curve showing changes in the ST vector magnitude and in the QRS vector difference over time. The patient has a persistent occlusion of the left circumflex artery despite thrombolysis and attempted angioplasty. QRS vector difference is slowly increasing, indicating a continuously but slowly evolving myocardial infarction. The patient was transferred to acute coronary bypass surgery after 2 hours of monitoring. Arrow indicates first injection of contrast medium.



**Fig. 4.** Persistent occlusion. Print-out directly from the computer screen of a trend curve showing changes in the ST vector magnitude and in the QRS vector difference over time. The patient has a persistent occlusion of the left circumflex artery at angiography after 20 minutes of vectorcardiographic monitoring (arrow). The patient fulfills the objective criteria for vectorcardiographic perfusion at the time of angiography. During the following 12 hours the QRS vector difference slowly increases, indicating a slowly developing myocardial infarction.

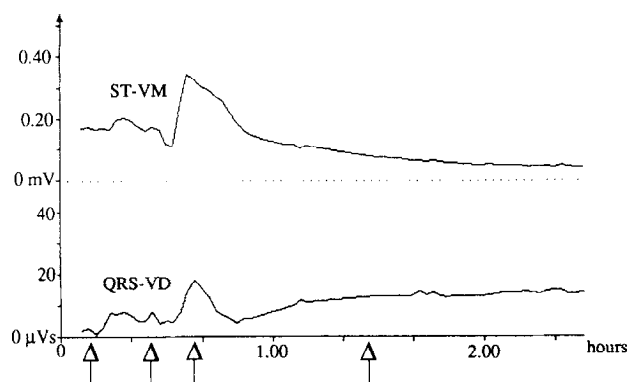
and, if performed, angioplasty, accompanied the floppy disks. Information regarding coronary anatomy or clinical information such as electrocardiographic changes was not available to the interpreter of the vectorcardiograms.

**Vectorcardiographic criteria for determining perfusion and occlusion.** Prospective criteria for the development of QRS and ST vector changes were set up. These criteria were derived from a previous study<sup>8</sup> in which we observed a pattern of rapid evolution of the QRS vector difference associated with rapid relief of chest pain, rapid decline of the elevated ST vector magnitude, and low in-hospital and 1-year mortality compared with patients without this rapid pattern. The rapid pattern was defined as a rapid evolution of the QRS vector difference, reaching a plateau within 2 hours from the start of thrombolytic treatment and the start of monitoring, with a concomitant but otherwise unspecified decline of the ST vector magnitude. The rapid pattern was highly associated with treatment with rt-PA and we therefore interpreted this finding as possibly caused by rapid coronary reperfusion. The mean rate of QRS vector difference evolution was  $0.27 \mu\text{V}/\text{min}$  and the mean rate of ST vector magnitude decline was  $2.0 \mu\text{V}/\text{min}$  in patients with the "rapid pattern," versus  $0.14 \mu\text{V}/\text{min}$  and  $1.0 \mu\text{V}/\text{min}$  for patients with a slow evolution of the QRS vector difference. In the present trial, perfusion, defined as a Thrombolysis In Myocardial Infarction (TIMI) grade flow  $\geq 2$  of the infarct-related artery at the first injection of contrast medium, was tentatively identified by an increase of the QRS vector difference by  $\geq 0.10 \mu\text{V}/\text{min}$  from the start of vectorcardiographic monitoring until the first injection of contrast medium. A decrease of

the ST vector magnitude of  $>0.83 \mu\text{V}/\text{min}$  was tentatively defined as TIMI grade flow  $\geq 2$ . A subjective evaluation and "eye-balling" of each trend curve was also part of the protocol. This subjective evaluation also took into consideration the time to the QRS vector difference evolution plateau and the subsequent evolution of both the QRS vector difference and the ST vector magnitude. Data from both the "objective" and the "subjective" evaluation of the trend curves were analyzed and were related to the angiographic changes.

## RESULTS

Of the 21 patients included, 16 had a patent infarct-related artery at the time of the angiography and five had a persistent occlusion. Applying the prospective criteria for QRS vector difference evolution would correctly classify 15 of these 16 vessels as patent and would correctly classify two of the five persistently occluded arteries. In Fig. 2 the trend curves from a patient with pharmacologically induced perfusion are shown, and in Fig. 3 an example of a patient with a persistent occlusion is shown. In both cases total agreement was found between the objective criteria, the subjective evaluation, and the angiogram. The subjective blind evaluation of the QRS vector difference trend curve could correctly identify 15 of 16 patients with a patent coronary artery and four of five patients with persistent occlusion (sensitivity, 94%; specificity, 80%; positive pre-



**Fig. 5.** Thrombolytic failure—mechanical reperfusion. Print-out directly from the computer screen of a trend curve showing the change over time in the QRS vector difference (*QRS-VD*) and ST vector magnitude (*ST-VM*) of a patient with acute myocardial infarction. *The first arrow from left indicates the first angiogram, which revealed an occluded left circumflex coronary artery despite previous treatment with intravenous urokinase. Limited perfusion was established with the guide wire (TIMI grade 1 flow) and subsequently improved to TIMI grade 3 flow by angioplasty (second arrow from left). The patient then had an episode of coronary spasm treated by intracoronary nitroglycerin (third arrow from left). Approximately 50 minutes after the reestablishment of coronary patency, the QRS changes reached a plateau, indicating the end of electrocardiographic change. Vectorcardiographic signs of reperfusion are the rapid development of QRS vector difference change with an early plateau and the rapid decline of the ST vector magnitude.*

dictive value for vectorcardiographic perfusion, 94%; positive predictive value for vectorcardiographic occlusion, 80%).

In 17 of the 21 patients there was complete agreement between the two vectorcardiographic evaluations. In two cases the objective criteria classified the patients as having an open infarct-related artery whereas both the subjective vectorcardiographic evaluation and the angiogram classified the artery as being closed. One of these patients is shown in Fig. 4. In one case the objective criteria and the angiogram defined the artery as open, in contrast to the result from the subjective evaluation, and in one case the angiogram defined the artery as closed when the objective and subjective evaluation agreed it was open. ST vector changes were found to be less informative, mostly due to the fact that six patients showed no changes in the ST vector magnitude trend curve throughout the monitoring period.

In Fig. 5 a patient with an occluded left circumflex coronary artery at the first contrast medium injection (*first arrow from the left*) is shown. Perfusion was established with the guide wire (*second arrow from the left*) and an angioplasty was performed, resulting

in TIMI grade 3 flow. Recurrent ischemia caused by coronary spasm was successfully treated with intracoronary nitroglycerin (*third arrow from the left*). After establishing TIMI grade 3 flow, a rapid change of the QRS and ST vector trend curves occurred, and within 45 minutes of reperfusion the QRS vector difference and the ST vector magnitude trend curves reached a stable plateau, indicating the end of electrocardiographic change (*fourth arrow from the left*).

## DISCUSSION

In the present study coronary perfusion was associated with a rapidly evolving QRS vector difference. By using trend analysis of QRS vector difference, we were also able to correctly blindly identify 15 of 16 patients with a perfused infarct-related artery and four of five patients with a persistently occluded artery at an early angiogram. ST vector magnitude changes in the present study were less informative, mostly because 6 of 21 patients showed no ST vector magnitude changes throughout the monitoring period.

There have been several attempts to establish a method for the noninvasive detection of reperfusion. The triad of rapid relief of chest pain, ST segment normalization, and the appearance of an idioventricular rhythm has been shown to predict reperfusion with high diagnostic specificity but with too low sensitivity to be of practical clinical value.<sup>11,12</sup> Enzymatic methods may detect reperfusion with high accuracy, but their ability to detect ischemia or intermittent brief episodes of coronary perfusion is limited.<sup>13-15</sup> Despite recent advances, they do not have true real-time capacity.

ST segment trend analysis of a continuous three-lead electrocardiogram (ECG) has shown high diagnostic accuracy in the clinical setting,<sup>16</sup> but offers no information on the development of necrosis. The conventional 12-lead ECG has low sensitivity for detecting lateral and posterior ischemia,<sup>17</sup> but the use of the digitized summated 12-lead ECG ST trend was recently reported to yield high diagnostic accuracy for the noninvasive detection of reperfusion.<sup>18</sup> In animal studies of coronary occlusion/reperfusion, the QRS vector difference has been shown to reflect progression of myocardial necrosis as well as myocardial ischemia.<sup>19</sup> There are several reports<sup>20,21</sup> describing changes in the QRS complex in up to 90% of all coronary occlusions during coronary angioplasty.

In a double-blind, placebo-controlled study with rt-PA in patients with suspected acute myocardial infarction, we found the QRS vector difference evolution to be significantly more rapid in patients treated with rt-PA.<sup>8</sup> Inclusion criteria were chest pain of less than 2 hours and 45 minutes' duration

with or without changes in the resting 12-lead ECG. Only 75% of the patients had any ST elevation on a standard 12-lead ECG. We were able to blindly identify among patients with a final diagnosis of acute myocardial infarction a pattern of very rapidly developing QRS vector difference. This pattern was found in 37% of the patients in the rt-PA group compared with 4% in the placebo group. In light of the present finding that a high rate of evolution of QRS vector difference is associated with perfusion, the rapid pattern of this evolution is interpreted as a sign of rapidly restored coronary perfusion. Taking only patients with ST segment elevation into consideration, the rapid pattern was thus observed in 50% of the patients treated with rt-PA and in 5% in the placebo group. A reperfusion rate of 50% within 2 hours from the start of treatment with rt-PA is somewhat low, but within the range previously reported, and a spontaneous rate of 5% within 2 hours also seems reasonable.

One possible explanation for the lack of ST vector magnitude change in 30% of our patients is the relatively late start of monitoring in the present study. We have previously found that in patients with acute myocardial infarction treated with intravenous streptokinase or rt-PA, the ST vector magnitude returned to baseline a mean of 15 minutes before complete evolution of the QRS vector difference had occurred.<sup>8,9</sup> In the absence of thrombolytic treatment, the ST vector magnitude returns to baseline 1 hour and 20 minutes before the evolution of the QRS vector difference is completed. In the present study many patients were referred from other hospitals and had thus been under treatment with thrombolytic agents for some time before vectorcardiographic monitoring was started. Thus trend analysis of the QRS vector difference may expand the time window for ECG analysis of the dynamic process of development of myocardial ischemia and necrosis, especially if thrombolysis is not used (or if it is unsuccessful).

Failed thrombolysis is associated with a comparatively high short- and long-term mortality.<sup>4-7</sup> If these patients can be accurately identified, therapeutic interventions such as rescue angioplasty can be targeted to this subset of patients. In patients with successful thrombolysis with early reestablishment of coronary flow, a strategy of "watchful waiting" has been advocated.<sup>22</sup> Recurrent ischemic events after thrombolytic therapy are relatively frequent and occur in 12% to 20% of such patients, in most cases within the first 72 hours after therapy and often in the absence of symptoms.<sup>4, 22-25</sup> The rapid detection of these ischemic events is important, since an aggressive response to such events is necessary to prevent reinfarction.<sup>26</sup>

Because of the sometimes transient nature of cor-

onary perfusion,<sup>27</sup> the rapid development of coronary reocclusion, and the frequency of recurrent ischemia, an ideal method for monitoring patients with acute myocardial infarction should be safe, accurate, and reproducible and should present the results on-line for real-time analysis. At present only ECG monitoring with ST segment and/or QRS complex analysis seem to fulfill these demands. Although the capability of continuous vectorcardiography in detecting recurrent ischemia is beyond the scope of the present report, Fig. 5 illustrates the immediate changes occurring on the QRS/ST trend curves when ischemia recurs. Since the monitoring system has full on-line capacity, the changes can truly be observed in real-time. We believe that QRS complex and ST segment monitoring with continuous on-line vectorcardiography has substantial potential for monitoring of patients with acute myocardial infarction. The present results are based on a limited number of patients and the present data should be regarded as preliminary. Continuous on-line vectorcardiography is presently the subject of further study in this field.

The excellent technical assistance of Eva Kline, RN, and Kerstin Korssell, RN, is gratefully acknowledged.

#### REFERENCES

1. Gruppo Italiano per lo Studio della Streptochinasi nell'Infarto miocardico (GISSI). Effectiveness of intravenous thrombolytic treatment in acute myocardial infarction. *Lancet* 1986;1:397-401.
2. ISIS-2 Collaborative group. Randomised trial of intravenous streptokinase, oral aspirin, both or neither among 17,187 cases of suspected acute myocardial infarction: ISIS-2. *Lancet* 1988;2:349-60.
3. Wilcox RG, von der Lippe, Olsson CG, Jensen G, Skene AM, Hampton JR, for the ASSET study group. Trial of tissue plasminogen activator for mortality reduction in acute myocardial infarction. *Lancet* 1988;2:525-30.
4. Topol EJ, Califf RM, George BS, Kereiakes DJ, Abbottsmith CW, Candela RJ, Lee KL, Pitt B, Stack RS, O'Neill WW, and the Thrombolysis and Angioplasty in Myocardial Infarction study group. A randomized trial of immediate versus delayed elective angioplasty after intravenous tissue plasminogen activator in acute myocardial infarction. *N Engl J Med* 1987; 317:581-8.
5. Chesebro JH, Knatterud G, Roberts R, Borer J, Cohen L, Dalen J, Dodge HT, Francis CK, Hillis D, Ludbrook P, Markis JE, Mueller H, Passamani ER, Powers ER, Rao AK, Robertson R, Ross A, Ryan TJ, Sobel BE, Willerson J, Williams DO, Zaret BL, Braunwald E. Thrombolysis In Myocardial Infarction (TIMI) trial, Phase I. A comparison between intravenous tissue plasminogen activator and intravenous streptokinase. *Circulation* 1987;76:142-54.
6. Kennedy JW, Ritchie JL, Davis KB, Stadius ML, Maynard C, Fritz JK. The Western Washington randomized trial of intracoronary streptokinase in acute myocardial infarction. *N Engl J Med* 1985;312:1073-8.
7. Stack RS, O'Connor CM, Mark DB, Hinohara T, Phillips HR, Lee MM, Ramirez NM, O'Callaghan WG, Simonton CA, Carlson EB, Morris KG, Behar VS, Kong Y, Peter RH, Califf RM. Coronary perfusion during acute myocardial infarction with a combined therapy of coronary angioplasty and high-dose intravenous streptokinase. *Circulation* 1988;77:151-61.

8. Dellborg M, Riha M, Swedberg K, for the TEAHAT study group. Dynamic QRS-complex and ST-segment monitoring in acute myocardial infarction during recombinant tissue plasminogen activator therapy. *Am J Cardiol* 1991;67:343-9.
9. Dellborg M, Riha M, Swedberg K. Dynamic QRS- and ST-segment changes in myocardial infarction monitored by continuous on-line vectorcardiography. *J Electrocardiol* 1991;23(suppl):11-9.
10. Frank E. Accurate, clinically practical system for spatial vectorcardiography. *Circulation* 1956;13:737-44.
11. Kircher RJ, Topol EJ, O'Neill WW, Pitt B. Prediction of infarct coronary artery recanalization after intravenous thrombolytic therapy. *Am J Cardiol* 1987;59:513-5.
12. Califf RM, O'Neill W, Stack RS, Aronson L, Mark DB, Mantell S, George BS, Candela RJ, Kereiakes DJ, Abbottsmith C, Topol EJ, and the TAMI study group. Failure of simple clinical measurements to predict perfusion status after intravenous thrombolysis. *Ann Intern Med* 1988;108:658-62.
13. Garbedian HD, Gold HK, Yasuda T, Johns JA, Finkelstein DM, Gaivin RJ, Cobbaert C, Leinbach RC, Collen D. Detection of coronary artery reperfusion with creatine kinase-MB determinations during thrombolytic therapy: correlation with acute angiography. *J Am Coll Cardiol* 1988;11:729-34.
14. Seacord LM, Abendschein DR, Nohara R, Hartzler G, Sobel B, Jaffe AS. Detection of reperfusion within 1 hour after coronary recanalization by analysis of isoforms of the MM creatine kinase isoenzyme in plasma. *Fibrinolysis* 1988;2:151-6.
15. Ellis AK, Little T, Masud ARZ, Klocke FJ. Patterns of myoglobin release after reperfusion of injured myocardium. *Circulation* 1985;72:639-47.
16. Krucoff M, Green C, Satler L, Miller F, Pallas R, Kent KM, Del Negro AA, Pearle DL, Fletcher RD, Rackley CE. Noninvasive detection of coronary artery patency using continuous ST-segment monitoring. *Am J Cardiol* 1986;57:916-22.
17. Berry C, Zalewski A, Kovach R, Savage M, Goldberg S. Surface electrocardiogram in the detection of transmural myocardial ischemia during coronary artery occlusion. *Am J Cardiol* 1989;63:21-6.
18. Krucoff M, Croll M, Granger C, O'Connor M, Sigmon K, Pope J, Waugh R, Kereiakes D, George B, Samaha J, Califf R. Prospective blinded noninvasive detection of failed thrombolysis using digital trending from continuous 12-lead ST segment monitoring. [Abstract]. *Circulation* 1990;82(suppl III):254.
19. Gröttum P, Mohr B, Kjekshus JK. Evolution of vectorcardiographic QRS changes during myocardial infarction in dogs and their relation to infarct size. *Cardiovasc Res* 1986;20:108-16.
20. Abboud S, Cohan R, Selwyn A, Ganz P, Sadeh D, Friedman P. Detection of transient myocardial ischemia by computer analysis of standard and signal-averaged high-frequency electrocardiograms in patients undergoing percutaneous transluminal coronary angioplasty. *Circulation* 1987;76:585-96.
21. Wagner N, Sevilla D, Krucoff M, Lee KL, Pieper KS, Kent KK, Bottner RK, Selvester RH, Wagner GS. Transient alterations of the QRS complex and ST segment during percutaneous transluminal balloon angioplasty of the left anterior descending coronary artery. *Am J Cardiol* 1988;62:1038-42.
22. The TIMI study group. Comparison of invasive and conservative strategies following intravenous tissue plasminogen activator in acute myocardial infarction: results of the Thrombolysis In Myocardial Infarction (TIMI) phase II trial. *N Engl J Med* 1989;320:618-28.
23. Topol EJ, George BS, Kereiakes DJ, Stump DC, Candela RJ, Abbottsmith CQ, Aronson L, Pickel A, Boswick JM, Lee KL, Ellis SG, Califf RM, and the TAMI study group. A randomized controlled trial of intravenous tissue plasminogen activator and early intravenous heparin in acute myocardial infarction. *Circulation* 1989;79:281-6.
24. Passamani E, Hodges M, Herman M, Grose R, Chaitman B, Rogers W, Forman S, Terrin M, Knatterud G, Robertson T, Braunwald E, for the TIMI investigators. The Thrombolysis In Myocardial Infarction (TIMI) Phase II pilot study: tissue plasminogen activator followed by percutaneous transluminal coronary angioplasty. *J Am Coll Cardiol* 1987;10:51B-64B.
25. Simoons ML, Arnold AER, Betriu A, De Bono DP, Col J, Dougherty FC, von Essen R, Lambert H, Lubsen J, Meier B, Michel PL, Raynaud P, Rutsch W, Sanz GA, Schmidt W, Seruys PW, Thery C, Uebis R, Vahanian A, Van de Werf F, Willems GM, Wood D, Verstraete M. Thrombolysis with rt-PA in acute myocardial infarction: no beneficial effects of immediate PTCA. *Lancet* 1988;1:197-203.
26. Topol EJ. Mechanical interventions for acute myocardial infarction. In: Topol EJ, ed. *Textbook of interventional cardiology*. Philadelphia: WB Saunders Company, 1990:287.
27. Hackett D, Davies G, Chierchia S, Maseri A. Intermittent coronary occlusion in acute myocardial infarction. *N Engl J Med* 1987;317:1055-9.