

# Clinical Angiographic and Histologic Correlates of Ectasia After Directional Coronary Atherectomy

Nicoletta B. De Cesare, MD, Jeffrey J. Popma, MD, David R. Holmes, Jr., MD, Ronald J. Dick, MBBS, Patrick L. Whitlow, MD, Spencer B. King, MD, Cass A. Pinkerton, MD, Dean J. Kereiakes, MD, Eric J. Topol, MD, Christian C. Haudenschild, MD, and Stephen G. Ellis, MD

**Directional coronary atherectomy can cause ectasia (final area stenosis <0%), presumably due to an excision deeper than the angiographically "normal" arterial lumen. In a multicenter series in which quantitative coronary arteriography was performed after directional atherectomy in 382 lesions (372 patients), ectasia after atherectomy occurred in 50 (13%) lesions. By univariate analysis, ectasia was seen more often within the circumflex coronary artery ( $p = 0.008$ ), in complex, probably thrombus-containing lesions ( $p = 0.015$ ), and with higher device:artery ratios ( $p < 0.001$ ). Ectasia occurred less often in lesions within the right coronary artery ( $p = 0.008$ ). Histologic analysis demonstrated adventitia or media, or both, in all patients with angiographic ectasia. Repeat angiography was performed in 188 of 271 eligible patients (69%)  $6.1 \pm 2.4$  months after atherectomy. Restenosis, defined as a follow-up area stenosis  $\geq 75\%$ , was present in 50% of patients without procedural ectasia and in 70% of patients with marked ectasia (residual area stenosis  $< -20\%$ ;  $p = 0.12$ ). It is concluded that excision beyond the normal arterial lumen may occur after directional coronary atherectomy, related, in part, to angiographic and procedural features noted at the time of atherectomy. Restenosis tends to occur more often in patients with marked ectasia after coronary atherectomy.**

(Am J Cardiol 1992;69:314-319)

From the Departments of Internal Medicine (Cardiology Divisions) of the University of Michigan Medical Center, Ann Arbor, Michigan, the Mayo Clinic, Rochester, Minnesota, the Cleveland Clinic Foundation, Cleveland, Ohio, Emory University, Atlanta, Georgia, St. Vincent's Hospital, Indianapolis, Indiana, the Christ Hospital, Cincinnati, Ohio, and the Mallory Institute of Pathology, Cardiovascular Research Laboratory, Boston, Massachusetts. Manuscript received August 8, 1991; revised manuscript received September 27, 1991, and accepted September 29.

Address for reprints: Jeffrey J. Popma, MD, Washington Cardiology Center, 1100 Irving Street, N.W. Suite 4B-14, Washington, D.C. 20010.

Because of limitations of standard balloon angioplasty, including abrupt vessel closure and delayed restenosis, alternative methods of nonsurgical coronary revascularization have been used.<sup>1-3</sup> One such technique is directional coronary atherectomy, which dilates and selectively excises the obstructive atheroma.<sup>4,5</sup> Directional atherectomy has been shown to be particularly useful in lesions deemed high risk for standard coronary angioplasty, such as those with irregularity, ulceration or those containing thrombus.<sup>6,7</sup>

Despite the potential advantages of directional coronary atherectomy, the optimal depth of resection by this method has not been determined. Whereas deeper excisions into the normal vessel wall may be performed without important immediate clinical sequelae,<sup>8</sup> higher restenosis rates after directional atherectomy have been reported when the depth of resection includes media and adventitia, particularly in lesions within saphenous vein grafts.<sup>9</sup> Often, the direction and depth of cut is operator-dependent, with some clinicians advocating an aggressive approach to atheroma resection in an effort to reduce late restenosis,<sup>10</sup> while others resect less atheroma because of the potential risk of vessel perforation.<sup>1</sup>

Whether excision beyond the "normal" arterial lumen, demonstrated angiographically as ectasia, results in an increased incidence of early or late clinical sequelae has not been previously studied. Therefore, to characterize the incidence, predisposing factors, histologic findings, and clinical outcome of ectasia after directional coronary atherectomy, clinical case report forms were reviewed and cineangiograms were analyzed using qualitative morphologic and quantitative angiographic methods for 382 directional atherectomy procedures performed at 6 clinical sites.

## METHODS

**Patient population:** Between January 1988 and July 1990, directional coronary atherectomy was performed in 400 procedures at 6 clinical centers. Proximal lesions or lesions with irregularity, ulceration, or eccentricity in coronary arteries  $\geq 2.5$  mm were deemed suitable for directional coronary atherectomy. Before the atherectomy procedure, all patients gave informed consent, approved by the respective institutional review boards. Completed clinical case report forms and cineangiograms suitable for quantitative coronary analysis were obtained in 382 procedures.

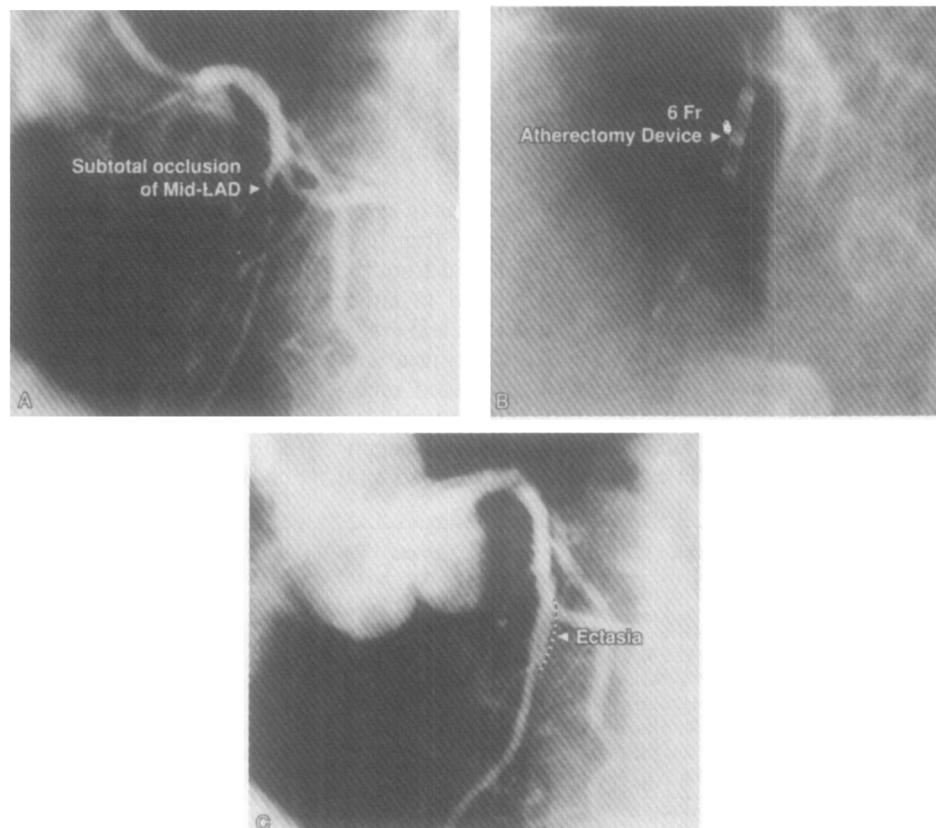
**Atherectomy procedure:** Directional coronary atherectomy was performed with the Simpson AtheroCath™ (Devices for Vascular Intervention, Inc., Redwood City, California) using previously described methods.<sup>1</sup> In general, the depth of resection was determined primarily by the principal investigator. After each series of passes, repeat arteriography was performed to ascertain the amount of residual obstruction. Before November 1989, most investigators attempted to resect all angiographically apparent atheroma. Thereafter, because of concern about a rarely reported perforation,<sup>1</sup> a less aggressive approach to complete atheroma resection was taken by some investigators. Successful atherectomy was defined as a residual area stenosis <75%, tissue retrieval, and the absence of in-hospital ischemic complications.

**Clinical and procedural features:** Case report forms were reviewed for age, gender, angina status, the presence of diabetes mellitus, multivessel disease and a history of restenosis. Procedural variables, including adjunctive coronary angioplasty, atherectomy device size, number of passes, and number of specimens obtained, were also recorded. The occurrence of major postprocedural ischemic complications, such as abrupt closure, myocardial infarction, emergency coronary bypass surgery and death, was noted.

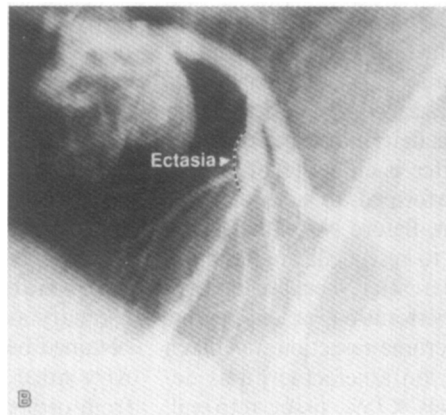
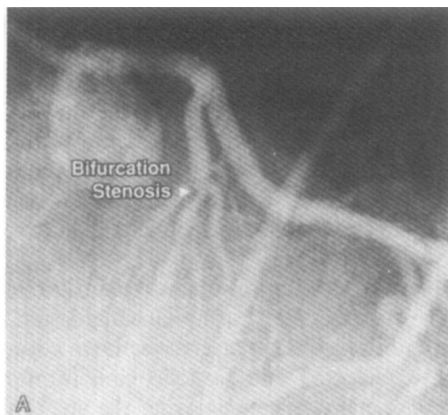
**Qualitative morphologic analysis:** Cineangiograms were collected at the University of Michigan Core Angiographic Laboratory and analyzed by an observer unaware of the clinical outcome. Lesions were visualized in multiple projections and scored according to lesion location, eccentricity, proximal tortuosity, diffuse proximal disease, lesion length  $\geq 10$  mm, bend  $\geq 45^\circ$ , irregu-

larity, presence of calcific deposits, or bifurcation location using the criteria developed by Ellis and co-workers.<sup>11</sup> Complex, probably thrombus-containing, stenoses were defined as the presence of either an easily recognized filling defect or gross luminal irregularities within the lesion. The device:artery ratio was measured by calipers and defined as the ratio of the atherectomy device and the normal adjacent coronary artery for the largest device that crossed the stenosis.

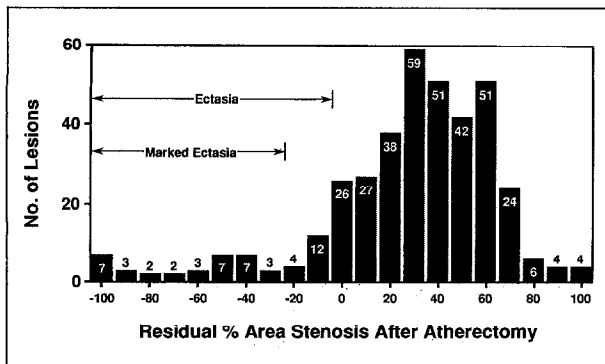
**Quantitative coronary angiography:** Quantitative coronary analysis was performed using cineangiograms obtained before and immediately after directional coronary atherectomy. Selected end-diastolic cine frames from orthogonal projections demonstrating the stenosis in its least foreshortened projection were digitized using a cine-video converter. A computer-assisted edge-detection algorithm was applied to the digitized images<sup>12</sup> and, using the guiding catheter as the reference standard, absolute coronary dimensions and percent stenoses were obtained. The normal segment was measured in a region without luminal irregularities 5 to 10 mm proximal to and 5 to 10 mm distal to the stenosis. The identical region of minimal luminal diameter before coronary atherectomy was used to define the region of measurement of the luminal diameter immediately after atherectomy. Normal and minimal cross-sectional areas were determined based on the geometry of an ellipse.<sup>13</sup> Ectasia was defined as <0% residual area stenosis after coronary atherectomy and marked ectasia was defined as <-20% area stenosis in the region of atherectomy (Figures 1 and 2). At time of follow-up arteriography, restenosis was defined as an area stenosis  $\geq 75\%$  using



**FIGURE 1.** A subtotal occlusion of the left anterior descending artery (LAD) is noted in the left anterior oblique projection (panel A). A 6Fr directional atherectomy device is positioned across the stenosis and 4 passes are performed (panel B). After atherectomy, ectasia is noted within the midleft anterior descending artery (panel C). Subacute abrupt vessel closure developed 4 days after atherectomy and was successfully managed with coronary angioplasty.



**FIGURE 2.** A complex stenosis of the midleft anterior descending artery is noted (panel A). After atherectomy with a 7Fr device, marked ectasia is seen (panel B). At follow-up arteriography 6 months later, no significant change in the luminal dimensions was noted.



**FIGURE 3.** Distribution of residual percent area stenosis after atherectomy. Ectasia, defined as <0% residual stenosis, was present in 50 lesions (13%), and marked ectasia, defined as <-20% residual stenosis, was present in 34 lesions (9%).

similar quantitative methods. Intimal hyperplasia was defined as the loss of minimal lesion cross-sectional area (mm<sup>2</sup>) during the period of follow-up. Because of institutional requirements, follow-up films were not available for analysis from 1 participating institution; therefore, these lesions were not included in follow-up analysis.

**Histologic analysis:** Pathologic examination of specimens retrieved from 76 lesions was available from 1 of the 6 participating institutions. After removal from the atherectomy device, specimens were placed in either formalin or glutaraldehyde/formalin fixative and evaluated by a histopathologist unaware of the clinical and angiographic results using previously described methods.<sup>14</sup> Atherosclerotic plaque, including fibrocellular, sclerotic and lipid-containing components, was identified using a hematoxylin-eosin stain. Normal vessel wall

beyond the internal elastic lamina, containing media and adventitia, was identified using a Van Gieson elastin stain.

**Statistical analysis:** All continuous variables were expressed as mean  $\pm$  SD and dichotomous variables were expressed as frequencies. Nonparametric analysis was used to evaluate differences in continuous variables and chi-square analysis was used to evaluate differences in dichotomized variables. A  $p < 0.05$  was considered significant.

## RESULTS

### Incidence of ectasia after directional atherectomy:

During the study period, successful directional atherectomy was performed in 317 of 382 procedures (83%). The clinical, angiographic and procedural factors correlating with the procedural success and complication rates have been reported elsewhere.<sup>7,15</sup> With use of quantitative angiographic methods, ectasia developed in 50 lesions (13%) and marked ectasia, defined as a residual area stenosis <-20%, occurred in 34 lesions (9%) (Figure 3). No clinical characteristics were correlated with the development of ectasia after directional atherectomy (Table I). However, using univariate analysis, ectasia was seen more often in lesions within the circumflex coronary artery and in complex, probably thrombus-containing lesions (Table II). Despite the varying criteria for tissue resection during the study period, no differences were noted in the incidence of ectasia between early ( $\leq 20$  procedures) and later ( $> 20$  procedures) experience (11 vs 14%, respectively;  $p =$  not significant). Notably, ectasia occurred more often with larger device:artery ratios (Table III), but was not related to any other procedural factors. Coronary perforation developed in 2 (0.6%) procedures, but was not re-

**TABLE I** Clinical Correlates of Ectasia After Directional Atherectomy

Features	Ectasia— No. (%)	No Ectasia— No. (%)	Likelihood Ratio	Univariate p Value
Age (years)	59 $\pm$ 10	59 $\pm$ 11	—	NS
Male gender	40 (80)	259 (78)	1.02	NS
Unstable angina	27 (61)	151 (49)	1.63	0.14
Diabetes mellitus	7 (18)	39 (14)	1.39	NS
History of restenosis	19 (44)	146 (49)	0.83	NS
Multivessel disease	19 (45)	141 (47)	0.93	NS

NS = not significant.

lated to the presence of angiographic ectasia. Ischemic complications were relatively infrequent after directional atherectomy, and were not related to the presence of angiographic ectasia (Table IV).

**Histologic analysis of lesions with angiographic ectasia:** In lesions with histologic analysis, normal vessel wall constituents were obtained in all 11 patients with angiographic ectasia (Figure 4). In the 65 lesions without angiographic ectasia, media was obtained in 37 (53%) and adventitia was obtained in 19 (29%) lesions.

**Restenosis after angiographic ectasia:** Repeat coronary arteriography was performed  $6.1 \pm 2.4$  months after directional atherectomy in 188 of 271 eligible pa-

tients (69%). Restenosis developed in 80 of 160 lesions (50%) without ectasia, in 17 of 28 lesions (61%) with ectasia, and in 13 of 19 lesions (68%) with marked ectasia ( $p = 0.12$ ) (Table IV). Notably, intimal hyperplasia was significantly greater in lesions with angiographic ectasia immediately after directional atherectomy.

## DISCUSSION

In contrast to balloon angioplasty, which exerts its principal geometric effect by splitting and tearing the atherosclerotic segment,<sup>16,17</sup> pathologic study has suggested that directional coronary atherectomy results in improved coronary dimensions by selectively excising

**TABLE II** Angiographic Correlates of Ectasia After Directional Atherectomy

Features	Ectasia— No. (%)	No Ectasia— No. (%)	Likelihood Ratio	Univariate p Value
Artery				
Left main	0 (0)	3 (1)	*	NS
LAD	28 (56)	186 (57)	0.97	NS
RCA	5 (10)	87 (27)	0.31	0.011
LCX	7 (14)	15 (5)	3.39	0.008
SVG	10 (20)	40 (11)	2.05	0.062
Lesion location				
Ostial	3 (8)	31 (11)	0.67	NS
Proximal	18 (45)	132 (46)	0.97	NS
Mid/distal	19 (48)	125 (43)	1.18	NS
Lesion morphology				
Eccentric	27 (56)	189 (59)	0.88	NS
Tortuosity	1 (2)	15 (5)	0.44	NS
Diffuse disease	4 (8)	45 (14)	0.63	NS
Length $\geq 10$ mm	5 (10)	35 (11)	0.93	NS
Bend $\geq 45^\circ$	3 (6)	30 (9)	0.63	NS
Irregularity	8 (16)	56 (17)	0.95	NS
Calcification	5 (10)	36 (11)	0.91	NS
Bifurcation	6 (12)	33 (10)	1.23	NS
Complex, thrombus containing	8 (16)	21 (6)	2.85	0.015
Before atherectomy				
Normal area (mm <sup>2</sup> )	$8.8 \pm 3.2$	$9.7 \pm 4.0$	—	0.07
Stenotic area (mm <sup>2</sup> )	$1.2 \pm 1.0$	$1.2 \pm 1.0$	—	NS
% Area stenosis	$88 \pm 9$	$86 \pm 10$	—	NS
After atherectomy				
Normal area (mm <sup>2</sup> )	$8.4 \pm 3.4$	$10.0 \pm 3.9$	—	0.003
Stenotic area (mm <sup>2</sup> )	$12.6 \pm 6.3$	$5.6 \pm 3.1$	—	<0.001
% Area stenosis	$-0.5 \pm 0.5$	$0.4 \pm 0.2$	—	<0.001

\*Not done due to no observations in ectasia group.  
LAD = left anterior descending artery; LCX = left circumflex; NS = not significant; RCA = right coronary artery; SVG = saphenous vein graft.

**TABLE III** Procedural Correlates of Ectasia After Directional Atherectomy

Features	Ectasia— No. (%)	No Ectasia— No. (%)	Likelihood Ratio	Univariate p Value
7Fr device	26 (53)	138 (45)	1.36	NS
DAR	$0.76 \pm 10$	$0.69 \pm 11$	—	<0.001
No. of specimens	$7 \pm 5$	$6 \pm 5$	—	NS
No. of passes	$12 \pm 7$	$11 \pm 8$	—	NS
Before PTCA	6 (12)	50 (15)	0.77	NS
After PTCA	2 (4)	38 (12)	0.33	NS
Postprocedural angiography				
Haziness	18 (38)	113 (39)	0.94	NS
Irregularity	8 (17)	51 (18)	0.94	NS
Dissection	17 (35)	66 (23)	1.87	0.057
Perforation	9 (0)	2 (1)	*	NS

\*Not performed owing to no observation in the ectasia group.  
DAR = device artery ratio; NS = not significant; PTCA = percutaneous transluminal coronary angioplasty.

**TABLE IV** Early and Late Outcome After Directional Atherectomy

	Ectasia— No. (%)	No Ectasia— No. (%)	Likelihood Ratio	Univariate p Value
Clinical outcome				
Abrupt closure	2 (4)	23 (7)	0.55	NS
Myocardial Infarction	1 (2)	4 (1)	1.63	NS
Coronary bypass surgery	1 (2)	18 (5)	0.35	NS
Death	0 (0)	3 (1)	*	NS
Restenosis†	17 (61)	80 (50)	1.62	NS
Intimal hyperplasia (mm <sup>2</sup> )	8.3 ± 8.9	2.4 ± 5.0	*	0.002

\*Not performed due to no observations in the ectasia group.  
†Analysis includes 188 patients with angiographic follow-up.  
NS = not significant.

the atherosclerotic lesion,<sup>5</sup> although a significant degree of mechanical dilatation may also occur.<sup>4</sup> Compared with standard balloon angioplasty, less angiographic dissection has been reported with directional atherectomy.<sup>18,19</sup>

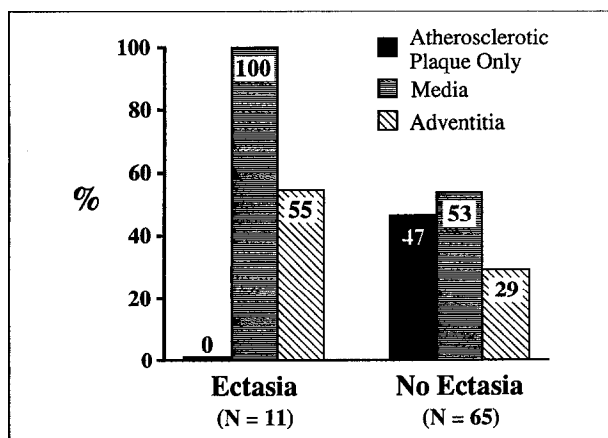
Despite these findings, the optimal depth of resection by directional atherectomy is not known. Larger luminal dimensions immediately after directional atherectomy have resulted in a lower incidence of late restenosis,<sup>10</sup> but deeper atheroma resection may be associated with retrieval of media and adventitia. In saphenous vein graft lesions, resection of normal vessel wall has been correlated with higher rates of restenosis.<sup>9</sup> Furthermore, vessel perforation may occur with more aggressive atheroma resection by directional atherectomy.<sup>1</sup>

Dilatation beyond the normal arterial lumen, defined angiographically as ectasia, is an uncommon finding after coronary angioplasty.<sup>20-22</sup> To date, the incidence and clinical implications of ectasia after directional atherectomy have not been reported. In the present series, ectasia occurred in 50 of 382 procedures (13%). Ectasia occurred more often in lesions within the circumflex coronary artery, presumably due to the more severe angulation of the circumflex artery, and less frequently in lesions within the right coronary artery. In

general, qualitative morphologic findings were not correlated with ectasia, although it was more frequent in complex, probably thrombus-containing lesions. Normal arterial diameters were smaller and device:artery ratios were higher in lesions with postprocedural ectasia, suggesting that oversized devices contributed to the deeper tissue resection in lesions with postprocedural ectasia. The incidence of postprocedural ectasia did not vary significantly between the early<sup>1-20</sup> and later operator (>20) experience. Although coronary dissection was performed more often in patients with ectasia, the presence of angiographic ectasia was not associated with an increased incidence of periprocedural complications.

In prior series, adventitia or media, or both, have been resected in 10 to 40% of lesions after directional atherectomy without apparent clinical sequelae.<sup>4,8</sup> In the present series, normal vessel wall was detected in all patients with angiographic ectasia, but was also present in 53% of lesions without ectasia. The present report also suggests an association between severe ectasia, defined by a residual area stenosis <-20%, and an increased incidence of restenosis compared with no ectasia (70 vs 50%;  $p = 0.12$ ). Moreover, intimal hyperplasia, defined as the loss of luminal dimensions from the postprocedural to follow-up study, was significantly greater in lesions with postprocedural ectasia.

The present study has several important limitations. First, the proximal and distal normal segments were selected by virtue of their location relative to the stenosis and relatively smooth angiographic borders. In the present report, the definition of angiographic ectasia was based on selection of a normal reference segment. If the segment selected had significant luminal narrowing due to atherosclerosis not apparent angiographically, the frequency of excision into the normal vessel wall may have been overestimated. Second, major ischemic complications occur infrequently after directional atherectomy and the sample size in the present study may be insufficient to detect differences in patients with and without angiographic ectasia. Finally, the present study does not address whether resection of media and adventitia predisposes to subsequent intimal hyperplasia restenosis. The high rate of media and adventitia resection and restenosis in patients without angiographic ectasia suggests that further studies evaluating the effect of the depth of resection on restenosis are needed.



**FIGURE 4.** Histologic findings in lesions with angiographic ectasia after atherectomy. Adventitia or media, or both, were present in all patients with angiographic ectasia, but also present in 53% of lesions without angiographic ectasia.

## REFERENCES

1. Hinohara T, Robertson GC, Selmon MR, Simpson JB. Directional coronary atherectomy. *J Invasive Cardiol* 1990;2:217-226.
2. Schatz RA, Baim DS, Leon M, Ellis SG, Goldberg S, Hirschfeld JW, Cleman MW, Cabin HS, Walker C, Stagg J, Buchbinder M, Teirstein PS, Topol EJ, Savage M, Perez JA, Curry RC, Whitworth H, Sousa JE, Tio F, Almagor Y, Ponder R, Penn IM, Leonard B, Levine SL, Fish RD, Palmaz JC. Clinical experience with the Palmaz-Schatz coronary stent. Initial results of a multicenter study. *Circulation* 1991;83:148-161.
3. Karsch KA, Haase KK, Voelker W, Baumbach A, Mausek M, Seipel L. Percutaneous coronary excimer laser angioplasty in patients with stable and unstable angina pectoris: results and incidence of restenosis during 6 months follow-up. *Circulation* 1990;81:1849-1859.
4. Safian RD, Gelbfish JS, Erny RE, Schmitt SJ, Schmidt DA, Baim DS. Coronary atherectomy. Clinical, angiographic, and histologic findings and observations regarding potential mechanisms. *Circulation* 1990;82:69-79.
5. Garratt KN, Edwards WD, Vlietstra RE, Kaufmann UP, Holmes DR Jr. Coronary morphology after percutaneous directional coronary atherectomy in humans: autopsy analysis of three patients. *J Am Coll Cardiol* 1990;16:1432-1436.
6. Hinohara T, Rowe M, Robertson G, Selmon M, Braden L, Simpson JB. Directional coronary atherectomy for the treatment of coronary lesions with abnormal contour. *J Invasive Cardiol* 1990;2:57-63.
7. Ellis SG, DeCesare NB, Pinkerton CA, Whitlow P, King SB III, Ghazzal ZMB, Kereiakes DJ, Popma JJ, Menke KK, Topol EJ, Holmes DR. Relation of stenosis morphology and clinical presentation to the procedural results of directional coronary atherectomy. *Circulation* 1991;84:644-653.
8. Garratt KN, Kaufmann UP, Edwards WD, Vlietstra RE, Holmes DR. Safety of percutaneous coronary atherectomy with deep arterial resection. *Am J Cardiol* 1989;64:538-540.
9. Garratt KN, Holmes DR Jr, Bell MR, Bresnahan JF, Kaufmann UP, Vlietstra RE, Edwards WD. Restenosis after directional coronary atherectomy: differences between primary atheromatous and restenosis lesions and influence of subintimal tissue resection. *J Am Coll Cardiol* 1990;16:1665-1671.
10. Kuntz RE, Safian RD, Schmidt DA, Levine MJ, Reis GJ, Baim DS. Restenosis following new coronary devices: the influence of post-procedural luminal diameter (abstr). *J Am Coll Cardiol* 1991;17:2A.
11. Ellis SG, Vandormael MG, Cowley MJ, DiSciascio G, Deligonul U, Topol EJ, Bulle TM. Coronary morphologic and clinical determinants of procedural outcome with angioplasty for multivessel coronary disease. Implications for patient selection. *Circulation* 1990;82:1193-1202.
12. Mancini GBJ, Simon SB, McGillem MJ, LeFree MT, Friedman HZ, Vogel RA. Automated quantitative coronary arteriography: morphologic and physiologic validation in vivo of a rapid digital angiographic method. *Circulation* 1987;75:452-460.
13. Johnson MR, Brayden GP, Ericksen EE, Collins SM, Skorton DJ, Harrison DG, Marcus ML, White CW. Changes in cross-sectional area of the coronary lumen in the six months after angioplasty: a quantitative analysis of the variable response to percutaneous transluminal angioplasty. *Circulation* 1986;73:467-475.
14. Dick R.J.L., Haudenschild CC, Popma JJ, Ellis SG, Muller DW, Topol EJ. Directional atherectomy for total coronary occlusions. *Coronary Artery Disease* 1991;2:189-199.
15. Popma JJ, De Cesare NB, Ellis SG, Holmes DR, Pinkerton CA, Whitlow P, King SB, Ghazzal ZMB, Topol EJ, Garratt KN, Kereiakes DJ. Clinical, angiographic, and procedural correlates of quantitative coronary dimensions following directional coronary atherectomy. *J Am Coll Cardiol* 1991;18:1183-1189.
16. Austin GE, Ratliff NH, Hollman J, Tabei S, Phillips DF. Intimal proliferation of smooth muscle cells as an explanation for recurrent coronary artery stenosis after percutaneous transluminal coronary angioplasty. *J Am Coll Cardiol* 1985;6:369-375.
17. Waller BF. "Crackers, breakers, stretchers, drillers, scrapers, shavers, burners, welders, and melters"—The future treatment of atherosclerotic coronary artery disease? A clinical-morphologic assessment. *J Am Coll Cardiol* 1989;13:969-987.
18. Rowe MH, Hinohara T, White NW, Robertson GC, Selmon MR, Simpson JB. Comparison of dissection rates and angiographic results following directional coronary atherectomy and coronary angioplasty. *Am J Cardiol* 1990;66:49-53.
19. Muller DWM, Ellis SG, Debowey DL, Topol EJ. Quantitative angiographic comparison of the immediate success of coronary angioplasty, coronary atherectomy, and endoluminal stenting. *Am J Cardiol* 1990;66:938-942.
20. Hill JA, Margolis JR, Feldman RL, Conti CR, Pepine CJ. Coronary arterial aneurysm formation after balloon angioplasty. *Am J Cardiol* 1983;52:261-264.
21. Wetson MW, Bowerman RE. Coronary artery aneurysm formation following PTCA. *Cathet Cardiovasc Diagn* 1987;52:261-264.
22. Holmes DR, Vlietstra RE, Mock MB, Reeder GS, Smith HC, Bove AA, Bresnahan JF, Piehler JM, Schaff HV, Orszulak TA. Angiographic changes produced by percutaneous transluminal coronary angioplasty. *Am J Cardiol* 1983;51:676-683.