

Thrombolytic Therapy: Adjuvant Mechanical Intervention for Acute Myocardial Infarction

David W.M. Muller, MBBS, and Eric J. Topol, MD

Following successful pharmacologic thrombolysis, early coronary angiography frequently shows a tight residual stenosis in the infarct-related artery at the site of recent occlusion. Approaches to the management of the residual stenosis have undergone a gradual evolution from an aggressive strategy of immediate balloon dilation to a more conservative approach. Randomized, controlled trials have indicated that immediate percutaneous transluminal coronary angioplasty (PTCA) is associated with no greater recovery in regional or global left ventricular function, and a tendency toward an increased incidence of complications, including the need for emergency coronary artery surgery and blood transfusion. The role of immediate rescue PTCA for failed thrombolysis has not been as rigorously investigated, but selected patients, including those with evidence of ongoing myocardial ischemia or hemodynamic instability, may benefit from this approach. A major source of current controversy is the value of routine coronary angiography after uncomplicated myocardial infarction. Two carefully conducted trials have indicated that a conservative strategy of clinically indicated, predischARGE cardiac catheterization may be associated with an increased need for readmission and late, elective cardiac catheterization when compared with a more invasive strategy of routine coronary angiography, but that the conservative approach is not associated with an increased incidence of death or reinfarction. Provision was not made in these studies, however, for evaluating the positive economic and psychologic impact of early coronary angiography, early hospital discharge, and early return to work of patients with a favorable postinfarction prognosis. It is

concluded that early mechanical revascularization following thrombolysis should be considered for ongoing myocardial ischemia, but should otherwise be deferred pending the results of predischARGE functional studies. For most patients, routine coronary angiography is likely to remain an important diagnostic tool and an integral component of the management of the convalescent phase of acute myocardial infarction.

(Am J Cardiol 1992;69:60A-70A)

Data accumulated in recent years have suggested strongly that both in-hospital and long-term survival after acute myocardial infarction can be increased significantly by measures that achieve early and sustained patency of the infarct-related coronary artery.¹⁻⁶ Thrombolytic therapy is one means of effectively restoring antegrade coronary flow in a high proportion of treated patients. Thrombolysis alone does little, however, to alter the underlying vessel wall disease that precipitated the acute ischemic event. As a result, infarct vessel reocclusion is relatively common and is associated with a high incidence of adverse clinical outcomes.⁷ In an attempt to reduce the likelihood of recurrent myocardial ischemia and to facilitate left ventricular functional recovery after myocardial reperfusion, mechanical revascularization therapies, including coronary balloon angioplasty and coronary artery bypass grafting, have been systematically evaluated by many investigators as adjuncts to pharmacologic thrombolysis.

In 1982, Meyer and colleagues⁸ described the use of percutaneous transluminal coronary angioplasty (PTCA) to dilate high-grade residual coronary stenoses after successful thrombolysis. In this small retrospective study, PTCA was attempted in 21 patients between 20 minutes and 31 hours after intracoronary administration of streptokinase. The procedure was successful in 17 patients; there were no in-hospital reocclusions and the late follow-up period was characterized by a low incidence of recurrent myocardial ischemia. In contrast, recurrent myocardial infarction occurred during the

From the Division of Cardiology and Department of Internal Medicine, University of Michigan Medical Center, Ann Arbor, Michigan, and Division of Cardiology, The Cleveland Clinic Foundation, Cleveland, Ohio.

Address for reprints: David W. M. Muller, MBBS, Division of Cardiology, B1 F245, University of Michigan Medical Center, 1500 East Medical Center Drive, Ann Arbor, Michigan 48109-0022.

initial hospitalization in 4 of 18 patients treated medically after intracoronary thrombolysis, and 3 patients died during the follow-up period.⁸ Early surgical revascularization following successful intracoronary thrombolysis for evolving myocardial infarction was also reported to be associated with a favorable long-term outcome by Mathey and colleagues.⁹ These 2 studies focused attention on the possibility of a combined pharmacologic and mechanical approach to restoring and maintaining antegrade coronary flow as the definitive treatment for acute myocardial infarction. In the intervening 10 years since the publication of these reports, the use of thrombolytic therapy has become firmly established as the first line of therapy for a substantial proportion of patients,¹⁰ but the need for, and optimal timing of, adjuvant mechanical revascularization to prevent late complications in this population remains somewhat controversial. Several post-thrombolytic revascularization strategies have been examined in multicenter, randomized, controlled trials. These include PTCA immediately after successful thrombolysis or for thrombolytic failure, late (usually pre-discharge) PTCA of residual critical stenoses in patent infarct-related arteries, and selective PTCA, in which mechanical revascularization is reserved for patients with recurrent, spontaneous or stress-induced postinfarction myocardial ischemia.

THROMBOLYSIS AND IMMEDIATE PERCUTANEOUS TRANSLUMINAL CORONARY ANGIOPLASTY

The role of balloon dilation of residual coronary stenoses in patent arteries immediately after successful thrombolysis has been well studied in randomized, controlled clinical trials. Three large trials compared immediate PTCA with a deferred interventional strategy in patients who had received intravenous recombinant tissue plasminogen activator (rt-PA).¹¹⁻¹³ Although the underlying hypothesis was the same for each of the studies, there were several important differences in study design among the trials. In the Thrombolysis and Angioplasty in Myocardial Infarction (TAMI) trial,¹¹ patients presenting within 4 hours of symptom onset underwent diagnostic coronary angiography 90 minutes after the initiation of the thrombolytic infusion. Only those patients with patent infarct vessels and anatomy deemed suitable for PTCA were then randomized to immediate coronary angioplasty or to repeat cardiac catheterization and PTCA prior to hospital discharge. In the Thrombolysis in Myocardial Infarction (TIMI-IIA)

study,^{12,13} randomization to 1 of 3 treatment strategies was performed prior to coronary angiography. Immediate PTCA (including dilation of persistently occluded arteries), was compared first with deferred coronary angiography and PTCA of suitable stenoses, performed 18-48 hours after the administration of thrombolytic therapy, and second, with a conservative strategy that consisted of pre-discharge coronary angiography in all patients and PTCA only in patients with exercise-induced ischemia and appropriate coronary anatomy. In the European Cooperative Study Group (ECSG) trial,¹⁴ eligible patients were randomly allocated either to a strategy of immediate coronary angioplasty, including PTCA of persistently occluded arteries, or to a strategy in which coronary angiography without PTCA was performed 10-20 days after admission. Because of these differences in study design, there were important differences between the trials in the frequency with which mechanical revascularization was actually performed. Coronary angioplasty was attempted in 100% of patients randomized to the immediate PTCA group in TAMI, compared with 72% in TIMI-IIA and 92% in ECSG. Similarly, in the deferred intervention groups, PTCA was performed in 52% of the patients in TAMI, but in 55% in TIMI-IIA and 6% in ECSG.

Despite these differences in trial design, the conclusions of the respective study groups were remarkably concordant. The principal end point for each study was left ventricular ejection fraction, determined by contrast ventriculography performed prior to hospital discharge. Each of the 3 trials concluded that immediate PTCA did not improve the extent of left ventricular global or regional functional recovery during the early convalescent period (Figure 1). Moreover, in each study, immediate intervention was associated with an increased incidence of procedural complications (including the need for emergency coronary artery bypass surgery and blood transfusion), no reduction in the incidence of reocclusion and reinfarction, and a trend toward an increased in-hospital mortality (Table I).

Studies of PTCA immediately after successful thrombolysis using agents other than rt-PA have also shown no significant advantage of this strategy over a deferred PTCA approach. Erbel and colleagues¹⁵ randomly assigned 206 patients with acute myocardial infarction to immediate angioplasty or no PTCA after initial treatment with combined intravenous and intracoronary streptokinase and mechanical recanalization using a flexible guide

TABLE I Clinical Outcomes in the Trials of Intravenous Tissue Plasminogen Activator and Immediate Percutaneous Transluminal Coronary Angiography: Comparison of Immediate and Deferred Interventional Strategies

	TAMI (n = 386)	ECSG (n = 367)	TIMI-IIA (n = 389)
In-hospital mortality (%)			
Immediate	4	7	8
Deferred	1	3	5
Reocclusion (%)			
Immediate	11	12.5	—
Deferred	13	11	—
Emergency CABG (%)			
Immediate	7	3	5
Deferred	2	0	3
Blood transfusion (%)			
Immediate	21	10	11
Deferred	14	4	3

CABG = coronary artery bypass graft surgery; ECSG = European Cooperative Study Group; TAMI = Thrombolysis and Angioplasty in Myocardial Infarction Trial; TIMI = Thrombolysis in Myocardial Infarction trial.

wire. Coronary angioplasty was attempted in all but 2 of the patients assigned to immediate PTCA, including patients with complex coronary anatomy, but was considered to have been successful in only 69% of these attempts. No difference in clinical outcome or mortality was apparent after 3 years follow-up. Coronary reocclusion or reinfarction occurred in 18% of patients undergoing immediate PTCA compared with 29% in the conservatively treated patients ($p = \text{nonsignificant}$) and the 3-year survival rates were 80% and 78%, respectively.

POTENTIAL EXPLANATIONS FOR THE NEGATIVE IMPACT OF IMMEDIATE PERCUTANEOUS TRANSLUMINAL CORONARY ANGIOPLASTY

From the above studies, it appears that immediate PTCA after successful pharmacologic thrombolysis has no role in the routine management of acute myocardial infarction. Several explanations may account for the failure of this therapeutic approach. Conceivably, the results may be falsely negative because of the inclusion of inappropriate

patients or the selection of insensitive end points or, alternatively, immediate PTCA may be truly detrimental and may actually promote adverse outcomes.

First, several trial design issues should be considered. One potential explanation for the lack of benefit of immediate mechanical revascularization in these studies may be that global and regional left ventricular function are insensitive endpoints that poorly reflect the potential impact of a therapy on long-term postinfarction survival.^{3,16} Indeed, several studies have shown clearly that early myocardial reperfusion therapy may increase long-term survival in the absence of a demonstrable effect on left ventricular functional recovery.^{1,17,18} In part, this lack of sensitivity may arise because patients selected for inclusion in the trials had well preserved global left ventricular function at presentation; the mean predischarge left ventricular ejection fraction for the 953 patients in the 3 rt-PA and immediate PTCA trials was 51%. A second possibility is that the duration of the initial follow-up period may have been inadequate to demonstrate improvement in left ventricular functional recovery and a reduction in late adverse events. However, careful assessment of late events and out-of-hospital survival of patients enrolled in the TIMI study¹³ showed that at 6 weeks, no difference was apparent between the groups in resting left ventricular ejection fraction, peak exercise ejection fraction or infarct zone segmental ejection fraction (Table II). Similarly, clinical follow-up 12 months postinfarction showed no difference in the cumulative incidence of recurrent myocardial infarction, the need for coronary artery bypass graft surgery or death, despite a considerable difference in the frequency with which coronary angioplasty was performed in the 3 groups (Table II). Finally, the inclusion of patients with noncritical residual stenoses may have obscured recognition of a positive impact of PTCA in patients with critical stenoses,

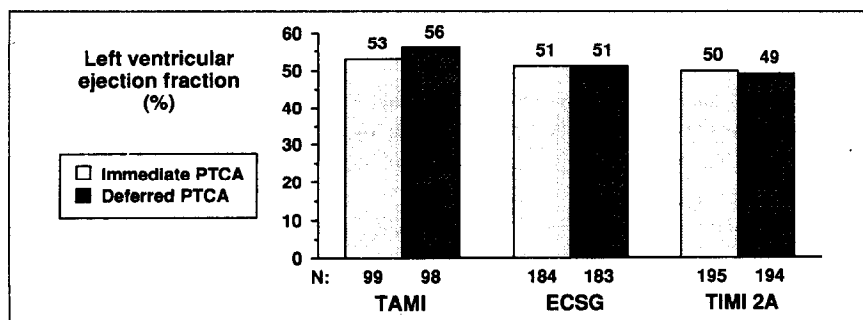


FIGURE 1. Predischarge left ventricular ejection in the immediate and deferred percutaneous transluminal coronary angioplasty (PTCA) groups of the 3 rt-PA/PTCA trials. Immediate PTCA was not associated with significant improvement in global left ventricular function in any of the trials. ECSG = European Cooperative Study Group; TAMI = Thrombolysis and Angioplasty in Myocardial Infarction trial; TIMI = Thrombolysis in Myocardial Infarction trial. (Adapted from *N Engl J Med*,¹¹ *JAMA*,¹² and *Lancet*.¹⁴)

the group at greatest risk of reocclusion and in whom flow restriction is most likely to compromise left ventricular functional recovery.¹⁹⁻²² This possibility was explored by Belenkie and colleagues²³ in a recent randomized study of immediate PTCA versus PTCA performed 18-48 hours after intravenous thrombolysis. In the study, the angiographic and left ventricular functional outcomes were stratified according to the adequacy of thrombolytic reperfusion and correlated with the incidence of reocclusion.²³ Ineffective reperfusion was defined as a residual lumen diameter stenosis >90% or delayed distal filling at the time of the initial diagnostic coronary angiogram. Reocclusion during the 18-48 hours before the scheduled angiographic procedure in patients assigned to the delayed PTCA strategy occurred in 37% of the patients with ineffective reperfusion compared with 5% of those with effective reperfusion ($p = 0.02$). Improvement in regional, but not global, left ventricular function was also greater in patients with initially ineffective reperfusion. However, neither the frequency of reocclusion nor the left ventricular functional recovery was influenced by whether PTCA was performed immediately or at 18-48 hours.²³

More likely than any of the methodologic considerations mentioned is the possibility that balloon dilation is truly detrimental and actually incites further thrombus formation and reocclusion in patients with freshly disrupted atheromatous plaques, even in the presence of systemic fibrinolysis. The presence of an intraluminal thrombus is known to be a risk factor for abrupt occlusion during elective coronary angioplasty,²⁴⁻²⁶ and for procedural failure in the setting of acute myocardial infarction.²⁷ Nonrandomized, retrospective studies have also suggested that elective balloon angioplasty performed within 1 week of symptom onset in patients with unstable coronary syndromes is associated with a lower success rate and a higher incidence of major procedural complications than a deferred PTCA strategy.²⁸ Several studies have described the histopathologic appearance of coronary arteries after sequential thrombolysis and balloon dilation in patients dying during the early postinfarction period.^{29,30} In one study,³⁰ prominent intramural hemorrhage was noted at the site of balloon dilation, and in 1 patient, medial hemorrhage resulted in subtotal occlusion of the dilated vessel.

Whether immediate PTCA would become a valuable strategy if reocclusion could be prevented by more potent antithrombin and antiplatelet

TABLE II Delayed, Elective Intervention and a Conservative Management Strategy after Thrombolysis

	TIMI-2B (n = 3,262)	SWIFT (n = 800)
Thrombolytic agent	t-PA	Anistreplase
Follow-up	6 weeks	1 year
Mortality (%)		
Invasive	5.2	5.8
Conservative	4.7	5.0
Reinfarction (%)		
Invasive	6.4	15.1
Conservative	5.8	12.9
Blood transfusion (%)		
Invasive	5.5	19.9*
Conservative	4.3	16.1*
Resting LVEF (%)		
Invasive	50.5	50.7
Conservative	49.9	51.7

LVEF = left ventricular ejection fraction; SWIFT = Should We Intervene Following Thrombolysis? trial; TIMI = Thrombolysis In Myocardial Infarction trial; t-PA = tissue plasminogen activator.
*Total hemorrhagic events.

agents, or by other interventional procedures such as directional coronary atherectomy or laser balloon angioplasty, is at present unclear. This possibility was suggested by a recent retrospective analysis of the results of the ECSG trial.³¹ The study examined the effects of immediate PTCA on left ventricular functional recovery in the subgroup of patients with successful reperfusion and sustained patency of the infarct artery. In these patients, global left ventricular function was somewhat better in the immediate PTCA group (left ventricular ejection fraction 50.8% vs 49.0%) due principally to a less extensive segment of regional infarct zone dysfunction.³¹ At the present time, however, the potential hazards of these procedures appear to outweigh this relatively small benefit, and there do not appear to be any data to suggest that immediate PTCA should be performed routinely following successful thrombolysis, no matter how severe the residual coronary stenosis.

RESCUE CORONARY ANGIOPLASTY

In contrast to the apparent consensus of opinion on the role of immediate PTCA of successfully recanalized infarct vessels, opinions on the importance of emergency balloon dilation of persistently occluded coronary arteries remain divergent, primarily because of a lack of relevant randomized data. Data from several observational studies do suggest, however, that rescue coronary angioplasty may be of value for thrombolytic failure in selected patients. The combined experience of rescue coronary angioplasty in the first 5 TAMI studies was recently reported.³² In this retrospective analysis, the in-hospital and long-term outcomes of 607

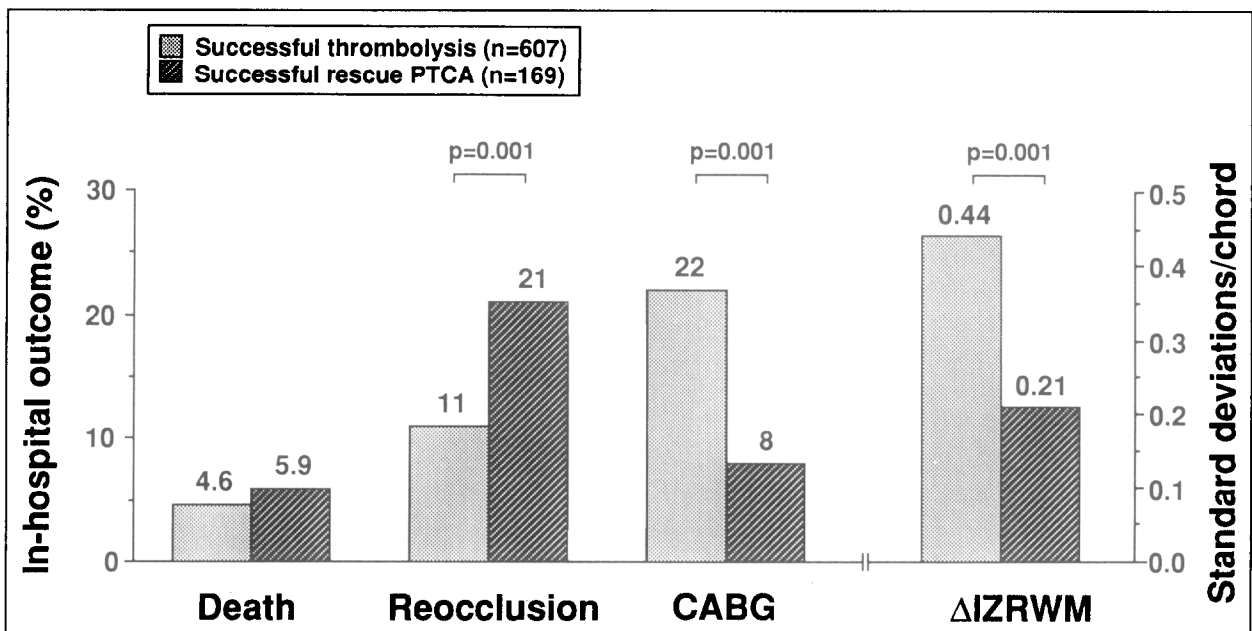


FIGURE 2. Successful pharmacologic thrombolysis versus successful rescue percutaneous transluminal coronary angioplasty (PTCA) after failed thrombolysis: in-hospital clinical outcome and regional infarct zone wall motion recovery (IZRWM). CABG = coronary artery bypass grafting. (Adapted from *J Am Coll Cardiol.*²⁵)

patients with successful thrombolysis were compared with the outcomes of 169 patients with successful rescue PTCA following failed intravenous thrombolysis. Although the overall in-hospital and long-term mortalities were similar in the 2 groups (4.6% vs 5.9% and 2% vs 3%, respectively), the incidence of reocclusion of the infarct-related artery was considerably higher following rescue angioplasty than following successful pharmacologic thrombolysis (21% vs 11%, $p < 0.001$) (Figure 2). This increased reocclusion rate was associated with significantly less improvement in both global and regional left ventricular functional recovery. Importantly, the incidence of reocclusion appeared to be markedly influenced by the thrombolytic regimen. Reocclusion after successful rescue PTCA occurred in 29% of patients treated with rt-PA alone, compared with 12% of patients treated with intravenous urokinase and 4% of patients treated with the combination of rt-PA and urokinase ($p < 0.019$). These findings are consistent with previous observations of a very high reocclusion rate following PTCA for unsuccessful rt-PA therapy³³ and lower, but nonetheless significant, reocclusion rates following the use of agents with more profound systemic fibrinolytic potential.³⁴⁻³⁹ Several explanations have been offered for the high reocclusion rate after successful rescue PTCA.^{32,40,41} Postmortem studies have suggested that atheromatous plaque at the site of acute occlusion in patients in whom pharmacologic thrombolysis has failed to restore luminal patency is characterized

by more extensive fissuring and disruption, with a greater component of intramural, platelet-rich thrombus that is relatively resistant to systemic fibrinolysis. Balloon dilation may simply extend the intimal fissure and aggravate an already highly thrombogenic focus.

Data from the TAMI study group experience also suggest that failure of rescue angioplasty to restore infarct vessel patency may be associated with a considerably increased early postinfarction mortality.³² Although the overall mortality of patients undergoing rescue PTCA was 9.9%, the in-hospital mortality following successful rescue PTCA was 5.9% compared with 39.1% in patients in whom the procedure failed to restore antegrade flow (Figure 3). Although this may, in part, reflect a natural selection bias (i.e., patients who fail

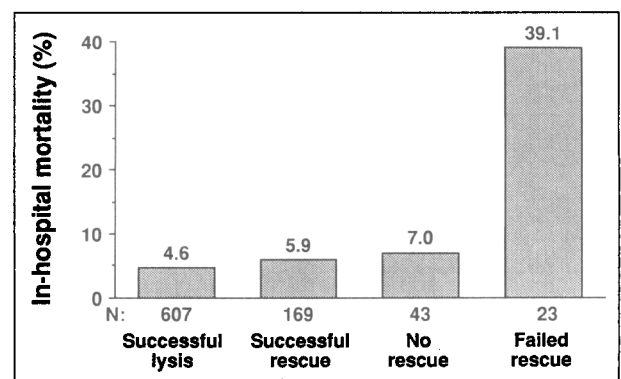
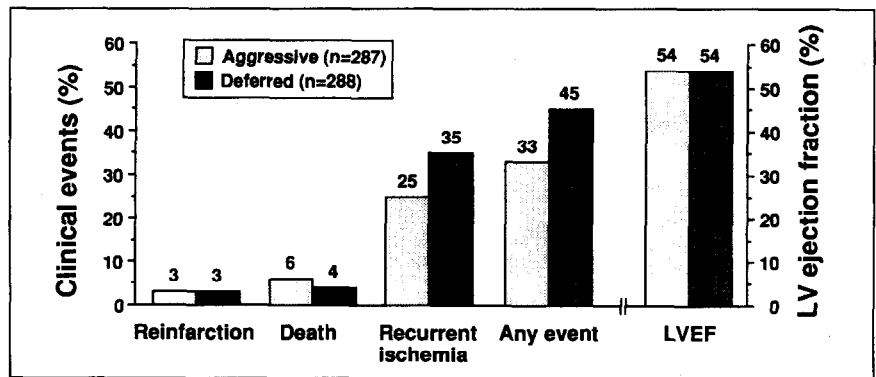


FIGURE 3. Impact of rescue percutaneous transluminal coronary angioplasty failure on in-hospital mortality. (Adapted from *J Am Coll Cardiol.*²⁵)

FIGURE 4. In-hospital outcomes of patients assigned to immediate cardiac catheterization (aggressive strategy) or predischARGE catheterization (deferred strategy) in the TAMI-V study. LVEF = left ventricular ejection fraction. (Adapted from *Circulation*.⁴²)



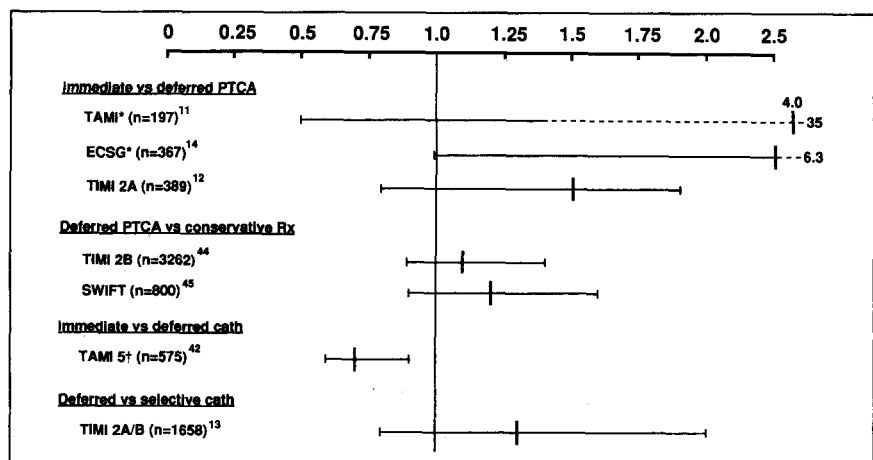
pharmacologic thrombolysis may be inherently sicker and more hemodynamically compromised), it may also indicate that rescue angioplasty can precipitate hemodynamic and electrical instability. This latter explanation may be particularly true for rescue angioplasty of persistently occluded right coronary arteries, a procedure that appears to be associated with an increased risk of heart block and life-threatening ventricular arrhythmias.³²

In addition to a retrospective analysis of the value of rescue angioplasty,³⁴ the TAMI study group has recently reported the results of a study that prospectively compared an aggressive interventional strategy with a more conservative post-thrombolytic strategy.⁴² In TAMI-V, 575 patients were randomly assigned to undergo immediate coronary angiography with rescue angioplasty for failed thrombolysis, or predischARGE cardiac catheterization after the administration of intravenous rt-PA, urokinase, or the combination of rt-PA and urokinase. The aggressive strategy was associated with a somewhat better predischARGE regional infarct zone wall motion (-2.16 vs -2.49 standard deviations/chord, $p = 0.004$) and greater freedom from adverse clinical outcomes (67% vs 55%,

$p = 0.004$) (Figures 4 and 5). In-hospital mortality was, however, slightly higher in the aggressively treated group (6% vs 4%), but this difference did not reach statistical significance.

The findings of these studies suggest that the role of rescue coronary angioplasty for failed pharmacologic therapy has not yet been defined adequately. Ongoing randomized trials will, it is hoped, further define the relative risks and benefits of this approach and may identify subgroups of patients in whom meaningful clinical benefits outweigh the potential hazards. Attention must also be given in future studies to the appropriate timing of mechanical revascularization in this setting. Conventionally, the angiographic success of pharmacologic thrombolysis has been recorded 90 minutes after initiation of the thrombolytic infusion. Thrombolysis continues beyond this point, however, and the patency rate may increase considerably between 90 minutes and 24-36 hours.⁴³ It is conceivable, therefore, that in some patients, PTCA of persistently occluded vessels could be deferred (to increase the likelihood of pharmacologic thrombolysis) without adversely affecting the extent of myocardial salvage or the likelihood of subsequent survival.

FIGURE 5. Impact of interventional strategy on clinical outcome at day 7 through 10 (TAMI, TAMI-V), day 21 (TIMI-IIA), day 42 (TIMI-IIB), day 90 (ECSG) and 1 year (SWIFT, TIMI-IIA/B). The vertical line indicates the relative risks of death or reinfarction of the more aggressive of the 2 strategies in each study. A relative risk < 1 indicates the treatment reduces the incidence of death or reinfarction; > 1 indicates an increased incidence of these outcomes. The horizontal line indicates the 95% confidence limits; superscript numbers indicate the reference number. PTCA = percutaneous transluminal coronary angioplasty; Rx = treatment; SWIFT = Should We Intervene Following Thrombolysis? trial. See Figure 1 for other abbreviations. *Incl-



CONSERVATIVE POST-THROMBOLYTIC STRATEGY

The failure of immediate PTCA to improve the short- and long-term clinical outcome of patients treated with intravenous thrombolysis in 3 well-controlled studies raised questions about the need for mechanical intervention, and even routine diagnostic coronary angiography, at any time in the postinfarction period. A conservative, noninvasive strategy was, therefore, evaluated in 2 large, randomized trials.^{44,45} After showing no advantage of immediate PTCA over deferred intervention, the TIMI study group compared a deferred PTCA strategy to a noninvasive strategy in a much larger population of patients.⁴⁴ Following the administration of intravenous rt-PA, 3,262 patients were randomly allocated to undergo either coronary angiography and balloon dilation of suitable infarct vessel stenoses 18–48 hours after admission, or to a conservative strategy. Patients in the latter group underwent diagnostic coronary angiography and mechanical revascularization only if myocardial ischemia recurred prior to hospital discharge, or if a pre-discharge functional study showed exercise-induced ischemia. Of the 1,636 patients assigned to the invasive strategy, 928 (56.7%) underwent attempted PTCA; 216 (13.2%) of the conservatively treated patients required PTCA within 14 days of admission for recurrent or provokable ischemia. The principal end points of the study were the incidence of reinfarction or death within 6 weeks of presentation. Secondary end points included rest and exercise left ventricular ejection fraction and exercise-induced myocardial ischemia. The study concluded that the conservative, clinically driven interventional strategy was associated with a clinical outcome that was at least as favorable as the more aggressive and invasive interventional strategy. The 2 groups were well matched with respect to age and sex distribution, time to treatment, and clinical condition at presentation. The early postinfarction survival was excellent in both groups, with a cumulative 6-week mortality of 5.2% in the invasive group compared with 4.7% in the conservatively treated group. Reinfarction occurred within the first 6 weeks in 5.9% and 5.4%, respectively (Figure 5). Similarly, no difference was apparent between the groups in resting left ventricular ejection fraction at hospital discharge (50.5% vs 49.9%, $p = 0.30$), or at 6 weeks (50.0% vs 50.4%, $p = 0.51$) (Table II). There was, however, a greater stress-induced increase in ejection fraction in the invasive strategy group (3.3% vs 2.3%, $p = 0.02$) and a higher incidence of exercise-induced myocar-

dial ischemia in the conservatively treated patients (17.7% vs 12.8%, $p < 0.001$).

The major conclusion of this study, that most patients can be successfully managed conservatively following thrombolysis, is supported by the findings of a European multicenter trial of delayed elective mechanical revascularization versus conservative therapy after intravenous anisoylated plasminogen activator complex therapy.⁴⁵ Patients who were pain free and hemodynamically stable during the first 24 hours of hospital admission were randomly assigned in the SWIFT (Should We Intervene Following Thrombolysis?) trial to one of 2 post-thrombolytic strategies. Patients assigned to the invasive strategy underwent diagnostic coronary angiography and, if appropriate, mechanical revascularization within 48 hours of randomization. Balloon dilation of persistently occluded vessels was not encouraged. As in the TIMI-IIIB study, coronary angiography with mechanical revascularization was performed on patients assigned to the conventional care group only if they developed recurrent postinfarction angina or had stress-induced ischemia. Of the 397 patients assigned to early intervention, 377 (95%) underwent coronary angiography within 7 days of admission and 228 (57%) were revascularized (169 by balloon dilation and 59 by coronary artery bypass graft surgery). In contrast, angiography was performed for clinical indications in 54 (13%) of 403 patients treated conservatively. Of these, only 19 patients (4.7%) were revascularized during the initial hospital admission, and an additional 40 patients (10%) underwent revascularization procedures during the 12-month follow-up period. Despite the considerably greater frequency of intervention in the invasive group, no difference in infarct-free survival was apparent between the two groups. The cumulative 1-year mortality was 5.8% in the intervention group compared with 5.0% in the conservative care group ($p = 0.6$), and the incidences of reinfarction were 15.1% and 12.9%, respectively ($p = 0.4$) (Figure 5). Similarly, no differences were apparent in left ventricular functional recovery or symptom status at 12 months (Table II).

Although these data are very compelling, several factors may limit the interpretation of the findings of these 2 studies. First, in both studies, PTCA was performed 18–48 hours after intravenous thrombolysis in the invasive groups, a time that, although “deferred,” is still early in the convalescent period. Although not formally tested in any of the randomized trials, it is possible that further deferral of the interventional procedure

until at least 1–2 weeks postinfarction might improve procedural outcome by allowing an adequate period for plaque stabilization and thrombus resolution. Angiographic studies have suggested, for example, that the morphology of the lesion in the infarct-related artery improves progressively over the 7–10 days after thrombolytic therapy, with resolution of intraluminal filling defects, a reduction in contour irregularity and a decrease in indices of lesion ulceration.⁴⁶ Thus, a truly deferred interventional strategy has not been tested against a noninvasive strategy. Secondly, although 67% of patients enrolled in the TIMI-IIB study were classified as “not-low-risk,” the in-hospital and long-term mortality of patients treated conservatively in this study and in the SWIFT trial were low, suggesting that the patients enrolled may, in fact, have had an excellent prognosis, regardless of the interventional strategy. Thus, the ability of these studies to detect an important difference in outcomes may have been limited, and extrapolation of the results to higher risk patient subgroups, including the elderly and patients presenting more than 3–4 hours after symptom onset, should therefore be undertaken with some caution.

MANAGEMENT OF RECURRENT MYOCARDIAL ISCHEMIA

If a conservative post-thrombolytic strategy is adopted, what then is the optimal management of recurrent myocardial ischemia and hemodynamic compromise during the early convalescent period? The frequency with which urgent cardiac catheterization was performed for these complications during the initial hospitalization of conservatively treated patients has ranged from 12% in the TIMI-IIA study¹² to 26% in the TAMI-V study.⁴⁷ The rationale for aggressive intervention in this setting is that angiographic evaluation permits appropriate triage to urgent mechanical revascularization or to continued medical therapy. In nonrandomized studies, urgent coronary angioplasty has been shown to improve 30-day survival for patients with cardiogenic shock⁴⁸ and to treat acute ischemic mitral valve regurgitation successfully.⁴⁹ Staged balloon angioplasty has also been advocated for patients with multivessel coronary artery disease,⁵⁰ a group known to be at increased risk of postinfarction mortality.⁵¹ Similarly, emergency coronary artery bypass surgery, performed for unsuccessful sequential intravenous rt-PA therapy and coronary angioplasty or for severe multivessel disease, has been shown to be a safe and effective therapy that, in one study, was associated with a substantial

degree of improvement in both global and regional left ventricular function.⁵²

This aggressive interventional approach for recurrent myocardial ischemia or hemodynamic instability was recently evaluated by the TAMI-V study group.⁴⁷ Of 288 patients initially allocated to a conservative treatment strategy, 54 (19%) underwent urgent cardiac catheterization within 24 hours and a further 21 patients (7%) required urgent intervention during the second to fourth hospital days. Coronary angiography showed that the infarct-related artery was occluded (TIMI flow grade 0 or 1) in 39%, but was patent in the remainder. Emergency coronary angioplasty was performed in 49% of the patients and 3% underwent emergency coronary artery bypass surgery. Despite this intervention, the need for urgent cardiac catheterization was associated with an increased in-hospital mortality (7% vs 3%, $p = 0.36$), and poorer predischARGE left ventricular function (left ventricular ejection fraction $50 \pm 11\%$ vs $54 \pm 11\%$, $p=0.12$). Multivariate analysis of 16 clinically available parameters identified only patient age and anterior wall myocardial infarction as independent predictors of the need for urgent intervention. The implications of this study are that recurrent ischemia and reinfarction, which are relatively common with currently available thrombolytic and anticoagulant regimens, are predicted poorly by clinical parameters. Further, these complications are associated with a significant morbidity and mortality despite aggressive interventional therapy. In the absence of a control group, it is unclear whether urgent intervention is the optimal treatment in this setting; it remains possible that some of these patients might respond better to repeated administration of intravenous thrombolytic therapy,⁵³ but this approach has not yet been adequately evaluated.

ROUTINE PREDISCHARGE DIAGNOSTIC CORONARY ANGIOGRAPHY

The final post-thrombolytic strategy that should be considered is routine predischarge coronary angiography without routine mechanical revascularization.⁵⁴ Using this approach, delineation of the coronary anatomy is performed primarily for prognostic purposes. The value of this approach has not been formally tested, but a nonrandomized comparison of selective and routine coronary angiography was performed by the TIMI study group using data acquired in the TIMI-IIA and -IIB studies.⁵⁵ The clinical outcomes of 197 patients assigned in the TIMI-IIA study to conservative management and

routine predischarge coronary angiography was compared with that of 1,461 patients assigned to selective cardiac catheterization (for recurrent or provokable ischemia) in the TIMI-IIB study. In the former group, coronary angiography was actually performed on 94% of the eligible patients compared with 35% of the patients in the selective catheterization group; 59.4% of the latter group had undergone invasive evaluation by the end of the 1-year follow-up period. The incidence of predischarge mechanical revascularization by coronary angioplasty or bypass graft surgery was similar in the 2 groups. At 1 year, the incidence of death and nonfatal reinfarction were similar in the 2 groups (Figure 5), but the number of hospital readmissions was greater in the selective coronary angiography group (37.9% vs 27.6%, $p = 0.007$). It could be concluded from this study that a reduction in the number of postinfarction angiographic procedures by 40% would substantially reduce health care costs and the risks to the patient of an unnecessary procedure. However, the added costs of routine angiography may well be offset by the 30% reduction in the need for hospital readmission and a reduction in the need for repeat (and perhaps even predischarge) exercise stress testing. Further, knowledge of the coronary anatomy may have a positive impact on the timing of hospital discharge,^{56,57} the psychologic health, and the employability of patients with a good prognosis, such as those with minimal coronary disease⁵⁸ or disease confined to a side branch coronary artery. Finally, knowledge of the coronary anatomy may have an important influence on the selection of medical therapy for patients with uncomplicated infarcts. Recent data have suggested, for example, that long-term β blockade may reduce postinfarction mortality in patients with persistently occluded infarct-related arteries.⁵⁹

CURRENT RECOMMENDATIONS

From the data given, several broad recommendations can be made for the use of adjuvant mechanical revascularization following intravenous thrombolysis. First, the majority of patients can be initially managed without urgent coronary angiography and PTCA. Patients with an uncomplicated course should undergo a submaximal stress test prior to hospital discharge and, in many cases, can be managed medically if the functional study shows no evidence of inducible myocardial ischemia. Our own bias is, however, that predischarge, diagnostic coronary angiography is a low risk, relatively inexpensive investigation that should be

offered to virtually all patients. Certainly, patients with provokable myocardial ischemia should undergo coronary angiography, preferably before hospital discharge, and, depending on the coronary anatomy, should then undergo elective mechanical revascularization of diseased arterial segments. In centers with active cardiac catheterization laboratories, early coronary angiography (days 4 to 6) should be considered with a view to early patient discharge and return to work, particularly for young, otherwise healthy patients without evidence of extensive myocardial infarction. In patients with evidence of a large, evolving myocardial infarction, persisting ischemic chest pain or hemodynamic instability at the time of admission, urgent coronary angiography remains a valuable diagnostic tool that permits triage to rescue PTCA for persistently occluded infarct vessels, urgent coronary artery bypass grafting for severe left main or triple vessel coronary disease or to medical therapy (and perhaps intra-aortic balloon pump support) if the infarct vessel is patent. This schema will undoubtedly require modification as data from ongoing clinical investigations become available and as more reliable noninvasive means are identified for determining peri- and postinfarction mortality risk for individual patients.

REFERENCES

1. Kennedy JW, Ritchie JL, Davis KB, Stadius ML, Maynard C, Fritz JK. The Western Washington randomized trial of intracoronary streptokinase in acute myocardial infarction. *N Engl J Med* 1985;312:1073-1078.
2. Cigarroa RG, Lange RA, Hillis LD. Prognosis after myocardial infarction in patients with and without residual antegrade coronary blood flow. *Am J Cardiol* 1989;64:155-160.
3. Van der Werf F. Discrepancies between the effects of coronary reperfusion on survival and left ventricular function. *Lancet* 1989;i:1367-1369.
4. Mathey DG, Schofer J, Sheehan FH, Krebber H, Justen M, Rodewald G, Dodge HT, Bleifeld W. Improved survival up to four years after early coronary thrombolysis. *Am J Cardiol* 1988;61:524-529.
5. Dalen JE, Gore JM, Braunwald E, Borer J, Goldberg RJ, Passamani ER, Forman S, Knattud G, and the TIMI Investigators. Six and twelve month follow-up of the phase I Thrombolysis in Myocardial Infarction (TIMI) trial. *Am J Cardiol* 1988;62:179-185.
6. Stack RS, Califf RM, Hinohara T, Phillips HR, Pryor DB, Simonton CA, Carlson EB, Morris KG, Behar VS, Kong Y, Peter RH, Hlatky MA, O'Connor CM, Mark DB. Survival and cardiac event rates in the first year after emergency coronary angioplasty for acute myocardial infarction. *J Am Coll Cardiol* 1988;11:1141-1149.
7. Ohman EM, Califf RM, Topol EJ, Candela R, Abbottsmith C, Ellis S, Sigmon KN, Kereiakes D, George B, Stack R. Consequences of reocclusion after successful reperfusion therapy in acute myocardial infarction. *Circulation* 1990;82:781-791.
8. Meyer J, Merx W, Schmitz H, Erbel R, Kiesslich T, Dorr R, Lambertz H, Bethge C, Krebs W, Bardos P, Minale C, Messmer BJ, Effert S. Percutaneous transluminal coronary angioplasty immediately after intracoronary streptolysis of transmural myocardial infarction. *Circulation* 1982;66:905-913.
9. Mathey DG, Rodewald G, Rentrop P, Leitz K, Merx W, Messmer BJ, Rutsch W, Bucherl ES. Intracoronary streptokinase, thrombolytic recanalization and subsequent surgical bypass of remaining atherosclerotic stenosis in acute myocardial infarction: complimentary combined approach affecting reduced infarct size, preventing reinfarction and improving left ventricular function. *Am Heart J* 1981;102:1194-1202.

10. Muller DWM, Topol EJ. Selection of patients with acute myocardial infarction for thrombolytic therapy. *Ann Intern Med* 1990;113:949-960.
11. Topol EJ, Califf RM, George BS, Kereiakes DJ, Abbottsmith CW, Candela RJ, Lee KL, Pitt B, Stack RS, O'Neill WW, and the TAMI Study Group. A randomized trial of immediate versus delayed elective angioplasty after intravenous tissue plasminogen activator in acute myocardial infarction. *N Engl J Med* 1987;317:581-588.
12. The TIMI Research Group. Immediate vs delayed catheterization and angioplasty following thrombolytic therapy for acute myocardial infarction: TIMI-IIA results. *JAMA* 1988;260:2849-2858.
13. Rogers WJ, Baim DS, Gore JM, Brown BG, Roberts R, Williams DO, Chesebro JH, Babb JD, Sheehan FH, Wackers FJTh, Zaret BL, Robertson TL, Passamani ER, Ross R, Knatterud GL, Braunwald E. Comparison of immediate invasive, delayed invasive, and conservative strategies after tissue-type plasminogen activator: results of the Thrombolysis in Myocardial Infarction (TIMI) Phase II-A Trial. *Circulation* 1990;81:1457-1476.
14. Simoons ML, Arnold AER, Betriu A, Bokslag M, de Bono DP, Brower RW, Col J, Dougherty FC, von Essen R, Lambertz H, Lubsen J, Meier B, Michel PL, Raynaud P, Rutsch W, Sanz GA, Schmidt W, Serruys PW, Thery C, Uebis R, Vahanian A, Van der Werf F, Willems GM, Wood D, Verstraete M. Thrombolysis with tissue plasminogen activator in acute myocardial infarction: no additional benefit from immediate percutaneous coronary angioplasty. *Lancet* 1988;i:197-202.
15. Erbel R, Pop T, Diefenbach C, Meyer J. Long-term results of thrombolytic therapy with and without percutaneous transluminal coronary angioplasty. *J Am Coll Cardiol* 1989;14:276-285.
16. Califf RM, Harrelson-Woodlief L, Topol EJ. Left ventricular ejection fraction may not be useful as an end point of thrombolytic therapy comparative trials. *Circulation* 1990;82:1847-1853.
17. Chesebro JH, Knatterud G, Roberts R, Borer J, Cohen LS, Dalen J, Dodge HT, Francis CK, Hillis D, Ludbrook P, Markis JE, Mueller H, Passamani ER, Powers ER, Rao AK, Robertson T, Ross A, Ryan TJ, Sobel BE, Willerson J, Williams DO, Zaret BL, Braunwald E. Thrombolysis in Myocardial Infarction (TIMI) trial: a comparison between intravenous tissue plasminogen activator and intravenous streptokinase. *Circulation* 1987;76:142-154.
18. Stack RS, O'Connor CM, Mark DB, Hinohara T, Phillips HR, Lee MM, Ramirez NM, O'Callaghan WG, Simonton CA, Carlson EB, Morris KG, Behar VS, Kong Y, Peter RH, Califf RM. Coronary perfusion during acute myocardial infarction with a combined therapy of coronary angioplasty and high dose intravenous streptokinase. *Circulation* 1988;77:151-161.
19. Harrison DG, Ferguson DW, Collins SM. Retrombosis after reperfusion with streptokinase: importance of geometry of residual lesions. *Circulation* 1984;69:991-994.
20. Sheehan FH, Mathey DG, Schofer J, Dodge HT, Bolson EL. Factors that determine recovery of left ventricular function after thrombolysis in patients with acute myocardial infarction. *Circulation* 1985;71:1121-1128.
21. Williams DO, Borer J, Braunwald E, Chesebro JH, Cohen LS, Dalen J, Dodge HT, Francis CK, Knatterud G, Ludbrook P, Markis JE, Mueller H, Desvigne-Nickens P, Passamani ER, Powers ER, Rao AK, Roberts R, Ross A, Ryan TJ, Sobel BE, Winniford M, Zaret B. Intravenous recombinant tissue plasminogen activator in patients with acute myocardial infarction: a report from the NHLBI Thrombolysis in Myocardial Infarction Trial. *Circulation* 1986;73:338-346.
22. Belenkie I, Thompson CR, Manyari DE, Knudtson ML, Duff HJ, Poon MC, Smith ER. Importance of effective, early and sustained reperfusion during acute myocardial infarction. *Am J Cardiol* 1989;63:912-916.
23. Belenkie I, Knudtson ML, Roth DL, Hansen JL, Traboulsi M, Hall CA, Manyari D, Filipchuck NG, Schnurr LP, Rosenthal TW, Smith ER. Relation between flow grade after thrombolytic therapy and the effect of angioplasty on left ventricular function: a prospective randomized trial. *Am Heart J* 1991;121:407-416.
24. Deligonul U, Gabliani GI, Caralis DG, Kern MJ, Vandormael MG. Percutaneous transluminal coronary angioplasty in patients with intracoronary thrombus. *Am J Cardiol* 1988;62:474-476.
25. Mabin TA, Holmes DR Jr, Smith HC, Vliestra RE, Bove AA, Reeder GS, Chesebro JH, Bresnahan JF, Orszulak TA. Intracoronary thrombus: role in coronary occlusion complicating percutaneous transluminal coronary angioplasty. *J Am Coll Cardiol* 1985;5:198-202.
26. Ellis SG, Roubin GS, King SB III, Douglas JS Jr, Weintraub WS, Thomas RG, Cox WR. Angiographic and clinical predictors of acute closure after native vessel coronary angioplasty. *Circulation* 1988;77:372-379.
27. Ellis SG, Topol EJ, Gallison L, Grines CL, Langburd AB, Bates ER, Walton JA, O'Neill WW. Predictors of success for coronary angioplasty performed for acute myocardial infarction. *J Am Coll Cardiol* 1988;12:1407-1415.
28. Myler RK, Shaw RE, Stertzer SH, Bashour TT, Ryan C, Hecht HS, Cumberland DC. Unstable angina and coronary angioplasty. *Circulation* 1990;82(suppl):88-95.
29. Duber C, Jungbluth A, Rumpelt H-J, Erbel R, Meyer J, Thoenes W. Morphology of the coronary arteries after combined thrombolysis and percutaneous coronary angioplasty for acute myocardial infarction. *Am J Cardiol* 1986;58:698-703.
30. Waller BF, Rothbaum DA, Pinkerton CA, Cowley MJ, Linnemeier TJ, Orr C, Irons M, Helmuth RA, Wills ER, Aust C. Status of the myocardium and infarct-related coronary artery in 19 necropsy patients with acute recanalization using pharmacologic (streptokinase, r-tissue plasminogen activator), mechanical (percutaneous transluminal coronary angioplasty) or combined types of reperfusion therapy. *J Am Coll Cardiol* 1987;9:785-801.
31. Arnold AER, Serruys PW, Rutsch W, Simoons ML, de Bono DP, Tijssen JGP, Lubsen J, Verstraete M. Reasons for the lack of benefit of immediate angioplasty during recombinant tissue plasminogen activator therapy for acute myocardial infarction: a regional wall motion analysis. *J Am Coll Cardiol* 1991;17:11-21.
32. Abbottsmith CW, Topol EJ, George BS, Stack RS, Kereiakes DJ, Candela RJ, Anderson LC, Harrelson-Woodlief LS, Califf RM. Fate of patients with acute myocardial infarction with patency of the infarct-related vessel achieved with successful thrombolysis versus rescue angioplasty. *J Am Coll Cardiol* 1990;16:770-778.
33. Baim DS, Braunwald E, Feit F, Knatterud GL, Passamani ER, Robertson TL, Rogers WJ, Solomon RE, Williams DO. The Thrombolysis in Myocardial Infarction (TIMI) Trial Phase II: additional information and perspectives. *J Am Coll Cardiol* 1990;15:1188-1192.
34. Fung AY, Lai P, Topol EJ. Value of percutaneous transluminal coronary angioplasty after unsuccessful intravenous streptokinase therapy in acute myocardial infarction. *Am J Cardiol* 1986;58:686-691.
35. O'Connor CM, Mark DB, Hinohara T, Stack RS, Rendall D, Hlatky MA, Pryor DB, Phillips HR, Califf RM. Rescue coronary angioplasty after failure of intravenous streptokinase in acute myocardial infarction: in-hospital and long-term outcomes. *J Invasive Cardiol* 1989;1:85-95.
36. Grines CL, Nissen SE, Booth DC, Branco MC, Gurley JC, Bennett KA, DeMaria AN, and the KAMIT Study Group. A new thrombolytic regimen for acute myocardial infarction using combination half dose tissue-type plasminogen activator with full dose streptokinase: a pilot study. *J Am Coll Cardiol* 1989;14:573-580.
37. Holmes DR, Gersch BJ, Bailey KR, Reeder GS, Bresnahan JF, Bresnahan DR, Vliestra RE. Emergency "rescue" percutaneous transluminal coronary angioplasty after failed thrombolysis with streptokinase: early and late results. *Circulation* 1990;81(suppl):IV51-56.
38. Whitlow PL, and the CRAFT Study Group. Catheterization/Rescue Angioplasty Following Thrombolysis (CRAFT) Study: results of rescue angioplasty (abstr). *Circulation* 1990;82:III-308.
39. Morris JA, Muller DWM, Topol EJ. Combination thrombolytic therapy: a comparison of simultaneous and sequential regimens of tissue plasminogen activator and urokinase. *Am Heart J* 1991;122:375-379.
40. Richardson SG, Callen D, Morton P, Murtagh JG, Scott ME, O'Keefe DB. Pathologic changes after intravenous streptokinase treatment in eight patients with acute myocardial infarction. *Br Heart J* 1989;61:390-395.
41. Davies MJ. Successful and unsuccessful coronary thrombolysis. *Br Heart J* 1989;61:381-384.
42. Califf RM, Topol EJ, Stack RS, Ellis SG, George BS, Kereiakes DJ, Samaha JK, Worley SJ, Anderson JL, Harrelson-Woodlief L, Wall TC, Phillips HR, Abbottsmith CW, Candela RJ, Flanagan WH, Sasahara AA, Mantell SJ, Lee KL. Evaluation of combination thrombolytic therapy and timing of cardiac catheterization in acute myocardial infarction. Results of Thrombolysis and Angioplasty in Myocardial Infarction-phase 5 randomized trial. *Circulation* 1991;83:1543-1556.
43. PRIMI Trial Study Group. Randomized double-blind trial of recombinant pro-urokinase against streptokinase in acute myocardial infarction. *Lancet* 1989; i:863-867.
44. The TIMI Study Group. Comparison of invasive and conservative strategies after treatment with intravenous tissue plasminogen activator in acute myocardial infarction. Results of the Thrombolysis in Myocardial Infarction (TIMI) phase II trial. *N Engl J Med* 1989;320:618-627.
45. SWIFT (Should We Intervene Following Thrombolysis?) Trial Study Group. SWIFT trial of delayed elective intervention vs conservative treatment after thrombolysis with anistreplase in acute myocardial infarction. *Br Med J* 1991;302:555-560.
46. Davies SW, Marchant B, Lyons JP, Timmis AD, Rothman MT, Layton CA, Balcon R. Coronary lesion morphology in acute myocardial infarction:

demonstration of early remodeling after streptokinase treatment. *J Am Coll Cardiol* 1990;16:1079-1086.

47. Muller DWM, Topol EJ, Woodlief LH, Ellis SG, George BS, Kereiakes DJ, Samaha J, Worley S, Sigmon KN, Califf RM and the Thrombolysis and Angioplasty in Myocardial Infarction (TAMI) Study Group. Determinants of the need for early acute intervention in patients treated conservatively following thrombolytic therapy for acute myocardial infarction. *J Am Coll Cardiol* 1991;18 (in press).

48. Lee L, Bates ER, Pitt B, Walton JA, Laufer N, O'Neill WW. Percutaneous transluminal coronary angioplasty improves survival in acute myocardial infarction complicated by cardiogenic shock. *Circulation* 1988;78:1345-1351.

49. Shawl FA, Forman MB, Punja S, Goldbaum TS. Emergent coronary angioplasty in the treatment of acute ischemic mitral regurgitation: long-term results in five cases. *J Am Coll Cardiol* 1989;14:986-991.

50. Nath A, Disciascio G, Kelly KM, Vetrovec GW, Testerman C, Goudreau E, Cowley MJ. Multivessel coronary angioplasty early after acute myocardial infarction. *J Am Coll Cardiol* 1990;16:545-550.

51. Muller DWM, Topol EJ, Ellis SG, Sigmon KN, Lee K, Califf RM and the Thrombolysis and Angioplasty in Myocardial Infarction (TAMI) Study Group. Multivessel coronary artery disease: a key predictor of short-term prognosis after reperfusion therapy for acute myocardial infarction. *Am Heart J* 1991;121:1042-1049.

52. Kereiakes DJ, Topol EJ, George BS, Abbottsmith CW, Stack RS, Candela RJ, O'Neill WW, Martin LH, Califf RM, and the TAMI Study Group. Emergency coronary artery bypass surgery preserves global and regional left ventricular function after intravenous tissue plasminogen activator therapy for acute myocardial infarction. *J Am Coll Cardiol* 1988;11:899-907.

53. Barbash GI, Hod H, Roth A, Faibel HE, Mandel Y, Miller HI, Rath S, Zahav YH, Rabinowitz B, Seligsohn U, Pelled B, Schlesinger Z, Motro M, Laniado S, Kaplinsky E. Repeat infusions of recombinant tissue-type plasminogen activator in patients with acute myocardial infarction and early recurrent myocardial ischemia. *J Am Coll Cardiol* 1990;16:779-783.

54. Topol EJ, Holmes DR, Rogers WJ. Coronary angiography after thrombolytic therapy for acute myocardial infarction. *Ann Intern Med* 1991;114:877-885.

55. Rogers WJ, Babb JD, Baim DS, Chesebro JH, Gore JM, Roberts R, Williams DO, Frederick M, Passamani ER, Braunwald E. Selective versus routine predischarge coronary arteriography after therapy with recombinant tissue-type plasminogen activator, heparin and aspirin for acute myocardial infarction. *J Am Coll Cardiol* 1991;17:1007-1016.

56. Topol EJ, Burek K, O'Neill WW, Kewman DG, Kander NH, Shea MJ, Schork MA, Kirscht J, Juni JE, Pitt B. A randomized controlled trial of hospital discharge three days after myocardial infarction in the era of reperfusion. *N Engl J Med* 1988;318:1083-1088.

57. Mark DB, Sigmon K, Topol EJ, Kereiakes DJ, Pryor DB, Candela RJ, Califf RM. Identification of acute myocardial infarction patients suitable for early hospital discharge after aggressive interventional therapy. *Circulation* 1991;83:1186-1193.

58. Kereiakes DJ, Topol EJ, George BS, Stack RS, Abbottsmith CW, Ellis S, Candela RJ, Harrelson L, Martin LH, Califf RM. Myocardial infarction with minimal coronary atherosclerosis in the era of thrombolytic reperfusion. *J Am Coll Cardiol* 1991;17:304-312.

59. Glamann BD, Lange RA, Hillis LD. Beneficial effect of long-term beta blockade after acute myocardial infarction in patients without antegrade flow in the infarct artery. *Am J Cardiol* 1991;68:150-154.