

GASTROJEJUNOCOLIC FISTULA*

C. SHERRILL RIFE, M.D.

Instructor in Surgery, University of Michigan Medical School

ANN ARBOR, MICHIGAN

NO disease of the abdomen commands more respect from the surgeon than gastrojejunocolic fistula. It is approached with apprehension because of its operative difficulties and its questionable outcome. Gastrojejunal ulcer, the preceding lesion of fistula, has resulted from the promiscuous use of gastroenterostomy for all types of ulcer, and, as a consequence, has brought the operation into ill-repute as far as many surgeons are concerned. It must be admitted, however, that this procedure is still efficacious in selected cases, particularly in the older group of patients with pyloric stenosis and low gastric acidity. The declining popularity of gastroenterostomy may be partially attributed to the failure of many surgeons to insist on a careful medical program of treatment long after operation, if not for life.

The first authentic case of gastrojejunocolic fistula was reported by Czerny in 1903. At operation, the fistula was removed by a block resection of the involved portions of the stomach, jejunum, and colon, and a new gastroenterostomy constructed; this method is still employed in selected cases. Verbrugge, in 1925, made an exhaustive review of the literature and reported 216 cases of gastrocolic and jejunocolic fistulas, including twenty-one cases seen at the Mayo Clinic. In ninety-five of these cases, fistula was the result of an anastomotic ulcer which had followed gastroenterostomy for duodenal or gastric ulcer. In a series of 6,214 gastroenterostomies done at the Mayo Clinic prior to 1924, Verbrugge reported that 1.4 per cent developed gastrojejunal ulcer, and that 0.06 per cent developed fistula.

A study of the literature reveals that there is a wide variation in the reported incidence of gastrojejunal ulcer. Walton reports an incidence as low as 1.7 per cent, while Strauss, Block, and Friedman state that the incidence in their cases is about 24 per cent. Wilkie's figures show an incidence of about 3.5 per cent for all types of gastroenterostomy for ulcer. The correct incidence of fistula is even more difficult to determine than that of jejunal ulcer, chiefly because of failure to make the diagnosis clinically or by Roentgen ray examination, and because of the fact that many suspected cases do not come to operation. Loewy, in 1921, reviewed the literature and reported seventy-six cases of fistula following 400 cases of secondary ulcers, an incidence of about 19 per cent. Allen, in a recent study of his cases of fistula, has reported its incidence to be about 14 per cent in cases of post-operative gastrojejunal ulcer.

ETIOLOGY

Inasmuch as the primary etiologic factors leading to the production of gastrojejunocolic fistula are those concerned with formation of jejunal ulcer, the various theories pertaining to the development of jejunal ulcer itself will be discussed in the following paragraphs.

Gastrojejunocolic fistula is usually due to post-operative jejunal ulcer, and the original lesion is, in most instances, a duodenal ulcer. In Loewy's series of seventy-six cases, there were twenty-seven duodenal ulcers, twenty-eight pyloric ulcers, and ten gastric ulcers. In the series of fourteen cases of fistula reported in this

* From the Department of Surgery, University of Michigan.

study, duodenal ulcer was the original lesion in thirteen cases. One was due to extensive carcinoma of the stomach extend-

these two operations. That is, by using the above methods to divert the secretions which neutralize gastric juice, they con-

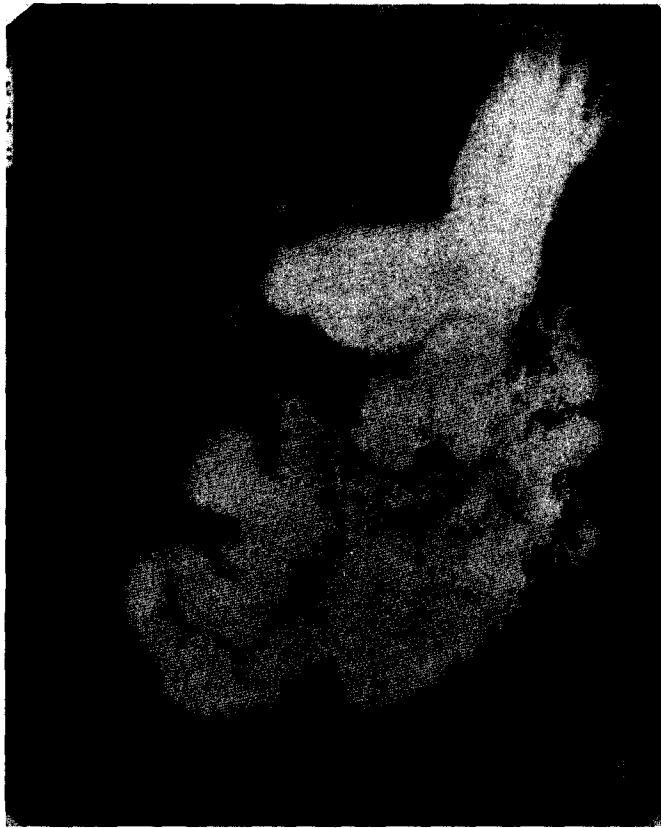

FIG. 1. Case XI. Roentgenogram showing the communication between the stomach and the transverse colon. Film was taken about ten minutes after ingestion of barium. Note the extensive filling of the small bowel. At fluoroscopy a loop of jejunum was easily visualized between the stomach and the colon.

ing into the transverse colon and will not be considered in detail in this study.

Ample evidence has been submitted to show that hyperacidity plays a major rôle in the production of peptic ulcer; this evidence also holds in regard to jejunal ulcer. The experiments of Mann and Williamson have given considerable confirmation to this theory. In operations on dogs they worked on the presumption that the increase in acid or the deficiency of alkali was an important factor in the production of ulcer. These operations were: (1) duodenectomy; (2) transplantation of the bile and pancreatic ducts to the terminal ileum; and (3) a combination of

sistently produced types of peptic ulcer similar to the subacute and chronic ulcers found in man.

The sex incidence of gastrojejunal ulcer and fistula lends support to the importance of hyperacidity as a causal factor. We know that men have higher gastric acidities than women, and that peptic ulcer is more common in men than in women; this disproportion is even more striking in jejunal ulcer and in fistula. In the group of ninety-five cases of fistula following gastroenterostomy for ulcer which were reported by Verbrugge, all but one occurred in males. It is interesting that in this small series of thirteen cases of fistula following

gastrojejunal ulcer, two occurred in woman, an incidence of about 15 per cent.

Persons with duodenal ulcer are more

anacidity, or a very low acidity, is usually present in carcinoma of the stomach.

The use of tight intestinal clamps has

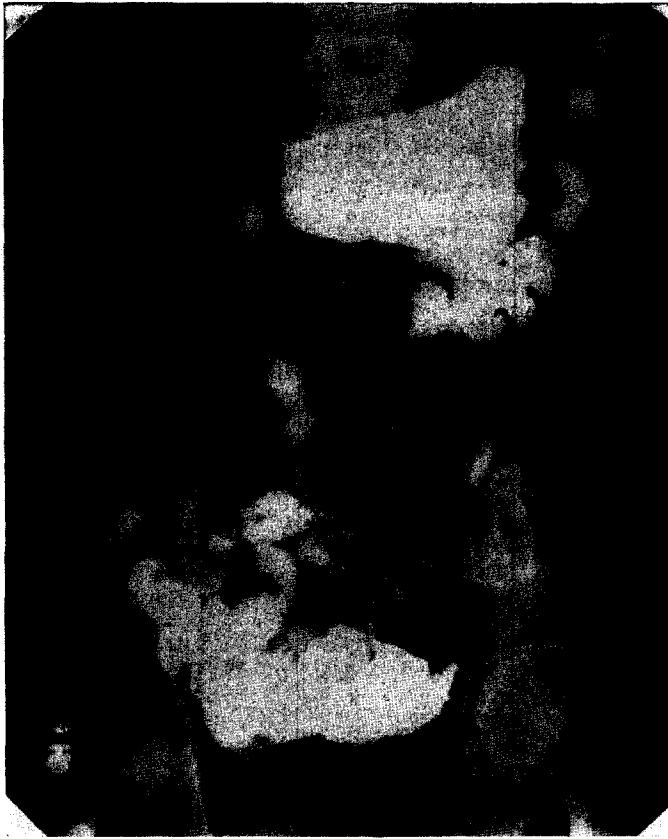


FIG. 2. Case XI. Roentgenogram taken four hours after that shown in Figure 1. Most of the barium in the small bowel has now passed into its distal loops. There is still barium present in the transverse colon at the point of communication with the stomach.

likely to have higher acids than those with gastric ulcer. Gastrojejunal ulcer and fistula are much more common following operations for duodenal ulcer. However, all the blame for these complications cannot be attributed to hyperacidity, for duodenal ulcers are more common than gastric ulcers. Also, ulcers of the stomach are frequently excised or destroyed by cauterization at the time of gastroenterostomy or are removed by partial gastrectomy.

Gastrojejunal ulcer and fistula are practically unheard of in patients in whom gastroenterostomy is done for unresectable carcinoma of the stomach. We know that

been alleged to be a cause of gastrojejunal ulcer. There are many arguments against this hypothesis. We know that the common site for jejunal ulcer is in that portion of the jejunum not gripped by the clamps, and also that the interval between operation and onset of ulcer symptoms may be several years in length. In support of this statement the work of Hurst and Stewart is definitely contributory. They had the opportunity of doing autopsies on 131 patients who had had operations for ulcer. In this group there were forty-six patients who had died within ten days following operation, and none of these had evidence

of jejunal ulcer at autopsy. There were only three jejunal ulcers in a group of forty-one patients who had died from ten than anterior, gastroenterostomy. This is unfortunate from the technical standpoint, for with the short loop used in the posterior

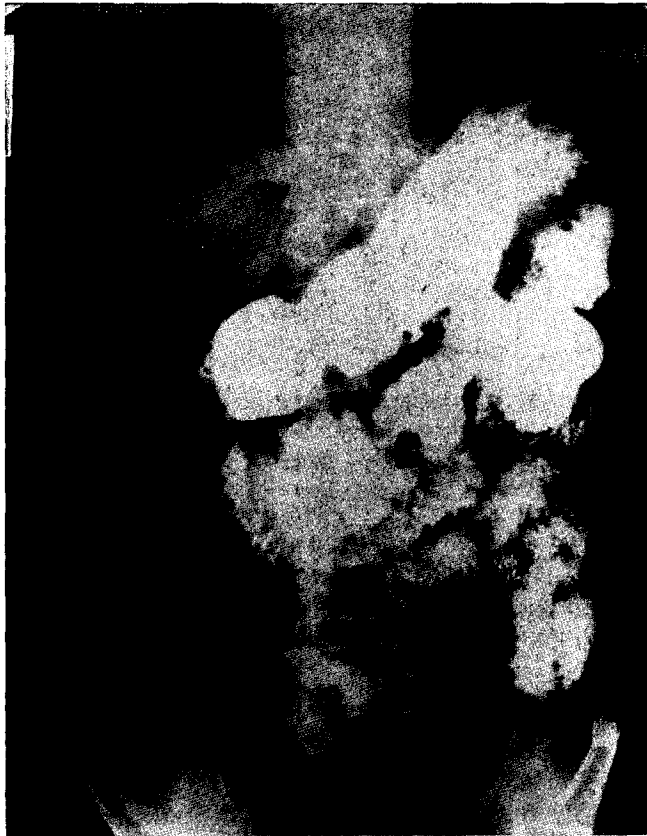

FIG. 3. Case XIV. Film taken immediately after the ingestion of barium. The gastrojejunal fistula is clearly shown. Note the extensive filling of the transverse colon.

days to two months following operation. However, in a group of forty-three patients whose deaths occurred nine months or more after operation, there were twenty-two cases of jejunal ulcer. It is admitted that jejunal ulcer may occur almost immediately after gastroenterostomy, but this is rare.

The theory that non-absorbable suture material is responsible for the production of anastomotic ulcer has been largely abandoned. The complication is still highly prevalent in spite of the use of absorbable materials.

PATHOLOGY

When a fistula occurs it is practically always a complication of posterior, rather

type of operation, the inflammatory process in the jejunum may extend well down into the root of the mesentery near the ligament of Treitz, making resection of the fistula very difficult. In the majority of cases reported in the literature the fistulous connection is between the jejunum and the transverse colon. A direct communication between the stomach and colon is uncommon. The location of the fistula varies considerably, but it is usually situated close to the gastroenterostomy and below it. Depending upon the time and mode of perforation of the jejunal ulcer into the transverse colon, there may or may not be extensive adhesion formation.

The mucous membrane which lines the fistulous tract is usually smooth and has a

glistening appearance. Ulceration in the tract is rare, and it has been demonstrated at operation that the formation of fistula from the colon into the jejunum rather than in the opposite direction. This is due to the fact that the orifice on the jejunal




FIG. 4. Case XIII. Post-evacuation film taken about fifteen minutes following introduction of barium per rectum. The fistulous tract cannot be seen in this study, but note the marked filling of the stomach.

has resulted in a cure of the original gastrojejunal ulcer. The absence of an active marginal ulcer is also the rule in cases where the communication between the jejunum and colon is located quite distal to the gastroenterostomy stoma (18 cm. distal to the stoma in one of the cases reported in this study).

The size of the fistula may vary greatly; in the cases presented in this report, the size varied from about 4 mm. to 6 cm. Fistulas are nearly always single, even though there may be multiple gastrojejunal ulcers. In most cases of fistula there is structural evidence that the greater part of the regurgitation which takes place is

side may be located in the folds of mucosa and constitute a valve-like action. This accounts for the relatively low incidence of cases which show undigested food materials in the stools, and for the high incidence of those which have foul eructations. It also helps to explain the intermittent nature of symptoms. Frequently the efferent loop of jejunum is dilated and hypertrophied, probably due to irritation from acid gastric contents and from fecal colon contents. The colon may be constricted at the location of the fistula, and dilated proximal to this point, simulating intestinal obstruction.

SYMPTOMATOLOGY

Diarrhea. The occurrence of a persistent or intermittent diarrhea in a patient who has had a gastroenterostomy for ulcer is the most significant symptom of the presence of a fistula. It is the most common symptom and is frequently the first to appear. It is not unusual for patients with fistula to be treated for ulcerative colitis or dysentery for long periods of time before the correct diagnosis is made. The stools may be watery or semi-liquid; they contain neutral fats and are usually very foul smelling. As stated above, undigested food particles are usually absent; this may be the case even though the fistula be large.

Diarrhea is the manifestation of the disease which is responsible for the emaciated condition of the patient. It is the most difficult symptom to abate, being refractory to medication, though it may be alleviated somewhat by the use of a high residue diet.

Diarrhea was a prominent symptom in all the fourteen cases reported in this study, and the chief complaint of ten patients.

Vomiting. Vomiting may occur in patients with fistula, but it is unusual to find actual fecal vomiting. Foul-smelling eructations, on the other hand, occur frequently and are more prevalent during the periods of diarrhea. After the patient has been on a constipating diet for several days, the vomiting and eructations sometimes disappear, recurring with the next episode of diarrhea.

It is interesting to note that in one of our cases (Case VIII), fecal vomiting occurred on the fourteenth day following operation done elsewhere; this type of vomiting occurred intermittently for five and one-half years before the diagnosis of fistula was made and surgical treatment instituted. At operation, it was found that an erroneous anastomosis had been made between the stomach and the transverse colon.

Pain. There are no identifying characteristics of the type of pain which accom-

panies fistula. There is a preliminary epigastric pain due to the ulcer itself, but this frequently disappears when the ulcer erodes through to the colon, curing itself. The pain of fistula is usually referred to the colon area, is worse during periods of constipation, and may be relieved by a bowel movement. Severe pain is rare except when there is associated intestinal obstruction.

Anorexia. Loss of appetite is an uncommon symptom of fistula, even in patients who have eructations with a feculent odor. It is a significant symptom in patients who are afflicted with fecal vomiting.

Loss of Weight. Loss of weight is practically a constant symptom of fistula. It may be tremendous, the patient reaching a marked degree of emaciation, thereby increasing the operative risk. The patient may regain some weight during the periods when the appetite is good and when the diarrhea ceases, but in general pre-operative attempts to increase the weight are discouraging. In this series of thirteen patients with fistula which followed ulcer, one had had a weight loss of 60 pounds, four had lost 40 pounds or more, and three had lost about 30 pounds. Poynton and MacGregor have reported a patient who not only showed a marked degree of emaciation, but who also had an associated nutritional edema of considerable severity.

PHYSICAL FINDINGS

Evidence of emaciation is the most striking characteristic of patients with fistula. As a rule, palpation of the abdomen reveals nothing significant. A small percentage of patients show a varying degree of distention of either the small or large bowel. Tenderness may be present over a dilated loop of gut. Four of the patients in this study had incisional hernias of moderate size.

CLINICAL DIAGNOSIS

The classical picture of gastrojejunal colic fistula is that of a history of relief of ulcer symptoms by operation, followed by a

period of recurrent epigastric pain months or years later, and then by a period of intermittent diarrhea with associated foul eructations or fecal vomiting, leading finally to a marked degree of emaciation. The appearance of undigested food materials in the stools very soon after ingestion is pathognomonic of the disease, but this occurs only in the fistulas of large diameter. In those of smaller caliber, various dye stuffs, such as carmine, charcoal, etc., may be useful in demonstrating this rapid passage. Because of the occasional valve-like character of the opening of the jejunal side, a fistula may occasionally be more easily demonstrated with colored enemata.

ROENTGENOLOGIC DIAGNOSIS

The roentgenologic aspects of fistulous communication between the stomach and large intestine are spectacular and can scarcely be misinterpreted. Conclusive as they are, however, these signs cannot be observed unless the diagnostic procedures employed are well suited to the situation.

A few technical principles are of prime importance in this connection. If opaque material is seen to leave the stomach by an unusual route, the fluoroscopist should at once apply digital pressure over the point of escape to prevent rapid filling of intestinal loops which would otherwise obscure the finer details of the stomach and proximal duodenum. The initial use of a spoonful of Rugar, or any concentrated barium preparation of high viscosity, is very helpful, particularly if previous gastric surgery is known or suspected, because the time interval between deglutition and initial gastric emptying is definitely prolonged, permitting more leisurely observation.

When any short-circuiting operation has been performed upon the stomach, it is important to determine the degree of residual obstruction at or near the pylorus. Manual obstruction of the operative gastric opening at fluoroscopy is necessary in making such an examination.

If barium can be observed to enter the colon shortly after escaping from the stomach the diagnosis of gastrocolic or gastrojejunal colic fistula may be postulated with certainty. In case folds of mucosa prevent this, subsequent examination at two or five hours may show the abnormal rapidity of passage to the pelvic colon.

If fistula is suspected, an indispensable procedure is the employment of opaque enema after all administered barium has been evacuated. As the barium approaches the mid-point of the transverse colon, its advance should be quite slow. The characteristic patterns of small bowel and gastric mucosa are unmistakable when shown in relief and the contour and size of the gastric lumen are, of course, characteristic. If there is doubt as to the identification of the stomach, the patient's head may be tilted downward, filling the cardiac end. It is seldom that communication between the colon and stomach cannot be demonstrated with ease if this plan is followed.

TREATMENT

The treatment of gastrojejunal colic fistula is probably as difficult as that of any surgical condition of the abdomen. Faced, as a rule, with an emaciated patient in poor general condition, who has had one or more gastric operations previously, the surgeon has many obstacles before him which may prevent his obtaining anything better than a fair result. Certainly no routine operation can be applied efficaciously to all fistulas.

In spite of the fact that there is a certain amount of peritoneal immunity established by fistula formation, peritonitis from contamination is still an ever present danger. Harvey Cushing showed many years ago that the contents of the stomach and duodenum were relatively sterile, and that the number of virulence of the various bacteria increased as one passes down the intestinal tract. We know that if perforated peptic ulcers are closed very soon after their occurrence there is little danger of a

severe peritonitis; this is not true with perforations of the colon. It is reasonable to suppose that hydrochloric acid is an important factor in the prevention of growth of pathogenic organisms, for we know that pathogenic organisms do grow in the stomach in cases of carcinoma, a condition in which anacidity is usually present.

The excision or simple closure of the fistula, undoing of the old gastroenterostomy, and reconstruction of the gastrointestinal tract to its normal state have composed the operation which we have used to the best advantage in the majority of our patients. In the presence of pyloric obstruction, obviously a pyloroplasty or some other form of anastomosis will have to be done. For fistulas with extensive inflammatory reaction and adhesion formation, resection "en bloc" may be mandatory. The importance of carrying out any operation in a manner as aseptic as possible goes without saying.

Findlay has recently utilized the Mikulicz procedure, together with pre-operative peritoneal immunization, in a multiple stage operation for gastrojejunal colic fistula, bringing the loop of transverse colon with the attached jejunal stump outside the abdomen. This method may prove to be a substantial contribution in selected cases.

Schrimger has suggested for trial another operation which avoids the extensive resection of the involved portions of the stomach, jejunum, and colon. The essential feature of the operation is the use of denuded cuffs to close the stoma without encroaching upon its lumen. It consists in dissecting off the mucosa and then suturing the muscular walls together, everting the edges as in arterial suture, and using no serosal suture. The operation is applicable chiefly to advanced cases of gastrojejunal ulcer with or without fistula.

Lahey and Swinton, in 1935, suggested the use of an operation which appears to have promise in the treatment of large gastrojejunal colic fistulas by a two-stage

procedure. The method was used in two cases, but it was unfortunate that both patients died, from causes not directly attributable to the operation. Using a left rectus incision, the stomach was cut off proximal to the gastroenterostomy and anastomosed to the jejunum at a location distal to the fistula, the distal end of the stomach then being closed, thereby shunting the gastric contents away from the ulcer and fistula. It was hoped that this might aid in decreasing the inflammatory reaction around the fistula, but autopsies failed to show any such improvement. (One patient had a cardiac death twenty-six days post-operatively; the other died of intestinal obstruction six months after operation.) In retrospect, they feel that it would be worthwhile to attempt resection of the lower end of the stomach, jejunum, and right colon through a right rectus incision about three weeks after the first stage.

The importance of adequate pre-operative preparation of patients with gastrojejunal colic fistula cannot be over-emphasized. Most of them come for treatment in a very poor general condition. The marked loss of weight is accompanied by great alteration in the body chemistry. Dehydration is present in some degree as a result of diarrhea. Alkalosis or acidosis may occur, depending on the amount of chlorides lost by vomiting or the sodium lost by diarrhea. Hypochloremia is to be suspected, and some degree of ketosis is always present as a result of malnutrition. The proper restoration of fluids, salt, and glucose, along with the administration of available vitamins should be carried out until chemical studies assure us that the patient is restored to as near normal as possible before operation is attempted. If this plan is adhered to, the patient will stand an operation of infinitely greater magnitude than if the operation were performed without it.

In most patients, once the diagnosis of gastrojejunal colic fistula is made, we feel that operation is indicated. In some pa-

tients, because of age, absence of severe symptoms, or because of the coexistence of other serious maladies, conservative treatment may be a wiser choice than operation.

SUMMARY OF CASES

Fourteen cases of gastrojejunal colic fistula have been seen at the University Hospital during the period from October 1927 to February 1937. Thirteen cases were the result of posterior gastroenterostomy done for duodenal ulcer. One was due to erosion by carcinoma of the stomach which involved a large segment of the transverse colon; no attempt at resection was made.

The average age of the patients studied in this series was 46 years. The youngest patient was 31, the oldest 72. The interval between gastroenterostomy and development of definite symptoms of fistula varied from six months to eleven years, with an average interval of about four and one-half years.

Of the group of thirteen cases resulting from ulcer, ten were operated upon, two of whom died, a mortality rate of 20 per cent. One patient died from peritonitis on the fourteenth day following excision of the fistula, closure of the colon, and resection of the lower half of the stomach and a segment of the jejunum at the site of the fistula. The other death resulted from a lung abscess eighteen days following closure of the fistula and Finney pyloroplasty. In the group of eight patients who survived operation, one died of acute lymphatic leucemia four and one-half years after operation, but had had no symptoms of recurrence prior to death. Two patients had gastrocolic fistula, both treated by simple closure. Six of the patients who survived had jejunal colic or gastrojejunal colic fistula. Four of these were treated by closure of the fistula and disestablishment of the gastroenterostomy; in one of these a Finney pyloroplasty was also done; in another a resection of the involved jejunum was done in addition. Of

the remaining two cases, one was treated by excision of the jejunal colic fistula, the gastroenterostomy being left intact; in the other the fistula was excised and a new gastroenterostomy made. Two patients developed symptoms of reactivated duodenal ulcer, one four months and one six years following operation; both had had a closure of the fistula with reconstruction of the gastrointestinal tract to its normal state. Partial gastrectomy may eventually be necessary in these patients. One patient (Case IX), in whom a new anastomosis had been made, developed a new jejunal ulcer $3\frac{1}{2}$ inches distal to the stoma; this was treated by resection of the jejunum, leaving her practically asymptomatic three years later.

One patient, because of his age and absence of distressing symptoms was treated conservatively. He lived approximately four years after symptoms of fistula developed.

Two patients refused operation. One died three weeks after leaving the hospital; the other has not been heard from since.

SUMMARY AND CONCLUSIONS

Thirteen cases of gastrocolic and jejunal colic fistula following gastroenterostomy for duodenal ulcer are presented in detail. One case of gastrocolic fistula due to carcinoma of the stomach is mentioned briefly.

The various theories pertaining to the development of gastrojejunal ulcer and fistula are discussed. Particular stress is laid upon the importance of hyperacidity as an etiologic factor.

A description of the clinical and pathologic pictures of gastrojejunal colic fistula is presented in some detail.

The salient points in the roentgenologic diagnosis are enumerated.

The difficulties encountered in the treatment of fistula are discussed. Our method of treatment has been presented, together with other recognized operative procedures.

The excision or the simple closure of the fistula, undoing of the old gastro-

enterostomy, and reconstruction of the gastrointestinal tract to its normal state constitute the operation which we have used to the best advantage in the majority of our cases.

We wish to emphasize that, in all patients for whom operation is planned, a careful pre-operative régime designed to restore the body chemistry to as near normal as possible is imperative.

It is our feeling that, in most cases, once the diagnosis of fistula is made, operation is indicated. In some patients, because of age, absence of severe symptoms, or other factors, conservative treatment may be a wiser choice.

CASE REPORTS

CASE I. A man, aged 32, was admitted to the hospital October 28, 1927, complaining of vomiting which had been present intermittently for a period of eight months. Fourteen years before entry he developed typical symptoms of peptic ulcer, relieved partially by medical treatment. Gastroenterostomy was done elsewhere in December, 1925. Sixteen months later, he began to have nausea, feculent vomiting, slight abdominal pain, and intermittent diarrhea. He had one hemorrhage, followed by tarry stools for three or four days. He reported a weight loss of sixty pounds.

Examination revealed an emaciated man who was both acutely and chronically ill. Roentgen ray examination demonstrated what was interpreted as a communication between the jejunum and colon.

Operation was done October 29, 1927. A fistula about 4 cm. in diameter was found to exist between the jejunum and transverse colon. It was located just distal to the gastrojejunostomy. The fistula was isolated and excised, and the opening in the colon closed. The gastroenterostomy was separated and no ulcer was found at the line of anastomosis. The pylorus was closed, probably due to scarring from the old duodenal ulcer. The lower half of the stomach was resected. The jejunum was resected about 4 inches from its origin and reconstructed by an end-to-end suture. The jejunum distal to this was then anastomosed to the stomach according to the method of Polya. The patient was in shock at completion of the operation.

He was given two transfusions following operation and rallied remarkably well. He remained in fairly good condition for a week, when he had a sudden turn for worse, began to vomit, became distended, and rapidly lost ground. Respirations ceased on November 8, 1927. At autopsy it was found that the colon had broken open and drained large amounts of fluid fecal material into the abdomen.

CASE II. A man, aged 49, was admitted to the hospital September 23, 1929, complaining of pain in the upper abdomen following meals. Roentgen ray examination at that time showed no persistent deformity in the stomach or duodenum. The gall-bladder did not visualize by the Graham test. After he failed to improve on conservative treatment, the abdomen was explored. Neither a gastric nor duodenal lesion could be demonstrated, even after opening into the stomach. The gall-bladder was found to be chronically inflamed and was removed. He was well for three years, when he developed persistent vomiting. He presumably had pyloric obstruction, which was treated elsewhere by gastroenterostomy in 1932, which relieved his symptoms for about one year. One year prior to entry he developed an alternating constipation and diarrhea, slight bleeding per rectum, weakness, and some upper abdominal pain.

Examination showed nothing other than the scars from previous operations. Roentgen ray examination demonstrated a satisfactorily functioning gastroenterostomy. There was a fistulous communication between the transverse colon and the small bowel in the region of the gastroenterostomy stoma. Operation was advised, but the patient did not wish to go through with this. He was discharged against advice on November 29, 1934.

CASE III. A man, aged 31, was admitted to the hospital August 29, 1930, complaining of diarrhea of three and one-half years duration. Gastroenterostomy had been done elsewhere in 1920 for duodenal ulcer. He was relieved of ulcer symptoms for about seven years, when the diarrhea developed. This became progressively worse and just before admission he was having from ten to twenty watery stools per day, which resulted in a weight loss of 30 pounds. He had some cramping abdominal pain and a history of food particles in the stool within twenty minutes of ingestion. He also had eructations of fetid gas.

Physical examination revealed a poorly nourished man. The sigmoid colon was palpable and slightly tender. There were no masses felt. Hemoglobin was 97 per cent. Roentgen ray examination demonstrated a communication between the stomach, jejunum, and transverse colon. There was a rapid motility of barium through this fistulous tract. The colon was markedly constricted just proximal to the splenic flexure. Subsequently the patient was given charcoal with a meal; this was recovered in the stool one hour later. Gastric analysis revealed presence of free hydrochloric acid in the stomach.

Operation was advised, but the patient preferred to return home for a few days before submitting to surgery. Discharged September 17, 1930. Communication with relatives revealed that death occurred October 4, 1930.

CASE IV. A man, aged 43, was admitted to the hospital May 4, 1931, complaining of abdominal pain which had been present for about five months. He had had sour eructations, a feeling of fullness, and nausea, but no vomiting. Examination showed a mass in the left upper quadrant which was thought to be spleen. Roentgen ray examination of the stomach and duodenum was negative. The patient refused to remain for further studies at the time of his admission in May, but returned in November with the additional symptoms of diarrhea and fecal vomiting. Roentgen ray examination in November demonstrated an intrinsic lesion on the postero-lateral wall of the stomach and a fistulous connection between the stomach and transverse colon.

Operation was carried out November 28, 1931. Exploration revealed a mass involving the posterior wall of the stomach and about 6 inches of the transverse colon up to the splenic flexure. The tail of the pancreas was also involved in the mass. The lesion appeared inoperable and the abdomen was closed without attempt to resect it. The patient left the hospital on December 9, 1931. Communication from his local physician one month following operation stated that the patient was failing rapidly.

CASE V. The patient, a man 33 years of age, was admitted to the hospital October 9, 1931 complaining of watery diarrhea. Six years before this he had developed typical ulcer symptoms, only partially relieved by medical treatment. Gastroenterostomy was done elsewhere in February 1928 for duodenal ulcer, with

complete relief of symptoms for five months, following which the old ulcer symptoms recurred. In May 1931 he began to have diarrhea, which became progressively worse. There had been a weight loss of 35 pounds. Associated symptoms were nausea, foul eructations, slight pain and abdominal distention.

Physical examination revealed a poorly nourished man. There was some tenderness in the left flank anteriorly. Hemoglobin was 70 per cent. Roentgenologic examination demonstrated a fistulous connection between the stomach and colon at the point of the operative stoma.

Operation was done October 30, 1931. A communication about 3.5 cm. in diameter was found between the jejunum and the colon. There was moderate reaction and adhesion formation around the fistula. Clamps were applied and the jejunum freed from the colon. The gastroenterostomy was undone and no jejunal ulcer was found. The jejunum was reconstructed in a transverse direction to enlarge the lumen. The opening in the stomach was closed. The pylorus had a scar suggestive of old duodenal ulcer. The post-operative course was uneventful and he was discharged on the twelfth day following operation.

He was relieved for six years, then neglected his diet and began to have recurrent epigastric pain, nausea and vomiting. Check-up x-rays (December 22, 1937) demonstrated what was interpreted as a reactivated duodenal ulcer. The patient is having a strict medical program of treatment at the University Hospital at this time.

CASE VI. A man, aged 56, was admitted to the hospital March 6, 1933 complaining of diarrhea which had been present for about six months. Vomiting had been present for about three weeks, never feculent in character, but there was a history of bright red blood in the vomitus two weeks prior to entry. Cholecystectomy and gastroenterostomy (presumably for ulcer) were done in 1929. The weight loss was 40 pounds.

Physical examination was not significant except for evidence of weight loss and a large incisional hernia. Hemoglobin 76 per cent. Roentgen ray examination showed no definite evidence of gastrojejunal fistula. There was marked small bowel distention just proximal to the gastroenterostomy stoma.

Operation was done March 14, 1933. A communication was found between the jejunum

and mid-portion of the transverse colon. It was about 2 cm. in diameter and located just distal to the gastroenterostomy. There was little reaction around the fistula. This was isolated and excised and the opening in the colon closed. The jejunum was then repaired by an end-to-end anastomosis.

The post-operative course was uneventful and the patient was discharged on the sixteenth day after operation. He had good health for about three and one-half years when he developed acute lymphatic leucemia. Death occurred November 24, 1937 following an illness of about two weeks.

CASE VII. A man, aged 50, was first admitted to the hospital in 1922, at which time a gastroenterostomy was done for gastric ulcer of several years' duration. He was free from symptoms until May 1933 when he began to have a watery diarrhea consisting of three to ten stools daily. He had also been bothered considerably with bleeding hemorrhoids. He was readmitted to the hospital September 4, 1933 with a history of having lost 40 pounds in weight. Other prominent symptoms were foul eructations, sensations of bloating, and extreme weakness.

Examination revealed an emaciated, middle-aged man in no acute distress. The abdomen was thin-walled and slightly distended. He had a moderate secondary anemia which was attributed to bleeding hemorrhoids. Hemoglobin was 45 per cent; red blood cells 2,940,000 per cu. mm. Roentgen ray examination showed the presence of a fistula between the transverse colon and the gastroenterostomy stoma.

The patient was transfused several times before operation and given measures to improve his general condition.

Operation was done September 16, 1933. There was a rather marked inflammatory reaction around the fistula, which was located between the inferior aspect of the transverse colon and the stoma of the gastroenterostomy. The opening in the colon was 6 cm. in diameter, and after being dissected free was closed in a transverse direction. The gastrojejunostomy was severed and the opening in the stomach closed. The opening in the jejunum was closed transversely. The pylorus was occluded, this being treated by a Finney pyloroplasty.

The patient was in good condition for eighteen days following the operation and seemed to be well on the road to recovery when he had a sudden collapse, characterized by marked

weakness, dyspnea, cyanosis and slight chest pain. He died two hours later. Autopsy showed a large abscess of the lower lobe of the right lung which had ruptured into the pleural cavity. There were multiple ulcers in the stomach and jejunum, and evidence of chronic productive peritonitis in the region of the anastomosis, though the peritoneum was smooth elsewhere. Suture lines were intact.

CASE VIII. A woman, aged 36, was admitted to the hospital March 27, 1934, complaining of loss of weight, indigestion and vomiting of feculent material. In the early part of 1928, she had had several attacks of severe epigastric pain associated with nausea and vomiting. This was diagnosed as duodenal ulcer and treated by an operation, alleged to have been a gastroenterostomy, done elsewhere in September, 1928. Before the patient left the hospital she was reported to have had fecal vomiting. Diarrhea developed shortly thereafter and continued intermittently, along with the vomiting, up to the time of admission. She had passed definite food particles as soon as two hours after ingestion. Weight decreased from 126 to 71 pounds. Nineteen months before admission she developed carpal spasm, attributed to chloride deficiency, and partially relieved by administration of hydrochloric acid.

Examination revealed a markedly emaciated woman. Blood studies showed a macrocytic anemia, color index 1; hemoglobin 77 per cent; red blood count 3,870,000 cells per cu. mm. Roentgen ray studies demonstrated what was thought to be a gastrocolic fistula.

Operation was done April 5, 1934. An anastomosis was found between the stomach close to the greater curvature and the transverse colon at the junction of its middle and distal thirds. It was obvious that this anastomosis had been erroneously made at a previous operation. Its longest diameter was 5.5 cm. The communication was isolated, clamped, cut with cautery, and the openings in the stomach and transverse colon closed aseptically. The entire length of the jejunum was found to be normal.

Following the operation, the patient developed an acute toxic psychosis which cleared up in about one week. Otherwise her condition was good and she was discharged on the fourteenth post-operative day with instructions to follow a restricted ulcer diet and to receive treatment at home for the anemia.

Three and one-half years after operation the patient was in excellent health. She had doubled her former weight of 71 pounds. The anemia and peripheral neuritis had entirely disappeared.

CASE IX. A woman, aged 55, was admitted to the hospital April 4, 1934. She had had several operations directed toward relief of abdominal pain, all done elsewhere. Cholecystostomy was done in 1926 with partial relief. In 1933 a cholecystectomy and gastroenterostomy were done. The gastroenterostomy did not function well and a second operation, consisting of partial gastrectomy, was carried out while the patient was still in the hospital. Six months following the last operation she began to have abdominal pain, nausea, vomiting, and attacks of watery diarrhea.

Examination revealed an undernourished adult female who was chronically ill. Abdomen was slightly distended. There were four surgical scars in the upper abdomen. No masses or tenderness. Roentgen ray examination showed a definite communication between the efferent loop of jejunum and the transverse colon.

Operation was performed April 10, 1934. Marked adhesion formation made the separation of jejunal coils difficult. The jejunal colic fistula was located about 3 inches distal to the margin of the stomach; it was about 2 cm. in diameter. The opening in the colon was now closed. The stomach was isolated and a new anastomosis made at the aboral angle of the stomach, between it and the jejunum. There was still a sharply angulated loop of jejunum, and in order to obtain better drainage a lateral anastomosis was made between this loop and an adjacent loop of ileum. The post-operative course was surprisingly good, but she was relieved of her symptoms for only six weeks.

The patient returned July 19, 1934 complaining of pain, nausea and vomiting. Roentgen ray examination demonstrated a penetrating jejunal ulcer about 3 inches distal to the gastric stoma. Operation was done the following day and an ulcer 2½ inches in diameter found in the greater curvature of the stomach at the site of its union with the jejunum. The floor of the ulcer was the colon. The upper 8 inches of the jejunum were now resected and an anastomosis made between the superior end of the jejunum and the stomach. Except for a wound infection, the post-operative course was quite good. She was discharged the nineteenth day after operation. Communication with the patient three

years later revealed that she was getting along nicely, having no symptoms except occasional nausea.

CASE X. A man, aged 62, was admitted to the hospital, May 15, 1934, complaining of persistent vomiting and diarrhea. Gastroenterostomy had been performed elsewhere four years ago for ulcer. Symptoms were relieved until about six weeks prior to admission, when a severe watery diarrhea developed rather suddenly and became progressively worse. Vomiting had been present for two weeks and was of feculent nature just before entry. A weight loss of 41 pounds was reported.

Examination revealed an elderly man in poor general condition and quite emaciated. There were no significant abdominal findings. Hemoglobin was 83 per cent; white blood count 21,600. Roentgen ray examination of the upper gastrointestinal tract showed a normally functioning gastroenterostomy with no evidence of marginal ulcer. Barium enema revealed a fistulous opening between the small bowel and the proximal transverse colon.

Operation was done May 25, 1934 following several days hydration and general supportive treatment. On opening the abdomen, extensive adhesions were encountered and severed. A fistula was found between the mid-point of the transverse colon and the jejunum at a point about 18 cm. distal to the gastroenterostomy stoma. The opening was 3 cm. in diameter and there was little reaction around it. The fistulous tract was isolated, clamped and excised. The openings in the jejunum and transverse colon were closed transversely.

The patient had a fairly stormy post-operative course which was complicated by a mental upset and a wound infection, both of which cleared up. He was discharged home on the thirty-third day following operation. A letter from the patient's home physician on December 22, 1937 revealed that he had been practically asymptomatic ever since operation, but had had vague epigastric pain for the last four weeks. He had been on a #4 Mills diet ever since operation.

CASE XI. The patient, a man, aged 36, came to the hospital November 11, 1935, complaining of diarrhea and vomiting. Thirteen years before admission he had had a perforated peptic ulcer closed elsewhere, at which time a gastroenterostomy was also done. A year later, he developed a jejunal ulcer, proved by x-ray. This was treated fairly satisfactorily for four

years by dietary methods. For three years prior to admission he had had intermittent watery diarrhea which became progressively worse. Vomiting had occurred irregularly for three months and had recently been of feculent character. The weight loss was 32 pounds.

Physical examination revealed nothing significant except emaciation. Hemoglobin was 86 per cent. Roentgen ray examination showed a freely functioning gastroenterostomy and a fistulous connection between the jejunum and transverse colon to the left of the midline.

Operation was performed November 11, 1935. There was a definite fistula between the jejunum and the transverse colon, located about 3 cm. distal to the gastroenterostomy. The fistula was about 3 cm. in diameter. This was isolated, clamped, cut and the opening in the colon closed. The gastroenterostomy was disconnected, but no evidence of jejunal ulcer could be found. The opening in the stomach was closed. The jejunal openings were both closed transversely and omentum drawn over them. Post-operative course was without event and the patient was discharged on the thirteenth day following operation.

The follow-up on December 13, 1937 revealed that he had been asymptomatic ever since operation. He had had a gain in weight of 65 pounds and was working daily in a machine shop.

CASE XII. A man, aged 72, was admitted to the hospital November 4, 1935 complaining of abdominal pain, slight weight loss and alternating constipation and diarrhea. The diarrhea was not severe. Operation for peptic ulcer had been done some years previously, exact date unknown. He had been relieved until two years before entry, when the above symptoms developed.

Examination revealed an elderly man in an undernourished condition. There was an upper midline scar and a questionable mass in the left lower quadrant. Roentgen ray examination demonstrated a gastrojejunocolic fistula at about the mid-portion of the transverse colon.

Because of the patient's age, it was decided to treat him conservatively. He was discharged on a high caloric diet, avoiding food which gave him particular distress. Death occurred at his home about nineteen months later, following a downhill course.

CASE XIII. A man, aged 40, was admitted to the hospital January 5, 1937, complaining of watery diarrhea of two years' duration. Fifteen

years before entry, he had developed typical symptoms of peptic ulcer, and seven years later, following a period of persistent vomiting, gastroenterostomy was performed elsewhere for pyloric obstruction. He was relieved for about six years, when the diarrhea developed. He lost about 30 pounds in weight but gained considerably during a period of three months prior to entry.

Examination revealed a fairly well nourished adult male. Abdominal findings were not contributory. Roentgen ray examination demonstrated a definite communication between the stomach and transverse colon at the gastroenterostomy stoma. The duodenal bulb was deformed by scar.

Operation was done January 11, 1937. There was scarring from the old duodenal ulcer. The stomach was freed from its connection with the jejunum and the site of anastomosis was then cut away. The opening in the jejunum was then closed transversely.

The patient's course following operation was without significant event and he was discharged on the eighteenth post-operative day. He returned four months later with symptoms of reactivated duodenal ulcer. He was relieved temporarily after two weeks treatment with a Sippy diet. Since then he has had intermittent ulcer symptoms.

CASE XIV. A man, aged 52, was admitted to the hospital January 25, 1937, complaining of diarrhea. He had had a known duodenal ulcer for fifteen years, which was treated elsewhere by gastroenterostomy eleven years prior to admission, with relief for eighteen months. Two years following operation he developed a persistent diarrhea, the cause of which was subsequently found to be a gastrojejunocolic fistula. This was also operated elsewhere with complete relief of symptoms for nine years, when the diarrhea again appeared.

Physical examination at the time of admission was not significant. The patient was slender, well developed and in fair general condition.

Roentgenologic examination revealed a slowly functioning gastroenterostomy. A definite fistulous connection was demonstrated between the small bowel at the site of anastomosis and the transverse colon, distal portion.

Operation was done January 27, 1937. The transverse colon was found to be closely adherent to the jejunum immediately beneath

the gastroenterostomy stoma, which was patent. A fistula about 1 cm. in diameter connected the jejunum and colon. There was still slight scarring from the old duodenal ulcer. The gastroenterostomy was disconnected and the jejunum separated from the colon, the latter being closed transversely. The openings in the stomach and jejunum were then closed and a Finney pyloroplasty done.

Post-operative distention was treated with continuous gastric suction for three days. The development of a wound infection delayed recovery. However, he was discharged on the twenty-sixth post-operative day in good condition.

The patient returned to the hospital on April 7, 1937 because of severe cardiospasm which was relieved without event by esophagoscopy.

REFERENCES

- ALLEN, A. W. An aseptic technic applicable to gastrojejunal colic fistula. *Surgery*, 1: 338-348 (March) 1937.
- ARONS, H. Zur Frühdiagnose der Fistula Gastrocolica. *Berlin. klin. Wchnschr.*, 58: 661-662 (June 20) 1921.
- BENEDICT, E. B. Jejunal ulcer. *Surg., Gynec. & Obst.*, 56: 807-819, 1933.
- BOLTON, C., and TROTTER, W. Jejunal colic fistula following gastrojejunostomy. *Brit. M. J.*, 1: 757-762, 1920.
- BRADBURY, L. A. Gastrojejunal colic fistula, with case report. *U. S. Veterans' Bureau Med. Bull.*, 3: 1120 (Nov.) 1927.
- BRAMS, W. A., and MEYER, K. A. Diagnosis and treatment of gastrojejunal colic fistula. *Surg., Gynec. & Obst.*, 38: 646-649, 1924.
- BRAUN, H. Demonstration eines Präparates einer 11 Monate nach der Ausführung der Gastroenterostomie entstandener Perforation des Jejunum. *Verhandl. d. deutsch. Gesellsch. f. Chir.*, 37: 765-769, 1903.
- BROCK, R. C. Four cases of gastrocolic fistula. *Guy's Hosp. Rep.*, 78: 178-190, 1928.
- CABOT, R. C. A case of gastrocolic fistula. *Boston M. & S. J.*, 197: 743-748, 1927.
- CIVALDI, A. Contributo alla diagnosi delle fistole gastro-coliche. *Policlinico*, 27: 301-310 (Oct.) 1920.
- CUSHING, H., in HOWELL, W. H. Textbook of Physiology, ed. 11, Philadelphia, 1930. W. B. Saunders Co.
- CZERNY, V. Zur Behandlung der Fissur und des Vorfalls des Mastdarms. *Beitr. z. klin. Chir.*, 37: 765-769, 1903.
- DICKSON, W. H. Gastrocolic fistula. *Canad. M. A. J.*, 18: 272-276, 1928.
- ESTES, W. L., JR. Advanced gastrojejunal ulcer. *Ann. Surg.*, 96: 250-257, 1932.
- FINDLAY, F. M. Treatment of gastrojejunal colic fistula by multiple stage operations. *Arch. Surg.*, 32: 896-906 (May) 1936.
- FINSTERER, H., and PATERSON, H. J. Place of gastrojejunostomy in gastric and duodenal surgery. *Brit. M. J.*, 2: 555, 1926.
- FIRTH, D. A case of gastrocolic fistula. *Lancet*, 1: 1061 (May 15) 1920.
- FLINT, J. M. The healing of gastrointestinal anastomosis. *Ann. Surg.*, 65: 202-221, 1917.
- GLICKMAN, L. G. Gastrojejunal colic fistula. *Radiology*, 23: 609, 1934.
- GOLOB, M. Gastrocolic fistula. *Am. J. Surg.*, 8: 1007-1009, 1930.
- HODGES, F. J. Personal communication.
- HORSLEY, J. S., in LEWIS, D. Practice of Surgery, Hagerstown, Md., 1929. W. F. Prior Co., vol. 6, Chapters 3 and 12.
- HURST, A. F., and STEWART, M. J. Jejunal and gastrojejunal ulcers. *Lancet*, 2: 742-749; 805-809, 1928.
- LAHEY, F. H. Experiences with post-operative jejunal ulcer and gastrojejunal colic fistula. *Am. J. Diges. Dis. & Nutrition*, 2: 673 (Jan.) 1936.
- LAHEY, F. H., and JORDAN, S. M. Gastrojejunal ulcers and gastrojejunal colic fistulae. *Ann. Surg.*, 87: 231, 1928.
- LAHEY, F. H., and SWINTON, N. W. Gastrojejunal ulcer and gastrojejunal colic fistula. *Surg., Gynec. & Obst.*, 61: 599-612, 1935.
- LOEWY, G. Fistules jéjunocoliques par ulcère perforant après gastroenterostomie. Paris, 1921. Desfosses.
- MACDONALD, IAN. Gastrojejunal colic fistula. *Lancet*, 2: 804-806, 1927.
- MANN, F. D., and WILLIAMSON, C. S. The experimental production of peptic ulcer. *Ann. Surg.*, 77: 409, 1923.
- MAYO, C. H., and RANKIN, F. W. Gastrojejunal colic fistulas following gastro-enterostomy. *Tr. South. Surg. & Gynec. A.*, 34: 421-433, 1921.
- MONROE, R. T., and EMERY, E. S., JR. Gastrocolic fistula as a result of peptic ulcer. *New England J. Med.*, 198: 550-553, 1928.
- OWINGS, J. C., and SMITH, I. H. Experimental production and cure of jejunal ulcers. *Proc. Soc. Exper. Biol. & Med.*, 29: 832-833, 1932.
- PATERSON, H. J. Jejunal and gastrojejunal ulcer: its etiology and prevention. *Internat. J. Surg.*, 33: 138 (May) 1920.
- POYNTON, F. J., and MACGREGOR, J. V. Gastrojejunal colic fistula with oedema. *Lancet*, 2: 240-241, 1930.
- PRATT, G. P. Gastrojejunal colic fistula. *Med. Clin. North America*, 12: 307-317, 1928.
- PRIESTLEY, J. T. Obstructing and recurring inflammatory lesions of the stomach and duodenum. *Proc. Staff. Meet., Mayo Clin.*, 8: 33-36 (Jan. 18) 1933.
- RICHARDSON, E. P. Jejunal ulcer without previous gastro-enterostomy. *Surg., Gynec. & Obst.*, 35: 1, 1922.
- SCHRIMGER, F. A. C. A technic for the management of gastrojejunal ulcers with or without gastrocolic or jejunal colic fistula. *Ann. Surg.*, 104: 594-600, 1936.
- STENHOUSE, H. M. Gastrojejunal colic fistula. *J. A. M. A.*, 82: 1924, 1926.

40. SHANGLE, M. A., and BEISLER, L. G. Gastrojejunal colic fistula. *Surg. Clin. North America*, 6: 1647-1652, 1926.
41. SHORE, B. R. Gastrojejunal colic fistula. *Ann. Surg.*, 87: 578-580, 1928.
42. STRAUSS, A. A., BLACK, L., and FRIEDMAN, J. G. Gastrojejunal ulcer. *J. A. M. A.*, 90: 181-186, 1928.
43. STRAUSS, H. Fettstuhle als Symptom der Fistula Gastrocolica. *Berlin. klin. Wchnschr.*, 58: 661-662 (June 20) 1921.
44. TOLAND, C. G., and THOMPSON, H. L. Acute perforation of gastrojejunal ulcer. *Ann. Surg.*, 401-409, 1934.
45. VERBRUGGE, J. Gastrojejunal colic fistulas. *Arch. Surg.*, 2: 790-808, 1925.
46. WALTON, A. J. Gastrojejunal ulceration. *Brit. J. Surg.*, 22: 33-55, 1934.
47. WIESE, H. W. Gastrojejunal colic fistula. *Radiology*, 16: 477, 1931.
48. WILKIE, D. P. D. Jejunal ulcer. *Ann. Surg.*, 99: 401-409, 1934.



RUPTURE of the diaphragm is uncommon. It may be produced by a sudden increase in abdominal pressure as the result of crushes or muscular efforts in vomiting or parturition. It is usually on the left side, and cases have occurred where the rupture has been produced by an esophageal bougie.

From—"The Science and Practice of Surgery" by W. H. C. Romaines and Philip H. Mitchiner, 6th Ed. (Churchill).