

TABLE IV—NEPHEWS AND NIECES OF SURVIVING PATIENTS WITH SPINA BIFIDA CYSTICA, SHOWING THOSE AFFECTED

| Index patients | Brothers | | Sisters | | Total |
|----------------|----------|-----------|---------|-----------|----------|
| | Sons | Daughters | Sons | Daughters | |
| Male 100 .. | 42 | 38 | 49 (1S) | 58 | 187 (1S) |
| Female 115 | 53 | 47 | 43 | 36 | 179 |
| Total 215 .. | 95 | 85 | 92 (1S) | 94 | 366 (1S) |

S = spina bifida.

Nephews and Nieces

Altogether, of 366 nephews and nieces, one boy born to the sister of a male patient had spina bifida (table iv). In addition, there were 3 stillborn children. Hospital reports were available for 2 of these and there was no mention of neural-tube malformations.

Discussion

The finding of 2 children affected in 104, if added to Tünte's comparable series, makes 4 in 133 (3%) affected. Lorber's finding, in a more variously ascertained group, of 3 in 86 children affected, is comparable. The proportion of children affected is less than, though not significantly less than, the proportion of sibs affected in the large London series⁴ of recently born index patients with neural-tube malformations. In the latter study the proportions were 4.5% for sibs of all index patients and 3.4% for the sibs of index patients with spina bifida. In the South Wales series⁵ the proportions were 5.2 and 6.1%, respectively. The proportion of sibs of index patients affected in the present series (2.7%) is a less reliable result since they were born a generation ago and the information available, especially on the causes of stillbirths, at that time is incomplete.

These early findings on the offspring of patients do not help to distinguish between a polygenic or a modified monogenic genetic contribution to the aetiology of neural-tube malformations. However, since the proportion of children affected is of the same order as the proportion of sibs affected, it is unlikely that a persistent influence of the intrauterine milieu provided by the mother is important in the aetiology. Further, there is now an indication that male patients are as likely to have affected children as female patients, and this makes the hypothesis of cytoplasmic inheritance put forward by Nance⁶ seem implausible. In the present series the proportion was 1 in 35 of children of male patients and 1 in 69 of children of female patients. In Tünte's series¹ the numbers of children born to male and female index patients were not stated, but 1 of 7 fathers and none of 7 mothers had affected children. In Lorber's series,² 1 of 15 children born to male patients and 2 of 71 children born to female patients were affected. These results indicate that the risk to children of male patients is at least as high as the risk to children of female patients. This is an interesting result, since the women who had children were more severely affected than the men (see above). With polygenic inheritance it might be expected that the more severely affected would be more liable to have affected offspring.

The best estimate for risk to offspring of patients with spina bifida cystica is perhaps the 3% for parents of either sex given by the present series and that of Tünte combined. This is, however, entirely compatible with the estimate of 3.5% from Lorber's more variously ascertained series.

We thank the physicians and surgeons of The Hospital for Sick Children for access to their former patients; Mr Ellison Nash for an introduction to the patients who constitute the subsidiary series; and Mrs Veronica Hickman, who shared the family visiting with Mrs Evans. Tracing the patients was made possible by Mr D. Smale and his staff of the N.H.S. Central Register at Southport and the family doctors of the index patients.

Requests for reprints should be addressed to C. O. C.

REFERENCES

1. Tünte, W. *Humangenetik*, 1971, **13**, 43.
2. Lorber, J. Link (A.S.B.A.H.), 1971, **20**, 10.
3. Evans, K., Hickman, V. Unpublished.
4. Carter, C. O., Evans, K. *J. med. Genet.* 1973 **10**, 209.
5. Carter, C. O., David, P. A., Laurence, K. M. *ibid.* 1968, **5**, 81.
6. Nance, W. in *The Clinical Delineation of Birth Defects*. Part vi, vol. VII, no. 1, p. 97. Baltimore, 1971.

POSSIBLE ASSOCIATION BETWEEN BENIGN HEPATOMAS AND ORAL CONTRACEPTIVES

JANET K. BAUM FRED HOLTZ
JOSEPH J. BOOKSTEIN EDWARD W. KLEIN

Departments of Radiology, University of Michigan Hospital, St. Joseph Mercy Hospital, and Wayne County General Hospital, and Department of Pathology, St. Joseph Mercy Hospital, Ann Arbor, Michigan, U.S.A.

Summary Seven cases of hepatic adenoma are presented, all in women on oral contraceptives. It seems likely that oral contraceptives play a role in the development of this lesion. Although benign, the tumour may cause serious or fatal hæmorrhage. Hepatic arteriography allows prompt and precise diagnosis.

Introduction

PRIMARY benign hepatoma of the liver is rare. Within the past 5 years, however, seven histologically proven cases have been seen in this area—all in young women on oral contraceptives.

Case-reports

Case 1

A 26-year-old woman was well until she suddenly experienced severe midepigastic pain. She had been on norethynodrel and mestranol ('Enovid') for 2 years. Because of signs of an acute abdomen with impending shock, a coeliotomy was performed immediately after admission to the hospital. Massive intraperitoneal bleeding was found arising from a tumour of the left lobe of the liver. A left hepatectomy and cholecystectomy were performed.

1 year later she required surgery for intestinal obstruction due to adhesions. No evidence of recurrence of the tumour was found at that time, and she has continued to do well in the ensuing 4 years.

The surgical specimen contained a circumscribed yellow-tan tumour 45 mm. in diameter. The neoplasm

extended close to the capsule, where there was a site of rupture and hæmorrhage.

Case 2

A 27-year-old woman was well until 7 hours before admission, when she awoke with severe abdominal pain radiating to the right shoulder. She had been on dimethisterone and ethinylœstradiol ('Oracon') for an unknown time. Physical findings were those of an acute abdomen. White-blood-cell count 22,000 per c.mm., and serum-amylase and urinalysis normal.

Emergency intravenous cholangiography and abdominal series revealed moderate hepatomegaly. An upper-gastrointestinal examination done 6 hours after admission revealed progressive hepatomegaly and elevation of the right hemidiaphragm with medial displacement of the opacified gallbladder. The diagnosis was acute hæmorrhage into a tumour, cyst, or abscess of the liver. While in the radiology department she became hypotensive. Peritoneal tap 8 hours after admission produced unclotted blood.

At laparotomy she was found to have a massive intra-peritoneal hæmorrhage arising from a large tumour of the right lobe of the liver. A right hepatectomy was performed, the operation was complicated by massive bleeding and hypotension. Hæmostasis was a continuous problem postoperatively. Blood-pressure and hæmatocrit could not be maintained and cardiac arrest occurred 20 hours after admission.

The surgical specimen consisted of multiple large fragments of the right lobe of the liver. There was a solitary 12 cm. tumour which extended close to the surface and produced a subcapsular hæmatoma before rupture into the peritoneal cavity.

Case 3

This 25-year-old former beauty queen was well until 1 month before admission, when she noted a progressive increase in weight and a right-upper-quadrant mass. Incidental hospital admission 2 years earlier had dis-

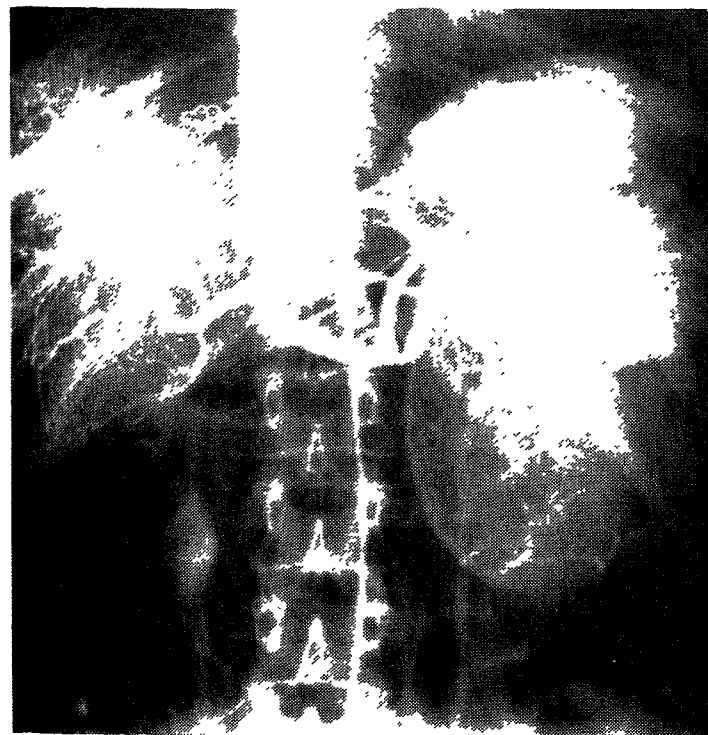


Fig. 1—Case 3: coeliac arteriography demonstrates a large, rounded hypervascular mass supplied by the left hepatic artery arising from the left gastric artery.

The mass has large, peripheral vessels without venous shunting, venous laking, or frankly bizarre tumour vessels, which would have indicated malignancy.

closed no findings of hepatic mass. She had been on oral contraceptives for 6 years.

Multiple liver-function tests were normal. A survey film of the abdomen revealed a mass in the left upper quadrant. An upper-gastrointestinal series revealed some displacement of the hepatic flexure and the duodenum, and an intravenous pyelogram showed some rotation of the right kidney. The gold-198 colloid liver scan showed equivocally decreased uptake in the left lobe of the liver. Abdominal angiography demonstrated a well-demarcated hepatic tumour in the left upper quadrant (fig. 1).

At laparotomy a pedunculated mobile tumour was found arising from the left lobe of the liver. This explained its intermittent radiographic appearance on the right. The tumour with its pedicle was removed and the patient made an uneventful recovery.

The surgical specimen consisted of a 500 g. encapsulated mass measuring 12 × 6 cm. on a 9 cm. pedicle.

Case 4

This 25-year-old woman noted progressive weakness, fatigue, and pallor beginning 2 months before admission. On the day of admission she experienced the abrupt onset of a sharp, stabbing right-upper-quadrant pain that radiated across the epigastrium and lower chest. At the time of admission she was diaphoretic and dyspnoeic and had a blood-pressure of 70/50 mm. Hg. Her only medication was norgestrel and ethinylœstradiol ('Ovral'), which she had been taking for 6 months.

Hb was 8.6 g. per 100 ml. Further laboratory studies demonstrated mildly abnormal serum-glutamic-oxaloacetic-transaminase and lactic dehydrogenase values, normal bilirubin, amylase, and blood-urea-nitrogen. Chest, abdomen, upper-gastrointestinal, and gallbladder X-rays were normal. After 5 days an arteriogram was performed which demonstrated a tumour of the right lobe of the liver.

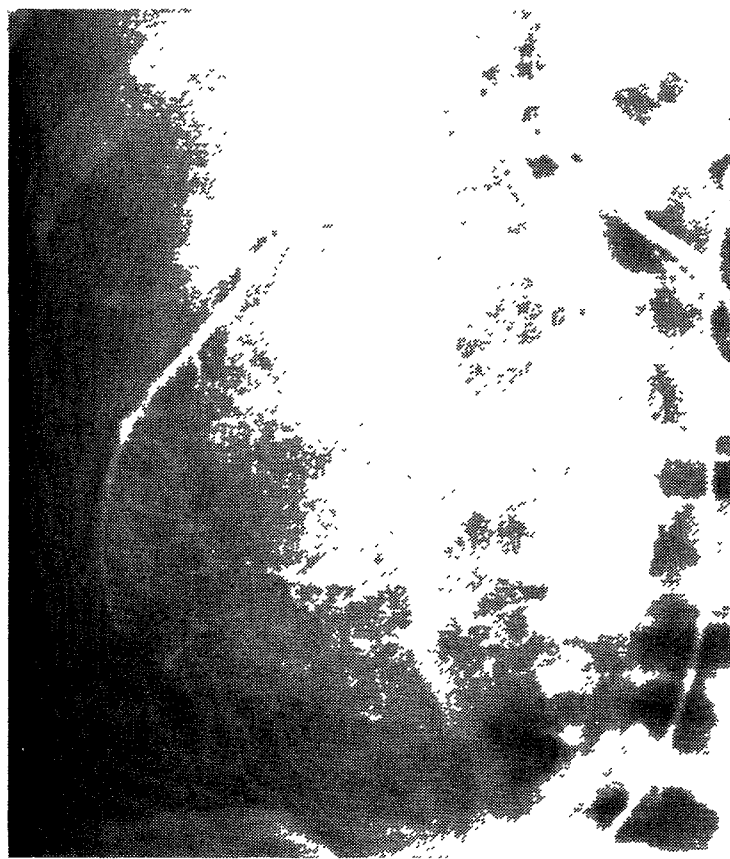


Fig. 2—Case 5: hepatic arteriogram shows a hypervascular, well-circumscribed mass with the blood-supply arising from the periphery and relatively parallel centrally penetrating branches.

7 days after onset of pain a right hepatectomy was performed. She did well postoperatively and was doing well on a 2-month follow-up examination.

Case 5

Upon discovering a right-upper-quadrant mass herself, this 29-year-old female went to see her local physician. After admission to her local hospital, intravenous pyelogram and cholecystogram, barium enema, and upper-gastrointestinal-tract examinations were normal except for a mass in the region of the right lobe of the liver. Liver-function tests were normal. Past medical history was non-contributory except for the administration of norethynodrel and mestranol for the past 5 years.

At surgery a 12 cm. mass was seen arising from the right lobe of the liver. Dilated blood-vessels were noted over the surface of the lesion. A specimen was taken and the abdomen was closed without attempting to remove the tumour.

The patient was transferred to University of Michigan Hospital, and an arteriogram was done (fig. 2). A 13×17 cm. hypervascular mass arose from the quadrate lobe of the liver.

2 weeks after the mass had been noted the lesion was completely removed along with a rim of normal liver tissue. Recovery was uneventful, and follow-up after 3½ years revealed no recurrence.

Case 6

After the onset of sharp epigastric pain radiating into the back and a dull right lower-quadrant ache, this 30-year-old White female became weak and fainted. Upon arrival at the emergency room, her blood-pressure was 60/30 mm. Hg, with a pulse of 80 to 100. No external signs of blood-loss were found despite the presence of a hæmatocrit of 25%. An abdominal tap was 5+ positive.

The patient had been on phenobarbitone and diuretics for 1½ years after the onset of hypertension during her third pregnancy. She had also taken several types of birth-control pill for a total of 7 years between pregnancies. Since the birth of her last child 1 year before admission she had been on one of the low-dose contraceptive agents on a 21-day cycle.

The patient was immediately taken to the operating-room, where a large mass in the right lobe of the liver was noted adjacent to the hepatic capsule in one area. At this site the capsule was ruptured. A right hepatectomy was performed. The patient lost an estimated 18,000 ml. of blood at the time of surgery. Postoperatively the patient had some difficulties with infection, coagulation defects, and jaundice. However, she subsequently recovered and on a 15-month follow-up examination was found to be doing well.

The surgical specimen consisted of the right lobe of the liver containing a white to yellow focally hæmorrhagic mass measuring 18×17 cm. in cross-section.

Case 7

This 39-year-old female was in good health until the day of admission, when she developed right-upper-quadrant pain followed by nausea and vomiting. Her only history of previous medications was the ingestion of enovid for approximately 7 years. Upon admission to her local hospital, she was felt to have appendicitis and was therefore taken to the operating-room, where a mass in the right lobe of the liver, which was the site of a massive intraperitoneal hæmorrhage, was found. The site was packed and the patient was transferred by ambulance to the university hospital, where an emergency 60% hepatectomy was performed with an estimated blood loss of over 24,000 ml. Postoperatively, coagulation difficulties, renal and hepatic failure, and electrolyte imbalance developed. A postoperative angiogram showed a normal

left lobe of the liver without other evidence of tumour. At 2 months, the patient continues to have difficulty with hepatic insufficiency.

The surgical specimen was a hæmorrhagic, partly necrotic, yellow-tan neoplasm approximately 10 cm. in diameter. The rounded margins of the tumour were fairly well demarcated from the normal surrounding liver.

Microscopic Appearance

The microscopic appearances of these cases are all similar to the description of Edmondson in the A.F.I.P. fascicle.¹ All were composed of uniform normal to very slightly atypical hepatic cells arranged in cords and sometimes forming pseudoacini about secreted and retained bile. There were no portal tracts or central veins to suggest the usual lobular architecture. All were relatively vascular. Rare poorly formed bile ducts were present. The pedunculated tumour was completely encapsulated; the remaining tumours were discretely separable from adjacent liver, but encapsulation was incomplete. Each of these tumours were solitary and adjacent to the hepatic capsule in one area.

Discussion

Primary benign liver tumours are rare. Warvi² reported that by 1944 only sixty-seven cases of microscopically proven benign hepatoma had been recorded, most of which demonstrated multiple nodules and might have actually represented hepatic regeneration in cirrhotic livers. Probably most of the so-called benign hepatomas in cirrhotics are really areas of regenerative nodular hyperplasia.³⁻⁵ Henson et al.⁶ reviewed all the benign liver tumours seen at the Mayo Clinic between 1907 and 1954 and found only four benign hepatomas as well as nine benign cholangioadenomas, thirty-five hæangiomas, and seventy-six non-parasitic cysts. Older reports suggest that true benign hepatomas in non-cirrhotic livers are very rare and scarcely warrant mention.^{1,4,5,7,8}

Our own experience also indicates that these are very rare tumours. A review of all the primary liver tumours seen at St. Joseph Mercy Hospital in Ann Arbor, Michigan, since 1913 revealed eight cases classified as benign hepatomas. Re-examination of the histological sections resulted in the reclassification of four as regenerative nodular hyperplasia in cirrhotic livers and one as an early hepatocellular carcinoma arising in a cirrhotic liver. Only the three included in the present report were classified as benign hepatomas not associated with cirrhosis. The remaining four cases of this series were seen at the University and Wayne County General Hospitals, where the total experience has not been reviewed.

Patients with benign hepatomas have presented variable clinical features which may make preoperative diagnosis difficult. Two of our cases presented because of right-upper-quadrant masses, while five had signs and symptoms of acute intraperitoneal hæmorrhage. Routine radiological and laboratory studies may not be helpful. Liver scans may clearly show a focal defect. However, the characteristics on scans are such that benign and malignant hepatomas cannot be distinguished.

Hepatic arteriography is a very useful procedure in diagnosing primary liver neoplasm.⁹⁻¹⁴ The spectrum of angiographic findings in malignant hepatomas as described by Reuter et al.¹² includes dilated

hepatic arteries with irregular tumour vessels, increased accumulation of contrast with vascular lakes, and arteriovenous shunting. Hypovascular tumours may show only arterial displacement or encasement. Unicentric and multicentric lesions are described.

Goldstein et al.¹⁴ describe the angiographic findings of benign hepatomas as distinct from focal nodular hyperplasia and the angiographic differentiation between benign and malignant liver tumours. Benign lesions show a clearly defined margin and a peripheral arterial supply with approximately parallel centrally penetrating arteries. Vascular laking, arteriovenous shunting, and portal-vein invasion were seen only with the malignant hepatomas. Thus hepatic arteriography is not only useful in diagnosis but also in preoperative differentiation between benign and malignant hepatomas.

Possible aetiological factors of benign hepatomas are discussed only briefly in the literature. Warvi² states that they are usually found in children, and Franklin and Downing³ believe that they may be congenital tumours arising from hepatic rests. They also mentioned, among other possible aetiological factors, hormonal effects. Bockus¹⁵ mentions that cirrhosis is commonly associated with benign hepatomas, especially when they are multiple. His cases of multiple hepatomas in cirrhotic livers may represent examples of regenerative nodular hyperplasia.

After reviewing our patients' clinical histories and histological material, there is no evidence of cirrhosis, hepatitis, or congenital aetiology. The common history, however, of oral-contraceptive ingestion for from 6 months to 5 years suggests that oral contraceptives may play an aetiological role. Also suggesting an aetiological relationship is the parallel between the increased frequency of benign hepatic adenoma and the widespread utilisation of oral contraceptives. The carcinogenic potential of oestrogenic agents in other organs such as the vagina or breast is already widely recognised.^{16,17} An association of hepatocellular carcinomas with androgenic-anabolic steroids¹⁸ further supports this hypothesis and leads to an interesting question: do androgenic steroids stimulate the production of hepatic carcinomas while oestrogenic steroids stimulate production of hepatic adenomas? An extensive review of the interaction between liver and female sex hormones, especially oral contraceptives,¹⁹ makes no mention of the development of benign hepatoma. Only ultrastructural changes in the bile canaliculi, endoplasmic reticulum, and mitochondria were described.

Further study is necessary to elucidate the suggestive relationship between androgenic and oestrogenic steroids and the development of benign and malignant hepatomas.

Requests for reprints should be addressed to J. K. B., Department of Radiology, Wayne County General Hospital, Eloise, Michigan 48132, U.S.A.

REFERENCES

1. Edmondson, H. A. Atlas of Tumor Pathology: section 7, fascicle 25, p. 18. Armed Forces Institute of Pathology, Washington, D.C., 1958.
2. Warvi, N. *Archs Path.* 1944, **37**, 367.

References continued at foot of next column

SUSTAINED LEVODOPA THERAPY IN PARKINSONISM

K. R. HUNTER

D. R. LAURENCE

K. M. SHAW

G. M. STERN

Department of Neurology, University College Hospital, London, and Department of Clinical Pharmacology, Medical Unit, University College Hospital Medical School, London

Summary Levodopa was used to treat a hundred and eighty-seven patients with parkinsonism. While most benefited after 3 months' treatment, after 36 months only 40% had maintained their initial improvement. After a static period of about 2 years, parkinsonian disabilities continued to increase despite retention of partial responsiveness to levodopa.

Introduction

NUMEROUS clinical reports have described the immediate effects of levodopa therapy in parkinsonism and conclusions have been fairly uniform; some two-thirds of patients gain worthwhile benefit varying from modest to spectacular. There have been fewer published reports of the effects of more prolonged administration of levodopa, but these give the impression of sustained response and even possible arrest of the disease.^{1,2} These reports do not accord with our experience, and we describe results in patients who have taken levodopa for up to 3½ years.

Patients and Methods

Since November, 1969, a hundred and eighty-seven parkinsonian patients attending the Department of Neurology of University College Hospital have been treated with levodopa. This study excluded those patients with severe postencephalitic parkinsonism^{3,4} and those believed to be unsuitable for treatment—e.g., those with unstable personalities, pronounced confusion, frank dementia (20), severe ischaemic heart-disease (7), drug-induced parkinsonism (5), recent strokes (2), and with Shy-Drager syndrome (2). Of those treated, there were a hundred and four men and eighty-three women; the average age of onset of symptoms for men was 54.7 (± 12.6) and for women 57.0 (± 11.03)

DR BAUM AND OTHERS: REFERENCES—continued

3. Franklin, R. G., Downing, C. F. *Am. J. Surg.* 1947, **73**, 390.
4. Popper, H. P., Schaffner, F. *Liver: Structure and Function*: p. 592. New York, 1957.
5. Berkheiser, S. W. *Gastroenterology*, 1959, **37**, 760.
6. Henson, S. W., Jr., Gray, H. K., Dockerty, M. D. *Surgery Gynec. Obstet.* 1956, **103**, 23.
7. Leon-Sotomayor, L., Moore, V. A. *Unusual Clinical Features of Cirrhosis and Primary Liver Cell Carcinoma*; p. 86. Springfield, Illinois, 1967.
8. Gall, E. A. *in Diseases of the Liver* (edited by L. Schiff); p. 543. Philadelphia, 1956.
9. Bosniak, M. A., Phanthumachinda, P. *Am. J. Surg.* 1966, **112**, 348.
10. Yu, C. *Am. J. Roentgenol. Radium Ther. nucl. Med.* 1967, **99**, 142.
11. Alfidi, R. J., Rastogi, H., Buonocore, E., Brown, C. H. *Radiology*, 1968, **90**, 1136.
12. Reuter, S. R., Redman, H. C., Siders, D. B. *ibid.* 1970, **94**, 89.
13. Gammill, S. L., Takahashi, M., Kawanami, M., Font, R., Sparks, R. *ibid.* 1971, **101**, 549.
14. Goldstein, H., Neiman, H., Mena, E., Bookstein, J. J. (Unpublished.)
15. Bockus, H. L. *Gastroenterology*, 1965; vol. III, p. 502. Philadelphia.
16. Black, M. N., Leis, H. P., Jr. *N.Y. State J. Med.* 1972, **72**, 1601.
17. Herbst, A. L., Kurman, R. J., Scully, R. E. *Obstet. Gynec.* 1972, **40**, 287.
18. Johnson, F. L., Feagler, J. R., Lerner, K. G., Majerus, P. W., Siegel, M., Hartmann, J. R., Thomas, E. D. *Lancet*, 1972, ii, 1273.
19. Adlercreutz, H., Tenhuen, R. *Am. J. Med.* 1970, **49**, 630.