

Case Reports

Left Ventricular Apical Puncture: A Procedure Surviving Well Into the New Millennium

Tansel Turgut,¹ MD, Michael Deeb,² MD, and Mauro Moscucci,^{1*} MD

We report two patients with a history of prior mitral valve and aortic valve replacement with St. Jude prosthetic valves, who were referred for repeat valve replacement after noninvasive assessment was suggestive of prosthetic valve malfunction. Both patients were managed medically after evaluation with direct left ventricular apical puncture revealed normal hemodynamics in the first and mild aortic stenosis in the second patient. These two cases illustrate that, despite the advancements in the noninvasive evaluation of prosthetic heart valves, left ventricular direct puncture continues to have an important value in the evaluation of patients referred for repeat valve replacement, and it can prevent unnecessary surgeries associated with a high risk of morbidity and mortality. *Cathet. Cardiovasc. Intervent.* 49:68–73, 2000. © 2000 Wiley-Liss, Inc.

Key words: left ventricular apical puncture; retrograde catheterization; prosthetic heart valve; aortic stenosis

INTRODUCTION

Accurate evaluation of valve function among patients with prosthetic heart valves is difficult and frequently requires direct measurement of the left ventricular and aortic pressures with cardiac catheterization. Unfortunately, the conventional retrograde catheterization has the risk of temporary dislocation or immobilization of the disk by the catheter. Due to the technical problems with this method, alternative approaches of obtaining left ventricular (LV) pressure have been sought. Although rarely used, a reliable and effective method of obtaining direct LV pressure is by direct transthoracic puncture of the left ventricle.

We report two patients who had a history of prosthetic mitral and aortic valve replacement and were referred for repeat valve replacement after echocardiographic evaluation suggested severe aortic stenosis. In the first case, transthoracic left ventricular and transseptal punctures were performed, and the valves were found to be normal. In the second case, hemodynamic evaluation revealed mild prosthetic valve dysfunction. Based on the findings of cardiac catheterization, both patients have been managed medically.

CASE REPORTS

Case 1

A 64-year-old female presented with complaints of fatigue, exertional dyspnea, and atypical chest pain. Her

past medical history was significant for hypertension, chronic atrial fibrillation, and rheumatic heart disease involving the mitral and aortic valves. She underwent an open mitral commissurotomy 19 years ago. Eight years later, due to native valve endocarditis, she required aortic and mitral valve replacement. A 31-mm St. Jude valve (St. Jude Medical, Minneapolis, MN) was placed in the mitral position and a 21-mm St. Jude valve was placed in the aortic position.

Her physical examination revealed an irregular rhythm with a rate of 68 bpm and a blood pressure of 120/80 mm Hg. Carotid upstrokes and pulmonary examination were normal. A 2/6 ejection systolic murmur was heard in the second right intercostal space and normal prosthetic aortic and mitral valve clicks were appreciated. There was trace lower extremity edema. She was evaluated with a transesophageal echocardiogram (TEE), which revealed

¹Department of Internal Medicine, Division of Cardiology, Interventional Cardiology, University of Michigan Medical Center, Ann Arbor, Michigan

²Department of Surgery, Cardio-Thoracic Section, University of Michigan Medical Center, Ann Arbor, Michigan

*Correspondence to: Dr. Mauro Moscucci, University of Michigan Medical Center, Division of Cardiology, B1 F245 UH, 1500 East Medical Center Drive, Ann Arbor, MI 48109. E-mail: moscucci@umich.edu

Received 4 February 1999; Revision accepted 9 August 1999

normally functioning dual disk prosthetic mitral valve. The aortic prosthesis was poorly visualized; however, turbulent flow was noted in the ascending aorta. The peak aortic valve gradient was 66 mm Hg and the mean gradient was 33 mm Hg, thus suggestive of prosthetic aortic valve stenosis. Further evaluation with cinefluoroscopy revealed normally functioning St. Jude prosthetic valves in mitral and aortic positions. Despite the fluoroscopic findings, due to her symptoms and the high gradients across the aortic valve on echocardiogram, the patient was referred for aortic valve replacement. In view of the operative risk and her relatively vague symptoms, it was decided to proceed with direct measurement of left atrial and left ventricular pressures by transeptal and transapical left ventricular punctures.

The patient was brought to the cardiac catheterization laboratory. The cardiac apex was palpated and the exact location was marked with a pen. Using a modified Seldinger approach, a 6 Fr sheath was placed into the right femoral artery and two 8 Fr sheaths were placed into the right and left femoral veins. An 8 Fr Swan-Ganz catheter was advanced into the pulmonary capillary wedge (PCW) position through the left femoral venous sheath and right heart catheterization was performed. Diagnostic coronary angiography using standard Judkin's technique was performed. A 6 Fr pigtail catheter was then advanced into the ascending aorta.

After adequate intravenous sedation and topical anesthesia with 1% lidocaine, the left ventricular apex was punctured at the sixth intercostal space using a 7-cm-long 21-gauge needle (Cook Micropuncture Introducer set, Cook, Bloomington, IN). The needle was inserted into the left ventricle with a single continuous thrust. Then a 0.018", 40-cm-long Nitinol guidewire with platinum tip (Cook) was advanced into the left ventricle. Over the nitinol wire, a 4 Fr, 10-cm-long introducer (Cook) was advanced into the left ventricle. The introducer was then exchanged for a 65-cm-long 4 Fr pediatric pigtail catheter (Mallinckrodt Med, St. Louis, MO; Fig. 1) over a 0.035" J-wire. Using the standard Brockenburg technique, the interatrial septum was punctured and a Brockenburg transeptal needle was advanced into the left atrium (LA). There were no complications.

The aortic and left ventricular (LV) pressures were recorded. The gradient across the aortic valve measured simultaneously through the aortic and left ventricular catheters was only 7 mm Hg (Fig. 2). The cardiac output by thermodilution technique was 3.8 liters/min. The calculated aortic valve area was 1.7 cm². Simultaneous LV and LA pressure measurements were recorded (Fig. 3). The mean left atrial pressure was 12 mm Hg. There was no end-diastolic gradient across the mitral valve and the calculated mitral valve area was 2.6 cm². Left

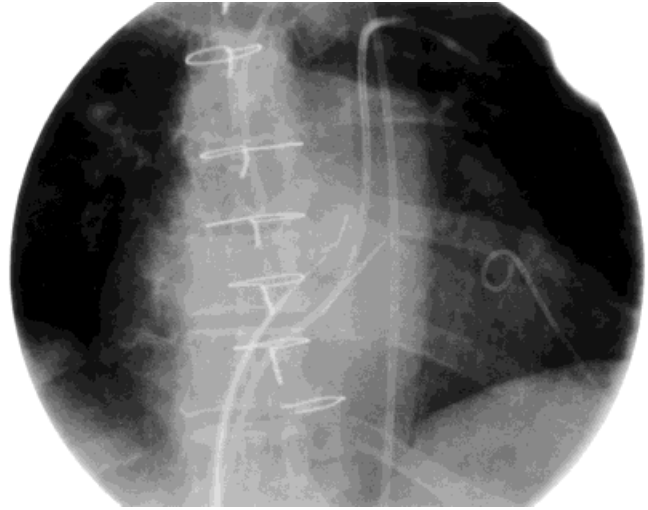


Fig. 1. Cine frame in RAO view. There is a pigtail catheter inserted in the left ventricle through a transthoracic apical LV puncture, a second pig tail catheter positioned in the ascending aorta, a Mullins catheter advanced into the left atrium through the transeptal approach, and a Swan-Ganz catheter positioned in the pulmonary artery. The mitral and aortic St. Jude valve prostheses are visible on the left of the spine (arrows).

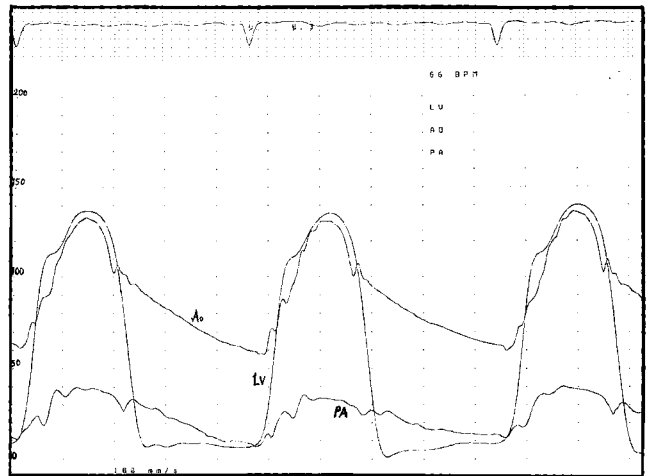


Fig. 2. Simultaneous aortic (A) and left ventricular (LV) pressure tracings, revealing no significant gradient across the aortic valve.

ventriculography was performed by injecting a total of 44 cc at a rate of 11 cc/sec at 328 PSI. To ensure that no side holes were entrapped in the left ventricular wall, position of the pig tail catheter was confirmed by low-pressure contrast injection. Left ventriculography revealed normal LV systolic function (Fig. 4). There was mild (1+) mitral regurgitation. Aortography revealed trace aortic regurgitation. Based on these findings, the patient was diverted from an unnecessary high-risk operation and was successfully treated medically.

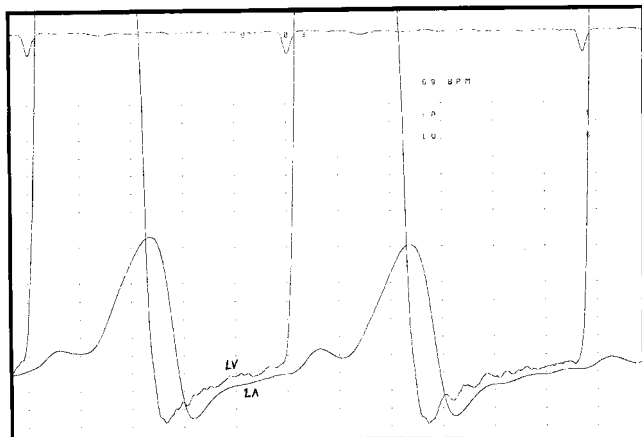


Fig. 3. Simultaneous left ventricular (LV) and left atrial (LA) pressure tracings revealing no significant gradient across the mitral valve.

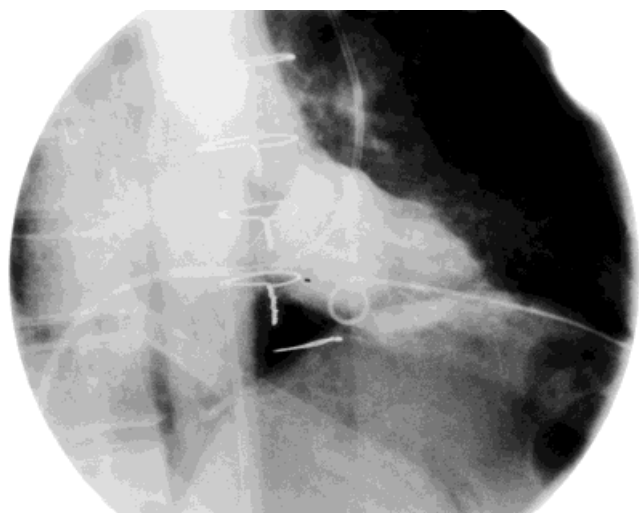


Fig. 4. Left ventriculogram through the left ventricular apical approach.

Case 2

A 54-year-old woman with a past medical history of rheumatic fever, s/p mitral and aortic valve replacement with St. Jude's prosthetic valves (21-mm aortic valve and 31-mm mitral valve) presented to an outside hospital with complaints of increasing fatigue, newly onset atrial fibrillation, decreased exercise tolerance, and New York Heart Association Class III symptoms. Her evaluation included an echocardiogram that revealed a peak gradient of 50 mm Hg, a mean gradient of 31 mm Hg, and an estimated valve area of 0.6 cm², thus consistent with prosthetic aortic valve stenosis.

Fluoroscopic examination revealed a normally functioning mitral valve. The aortic valve leaflets appeared both to be moving. However, the excursion of the aortic valve

leaflets was thought to be mildly impaired. Due to the clinical presentation, the results of the echocardiographic study, and the uncertainty of the fluoroscopic evaluation, it was decided to proceed with further hemodynamic evaluation of the aortic valve with a left ventricular apical puncture. The cardiac apex was palpated, and the exact location was reconfirmed using transthoracic echocardiography. Transthoracic LV apical puncture was performed using the techniques described above without complications, except for transient nonsustained ventricular tachycardia during advancement of the needle. The mean gradient across the aortic valve was 17 mm Hg, and the aortic valve area was calculated at 1.1 cm², thus suggesting mild to moderate aortic stenosis. The mean gradient across the mitral valve was 3.9 mm Hg and the mitral valve area was 2.4 cm². Left ventriculography revealed globally reduced left ventricular systolic function and an estimated ejection fraction of 40%.

Based on these findings, the patient was managed medically and was discharged home on furosemide, amiodorone, digoxin, metoprolol, and coumadin.

DISCUSSION

In 1960, Starr and Edward [1] and Harken et al. [2] performed the first human prosthetic valve implantations. Unfortunately, it was soon recognized that stenosis and regurgitation of these valves were common and a new era in cardiology, requiring careful follow-up and frequent assessment of prosthetic heart valves (PHV), was introduced. Despite recent technological advancement, the value of noninvasive tests in the assessment of PHV remains unsatisfactory and an accurate evaluation of valvular function continues to be challenging.

Physical examination may be misleading in evaluation of prosthetic valvular disease [3,4]. Absence of the opening click of a mitral valve prosthesis and a reduction of A2-opening click interval may be helpful [5,6]. Excessive tilting motion of a prosthetic valve on fluoroscopy or echocardiography is considered a sign of paraprosthetic leak. However, due to the wide variation between individuals, this finding is only useful in serial follow-up in the same patient. Noninvasive echocardiographic evaluation of prosthetic valve stenosis with two-dimensional or Doppler echocardiography is commonly used. However, it may be challenging to obtain two-dimensional images of a prosthetic aortic valve with echocardiography, and unfortunately, such imaging does not necessarily differentiate normal from abnormally functioning valves [6]. Doppler echocardiography is another frequently used tool in the assessment of prosthetic valve function [7–9]. Even with this method, the determination of the degree of prosthetic valve stenosis can be extremely difficult because of the wide range of normal velocities through

these valves. The measurements required for prosthetic valve area calculation include the peak velocity, mean velocity, velocity time integral, valve area using pressure half-time, and effective valve orifice using the continuity equation [10]. Unfortunately, the measurement of these variables is occasionally inexact, and the accurate calculation of the valve area becomes impossible. Another source of potential error is the phenomenon of pressure recovery. This concept is based on the principle of energy conservation, which requires that the velocity of a fluid increases as the pressure decreases [10]. As blood accelerates across the valve orifice, hydrostatic pressure is converted into kinetic energy, thus resulting in an increase in velocity. Moving away from the prosthesis, the velocity then decreases and the pressure increases. Because of the hydrodynamic flow through prosthetic valves, this phenomenon is more significant when compared to native valves, and it might lead to overestimation of the gradients, particularly across small mechanical valves. As an alternative method, physiological examination of prosthetic valves with Doppler studies performed during exercise has been suggested [11].

Although a homograft or xenograft prosthetic valve can be easily crossed with an angiographic catheter with retrograde catheterization, catheter passage across a mechanical prosthesis may cause acute malfunction of the valve, leading to serious complications. The most dangerous complication is the entrapment of the catheter inside the prosthetic mechanical valve requiring surgical removal. Aortic regurgitation caused by incomplete closure of the valve may lead to incorrect hemodynamic evaluation. Several investigators reported their clinical experience with Bjork-Shiley or Starr-Edwards prosthetic valves. However, retrograde cannulation of tilting discs may result in catheter entrapment, and potential major complications. Maranhao et al. [12] used a 7 Fr Sones catheter through a right brachial approach among patients with Bjork-Shiley aortic valve prosthesis. Due to the asymmetric configuration, they recommended careful advancement of the catheter under fluoroscopic guidance through the larger ventricular strut in systole. In 2 of the 13 patients reported, the catheter was entered in the LV through a small strut and some difficulty was experienced in subsequent withdrawal of the catheter to the aorta. Karsh et al. [13] reported their experience with retrograde left ventricular catheterization in 27 consecutive patients with aortic valve prosthesis. The prosthesis was successfully crossed and no complications were encountered in all 27 patients. In left anterior oblique projection, Starr-Edwards and Bjork-Shiley aortic prosthesis were crossed with 5 Fr Cook catheter or with catheters tapering to a 5 Fr tip (8 Fr Sones). They reported a systolic pressure gradient (averaging 12 mm Hg) induced by the catheter in addition to any gradient caused by the prosthesis itself.

With Starr-Edwards prosthetic valves, the ball did not seat completely in diastole with the catheter across the valve, and hemodynamically detectable aortic regurgitation was noted in some patients. Retrograde catheterization was avoided in patients with a recent history of active endocarditis or systemic embolization due to increased risk of embolization. The procedure was suggested as an alternative method for operators who are not willing to accept the risks of direct left ventricular puncture. MacDonald et al. [14] suggested an alternative method using a left coronary artery angioplasty guiding catheter and a 4 Fr coronary probing catheter. The technique was successfully used in seven patients. The major limitation of this technique was the inability to perform conventional left ventricular angiography through the probing catheter due to the size. Rigaud et al. [15] reported the hemodynamic measurements performed with retrograde left ventricular catheterization compared to transseptal or transapical left ventricular catheterization in 23 patients with Starr-Edwards or Bjork-Shiley prosthesis. They reported interference with the diastolic closure mechanism of the valve with resultant aortic regurgitation and approximately a 50% increase in the gradient across the aortic valve with retrograde left ventricular catheterization.

Transbronchial, posterior perispinal [16], transseptal, and direct percutaneous punctures of the LV through the chest wall [17] have been thus introduced as potential approaches of assessing left atrial and left ventricular hemodynamics in patients with prosthetic valvular disease. The first two of these methods are no longer performed due to the unacceptable complication rates and the transeptal approach, which still has wide clinical applications, is only useful in the absence of mechanical mitral prosthesis.

Percutaneous LV puncture, introduced into clinical practice as early as the 1930s [18,19], has been shown to be a reliable and effective method of obtaining LV pressure [20]. This approach consists of introducing a short, small needle into the left ventricle directly through the chest wall through the cardiac apex, under close hemodynamic monitoring. It allows simultaneous measurement of LV and aortic pressures and is also suitable for performing a ventriculogram. The overall risk is considered acceptable, with a major complication rate estimated at 3%–4% [21]. Ventricular arrhythmias, pneumothorax, transient hypotension, vasovagal symptoms, and inadvertent puncture of the lung, a bronchus, the right ventricle, or the coronary arteries have been reported as potential complications of the procedure. In one of the largest series reported, Morgan et al. [22] noted their experience with 112 patients. The LV cavity was successfully entered in 95% of patients and major complications were observed in 3% of patients. There was one death that was observed 4 days after the procedure. An autopsy was

not performed and the authors suggested severe aortic stenosis as the likely cause of death. Two patients required urgent pericardial aspiration due to tamponade. Pericardial and pleuritic pain were observed in 9 (7%) of patients. Pneumothorax was observed in one patient. Levy et al. [23] reported their experience with 122 patients. Out of the 68 patients who were subjected to valve replacement, hemopericardium was found in 6 (8%). One procedure-related death was observed in a patient with transposition of great vessels. Wong et al. [5] reported a series of 13 patients, of which 1 developed hemothorax requiring blood transfusions and surgical drainage. Laceration of a coronary artery is a rare but possible complication of the procedure. Ventricular ectopic beats are frequently encountered [5].

No major complications occurred in our two patients, while minor complications included transient nonsustained ventricular tachycardia during advancement of the needle and transient postprocedure pleuritic chest pain in the second patient.

A useful and complimentary tool in increasing the safety of the procedure is the optimal localization of the cardiac apex prior to the puncture by transthoracic echocardiography. Vignola et al. [24] reported their experience with M-mode echocardiography in seven patients. Interestingly in some of their patients, the point of maximal palpation did not correspond to the cardiac apex. The authors concluded that the maximum apical impulse by palpation may in fact represent an unusually prominent and laterally displaced right ventricular impulse in patients with pulmonary hypertension and right ventricular enlargement [24] and may be misleading. They also recommended the measurement of the exact depth from the skin to the left ventricular cavity with ultrasound recording. In all seven cases, the left ventricle was entered successfully on the first attempt and no complications were observed.

Another important technical tip in our patient was the use of a 21-gauge pediatric needle and a pediatric arterial access kit for the percutaneous LV apical puncture, and the use of a 4 Fr pigtail catheter for left ventriculography. The use of 18- [21,23–25], 19- [22], and 20-gauge [3] needles has frequently been described in the literature. However, despite its first description as early as 1956 [7], the reliable but forgotten technique of using a 21-gauge needle for the percutaneous left ventricular apical puncture is rarely reported today [5]. Despite the low complication rates reported in earlier studies, it is important to note that the procedure can also safely and satisfactorily be performed with smaller needles and hence we feel that larger needles can be avoided.

Reoperation for a prosthetic heart valve carries a significantly higher mortality [26–29] and morbidity [29] risk compared to the initial operation and should only be

attempted when the valve dysfunction is absolutely clear. Despite the improved techniques, the reported overall mortality rates for redo valve surgery still ranges from 8.1% to 31.6% [26,27]. The major risk factors are the need for replacement of a mechanical prosthetic valve (22%) compared to a bioprosthetic valve (7%) [27] and need for double valve replacement. In the latter case, the mortality rates may be even as high as 20%–50% [27,28,30]. Mortality significantly increases for the ball valve prostheses and the reoperative mortality rates may be higher than 30% [26]. Thus, when the risks of a reoperation and the potential limitations of the noninvasive tests are considered, invasive hemodynamic assessment with direct left ventricular puncture appears to be more appropriate.

CONCLUSIONS

The increasing necessity of accurate evaluation of mechanical malfunction in patients with valvular prosthesis often demands the use of nonconventional procedures. One of these nonconventional methods is the percutaneous LV apical puncture and direct measurement of LV pressures from the left ventricular cavity. Despite the invasive nature, the reported risk and complication rate of the procedure is low and acceptable. As shown by the cases reported, it is not uncommon for patients with prosthetic heart valves to present with vague symptoms and with echocardiographic findings supporting the possibility of valvular stenosis. Especially in difficult cases where a clinical decision cannot be made on the basis of noninvasive diagnostic tests, or when these tests do not support the clinical diagnosis, percutaneous left ventricular puncture should be seriously considered to avoid potentially unnecessary high-risk operations.

REFERENCES

1. Starr A, Edward ML. Mitral replacement: clinical experience with a ball-valve prosthesis. *Ann Surg* 1961;154:726–740.
2. Harken DE, Soroff HS, Taylor WJ, Lefermine AA, Gupta SK, Lurizer S. Partial and complete prosthesis in aortic insufficiency. *J Thorac Cardiovasc Surg* 1960;40:744.
3. Morrow AG, Harrison DC, Ross J, Braunwald NS, Clark WD. The surgical management of mitral valve disease: a symposium on diagnostic methods, operative techniques and results. *Ann Intern Med* 1964;60:1073–1100.
4. Sanders CA. Prosthetic problems. *N Engl J Med* 1969;281:501–502.
5. Wong CM, Wong PHC, Miller GAH. Percutaneous left ventricular angiography. *Cathet Cardiovasc Diagn* 1981;7:425–432.
6. Willerson JT, Kastor JA, Dinsmore RE, Mundth E, Buckley MJ, Austen WG, Sanders CA. Noninvasive assessment of prosthetic mitral paravalvular and intervalvular regurgitation. *Br Heart J* 1972;34:561–568.

7. Cooper DM, Stewart WJ, Schiavone WA, Lombardo HP, Lytle BW, Loop FD, Salcedo EE. Evaluation of normal prosthetic valve function by Doppler echocardiography. *Am Heart J* 1987;114:576–582.
8. Heldman D, Gardin JM. Evaluation of prosthetic valves by Doppler echocardiography. *Echocardiography* 1989;6:63.
9. van den Brink RB, Verhaul HA, van Capelle FJL, Visser CA, Dunning AJ. Long term reproducibility of conventional Doppler analysis in patients with prosthetic valves. *J Am Soc Echocardiogr* 1991;4:442–450.
10. Feigenbaum H. *Echocardiography*. New York: Lea & Febiger; 1994. p 300–306.
11. Dresler FA, Labovitz AJ. Exercise evaluation of prosthetic heart valves by Doppler echocardiography: comparison with catheterization studies. *Echocardiography* 1992;9:235.
12. Maranhou V, Fernandez J, Goldberg H. Experience with retrograde left heart catheterization through the Bjork-Shiley aortic valve prosthesis: a Preliminary report. *Chest* 1975;67:348–349.
13. Karsh DL, Michaelson SP, Langou RA, Cohen L, Wolfson S. Retrograde left ventricular catheterization in patients with an aortic valve prosthesis. *Am J Cardiol* 1978;41:893–896.
14. MacDonald RG, Feldman RL, Pepine CJ. Retrograde catheterization of left ventricle through tilting disc valves using a modified catheter system. *Am J Cardiol* 1984;54:1372–1374.
15. Rigaud M, Dubour O, Luwaert R, Pocha P, Hamoir V. Retrograde catheterization of left ventricle through mechanical valve prosthesis. *Euro Heart J* 1987;8:689–696.
16. Nixon PGF. The diagnosis of the mitral lesion in patients with regurgitation. *Postgrad Med J* 1964;40:136–142.
17. Levy MJ, Lillehei W. Percutaneous direct cardiac catheterization. *N Engl J Med* 1964;271:273–280.
18. Nuvoli I. Arteriografia dell' aorta toracica mediante puntura dell' aorta ascendente o del ventricolo S. *Il Policlinico-Sezione Pratica*. 1936;43:227–237.
19. Reboul H, Racine M. Ventriculographic cardique experimentale. *Presse Med* 1933;37:763–767.
20. Brock SR, Milstein BB, Ross DN. Percutaneous left ventricular puncture in the assessment of aortic stenosis. *Thorax* 1956;11:163–171.
21. Kern MJ. Hemodynamic round series. II. Left ventricular puncture for hemodynamic evaluation of double prosthetic valve stenosis. *Cathet Cardiovasc Diagn* 1998;43:466–471.
22. Morgan JM, Gray HH, Gelder C, Miller GAH. Left heart catheterization by direct ventricular puncture: withstanding the test of time. *Cathet Cardiovasc Diagn* 1989;16:87–90.
23. Levy MJ, Lillehei W. Percutaneous direct cardiac catheterization. *N Engl J Med* 1964;271:273–280.
24. Vignola PA, Swaye PS, Gosselin AJ. Safe transthoracic left ventricular puncture performed with echocardiographic guidance. *Cathet Cardiovasc Diagn* 1980;6:317–324.
25. Wong PHC, Chow JSF, Chen WC, Miller GAH. Aortic catheterization via percutaneous left ventricular puncture. *Cathet Cardiovasc Diagn* 1983;9:421–427.
26. Valty J, Bickert P, Maurice P. Re-operations on patients with ball valve prosthesis. *Arch Mal Coeur Vaiss* 1977;70:483–492.
27. De Bruin MJ, Lacquet LK, Skotnichi SH, Vincent JG, van der Meer JJ. Reoperation for prosthetic heart valve replacement. *Thorac Cardiovasc Surg* 1986;34:12–16.
28. Keenan RJ, Armitage JM, Trento A, Siewers RD, Hardesty RL, Bahnson HT, Griffith BP. Clinical experience with the Medtronic-Hall valve prosthesis. *Ann Thorac Surg* 1990;5:748–753.
29. Nallet O, Roger V, Michel PL, Remadi F, Farah E, Acar J. Prognosis of reoperation for prosthesis dysfunction. *Arch Mal Coeur Vaiss* 1992;85:303–308.
30. Kawachi Y, Matuzaki K, Tominaga R, Yasui H, Tokunaga K. The risks of reoperation for prosthetic valve dysfunction. *Surg Today* 1994;24:415–419.