

*Clinical Study*

## **Improved prognosis of intracranial non-germinoma germ cell tumors with multimodality therapy**

Patricia L. Robertson<sup>3</sup>, Robert C. DaRosso<sup>1,2</sup> and Jeffrey C. Allen<sup>1,2</sup>

<sup>1</sup>*Department of Neurology and* <sup>2</sup>*the Kaplan Comprehensive Cancer Center, New York University Medical Center, New York, NY, and the* <sup>3</sup>*Departments of Pediatrics and Neurology, University of Michigan Medical Center, Ann Arbor, MI, USA*

*Key words:* germ cell tumor, brain neoplasm, chemotherapy, radiotherapy

### **Abstract**

The 5 year survival for patients with malignant intracranial non-germinoma germ cell tumors (NGGCT) which include endodermal sinus tumors, embryonal carcinomas, choriocarcinomas and immature teratomas is less than 25% following a small resection and radiotherapy. In an effort to improve the survival of these patients, an approach using an attempt at radical resection where feasible, followed by multi-modality 'sandwich' therapy (chemotherapy-radiation-chemotherapy) was used to treat 18 newly diagnosed patients between 1986 and 1994 in a multi-institution study. Fourteen patients had histologically proven NGGCT and four were presumed NGGCT because of markedly elevated concentrations of serum and/or CSF alpha fetoprotein (AFP) and/or beta human chorionic gonadotrophin (b-HCG). The primary tumor was confined to the pineal region in 12 patients, the suprasellar region in five, and a cerebral hemisphere in one. None of the patients had central nervous system metastases at diagnosis by MRI imaging of the spine and CSF cytology. Radical surgical resection was performed initially in 11 patients (gross total – 6, subtotal – 5); four had a biopsy and three had no surgery. All patients then received 3 or 4 cycles of neoadjuvant chemotherapy with cisplatin (100 mg/m<sup>2</sup>/cycle) and VP-16 (500 mg/m<sup>2</sup>/cycle). Of the 12 patients with evaluable disease there were 9 responses to the neoadjuvant chemotherapy (5 CR, 4 PR); 2 patients had stable disease and 1 progressed during chemotherapy. Six patients with no evaluable disease after a gross total resection had a continuous complete response. Seventeen patients received radiation therapy (involved field – 11, involved field + craniospinal – 4, involved field + whole brain – 2). Twelve patients received 4 cycles post-radiation chemotherapy with vinblastine (6.5 mg/m<sup>2</sup>/cycle), bleomycin (15 U/m<sup>2</sup>/cycle), VP-16 (300 mg/m<sup>2</sup>/cycle, carboplatin (450 mg/m<sup>2</sup>/cycle). A total of four patients have died (3 – progressive/recurrent disease, 1 – metabolic). Four year actuarial event-free and total survival rates are 67% and 74%. This multi-modality adjuvant therapy approach appears to dramatically improve the outcome of malignant intracranial NGGCT.

### **Introduction**

Primary germ cell tumors are uncommon malignancies in the central nervous system, making up less than 5% of the histopathological diagnosis of brain tumors in North American series [1, 2]. They have a peak incidence in the second and third decade, and

usually arise in midline locations, predominantly in the pineal or suprasellar regions of the brain [3]. Like their gonadal counterparts, they are histologically diverse, constituted by several, mostly malignant variants. The germinoma is the most common of these and although the least differentiated, is the most readily cured by radiotherapy, with 5 year dis-

ease-free survival rates approaching 90% in modern series [4–6].

In contrast, the intracranial malignant non-germinoma germ cell tumors (NGGCT) are distinguished as a separate entity because of their relatively poor response to radiotherapy [7]. These tumors include immature teratomas (IT), embryonal carcinomas (EC), endodermal sinus or yolk sac tumors (EST), choriocarcinomas (CC), and mixed tumors that have various combinations of these histologies. As more radical resections of these tumors have been attempted recently, with larger specimens available for analysis, the mixed type is being reported as the most common histological diagnosis [3]. NGGCT make up approximately 40% of the intracranial germ cell tumors [7].

Children and young adults with these NGGCT have a much poorer prognosis than do those with germinomas. With conventional therapy which has usually been a biopsy or small resection followed by radiotherapy, long-term disease free survival rates are less than 25%, with virtually no chance of survival with some of the histological subtypes [7].

More effective therapy is clearly needed for these tumors. Anecdotal cases and small series of recurrent and newly diagnosed intracranial NGGCT have shown responses to chemotherapeutic agents that have been effective in the treatment of systemic germ cell tumors [8–12]. This suggests that a regimen using some of these agents could play an important role in a therapy approach aimed at improving the long term survival of patients with newly diagnosed intracranial NGGCT.

Although intracranial NGGCT are relatively insensitive to radiotherapy compared to germinomas, some do respond [4]. Moreover, anecdotal reports of successful treatment of intracranial NGGCT with chemotherapy also employed radiation [12].

Thus, in an attempt to improve survival of these patients, we conducted a study in which 18 patients with newly diagnosed NGGCT were treated with a multi-modality approach that employed radical surgical resection where feasible followed by radiotherapy ‘sandwiched’ between courses of two different chemotherapy regimens.

## Clinical materials and methods

### *Patient population*

Eighteen patients with primary intracranial NGGCT participated in this multi-institution study between 1986 and 1994. The institutions included: NYU Medical Center, New York, NY; Children’s Hospital of Philadelphia, Philadelphia, PA; University of Michigan, Ann Arbor, MI; St. Joseph Hospital/Marshfield Clinic, Marshfield, Wisconsin, Children’s Hospital and Medical Center, Seattle, WA; Indiana University, Indianapolis, IN; Hackensack Medical Center, Hackensack, NJ; University of California Medical Center, Irvine, CA; Cooper Hospital/University Medical Center, Camden, NJ. Fourteen of the tumors were histologically-proven NGGCT (1 IT, 1 CC, 12 mixed) and four were presumed NGGCT because of elevated ( $> 50$  IU/ml) levels of serum or CSF tumor markers, alpha fetoprotein (AFP) and/or the beta subunit of human chorionic gonadotrophin (b-HCG). No tissue was obtained in three of the latter and one had a biopsy diagnosed as a germinoma. The histopathological diagnosis of record was that of the referring institution. The median age was 12 years (range, 6–24 years). Twelve patients were male and six were female. The site of origin of the tumor was the pineal region in 12, the suprasellar region in five, and a cerebral hemisphere in one.

Ten of the 12 patients with pineal tumors presented with a Parinaud’s syndrome and eleven patients with signs of increased intracranial pressure (headache, lethargy, nausea and vomiting). All five patients with suprasellar tumors presented with diabetes insipidus, three with decreased vision, and one with precocious puberty. Two of the patients with suprasellar tumors had signs of increased intracranial pressure at diagnosis. The child with the cerebral hemisphere tumor presented with a hemiparesis.

Eleven of the 18 patients underwent initial radical surgical resections of their tumors (Table 1). These were gross total resections (GTR) confirmed by imaging in six (5 pineal, 1 suprasellar) and subtotal ( $> 50\%$ ) resections (STR) in five (3 pineal, 1 suprasellar, 1 hemispheric). Four patients under-

went biopsies and three underwent no surgery. One of the patients who was initially only biopsied eventually underwent a gross total resection after neoadjuvant chemotherapy.

All patients were studied with brain CT scans with contrast or MRI scans with gadolinium, metrizamide myelograms or spine MRI, cytological examination of cerebrospinal fluid (CSF) and measurement of serum and/or CSF tumor markers, AFP and b-HCG. None of the 18 patients had evidence of central nervous system dissemination on brain or spine imaging or on CSF cytological examination at diagnosis.

Tumor markers, AFP and b-HCG, were measured prior to therapy in serum and/or cerebrospinal fluid in 14/18 patients (serum only – 5; CSF only – 2; both serum and CSF – 7). Markers were elevated in 12 of the 14 patients (Table 1). Beta-HCG alone was elevated in 3 (1 mixed, 1 CC, 1 no biopsy); AFP was elevated alone in 4 (2 mixed, 1 EST, 1 IT); both AFP and b-HCG were elevated in 5 patients (3 mixed, 1 presumed mixed with histology of germinoma, 1 no biopsy). In all 12 the concentration of at least one of the markers in serum and/or CSF was > 50 mIU/ml. In the 6 patients with elevated marker (s) in whom both CSF and serum marker concentrations were measured, they were > 50 mIU/ml in both serum and CSF in three, > 50 mIU/ml only in CSF in two, > 50 mIU/ml only in serum in one. Neither b-HCG nor AFP were elevated in 2/14 patients (both mixed). B-HCG and AFP were elevated in CSF in another 3/18 patients but the exact concentrations are unknown (2 mixed, 1 presumed mixed). Marker concentrations were not measured prior to a subtotal resection in one patient, but the serum b-HCG was still > 50 mIU/ml after surgery.

### Post-surgery treatment plan

The study protocol (see Treatment schema) prescribed that after any surgery, patients with NGGCT would receive 4 cycles of neoadjuvant chemotherapy administered as follows: cisplatin, 20 mg/m<sup>2</sup>/day and etoposide, 100 mg/m<sup>2</sup>/day, on 5 consecutive days at the beginning of each cycle. Cycles would be repeated every 4 weeks. A response

determination using the imaging modality that originally identified the tumor would be made after 2 and 4 cycles. If residual disease remained after 4 cycles, a second resection was recommended regardless of tumor marker status.

Patients then would receive radiation therapy. Radiotherapy at a dosage of 5500 cGy would be given to the involved field. Craniospinal therapy would be given to patients with disseminated disease at diagnosis, with focal boosts given to areas of measurable metastases. There was considerable controversy about the need for craniospinal irradiation in patients with non-disseminated disease, and this decision was ultimately left to the treating institution. Response determination by brain imaging would be made 4 weeks after radiotherapy if evaluable disease existed prior to radiotherapy.

After completion of radiotherapy, patients would receive four 6 weeks cycles of further adjuvant chemotherapy as follows: Day 1: vinblastine, 4 mg/m<sup>2</sup>; Days 1 and 2: bleomycin, 15 U/m<sup>2</sup> given as a continuous infusion over the 2 days; Days 3, 4, and 5: carboplatin, 100 mg/m<sup>2</sup>/day and etoposide, 150 mg/m<sup>2</sup>/day. Response determination would again be performed after 4 cycles.

After completion of therapy, patients would be followed at intervals with neurological examinations, imaging studies, CSF cytologic examination and measurement of tumor markers. No further therapy would be given to patients who remained in continuous remission.

## Results

### *Response to pre-radiation chemotherapy*

Eighteen patients received either three or four cycles of pre-radiation chemotherapy. There were nine objective responses among the 12 patients with evaluable disease (Table 1). Five patients had a complete response (CR) after 4 cycles and four had a partial response (PR) (Figure 1). Two patients with evaluable disease had stable residual disease (SD) after 4 cycles of chemotherapy and one had progressive disease during chemotherapy. The remaining six patients without evaluable disease had

Table 1. Treatment schema

PT.	Age (Yrs)	Sex	Tumor Location	Tumor Histology	Pre-DX Tumor markers (mlu)			Surgery	Pre-radiation Chemotherapy # of Cycles/Response	Radiation Dose-Field cGy	Post-radiation Chemotherapy # Cycles	Outcome	Survival (yrs.)	
					AFP	HCG	CSE/Serum						EFS	TS
1	13	F	Suprasellar	Choriocarcinoma	(-) (-)	16,000/19,000	STR	3/CR	IF-5500	-	NED	4.3	4.3*	
2	11	F	Suprasellar	Presumed Mixed GCT	NM/(-)	NM/489	No Surgery	4/CR	IF-5500	3 → ongoing	NED	0.4	0.4*	
3	20	M	Suprasellar	Mixed GCT	(-)/NM	88/NM	Biopsy	4/CR	IF-5500	-	NED	8.9	8.9*	
4	8	F	Suprasellar	Germinoma (Presumed Mixed GCT)	146/84	34,000/36,000	Biopsy	4/PR	IF-5040	4	PD (at primary site)	2	2.1	
5	9	F	Suprasellar	Mixed GCT	248/16	(-)/(-)	GTR	3/cCr	-	-	Metabolic Death	0.4	0.4	
6	6	M	Pineal	Presumed Mixed GCT	3.0/31	228/10	No Surgery	4/CR	IF-5500	4	NED	8.2	8.2*	
7	8	M	Pineal	Mixed GCT	↑/NM	↑/NM	Biopsy	4/CR	IF-5500	3	NED	6.9	6.9*	
8	9	M	Pineal	Presumed Mixed GCT	↑/NM	↑/NM	No Surgery	4/PR	IF-5400	4	NED	6.2	6.2*	
9	24	M	Pineal	Mixed GCT	(-)/(-)	25/127	STR	4/PR	IF-5040	4	RD (outside primary site)	7.3	7.4	
10	22	M	Pineal	Mixed GCT	Post STR 693/1399	(-)/(-)	STR	4/PR	IF-5040	4	RD (outside primary site)	2.5	2.7	
11	14	M	Pineal	Mixed GCT	NM/989	NM/26	STR	3/SD	IF-5040	5	SD	5.9	5.9*	
12	6	M	Pineal	Mixed GCT	NM/60	NM/(-)	PD after GTR, before ChRx	4/cCr	IF-5000	4	NED	3.5	3.5*	
13	12	M	Pineal	Immature Teratoma	NM/227	NM/(-)	GTR	4/cCr	IF-5040	4	NED	4.8	4.8*	
14	22	M	Pineal	Mixed GCT	↑/NM	↑/NM	GTR	4/cCr	IF-5040	4	NED	5.5	5.5*	
15	7	M	Pineal	Mixed GCT	(-)/(-)	(-)/(-)	GTR	4/cCr	IF-5040	1	NED	0.9	0.9*	
16	16	M	Pineal	Mixed GCT	NM/74	NM/1149	GTR	4/cCr	IF-5040	4	RD (outside primary site)	0.8	1.1	
17	7	M	Pineal	Mixed GCT	26/3220	17/431	BX (GTR after ChRx)	4/SD	IF-5580	4	RD (outside primary site)	1.2	1.4	
18	4	F	Lateral Ventricle	Mixed GCT	(-)/NM	(-)/NM	STR	3/PD	IF-2000	-	Death	0.1	0.4	

**Abbreviations**

CR-complete response  
 cCR-continuous complete response  
 CS-craniospinal radiation  
 EFS-event free survival  
 GTR-gross total resection  
 IF-involved field radiation  
 IF-no evidence of disease  
 NM-not measured  
 NED-no evidence of disease  
 PD-progressive disease  
 PR-partial resection  
 \* = Continuous Event Free  
 RC-recurrent disease  
 ST-stable disease  
 STR-subtotal resection  
 TS-total survival  
 WB-whole brain radiation

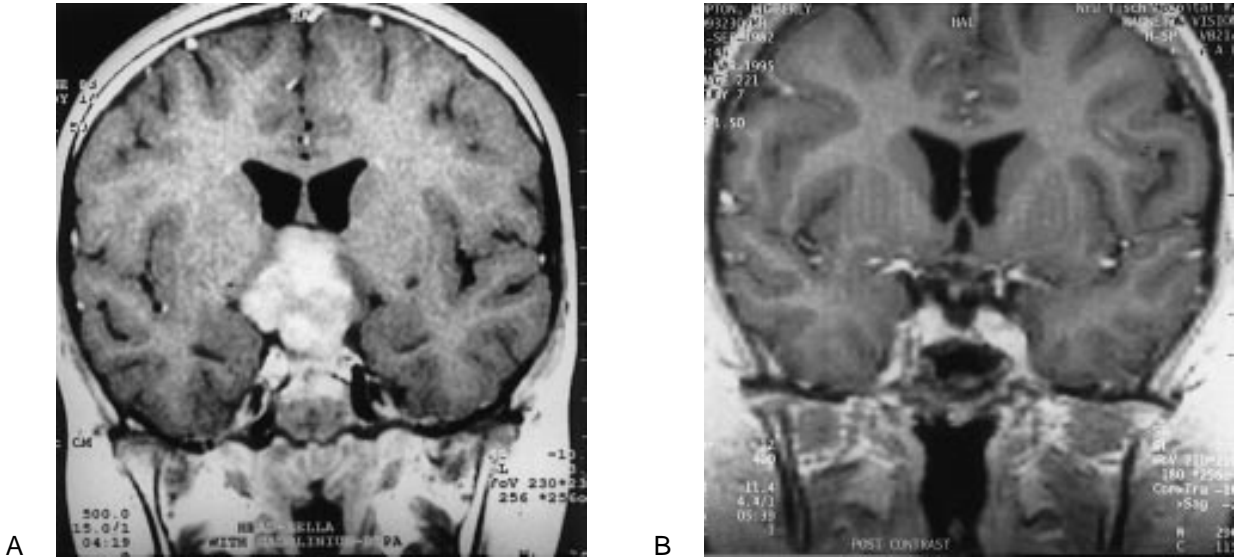


Figure 1. T1-weighted coronal gadolinium-enhanced MRI of a suprasellar NGGCT at diagnosis (a), and showing a complete response after 4 cycles of neoadjuvant chemotherapy (b).

continued complete responses (cCR) to pre-radiation chemotherapy, after gross total resections. One of these developed increased enhancement near the original tumor bed after two cycles of chemotherapy but had no residual tumor at second-look surgery, and the area of enhancement had diminished after the 4th cycle of chemotherapy. One patient with a cCR died of complications of diabetes insipidus after 3 cycles of chemotherapy.

Tumor markers correlated with response to chemotherapy. There were seven patients with evaluable disease in whom marker(s) were initially elevated and again measured after 4 cycles of neoadjuvant chemotherapy. Tumor markers became negative in six patients who had an objective response (4 CR and 2 PR), and decreased but were still elevated above normal in one patient with stable disease.

#### *Response to radiotherapy*

Seventeen patients received radiotherapy after the neoadjuvant chemotherapy. This consisted of involved field radiation as prescribed by the protocol, in 11 patients. Four patients also received craniospinal therapy and two received whole brain radiation because of institutional preference, although none

had disseminated disease. Of the 8/17 patients with radiographically evaluable disease before starting radiotherapy, one had a CR (after a PR to chemotherapy), 6 had stable disease, and one continued to progress and died before completion of radiotherapy. Of the 9/17 without evaluable disease, all had cCRs after radiotherapy.

#### *Response to post-radiation chemotherapy*

Twelve patients completed post-radiation chemotherapy; of the 4/12 with evaluable disease, one had a CR (after a PR to neoadjuvant chemotherapy and SD after radiotherapy), and three had SD; the 8/12 with no evaluable disease had cCRs after post-radiation chemotherapy. Seven of the 19 patients did not complete post-radiation chemotherapy. Two died before receiving it, three refused further treatment after radiation, one continues to receive therapy, and one had discontinuation of therapy because of exacerbation of a pre-existing muscle disease.

### Status at completion of all therapy

Thus, by the time all therapy was terminated, the disease status of the 16 survivors was as follows: 13/16 had no evidence of disease (NED) as a result of a CR at some time during the chemotherapy or radiation (7) or a cCR after a gross total resection (6); 3/16 had measurable radiographic evidence of stable residual disease of which the maximum diameters on MRI were 2 cm, 2.5 cm and 3 cm.

### Outcome

The median length of follow-up of these patients was 4.1 years. Fourteen of the 18 patients initially treated are alive; eleven are in continuous remission, 10 with no evidence of disease (NED) and one with residual stable disease (SD); three survivors developed progressive or recurrent disease 2, 2 2/3, and 7 years from diagnosis. Four patients have died, three of progressive or recurrent disease and one of metabolic complications of diabetes insipidus. Five year actuarial event-free and total survival rates are  $67 \pm 9\%$  and  $74 \pm 10\%$  (SE) (Figure 2).

Ten of the 14 survivors had evaluable disease when they received the neoadjuvant chemotherapy, to which nine had an objective response (5 CR, 4 PR). Six of the nine responders remain in continuous remission and three have progressed or recurred at 2 years, 2 2/3 years, and 7 years after having had PRs to initial chemotherapy; one of these progressed only at the primary site and two recurred in brain outside the radiation field without local recurrence. The single survivor with evaluable disease and no objective response to pre-radiation chemotherapy initially had recurrent disease after a gross total resection before receiving the neoadjuvant chemotherapy. This patient had stable disease (residual pineal mass measuring 3 cm in maximal diameter on MRI) after neoadjuvant chemotherapy, which has remained unchanged after radiotherapy, post-radiation chemotherapy and for 5 years since diagnosis. The four survivors without evaluable disease before pre-radiation chemotherapy have had continuous complete remissions

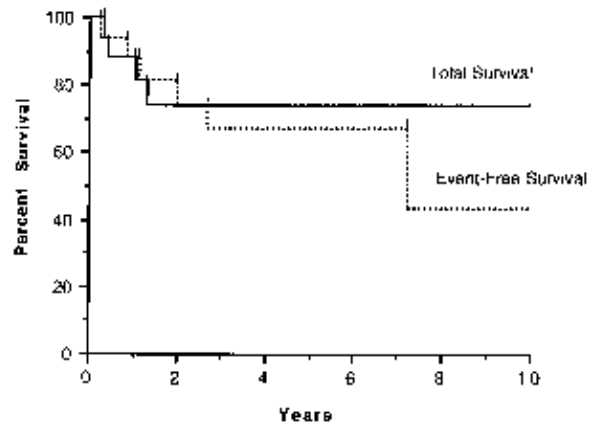


Figure 2. Outcome of NGGCT – Five year actuarial event-free and total survival.

(cCR) with no evidence of disease throughout and since completion of all prescribed therapy.

Of the three patients who died of progressive or recurrent disease, two had evaluable disease prior to chemotherapy. One of these had progressive disease during pre-radiation chemotherapy and died of continued progressive disease during an attempt to deliver radiotherapy, 4 months after diagnosis. The other had no response after 3 cycles of chemotherapy (SD) and then underwent a gross total surgical resection of viable pineal region mixed NGGCT. This patient had continued remission through the completion of involved-field radiotherapy and post-radiation chemotherapy, but developed metastatic disease in the spine without local recurrence and died 16 months following diagnosis. The third patient who eventually died of disease had a GTR and a cCR throughout all prescribed therapy but developed diffuse leptomeningeal metastases in the spine and brain without local recurrence and died 13 months after diagnosis.

Tumor markers were measured in three of the patients at the time of progression or recurrence, and all were again elevated after they had previously become normal in response to therapy.

No treatment-related mortality occurred during this study. Two patients developed venous thrombotic disease during pre-radiation chemotherapy. One had severe systemic veno-occlusive disease treated with anticoagulation and a Greenfield vena caval filter, which resolved within several weeks.

The other had sagittal sinus and one lateral sinus thrombosis associated with headaches. The symptoms promptly resolved with heparinization and the patient remained on coumadin throughout the neoadjuvant chemotherapy and radiotherapy without further problems. One patient developed grade 2 pulmonary toxicity from bleomycin and did not receive the 4th cycle of post-radiation chemotherapy. No grade 3 or 4 otological toxicity was reported in any of the patients. One patient who appeared to have a pre-existing metabolic myopathic disease with low grade elevations of CPK and muscle cramping prior to diagnosis of this tumor, developed acute rhabdomyolysis and myoglobinuria during the first cycle of post-radiation chemotherapy.

## Discussion

Patients with primary malignant intracranial NGGCT historically have had a much poorer prognosis for long term survival than those with germinomas. Patients with these tumors have a very low likelihood of being cured with conventional therapy, which in most cases has been a biopsy or small resection and high dose/high volume radiotherapy. In a meta-analysis of previously published cases, virtually no long term survivors at five years were reported with several types of NGGCT (CC, EC, EST) treated with radiotherapy alone, with an overall survival rate of less than 25% [7]. The multi-modality approach of our study was initiated in 1986 in an effort to improve on the poor outcome of patients with these tumors.

Radical surgical resection was encouraged on this protocol for several reasons. Sampling error from a small piece of tissue may lead to the misdiagnosis of a NGGCT as a germinoma, as was demonstrated in patient # 4 in this series. The determination of the concentrations of the serum and CSF tumor markers, AFP and b-HCG, may compensate for this and it appears that when tumor makers are elevated above 50–100 IU/ml, regardless of histopathology, the tumors behave like NGGCTs and should be treated as such [13, 14]. There was correlation between the degree of marker elevation and

NGGCT histopathology among our patients. In all with histologically proven NGGCT and marker elevation in serum and/or CSF, the concentration of at least one marker was greater than 50 mIU/ml. It should be noted that where both CSF and serum concentrations were measured, the elevated concentration was sometimes seen only one or the other, pointing to the importance of measurement from both sources for diagnosis of these tumors. Moreover, markers are not always elevated with NGGCT [15] as was also illustrated in patients # 2 and # 18. Thus, a larger tissue specimen makes the diagnosis more secure.

It was less certain whether therapeutic benefit would be derived from a more aggressive surgical resection. The prevailing wisdom in oncology is that decreasing tumor burden by surgical means increases the curative potential of subsequent radiotherapy and chemotherapy, and gives the best chance for these treatments to be effective [16]. Although surgery on brain tumors can rarely be as radical as that for systemic tumors, technological advances in surgery and perioperative care have greatly improved the safety of a surgical approach to pineal or suprasellar tumors, and has made a more radical resection feasible in many cases [4, 16].

Whether radical surgical resection of these tumors contributed to good outcome in this study could not be determined given the relatively small number of patients and use of multi-modality therapy. Although 3 of the 7 patients who underwent a gross total resection eventually developed further disease, only one had local progression while 2/3 recurred outside the primary site. Likewise, 3 of the 4 patients who had subtotal resections developed further disease but only one had progressive disease locally while two recurred only outside the primary site. This data still leaves open the possibility that radical surgery could benefit local disease control. Recently reported abstracted data from an international study suggested improved early survival with radical surgery [4], although the combined data reported from several other European studies of 50 NGGCT showed no positive correlation between the extent of surgery and outcome [14].

Several sources of data support the addition of chemotherapy to a multi-modality therapy regimen

aimed at improving outcome with NGGCT. High risk systemic germ cell tumors with non-germinoma histological features have been cured with regimens that included various multi-agent platinum-based regimens [10, 11, 17–23]. Anecdotal reports and small studies suggest that recurrent and newly diagnosed NGGCT of the brain respond to similar platinum-based regimens [8, 9, 12, 24, 25]. The neoadjuvant strategy of the initial chemotherapy has several potential advantages. In patients with evaluable disease it permits determination of the efficacy of specific agents. Response of evaluable disease to chemotherapy may help to stratify patients with regard to risk and possible need for more intensive additional therapy. Neoadjuvant therapy could also have synergistic interaction with subsequent radiation and offers potential control of occult metastases when involved-field radiation is used.

The response of the tumors to this neoadjuvant pre-radiation chemotherapy was excellent, with nine of the twelve patients with evaluable disease showing objective responses. An objective response to the neoadjuvant therapy was predictive of outcome. All nine patients with an objective response are alive at the time of follow-up; six are event-free and 3 have progressed or recurred. There were two objective responses to therapy given after the initial chemotherapy (one CR to radiation after a PR to chemotherapy, and one CR to post-radiation chemotherapy after a PR to initial chemotherapy and SD after radiation). No conclusions about these later responses can be made both because of the very small numbers and the difficulty in interpreting responses to sequential therapy. The platinum dose of the neoadjuvant therapy may be critical to the response rate and ultimate outcome. Recently reported combined data from several European studies showed a four-year survival rate of 86%, comparable to that of our study, in patients who also received 400 mg/m<sup>2</sup> cumulative cisplatin dose before radiotherapy, compared to only 56% in a 200 mg/m<sup>2</sup> cumulative cisplatin group [14]. The degree of response to the neoadjuvant chemotherapy may also be significant to outcome. All three patients with an objective response to the initial chemotherapy but subsequent progression, had only PRs and not CRs to the therapy.

Conversely the lack of an objective response to the platinum-based neoadjuvant therapy in our study correlated with a poorer outcome. Two of three patients without a response were among the three patients who eventually died of their disease. Whether the post-radiation chemotherapy regimen used in this protocol was essential to the overall good outcome is difficult to determine from such a single arm multi-modality study. The combined data from the European studies with survival rates comparable to ours do not answer this question either, because they employed slightly different multi-agent platinum-based regimens given in various orders, each to a relatively small number of patients [14]. However, the lack of an objective response or of a complete response in particular cases, to the neoadjuvant chemotherapy given here supports the need for different additional therapy in this subgroup. The optimal combination and intensity of chemotherapy agents and radiotherapy remains to be determined. The addition of an alkylating agent such as cyclophosphamide, to which some intracranial and other germ cell tumors have also shown responsiveness, is a logical direction [8].

The chemotherapy in this regimen was well tolerated. There were no deaths thought to be related to toxicity from chemotherapy. The development of venous thrombosis in 2 patients during neoadjuvant chemotherapy is of interest. Both of these had remarkably high elevations of the tumor marker b-HCG (36,000 and 19,000 mIU/ml). Whether this complication could be the result of some interaction between the markers and the specific chemotherapy agents is unknown. Another patient who received cisplatin chemotherapy for an intracranial NGGCT has been reported with venous thrombotic complications as well [12].

Although the relative radio-resistance of NGGCT justified using a more aggressive treatment approach for these tumors, there seemed still to be merit to including radiotherapy in a multi-modality regimen in this very high risk group of patients. Some NGGCT's do respond to radiotherapy, and five year survival in two smaller series using radiation alone was recently reported at 33–45% [4, 6]. Radiation therapy may potentially be synergistic with chemotherapy, as well.



Because patients with objective responses to neoadjuvant chemotherapy had good outcomes treated on this protocol, the question of whether the radiation is crucial to the improved prognosis in this subgroup, might be raised. In data from combined European intracranial NGGCT series, nine of ten patients treated with platinum-based chemotherapy, alone, died of their disease, while the 27 patients treated with platinum regimens plus radiotherapy had much better outcomes. In this group, 4 year event-free survivals were 56% and 86% with low dose and high dose platinum plus radiotherapy, comparable to that of our study [14]. Although this data was not specifically analyzed with respect to chemotherapy response, taken together with our data, it supports the conclusion that combination chemotherapy based on high dose platinum plus radiation therapy is the most effective treatment to date. Unless different adjuvant chemotherapy is shown to independently contribute to improved outcome for NGGCT, radiation probably should not be eliminated from this therapy regimen. The tumor progression seen in three of our patients more than two years from diagnosis also demonstrates that long-term follow-up is crucial to assessing the efficacy of any treatment regimen for this type of tumor.

The pattern of recurrence in our patients was noteworthy with regard to optimal radiotherapy volume. Two of the three patients who died of their disease had spinal metastases with no recurrence at the primary site. Neither had received spinal irradiation. Moreover, two of three survivors with progressive disease progressed intracranially outside the radiation field without local recurrence (one suprasellar, one temporal lobe). This raises consideration of a role for craniospinal radiation in the treatment of these tumors, at least for patients without a complete response to initial chemotherapy who may be at higher risk for neuroaxis spread. Other reports of isolated neuroaxis failures with intracranial NGGCT after chemotherapy support this idea, as well [26, 27].

On the basis of our experience with NGGCT, we conclude that this combined multi-modality regimen of neoadjuvant cisplatin/etoposide chemotherapy, radiation and further adjuvant chemother-

apy is effective treatment for these tumors. Although the number of patients treated on this regimen was not large, their median follow-up is long and they have had a better outcome than patients historically treated with radiotherapy alone. The response rate to the neoadjuvant chemotherapy was high and predictive of long-term survival in these patients. Radical surgical resection may contribute to disease control, and obtaining a generous tissue sample for accurate histopathological diagnosis is important in most cases.

Since all patients received at least local radiation, this study can not absolutely establish the necessity of radiotherapy for the improved outcome. However, based on our data taken together with the experience of others where patients treated with high dose platinum regimens but without radiotherapy had a much worse prognosis, we believe that involved-field radiation, at least, should continue to be included in this successful regimen [14]. We also conclude that patients who do not respond and perhaps those who do not have a complete response to the neoadjuvant chemotherapy of this regimen are at significantly higher risk for progression and death from their tumors. Different chemotherapy agents and possibly craniospinal radiation, need to be considered for the treatment regimens of such patients.

### Acknowledgements

The authors wish to acknowledge J. Russel Geyer, M.D., Roger C. Packer, M.D., Arther J. Provisor, M.D., Eric D. Kramer, M.D., Violet Shen, M.D., H. James Nickerson, M.D., Beverly Rossi Ryan, M.D. and their institutions, who treated patients on this protocol.

### References

1. Bloom HJ: Primary intracranial germ cell tumors. *Clin Oncol* 2: 233-257, 1983
2. Jellinger K: Primary intracranial germ cell tumors. *Acta Neuropathol* 25(4): 291-306, 1973
3. Sano K, Matsutani M, Seto T: So-called intracranial germ

- cell tumors: Personal experiences and a theory of their pathogenesis. *Neurol Res* 11(2): 118–126, 1989
4. Hoffman HJ, Otsubo H, Hendrick EB, Humphreys RP, Drake JM, Becker LE, Greenberg M, Jenkin D: Intracranial germ-cell tumors in children. *J Neurosurg* 74(4): 545–551, 1991
  5. Lindstadt D, Wara WM, Edwards MS, Hudgins RJ, Sheline GE: Radiotherapy of primary intracranial germinomas: The case against routine craniospinal irradiation. *Int J Radiat Oncol Biol Phys* 15(2): 291–297, 1988
  6. Matsutani M, Takakura K, Sano K: Primary intracranial germ cell tumors: Pathology and treatment. *Prog Exp Tumor Res* 30: 307–312, 1987
  7. Jennings MT, Gelman R, Hochberg F: Intracranial germ-cell tumors: Natural history and pathogenesis. *J Neurosurg* 63(2): 155–167, 1985
  8. Allen JC, Kim JH, Packer RJ: Neoadjuvant chemotherapy for newly diagnosed germ-cell tumors of the central nervous system. *J Neurosurg* 67(1): 65–70, 1987
  9. Allen JC, Bosl G, Walker R: Chemotherapy trials in recurrent primary intracranial germ cell tumors. *J Neurooncol* 3(2): 147–152, 1985
  10. DeLeo MJ, Greco FA, Hainsworth JD, Johnson DH: Late recurrences of long-term survivors of germ cell neoplasms. *Cancer* 62(5): 985–988, 1988
  11. Borge N, Fossa SD, Ous S, Stenwig AE, Lien HH: Late recurrence of testicular cancer. *J Clin Oncol* 6: 1248–1253, 1988
  12. Kida Y, Kobayashi T, Yoshida J, Kato K, Kageyama N: Chemotherapy with cisplatin for AFP-secreting germ-cell tumors of the central nervous system. *J Neurosurg* 65(4): 470–475, 1986
  13. Balmaceda C, Finlay J, Heller G, Vliamis V, Maher P, Rosenblum M: Prognostic factors at diagnosis in patients with primary CNS germ cell tumors (CNS GCT): A report of an international collaborative trial of chemotherapy (meeting abstract). *Proc Ann Meeting Am Soc Clin Oncol* 13: A494, 1994
  14. Calaminus G, Bamberg M, Baranzelli MC, Benoit Y, di Montezemolo LC, Fossati-Bellani F, Jurgens H, Kuhl HJ, Lenard HG, Curto ML et al.: Intracranial germ cell tumors: A comprehensive update of the European data. *Neuropediatrics* 25(1): 26–31, 1994
  15. Packer RJ, Sutton LN, Rosenstock JG, Rorke LB, Bilaniuk LT, Zimmerman RA, Littman PA, Bruce DA, Schut L: Pineal region tumors of childhood. *Pediatrics* 74(1): 97–102, 1984
  16. Allen JC: Controversies in the management of intracranial germ cell tumors. *Neurol Clin* 9(2): 441–452, 1991
  17. Kobayashi T, Yoshida J, Ishiyama J, Noda S, Kito A, Kida Y: Combination chemotherapy with cisplatin and etoposide for malignant intracranial germ-cell tumors. An experimental and clinical study. *J Neurosurg* 70: 676–681, 1989
  18. Barlow JJ, Lele SB: Etoposide (VP-16) plus cisplatin (DDP): A new active chemotherapeutic combination in patients with stage III–IV ovarian adenocarcinoma. *J Surg Oncol* 32(1): 43–45, 1986
  19. Bosl GJ, Yagoda A, Whitmore WF Jr, Sogani P, Herr H, Vugrin D, Dukeman M, Golbey R: VP-16 213 and cisplatin in the treatment of patients with refractory germ cell tumors. *Am J Clin Oncol* 7(4): 327–330, 1984
  20. Ozols RF, Ihde DC, Linehan WM, Jacob J, Ostchega Y, Young RC: A randomized trial of standard chemotherapy V. A high-dose chemotherapy regimen in the treatment of poor prognosis nonseminomatous germ-cell tumors. *J Clin Oncol* 6(6): 1031–1040, 1988
  21. Ozols RF, Deisseroth AB, Javadpour N, Barlock A, Messerschmidt GL, Young RC: Treatment of poor prognosis nonseminomatous testicular cancer with a 'high dose' platinum combination chemotherapy regimen. *Cancer* 51(10): 1803–1807, 1983
  22. Vugrin D, Herr HW, Whitmore WF Jr, Sogani PC, Golbey RB: VAB-6 combination chemotherapy in disseminated cancer of the testis. *Ann Int Med* 95(1): 59–61, 1981
  23. Roth BJ, Greist A, Kubilis PS, Williams SD, Einhorn LH: Cisplatin-based combination chemotherapy for disseminated germ cell tumors: Long-term follow-up. *J Clin Oncol* 6(8): 1239–1247, 1988
  24. Graziano SL, Paolozzi FP, Rudolph AR, Stewart WA, Elbdawi A, Comis RL: Mixed germ-cell tumor of the pineal region. Case report. *J Neurosurg* 66(2): 300–304, 1987
  25. Watterson J, Priest JR: Control of extraneural metastasis of a primary intracranial nongerminomatous germ-cell tumor. Case report. *J Neurosurg* 71: 601–604, 1989
  26. Senan S, Rampling R, Kaye SB: Malignant pineal teratomas: A report on three patients and the case for craniospinal irradiation following chemotherapy. *Radiotherapy Oncol* 22(3): 209–212, 1991
  27. Wilson ER, Takei Y, Bikoff WT, O'Brein MS, Tindall GT, Boehm WM: Abdominal metastases of primary intracranial yolk sac tumors through ventriculoperitoneal shunts: Report of three cases. *Neurosurgery* 5(3): 356–364, 1979

*Address for offprints:* P.L. Robertson, L3208 Women's Hospital, University of Michigan Medical Center, Ann Arbor, MI 48109-0302, USA