

THE DIENCEPHALON OF THE MINK

I. THE NUCLEAR PATTERN OF THE DORSAL THALAMUS

M. W. M. SLOANE

*Laboratory of Comparative Neurology, Department of Anatomy,
University of Michigan, Ann Arbor*¹

TEN FIGURES

INTRODUCTION

Over the years, many papers have appeared describing the diencephalon of various vertebrates. However, as yet, no author has presented an analysis of this interesting and important region in the mink. The study of this hitherto neglected form has been undertaken in the hope that it will contribute to the knowledge of this portion of the vertebrate nervous system.

The description of the cellular pattern of the diencephalon of the mink (*Mustela vison*) is divided for convenience into two parts. The present study, which forms part I deals with the nuclear arrangement of the dorsal thalamus. Part II, which will appear at a later date, will consider the cellular structure of the epithalamus, subthalamus, and hypothalamus.

A complete review of the literature describing the nuclear pattern of the dorsal thalamus will not be attempted here. In 1936 Ariëns Kappers, Huber, and Crosby reviewed much of the data published about the diencephalon up to that time. For an account of the earlier work reference should be made to their text. LeGros Clark ('36; see also '30, '31, '32), Walker ('37a, b) and Solnitzky ('38) added further papers to the expanding literature on this region. In 1938 Walker ('38a, b)

¹ A dissertation submitted in partial fulfillment of the requirements for the degree of Doctor of Philosophy in the University of Michigan.

published his monograph on the primate thalamus and an account of the thalamus of the chimpanzee and, in the following year, Bodian ('39) brought out the first of his well-known papers on the diencephalon of the Virginia opossum. The next decade brought many more publications dealing with the same subject, among which are the papers by Bodian ('40), Walker ('40), Ibrahim and Shanklin ('41), Vogt and Vogt ('41), Bodian ('42), Rose ('42), Krieg ('44), Sheps ('45), Toncray and Krieg ('46), and Krieg ('48). Also to be quoted are the papers of Clark ('41), Solnitzky and Harman ('43), and Harman and Solnitzky ('44) in which the lateral geniculate body only was considered.

TERMINOLOGY, MATERIAL AND METHODS

The terminology employed is that used by workers at the University of Michigan, notably by Gurdjian ('27), Rioch ('29) and Ariëns Kappers, Huber, and Crosby ('36). In those instances in which the nomenclature adopted by these investigators does not seem to be appropriate, the terminology has been altered to fit more accurately the peculiarities of arrangement found in the diencephalon of the mink.

The material is from the Huber Neurological Collection. It consists of a mink brain fixed in trichloroacetic acid according to the method recommended by Huber, sectioned at 25 μ in the coronal plane, and stained with toluidin blue. Photomicrographs at a magnification of 20 were made of selected sections to illustrate the essential features.

For her encouragement and generous assistance during the course of this investigation, I express my gratitude to Professor Elizabeth C. Crosby. I wish, too, to thank the authorities of Queen's University for a grant from the Ontario Research Fund in aid of the prosecution of this study. My thanks are due, also, to Mr. George Smith, Research Technical Assistant in the Laboratory of Comparative Neurology at the University of Michigan, for the photomicrographs which accompany this paper.

The natural history of the mink is discussed in a paper in process of preparation by Jeserich.²

DESCRIPTION

Anterior group of nuclei

Three nuclei, nucleus anterodorsalis, nucleus anteroventralis, and nucleus anteromedialis, comprise the anterior group. They occupy tuberculum anterius at the rostral pole of the thalamus.

Nucleus anterodorsalis (figs. 1, 2, 3). This nucleus extends from the level of the posterior part of the anterior commissure to a plane through the middle of the optic chiasma. It has a computed length of 1.77 mm. It lies immediately subjacent to stratum zonale and is separated by a fibrous band from nucleus anteroventralis and nucleus anteromedialis, which lie ventrolateral to it. In its rostral part, it is adjacent to the head of the caudate nucleus and is rounded in form. As it is traced caudally, it shifts ventromedially, becoming a flattened band overlying nucleus anteroventralis and nucleus anteromedialis. At the caudal end, it is extremely narrow.

It is composed of closely packed polygonal cells with a varying number of processes. Their cytoplasm stains deeply and is coarsely granular. There is a single, large, pale nucleus with a definite chromatin network and a single deeply stained nucleolus.

Nucleus anteroventralis and nucleus anteromedialis (figs. 1, 2, 3, 4). The cell mass which ultimately partially resolves into these two nuclei first appears at the same level as the posterior border of the optic chiasma and extends caudad to a distance of .325 mm beyond the caudal pole of nucleus anterodorsalis. The whole has a computed length of 2.075 mm and lies ventrolateral to nucleus anterodorsalis. That part of the mass which first appears is nucleus anteromedialis. As it is traced caudally, nucleus anteromedialis becomes more

² M. Jeserich, The Brainstem of the Mink.

clearly defined but on its superolateral aspect it is intimately related with nucleus anteroventralis. For several sections it is difficult to determine the boundary between the two nuclei but as the cells of nucleus anteromedialis stain more darkly, an approximate line of demarcation can be recognized. There appears to be an extension of cells from nucleus anteromedialis along the superomedial border of nucleus anteroventralis. Farther caudally the ventromedial extremity of nucleus anteromedialis extends toward the midline to pass over into nucleus commissuralis interanteromedialis, through which it is in communication with the corresponding nucleus of the other side (fig. 2). As nucleus commissuralis interanteromedialis fades out, the cells of nucleus anteromedialis become

 ABBREVIATIONS

A.PRE., area pretecalis	N.L.P.P.PR.V., nucleus lateralis pars posterior portio ventralis
COR.CALL., corpus callosum	N.LIM., nucleus limitans
CO.HB., habenular commissure	N.OP.TR., nucleus of the optic tract
CO.PR., posterior commissure	N.PAR.C., nucleus paracentralis
FX., fornix	N.PAR.F., nucleus parafascicularis
N.A.D., nucleus anterodorsalis	N.PTR., nucleus parataenialis
N.A.M., nucleus anteromedialis	N.PV.A., nucleus paraventricularis anterior
N.A.V., nucleus anteroventralis	N.PV.P., nucleus paraventricular posterior
N.CAUD., nucleus caudatus	N.RET., nucleus reticularis
N.CENT.LAT., nucleus centralis lateralis	N.RNS., nucleus reuniens
N.CENT.MED., nucleus centralis medialis	N.RHM., nucleus rhomboidalis
N.CO.I.A.D., nucleus commissuralis interanterodorsalis	N.SUBM., nucleus submedius
N.CO.I.A.V., nucleus commissuralis interanteroventralis	N.SUPG., nucleus suprageniculatus
N.CO.I.P.T., nucleus commissuralis interparataenialis	N.TR.HB.P.L., nucleus tractus habenulo-peduncularis lateralis
N.CTM.MED., nucleus centrum medianum	N.TR.HB.P.M., nucleus tractus habenulo-peduncularis medialis
N.D.M., nucleus dorsomedialis	N.V.P.A., nucleus ventralis pars anterior
N.G.L.D., nucleus geniculatus lateralis dorsalis	N.V.P.ARC., nucleus ventralis pars arcuata
N.G.L.V., nucleus geniculatus lateralis ventralis	N.V.P.CO., nucleus ventralis pars commissuralis
N.G.M., nucleus geniculatus medialis	N.V.P.EX., nucleus ventralis pars externa
N.HB.L., nucleus habenularis lateralis	N.V.P.M., nucleus ventralis pars medialis
N.HB.M., nucleus habenularis medialis	PUL., pulvinar
N.L.P.A., nucleus lateralis pars anterior	PUL.D., pulvinar dorsalis
N.L.P.I., nucleus lateralis pars intermedia	TR.M.TH., tractus mammillo-thalamicus
N.L.P.P.PR.D., nucleus lateralis pars posterior portio dorsalis	
N.L.P.P.PR.M., nucleus lateralis pars posterior portio medialis	

arranged as a narrow band along the ventral aspect of nucleus anteroventralis, which withdraws laterally to form a rapidly diminishing clump of cells (fig. 3). At the same time, nucleus anteroventralis shifts toward the midline to replace nucleus anteromedialis. It, in turn, establishes a broad connection with the other side through the nucleus commissuralis in-

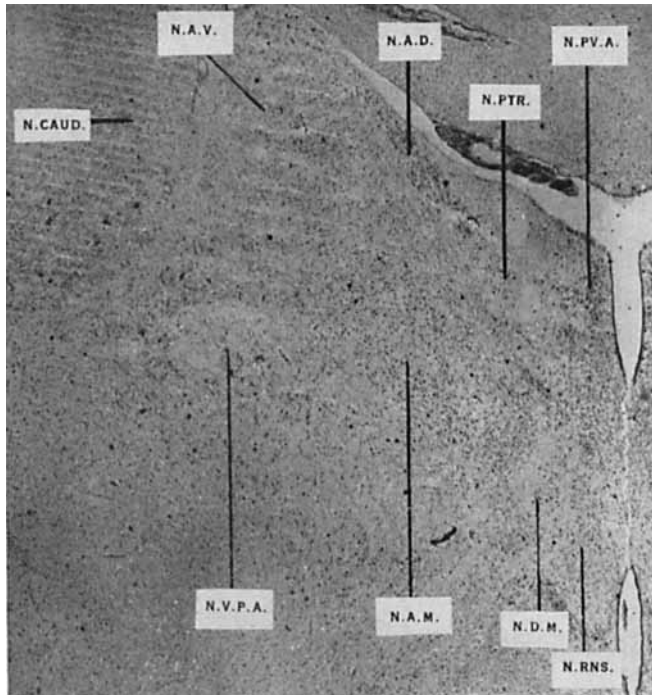


Fig. 1 Section through the rostral end of the thalamus at the level of the rostral pole of nucleus ventralis pars anterior and of nucleus reuniens.

teranteroventralis (fig. 3). As the latter disappears, nucleus anteroventralis can be followed to its rather elongated caudal pole.

The cells of nucleus anteromedialis are similar to those of nucleus anterodorsalis but the Nissl substance is not so abundant nor does it stain so darkly. The nucleus is paler and the chromatin network is not so definite.

Due to fibers of passage, the cells of nucleus anteroventralis are disposed in bands of varying width. This nucleus may be said to consist of a superomedial large cell portion and an inferolateral small cell portion, the extent of each varying from section to section. The large cells are polygonal in shape and resemble closely those of nucleus anteromedialis




Fig. 2 Section through the thalamus at a level slightly more caudal than figure 1.

though not so deeply stained. The small cells are fewer in number, variable in shape though tending to be fusiform in outline, and stain very faintly. The nucleus is relatively large with a fairly well stained nucleolus. The chromatin network can be faintly seen.

As has been pointed out, nucleus anteroventralis and nucleus anteromedialis appear as a common cellular mass which,

farther caudally, only partially differentiates into two nuclei. Nissl (1889) united these nuclei in the rabbit under the same anterior ventral nucleus, although he made secondary divi-




Fig. 3 Section through the thalamus at the level of the caudal border of the optic chiasma.

sions of the cell mass with which no later authors have agreed. Sachs ('09b) called such a combination nucleus dorsalis magnus; Vogt ('09), in *Ceropithecus*, described a main anterior nucleus and a thin accessory nucleus commissuralis thalami pars dorsalis; Friedman ('12) also working with *Ceropithecus*

gave a description similar to that of C. Vogt. Foix and Nicolesco ('25) described only one anterior nuclear mass in man. LeGros Clark ('32) stated that undoubtedly what has been called nucleus anteromedialis in some higher mammals is really a differentiated part of nucleus anteroventralis and that nucleus anteromedialis has become merged with nucleus submedius. Grünthal ('34) agreed with Foix and Nicolesco in his description of this nuclear group. Walker ('38a) mentioned the poor definition between nucleus anteromedialis and nucleus anteroventralis in the macaque. So did Larsell ('42, lit. cit., pps. 237-247), calling the composite cellular mass the chief anterior nucleus. Sheps ('45), however, recognized in man a few cells which he termed nucleus anterodorsalis and described a nucleus anteromedialis but could not delimit it from nucleus anteroventralis since he found the same type of cells in both nuclei. Toneray and Krieg ('46), working with macaque, noted the same lack of demarcation between these two nuclei. Phylogenetically, they stated, nucleus anterodorsalis and nucleus anteromedialis regress and in man neither can be found but nucleus anteroventralis increases in size in the phyletic scale forming most of the anterior group in the chimpanzee and the sole representative of this group in man. They adopted the name nucleus anterior medioventralis.

Mid-line group of nuclei

Nucleus paraventricularis anterior and posterior (figs. 1, 2, 3, 4). These nuclei have an over-all length of 2.450 mm. Nucleus paraventricularis anterior appears just as the postcommissural fibers of the fornix and the anterior commissure are disappearing from view. Beginning as a small group of cells, it enlarges rapidly to form a broad band situated in the dorsomedial angle of the thalamus. The nucleus of one side faces that of the other side across the intervening third ventricle. It is separated from the ependymal lining of the ventricle by a narrow band of fibers. The medullary stria lies above it

and nucleus parataenialis lies directly laterally and closely applied to it. Farther caudally, the nucleus becomes much narrower and elongated dorsoventrally, and the fiber band separating it from the ependyma thins out to the vanishing point. The cells of the dorsal portion of the nucleus stand out more prominently than those of the remainder. The nuclei paraventriculares anteriores form a V or Y around the cavity of the ventricle at this point. Farther caudally, as the commissural nuclei are approached, nucleus paraventricularis anterior is reduced dorsoventrally to allow for the communication of these across the midline. Nuclear paraventricularis anterior now passes over into nucleus paraventricularis posterior, which, in turn, becomes elongated dorsoventrally. The more dorsal part of nucleus paraventricularis posterior stands out prominently in this region due to a certain amount of overlap by nucleus paraventricularis anterior. Slightly farther caudally, the whole periventricular gray becomes less differentiated and nucleus paraventricularis posterior finally ends as scattered cells among the mass of periventricular fibers. It can be traced to a level a short distance caudal to the rostral end of the medial habenular nucleus.

The cells of both nuclei are parallel to the ventricular wall and are fusiform in outline due to compression by the periventricular fibers among which they lie. Their outstanding feature is a large, pale nucleus occupying almost the whole cell, but surrounded by a fairly well stained cytoplasm. The chromatin network of the nucleus is poorly differentiated. There is a single well stained nucleolus.

Nucleus centralis medialis (figs. 2, 3). The rostral end of of this nucleus coincides with the level of nucleus commissuralis interanteromedialis, which forms its dorsal boundary, and the nuclei paracentrales between which it lies and from which it is separated by periventricular fibers. Caudally the cells become more densely packed, so that the nucleus stands out prominently as a midline structure. It extends toward the paracentral nuclei with which it blends, all three forming a composite structure shaped like a bat or a sphenoid bone ly-

ing astride the midline. In the dog, Rioch divided the nucleus into a dorsal commissural portion and a ventral midline portion on either side of which lie nucleus submedius and nucleus reuniens. However, in the mink, as in the cat, nucleus reuniens is a much larger structure and there is no discernible ventral portion of nucleus centralis medialis, so that nucleus centralis medialis of the mink represents the dorsal portion of this nucleus in the dog. Ventrally it is bounded by nucleus reuniens. Farther caudally the dorsal boundary is formed by nucleus rhomboidalis followed by periventricular fibers. In the rostral part of nucleus centralis medialis the cells are closely packed in the midline but in the caudal portion they become arranged in a V, the limbs of which connect the paracentral nuclei. The relatively few cells near the midline are arranged perpendicularly along periventricular fibers. The caudal end of the nucleus consists of scattered cells among these fibers.

The cells of nucleus centralis medialis are rather small in size and rounded or polygonal in shape. The cytoplasm stains intensely and homogeneously. The nucleus is relatively large and the chromatin reticulum is stained almost as intensely as is the cytoplasm. The nucleolus is centrally placed and, though colored deeply, does not stand out clearly due to the intense staining of the reticulum.

Nucleus reuniens (figs. 1, 2, 3, 4, 5). Rostrally nucleus reuniens is of large size and rather triangular in outline. It is divisible into a dorsolateral portion of larger, deeper staining cells and a ventromedial portion in which the cells are smaller, less numerous, and not so well stained. At this level, it lies between the ventromedial extremities of the nuclei anteromediales from which it is separated by the internal medullary lamina. Periventricular gray separates the corresponding nuclei across the midline. Farther caudally it lies ventral to nucleus paracentralis and nucleus centralis medialis and is interposed for a short distance between these two nuclei. It is separated laterally by a fibrous band from the ventral extension of nucleus paracentralis. Somewhat more caudally there is a definite commissural connection which can be fol-

lowed for several sections before becoming a complete fusion of the two nuclei across the midline. At the rostral end of the habenular complex, nucleus reuniens becomes difficult to delineate, due to encroachment by nucleus ventralis pars

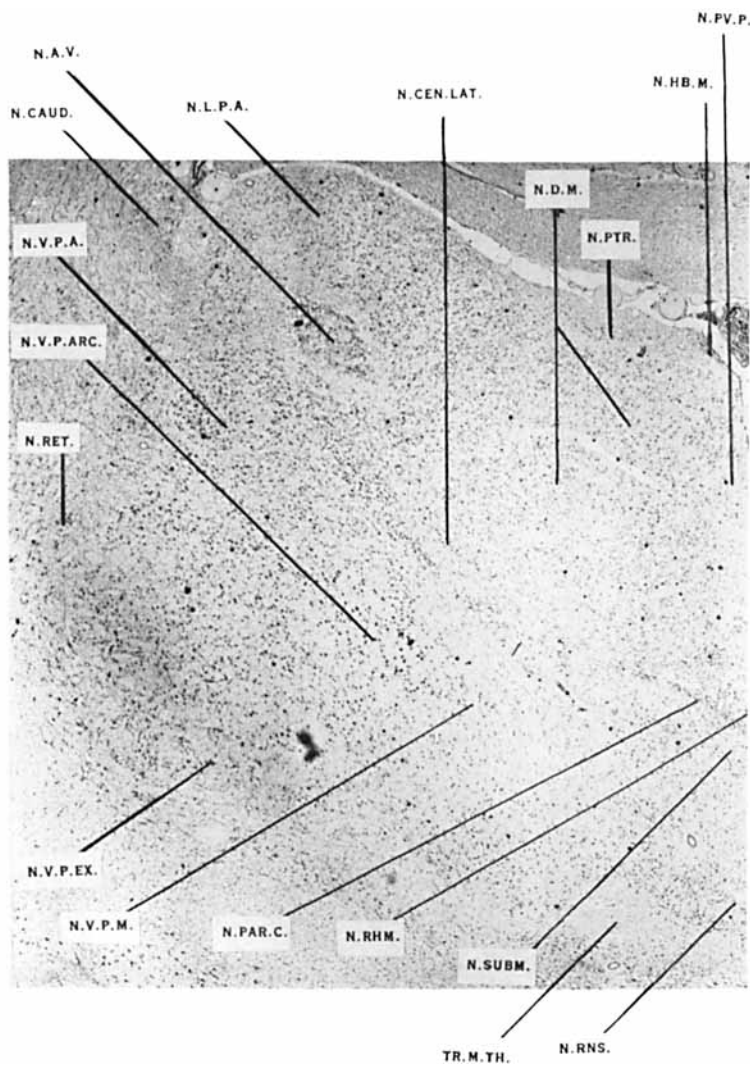


Fig. 4 Section through the thalamus at the level of the caudal pole of nucleus ventralis pars anterior.

medialis. It is replaced at this point by nucleus commissuralis interventralis, which bounds it caudally.

The cells along the lateral border of nucleus reuniens are larger and better stained, those of the medial and ventral portions are more faintly stained and fewer in number. This arrangement, however, does not obtain throughout. The cells

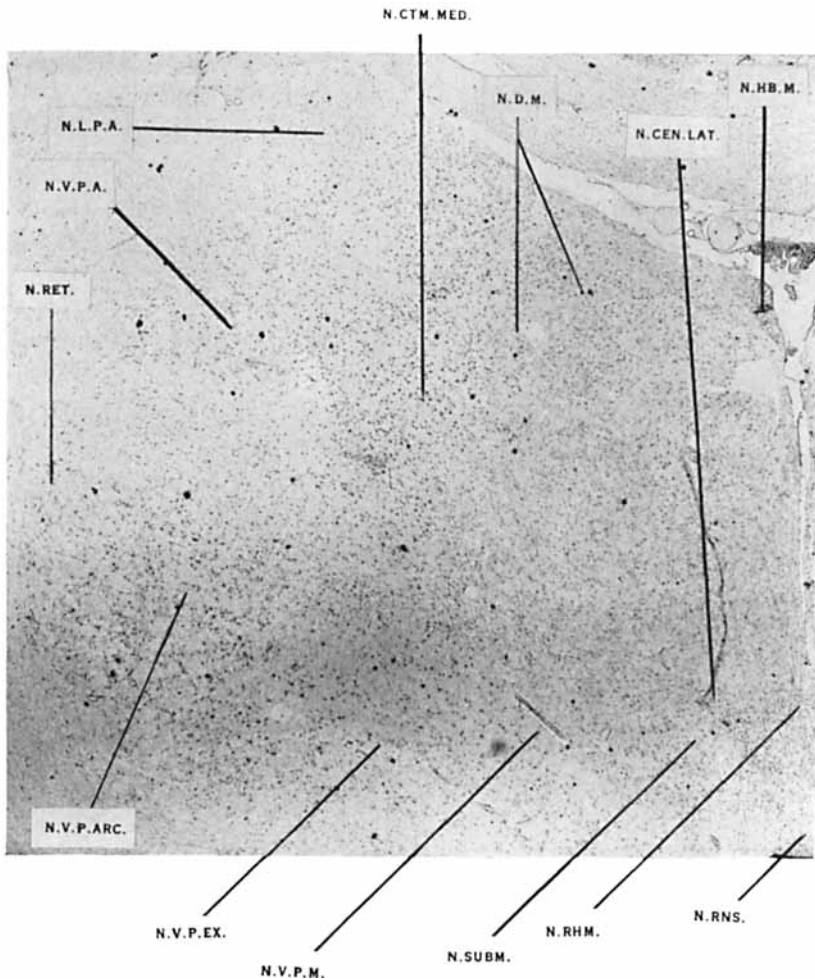


Fig. 5 Section through the thalamus at the level of the caudal pole of nucleus submedius.

along the lateral margin are triangular and fusiform in shape with dense Nissl substance. The nucleus is relatively large with a well defined chromatin network. The nucleolus is well stained and centrally disposed.

Nucleus rhomboidalis (figs. 2, 3, 4, 5). Nucleus rhomboidalis appears at the level of the rostral pole of nucleus centralis medialis as a very small group of well stained cells on either side of the midline. They are dorsal to nucleus centralis medialis and ventral to nucleus dorsomedialis. A little farther caudally, nucleus commissuralis interanteromedialis overlies nucleus rhomboidalis and forms its dorsal boundary. It now becomes compressed by, and intimately fused with, nucleus commissuralis interanteromedialis above and nucleus centralis medialis below. So complete is this blending that, were it not for a few more darkly stained cells interposed between these structures, identification of nucleus rhomboidalis would be impossible. Nucleus commissuralis interanteroventralis now succeeds nucleus commissuralis interanteromedialis as the dorsal boundary of nucleus rhomboidalis. A short distance farther caudally, as nucleus commissuralis interanteroventralis disappears, nucleus rhomboidalis expands and for the first time can be said to be rhomboidal in form. The nucleus can be traced for some distance caudally but finally breaks up in the periventricular gray.

The cells of this nucleus are easily seen because of the intensity of their staining. They are polygonal in form with abundant, coarsely granular Nissl substance. There is a single nucleus with a heavy chromatin network and a single intensely colored nucleolus.

Nucleus commissuralis interanteromedialis (fig. 2). This nucleus appears first as a line of cells which rapidly widens into a well-marked band and which joins the two nuclei anteromediales across the midline. It may be divided into a midline portion and a lateral extension on either side. The extent of the latter parts cannot be determined as they mingle with the nuclei anteromediales so intimately that the boundary between the nuclei is lost. The nucleus commissuralis in-

teranteromedialis lies between nucleus commissuralis interanterodorsalis dorsally and nucleus rhomboidalis ventrally. Its lateral extensions are bounded dorsally by the lateral extensions of nucleus commissuralis interanterodorsalis and ventrally by nucleus paracentralis. The nucleus gives way after a few sections to nucleus commissuralis interanteroventralis.

The cells present no distinguishing features. They are of rather small size, polygonal in shape, and with a coarsely granular cytoplasm. The chromatin network of the nucleus is densely stained as in the single nucleolus. The cells appear to resemble those of nucleus anteromedialis except that they are smaller.

Nucleus commissuralis interanterodorsalis (fig. 2). The lateral extensions of this nucleus are first to appear, extending out dorsolaterally to meet the anteromedial extremity of nucleus anterodorsalis. They are ventrolateral to nucleus parataenialis and dorsomedial to nucleus anteromedialis. Caudally the lateral extensions unite with the central part of the nucleus which appears as a very narrow band across the midline. The cells of both parts are more loosely arranged because of periventricular fibers traversing the nucleus. This nucleus is also divisible into a central midline portion and two lateral extensions.

The cells are paler than those of nucleus anterodorsalis and resemble those of nucleus parataenialis except that they are smaller in size. They are small and elongated in form with a finely granular cytoplasm, which stains faintly. The reticulum of the nucleus also stains rather lightly, so that there is little contrast between cytoplasm and nucleus. The nucleolus stains more intensely.

Nucleus commissuralis interanteroventralis (fig. 3). This nucleus begins to replace nucleus commissuralis interanteromedialis before the latter has completely disappeared. It appears as a well-marked band which rapidly increases in size. It consists of a central portion, in which the cells are dark in color, and two lateral extensions, the cells of which are

lighter. The whole system unites the nuclei anteroventrales across the midline. The central part is bounded dorsally by the periventricular system, more laterally and dorsally lies nucleus dorsomedialis. Ventrally, nucleus commissuralis interanteroventralis is fused with nucleus rhomboidalis. A short distance caudally the lateral extensions become a mere line and they, along with the midline portion, disappear just caudal to the rostral pole of nucleus rhomboidalis.

The cells are small, elongated, and have a finely granular cytoplasm which is moderately well stained. The nucleus has a well impregnated reticulum and the nucleolus stains only moderately well.

Nucleus commissuralis interparataenialis (fig. 2). This is the most dorsal of all the midline nuclei. The lateral extensions are seen before there is any definite evidence of a midline portion. They extend from the ventromedial extremity of nucleus anterodorsalis to the periventricular system, which intervenes between them. Farther caudally, though it is not possible to determine the presence of a midline portion with definite boundaries, the cells of the central part of the nucleus appear. They infiltrate the periventricular fibers well across the midline.

The cells present nothing of note except that they resemble those of nucleus parataenialis.

Nucleus commissuralis interdorsomedialis. Although it is not possible to make out a distinct nucleus, as the cells resemble one another too closely, a definite commissural connection between the nuclei dorsomediales can be followed across the midline. It begins at the most rostral end of nucleus dorsomedialis, at the level of the rostral tip of nucleus rhomboidalis, and lies ventral to nucleus paraventricularis anterior and dorsal to nucleus commissuralis interanterodorsalis. It can be followed through only 4 sections, ending abruptly, and having a total midline length of 0.1 mm.

Nucleus commissuralis interventralis (figs. 6, 7). This is also known as nucleus ventralis pars commissuralis and will be described in detail with the ventral nuclear group.

Medial group of nuclei

Nucleus parataenialis (figs. 1, 2, 3, 4). Nucleus parataenialis begins at a level immediately caudal to the rostral end of the medial habenular nucleus, having a computed length of about 2.5 mm. It appears as a few scattered cells in the dorso-medial angle of the thalamus, ventral to stria medullaris and ventromedial to nucleus anterodorsalis as well as lateral to nucleus paraventricularis anterior. At first it is triangular in outline, but soon assumes a somewhat rhomboidal shape. The nucleus increases considerably in size, the cells becoming more densely packed and staining more deeply; those of the infero-medial angle begin to shift toward the midline. Then, traced caudally, nucleus parataenialis becomes flattened and elongated and closely applied to nucleus paraventricularis anterior, bending around its ventral end towards the midline. Due to numerical reduction of cells, the nucleus now becomes smaller, extending from stria medullaris above, where it is drawn out to a narrow point, to the midline below where it is joined to its fellow of the opposite side by the small nucleus commissuralis interparataenialis. Traced still farther caudad, the nucleus retracts from the midline and, withdrawing dorsally to a position underlying the stria medullaris, assumes a triangular form. It now loses its distinct outline and becomes a flattened band reaching laterally to nucleus anterodorsalis. It gradually diminishes in size until all that remain are a few cells along the ventrolateral border of stria medullaris. These finally fade out shortly after the rostral end of the medial habenular nucleus comes into view.

The cells are polygonal and triangular in form. Most cells are well filled with coarsely granular, moderately well stained Nissl substance, although many have less cytoplasm and are paler in color. The nuclei have a heavy chromatin network with a single, darkly stained nucleolus. With the above noted exception, the cells generally resemble those of the anterior nuclear group.

Nucleus paracentralis (figs. 2, 3, 4). Nucleus paracentralis is made up of a group of densely stained cells lying in the internal medullary lamina, closely applied to the ventral border of nucleus anteromedialis and extending laterally between this nucleus and nucleus ventralis pars anterior. As nucleus centralis lateralis appears, nucleus paracentralis joins the ventromedial tip of nucleus centralis lateralis with nucleus centralis medialis. Rostrally, it is bounded on the dorsal aspect by nucleus commissuralis interanteromedialis but more caudally, and throughout the rest of the extent of nucleus paracentralis, nucleus dorsomedialis forms the dorsal boundary. Ventrally, it is separated from nucleus submedius and nucleus ventralis pars medialis by fibers of the internal medullary lamina; more medially nucleus reuniens is interposed between it and nucleus centralis medialis. Nucleus paracentralis presents a ventral extension of its cells (fig. 3) which, more caudally, fuses with the rostral pole of nucleus submedius. Farther caudally, as nucleus submedius disappears, the ventral boundary of nucleus paracentralis is formed by nucleus ventralis pars medialis and nucleus ventralis pars arcuata. The cells range from moderate to small in size and tend to be elongated and fusiform due to compression by fibers of the internal medullary lamina. The Nissl substance is coarsely granular and stains intensely. The nucleus has a dense reticulum and the nucleolus is single and also deeply stained.

Nucleus centralis lateralis (figs. 3, 4, 5). At its rostral end, nucleus centralis lateralis appears to be an extension of nucleus paracentralis, being joined to the latter by a narrow band of cells. At first it consists of a few moderately stained cells lying in the internal medullary lamina, which separates the anterior nuclear group from the ventral nuclear group. At some levels it is difficult to be sure whether the nucleus paracentralis extends farther laterally or the nucleus centralis lateralis extends more medially, the two being intimately fused at their adjacent extremities. Nucleus centralis lateralis is closely adherent, in its rostral part, to nucleus ventralis, the boundary between them being clearly distinct because the

dark cells of nucleus centralis lateralis stand out prominently. Farther caudally, the ventral and lateral nuclear groups approach each other around the lateral tip of nucleus centralis lateralis. The medial boundary of the nucleus is difficult to determine at this point due to some darkly colored cells along the lateral border of nucleus dorsomedialis (fig. 4). The nucleus now turns directly dorsalward from the almost horizontal position it originally occupied. In this new location it lies in a vertical plane between the lateral and medial nuclear groups. It becomes round or ovoid in outline and, a few sections farther caudally, suddenly ends, some scattered cells extending farther caudally after the disappearance of the main mass. This vertically disposed portion of nucleus centralis lateralis is, in all probability, a primordial centrum medianum.

The cells of this nucleus are spindle-shaped and arranged parallel with the fibers of the internal medullary lamina, which are horizontally disposed. The cytoplasm is coarsely granular and stains intensely. The nucleus is of relatively large size with a coarse chromatin network. The single nucleolus is also of a dark hue. The cells of the lateral portion are more rounded in form with blotchy, darkly colored Nissl substance.

Nucleus submedius (figs. 2, 3, 4, 5). Nucleus submedius lies in the angle formed by nucleus paracentralis and its ventral extension. Its rostral tip appears as a few scattered well-stained cells at approximately the level of the rostral end of nucleus centralis medialis and nucleus paracentralis. Throughout its entire length, it is bounded dorsally by the internal medullary lamina and nucleus paracentralis. Nucleus submedius now shifts more closely into the angle of nucleus paracentralis and its ventral extension. The fiber layer between it and nucleus paracentralis is thin and the cells of the two nuclei intermingle to some degree. The mammillo-thalamic fasciculus lies ventrolateral to it and separates it from nucleus ventralis pars medialis. At the same time, the ventral extension of nucleus paracentralis becomes fused with the medial

border of nucleus submedius (fig. 3). More caudally, nucleus submedius is fused with the ventral border of nucleus dorsomedialis, due to a thinning out of the cells of nucleus paracentralis. A few sections farther caudally, where the ventral extension of nucleus paracentralis has disappeared and nucleus reuniens has shifted somewhat ventralward, the two nuclei submedii are separated at the midline by periventricular fibers. This separation is so narrow that it is difficult to be certain that a commissural connection is not established. As the mammillo-thalamic tract shifts ventrally, nucleus submedius is separated from nucleus ventralis pars medialis by a fiber band but, at some levels, the cells of the former transgress this boundary to blend with those of the latter. At the caudal pole, the intermingling of the cells of nucleus submedius and nucleus ventralis pars medialis becomes so intimate that it is impossible to find a definite boundary between them. Nucleus ventralis pars medialis thus comes to bound nucleus submedius caudally just a short distance behind the rostral pole of the habenular complex.

The cells tend to be arranged in concentric circles and, for the most part, are rather pale in color. They vary in shape from oval to quadrangular. The cytoplasm stains only fairly well and is coarsely granular in appearance. Throughout the cytoplasm there is a suggestion of a pinkish coloration such as is found in the cytoplasm of the cells of nucleus dorsomedialis. The reticulum of the nucleus is not well formed and stains a pale hue. The nucleolus is single and darkly colored.

Nucleus dorsomedialis (figs. 1, 2, 3, 6). This is the largest nucleus of the medial group of nuclei and it appears at the level of the anterior border of the optic chiasma. Its dorsal border is difficult and in places impossible to define, the cells being mingled rostrally with those of nucleus parataenialis, which forms its dorsal and medial boundaries. Laterally, it is separated from the nuclei of the anterior group by fibers of the internal medullary lamina. At this level it is roughly triangular in outline. Farther caudally, the ventromedial tip becomes wedged between nucleus commissuralis interpara-

taenialis and nucleus commissuralis interanterodorsalis. As nucleus parataenialis retracts dorsally, the nucleus dorsomedialis becomes much larger and occupies the space to the left. At the level of the rostral tip of nucleus rhomboidalis, there appears to be a definite commissural connection between the two nuclei dorsomediales. Nucleus dorsomedialis, at this point, is bounded dorsally by nucleus parataenialis and nucleus anterodorsalis, medially by the periventricular gray, and ventrally by nucleus anteroventralis and nucleus commissuralis interanteroventralis. Farther caudally, nucleus rhomboidalis becomes its ventral boundary and nucleus anteroventralis lies laterally but separated from it by the internal medullary lamina. As nucleus anteroventralis retracts from the midline, nucleus dorsomedialis is bounded ventrally by the internal medullary lamina and by nucleus paracentralis, which intervenes between it and nucleus submedius and nucleus ventralis pars medialis. The lateral boundary at this point is formed by nucleus anteroventralis and nucleus lateralis pars anterior with the internal medullary lamina interposed between them and nucleus dorsomedialis. Farther caudally, the lateral boundary is constituted, at first, by nucleus centralis and then by the primordial centromedian nucleus, as these lie in the internal medullary lamina. The separation does not appear to be complete for there is a certain amount of intermingling of the cells of the nucleus dorsomedialis and the nucleus lateralis pars anterior on the dorsal side. The ventrolateral border of nucleus dorsomedialis is difficult to define in this region due to many intercalated cells in the internal medullary lamina. The primordial centromedian nucleus, which now has become rather attenuated, separates nucleus dorsomedialis from the rostral pole of nucleus lateralis pars intermedius, which has appeared at this level. As nucleus centralis disappears, the caudal end of nucleus dorsomedialis is bounded by nucleus lateralis pars intermedius and nucleus lateralis pars posterior. The caudal pole of nucleus dorsomedialis hooks around the nucleus tractus habenulo-peduncularis lateralis, which it bounds laterally and

ventrally. As tractus habenulo-peduncularis finally extends to nucleus parafascicularis, the caudal extremity of nucleus dorsomedialis becomes obliterated by the encroaching cells of nucleus lateralis pars anterior.

The cells of nucleus dorsomedialis are of two types, this becoming apparent a short distance caudal to the rostral pole of the nucleus. The dorsomedial corner of the nucleus is composed of cells which are almost invariably radially disposed from the dorsomedial angle.

The cells are larger, on the whole, than those of the main portion of the nucleus but are much less numerous. They vary in form, some being quadrilateral, others triangular, a few spindle-shaped. The cytoplasm stains moderately well and the large nucleus has a fine reticulum, which is faintly stained. There is a single well stained nucleolus. These cells are mingled laterally with those of nucleus tractus habenulo-peduncularis lateralis and nucleus tractus habenulo-peduncularis medialis.

The cells of the main part of nucleus dorsomedialis are smaller and more closely arranged and are of variable shapes and sizes. The Nissl substance is densely packed and deeply stained. The nucleus has a dense reticulum and a single nucleolus, both of which are well stained.

Nucleus tractus habenulo-peduncularis lateralis (figs. 6, 7, 8). Unlike the dog, in which it lies farther rostrally, the lateral nucleus of the habenular complex in the mink does not appear until several sections caudal to the rostral pole of the medial nucleus of the habenular complex. Tractus habenulo-peduncularis appears after the rostral pole of the lateral habenular nucleus is well formed and, at this level, appears to be made up largely of fibers arising from the lateral habenular nucleus, although it also receives fibers from the medial habenular nucleus. Nucleus tractus habenulo-peduncularis lateralis is a group of cells arranged in a V about the tract as it extends ventrad into the substance of nucleus dorsomedialis. Ventromedially, nucleus tractus habenulo-peduncularis lateralis is bordered by the dorsomedial

part of nucleus dorsomedialis. More caudally, it is bounded by nucleus tractus-habenulo-peduncularis medialis and, still farther caudally, by the periventricular system. Ventrally

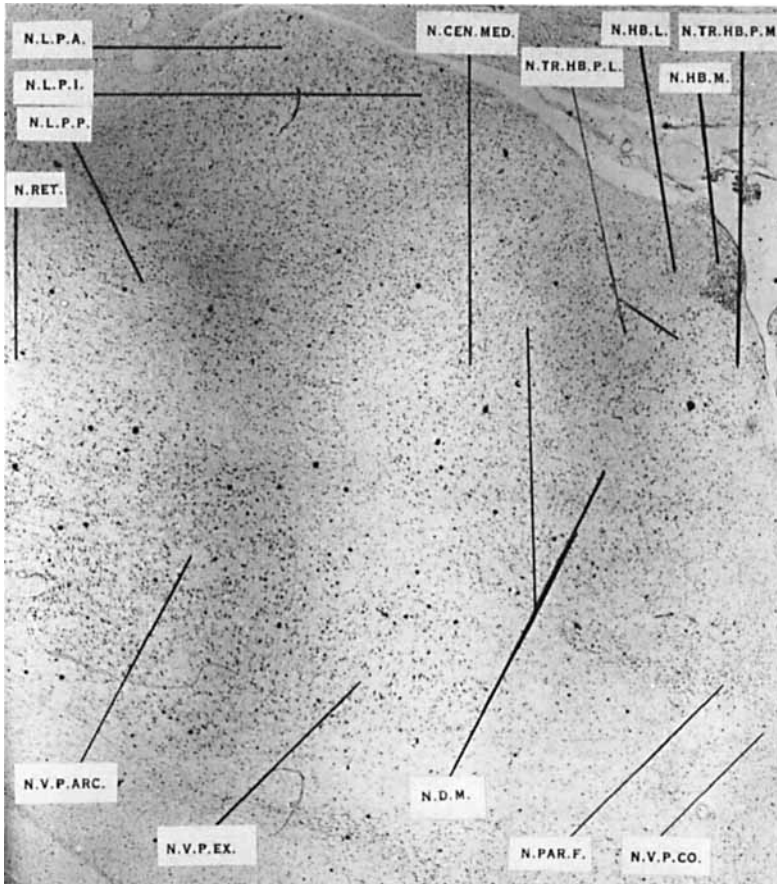


Fig. 6 Section through the thalamus at the level of the rostral end of nucleus habenularis lateralis.

and laterally is the rostral end of the main portion of nucleus dorsomedialis. The boundary between these nuclei is very definite.

More caudally, nucleus tractus habenulo-peduncularis lateralis and the habenulo-peduncular tract extend entirely

through nucleus dorsomedialis to nucleus parafascicularis, which now forms the ventral boundary, the main portion of nucleus dorsomedialis persisting on the lateral aspect up to

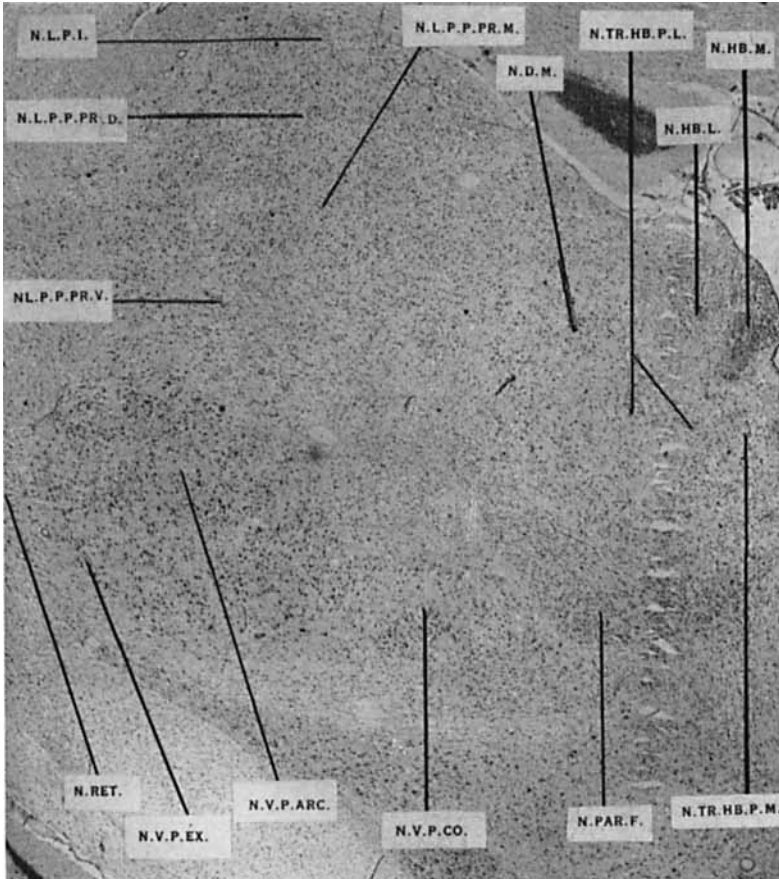


Fig. 7 Section through the thalamus at the level of the caudal tip of nucleus dorsomedialis.

this point. The capsular fibers of the habenular complex lie dorsal to nucleus tractus habenulo-peduncularis lateralis throughout. On the lateral side, the remaining portion of the main or principal part of nucleus dorsomedialis is finally replaced by nucleus lateralis pars posterior. Nucleus tractus

habenulo-peduncularis lateralis extends caudad beyond nucleus parafascicularis, being limited posteriorly by the nucleus lateralis pars posterior.

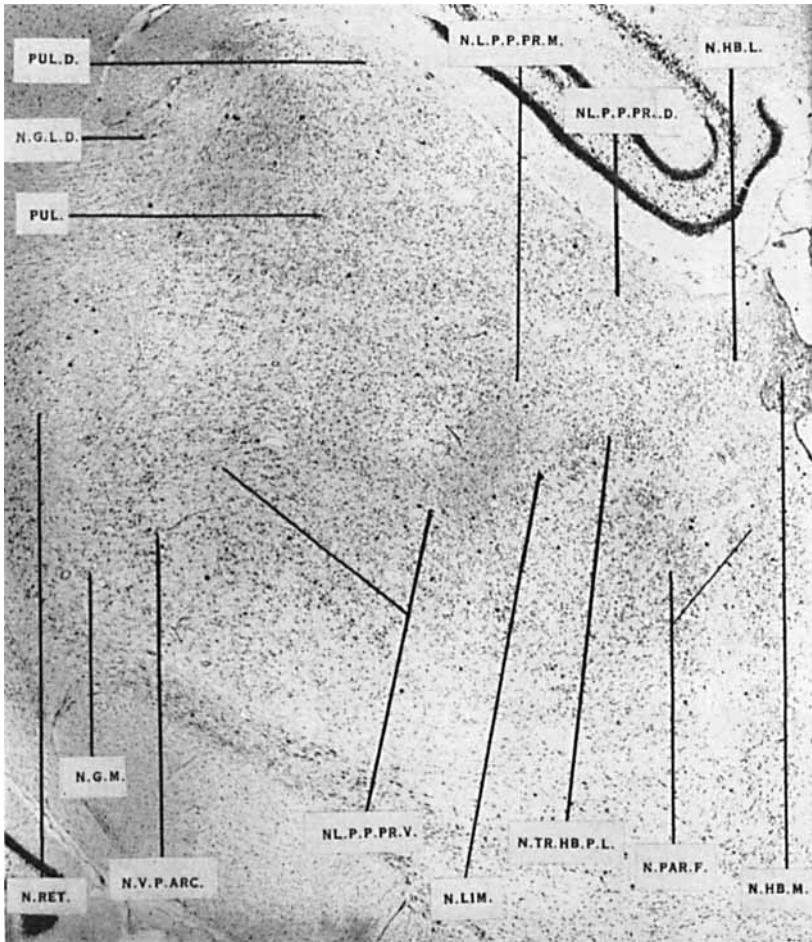


Fig. 8 Section through the thalamus near the level of the caudal end of nucleus habenularis lateralis.

The cells of this nucleus are polygonal in form and rather large in size. The cytoplasm of the cell body is coarsely granular and stains quite deeply but the color does not ap-

pear to extend into the cell processes. In many cells, there is a narrow strip along the margin of the cell body that is also colorless. The reticulum of the nucleus is well formed and easily discerned in some cells but in others the nucleus is quite pale. The single dark nucleolus is rather small.

Nucleus tractus habenulo-peduncularis medialis (figs. 6, 7). This nucleus, together with the nucleus tractus habenulo-peduncularis lateralis, is bounded rostrally by, and is continuous with, the cells of the dorsomedial portion of nucleus dorsomedialis. The cells of its rostral end are associated with fibers from the habenular complex, which run medially and adjacent to the periventricular fibers. In this position, fibers and intercalated cells of the periventricular system lie medial to the nucleus; laterally is nucleus tractus habenulo-peduncularis lateralis and ventrally lies nucleus dorsomedialis. The nucleus extends dorsally toward the capsule of the habenular complex. Traced caudally, nucleus tractus habenulo-peduncularis swings laterad to skirt the medial margin of the main portion of nucleus dorsomedialis with which it seems to be mingled. It enters an interval between the nucleus tractus habenulo-peduncularis lateralis and the nucleus parafascicularis, which now forms the ventral boundary of the nucleus tractus habenulo-peduncularis medialis. At the caudal pole of nucleus dorsomedialis, the cells of nucleus tractus habenulo-peduncularis medialis can no longer be recognized.

Lying among the fibers from the medial nucleus of the habenular-complex, the cells of the nucleus tractus habenulo-peduncularis medialis are spindle-shape. The cytoplasm is finely granular and stains moderately well. There is a dendritic process on either end in which the Nissl granules may or may not have taken the stain. The nucleus is elongated, with a well formed but poorly stained reticulum. There is a single dark nucleolus.

Nucleus parafascicularis (figs. 6, 7, 8). Nucleus parafascicularis appears in the internal medullary lamina at the level of the caudal extremity of nucleus paracentralis. It extends from the periventricular system medially, to the point

laterally at which the fibers of the internal medullary lamina turn dorsad. Rostrally, it is bounded dorsally by the nucleus dorsomedialis and ventrally by nucleus ventralis pars commissuralis, from both of which it is separated by fibers of the internal medullary lamina. Traced farther caudad, the dorsal boundary is augmented, being now formed by the nucleus tractus habenulo-peduncularis lateralis and the caudal pole of nucleus dorsomedialis. At this point nucleus parafascicularis is pierced, at an angle, by tractus habenulo-peduncularis, the cells being crowded around the fibers of the tract as it progresses through the substance of the nucleus. Laterally, the cells are more loosely arranged around fibers within the internal medullary lamina. As the caudal end of nucleus dorsomedialis disappears, nucleus parafascicularis extends upward toward the capsule of the habenular complex but is prevented from coming into direct relationship with it because a part of nucleus tractus habenulo-peduncularis lateralis is always interposed between them. Throughout its extent, nucleus parafascicularis is bounded laterally by fibers of the internal medullary lamina, which separate it from the lateral and ventral nuclear groups. The caudal boundary is formed by nuclei of the posterior commissure.

The cells are arranged horizontally along the fibers of the internal medullary lamina and almost parallel with the fibers of tractus habenulo-peduncularis. The cells along tractus habenulo-peduncularis appear to be larger than the other neurons, and are polygonal in form. The cytoplasm is finely granular and poorly stained. Each cell has a relatively large nucleus with a pale reticular network and a single darkly colored nucleolus. Some of the cells in the internal medullary lamina are also polygonal but the majority of them are fusiform. The cytoplasm is coarsely granular and the nucleus is relatively large with a well formed reticulum, which stains more deeply than in the habenulo-peduncular nuclei. There is a single dark nucleolus.

The nucleus dorsomedialis is the nucleus medialis dorsalis of Gurdjian ('27) and of Rioch ('29) and the nucleus

medialis of Aronson and Papez ('34), Krieg ('44), and of Toncray and Krieg ('46). It was not divided by Gurdjian ('27) in the albino rat. In the dog, Rioch ('29) was able to identify a main portion consisting of small and medium-size cells and a dorsomedial portion made up of somewhat larger cells. Aronson and Papez ('34), working with the macaque, made no division of the nucleus but described the larger darker cells along the periphery, which some other authors label their lateral, magnocellular part. Walker ('38a), also working with macaque, described nucleus dorsomedialis as having a ventromedial portion lying rostrally (which apparently corresponds to the pars magnocellularis of other authors including Rioch), a dorsolateral part composed of small cells (homologous, at least in part, with the small celled portion of other workers), and a posterolateral component within the internal medullary lamina composed of cells similar to those of nucleus centralis lateralis. According to Walker, these cells lying among the fibers of the internal medullary lamina should be considered to belong to nucleus dorsomedialis because they degenerate in experimental lesions of the prefrontal granular cortex. In his paper on the chimpanzee, Walker ('38b) made no mention of a dorsolateral part and divided the nucleus into only two portions. Bodian ('39) attempted no division of nucleus dorsomedialis in the Virginia opossum. Rose ('42) split nucleus dorsomedialis of the sheep into a rostroventral part and a dorsocaudal part. In marked disagreement with Gurdjian, Krieg ('44), also using the albino rat, subdivided the nucleus into a medial part having a medium intensity of staining and a lateral part composed of darkly colored cells. In his investigation, Sheps ('45) identified two components, a medial one of small cells and a lateral magnocellular part, which forms a peripheral coating around the medial element. The cells of this magnocellular part are very similar to those of nucleus paracentralis. In their comparative study of the human thalamus, Toncray and Krieg ('46) recognized two parts of the dorso-medial nucleus; one of these, a small collection of large cells

in the dorsomedial angle, is apparently homologous with Rioch's large cell portion in the dog. Thus Toncray and Krieg were at variance with Sheps on this particular point. In his paper on the macaque, Krieg ('48) felt that nucleus dorsomedialis should be divided into only two parts, although he admitted the validity of recognition of a third part by other workers.

In the mink, there is both a nucleus submedius and a nucleus ventralis pars medialis. Such an interpretation agrees with that of Rioch ('29) for the dog, of Aronson and Papez ('34) for the macaque, and of Walker ('38b) for the chimpanzee. Aronson and Papez considered nucleus submedius to be a part of nucleus ventralis and labelled it pars submedia of nucleus ventralis. Sheps ('45) and Toncray and Krieg ('46) were apparently in agreement that the human nucleus submedius is similar to that of the macaque and that in man there is no nucleus ventralis pars medialis, its place being taken by nucleus submedius. However, Krieg ('48), upon re-examination of the material used in the previous paper ('46), (Toncray and Krieg, '46) believed that nucleus submedius is not so extensive as was described in the earlier paper.

Nucleus centrum medianum has been relegated to different thalamic groups by various authors. The majority, including von Monakow (1895), Winkler and Potter ('11, '14), Rioch ('29), Walker ('38a, b), Sheps ('45), and Toncray and Krieg ('46), have put it with the medial group. Sachs ('09b) and LeGros Clark ('32) placed it in the lateral group and Rose ('42) and Ariëns Kappers, Huber, and Crosby ('36) included it with the ventral nuclear group. Aronson and Papez ('34) made it a part of their posterior group. LeGros Clark ('30, '31) described the centrum medianum as an elaboration of cells within the fibers of the internal medullary lamina and identified it in *Tarsius* and *Microcebus*. According to Rioch ('31) and Ingram, Hannett, and Ranson ('32), a group of cells blended with the lateral portion of nucleus parafascicularis and scattered among the fibers of the internal medul-

lary lamina is, in the case of carnivores, a forerunner of the centrum medianum of higher mammals. Rioch believed that the centrum medianum is probably present in all mammals but is larger and better differentiated in the higher forms. Ariëns Kappers, Huber, and Crosby ('36) were in agreement with Rioch. Walker ('38b) stated that this nucleus is larger in the chimpanzee than in lower forms. Bodian ('39), in his paper on the Virginia opossum, labelled a nucleus parafascicularis pars posterolateralis, which is rostrally continuous with nucleus parafascicularis. He believed it to be homologous with the centrum medianum of Rioch. Rose ('42) identified a centrum medianum in the sheep as a small area poorly delimited from nucleus parafascicularis. Krieg ('44) agreed with Clark in describing the nucleus as an elaboration of cells in the internal medullary lamina but Toncray and Krieg ('46) defined the centrum medianum as a specialization of the caudal end of nucleus centralis lateralis. They did not believe that Bodian's nucleus parafascicularis pars posterolateralis could be homologous with the centrum medianum of carnivores but thought it might correspond to a part of the centrum medianum of higher forms.

Ventral group of nuclei

Nucleus ventralis pars anterior (figs. 1, 2, 3, 4, 5, 6). This portion of the ventral nuclear group lies farthest rostrally and the rostral pole appears as a sparse collection of faintly stained cells at the level of the posterior limit of the anterior commissure. There, it is bounded anteriorly, laterally, and ventrally by fibers of the external medullary lamina, those on the lateral aspect intervening between this nucleus and the caudate nucleus and the internal capsule and, more caudally, the nucleus reticularis, while those on the ventral side of the nucleus intervene between it and the ventral thalamus. Dorsomedially the fibers of the fornix are interposed between nucleus ventralis pars anterior and the nuclei of the anterior group. Behind this level, the internal medul-

lary lamina is placed between nucleus ventralis pars anterior and nucleus reuniens. More caudally, pars anterior of nucleus ventralis is bounded medially by pars medialis of nucleus ventralis and, on its ventrolateral side, by nucleus ventralis pars externa. Then, these two portions of nucleus ventralis extend beneath pars anterior to form its ventral boundary. Still more caudally, nucleus ventralis pars arcuata replaces pars medialis and pars externa of the ventral nucleus as the ventral boundary of pars anterior and retains this position throughout the rest of the extent of pars anterior. The dorsal boundary of nucleus ventralis pars anterior is formed at this level by nucleus anteroventralis and nucleus centralis lateralis with which nucleus ventralis pars anterior appears to fuse because of the arrangement of the cells among the fibers of the thalamic radiations. As the caudal pole of nucleus anteroventralis is reached, it is replaced by pars intermedia of nucleus lateralis. More caudally pars anterior of nucleus ventralis becomes separated from the main mass of the ventral nucleus. In this region, pars intermedia of nucleus lateralis lies on the medial aspect of pars anterior of the ventral nucleus, and pars anterior of the lateral nucleus is adjacent to it, dorsally. Both are separated from pars anterior of the ventral nucleus by fibers of the internal medullary lamina. Pars anterior finally becomes lost among these fibers.

The cells of nucleus ventralis pars anterior are polygonal in form with several long cytoplasmic processes. The Nissl substance is coarsely granular throughout and stains moderately well. The color does not extend into the bases of the rather stout processes. The nucleus is large, almost filling the whole cell, and has a very fine reticulum. The nucleolus is single, rather small in size, and, though dark, is not so deeply colored as the nucleoli of cells in the other groups.

Nucleus ventralis pars medialis (figs. 2, 3). The rostral pole of pars medialis of nucleus ventralis lies on approximately the same level as the rostral pole of nucleus submedius. Here it is bounded dorsally by the internal medullary lam-

ina, ventrally by the external medullary lamina, which bounds the nucleus throughout its extent, and laterally by pars anterior and pars externa of nucleus ventralis. Nucleus submedius lies medial to it but separated from it by fibers of the inferior thalamic peduncle. As it is followed caudally, it increases gradually in size and approaches the mammillo-thalamic tract. Pars arcuata of nucleus ventralis supplants pars anterior of the nucleus as part of the lateral boundary of pars medialis, with pars externa completing this boundary. These form the lateral relationships of pars medialis for the remainder of its extent.

At this point pars medialis presents a lateral extension, which forms, for a short distance, a part of the dorsal boundary of pars arcuata. This extension disappears as pars arcuata rapidly enlarges, so that pars medialis is entirely medial to pars arcuata. At the caudal pole of nucleus submedius, pars medialis lies lateral to the fibers of the periventricular system and nucleus reuniens, mingling with both. Traced farther caudally, pars medialis goes over into pars commissuralis of nucleus ventralis (nucleus commissuralis interven-tralis) but it is impossible to detect the place at which this happens in coronally sectioned material. This can be seen in sagittally sectioned material, as noted by Rioch in his studies on the dog.

The cells of nucleus ventralis pars medialis are of average size and polygonal in shape with several processes on each cell. They bear a marked resemblance to the neurones of pars anterior of nucleus ventralis. The cytoplasm is granular and stains well, the color not extending into the processes. The nucleus is relatively large and contains a fine reticulum. The nucleolus is well impregnated and is rather small. Surrounding the mammillo-thalamic tract and bordering nucleus reuniens, there is a group of smaller cells, closely packed and polygonal in shape, in which the Nissl substance stains more intensely and the nucleus has a darker, coarser chromatin network. At the caudal pole of the nucleus, the cells

are very small and are arranged horizontally along commissural fibers.

Nucleus ventralis pars externa (figs. 2, 3, 4, 5, 6, 7). Pars externa forms a relatively narrow strip along the ventrolateral aspect of the rostral end of nucleus ventralis. Throughout its whole extent it is bounded ventrally by the external medullary lamina, which separates pars externa from nucleus reticularis, and medially by pars medialis of nucleus ventralis and by pars commissuralis of nucleus ventralis, which succeeds pars medialis. Dorsally, pars anterior of nucleus ventralis bounds pars externa at its rostral end. The cells of the rostral end of pars externa are similar in appearance to those of pars arcuata. Those cells which lie closer to the external medullary lamina are elongated due to compression by horizontally running fibers in this region. Traced farther caudally, pars externa rapidly expands in cross-sectional area until it makes up approximately one-third of the whole ventral nucleus. At this level, the rostral extremity of pars arcuata becomes evident, replacing pars anterior as the dorsal boundary of pars externa. From here to its caudal extremity, pars externa becomes progressively smaller. Thus its greatest elaboration is about in its rostral quarter. The last few cells of pars externa appear to blend with those of nucleus geniculatus medialis. The boundary between pars externa and pars arcuata is difficult to find. It is determined by locating the indefinite fiber layer between the two nuclei and by cellular arrangement.

The cells of pars externa are arranged for the most part along horizontally disposed fibers, lying parallel with the curvature of the nucleus. Ventrally, and especially more caudally, these fibers compress the constituent cells between them so that the latter are fusiform in shape.

In the region in which pars externa attains its greatest proportions, the cells are rather large and multipolar with coarsely granular, moderately stained cytoplasm. The nucleus is large, almost filling the cell with a well-developed chromatin network. There is a single, centrally placed, darkly

hued nucleolus. The cells conforming with this description are grouped chiefly in the lateral part of the nucleus. Caudally, the cells are smaller and more elongated due to compression, but of essentially the same appearance. Cells with a clear zone about the nucleus, as described by Rioch in his studies on the dog, could not be seen.

Nucleus ventralis pars arcuata (figs. 4, 5, 6, 7, 8). The rostral end of pars arcuata of the ventral nucleus is bluntly rounded and first appears at the level where pars externa has achieved its greatest dimensions. Pars arcuata rapidly expands in size at the expense of pars externa, as previously pointed out, so that the latter equally as quickly diminishes in size as it is followed caudally. The rostral end of pars arcuata is bounded on the dorsolateral aspect by pars anterior and on its dorsomedial side by pars medialis. Ventrolaterally, it is bounded by pars externa. As it is traced caudally, it extends dorsal to the internal medullary lamina, to come into relationship with the fibers of this stratum and nucleus centralis lateralis, the cells of which lie among the fibers of the lamina. Pars medialis is now directly medial to pars arcuata and so remains. A short distance caudally, pars medialis passes over into pars commissuralis, which in turn becomes the medial boundary of pars arcuata. Pars arcuata expands in a more dorsal and lateral direction so that it finally replaces pars anterior. Still farther caudally, the dorsal boundary of pars arcuata is formed by pars intermedia of nucleus lateralis in addition to the primordial centromedian nucleus, so that, ultimately, pars posterior of nucleus lateralis, more particularly its ventralis, forms the whole dorsal boundary of pars arcuata. At its caudal end, pars arcuata is bounded dorsally by portio ventralis of pars posterior of nucleus lateralis. Ventrally, the last cells of pars externa blend with nucleus geniculatus medialis, which now forms the ventral boundary of pars arcuata. Pars arcuata becomes compressed between the expanding nucleus geniculatus medialis and the pars posterior of nucleus lateralis, being reduced to a narrow band, the cells of which blend with,

and become lost among, those of pars posterior of nucleus lateralis.

The cells of pars arcuata are irregularly grouped and delimited from those of pars externa, pars medialis, and pars commissuralis by indefinite fiber bands. They are all polygonal in shape but differ in staining reaction. In some cells the cytoplasm is dark and coarsely granular. The nucleus is large with a well defined reticular network and a single, centrally placed nucleus. In other cells, the cytoplasm is lighter by comparison and more finely granular. The reticulum of the nucleus is more delicate and the nucleolus is single, well stained, and centrally placed. The lighter cells resemble closely those found in pars anterior of the nucleus ventralis and possibly predominate in pars arcuata. The darker cells resemble the large neurones described for the pars externa. They are grouped particularly in the dorsal and medial regions of the nucleus. In the dorsal region they mingle with the cells of nucleus centralis lateralis and in the medial region may be grouped around what appears to be a fiber bundle entering the ventral nucleus from a dorsal direction. There is no pale perinuclear zone to be seen as was found by Rioch in the cells of this nucleus in the dog.

Nucleus ventralis pars commissuralis (figs. 6, 7). This nucleus is shaped like a bow tie and extends from a level beneath the caudal end of nucleus paracentralis, which forms its dorsal boundary, rostrally to the caudal end of the dien-cephalon. Its ventral boundary, for approximately the rostral half of its extent, is nucleus reuniens, with which pars commissuralis is fused. The rest of the ventral boundary is formed by the external medullary lamina. Whereas, in the dog, the larger lateral portion of this nucleus extends farther rostrally and farther caudally than the smaller medial part, no such rostral extension can be made out in the mink, though the caudal extension is easily seen. The lateral portion of pars commissuralis blends laterally with nucleus ventralis pars medialis, but as the latter grows smaller and finally disappears, the lateral part of pars commissuralis borders upon pars arcu-

ata and pars externa of nucleus ventralis. This relationship is maintained until the caudal extension of the lateral portion of pars commissuralis terminates.

The cells of the medial portion of pars commissuralis are of a small, intercalated, fusiform variety, some being horizontally arranged along the commissural fibers, others being vertically disposed among the periventricular fibers. The cells of the lateral portion are larger and resemble closely the cells of pars medialis of nucleus ventralis.

Lateral group of nuclei

Nucleus lateralis pars anterior (figs. 4, 5, 6). The rostral end of this nucleus extends into the anterior tubercle of the thalamus to a plane through the posterior limit of the optic chiasma. Its dorsal, medial, and lateral borders are rounded, but the ventral border is concave in form, being molded around the dorsal aspect of nucleus anteroventralis. The nucleus is separated from the ventricular ependyma by stratum zonale, and the internal medullary lamina separates it from nucleus anteroventralis ventrally. Throughout its whole length, the external medullary lamina separates it from nucleus reticularis. As it is traced caudally, pars anterior of nucleus lateralis enlarges, nucleus dorsomedialis forming its medial boundary as nucleus anterodorsalis disappears. Farther caudally, nucleus dorsomedialis is succeeded by the primordial centromedium nucleus as the medial boundary. Nucleus ventralis pars anterior forms the ventral boundary, a heavy fibrous layer being interposed between it and nucleus lateralis pars anterior. Still farther caudally, pars anterior of the lateral nucleus becomes progressively smaller and is compressed into the dorsolateral region of the thalamus by the rostral end of nucleus lateralis pars intermedia, which now forms its ventromedial boundary. The caudal end of the nucleus becomes lost among the cells of pars intermedia.

There appears to be no regular arrangement of the cells, these being distributed rather irregularly. They are relatively

few in number and polygonal and triangular in shape. The protoplasm stains fairly well and contains some coarse granular masses. The nucleus is large but does not completely fill the cell. The chromatin network of the nucleolus is only very faintly stained in some neurons but it is more definite in others. The nucleolus is single, darkly stained, and centrally disposed.

Nucleus lateralis pars intermedia (figs. 6, 7). This portion of nucleus lateralis first appears as scattered cells lying in the internal medullary lamina. The rostral boundary is the caudal end of nucleus ventralis pars anterior, nucleus lateralis pars anterior lies dorsally. Medial to pars intermedia is the primordial centromedian nucleus and ventral to it lies pars arcuata of nucleus ventralis. The external medullary lamina separates it from nucleus reticularis on the lateral aspect.

The cells stain faintly though slightly more deeply than those of nucleus lateralis pars anterior, so that differentiation is very easy. They are disposed among the fibers of the region so that they lie in a roughly horizontal plane. Nucleus lateralis is well demarcated from the surrounding cell groups by well developed fiber bands in which lie intercalated cells. Pars intermedia expands rapidly in size in a dorsal direction, encroaching upon the space occupied by pars anterior of nucleus lateralis until it reaches stratum zonale of the ventricular floor. Also, pars posterior of nucleus lateralis becomes differentiated, forming a part of the ventrolateral boundary of pars intermedia and shortly thereafter becoming the whole of this boundary. With the rapid increase in size of pars posterior of nucleus lateralis, pars intermedia of nucleus ventralis becomes compressed dorsally into a smaller space, being now bounded by pars anterior laterally, pars posterior ventrally, nucleus dorsomedialis medially, and stratum zonale of the ventricle dorsally. As pars posterior of nucleus lateralis becomes differentiated into its constituent parts, portio dorsalis and portio medialis of pars posterior form the ventral boundary of pars intermedia. Expansion of

portio dorsalis of pars posterior displaces pars intermedia toward the ventricle, at the same time forming its whole ventral boundary. Slightly farther caudally, the rostral end of pulvinar lies in close apposition to pars intermedia until pars intermedia disappears to be replaced by nucleus lateralis pars posterior, portio dorsalis, and the pulvinar. The outlines of pars intermedia are easily determined by cell differentiation and by rather well marked fiber bands, which separate it from surrounding nuclei.

The arrangement of the cells is not uniform, for they are grouped in clumps, whorls, and bands. There seems to be a tendency, especially in the lateral part, for the cells to be lined up along horizontally running fibers. The cells are small in size and polygonal or triangular in shape. Some stain better than others but all are of the same type. The cytoplasm is coarsely granular and the nucleus is rather large, almost filling the cell. There is a darkly stained, centrally placed nucleolus.

Nucleus lateralis pars posterior (figs. 6, 7, 8, 9, 10). Pars posterior of nucleus lateralis has been divided by some workers into three portions: portio dorsalis, portio medialis, and portio ventralis. Such subdivision depends upon slight cellular differentiation and arrangement and upon ill-defined fiber bands, which only poorly demarcate one zone from the other. In the mink, these three portions of pars posterior can be identified and are so described.

This subdivision of pars posterior first becomes evident as the caudal tip of pars anterior of nucleus lateralis is reached. Its rostral end is bounded medially by pars intermedia of nucleus lateralis and ventrally by pars arcuata of nucleus ventralis but separated from them by fiber bands. Pars anterior of the nucleus lateralis lies dorsally. A few sections farther caudally, a medial extension of pars posterior forms a ventral boundary of the primordial centrum medianum. Beyond the caudal end of the primordial centrum medianum, the medial boundary of pars posterior is formed by nucleus dorsomedialis and the adjacent nucleus parafascicularis. For a short distance, the caudal end of pars commissuralis of

nucleus ventralis lies ventral to it. Farther caudally, the rostral pole of the pulvinar appears on the lateral aspect of pars posterior, fitting into a concavity formed by pars intermedia and pars posterior. Still farther caudally, pars intermedia having disappeared, pars posterior reaches the ventricular floor. At the same time, the medial boundary has been formed by the habenular nuclei, nucleus tractus habenulo-peduncularis lateralis, and nucleus parafascicularis. For the short limit of its extent, nucleus limitans forms a small part of the medial boundary. The pulvinar and its pars dorsalis here form the lateral boundary of pars posterior. Toward its caudal end, pars posterior is bounded on the ventral aspect by the external medullary lamina and nucleus geniculatus medialis, but on its medial side comes into direct contact with the nucleus of the optic tract and the nucleus of the posterior commissure. At this point, portio medialis and portio ventralis of pars posterior blend over into nucleus suprageniculatus, which owes its origin to a fusion of these two portions of pars posterior. Portio dorsalis persists for a short distance farther caudally, being replaced by the diminishing caudal end of the pulvinar.

The cells of portio dorsalis are rather small, not too numerous, and show a range in staining reaction from intensely dark to light. Although there are occasional polygonal or triangular neurons present, the cells are predominantly fusiform in shape and tend to be arranged horizontally. Some are dark, others light, but the essential structure appears to be the same in both types. The cytoplasm is granular, perhaps coarser in the darker cells. The nucleus is of good size with a definite chromatin network and a deeply stained nucleolus. The nucleolus appears to be centrally placed in most cells but occasionally appears to be eccentrically situated.

The cells of portio medialis have no definite arrangement, are numerically greater than those of portio dorsalis and appear to be of two kinds — a dark staining and a light staining cell. The darker cells appear much the same as those found in portio dorsalis, some of them having an eccentrically

placed nucleolus as had some cells of portio dorsalis. The lighter cells are of various shapes and all parts are poorly differentiated. They have a foamy appearance but no other significant features.

The cells of portio ventralis are relatively few in number and diffusely scattered throughout the stroma. They vary in size and shape but are all rather deeply stained. On the whole they are smaller than those of either portio dorsalis or portio medialis. The cytoplasm is granular, and the nucleus is of relatively large size with a definite chromatin network and a centrally placed, dark nucleolus.

Nucleus of the optic tract (figs. 9, 10). This nucleus begins at the level of the habenular commissure and extends caudally for a computed distance of approximately 0.3 mm. On the medial side lies the pretectal area, on the lateral side portio dorsalis and portio medialis of pars posterior of nucleus lateralis. Ventrally it is related to the nucleus of the posterior commissure and fibers of that commissure. Dorsally it extends to the stratum zonale of the ventricular floor. At its caudal end, the pulvinar forms its lateral boundary. It lies along the course of the optic tract fibers.

The cells are closely grouped in a narrow column and stand out prominently due to this compact arrangement and to their intense staining reaction. They are polygonal in shape, with a dark, coarsely granular cytoplasm. The color does not extend into the processes. The nucleus has a well impregnated, centrally placed nucleolus and a definite chromatin network.

Nucleus limitans (fig. 8). Nucleus limitans has an approximate rostrocaudal length of 1.07 mm. It stands out prominently as a small clump of darkly stained cells in the internal medullary lamina. Its rostral end begins at a level just caudal to the caudal tip of nucleus dorsomedialis. In this position it lies lateral to the dorsal tip of nucleus parafascicularis and nucleus tractus habenulo-peduncularis lateralis. Dorsal to it lies portio medialis of pars posterior of nucleus lateralis and lateral to it is portio ventralis of pars

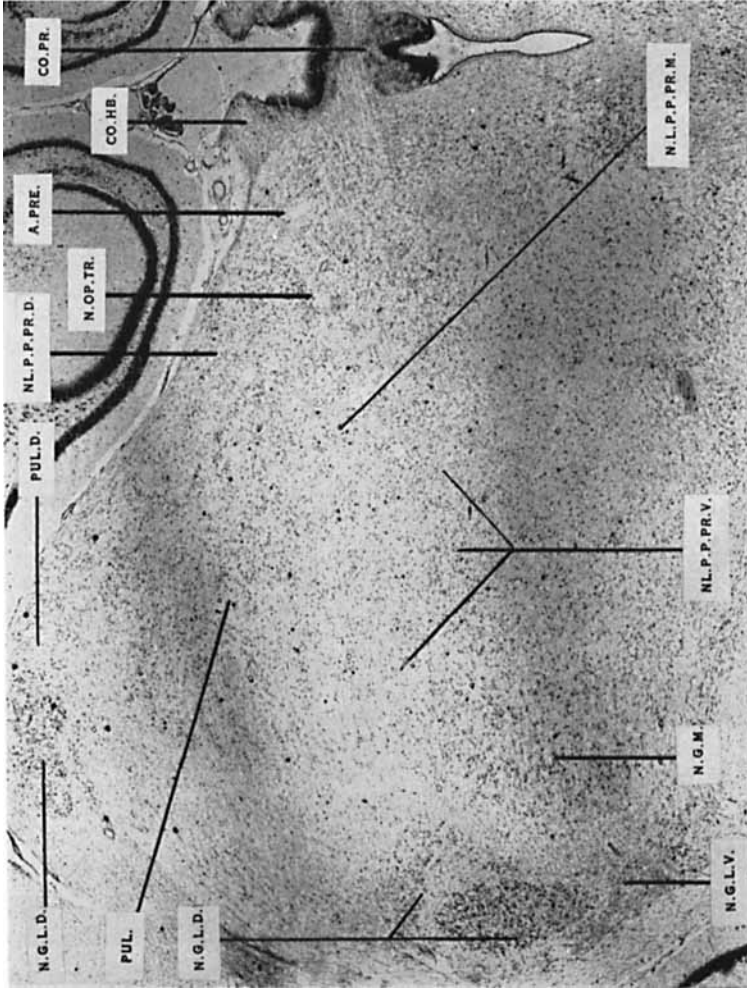


Fig. 9 Section through the caudal end of the thalamus at the level of the rostral limit of area pretectalis and the rostral border of the posterior commissure.

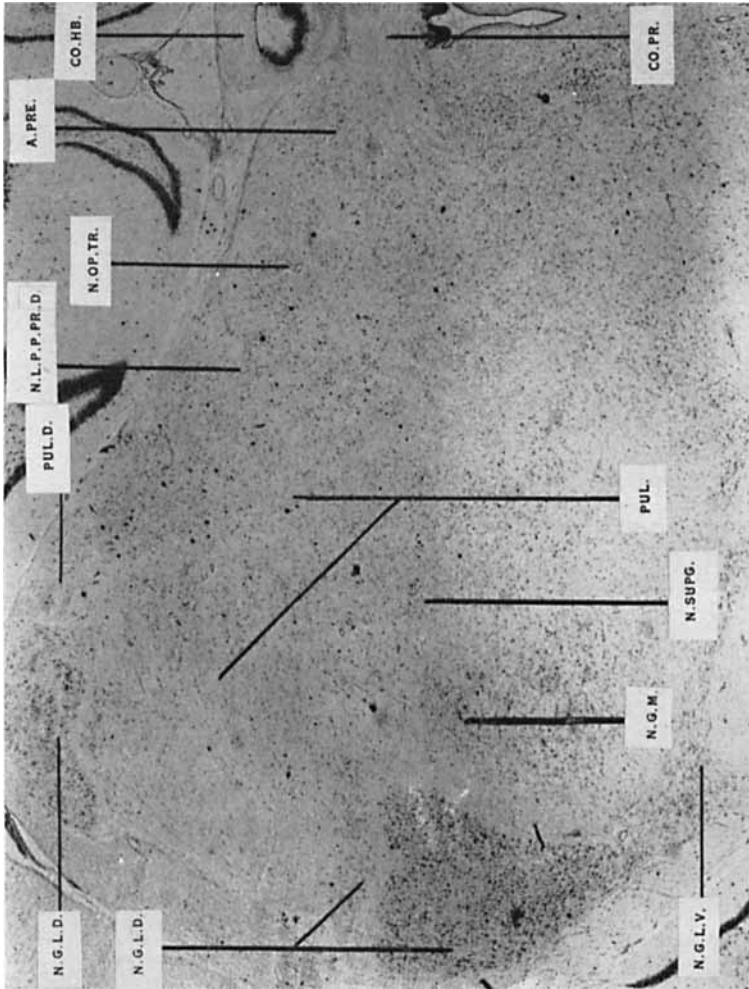


Fig. 10 Section through the caudal end of the thalamus at the level of the posterior commissure at a level slightly caudal to figure 9.

posterior. Farther caudally it shifts its position slightly and changes shape from a rounded clump to an elongated column of cells. Portio medialis of pars posterior of nucleus lateralis now lies lateral to it and portio dorsalis of pars posterior forms its dorsal boundary. A small part of the periventricular gray lies medially. Otherwise its relationships remain unaltered throughout its short extent.

The cells of this nucleus tend to be rather small and fusiform in shape, due probably to compression by the fibers of the internal medullary lamina among which they lie. There are some cells of triangular outline present. The cytoplasm is dark and coarsely granular and the stain extends into the cell processes. The nucleus has a dense chromatin network and a dark, centrally placed nucleolus.

Pulvinar (figs. 8, 9, 10). The pulvinar in the mink is divisible into three parts on a basis of cell type and arrangement: a pars medialis, a pars lateralis, and a pars dorsalis. Its rostral pole is rounded and first appears in the dorso-lateral angle of the thalamus. It overlaps the caudal end of pars intermedia of nucleus lateralis for a short distance. It is bounded here by pars intermedia and pars posterior of nucleus lateralis on the medial side, and pars posterior continues around it to form its ventral boundary as well. The external medullary lamina is related to the pulvinar on the lateral aspect and separates it from nucleus reticularis. Some distance farther caudally, the pulvinar is bounded dorsally by pars dorsalis pulvinaris and medially by portio dorsalis and portio medialis of pars posterior of nucleus lateralis. Ventrally lies portio ventralis of pars posterior of nucleus lateralis, laterally is the external medullary lamina. More caudally, the rostral end of nucleus geniculatus lateralis dorsalis is related to it on the lateral side. Still farther caudally, nucleus suprageniculatus has a ventromedial position. Its caudal pole is bounded by nucleus geniculatus medialis. That part of the pulvinar which lies caudal to a point approximately at the level of the caudal extremity of pars intermedia

of nucleus lateralis corresponds to nucleus posterior of other forms and includes portions of pars medialis and pars lateralis.

Pars medialis pulvinaris is larger than pars lateralis. The cellular elements are densely packed and show no particular pattern of arrangement being grouped in clumps and whorls. There is a mixture of cells of various shapes, all of which tend to be small. They do not stain quite so deeply as do those of the lateral part, though some cells are impregnated better than others. The cytoplasm is granular and the nucleus almost fills the cell. The chromatin network of the nucleus is dense and there is a dark, centrally placed nucleolus.

Pars lateralis pulvinaris is separated from pars medialis in the rostral part of the pulvinar by a well marked fiber band. The cells are about the same size as the larger cells of the medial portion but are fewer in number, and the cytoplasm is stained more deeply. They are arranged along horizontally disposed fibers and are predominantly triangular and fusiform in shape, due to compression by these fibers. Traced caudally, the cells of the lateral portion diminish and disappear long before those of the medial part so that the caudal pole of the pulvinar is composed entirely of pars medialis.

Pars dorsalis pulvinaris corresponds to pulvinar posterior of other forms and occupies the dorsolateral angle of the thalamus. It appears to be an extension of pars lateralis, which begins by swinging around the lateral side of the rostral end of the pulvinar into a position dorsal to it and is prolonged caudally almost as far as the caudal pole of the pulvinar. Pars dorsalis forms a broad band bounded dorsally by stratum zonale of the ventricle, medially by portio dorsalis of pars posterior of nucleus lateralis, and ventrally by the pars medialis and pars lateralis of the pulvinar. Laterally it is bounded by the external medullary lamina. Farther caudally, the lateral boundary is formed by nucleus geniculatus lateralis dorsalis and the ventral boundary is the

pulvinar and the portio dorsalis of pars posterior of nucleus lateralis. A short distance farther caudally, its attenuated caudal pole is replaced by the pulvinar. It is indistinctly marked off by fiber bands but its boundaries can be seen without difficulty.

The cells of pars dorsalis pulvinaris are similar to those of pars lateralis pulvinaris except that they appear to be less deeply stained. They are arranged roughly along horizontally running fibers and are triangular and fusiform in shape. They have a coarsely granular, well impregnated cytoplasm; the nucleus has a definite chromatin network, and a well defined, centrally placed nucleolus. Throughout its rostro-caudal extent, the cells of pars dorsalis pulvinaris are irregularly blended with those of pars lateralis pulvinaris.

Area pretectalis (figs. 9, 10). The rostral limits of this region begin at the level of the habenular commissure. The area is small in extent rostrally but rapidly expands caudally into a zone of considerable proportions. Its rostral extremity is limited in front by portio dorsalis of pars posterior of nucleus lateralis, dorsally by stratum zonale, and laterally by the nucleus of the optic tract. Ventral to it lies the posterior commissure with its nucleus. Throughout the rest of its extent it is bounded laterally by the nucleus of the optic tract assisted by pars medialis of nucleus lateralis pars posterior for a short distance and then by the pulvinar. The midbrain is ventral to it. Toward its caudal extremity, area pretectalis diminishes in size and ends by becoming continuous with the gray of the superior colliculus.

The cells of area pretectalis do not have any particular pattern of arrangement, although in some sections there is a suggestion that they are disposed along fibers radiating out from the midline. They are predominantly triangular in form with some fusiform and an occasional polygonal cell among them. The cytoplasm stains exceedingly faintly and is finely granular. The chromatin network of the nucleus is colored very faintly but a definite structure can be made out. The

outline of the nucleus is not discernible in many cells but in others is easily seen. The nucleolus is dark and centrally placed.

Nucleus suprageniculatus (fig. 10). This area is an indefinite cellular mass which first appears at the level of the habenular commissure. It is formed by compression of portions of both portio medialis and portio ventralis of nucleus lateralis pars posterior by the expanding pulvinar and the rostral pole of nucleus geniculatus medialis. Its rostrocaudal extent is very short and it ends by fusing with the overlying pulvinar. Throughout its limited extent it is bounded laterally by nucleus geniculatus lateralis dorsalis; and ventrally by nucleus geniculatus medialis, with which it is blended. On the dorsal aspect lies the pulvinar and on the medial side structures of the midbrain.

The cells resemble those of the nuclei from which nucleus suprageniculatus originated. They have no particular arrangement and are a mixture of polygonal, triangular, and bipolar types; the majority of them are lightly stained. The cytoplasm is finely granular. The reticulum of the nucleus is extremely delicate but the nucleolus is quite apparent and centrally placed.

Nucleus reticularis (figs. 2, 3, 4, 5, 6, 7, 8). Nucleus reticularis forms an irregular arc about the rest of the thalamus. Medially it is bounded by the external medullary lamina, which separates it rostrally from the anterior and ventral nuclear groups and more caudally from the lateral and ventral nuclear groups. Laterally it is bounded by the internal capsule and rostrally, near its dorsal tip, by stria terminalis, which separates it from the caudate nucleus. The rostral pole is on a level with the anterior part of the optic chiasma and, in this situation, the nucleus consists of a band of loosely arranged, medium-sized cells, which show some tendency to be disposed in an outer and an inner zone. The dorsal tip of the nucleus extends toward the ventricle but hardly reaches the stratum zonale of the ventricular floor. Ventrally, nu-

cleus reticularis blends with zona incerta, the point of union being easily distinguishable. Followed caudally, nucleus reticularis, due to the rapid increase in the size of the thalamus, is displaced laterally and ventrally. The more ventral portion of the nucleus becomes crowded into the angle between the cerebral peduncle and the optic tract where it ends by mingling with nucleus geniculatus lateralis ventralis.

On a basis of cell type and arrangement, nucleus reticularis can be divided into a ventral and a dorsal segment. The cells of the ventral segment are polygonal in shape and have several long, branching processes, in which the cytoplasm remains unstained. The cytoplasm of the cell body stains deeply and is coarsely granular. The nucleus is placed closer to one end of the cell so that all the cytoplasm is collected at the opposite end. There is a definite nuclear reticulum and a single, centrally situated, dark nucleolus.

The cells of the dorsal segment are much less numerous than those of the ventral segment and are very light in color. Caudally, the cells of this segment are very sparse and irregularly placed. Otherwise there are no essential differences. The ventral segment ends at the level of the rostral limit of the posterior commissure but the dorsal segment disappears farther rostrally, just as the optic fibers are about to enter nucleus geniculatus lateralis dorsalis.

In the dog, Rioch ('29) divided the pulvinar into a lateral superior part, a lateral inferior part and a medial part. He also described a nucleus posterior. Ingram, Hannett, and Ranson ('32), studying the cat, recognized a pulvinar pars posterior and a nucleus posterior. Their nucleus posterior corresponds to pars inferior of other workers and pars geniculata of Rose ('42). Crouch ('34) was able to distinguish three components of the pulvinar in the macaque: pars medialis, pars lateralis, and pars inferior. The pars medialis, which he subdivided into pars superior, pars intermedia, and pars inferior, comprises three-quarters or more of the pulvinar. Pars lateralis he divided into pars superior and pars inferior as did Rioch in the dog and Krieg, later, in the

macaque. His portio inferior corresponds to that of other workers. Aronson and Papez ('34), working on the diencephalon of *Pithecus rhesus*, identified 4 parts of the pulvinar, which they numbered 1, 2, 3, 4. Pulvinar 1 of their description lies most laterally and ventrally. It is homologous with nucleus posterior in the dog and the cat. Pulvinar 2, according to these authors, corresponds to the area labelled pulvinar by Rioch in the dog and by Ingram, Hannett, and Ranson ('32) in the cat. Pulvinar 3 homologizes with pulvinar posterior in the dog and in the cat. Pulvinar 4 lies too far medially to be homologous with any part of pulvinar in Rioch's description but appears to correspond to nucleus lateralis pars posterior (portio dorsalis) in the dog. Walker ('38a) in the macaque and ('38b) in the chimpanzee and Soltitzky ('38) in *Sus scrofa* recognized three parts of the pulvinar — a lateral, a medial, and an inferior. In the Virginia opossum, Bodian ('39) identified no pulvinar and no nucleus posterior. Ibrahim and Shanklin ('41) were able to divide the pulvinar of the coney into three component parts — pars principalis, pulvinar posterior, and pulvinar pars inferior with a nucleus posterior. Rose ('42) thought that the pulvinar in the sheep was divisible into only two parts, a pulvinar proper and a pars geniculata. The latter corresponds to pars inferior of other workers. Rose was unable to make any subdivision of his pulvinar proper. Sheps ('45) and Toncray and Krieg ('46), in their description of human material, divided the pulvinar into medial, lateral, and inferior portions. Krieg ('48), in his study of macaque diencephalon, again identified three regions in the pulvinar — medial, lateral, and dorsal portions.

Metathalamus

Nucleus geniculatus medialis (figs. 8, 9, 10). The rostral pole of this nucleus begins at the level of the cephalic border of the mammillary bodies and at the extreme caudal tip of pars externa of nucleus ventralis. It is bounded dorsomedially by a narrow band made up of the last few cells of pars

externa of nucleus ventralis, which merge with it. Ventrolaterally it lies against the external capsule, which separates it from nucleus reticularis and zona incerta. Slightly more caudally, pars arcuata of nucleus ventralis forms a dorso-medial relationship. Still farther caudally portio ventralis of pars posterior of nucleus lateralis is placed dorsomedially for a short distance; at this level nucleus geniculatus lateralis dorsalis has appeared on its lateral aspect with the external capsule intervening. Nucleus geniculatus medialis now expands rapidly resulting in the formation of nucleus suprageniculatus, with which it is intermingled and which is related to it dorsally. More caudally, the pulvinar succeeds nucleus suprageniculatus in this position. Medially and ventrally the medial geniculate nucleus is adjacent to the structures of the midbrain. Meanwhile nucleus geniculatus lateralis dorsalis has expanded in size, lying lateral to nucleus geniculatus medialis throughout most of the rest of its extent but separated from this latter nucleus by its own fibrous capsule. Nucleus geniculatus medialis continues to expand in a ventrolateral direction finally reaching the external surface on the ventrolateral aspect of the midbrain. At the caudal end of nucleus geniculatus lateralis dorsalis, nucleus geniculatus medialis lies between the superior and the inferior brachia.

Nucleus geniculatus medialis of the mink is divisible into three parts: pars compacta, pars principalis, and pars magnocellularis. The rostral pole of the nucleus is formed by pars compacta, which is mingled here with pars externa of nucleus ventralis. A short distance farther caudally, pars compacta extends downward and laterad to bring it into relationship with zona incerta and nucleus geniculatus lateralis ventralis. Pars compacta finally comes to the surface on the lateral aspect of the brain stem. Pars magnocellularis consists of a group of larger, darkly stained cells lying along the ventromedial border of nucleus geniculatus medialis and surrounded on three sides by the cells of pars compacta. Although pars principalis constitutes the larger part of the nucleus, it does

not extend so far caudally, the caudal pole of the nucleus being formed by pars compacta.

Rostrally, nucleus geniculatus medialis is bounded dorso-medially by pars externa and then by pars arcuata of nucleus ventralis. Ventrolaterally, it is next to zona incerta and nucleus reticularis, from which it is separated by fibers of the external medullary lamina. Farther caudally, the dorsomedial boundary is formed, for a short distance, by portio ventralis of pars posterior of nucleus lateralis, then by nucleus supra-geniculatus. On the lateral side is the rostral pole of the nucleus geniculatus lateralis dorsalis and on the medial side the structures of the midbrain. Still farther caudally, the pulvinar is dorsal to it. Nucleus geniculatus lateralis dorsalis lies lateral to it throughout its extent *but* separated from it by a fiber layer. The nucleus finally reaches the lateral surface of the brain stem between the cerebral peduncle and the optic tract. It ends at approximately the posterior border of the superior colliculus.

The cells of pars magnocellularis are larger than those of pars compacta, which almost surround them. They are polygonal in shape with several branching, filamentous processes. The cytoplasm stains darkly and is coarsely granular. The nucleus is large, almost completely filling the cell. It has a coarse chromatin network and a centrally placed nucleolus. The cells of pars compacta are smaller, rather numerous, dark in color, and rounded or polygonal in shape and possess several slender processes. Those cells around the periphery are fusiform, apparently due to pressure exerted upon them by the fibers of the capsule surrounding the nucleus among which they lie. The staining characteristics are very similar to those of the cells of pars magnocellularis but the nucleolus is eccentrically placed.

The cells of pars principalis are considerably fewer in number and seem to be arranged along horizontally and diagonally running fibers. They are polygonal, triangular, or fusiform in outline and stain less deeply than those of the other two parts. The cell processes are long, filamentous, and

branching. The cytoplasm stains moderately well and is coarsely granular. The nucleus is relatively large and very nearly fills the cell. The nuclear reticulum is easily discernible and the single dark nucleolus is eccentrically placed in many, though not in all, cells.

Nucleus geniculatus lateralis dorsalis (figs. 8, 9, 10). In material sectioned in a coronal plane, nucleus geniculatus lateralis dorsalis first appears at the level of the caudal end of nucleus limitans in the dorsalateral corner and in the ventrolateral angle of the thalamus. Traced caudally, these two areas fuse at about the level of the caudal end of the pulvinar to form a large mass. This mass lies on the lateral aspect of the pulvinar, the nucleus suprageniculatus, and the nucleus geniculatus medialis. Laterally, it is related to the fibers of the optic tract. Nucleus geniculatus lateralis dorsalis rapidly attains its maximum size and then becomes progressively smaller as it is followed caudally. It is separated from nucleus geniculatus medialis by a fibrous capsule. Its caudal tip lies a short distance rostral to the caudal end of nucleus geniculatus medialis and about equidistant between the rostral and caudal poles of the gray of the superior colliculus.

From about the level of the caudal end of the pulvinar, nucleus geniculatus lateralis dorsalis is semi-discoid in shape, the convexity facing laterally. The left nucleus, as viewed from behind, is roughly C-shaped. It is composed of 4 laminae each forming an incomplete ring and each with a gap on the medial side forming a hilum. The rings or laminae fit one inside the other but are separated from each other by fiber layers for some distance from the hilum. Traced caudally, the diameter of each ring becomes progressively less and the hilar aperture becomes gradually smaller as each section is taken closer to the periphery of the ring.

As material sectioned in the sagittal plane was not available, a paper model of the nucleus was constructed so that it could be visualized in three dimensions. By this means it was seen that nucleus geniculatus lateralis dorsalis is C-shaped in the sagittal plane also, i.e. if the right nucleus is

viewed from its lateral aspect; or reverse C-shaped if the left nucleus is viewed from its lateral aspect. Its greatest diameter is the dorsoventral one, the anteroposterior and side to side measurements being much less.

The most superficial and posterior layer is designated lamina posteroexterna and the deepest and most anterior layer is lamina anterointerna. The two laminae which lie between them are called lamina intermediomedialis and lamina intermediolateralis, their names indicating their relative positions.

The cells of each of the 4 laminae are more densely grouped on the lateral side than on the medial side. Lamina postexterna is composed of cells which tend to be small in size and somewhat elongated due to pressure by surrounding fibers. Their staining reaction is variable, some cells being very light while others are darker. The nucleus is filled with a fine reticulum and the nucleolus is intensely colored, very small, and centrally placed. The cells of lamina intermediolateralis are rather large and of variable shape. The cytoplasm is dark and blotchy and the nucleus contains a heavy chromatin network. The nucleolus is intensely stained and centrally placed. Lamina intermediomedialis is made up of cells of assorted sizes and shapes but small cells appear to predominate. The cytoplasm is dark and blotchy and the nucleus approximates it so closely in color that it is difficult to see the outline of it. The nucleolus is small and of dark hue. The cells of lamina anterointerna are of moderate size, polygonal in shape, and well impregnated. Here too, the nucleus is also deeply stained so that its outline is indefinite. The nucleolus is dark and centrally placed.

Nucleus geniculatus lateralis ventralis (figs. 9, 10). This nucleus is placed somewhat farther rostrally than nucleus geniculatus lateralis dorsalis. It lies dorsomedial to the optic tract and ventrolateral to the ventral segment of nucleus reticularis. It will be discussed in more detail with the description of the subthalamus.

Rioch ('29) divided the nucleus geniculatus medialis of the dog into a pars magnocellularis and a pars principalis. LeGros Clark ('32) identified three parts in the nucleus, a dorso-lateral, a caudoventral and an intervening small-celled portion said to be derived from the ventral nucleus. He regarded the dorsolateral element as probably a caudal extension of nucleus suprageniculatus and the caudoventral component as apparently the functional equivalent of nucleus geniculatus lateralis ventralis. Aronson and Papez ('34) in *Pithecus rhesus* recognized a large lateral parvocellular (principalis) portion apparently homologous with Rioch's pars principalis and a small, medially placed magnocellular portion corresponding in part to Rioch's pars magnocellularis. Ibrahim and Shanklin ('41), in the coney, described the nucleus as composed of a pars superior, a pars lateralis and a pars medialis. In man, Toncray and Krieg ('46) made a similar division of the nucleus, that is, divided it into a large-celled medial part with a greater cross-sectional area than the small-celled lateral element. Krieg ('48), studying macaque, agreed with other workers in describing a larger, lateral pars parvocellularis and a smaller, medial pars magnocellularis.

In many mammals, nucleus geniculatus lateralis consists of a dorsal and a ventral component, the dorsal entity extending farther caudally than the ventral one. Nucleus geniculatus lateralis dorsalis becomes progressively elaborated, in the phyletic scale, although nucleus geniculatus lateralis ventralis diminishes in size, until, in higher primates, it disappears, except for a possible vestige. In lower mammals, as described by Papez ('32) and Solnitzky ('38), nucleus geniculatus lateralis dorsalis is a relatively small and undifferentiated structure, but in carnivores, Thuma ('28) and Rioch ('29) identified 4 laminae. In primates, Aronson and Papez ('34) LeGros Clark ('41), Solnitzky and Harman ('43) and Harman and Solnitzky ('44) identified 6 layers in the nucleus. Toncray and Krieg ('46) and Krieg ('48) found the same number in man.

SUMMARY

In general, the nuclear pattern of the dorsal thalamus of the mink is the same as that of other mammals. However, there are certain differences in structure which suggest that the mink is one of the most highly organized carnivores.

The anterior nuclear group of the thalamus in the mink tends to approximate the pattern found in more highly organized mammals. As was pointed out in the description of this nuclear group, there is poor definition between nucleus anteroventralis and nucleus anteromedialis. The same is true in the macaque according to Walker ('38a), Larsell ('42), and Toncray and Krieg ('46). Similar observations with regard to this nuclear group in man were made by Foix and Nicolesco ('25), Grünthal ('34), and Sheps ('45).

There are no significant departures from the arrangement found in other forms in the case of the midline group of nuclei.

Nucleus dorsomedialis in the mink corresponds to the nucleus of that name described by Rioch ('20) in the dog. The peripheral band of darkly stained cells noted by other workers is present; some cells are distinctly within the nucleus proper, others lie among the fibers of the internal lamina. This band is not designated as a third part of the dorsomedial nucleus in the mink although, as pointed out by Walker ('38a), its component cells belong to that nuclear group. There is only a short commissural connection between the nuclei of the two sides in contrast to the almost complete fusion across the midline of nuclei dorsomediales in the macaque, as described by Aronson and Papez ('34).

Although both nucleus submedius and pars medialis of nucleus ventralis are present and easily identified in the mink, there is considerable blending of the two masses. This may presage a more complete fusion as Sheps ('45) and Toncray and Krieg ('46) have described in man. There is a primordium nucleus centrum medianum of lesser rostrocaudal extent than its counterpart in the dog and cat.

The ventral nuclear group in the mink corresponds to that which has been found in other forms.

In the lateral nuclear group the pulvinar requires special mention. The pulvinar of the mink corresponds closely to that of the macaque as described by Krieg ('48). He recognized a pars inferior (pars geniculata of other workers) but felt that it rightfully belongs to pars medialis. No such extension of the pulvinar can be found in the mink. The pars medialis of the mink makes up the caudal pole of the pulvinar as it does in the macaque. Like Rioch ('29), Krieg ('48) subdivided his pars lateralis into superior and inferior portions; such a subdivision is not possible in the mink. In his pars dorsalis Krieg was able to distinguish three strata which are not evident in the mink. It is more difficult to compare our results with the account of the pulvinar of the macaque given by Aronson and Papez ('34). Their pulvinar 1 would appear to correspond to the caudal end of pars medialis of the pulvinar of the mink. Pulvinar 2 of their division would seem to include the rostral portion of pars lateralis and perhaps pars dorsalis of the pulvinar in the mink. Pulvinar 3 and the caudal end of pulvinar 2 homologize with pars medialis of the pulvinar in mink except for its caudal end, which forms the caudal pole of the pulvinar and which, as stated above, corresponds to pulvinar 1. There is no part of the pulvinar in the mink (or the dog) which is homologous with the more medially situated pulvinar 4 of the macaque. Rioch's lateral superior portion of pulvinar in the dog occupies the same position as pars dorsalis of pulvinar in the mink. The pulvinar in the mink is similar to that of more specialized forms.

Pars magnocellularis of nucleus geniculatus medialis in the mink resembles its homologue in other forms but appears to be somewhat smaller. Pars compacta may be a result of compression of the cells of pars principalis between the cerebral peduncle and the nucleus geniculatus lateralis dorsalis

and may not be a true third part of nucleus geniculatus medialis.

It seems preferable to name the laminae of nucleus geniculatus lateralis dorsalis in the mink according to their position rather than their cell type. On this basis, lamina postero-externa in the mink corresponds to lamina parvocellularis of Rioch ('29) in the dog. Lamina intermediolateralis of the mink is homologous with pars magnocellularis of the dog. Lamina intermediomedialis and lamina anterointerna of the mink homologize with lamina principalis posterior and lamina principalis anterior of Rioch, respectively.

LITERATURE CITED

- ARIËNS KAPPERS, C. U., G. C. HUBER AND E. C. CROSBY 1936 The comparative anatomy of the nervous system of vertebrates, including man. The MacMillan Co., New York. 2 vols.
- ARONSON, L. R., AND J. W. PAPEZ 1934 The thalamic nuclei of *Pithecus* (*Macacus*) rhesus. *Arch. Neur. Psychiat.*, *32*: 27-44.
- BODIAN, D. 1939 Studies on the diencephalon of the Virginia opossum. I. The nuclear pattern in the adult. *J. Comp. Neur.*, *17*: 224-231.
- 1940 Studies on the diencephalon of the Virginia opossum. II. Fiber connections in normal and experimental material. *J. Comp. Neur.*, *72*: 207-297.
- 1942 Studies on the diencephalon of the Virginia opossum. III. Thalamo-cortical projection. *J. Comp. Neur.*, *77*: 525-575.
- CLARK, W. E. LEGROS 1930 The thalamus of *Tarsius*. *J. Anat.*, *64*: 371-414.
- 1931 The brain of *Microcebus murinus*. *Proc. Zool. Soc. London*, pt. 1: 463-486.
- 1932 The structure and connections of the thalamus. *Brain*, *55*: 406-470.
- 1936 Functional localization in the thalamus and hypothalamus. *J. Ment. Sci.*, *32*: 99-118.
- 1941 The lateral geniculate body in platyrrhine monkeys. *J. Anat.*, *76*: 131-140.
- CROUCH, R. L. 1934 The nuclear configuration of the thalamus of macacus rhesus. *J. Comp. Neur.*, *59*: 451-484.
- FOIX, C., ET J. NICOLESCO 1925 Anatomie cérébrale; les nouveaux gris centraux et la région mésencéphalo-sous-optique. Masson et Cie, Paris.
- FRIEDMANN, M. 1912 Die Cytoarchitektonik des Zwischenhirns der Cercopitheken mit besonderer Berücksichtigung des Thalamus opticus. *J. f. Psychol. u. Neur.*, *18*: 309-378.
- GRÜNTAL, E. 1934 Der Zellbau im Thalamus der Säuger und des Menschen. *J. f. Psychol. u. Neur.*, *46*: 41-112.

- GURDJIAN, E. S. 1927 The diencephalon of the albino rat. Studies on the brain of the rat. *J. Comp. Neur.*, *43*: 1-114.
- HARMAN, P. S., AND O. SOLNITZKY 1944 The lateral geniculate complex of the platyrrhine monkey, *Cebus fatuellus*. *J. Comp. Neur.*, *81*: 227-247.
- IBRAHIM, M., AND W. M. SHANKLIN 1941 The diencephalon of the coney, *Hyrax syriaca*. *J. Comp. Neur.*, *75*: 427-485.
- INGRAM, W. R., F. I. HANNETT AND S. W. RANSON 1932 The topography of the nuclei of the diencephalon of the cat. *J. Comp. Neur.*, *55*: 333-394.
- KRIEG, W. J. S. 1944 The medial region of the thalamus of the albino rat. *J. Comp. Neur.*, *80*: 381-415.
- 1948 A reconstruction of the diencephalic nuclei of *Macacus rhesus*. *J. Comp. Neur.*, *88*: 1-51.
- LARSELL, O. 1942 Anatomy of the nervous system. D. Appleton Century Company, New York. 237-247.
- VON MONAKOW, C. 1895 Experimentelle und pathologisch-anatomische Untersuchungen über die Haubenregion, den Sehhügel und die Regio subthalamica nebst Beiträgen zur Kenntnis früh erworbener. Gross- und Kleinhirndefects. *Arch. f. Psychiat.*, *27*: 1-128, 386-478.
- NISSL, F. 1889 Die Kerne des Thalamus beim Kaninchen. *Tageblatt der 62. Versammlung deutscher Naturforscher und Ärzte in Heidelberg*. 18.
- PAPEZ, W. J. 1932 The thalamic nuclei of the nine banded armadillo (*Tatusia novemcincta*). *J. Comp. Neur.*, *56*: 49-103.
- RIOCH, D. MCK. 1929 Studies on the diencephalon of carnivora. I. The nuclear configuration of the thalamus, epithalamus and hypothalamus of the dog and cat. *J. Comp. Neur.*, *49*: 1-119.
- 1931 A note on the center median nucleus of Luys. *J. Anat.*, *65*: 324-327.
- ROSE, J. E. 1942 The thalamus of the sheep; cellular and fibrous structure and comparison with pig, rabbit and cat. *J. Comp. Neur.*, *77*: 469-523.
- SACHS, E. 1909a Eine vergleichende anatomische Studie des Thalamus opticus der Säugetiere. *Arb. a. d. Neur. Inst. a. d. Wiener Univ.*, *17*: 280-306.
- 1909b On the structure and functional relations of the optic thalamus. *Brain*, *32*: 95-186.
- SHEPS, J. G. 1945 The nuclear configuration and cortical connections of the human thalamus. *J. Comp. Neur.*, *83*: 1-56.
- SOLNITZKY, O. 1938 The thalamic nuclei of *Sus scrofa*. *J. Comp. Neur.*, *69*: 121-169.
- SOLNITZKY, O., AND P. J. HARMAN 1943 The lateral geniculate complex in the spider monkey, *Ateles ater*. *Yale J. Biol. and Med.*, *15*: 615-639.
- THUMA, B. D. 1928 Studies on the diencephalon of the cat. I. The cytoarchitecture of the corpus geniculatum laterale. *J. Comp. Neur.*, *46*: 173-199.
- TONCRAV, J. E., AND W. J. S. KRIEG 1946 The nuclei of the human thalamus; a comparative approach. *J. Comp. Neur.*, *85*: 421-460.
- VOGT, C. 1909 La myeloarchitecture du thalamus du cercopithèque. *J. f. Psychol. u. Neur.*, *12*: 285-324.

- VOGT, C., AND O. VOGT 1941 Thalamusstudien I-III. *J. f. Psychol. u. Neur.*, 50: 32-152.
- WALKER, A. E. 1937a The thalamus in relation to the cerebral cortex. *J. Nerv. and Ment. Dis.*, 85: 249-261.
- 1937b Note on thalamic nuclei of macaca mulatta. *J. Comp. Neur.*, 66: 145-155.
- 1938a The primate thalamus. Univ. of Chicago Press, Chicago. 321 pp.
- 1938b The thalamus of the chimpanzee. II. Its nuclear structure, normal and following hemidecortication. *J. Comp. Neur.*, 69: 487-507.
- 1940 The medial thalamic nucleus. A comparative anatomical, physiological and clinical study of the nucleus medialis dorsalis thalami. *J. Comp. Neur.*, 73: 87-115.
- WINKLER, C., AND A. POTTER 1911 An anatomical guide to experimental researches on the rabbit's brain. Amsterdam, W. Versluys.
- 1914 An anatomical guide to experimental researches on the cat's brain. Amsterdam, W. Versluys.