

THE PARIETAL LOBE AS AN ADDITIONAL MOTOR AREA

THE MOTOR EFFECTS OF ELECTRICAL STIMULATION AND ABLATION
OF CORTICAL AREAS 5 AND 7 IN MONKEYS

J. F. ROSS FLEMING AND ELIZABETH C. CROSBY

*Department of Surgery, Section of Neurosurgery and Laboratory of Comparative
Neurology, Department of Anatomy, University of Michigan, Ann Arbor*

NINE FIGURES

Patients having destructive lesions of the precentral motor cortex (area 4) due to tumor, degenerative processes, or surgical excision always retain a considerable amount of useful movement of the contralateral extremities. However, the ability to perform delicate and fine movements is lost when the precentral motor cortex is destroyed, the remaining movements being more gross and usually confined to the more proximal portions of the extremities. The cerebral origin of such movements may be the remaining cortex of the contralateral or ipsilateral hemisphere or perhaps may be subcortical.

In recent years, several additional, second, or supplementary motor areas have been described or re-discovered in higher mammals including man; these represent cortical areas other than the precentral gyrus from which movements of either the opposite or the ipsilateral extremities, or both, may be obtained by electrical stimulation. In addition to their synergistic action in producing movements from an intact hemisphere, it is possible that these second motor areas take over to some extent the motor functions when the precentral motor cortex is destroyed. Such considerations prompted the present investigation into the possible motor functions of that part of the parietal lobe behind the postcentral gyrus (areas

5 and 7) which is usually considered as purely associative in function.

The detailed pattern of motor responses to electrical stimulation of the precentral and postcentral gyri and of the premotor area (area 6) has been extensively mapped out for man and lower primates by numerous investigators, prominent amongst whom are Foerster and Penfield and their associates. From the medial surface of the primate cerebral hemisphere anterior to the precentral gyrus, complex movements of the opposite arm and leg, head, eyes, and trunk have been elicited by Horsley and Schaefer (1888), C. and O. Vogt ('26), Penfield and his collaborators ('49, '50, '51, '54), Woolsey and Settlage ('50), Woolsey et al. ('50, '52), and Erickson and Woolsey ('51). To this area the name supplementary motor area has been given by Penfield and Welch. From the superior temporal gyrus in both man and monkeys, movements of the limbs, trunk, head, and eyes were obtained by Ferrier (1876), Horsley and Schaefer (1888), C. and O. Vogt ('26), Foerster ('36a and b), and Lemmen ('51). Similar movements have been obtained from the region of the temporal pole in monkeys by Schneider and Crosby ('54), from the lower half of the insula in monkeys by Frontera, from the opercular cortex and upper insular cortex in monkeys by Sugar, Chusid and French ('48), and from the occipital area 19 in both man and monkeys by Ferrier (1876), Horsley and Schaefer (1888), C. and O. Vogt ('26), Foerster ('36a and b), and Lemmen ('51). Ipsilateral face movements were obtained in monkeys from just below the face area of the precentral gyrus by Lauer ('52). Movements of the eyes have been obtained from areas of the frontal lobe by Foerster ('36b), Crosby et al. ('48 and '52), Crosby ('54), Penfield et al. ('54), and many others, and from the posterior parietal and occipital regions (areas 17-18 and 19) by Foerster ('36b), Crosby and Henderson ('48), Henderson and Crosby ('52), Crosby ('54), and various other observers.

The parietal regions (areas 5 and 7) have been extensively studied in man and other primates by electrical stimulation with considerable variation in the findings. Bartholow in 1874 was possibly the first investigator to elicit mass movements of the contralateral extremities by electrical stimulation of the parietal region in man. Ferrier (1876) reported in detail a pattern of movements and maneuvers in monkeys on stimulating area 5 and movements of the eyes on stimulating area 7. Beevor and Horsley (1888) mapped out a pattern of movements of the contralateral extremities and face in monkeys on stimulating the posterior parietal area. However, in 1890, Beevor and Horsley reported that stimulation of the posterior parietal region of an orang-outang yielded no movement. Flechsig (1896) regarded the parietal lobe as electrically inexcitable. In 1917 Leyton and Sherrington, stimulating the cortex of the chimpanzee, reported only echo responses from the posterior parietal area. The Vogts in 1926 elicited many movements of the contralateral extremities in man and monkeys on stimulation of area 5, and movements of the eyes from area 7. Foerster ('31, '36a and b), stimulating area 5 in man, reported complex movements of the opposite extremities and ipsilateral arm, and from area 7 elicited eye movements and rotation of the head. Dusser de Barenne et al. ('41a and b) reported movements of the contralateral arm by facilitation only, when stimulating areas 5 and 7 in the chimpanzee. Peele ('44) reported movements of the opposite arm and shoulder when stimulating areas 5 and 7 in monkeys. Moffie ('49) stated that movements arising from the parietal areas could not be elicited after the precentral cortex was removed.

In this study we have attempted to confirm the fact that movements may arise from the posterior and superior parietal cortex, and to determine whether or not these movements depend upon an intact motor cortex. In attempts to assess the significance of these movements, we have made various cortical ablations and studied the clinical effects of these in the monkeys. The extent and location of each lesion has been

confirmed by postmortem studies. Although degeneration studies have been carried out in order to trace the efferent pathways from the parietal lobe, these are not complete and will not be included in the present publication.

MATERIAL AND METHODS

These experiments were done on monkeys (*Macaca mulatta* and *Macaca cynomolgus*). Altogether 8 monkeys were used and 19 operations were performed. Preoperative and postoperative testing was carried out every day or two, as adequately as possible using untrained monkeys. The general condition of the monkey was noted and the temperature, pulse, and respiratory rates taken. Neurological examination included observation of the monkey in the cage when climbing, eating, and being chased. The pupillary size and reactions, eye movements, and presence or absence of facial weakness were noted. The power in each limb was estimated by the strength of grasp and by the ability to use that limb in climbing and other activities. The tonus of each limb was noted, as were the deep tendon, plantar, and Hoffmann reflexes. The sensory examination was limited to an assessment of the placing, hopping, and grasp reflexes when the monkey was blindfolded.

The operations were done under ether anesthesia. No premedication was used and, during the cortical stimulation, the plane of anesthesia was kept as light as possible. The ability to elicit movements by stimulation was directly proportional to the lightness of anesthesia. The monkey's head was shaved and prepared with alcohol and zephiran and the monkey placed on a specially prepared plastic frame (seen in figs. 3 and 5). This frame permitted unobscured vision of all parts of the monkey and enabled moving pictures to be taken of the evoked movements. Transparent plastic draping was used to insure a sterile field and yet allow observation of the eyes, face, and head through the drape. The desired portion of cortex was exposed by turning a suitable scalp flap, making a trephine opening through the skull, enlarging the

lesion as necessary, and opening the dura by a flap or by cruciate incisions. At the termination of each experiment, careful closure of the dura, pericranial tissues, and scalp was effected.

Stimulation was done using the Grass stimulator¹ (model 3 C). When a monopolar electrode was used, the ground lead was placed in the rectum. For bipolar stimulation, a silver electrode was utilized with the points between 1.5 and 2 mm apart. Alternating current was employed, with a pulse duration of 1 msec., pulse delay of 1 msec., and a variable frequency, usually 40 cycles per second. The voltage was varied from 4 to 14. An interval of one to two minutes was maintained between individual stimulations in order to avoid facilitation. The duration of stimulus was about one to two seconds. As the cortex was never exposed for over an hour and a half, no special attempt was made to moisten it or to keep it warm.

Records of the movements obtained were made by an observer who noted the precise point of stimulation on a previously prepared map of the cortex, along with the parameters of stimulation and the actual movements elicited. Moving pictures were taken of many of the responses for subsequent analysis.

In certain cases, various cortical areas were ablated by making an encircling pial incision and removing the cortex by suction. Great care was taken not to remove the underlying white matter and to destroy as much of the cortex as possible within any sulci in the area. Bleeding was controlled by the use of gelfoam and by ligation of vessels as needed.

Postmortem studies were made following perfusing of the vascular system of the anesthetized animal with formalin and then removing the brain. Degeneration material was prepared by the Marchi technique, using brains in which the cortical excision had been made 14 days previously.

¹ Made by the Grass Instrument Co., Quincy, Massachusetts.

*Factors influencing cortical activity and
motor response*

The most important variable is the *depth of anesthesia*. Several investigators using barbiturate anesthesia reported that they were unable to obtain any motor responses when stimulating the parietal area. With deep ether anesthesia we were often unable to obtain movements at all, or only with very high voltages. However, as the animal approached consciousness, just before voluntary movements appeared, excellent movements could be obtained using fairly low voltages. This was especially true of the eye movements obtained from area 7, particularly conjugate deviation obliquely upwards to the other side, which could only be elicited when the anesthesia was very light. The use of *premedication* similarly depresses cortical activity, and one monkey, to whom 3 mg of morphine had been given preoperatively, exhibited virtually no motor responses to parietal stimulation.

The general condition of the monkey also greatly influenced the activity of the parietal cortex. Thus, if the monkey were showing some signs of hypoxia, or if the operation had been unduly lengthy, responses were difficult to obtain and high voltages were required. With fresh, healthy, and well oxygenated animals, however, it was very easy to elicit movements.

The question of spread of electrical stimuli to the underlying white matter and adjacent cortex is of considerable importance. Using the bipolar electrode and low voltages, fairly discrete movements were obtained consistently from individual points on the cortex. When higher voltages were used, and especially with a monopolar electrode, there was some evidence of spread manifested by much more gross movements involving sometimes all four extremities, trunk, and head. Consequently a bipolar electrode was employed in most of the experiments, with the lowest voltages which would give distinct but discrete movements (i.e. slightly higher than threshold voltages).

The *frequency* of the current used was usually 40 cycles per second. In a few cases raising the frequency to 100 cycles per second or more enabled us to obtain movements from a less excitable cortex.

It is fairly certain that *facilitation* was not a factor in obtaining movements. As soon as the dura was opened, a minimal stimulus was applied to various parts of the parietal area being tested, without having first obtained movements from the precentral or postcentral gyri. *Reversal* and *deviation* from the usual response were seen fairly often. The *initial position of the limb*, prior to stimulation, is of interest. Hyde and Gellhorn ('51) and Ward ('52) both stressed this point in relation to the motor cortex, stating that the ultimate function of a given cortical point is to move a limb into a constant final position. Thus if a limb is already in a final position, stimulation of the corresponding cortical point is ineffectual; or, depending on the initial position of the limb, stimulation may produce either a flexion or an extension type of response. In our experiments the initial position was always constant, the limbs of the anesthetized animal being flaccid and hanging down in a neutral position from the suspending frame above. If, however, the anesthetic became too light and voluntary movements appeared, stimulation was withheld until the limbs became lax again.

EXPERIMENTS

Before going on to present the overall results of our experiments, we shall give in detail the protocols of three typical monkeys.

Monkey no. F-4

This was a small female *Cynomolgus*, who appeared healthy, alert, and aggressive. Several neurological examinations done preoperatively were normal. On March 2, 1954, a left fronto-parietal craniotomy was performed, dura was reflected and cortex stimulated. Moving pictures were taken of the resulting movements. The positive results of stimulation of several cortical points, as noted in figure 1, are given below. Points giving similar movement have been

grouped together. Following stimulation, a small cortical lesion was made in area 5 by suction, as outlined in figure 1.

1. Monopolar electrode, 4 volts. Conjugate deviation of eyes upward. At 6 volts some neck extension and turning of head to right.
14. Monopolar electrode, 7 volts. Conjugate deviation of eyes to right.
19. Monopolar electrode, 7 volts. Conjugate deviation of eyes obliquely downward toward other side.

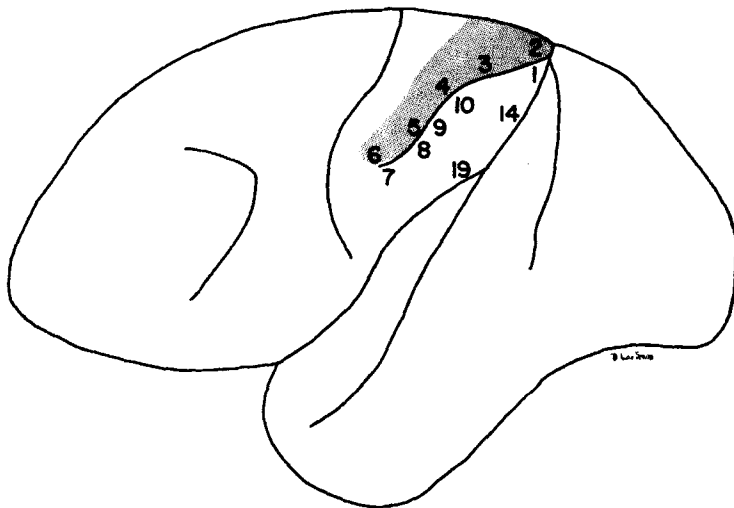


Fig. 1 Sketch of surface of left hemisphere of monkey F-4. The numbers refer to points stimulated as described in the text. The shaded area shows the extent of cortical ablation.

2. Monopolar electrode, 4 volts. Flexion of right hip, slight retraction of left shoulder, and extension of left elbow. At 5 volts, extension of right leg and arm and flexion of left leg and arm.
3. Monopolar electrode, 5 volts. Abduction and flexion of right arm at shoulder and elbow, slight extension of left arm, and slight flexion of right leg.
4. Monopolar electrode, 5 volts. Flexion at right elbow and slight extension of left arm.
5. Monopolar electrode, 5 volts. Flexion at right elbow.
6. Monopolar electrode, 5 volts. Retraction of right corner of mouth and slight flexion at right elbow.

7. Monopolar electrode, 5 volts. Extension of neck and retraction of right corner of mouth, with slight extension at both shoulders.
8. Monopolar electrode, 5 volts. Extension of neck and both shoulders.
9. Monopolar electrode, 6 volts. Extension and abduction at both shoulders.
10. Monopolar electrode, 6 volts. Extension of head and both shoulders.

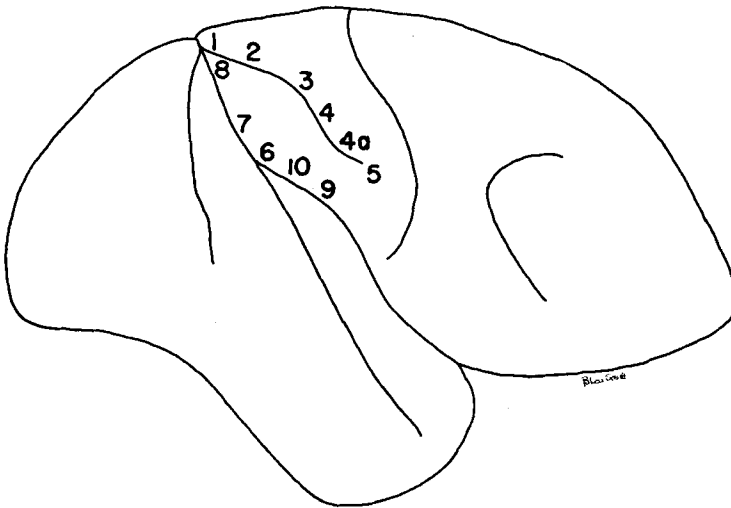


Fig. 2 Sketch of surface of right hemisphere of monkey F-4.

Immediately postoperatively the monkey did not use the right arm so much as the left in climbing but did have excellent strength in it when holding. The following day slight hypotonus was noted in the right arm and, although no definite paresis could be determined, placing, hopping, grasping, and holding were definitely impaired. By the 9th postoperative day these changes had almost completely disappeared, except for a very slight reluctance to use the right arm in placing and grasping. There was no demonstrable difference between the two arms by the 13th postoperative day.

On March 17, 1954, a right fronto-parietal craniotomy was performed; the results of stimulation of areas 5 and 7 are recorded below and in figure 2. Frames from the moving pictures of this experiment are reproduced in figure 3.

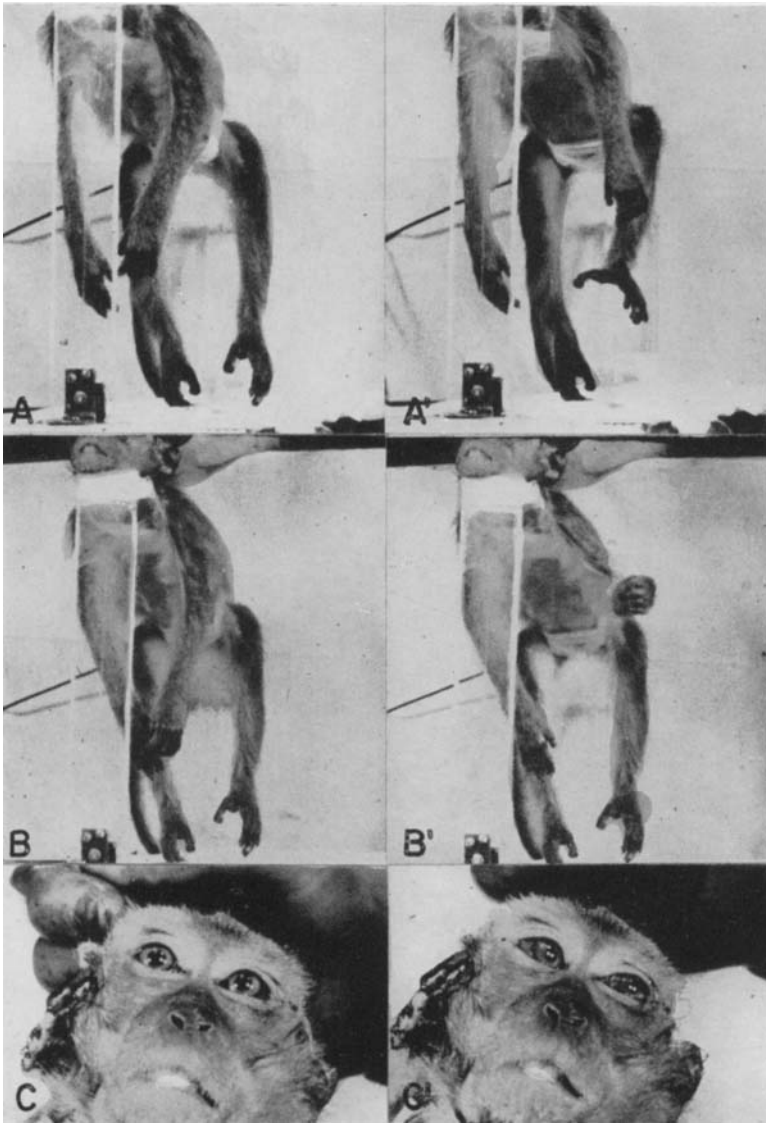


Fig. 3 Frames from the moving pictures taken during stimulation of the right hemisphere of monkey F-4 (see text).

1. Bipolar electrode, 11 volts. Flexion at left hip and knee, extension of left toes, especially the hallux, with spreading of toes.
2. Bipolar electrode, 11 volts. Left leg as at point 1, in addition extension of arm at shoulder and slight pronation of forearm (illustrated in fig. 3 A). At 13 volts the head also turned to left.
3. Bipolar electrode, 11 volts. Extension of left arm at shoulder but no leg movements.
4. Bipolar electrode, 11 volts. External rotation at left shoulder, flexion at left elbow, pronation of forearm, and hand clenched to make a fist (see fig. 3 B).
- 4a. Bipolar electrode, 11 volts. Same as point 4, in addition retraction of left corner of mouth.
5. Bipolar electrode, 11 volts. Extension at left wrist and retraction of left corner of mouth. At 9 volts slight pronation of left forearm, extension at right wrist, and retraction of left corner of mouth.
6. Bipolar electrode, 11 volts. Conjugate deviation of eyes downward and to the left.
7. Bipolar electrode, 11 volts. Conjugate horizontal deviation of eyes to left (illustrated in fig. 3 C).
8. Bipolar electrode, 11 volts. Nystagmus with quick component downward and slow component upward (i.e. ultimate deviation is upward).
9. Bipolar electrode, 11 volts. Internal rotation at left shoulder and left hand clenched, with some flexion at left elbow.
10. Bipolar electrode, 11 volts. No response.

At the end of this procedure, the monkey was perfused with formalin and the brain removed for subsequent degeneration studies.

Monkey no. F-5

This was a small male *Cynomolgus* who was healthy and whose neurological examination was repeatedly normal. On March 12, 1954, a right fronto-parietal craniotomy was performed; electrical stimulation of various points on area 5 produced the following motor responses. Figure 4 is a diagram of the cortex of this monkey and frames from the moving pictures of this experiment are reproduced in figure 5.

1. Bipolar electrode, 12 volts. Flexion at opposite hip and knee, extension and spreading of toes, especially the hallux (see fig. 5 A).

2. Bipolar electrode, 12 volts. Flexion of opposite leg and arm.
3. Bipolar electrode, 12 volts. Extension of opposite arm, flexion at opposite knee and ankle.
4. Bipolar electrode, 12 volts. Lateral rotation at opposite shoulder, flexion and slight supination of forearm, and slight flexion of fingers and thumb; no leg movements (illustrated in fig. 5 B).
5. Bipolar electrode, 12 volts. Pronation of opposite forearm, flexion of fingers and thumb.
6. Bipolar electrode, 12 volts. Flexion of opposite wrist and fingers.

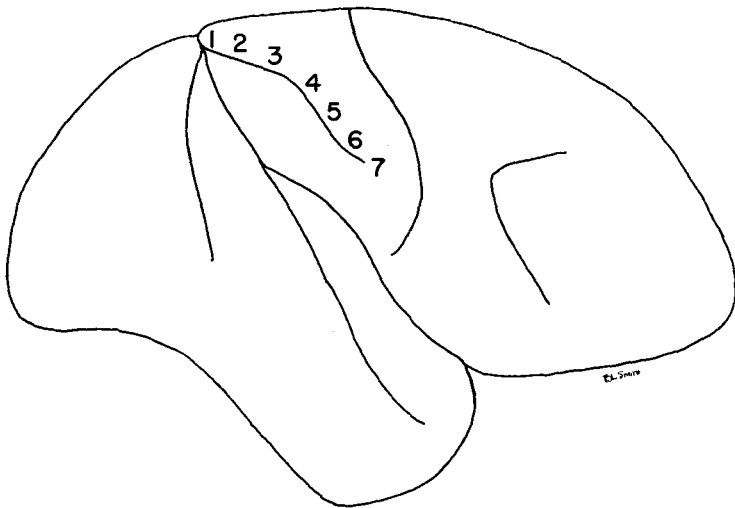


Fig. 4 Sketch of surface of right hemisphere of monkey F-5.

7. Bipolar electrode, 12 volts. Retraction of opposite side of mouth and lower face (illustrated in fig. 5 C).

Note that there were no movements of the ipsilateral extremities. Following these procedures, stimulation with the monopolar electrode was done. Although much lower voltages (as low as 4 volts) were required to produce movements, more mass responses were obtained than with the bipolar electrode and there were also some movements of the ipsilateral extremities.

Monkey no. F-8

This was a medium-sized female *Macaca mulatta*, in excellent health and with no neurological abnormalities. On May 21, 1954, a

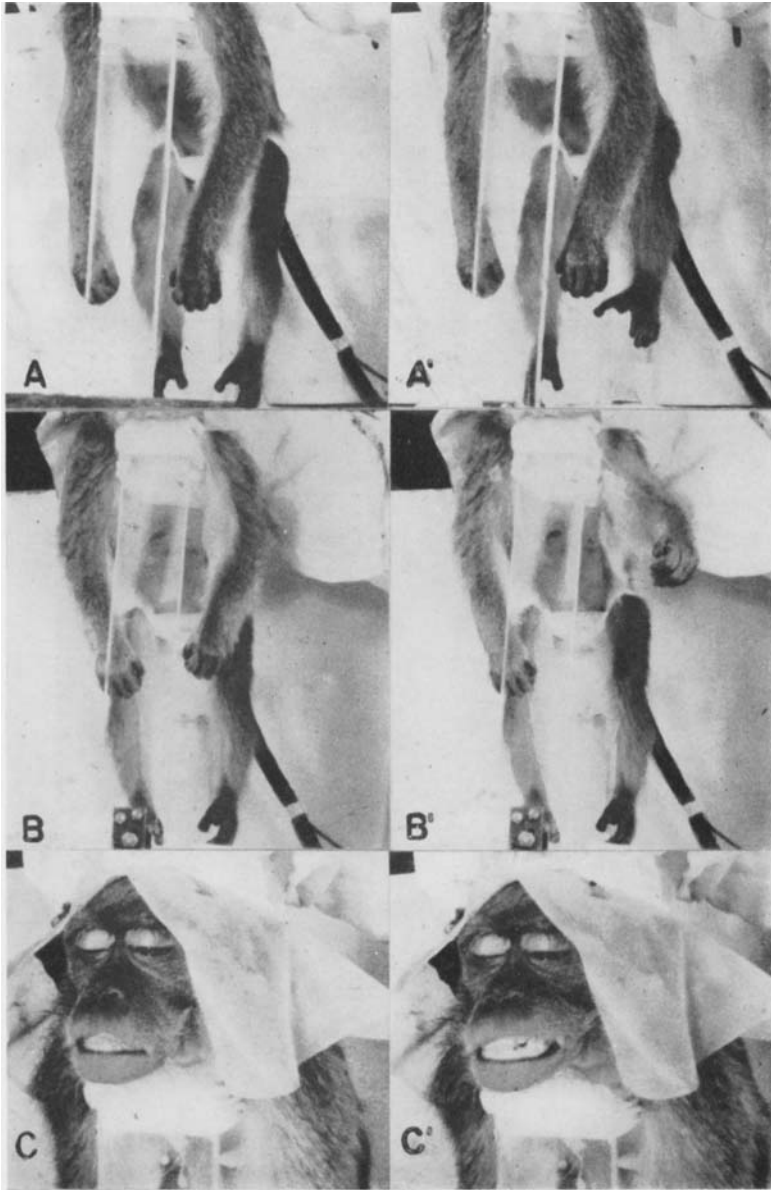


Fig. 5 Frames from the moving pictures taken during stimulation of the right hemisphere of monkey F-5 (see text).

right fronto-parietal craniotomy was performed and various points on areas 5 and 7 were stimulated, as shown in figure 6 and described below.

2. Bipolar electrode, 14 volts. Flexion at left elbow and supination of forearm, with fist clenched.
2. Monopolar electrode, 8 volts. Same response as with bipolar electrode. At 9 volts there was also some left lower facial movement.
3. Bipolar electrode, 14 volts. Flexion at left elbow, fist clenched.
3. Monopolar electrode, 8 volts. Response identical to above.

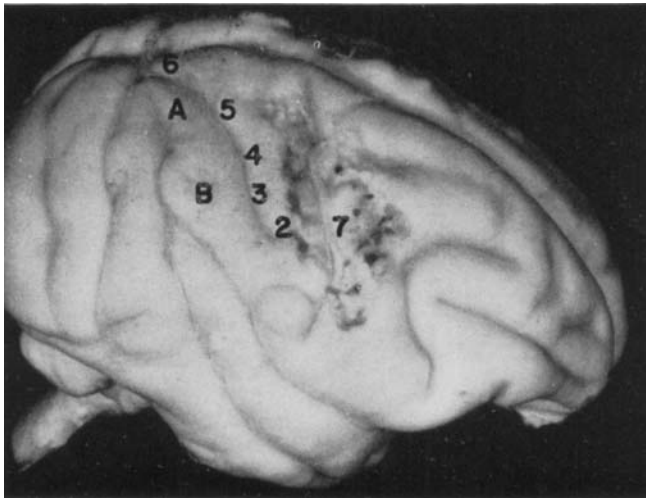


Fig. 6 Photograph of the right hemisphere of monkey F-8.

4. Bipolar electrode, 14 volts. Left fist clenched, elbow flexed, and forearm supinated.
4. Monopolar electrode, 8 volts. Same response as with bipolar electrode; in addition extension at left shoulder.
5. Bipolar electrode, 12 volts. Bilateral shoulder retraction, flexion at left hip, knee, and ankle, and abduction of both arms at shoulder. No hand or face movement.
5. Monopolar electrode, 10 volts. Identical response.
6. Bipolar electrode, 12 volts. "Running movements." Left leg advanced and left arm retracted, then flexion at left ankle and knee.
7. Bipolar electrode, 8 volts. This point on the motor cortex was stimulated to compare the relative excitability of the

motor and the parietal cortical areas. At this voltage, flexion at left elbow and left fist clenched.

- A. Bipolar electrode, 14 volts. Conjugate deviation of eyes to left.
- B. Bipolar electrode, 14 volts. Conjugate deviation of eyes to left and downward.

After carrying out these procedures, the portion of the right motor cortex (area 4) which, on stimulation, produced movements of the opposite arm and hand was excised and, following this, areas 5 and 7 were again stimulated. From each point on areas 5 and 7, movements comparable to those obtained before the excision were secured using similar electrodes and voltages. It is to be noted that there was no appreciable difference in motor responses of the upper extremity from areas 5 and 7 after the removal of the portions of the motor cortex related to arm and hand movement.

Then the arm portion of the postcentral gyrus (areas 1, 2, 3) was excised and, again, movements could be obtained readily from area 5, directly comparable to those obtained when the entire cortex was intact. Figure 6 shows the extent of the cortical lesions.

On the following day it was noted that the monkey had a profound paralysis of the left arm which was much more marked than that seen from a precentral gyrus lesion alone. There was almost no voluntary movement of the fingers, hand or wrist and marked weakness at the elbow but fairly normal shoulder movement. There was marked hypotonicity, an absence of grasp reflex, but no obvious changes in the deep tendon reflexes. No abnormality was noted in the leg. These findings persisted unchanged during the next 6 days.

On May 28, 1954, a left fronto-parietal craniotomy was performed. The results of stimulation of various points on areas 5 and 7 are outlined below and shown in figure 7.

1. Bipolar electrode, 6 volts. Flexion of right leg.
2. Bipolar electrode, 6 volts. Flexion of right leg and slight extension of right arm.
3. Bipolar electrode, 7 volts. Flexion and lateral rotation at right shoulder and slight flexion at right elbow.
4. Bipolar electrode, 7 volts. Right fist clenched, extension at right shoulder.
5. Bipolar electrode, 11 volts. Retraction of right corner of mouth.

Then the arm portions of area 4 and of areas 1, 2, 3 on the precentral and postcentral gyri were excised. The extent of the cortical ablation may be seen in figure 7. Unfortunately, there was a subpial hemorrhage extending backward into area 5. Following this ablation

it was more difficult to elicit movements and there were some differences in the movements obtained. The following results were noted.

1. Bipolar electrode, 13 volts. Very slight "running movements."
2. Bipolar electrode, 13 volts. Slight outward rotation at right shoulder.
3. Bipolar electrode, 13 volts. Slight extension at right elbow and external rotation at right shoulder.
4. Bipolar electrode, 13 volts. Extension at right wrist, opening of fingers, and slight abduction at shoulder.
- 4a. Bipolar electrode, 13 volts. Flexion at right elbow, fist clenched, external rotation at shoulder.

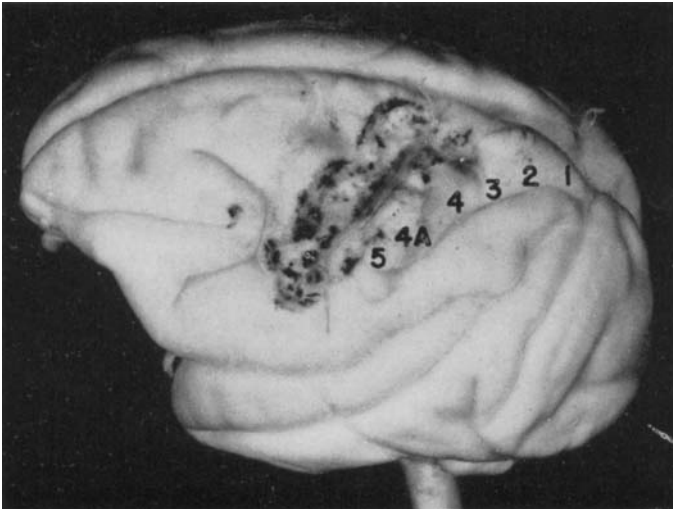


Fig. 7 Photograph of the left hemisphere of monkey F-8.

5. Bipolar electrode, 13 volts. Good face movements (retraction of opposite corner of mouth), but this also required a higher voltage than before the cortical excision, even though the face portion of these areas was not removed.

This suggested that there was a widespread depression of cortical excitability following the ablation.

Postoperatively, this monkey showed a profound paralysis with a hypotonicity of the right arm similar to that of the left arm. Ten days following the operation on the right hemisphere, there was considerable recovery in the left arm and, during excitement and rage, this monkey had a strong grasp with both hands and could climb

well. The deep tendon reflexes in each arm were somewhat increased and both Hoffmann reflexes were positive. Fourteen days after the first operation there was much recovery in the strength of the right arm and there was little definite change in the tonus of either arm. The monkey was then sacrificed and the brain removed for post-mortem study.

SUMMARY OF RESULTS

(1) *Results of cortical stimulation*

Figure 8 is a composite diagram showing the responses which were most commonly obtained from various points on areas 5 and 7. It must be borne in mind that there is much overlapping of the various points shown in the diagram, just as there is on the motor cortex of the precentral gyrus, and that there is no such thing as a consistent stereotyped response from each point on the cortex. It must also be remembered that there is some variation in the cortical excitability, not only in any individual monkey at different times but also between different monkeys.

It may be seen from figure 8 that, in general, the motor representation in area 5 mirrors that in the precentral and postcentral gyri. The feet are represented near the superior border of the hemisphere and, below them, the legs, trunk, and arms; the face is represented on the lowest part of area 5.

The motor responses obtained from area 5 differ in several respects from those obtained from area 4. (a) The parietal cortex has a higher threshold than the motor cortex. A higher voltage is required to obtain a response and, unless the level of anesthesia is quite light, no response will be elicited. (b) The responses from area 5 involve more mass movements and lack the precision and fine detail of those from area 4, with the greatest movements being at the more proximal joints. Almost no fine discrete movements of the distal joints, hands, and fingers were obtained from area 5. (c) Responses from area 5 often involve both the contralateral extremities and one or both of the ipsilateral ex-

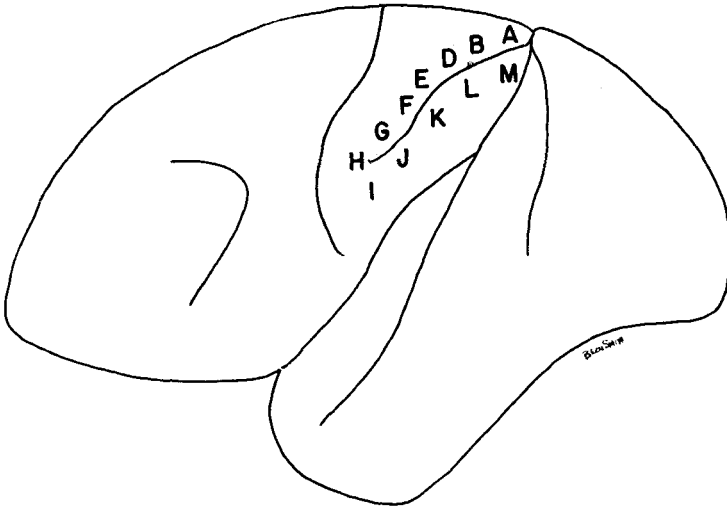


Fig. 8 Composite diagram of the monkey cortex showing the most commonly obtained motor responses.

- A. Flexion at opposite hip and knee, and spreading of toes. Slight flexion of opposite arm. Occasional extension of ipsilateral arm.
- B. Flexion of opposite leg and foot, some extension of opposite arm. Occasional movements of ipsilateral arm.
- D. Flexion or extension of opposite arm at shoulder and elbow, external rotation at shoulder, sometimes also flexion movements of opposite leg at hip, knee, and foot. Occasionally also slight extension of ipsilateral arm, and head turned towards opposite side.
- E. Flexion or extension of opposite arm at shoulder, elbow, and wrist, and supination of forearm. Occasionally also extension of ipsilateral arm.
- F. Flexion or extension of opposite arm at elbow and wrist, and lateral rotation and retraction of shoulder. Also opposite finger and hand movements quite often.
- G. Clenching of opposite fist and flexion or extension of opposite shoulder, elbow, and wrist. Also occasional movements of opposite side of face and of ipsilateral arm.
- H. Retraction of opposite corner of mouth and closing of opposite eye. Occasionally also movements of opposite wrist, hand, and fingers.
- I. Opposite side of face, and opposite wrist.
- J. Opposite side of face, occasionally opposite hand, arm, and shoulder.
- K. Conjugate deviation of eyes downward, or downward and to the opposite side. Often associated extension and retraction of both shoulders and extension of neck, with rotation of head to opposite side.
- L. Conjugate deviation of eyes to opposite side. Occasionally elevation or retraction of both shoulders.
- M. Conjugate deviation of eyes upward, or upward and to opposite side.

tremities, sometimes combined with a turning of the head and eyes toward the opposite side. Such patterns resemble maneuvers, assumption of postures, and automatic responses, such as running, stepping, and turning away. (d) There is considerable variation in the responses obtained from a given point on area 5 in each individual stimulation experiment, in contrast to the almost invariable topographic representation of the motor cortex.

(2) *Parietal stimulation after excision of precentral and postcentral gyri*

Six stimulation experiments were performed on various monkeys after either recent or old ablations of the precentral and postcentral gyri on one or both sides.

(1) *Monkey F-2, February 3, 1954.* Stimulation of the left area 5, both before and after ablation of the ipsilateral precentral arm area, yielded motor responses directly comparable to each other and to those previously described from the area.

(2) *Monkey F-4, March 17, 1954.* Stimulation of the left areas 5 and 7 before cortical ablation yielded excellent motor responses. After ablation of the ipsilateral precentral arm area, no motor responses were obtained by restimulating area 5, but the monkey had developed severe respiratory obstruction and died soon afterward, thus making this experiment invalid.

(3) *Monkey F-6, April 28, 1954.* This monkey had undergone excision of the left precentral arm area 4 weeks previously and the right precentral arm area 3 weeks previously. Stimulation of the left areas 5 and 7 yielded good motor responses, similar to those obtained with an intact motor cortex.

(4) *Monkey F-6, May 7, 1954.* Stimulation of the right areas 5 and 7 in the same monkey one week later yielded very poor motor responses. A high voltage was required and no fine movements were seen. Gross movements were obtained but these were much smaller in excursion than usual.

(5) *Monkey F-8, May 21, 1954.* Stimulation of the right areas 5 and 7 immediately after ablation of the ipsilateral precentral gyrus yielded excellent motor responses. Then the ipsilateral postcentral gyrus and cortex of the Rolandic fissure were removed and the Rolandic vessels ligated. Again, stimulation of areas 5 and 7

yielded excellent motor responses which repeated the patterns of movement obtained prior to cortical excision.

(6) *Monkey F-8, May 28, 1954.* In the same monkey, one week later, stimulation of the opposite (left) areas 5 and 7 yielded excellent motor responses. Then the precentral and postcentral gyri of the left side were removed, along with the Rolandic fissure cortex, and the Rolandic vessels were ligated. Considerable subpial hemorrhage extended back over much of area 5 and the monkey's general condition had deteriorated considerably during the procedure. Stimulation of area 5 yielded some motor responses but these were much less extensive than prior to ablation (see details of protocol given above).

From the experiments just reviewed it may be concluded that motor responses to stimulation of areas 5 and 7 can be obtained after both the ipsilateral and the contralateral precentral and postcentral cortices are removed.

In two experiments, stimulation of area 5 following excision of the opposite area 5 yielded excellent motor responses, indicating that one area 5 is able to act independently of the other in producing such responses.

(3) *Clinical effects of various parietal cortical excisions*

In two monkeys area 5 was excised from one hemisphere and the clinical effects were followed for about two weeks. In one monkey a portion of area 7 was removed from one hemisphere and subsequent clinical observations made. In another monkey several successive cortical ablations were done in both hemispheres, removing the precentral and postcentral gyri and areas 5 and 6.

Ablation of one area 5 alone (monkeys F-1 and F-4) produced transient changes in the contralateral arm and leg. Such changes included impairment of placing and grasping, especially when the monkey was blindfolded, with some hesitancy in using the limb for finer voluntary movements. There was no detectable weakness, sensory loss, nor reflex change; the muscular tonus was very slightly reduced. When the monkey was excited or angry no abnormality could be de-

tected. These changes disappeared by about the 10th post-operative day.

In the monkey who was subjected to ablation of the lower part of area 7 (monkey F-2), there was a similar change noted in the contralateral arm, which lasted 4 days. No impairment of eye movements was noted.

In another monkey (F-6) the precentral arm area was removed from each hemisphere at operations 8 days apart. Following each excision there was considerable paralysis of the contralateral arm, especially of finer movements involving the hands and fingers. The tonus was slightly increased and the Hoffmann reflex was positive for a few days. The monkey had marked disability, with difficulty in eating and climbing, and would fall frequently when climbing. The paralysis improved markedly about 10 days after each operation and, by 4 weeks following the first ablation, there was only very slight clumsiness of the hands when jumping and climbing. Thus he would hold the cage with the forearm and wrists rather than grasp it with hands and fingers. There was no demonstrable weakness, reflex change, or alteration in tonus. Then area 5 of the left hemisphere was removed; following this, there was no appreciable change in contralateral arm and leg. One week later, area 5 and the arm portion of the post-central gyrus were removed from the right hemisphere. This produced marked weakness and hypotonia in the left arm and hand which persisted only 10 days. Ten weeks after the first operation, there was no appreciable neurological deficit. Area 6 of the right hemisphere was then excised, and this resulted in marked impairment of function of the left arm and leg, with poor grasping and placing, and hypotonia, but little loss of motor power. After 9 days these findings had disappeared.

From these experiments it may be concluded that ablation of areas 5 and 7 may result in slight transient impairment of the voluntary use of the contralateral arm and leg, with slight weakness and hypotonia. Ablation of area 5 following bilateral precentral gyrus lesions produced no significant change.

(4) Pathways involved

No attempt will be made here to trace the efferent pathways from the parietal lobe as our degeneration studies are not completed. As indicative of the data available, the paper by Peele ('42) may be quoted in some detail. The remainder of the literature will be considered when our material is ready to report.

Peele ('42) was able to trace association fibers from area 5 to areas 2, 7, 1 and 3 of the ipsilateral cortex, and commissural fibers to areas 5, 3, 1, 2 and 4 of the contralateral cortex via the corpus callosum. Projection fibers traveled in the medial three-fifths of the posterior limb of the internal capsule and the lateral half of the cerebral peduncle. Some fibers ended in the substantia nigra, others in the pretectum and tectum of the midbrain, others around the pontine nuclei. No fibers ended in the tegmentum. In the pons, fibers were located laterally, and these descended to cross in the pyramidal decussation and course in the lateral cortico-spinal tracts, especially in the cervical cord. Some fibers from area 7 ended in the superior colliculus. These findings are in general agreement with those published by other workers.

DISCUSSION

“One of the great theoretical drawbacks of the technique of electrical stimulation of the cortex is the implication that it may have little if any logical connection with the biological functions of the cells so stimulated . . . Electrical stimulation of the motor cortex may bear but a remote analogy with the normal physiology of a willed movement” (Critchley, '53). One must constantly bear this in mind, lest he succumb to the danger of interpreting the results of electrical stimulation of the cortex in terms of physiology, especially when applying results obtained from monkey to man. Our experimental findings, however, illustrate the possible motor functions of the parietal area and are in agreement with the findings of other workers in this field. Furthermore, a sim-

ilar topography of motor representation in the parietal lobes has been described for man (C. and O. Vogt, '26; and Foerster, '31, '36a and b), although such representation lacks the confirmation of more recent workers. To draw an analogy between monkey and man, therefore, is not unjustified.

The addition of a large amount of parietal association cortex between the central and lateral sulci, on ascending the primate scale, may account for the more posterior location of that part of the posterior parietal lobe yielding motor responses in man. The amount of cortex buried in the various sulci and the proportionate distribution of cortex on the lateral and medial surfaces of the hemisphere may constitute some of the other differences between these areas in man and monkeys. In general, the topography and the type and pattern of motor response obtained from the posterior parietal lobe are much the same in man as in monkeys and mirror the motor representation of the precentral gyrus.

There is ample suggestion from human patients that the posterior parietal area is concerned with the production of movement. Epilepsy may originate from area 5. In describing such cases, Foerster ('36a and b) stated that the seizure begins with contralateral paresthesia, ipsilateral paresthesia, then sometimes vertigo, followed by combined flexion of the opposite side, and later, movements of the ipsilateral arm and leg (fig. 9). Penfield et al. ('54) described several patients with superficial posterior parietal lesions in whom convulsive movements of the opposite arm and face occurred. In one such patient (S. T.) with an epileptic focus in an atrophic gyrus behind the postcentral gyrus, the opposite arm was raised in tonic flexion, the head and eyes turned to one side, and then clonic movements involved the opposite arm, with spread to the face and leg.

Foerster ('36a) described a patient who suffered a traumatic loss of one area 4 and later required surgical excision of area 5 because of epilepsy. The latter procedure resulted in considerable increase in the paralysis of the opposite extremities.

Regarding the possible functions of the parietal efferent system, several workers feel that sensory neuronal sensitization is important (Peele, '42; Gobbel and Liles, '45). Others have suggested that the parieto-spinal system has to do with coordination and skilled movements.

It is the writers' suggestion that the parietal efferent system, like those from the other second motor areas considered at the beginning of this paper, plays an integral rôle in the production of voluntary movements. Voluntary movements may represent the sum total of impulses coming from many regions of the cortex capable of yielding efferent impulses. "Second" motor areas appear to lie in fairly close anatomical

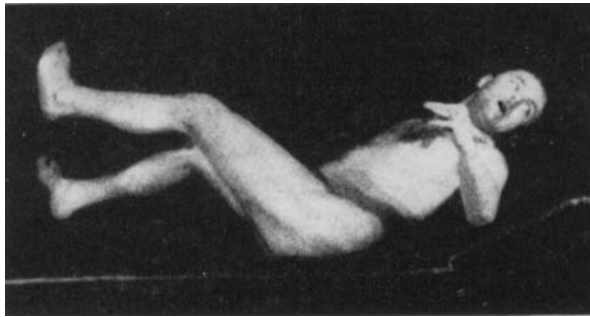


Fig. 9 Patient with a traumatic lesion of the right area 5 during an epileptic seizure. Note the flexion of left arm and leg and right leg, also the external rotation of left arm, and the rotation of head and eyes to the left. (From Foerster, '36b, reproduced by the kind permission of Julius Springer, Berlin.)

association with afferent areas of cortex, each of which is concerned with different modalities of sensation. For example, the portion of the superior temporal gyrus which yields motor responses lies adjacent to the auditory cortex and in an auditory association area. The insular cortex, which, on electrical stimulation initiates movements of the extremities, trunk, and head, lies in cortex with visceral afferent functions. Area 6, including Penfield's supplementary motor area, is adjacent to the brain's most highly developed association areas. Area 5 lies in close proximity to the sensory cortex, and area 19 to the visual cortex. Similarly those cortical areas yielding eye movements on stimulation lie close to or within various af-

ferent receptive and associative regions, areas 18 and 19 being near the visual cortex and in visual association areas, area 7 near the sensory and auditory cortex and in a region subserving associative functions, and area 8 near the frontal association areas. Therefore movements which occur in response to various afferent stimuli may arise, at least in part, from the second or additional motor area adjacent to the appropriate receptive cortex which often is also a major association area for that receptive cortex. Is it too presumptuous to suggest that the clinician might make use of the large number of additional motor areas and their close association with different afferent areas? Thus, a child who has lost the motor areas might be trained, by appropriate visual, sensory, and auditory associations, to develop more completely potentialities of the corresponding second motor areas with the resultant production of some useful voluntary movements.

SUMMARY

1. Electrical stimulation of area 5 in monkeys produces a pattern of motor responses of the contralateral extremities—trunk, and head, which mirrors the topography of area 4.

2. Stimulation of area 7 yields a pattern of eye movements similar to that obtained from the frontal and occipital eye fields.

3. These second or additional motor areas have a higher threshold of excitability than the motor cortex. Movements resulting from stimulation of these areas tend to be less precise, less fine, and not so discrete. They are often combined movements which resemble patterns and maneuvers such as running, turning, and avoiding movements or give posture.

4. These movements may be produced in the absence of the contralateral area 5 and the ipsilateral and contralateral precentral and postcentral gyri.

5. Excision of areas 5 and 7 results in slight transient hypotonia and weakness of the contralateral extremities.

6. There are several areas of cortex in both monkeys and man which give rise to movements on electrical stimulation.

It is suggested that voluntary movement is the net result of the integrative action of all these areas. However, as each of these second motor areas is located close to an afferent area of cortex and many of them in association areas, movement in response to a specific afferent stimulus may arise to a considerable extent from that second motor area which lies in close association with the afferent cortical area concerned.

LITERATURE CITED

- BARTHOLOW, R. 1874 Experimental investigations into the functions of the human brain. *Am. J. Med. Sci.*, 67: 305-313.
- BEEVOR, C. E., AND V. HORSLEY 1888 A further minute analysis by electrical stimulation of the so-called motor region of the cortex cerebri in the monkey (*Macacus sinicus*). *Phil. Trans. Roy. Soc. Lond.*, 179B: 205-256.
- 1890 A record of the results obtained by electrical excitation of the so-called motor cortex and internal capsule in an orang-outang (*Simia satyrus*). *Phil. Trans. Roy. Soc. Lond.*, 181B: 129-158.
- CRITCHLEY, M. 1953 *The Parietal Lobes*. E. Arnold and Co., London, 480 p.
- CROSBY, E. C. 1954 A discussion of certain cortical areas related to eye deviations. Given at the Centennial Celebration for Ramón y Cajal at Madrid, November, 1952. (To appear in special centennial volume from Madrid, now in press.)
- CROSBY, E. C., AND J. W. HENDERSON 1948 The mammalian midbrain and isthmus regions. II. Fiber connections of the superior colliculus. B. Pathways concerned in automatic eye movements. *J. Comp. Neur.*, 88: 53-92.
- CROSBY, E. C., R. E. YOSS AND J. W. HENDERSON 1952 The mammalian midbrain and isthmus regions. II. The fiber connections. D. The pattern for eye movements on the frontal eye field and the discharge of specific portions of this field to and through midbrain levels. *J. Comp. Neur.*, 97: 357-383.
- DUSSER DE BARENNE, J. G., H. W. GAROL AND W. S. McCULLOCH 1941a The "motor" cortex of the chimpanzee. *J. Neurophysiol.*, 4: 287-303.
- 1941b Functional organization of sensory and adjacent cortex of the monkey. *J. Neurophysiol.*, 4: 324-330.
- ERICKSON, T. C., AND C. N. WOOLSEY 1951 Observations on the supplementary motor area of man. *Trans. Am. Neurol. Assn.*, 76: 50-56.
- FERRIER, D. 1876 *The functions of the brain*. Smith, Elder and Co., London, 323 p.
- FLECHSIG, P. 1896 *Die Localisation der geistigen Vorgänge insbesondere der Sinnesempfindungen des Menschen*. Veit u. Co., Leipzig, 88 p.
- FOERSTER, O. 1931 The cerebral cortex in man. *Lancet*, 221: 309-312.
- 1936a The motor cortex in man in the light of Hughlings Jackson's observations. *Brain*, 59: 135-159.

- FOERSTER, O. 1936b Motorische Felder und Bahnen in: Handbuch der Neurologie, edited by O. Bumke and O. Foerster, 6: 1-352. Julius Springer, Berlin.
- FRONTERA, J. G. Unpublished data.
- GOBBEL, W. G., AND G. W. LILES 1945 Efferent fibers of the parietal lobe of the cat. *J. Neurophysiol.*, 8: 257-266.
- HENDERSON, J. W., AND E. C. CROSBY 1952 An experimental study of optokinetic responses. *Arch. Ophthalmol.*, 47: 43-54.
- HORSLEY, V., AND E. A. SCHAEFER 1888 A record of experiments upon the functions of the cerebral cortex. *Phil. Trans. Roy. Soc. Lond.*, 179B: 1-45.
- HYDE, J., AND E. GELLHORN 1951 The physiological effect of variations in the stimulus frequency on the motor cortex of the monkey. *Brain*, 74: 432-442.
- LAUER, E. W. 1952 Ipsilateral facial representation in the motor cortex of macaque. *J. Neurophysiol.*, 15: 1-4.
- LEMMEN, L. J. 1951 An anatomical and experimental study of temporal and occipital association areas. *J. Comp. Neur.*, 95: 521-560.
- LEYTON, A. S. F., AND C. S. SHERRINGTON 1917 Observations on the excitable cortex of the chimpanzee, orang-outang and gorilla. *Quart. J. Exp. Physiol.*, 11: 135-222.
- MOFFIE, D. 1949 The parietal lobe, a survey of its anatomy and functions. *Folia Psychiat. Neur. et Neurochir. Neerl.*, 52: 418-444.
- PEELE, T. L. 1942 Cytoarchitecture of individual parietal areas in the monkey (*Macaca mulatta*) and the distribution of the efferent fibers. *J. Comp. Neur.*, 77: 693-737.
- 1944 Acute and chronic parietal lobe ablations in monkeys. *J. Neurophysiol.*, 7: 269-286.
- PENFIELD, W., AND H. JASPER 1954 *Epilepsy and the functional anatomy of the human brain.* Little, Brown and Co., Boston, 896 p.
- PENFIELD, W., AND T. RASMUSSEN 1950 *The cerebral cortex of man.* The Macmillan Co., New York, 248 p.
- PENFIELD, W., AND K. WELCH 1949 The supplementary motor area in the cerebral cortex of man. *Trans. Am. Neur. Assn.*, 74: 179-184.
- 1951 The supplementary motor area of the cerebral cortex. *Arch. Neur. and Psych.*, 66: 289-317.
- SCHNEIDER, R. C., AND E. C. CROSBY 1954 Stimulation of "second" motor areas in the macaque temporal lobe. *Neurology*, 4: 612-622.
- SUGAR, O., J. G. CHUSID AND J. D. FRENCH 1948 A second motor cortex in the monkey. *J. Neuropath. and Exp. Neur.*, 7: 182-189.
- VOGT, C., AND O. VOGT 1926 Die vergleichend-architektonische und die vergleichend-reizphysiologische Felderung der Grosshirnrinde unter besonderer Berücksichtigung der menschlichen. *Naturwissenschaften*, 14: 1190-1194.

- WARD, J. W. 1952 Motor phenomena elicited in the unanesthetized animal by electrical stimulation of the cerebral cortex. Chapter XI in: Patterns of organization in the central nervous system, Res. Publ. Assn. nerv. ment. Dis., 30: 223-237. Williams and Wilkins Co., Baltimore.
- WOOLSEY, C. N., AND P. H. SETTLAGE 1950 Pattern of localization in the precentral motor cortex of *Macaca mulatta*. Fed. Proc., 9: 140.
- WOOLSEY, C. N., P. H. SETTLAGE, D. R. MEYER, W. SENCER, T. P. HAMUY AND A. M. TRAVIS 1950 Somatotopic organization of "supplementary motor area" of the monkey. Am. J. Physiol., 163: 763.
- 1952 Patterns of localization in precentral and "supplementary" motor areas and their relation to the concept of a premotor area. Chapter XII in: Patterns of organization in the central nervous system, Res. Publ. Assn. nerv. ment. Dis., 30: 238-264. Williams and Wilkins Co., Baltimore.