

# Olfactory Bulb Projections in the Bullfrog *Rana catesbeiana*

R. GLENN NORTHCUTT AND G. JAMES ROYCE  
*Department of Zoology, University of Michigan, Ann Arbor, Michigan 48104,  
and Department of Anatomy, Albany Medical College,  
Albany, New York 12208*

**ABSTRACT** The projections of the accessory and main olfactory bulbs of the bullfrog are described as part of a long term analysis of the morphological differences in amphibian and reptilian telencephalons. Unilateral aspiration of the accessory olfactory bulb results in an ipsilateral projection to the pars lateralis of the amygdala via the accessory olfactory tract. Degenerating fibers from the accessory olfactory bulb are tracable into the cell-free zone between the dorsal striatum and the lateral pallium, and projections to these neural populations may also exist. Unilateral lesions of the main olfactory bulb reveal two major secondary pathways: an ipsilateral medial olfactory tract that projects to the rostral ventromedial portion of the medial pallium, the postolfactory eminence and the rostral, lateral and medial septal nuclei; and an ipsilateral lateral olfactory tract that projects to the dorsal striatum, the lateral pallium and the ventral half of the dorsal pallium. Two crossed secondary olfactory pathways to the contralateral telencephalon decussate via the habenular commissure after entering the ipsilateral stria medullaris. A crossed lateral pathway terminates in the dorsal striatum, the caudal, lateral pallium and the ventral portion of the dorsal pallium. A crossed medial pathway terminates in the internal granule layer of the main olfactory bulb.

The transition from amphibians to reptiles marks the beginning of one of the major adaptive radiations in vertebrate phylogeny. The emergence of true land vertebrates is correlated with striking morphological changes in the telencephalon (fig. 1). The study of the observed differences was pioneered at the turn of the century and resulted in careful descriptions of the character and distribution of the neurons in a number of amphibians and reptiles (P. Ramon, 1896; Gaupp, 1896; Edinger, '08; Rothig, '26; Crosby, '17). While these early workers attempted to determine the interconnections of neurons, their techniques for tracing long connections were less adequate than the recently developed silver impregnation techniques of Nauta and co-workers (Nauta, '57; Fink and Heimer, '67) for demonstrating experimentally induced degenerating pathways. Information on neural interconnections provides critical data for both the recognition of homologous and functional units in the telencephalon. It is impossible to understand the adaptive significance of the telencephalic differences between amphibians and reptiles without recognizing homologous neural

structures and their interconnections. As one step in a new analysis we here report certain new observations on the normal anatomy of the telencephalon, describe the secondary olfactory pathways in the bullfrog, and compare them with those of other vertebrates.

## MATERIALS AND METHODS

Twenty-three adult specimens of *Rana catesbeiana* Shaw obtained from Southern Biological Supply Company in McKenzie, Tennessee, were subjected to unilateral aspiration, knife-cuts, or electrolytic lesions of the olfactory nerve (3 specimens), main olfactory bulb (11 specimens), accessory olfactory bulb (6 specimens), or habenular commissure (3 specimens), under ethyl m-aminobenzoate methanesulfonate (MS-222) anesthesia (200 mg/kg). After postoperative survival times ranging from 6 to 22 days at 24° to 27°C, the animals were sacrificed under MS-222 anesthesia by transcardial perfusion with 10% formalin. The brains were removed, fixed in 10% formalin for at least one week, and embedded in 25% (W/V) gelatin. Frozen sections were cut at 25 micra, stored in 2% formalin at 5°C, and proc-

essed by several modifications of the Nauta ('57) and Fink-Heimer ('67) procedures for the demonstration of degenerating axoplasm. Appropriate sections were drawn with the aid of a Bausch and Lomb micro-

projector, and the degenerating pathways were charted on these drawings. The chartings of the degenerating pathways were then transferred to line drawings of photographs taken of a normal brain, cut

#### Abbreviations

ac, anterior commissure	m, pars magnocellularis of the periventricular preoptic nucleus
act, accessory olfactory tract	ml, mitral layer
aot, anterior olfacto-habenular tract	mot, medial olfactory tract
apl, amygdala, pars lateralis	mp, medial pallium
apm, amygdala, pars medialis	ms, medial septum
bn, bed nucleus of the pallial commissure	na, nucleus accumbens
D, diencephalon	O, optic nerve
dp, dorsal pallium	OB, olfactory bulb
ds, dorsal striatum	OC, optic chiasm
dvr, dorsal ventricular ridge	ON, olfactory nerve
en, entopeduncular nucleus	OT, optic tectum
epl, extragranular plexiform layer	p, periventricular preoptic nucleus
gl, glomerular layer	pc, pallial commissure
hc, habenular commissure	pe, postolfactory eminence
igl, internal granule layer	sm, stria medullaris
lct, lateral cortico-habenular tract	st, striatum
lot, lateral olfactory tract	T, telencephalon
lp, lateral pallium	vn, vomeronasal nerve
ls, lateral septum	vs, ventral striatum

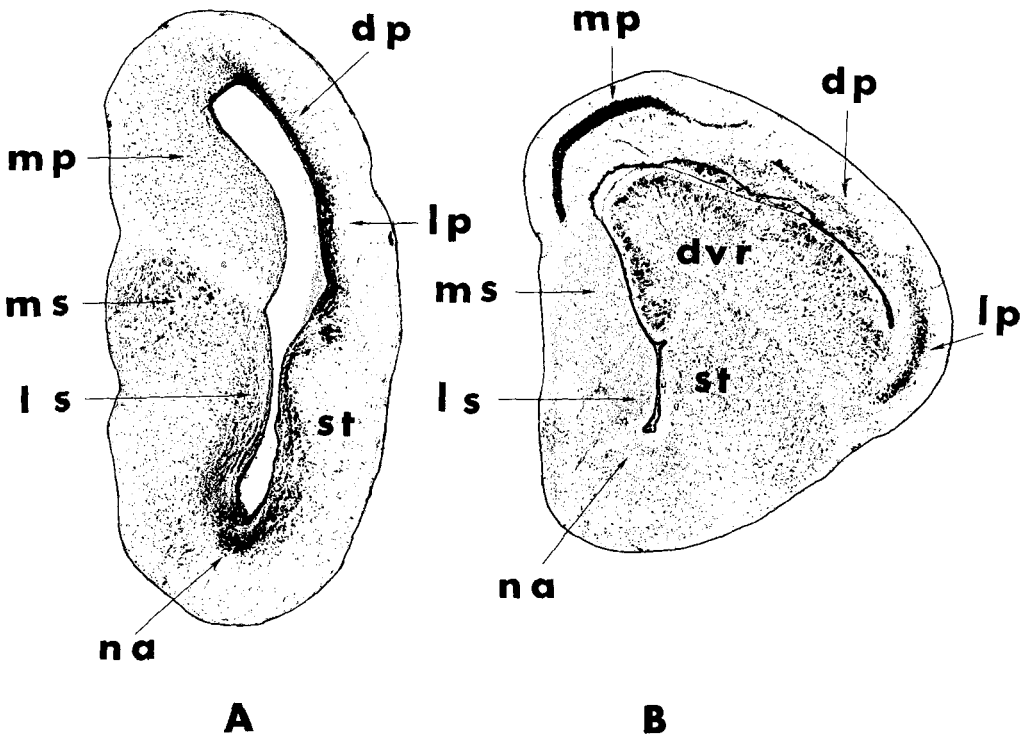


Fig. 1 Representative transverse sections through the left telencephalic hemisphere of *Rana* (A) and *Gekko* (B) illustrating the differences in the development of the lateral hemispheric wall and the migration of neuronal populations from a periventricular position.

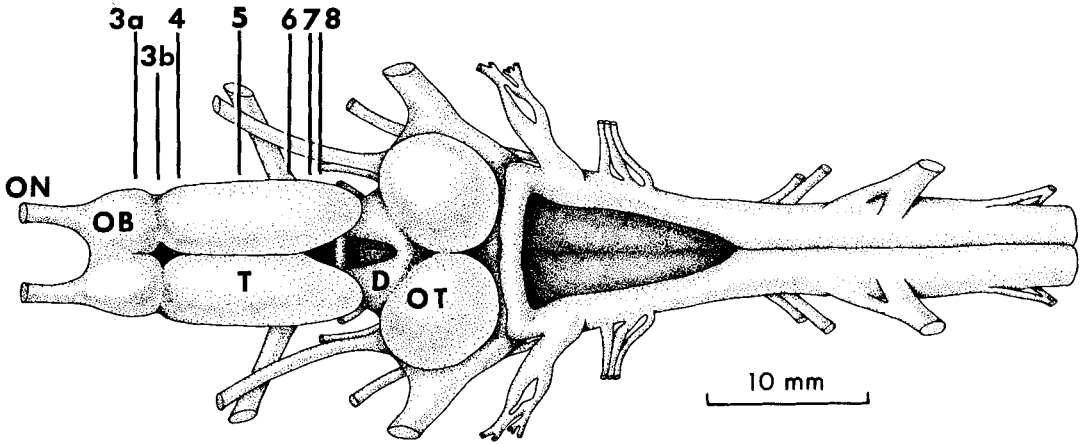


Fig. 2 Dorsal view of the brain of the bullfrog. Arrows indicate the level of transverse sections illustrated in figures 3 through 8.

in the transverse plane and stained with cresyl violet. Additional cresyl violet and Bodian stained material of *R. catesbeiana* cut in the three standard anatomical planes was used to study the normal anatomy of the prosencephalon. To demonstrate cytoarchitectonics selected sections in the cresyl violet series were photographed on Kodalith Ortho film, type 3 with a Leitz large-format camera. Degrating pathways and terminal fields were photographed on Kodak photomicrography monochrome film (50-410) with a Leitz Ortholux II microscope.

## RESULTS

### Normal anatomy

A dorsal view of the brain of *R. catesbeiana* is shown in figure 2 with indicated levels of the transverse sections illustrated in figures 3-8. The nomenclature used in the following descriptions is modified from Hoffman ('63), Scalia et al. ('68), and Northcutt ('74).

**Olfactory bulbs.** The olfactory bulbs are formed by evaginations of the rostral telencephalic walls and secondarily form main and accessory bulbs in anurans. The main olfactory bulbs possess a series of concentric laminae in the following centripetal order: (1) olfactory nerve fibers and glomerular layer, (2) external cellular layer composed of small granule and larger mitral cells, (3) extragranular plexiform layer composed of secondary olfactory fibers, (4) internal granule layer and (5) ependyma (fig. 3). The medial walls of the

main olfactory bulbs are fused and all laminae except the internal granule layer are continuous between the two bulbs. Beyond the most rostral levels of the main bulb, the glomerular layer is restricted to the ventral half of the bulbs (fig. 3). The internal granule layer continues further caudally than the other bulbar laminae and is first replaced dorsally by the telencephalic pallial areas then ventrally by the subpallial areas (figs. 3B-5). The transition from internal granule layer to telencephalic hemispheric areas is sudden and morphologically recognizable by a decrease in the packing density and a marked increase in the diameter of the hemispheric neurons. An anterior olfactory nucleus conforming to Hoffman's description as a portion of the granular layer of the bulb could not be recognized.

The accessory olfactory bulb occupies the ventrolateral caudal wall of the main olfactory bulb and possesses the same neural laminae as the main bulb (fig. 4). At the level of its maximal development, the accessory bulb occupies most of the bulbar wall and the mitral layer of the accessory bulb is in contact, if not in continuity, with the internal granule layer of the main olfactory bulb.

**Subpallium.** On the basis of cytoarchitectural and histochemical observations (Northcutt, '74) the telencephalon proper can be divided into a dorsal pallium and a ventral subpallium. The medial subpallial wall consists of four major nuclei: (1) postolfactory eminence, (2) lateral septal

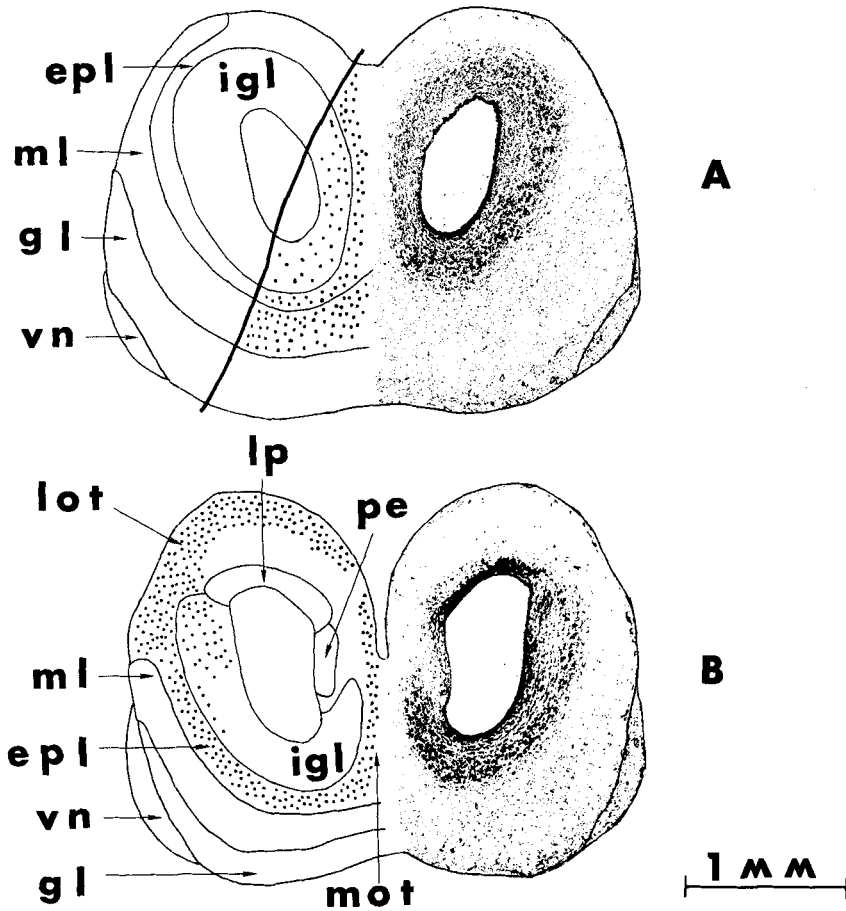


Fig. 3 Transverse sections through middle (A) and caudal (B) levels of the main olfactory bulb in the bullfrog. A Nissl preparation is shown on the right, and the contralateral side is drawn on the left. Degenerated fibers and preterminal degeneration is represented by stippling in figures 3 through 9. The heavy line running obliquely in the left half of A marks the medial extent of the main olfactory bulb lesion in case RC-OB-9.

nucleus, (3) medial septal nucleus, and (4) a pars medialis of the amygdala.

The postolfactory eminence is a small periventricular nucleus located rostral to the septal nuclei in the extreme rostral hemisphere (fig. 4). This nucleus corresponds to the similarly named nucleus of Rothig ('12) and appears to have been described as part of the primordium hippocampi by Hoffman ('63).

The lateral septal nucleus emerges as a caudal continuation of the medial internal granule layer (fig. 5) and continues as far caudally as the lamina terminalis (fig. 6) where it is bounded caudally by the hemispheric commissural system. Ventral to the lateral septal nucleus, another

neural population can be recognized, the pars medialis of the amygdala (fig. 6). This division of the amygdala begins just rostral to the lamina terminalis and can be distinguished from the lateral septal nucleus by its more densely packed neurons. The pars medialis continues to enlarge as it is traced caudally. Laterally it forms a distinct ridge in the floor of the lateral ventricle and medially fuses with the contralateral pars medialis across the lamina terminalis. Hoffman described this neural population as a caudal continuation of his nucleus accumbens.

Rostrally the medial septal nucleus is first recognized as a migrated cell group medial to the lateral septal nucleus. As

this group is traced caudally it is observed to form dorsal and ventral divisions (fig. 5). Hoffman only described the dorsal division as the medial septal nucleus while he referred to the ventral division as the nucleus of the diagonal band of Broca. Scalia et al. ('68) followed the usage of Rothig ('12) and included both divisions under the medial septal nucleus. That convention is followed in the present report, but until the connections of these divisions are experimentally determined it is impossible to resolve these differences. The medial septal nucleus continues caudally and finally terminates in the caudal, medial pole of the hemisphere (fig. 7). In this region one additional medial cell population can be recognized, the bed nucleus of the pallial commissure (fig. 7). This nucleus is not included in the list of medial subpallial nuclei as preliminary histochemical data suggest that these neurons are a dorsal and rostral extension of the

periventricular preoptic nucleus of the hypothalamus.

The lateral subpallial wall consists of a tier of nuclei: a lateral striatum proper and a medial nucleus accumbens adjacent to the septal nuclei (figs. 5, 6). This lateral wall is composed of a series of almost continuous cellular laminae. For this reason no general agreement exists in the literature regarding the basic number of recognizable nuclear units or their homologues with other vertebrate taxa. At rostral levels a pars dorsalis of the striatum can be distinguished from a pars ventralis due to differences in the packing density and the degree of neuronal migration from the ependyma (fig. 5). The pars dorsalis can be traced caudally to the level of the lamina terminalis. At this level it is presently impossible to determine whether this cell group terminates or merges ventrally with the pars ventralis. The pars ventralis can be recognized at even more caudal

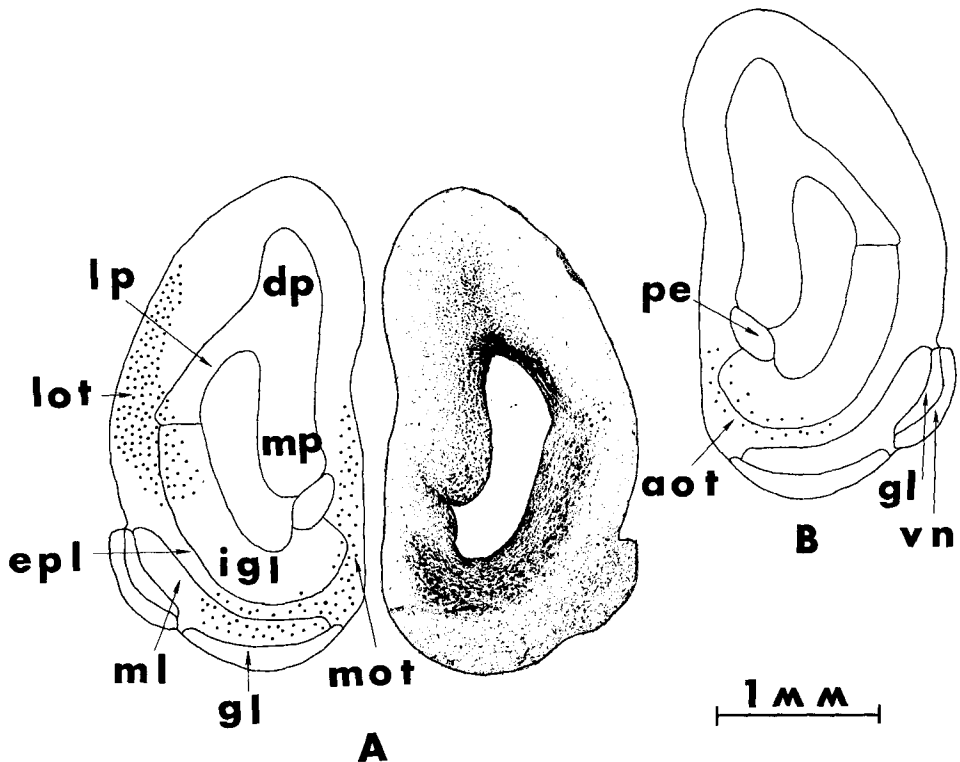


Fig. 4 Transverse sections through the rostral pole of the telencephalon at the level of the accessory olfactory bulb (A). Figure 4B is a line drawing of the contralateral hemisphere at the same telencephalic level as the Nissl preparation illustrating the position of the crossed secondary olfactory pathways.

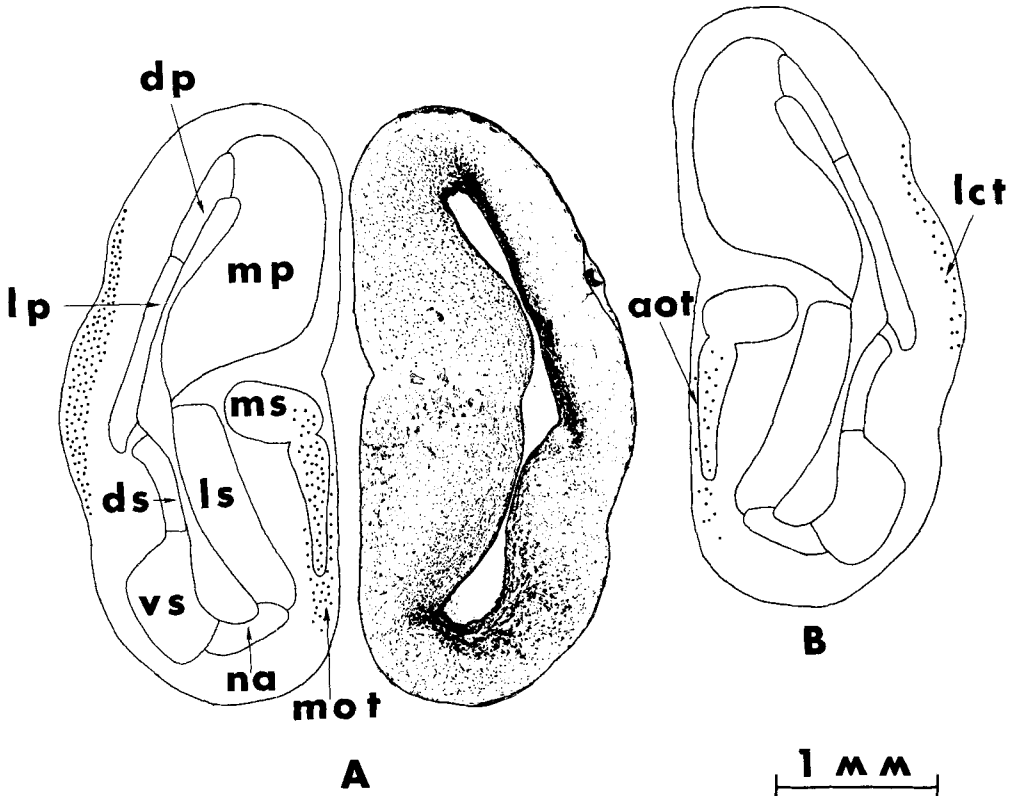


Fig. 5 Transverse sections through a mid-telencephalic level. Figure 5A illustrates the position of the ipsilateral secondary olfactory pathways, and figure B the position of the crossed secondary pathways at the same telencephalic level. This level marks the most caudal extent of the ipsilateral medial olfactory tract.

levels, but it becomes restricted both laterally and medially and can be traced ventrolaterally into the lateral forebrain bundle where the continuing cell column is then termed the entopeduncular nucleus (fig. 7). The medial nucleus accumbens is defined as a cellular population arising immediately caudal to the accessory olfactory bulb and replacing the internal granule layer of the main olfactory bulb. It occupies a subependymal position in the floor of the lateral ventricle (fig. 5) and its cells are closely packed and stain more darkly with cresyl violet than the more lateral cellular populations. Rostrally this population corresponds to the population similarly labeled by Hoffman ('63) but it was not traced beyond the rostral lamina terminalis. The cellular population labeled as accumbens by Hoffman at levels caudal to the lamina terminalis is here inter-

preted as the pars medialis of the amygdala (fig. 6).

*Pallium.* On the basis of cytoarchitectural and histochemical observations (Northcutt, '74) four pallial subdivisions are recognized: dorsal, lateral and medial pallial sheets, and a pars lateralis of the amygdala. The pallial sheets replace the internal granule layer dorsally and their rostral boundary is marked by an increase in the size of the neurons. The lateral pallium is the most rostrally occurring pallial component (fig. 3B). The lateral pallium consists of two components which are recognized on the basis of the differential thickness of their compact subependymal zones. The dorsal component possesses a compact subependymal zone half the thickness of the ventral component's subependymal zone (figs. 3B-5). At present it is not known whether the anatomical compo-

nents of the lateral pallium possess different functions. The medial pallium is the next pallial element to appear rostrally (fig. 4). It is easily recognized by the scattered subependymal layer and the large number of migrated neurons throughout its rostrocaudal extent (figs. 4-8).

The dorsal pallium appears just dorsal and caudal to the entry to the medial pallium (fig. 4). Traditionally the term dorsal pallium has been restricted to a population of transitional neurons some 0.38 millimeters in cross-sectional diameter between the lateral and medial pallia. However, as defined in this study the dorsal pallium includes a more lateral population usually considered to be the dorsal part of the lateral pallium (figs. 5, 6). This decision is strongly influenced by the results

of the distribution of the lateral olfactory tract and will be discussed after the experimental results of the present study are presented.

The pars lateralis of the amygdala is first recognized as a ventral continuation of the lateral pallium (fig. 5). Caudal to the level of the interventricular foramen (fig. 7), the pars lateralis expands to form a C-shaped nucleus and more caudally it becomes oval in outline (fig. 8). Its caudal portion has been termed the anterior entopeduncular nucleus by Frontera ('52).

*Experimental results*

All experimental cases from the shortest survival time, six days, to the longest survival time, 22 days, showed evidence of degeneration. Cases with survival times

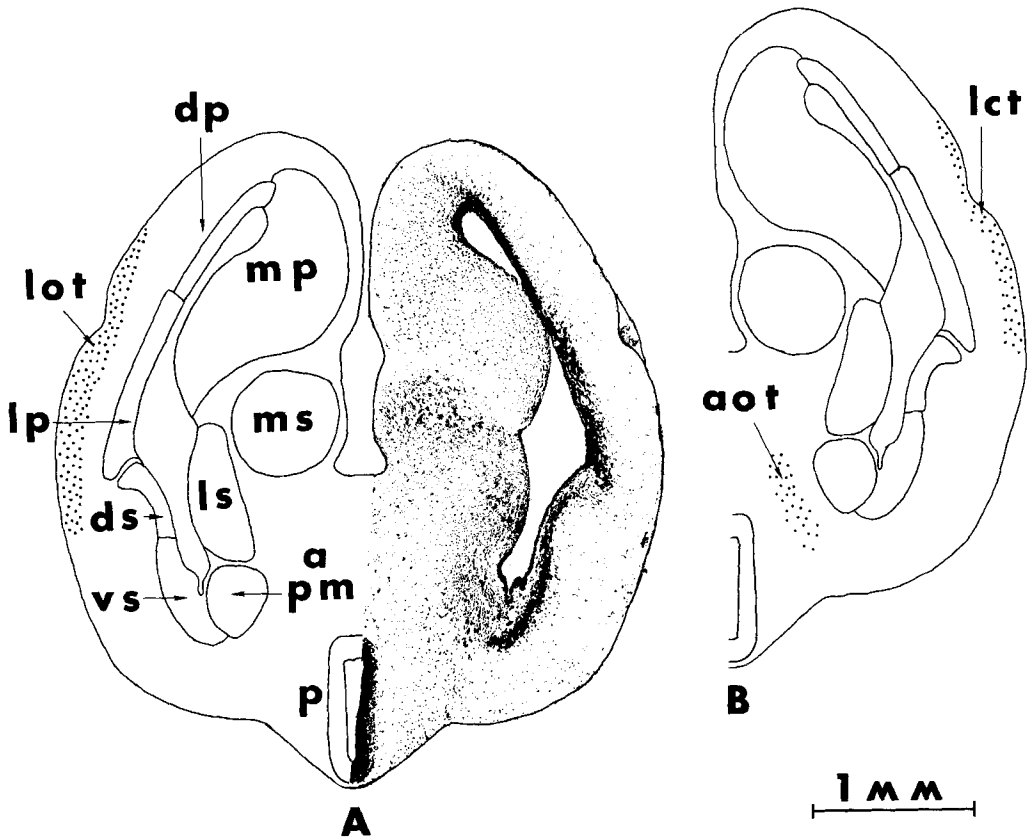


Fig. 6 Transverse sections at the level of the rostral telencephalon medium. Figure 6A illustrates the caudal continuation of the ipsilateral lateral olfactory tract, and figure 6B the course of the crossed secondary pathways at the corresponding contralateral hemispheric level.

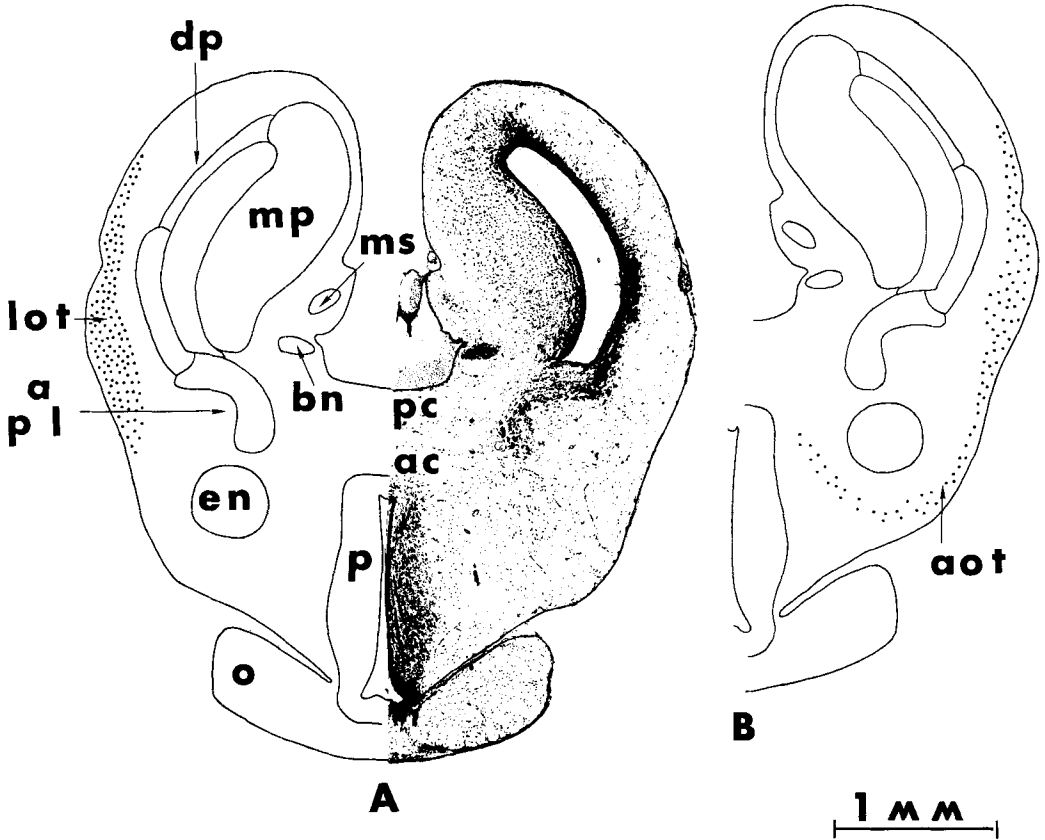


Fig. 7 Transverse sections at a telencephalic level immediately caudal to the level of the interventricular foramina. Figure 7A illustrates the position of the ipsilateral lateral olfactory tract at a level immediately rostral to the entry of the decussating fibers into the stria medullaris. Figure 7B illustrates a comparable level in the contralateral hemisphere where the crossed secondary olfactory fibers skirt the forebrain bundles and the preoptic area occupies a medial hemispheric position.

of 8 to 12 days showed maximal argyrophilia of degenerating axoplasm. Both the degenerating axons and terminals appeared as very fine opaque particles. The argyrophilic pattern usually observed in amniotes was not generally apparent. Two factors limit the precision with which we can identify the targets of secondary olfactory fibers. First the uniformly fine nature of the degenerating particles makes it difficult, if not impossible, at light microscopic levels to distinguish between degenerating axons and terminals. Second, much of the degeneration appears outside the nuclear boundaries suggesting that most of the terminals are of an axo-dendritic nature. The conclusions regarding targets of secondary olfactory fibers pre-

sented below are based on density of particles, proximity of degenerating particles to cellular groups, and termination of the degenerating pathways in specific targets beyond which the pathways can not be traced.

*Olfactory nerve.* Since several layers of the main olfactory bulbs in *Rana* are continuous along their medial surfaces, it is possible that each olfactory nerve could project to both bulbs. In order to examine this possibility three specimens were subjected to unilateral transection of the left olfactory nerve. A single olfactory nerve was exposed by drilling through the sphenethmoid bone rostral to the neurocranium. At this level the olfactory nerves are separately housed and possible dam-



age to the contralateral nerve is minimized. One animal survived eight days postoperatively while the remaining two animals survived 14 days postoperatively. All specimens demonstrated argyrophilic particles in the left olfactory nerve caudal to the transection. The glial elements in the transected nerve lost their linear arrangement along the individual olfactory fascicles and the degenerating fascicles were first characterized by fine almost dust-like particles and subsequently by larger argyrophilic particles. The contralateral olfactory nerve retained the orderly array of glial elements and very sparse argyrophilia was restricted to the circumference of the individual olfactory fascicles. This argyrophilia was interpreted as restricted to the glial and vascular elements.

Examination of the left main olfactory bulbs in all specimens revealed dense ar-

gyrophilic particles restricted to the glomerular and mitral layers. The glomerular layer of the right olfactory bulbs also contained dense argyrophilic particles. However, these particles were 2 to 4 times smaller in diameter than those in the left bulb, and no change in their diameter or density was observed at the longer survival time. Thus we believe that each olfactory nerve only projects to the ipsilateral olfactory bulb. This conclusion is further reinforced by the observation that surgical intervention into widely separated neural populations such as the cerebellum, medulla and tectum are almost inevitably associated with the presence of extremely fine argyrophilic particles in the accessory and main olfactory bulbs.

*Main olfactory bulb.* The following description is based on case RC-OB-9. This specimen sustained a pure unilateral lesion of the main olfactory bulb which

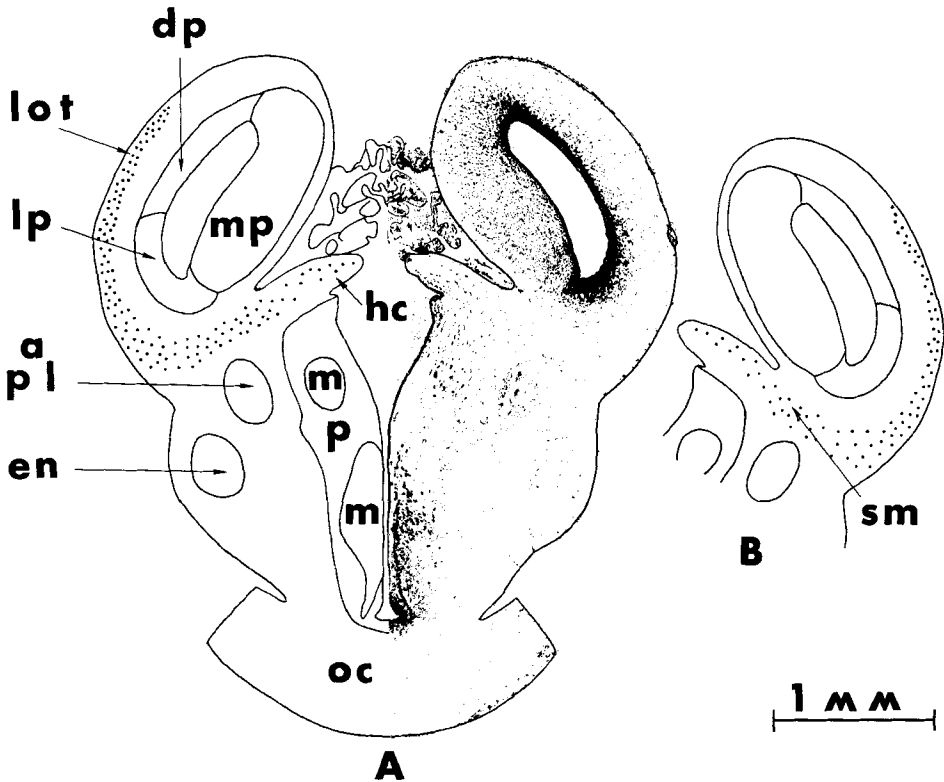


Fig. 8 Transverse sections at the level of the caudal hemispheric pole. Figure 8A illustrates the entry of the ipsilateral olfactory pathway into the stria medullaris. Figure 8B illustrates a comparable level in the contralateral hemisphere and the distribution of the crossed secondary olfactory fibers.

spared the most ventrocaudal portion of the bulb. There was no recognizable damage to the retrobulbar pallium. This animal survived ten days postoperatively and displayed what we believe to be the total projection pattern of the main olfactory bulb.

In the caudal bulb degenerating fibers collect in the extragranular plexiform layer to form the medial and lateral olfactory tracts (figs. 3B, 10A). The medial olfactory tract lies in a superficial position in the medial hemispheric wall. Rostrally it passes along the postolfactory eminence, the ventromedial surface of the medial pallium, and the lateral and medial septal nuclei (figs. 3-5). Ipsilaterally degenerating fibers in the medial olfactory tract were not traced beyond a level just rostral to the lamina terminalis (fig. 5). The medial septal nucleus is the only cellular population throughout the extent of the medial olfactory tract that demonstrates degenerating particles within its confines (fig. 5).

Rostrally degenerating fibers are seen in the extragranular plexiform and internal granule layers streaming dorsally and laterally to form the lateral olfactory tract (figs. 3B, 10A). This tract continues to add fibers at its ventrolateral edge until the posterior level of the accessory olfactory bulb is reached (fig. 4A). As the lateral olfactory tract is traced caudally it spreads over the lateral surface of the hemisphere (fig. 10C,D) and is confined to the outer molecular zones of the following cellular populations: the dorsal half of the dorsal striatum, the lateral pallium and the ventral half of the dorsal pallium (figs. 4-8). Degenerating fibers of the lateral olfactory tract were traced far caudally into the posterior hemispheric pole (fig. 8).

At the level of the telencephalon medium (fig. 7), the degenerating fibers in the ventral edge of the lateral olfactory tract turn medially after skirting the pars lateralis of the amygdala and enter the stria medullaris (fig. 8). A moderate number of degenerating particles were seen in the striae medullarium but few particles were seen in the habenular commissure proper.

Contralateral to the lesioned olfactory bulb, degenerating particles were traced laterally in the stria medullaris and lat-

eral olfactory tract (fig. 8B). At this level two separate degenerating pathways were traced. A lateral pathway was traced both dorso-caudally and dorso-rostrally. This lateral pathway could not be traced rostrally beyond a midtelencephalic level (fig. 5B), and is termed the lateral corticohabenular tract of Herrick ('48). A second pathway was traced ventrally and medially around the forebrain bundles (fig. 7B) where it skirted the periventricular preoptic nucleus (fig. 6B) and then passed rostrally in a comparable position to the ipsilateral medial olfactory tract (fig. 5B). This crossed medial component was traced rostrally to the internal granule and extragranular plexiform layers of the caudal main olfactory bulb (fig. 4B). This crossed pathway corresponds to the anterior olfactohabenular tract of Herrick ('21).

Since none of the lesions restricted to the main olfactory bulb resulted in definite evidence that the crossed olfactory pathways decussated via the habenular commissure, three animals were subjected to complete transection of the habenular commissure. Case RC-HC-1 survived nine days postoperatively and demonstrated bilateral degeneration of the striae medullarium, and the lateral and medial olfactory tracts along their entire rostro-caudal extent. Additionally this specimen showed extensive degenerating particles in the internal granule layer of both main olfactory bulbs.

*Accessory olfactory bulb.* The following description is based on RC-AOB-2. This specimen sustained a unilateral lesion of the entire left accessory olfactory bulb and survived eight days postoperatively. The lesion was inflicted by cannular aspiration through a ventral entry in the braincase by a surgical approach through the roof of the mouth. The lesion included the internal granule layer of the main olfactory bulb immediately medial to the mitral layer of the accessory olfactory bulb (fig. 9). This lesion insures that all layers of the accessory bulb were destroyed but analysis is complicated by interruption of the secondary olfactory pathways arising in the internal granule and extragranular plexiform layers of the main olfactory bulb. However, since the accessory olfactory bulb does not possess a distinct recognizable internal granule layer separate from that of

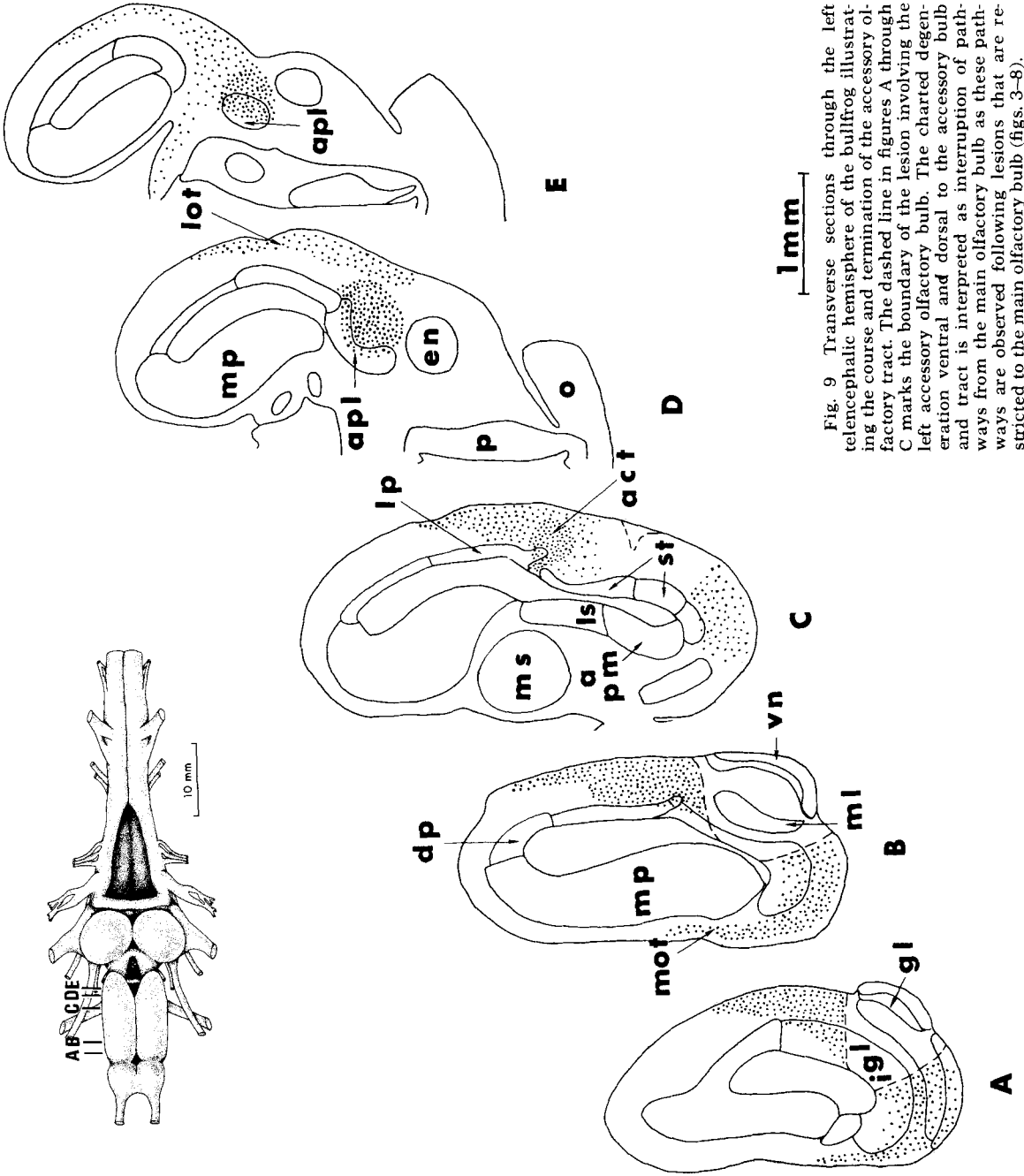


Fig. 9 Transverse sections through the left telencephalic hemisphere of the bullfrog illustrating the course and termination of the accessory olfactory tract. The dashed line in figures A through C marks the boundary of the lesion involving the left accessory olfactory bulb. The charted degeneration ventral and dorsal to the accessory bulb and tract is interpreted as interruption of pathways from the main olfactory bulb as these pathways are observed following lesions that are restricted to the main olfactory bulb (figs. 3-8).

the main olfactory bulb, this analytic complication cannot be avoided.

Comparison of the chartings of accessory olfactory bulb ablation (fig. 9) to those of main olfactory bulb ablation (figs. 3-8)

reveals the existence of a new degenerating pathway that is first seen collecting in an area lateral to the strio-pallial boundary (figs. 9C, 10B). This pathway was traced caudally where it terminated in the ipsi-

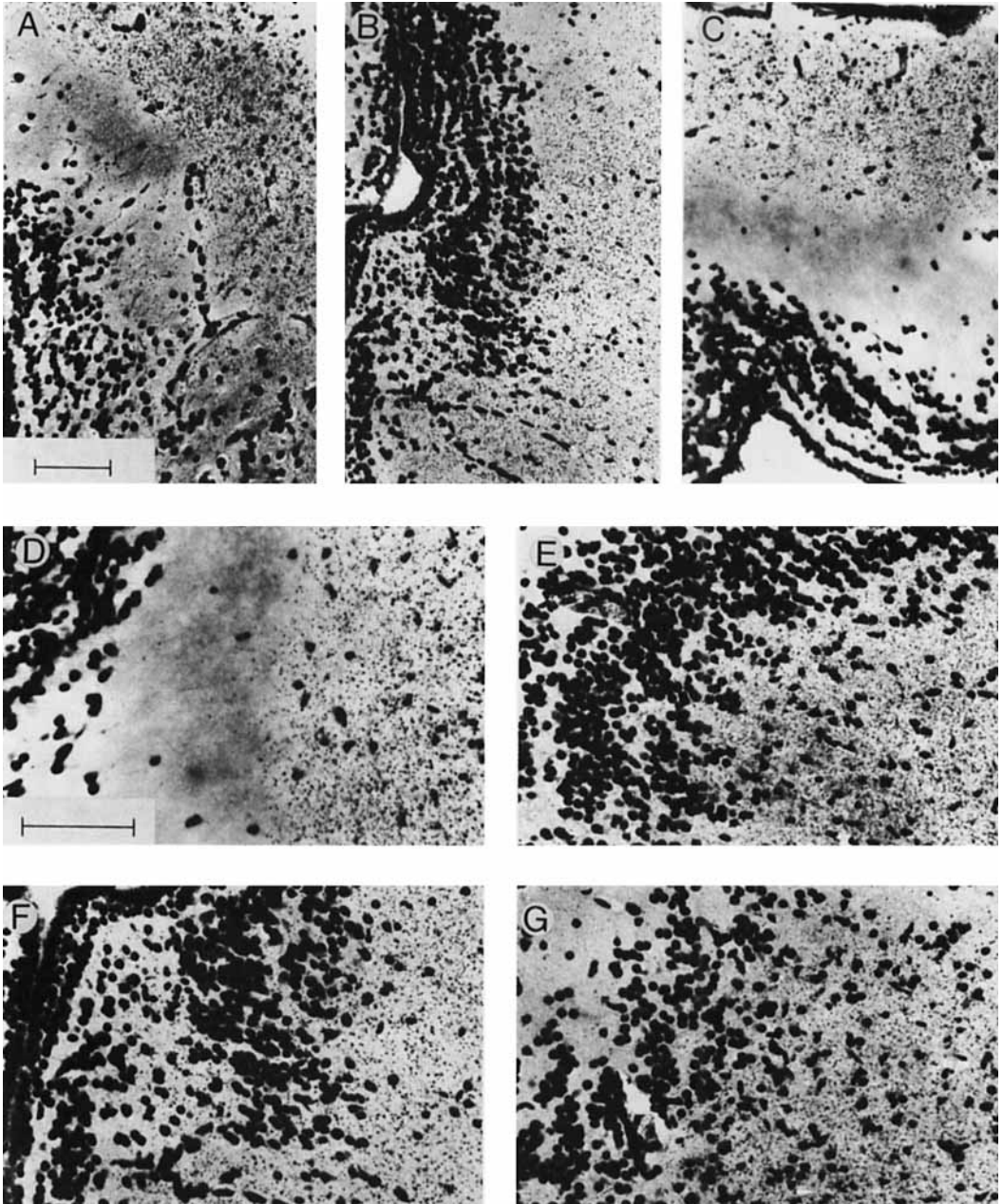


Figure 10

lateral pars lateralis of the amygdala (figs. 9D,E, 10E). The projection included the entire rostro-caudal extent of this nucleus including the extreme caudal portion labeled by Frontera ('52) as the anterior entopeduncular nucleus (fig. 10G). This pathway is termed the accessory olfactory tract and corresponds in part to the ventrolateral tract of Herrick ('21). Our material demonstrates that this projection enters the rostral pole of the pars lateralis of the amygdala from the external or lateral surface of the nucleus rather than the internal or ventricular surface as suggested by Herrick. While this pathway is clearly the major efferent pathway from the accessory olfactory bulb it may not be the sole one. Degenerating particles are also seen in the cell-free zone between the dorsal striatum and lateral pallium, as well as, in the deeper portions of the molecular zone of the lateral pallium (figs. 9B,C, 10B,F). Degenerating particles were never seen in these positions following lesions of the main olfactory bulb. Thus there may be additional projections from the accessory olfactory bulb, or there may be interrupted projections from other neural populations on their way to the lateral hemispheric wall. Further experimental studies on the

Fig. 10 Photomicrographs of degeneration following ablation of the accessory or main olfactory bulbs in the bullfrog. In all figures except C, the dorsal surface of the brain is toward the top of the figure. In C the dorsal surface is toward the right of the figure. Both bar scales represent 100 microns. The magnification of A, B and C is identical as is the magnification of D, E, F, and G. A. Degeneration in the ipsilateral lateral olfactory tract in the rostral lateral pallium at the same hemispheric level as figure 4 following ablation of the main olfactory bulb. B. Degeneration among the cells of the striopallial junction at the same hemispheric level as figure 9C following ablation of the accessory olfactory bulb. C. Degenerating ipsilateral lateral olfactory tract in the lateral pallium at a mid-hemispheric level following ablation of the main olfactory bulb. D. Higher magnification of the same pallial field as figure 10C to illustrate the size and nature of the degenerating particles seen after ablation of the main olfactory bulb. E. Degeneration in the pars lateralis of the amygdala following ablation of the accessory olfactory bulb. This terminal field is only observable following ablation of the accessory bulb. F. Higher magnification of the same ipsilateral strio-pallial junction as figure 10B to illustrate degeneration in the accessory olfactory tract following ablation of the accessory olfactory bulb. G. Degeneration in the ipsilateral, caudal pars lateralis of the amygdala following ablation of the accessory olfactory bulb. This field is at the same level as figure 9E.

projections of the forebrain are needed to resolve this problem.

#### DISCUSSION

*Olfactory pathways.* We believe that each olfactory nerve projects solely to the ipsilateral olfactory bulb even though argyrophilic particles are observed in the glomerular layer of the contralateral olfactory bulb. These contralateral particles are much smaller than those observed in the ipsilateral bulb, and their density does not vary with postoperative survival times nor were degenerating fibers ever traced from the ipsilateral to the contralateral olfactory bulb. Hence the contralateral olfactory bulb particles do not seem to be associated with anterograde degeneration.

The actual targets of the secondary olfactory pathways are difficult to determine due to the fine nature of the degenerating particles and their frequent position outside the cellular boundaries of the neural populations. The ipsilateral medial olfactory tract may project to the rostral ventromedial portion of the medial pallium, the postolfactory eminence and the rostral lateral septum as this pathway courses along the medial surface of these populations and their dendrites extend into the pathway (Hoffman, '63; Clairambault and Derer, '68). The medial septal nucleus is the most caudal target of the ipsilateral medial olfactory tract and is the only medial nucleus that demonstrates degenerating particles within its cellular boundary (fig. 5).

The ipsilateral olfactory tract probably projects to the dorsal striatum, the lateral pallium and the ventral half of the dorsal pallium as this pathway courses through the outer half of the molecular zones of all these neural populations (figs. 5, 6). Additionally the lateral olfactory tract could project to a restricted part of the pars lateralis of the amygdala since a ventral segment of this tract skirts the pars lateralis as it enters the stria medullaris (fig. 7). Rubaschkin ('03) suggested that the dendrites of some neurons in this telencephalic region reach the lateral olfactory tract. However, such a projection, if present, is minor in comparison to the massive projection of the accessory olfactory bulb to the pars lateralis of the amygdala (figs. 9, 10).

Our results also indicate the existence of crossed secondary olfactory pathways to the contralateral telencephalon. We believe two pathways exist which decussate through the habenular commissure after entering the ipsilateral stria medullaris. While lesions of the main olfactory bulb did not yield definitive evidence that these pathways cross in the habenular commissure as evinced by the clear presence of degenerating particles, degenerating particles were observed in both medullar striae and in the contralateral lateral and medial olfactory tracts. At least two other alternate interpretations of these results are possible: (1) the contralateral degeneration is due to damage to both olfactory bulbs, and (2) the contralateral degenerating pathways decussate in the interbulbar bridge formed by the continuation of the outer layers of the two main olfactory bulbs (fig. 3). If either of the alternate interpretations is correct, degenerating fibers should be observed in the interbulbar bridge and the degenerating pathways in the contralateral hemisphere should be in continuity with the main olfactory bulbs. In all experimental cases of lesions involving the main olfactory bulb, no degenerating fibers were ever observed crossing the interbulbar bridge and the degeneration in the contralateral lateral pallium was always restricted to the caudal half of the telencephalon (figs. 5-8). The most compelling evidence that the contralateral olfactory pathways decussate in the habenular commissure results from transection of the habenular commissure. In these preparations, degenerating particles were followed bilaterally from the stria medullaris into the lateral olfactory tracts of the telencephalon, as well as, from the stria medullaris into tracts which run ventrally and medially around the forebrain bundles to turn rostrally in the medial hemispheric wall just medial to the septal nuclei where these tracts terminate in the internal granule layer of the main olfactory bulbs. The crossed lateral pathway, the lateral corticohabenular tract, appears to terminate in a ventral portion of the dorsal pallium, the lateral pallium and a restricted dorsal portion of the dorsal striatum. The crossed medial pathway, the anterior olfactohabenular tract, terminates in the internal granule layer of the main olfactory bulb.

This pathway could also form connections with the periventricular preoptic nucleus as it skirts this formation laterally and/or the septal nuclei through which it passes on its way to the main olfactory bulb. While such connections can not be ruled out, it will require electron microscopic evidence to decide if such connections exist.

A major difference was seen in the rostral extent of the degeneration in the contralateral lateral olfactory tract following habenular commissural transection when compared to olfactory bulb ablation. Following transection of the habenular commissure, degenerating fibers in the lateral olfactory tracts were traced rostrally into both olfactory bulbs. However, following ablation of the main olfactory bulb, degenerating fibers were observed only in the caudal half of the contralateral hemisphere. This difference in degeneration might be the result of retrograde changes in the axons of cells located in the bulb, or more likely be due to interruption of an additional class of neurons that also project via the commissure but whose cell bodies are located in the retrobulbar hemisphere.

After lesions of the accessory olfactory bulb, a tract of degenerating fibers can be traced caudally to terminate massively in the ipsilateral pars lateralis of the amygdala (fig. 9). While projections to other targets (such as the dorsal striatum and lateral pallium) can not be ruled out since the dendrites of cells in these regions extend into the pathway, the main if not sole target of the accessory bulb appears to be the pars lateralis of the amygdala.

Our experimental results are in general agreement with those of Scalia et al. ('68) and Scalia ('72) on the olfactory projections in *Rana pipiens*. In addition to corroborating their earlier results on leopard frogs and extending these observations to bullfrogs, we recognize an additional crossed olfactory path, the anterior olfactohabenular tract, which projects to the internal granule layer of the contralateral main olfactory bulb. This difference in reported observations is most likely due to differences in interpreting criteria for recognizing degenerating fields or to differences in staining techniques rather than to species differences. Their earlier work relied on the original Nauta (Nauta, '57)

and modified Cajal (Romeis, '48) techniques rather than the later developed Fink-Heimer modifications (Fink and Heimer, '67).

*Phylogenetic problems.* Lateral and medial crossed olfactory pathways, similar to those here demonstrated, have been reported in reptiles (Gamble, '56; Heimer, '69; Scalia et al., '69; Northcutt, '70), but not in birds (Rieke and Wenzel, '73) or in mammals (Scalia, '68). Thus it is possible that amphibians and reptiles have independently evolved crossed olfactory pathways, or that ancestral land vertebrates possessed such pathways which were independently lost in birds and mammals. Information on other anamniotic olfactory projections is presently too fragmentary to relate to tetrapod olfactory projections. Phylogenetic questions of this nature may be answered by continued examination of variation among closely related radiations of recent animals. If future studies reveal crossed olfactory pathways in lungfish (Dipnoi) and/or generalized actinopterygian fishes, the argument for the presence of ancestral crossed pathways that were subsequently lost in birds and mammals would be greatly strengthened.

An alternative approach to this type of phylogenetic question involves investigation of the functional and adaptive significance of crossed olfactory pathways in different taxa. Such an analysis may pinpoint the selective pressures operating for crossed projections. If these pressures can be inferred to have existed in the ancestral population then we are probably dealing with retention of an ancestral character. On the other hand, if these pressures are restricted to descendant populations which have entered similar adaptive zones then we are probably dealing with the independent evolution of similar characters due to a common genome. Unfortunately, the functional significance of crossed olfactory projections is at present unknown.

The multiple evolution of new connections between cerebral hemispheres or their loss may seem unlikely, particularly if we assume that such characters are polygenic. However, Guillery et al. ('73) has recently shown similar changes in the bilaterality of retinal projections that are due to a single allele. This may be particularly true when we are dealing with

systems in which the genetic changes only reprogram ipsicontralateral differences in already existing targets rather than changes that utilize new targets for an expanding system.

*Telencephalic evolution.* Experimental studies on the main olfactory bulb of reptiles reveal that the primary target is the lateral pallium (Gamble, '56; Heimer, '69; Northcutt, '70; Scalia et al., '69; Halpern, '73). In frogs a comparable topographical region of the telencephalon also is the primary target of the main olfactory bulb (fig. 1A). However, in frogs the position of the lateral olfactory tract does not coincide with cytoarchitectonic boundaries as it does in reptiles. The anuran lateral olfactory tract projects to the ventral half of a more dorsally located compact zone of cells recognized as the dorsal pallium (fig. 1A). At present little is known regarding other possible projections to this dorsal region. Histochemical study of the dorsal pallium reveals a distinct band of succinate dehydrogenase activity in the outer plexiform zone (Northcutt, '74). Such activity is frequently associated with areas of high synaptic density such as sensory projection areas (Friede, '60). Based on the present available evidence, the dorsolateral hemispheric wall in anurans consists of two regions on either cytological or connectional criteria. However, the boundary between these two areas differs depending on the criterion used. Final recognition of a boundary should be facilitated by further experimental studies.

The most striking difference between the telencephalon of amphibians and reptiles is the presence of a dorsal ventricular ridge in reptiles (fig. 1B). This ridge consists of a rostral division containing the targets of thalamic nuclei concerned with vision and audition (Hall and Ebner, '70; Pritz, '72; Butler and Ebner, '72), and a caudal division containing a cup-shaped nucleus, nucleus sphaericus, which is the target of the accessory olfactory bulb (Heimer, '69; Halpern, '73).

Does the anuran telencephalon possess a neuronal field homologous to the reptilian dorsal ventricular ridge and if so, what is its topographical position? If the telencephalon of modern amphibians is comparable to that of the ancestral amphibians that gave rise to reptiles, then two possi-

bilities must be considered. The dorsal ventricular ridge could arise by migration of cells from either the striatum or the lateral pallium. At present three lines of evidence suggest that the reptilian dorsal ventricular ridge is homologous to a field of cells in the amphibian lateral pallium: (1) similarities in the histochemistry of the anuran lateral pallium and the reptilian dorsal ventricular ridge; (2) cellular continuity of the anuran pars lateralis of the amygdala with the lateral pallium and the probable homology of the anuran pars lateralis with the reptilian nucleus sphaericus; and (3) embryological evidence in reptiles that the lateral pallium and dorsal ventricular ridge represent subsequent migrations of the same matrix zone.

In both amphibians and reptiles the areas labeled as striatum in figure 1 contain high concentrations of acetylcholinesterase and biogenic monoamines while neither the anuran lateral pallium nor reptilian dorsal ventricular ridge demonstrate such concentrations (Shen et al., '55; Braak, '70; Parent and Oliver, '70; Kusunoki, '71; Parent, '71, '73; Northcutt, '74).

In amphibians the accessory olfactory bulb projects to the pars lateralis of the amygdala and in reptiles to nucleus sphaericus. It seems probable that these two nuclei are homologous as they both possess similar topographical positions within the telencephalon and both are the primary, if not sole, targets of the accessory olfactory bulb. An examination of the cytoarchitectonics further reveals that the anuran striatum continues caudally as the entopeduncular nucleus while the pars lateralis of the amygdala is a ventral continuation of the lateral pallium. In fact, there is no cell-free boundary between the lateral pallium and the pars lateralis of the amygdala.

Recent studies on the embryogenesis of the reptilian telencephalon suggest that the lateral pallium forms by a migration of neuroblasts from a periventricular position in the dorsolateral hemispheric wall and that the remaining neuroblasts differentiate in situ to form the dorsal ventricular ridge (Källén, '51; Kirsche, '72).

It is possible to argue that neurons could have migrated from the striatum in ancestral amphibians to form the dorsal ventricular ridge and in the process have

changed their biochemical properties. It is possible to argue that the connections of the anuran and reptilian accessory olfactory bulb evolved independently and do not project to homologous targets. It is possible to argue that due to yet unknown selective pressures reptilian embryos develop their telencephalon in a manner that spuriously correlates with a hypothesis regarding probable phylogenetic development. Yet evolutionary hypotheses and recognition of homologies are based on the number and degree of character similarities. The most parsimonious interpretation is that the anuran lateral pallium and pars lateralis of the amygdala are *field homologues* of the reptilian dorsal ventricular ridge and lateral cortex.

#### ACKNOWLEDGMENTS

The authors are pleased to thank Dr. Mark Braford who provided helpful suggestions, and Mr. Louis Martonyi for his expert assistance with the photography. Histological preparations were made by Mrs. Neena N. Shah and Mr. Homer Ferguson. This study was supported by National Institutes of Health Grant number R01 N508417 to R. G. N. and PHS Grant FR-5494 to G. J. R.

#### LITERATURE CITED

- Braak, H. 1970 Biogene Amine im Gehirn vom Frosch (*Rana esculenta*). Z. Zellforsch., 106: 269-308.
- Butler, A. B., and F. F. Ebner 1972 Thalamotellencephalic projections in the lizard *Iguana iguana*. Anat. Rec., 172: 282.
- Clairambault, P., and P. Derer 1968 Contributions à l'étude architectonique du Tèlencéphale des Ranides. J. Hirnforsch., 10: 123-172.
- Crosby, E. C. 1917 The forebrain of *Alligator mississippiensis*. J. Comp. Neur., 27: 325-364.
- Edinger, L. 1908 Bau der nervösen Zentralorgane. Second ed. F. C. W. Vogel, Leipzig, 334 pp.
- Fink, R. P., and L. Heimer 1967 Two methods for selective silver impregnation of degenerating axons and their synaptic endings in the central nervous system. Brain Res., 4: 369-374.
- Friede, R. L. 1960 Histochemical investigations on succinic dehydrogenase in the central nervous system. IV. A histochemical mapping of the cerebral cortex in the guinea pig. J. Neurochem., 5: 156-171.
- Frontera, J. G. 1952 A study of the anuran diencephalon. J. Comp. Neur., 96: 1-69.
- Gamble, H. J. 1956 An experimental study of the secondary olfactory connexions in *Testudo graeca*. J. Anat. (London), 90: 15-29.
- Gaupp, E. 1896 Anatomie des Frosches. Third ed. Friedrich Vieweg und Sohn, Braunschweig, 548 pp.



- Guillery, R. W., G. L. Scott, B. M. Cattnach and M. S. Deol 1973 Genetic mechanisms determining the central visual pathways of mice. *Science*, 179: 1014-1016.
- Hall, W. C., and F. F. Ebner 1970 Thalamotelencephalic projections in the turtle (*Pseudemys scripta*). *J. Comp. Neur.*, 140: 101-122.
- Halpern, M. 1973 Olfactory bulb and accessory olfactory bulb projections in the snake, *Thamnophis sirtalis*. *Anat. Rec.*, 175: 337.
- Heimer, L. 1969 The secondary olfactory connections in mammals, reptiles and sharks. *Ann. N. Y. Acad. Sci.*, 167: 129-146.
- Herrick, C. J. 1921 The connections of the vomeronasal nerve, accessory olfactory bulb and amygdala in Amphibia. *J. Comp. Neur.*, 33: 213-280.
- 1948 *The Brain of the Tiger Salamander*. The University of Chicago Press, 407 pp.
- Hoffman, H. H. 1963 The olfactory bulb, accessory olfactory bulb and hemisphere of some anurans. *J. Comp. Neur.*, 120: 317-368.
- Källén, B. 1951 On the ontogeny of the reptilian forebrain. Nuclear structures and ventricular sulci. *J. Comp. Neur.*, 95: 307-347.
- Kirsche, W. 1972 Die Entwicklung des Telencephalons der Reptilien und deren Beziehung zur Hirn-Bauplanlehre. *Nova Acta Leopoldina*, 37: 9-78.
- Kusunoki, T. 1971 The chemoarchitectonics of the turtle brain. *Yokohama Med. Bull.*, 22: 1-29.
- Nauta, W. J. H. 1957 Silver impregnation of degenerating axons. In: *New Research Techniques of Neuroanatomy*. W. F. Windle, ed. Thomas, Springfield, pp. 17-26.
- Northcutt, R. G. 1970 The telencephalon of the western painted turtle (*Chrysemys picta belli*). *Illinois Biological Monographs*, Urbana, 113 pp.
- 1974 Some histochemical observations on the telencephalon of the bullfrog, *Rana catesbeiana*. *J. Comp. Neur.*, 157: 379-390.
- Parent, A. 1971 Comparative histochemical study of the amygdaloid complex. *J. Hirnforsch.*, 13: 89-96.
- 1973 Distribution of monoamine-containing nerve terminals in the brain of the painted turtle, *Chrysemys picta*. *J. Comp. Neur.*, 148: 153-166.
- Parent, A., and A. Olivier 1970 Comparative histochemical study of the corpus striatum. *J. Hirnforsch.*, 12: 73-81.
- Pritz, M. B. 1972 Ascending projections of some auditory nuclei in *Caiman crocodilus*. *Anat. Rec.*, 172: 386-387.
- 1973 Connections of the alligator visual system: telencephalic projections of nucleus rotundus. *Anat. Rec.*, 175: 416.
- Ramon, P. 1896 L'encéphale des amphibiens. *Bibl. Anatomique*, 4: 232-252.
- Rieke, G. K., and B. M. Wenzel 1973 A neuro-anatomical investigation of the olfactory projection field in the pigeon (*Columba livia*). *Programs and Abstracts, 3rd Annual Meeting, Society for Neuroscience*, p. 177.
- Romeis, B. 1948 *Mikroskopische Technik*. Fifteenth ed. München: Leibniz Verlag, 695 pp.
- Rothig, P. 1912 Beiträge zur Studium des Zentralnervensystems der Wirbelthiere. 5. Die Zell- und Nervenordnungen im Vorderhirn der Amphibien, mit besonderer Berücksichtigung der Septumkerne und ihr Vergleich mit den Verhältnissen bei *Testudo* und *Lacerta*. *Verhandel. Koninkl. Akad. Wetensch. Amsterdam (ser. 2)*, 17: 3-23.
- 1926 Beiträge zum Studium des Zentralnervensystems der Wirbeltiere. 10. Über die Faserzüge im Vorder- und Zwischenhirn der Anuren. *Jahrb. Morphol. mikr. Anat.*, Abt. 2, Z. *Mikr. anat. Forsch.*, 5: 23-58.
- Rubaschkin, W. 1903 Zur Morphologie des Gehirns der Amphibien. *Archiv. Mikr. Anat. Entwickl.*, 62: 207-243.
- Scalia, F. 1968 A review of recent experimental studies on the distribution of the olfactory tracts in mammals. *Brain Behav. Evol.*, 1: 101-123.
- 1972 The projection of the accessory olfactory bulb in the frog. *Brain Res.*, 36: 409-411.
- Scalia, F., M. Halpern, H. Knapp and W. Riss 1968 The efferent connexions of the olfactory bulb in the frog: a study of degenerating unmyelinated fibers. *J. Anat.*, 103: 245-262.
- Scalia, F., M. Halpern and W. Riss 1969 Olfactory bulb projections in the South American caiman. *Brain Behav. Evol.*, 2: 238-262.
- Shen, S. C., P. Greenfield and E. J. Boell 1955 The distribution of cholinesterase in the frog brain. *J. Comp. Neur.*, 102: 717-744.