

an immune-mediated mechanism in delayed radiation injury to the brain, principally because of inflammatory infiltrates that are so frequently seen on microscopical examination [8, 10, 11]. Recently, Hart and associates [3] demonstrated that cerebral vasculitis can be produced by transfer of lymphocytes activated in vivo or in vitro after exposure to cerebral capillary endothelial cells. Endothelial cells injured or altered by radiation may also be capable of serving as a source of antigen to initiate a cerebral vasculitis.

Several approaches can be envisioned to define whether immune-mediated mechanisms contribute to the pathogenesis of delayed radiation necrosis. First, human biopsy or autopsy material can be studied immunohistochemically to search for antibody, complement, or immune complex localization. Second, the possibility of an immune contribution should be studied in a more controlled setting in experimental animals, in which models of radiation vasculitis have been developed [7, 11]. If an immune mechanism contributes in any way to the pathogenesis of delayed radiation necrosis, then immunosuppressive therapy may be beneficial in radiation brain injury.

Dr Groothuis is supported by grants from the National Institutes of Health (NS12745, NS00814, and NS20023). This project was also supported by the Boothroyd Foundation and the Richard M. Liliensfeld Brain Tumor Research Fund.

References

1. Caveness WF, Kemper TL, Brightman MW, et al: Directional character of vasogenic edema. *Adv Neurol* 29:271-291, 1978
2. Cochrane CG, Dixon FJ: Immune complex injury. In Samter M (ed): *Immunological Diseases*. Boston, Little, Brown, 1982, pp 210-229
3. Hart MN, Sadewasser KL, Cancelli PA, DeBault LE: Experimental autoimmune type of vasculitis resulting from activation of mouse lymphocytes to cultured endothelium. *Lab Invest* 48:419-427, 1983
4. Hoffman SA, Arbogast DN, Day TT, et al: Permeability of the blood cerebrospinal fluid barrier during acute immune complex disease. *J Immunol* 130:1695-1698, 1983
5. Hopewell JW: Late radiation damage to the central nervous system: a radiobiological interpretation. *Neuropathol Appl Neurobiol* 2:329-343, 1979
6. Lakha A: Immune complexes. In Jeffery MS, Dick WC (eds): *Clinics in Rheumatic Diseases*, Vol 9. Philadelphia, Saunders, 1983, pp 199-225
7. Levin VA, Edwards MS, Byrd A: Quantitative observations of the acute effects of x-irradiation on brain capillary permeability. *Int J Radiat Oncol Biol Phys* 5:1627-1631, 1979
8. Marks JE, Baglan RJ, Prasad SC, Blank WF: Cerebral radionecrosis: incidence and risk in relation to dose, time, fractionation and volume. *Int J Radiat Oncol Biol Phys* 7:243-252, 1981
9. Mikhael M: Radiation necrosis of the brain: correlation between computed tomography, pathology, and dose distribution. *J Comput Assist Tomogr* 2:71-80, 1978
10. Rottenberg DA, Chernik NL, Deck MDF, et al: Cerebral necrosis following radiotherapy of extracranial neoplasms. *Ann Neurol* 1:339-357, 1977
11. Rubenstein LJ: Tumors of the central nervous system. In Atlas of Tumor Pathology, second series, fascicle 6. Washington, DC, Armed Forces Institute of Pathology, 1972
12. Seibold JR, Buckingham RB, Medsger TA, Kelly RH: Cerebrospinal fluid immune complexes in systemic lupus erythematosus involving the central nervous system. *Semin Arthritis Rheum* 12:68-73, 1982

Increased Leukotriene C₄ and Vasogenic Edema Surrounding Brain Tumors in Humans

Keith L. Black, MD,* Julian T. Hoff, MD,*
John E. McGillicuddy, MD,*
and Stephen S. Gebarski, MD†

Leukotrienes are pharmacologically active compounds that promote vascular permeability. In this study we sought to determine whether tissue leukotriene-like immunoreactivity was increased in intracranial tumors associated with peritumoral edema. In 20 patients undergoing craniotomy tissue specimens were immediately frozen after removal and tissue leukotriene C₄ levels were determined by radioimmunoassay. An index of peritumoral edema was estimated from preoperative contrast-enhanced computed tomographic scans. There was a significant correlation between brain edema and tissue leukotriene levels ($p < 0.003$). Metastatic tumors ($n = 8$) had the highest leukotriene C₄ level at 13.8 ± 8.5 pg/mg tissue (mean \pm SE) and the highest index of edema 5.7 ± 1.8 . The mean leukotriene C₄ level in the gliomas ($n = 5$) was 6.2 ± 2.3 pg/mg tissue and the edema index was 2.1 ± 0.6 . There was no edema and no neoplasm in the temporal lobes removed for seizure ($n = 2$), and their level of leukotriene C₄ was 0.4 ± 0.1 pg/mg tissue. The formation of leukotriene C₄ is stimulated by intracranial tumors. Leukotrienes increase blood-brain barrier permeability and may be important in the formation of vasogenic edema surrounding tumors.

Black KL, Hoff JT, McGillicuddy JE, Gebarski SS:
Increased leukotriene C₄ and vasogenic
edema surrounding brain tumors in humans.
Ann Neurol 19:592-595, 1986

Leukotrienes (LTs) are biologically active hydroxy lipids (LTB₄) and peptidolipids (LTC₄, D₄, and E₄)

From the *Section of Neurosurgery, University of Michigan, Ann Arbor, MI 48109, and the †Division of Neuroradiology, University of Michigan, Ann Arbor, MI 48109.

Received June 17, 1985, and in revised form Sept 16. Accepted for publication Oct 27, 1985.

Address reprint requests to Dr Black, Section of Neurosurgery, 2124 Taubman Health Care Center, Box 0338, University of Michigan Hospitals, Ann Arbor, MI 48109.

formed from the unsaturated fatty acid arachidonic acid [14]. Leukotrienes have been shown to increase vascular permeability in postcapillary venules [1, 18], elicit erythema and wheal formation in skin [16], and produce coronary [10] and cerebral [17] vasoconstriction. We recently demonstrated that leukotriene B₄, C₄, or E₄ injected directly into brain parenchyma will significantly increase blood-brain barrier permeability, and we speculated that leukotrienes may be important in the generation of vasogenic brain edema [2, 3]. Since intracerebral neoplasms produce vasogenic brain edema, we sought to determine if leukotrienes could contribute to the development of peritumoral vasogenic edema.

Materials and Methods

Brain or tumor tissue was obtained from 20 patients undergoing craniotomy. Tissue was obtained from 8 patients with metastatic tumors, 5 patients with gliomas, 4 patients with meningiomas, 1 patient with a schwannoma, and 2 patients undergoing temporal lobectomy for seizures. Patients undergoing temporal lobectomy were considered controls since there was no evidence of neoplasm, infection, or injury on pathological examination. Tissue sample size ranged from 0.12 to 1.6 gm. In some patients several biopsies were obtained, including normal adjacent brain tissue, tumor periphery, and tumor core.

After removal, surgical specimens were immediately frozen in pentane that was cooled in dry ice. Samples were stored at -70°C until tissue extraction. Tissue LTC₄ levels were determined by radioimmunoassay using the New England Nuclear leukotriene C₄ [³H]radioimmunoassay kit (New England Nuclear, Boston, MA). The separation of antibody-antigen complexes from free antigen was achieved by the absorption of the free ³H tracer onto activated charcoal. The tissue samples were extracted using prostaglandin extraction methods previously described [4]. The limit of sensitivity was 3.7 pg per tube. The antibody cross-reacts 55% with LTD₄ and 8.6% with LTE₄. The cross-reactivity to LTB₄, prostaglandins, or unsaturated fatty acids was 0.006% or less.

Brain edema was determined from preoperative contrast-enhanced computed tomograms (CT) by a neuroradiologist (S. S. G.) who was unaware of the brain leukotriene levels. The tumor area was determined by measuring the maximum tumor diameter and the longest diameter perpendicular to the maximum diameter. From these two measurements an averaged diameter was determined and divided by 2 to approximate the average radius. For estimation of area, the tumor was assumed to represent a plane through the equator of a sphere. The averaged radius was squared and multiplied by π. The total abnormal area (tumor area plus edema area) was also determined by the same method. An edema index was then calculated by dividing the total abnormal area by the tumor area. Since a small neoplasm with a large area of surrounding edema could have the same absolute area of edema as a large tumor with a relatively small area of surrounding edema, we believe an edema index, which rep-

resents the ratio of edema to tumor size, is a better characterization of the edema surrounding a neoplasm. This determination yields similar results whether tumor area or tumor volume is measured.

Results

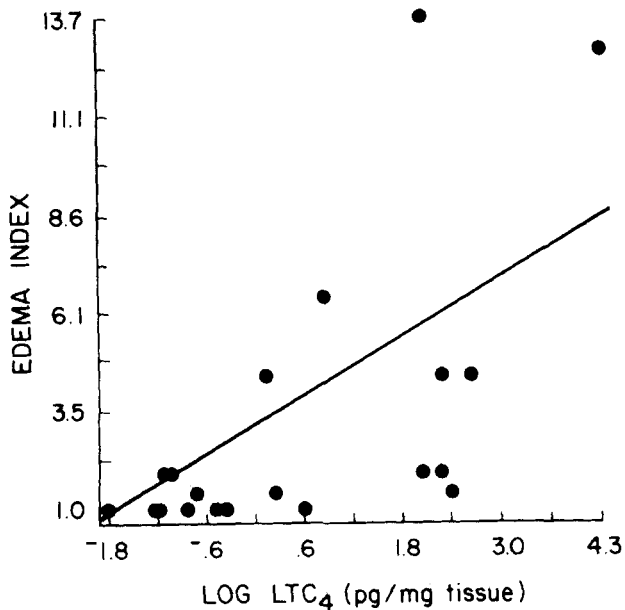
Metastatic tumors and gliomas had a significant amount of peritumoral edema (edema index, 5.7 ± 1.8 and 2.1 ± 0.6, respectively) and high LTC₄ levels (13.8 ± 8.5 and 6.2 ± 2.3 pg/mg tissue, respectively). There was no edema and no neoplasm in the temporal lobes removed for seizure (controls), and the LTC₄ level was 0.4 ± 0.1 pg/mg tissue (Table). One patient with a metastatic tumor had received radiation therapy three months prior to craniotomy. His CT scan prior to operation showed no peritumoral edema. The LTC₄ level in this patient was 0.16 pg/mg tissue. A second patient with a metastatic tumor had an edema index of 1.1 and an LTC₄ level of 1.9 pg/mg tissue. All other patients with metastatic tumor had an edema index of 1.6 to 12.8 and LTC₄ levels that ranged from 2.4 to 72.2 pg/mg tissue. In one patient with a schwannoma, without surrounding edema, an area of normal cerebellum was resected to expose the tumor. This cerebellar tissue had an LTC₄ level of 0.7 pg/mg brain and it is included with the control temporal lobes in the Table.

In order to satisfy the statistical assumptions of the analysis-of-variance model, analysis was done on the natural logarithm of the LTC₄ levels. There was a significant correlation between edema and the log LTC₄ levels with *p* < 0.003 and a correlation coefficient of 0.62185 (Figure). An analysis of covariance with edema as the dependent variable and the log LTC₄ as the covariable also revealed a significant relationship between the log LTC₄ and edema within the group distribution (*p* < 0.02) but no difference in the log LTC₄ levels between the groups.

In two patients with metastatic tumors and two patients with gliomas, nonneoplastic brain tissue immediately adjacent to the tumor was analyzed. The LTC₄ level in this tissue was 3.6 ± 1.1 (mean ± SE). This was significantly higher than the level in the control brain tissue at *p* < 0.003 using the two-sample *t*

Leukotriene C₄ Level and Index of Edema Surrounding Brain Tumors and Nonneoplastic Controls (mean ± SE)

Tumor Type	LTC ₄ Level (pg/mg tissue)	Edema Index
Controls (n = 3)	0.5 ± 0.1	1.0 ± 0.0
Metastatic tumors (n = 8)	13.8 ± 8.5	5.7 ± 1.8
Gliomas (n = 5)	6.2 ± 2.3	2.1 ± 0.6
Meningiomas (n = 4)	0.6 ± 0.2	1.6 ± 0.7



Graph showing relationship between the natural logarithm of the leukotriene C_4 (LTC_4) level and the edema index for all patients. There is a significant correlation between $\log LTC_4$ and edema at $p < 0.003$. The LTC_4 values are expressed as $\log LTC_4$ to satisfy the statistical assumptions of the analysis-of-variance model.

test. We have included in the Table only LTC_4 levels for the tumor itself.

Discussion

Brain lipids are rich in arachidonic acid. During cerebral injury membrane-bound arachidonic acid is released and the tissue content of free arachidonate can increase 20- to 40-fold [12]. Free arachidonic acid has been shown to produce vasogenic brain edema in a dose-dependent manner [6]. Free arachidonic acid is oxidized via two pathways: cyclooxygenase, leading to the formation of prostaglandins; and 5-lipoxygenase, leading to the formation of leukotrienes. We recently demonstrated that vasogenic edema induced by arachidonic acid can be prevented by pretreatment with a 5-lipoxygenase inhibitor, BW755C [3-amino-1-(3-trifluoromethylphenyl)-2-pyrazoline], but not by indomethacin, an inhibitor of cyclooxygenase [3]. This suggests that the ability of arachidonic acid to increase blood-brain barrier permeability is dependent on the formation of 5-lipoxygenase products (i.e., leukotrienes). Furthermore, we have shown that nanogram quantities of pure leukotrienes injected directly into brain significantly increase blood-brain barrier permeability [2, 3]. These observations taken together suggest that leukotrienes may be important in the formation of vasogenic brain edema.

Chan and co-workers [6] suggested that the ability of arachidonic acid to produce brain edema is not specific. They also reported increased edema after injections of linolenic acid, but not saturated fatty acids. Homa and colleagues [8], however, recently reported that polyunsaturated fatty acids, but not saturated fatty acids, stimulate the formation of lipoxygenase products from arachidonic acid. Therefore, theoretically, linolenic acid might increase edema by increasing the conversion of arachidonic acid to leukotrienes. Because the 5-lipoxygenase enzyme accepts a variety of polyunsaturated fatty acids as substrate, fatty acids with 19 to 21 carbons and with 3 or more unconjugated double bonds are converted to leukotrienes by the lipoxygenase enzyme.

Leukocytes and platelets are rich in the lipoxygenase enzyme and are known to accumulate in cerebral injury. The major pathway for arachidonic acid metabolism in leukocytes is via 5-lipoxygenase [13]. Platelets will convert arachidonic acid via 12-lipoxygenase to 12-L-hydroperoxy-5,8,10,14-eicosatetraenoic acid (12-HPETE). The 5-lipoxygenase enzyme is, in turn, activated by 12-HPETE [15] as well as prostaglandin endoperoxides [7], and the rate of arachidonic acid oxygenation by lipoxygenase is increased.

The tissue element or elements responsible for the conversion of arachidonic acid to leukotrienes in brain, however, has not been clearly defined. Moskowitz et al [11] suggested that leukotrienes were formed in brain gray matter. In support of this, leukotrienes C_4 , D_4 , and E_4 have been isolated after incubation of rat brain tissue with the ionophore A23187 and arachidonic acid in vitro [9]. We have demonstrated that severe leukopenia does not prevent arachidonic acid-induced vasogenic edema, which suggests that leukocytes may not be the major source for brain leukotriene production (unpublished observation, 1985).

Vasogenic edema associated with brain tumors, particularly metastatic and glial tumors, contributes to morbidity and mortality. We report here increased levels of LTC_4 -like immunoreactivity in brain tumors with peritumoral edema and suggest that one mechanism for peritumoral edema formation may be the elaboration of leukotrienes.

Meningiomas had low LTC_4 levels and less edema than did metastatic tumors or gliomas. The LTC_4 level in meningiomas, however, appeared disproportionately low. Unlike gliomas or metastatic tumors, meningiomas are extraaxial tumors and leukotriene formation in association with these tumors may occur in the brain parenchyma adjacent to the tumor rather than in the meningioma itself. We did not sample brain tissue adjacent to meningiomas.

Glucocorticoids reduce peritumoral edema [19]. Glucocorticoids also inhibit the release of free arachi-

donic acid, probably through the inhibition of phospholipase A₂, and reduce the formation of leukotrienes [5]. One mechanism by which glucocorticoids reduce vasogenic edema, therefore, may be through the reduction of leukotrienes.

Leukotrienes increase blood-brain barrier permeability, and we have observed that brain tumors stimulate the formation of LTC₄-like immunoreactivity. Although we believe the formation of brain edema is multifactorial, we suggest that leukotrienes are important in the formation of vasogenic brain edema. Selective inhibition of the 5-lipoxygenase enzyme could reduce peritumoral edema.

We thank Barry England, PhD, and Silviya Grauds of the Michigan Diabetes Research and Training Center Ligand Core for performing the leukotriene C₄ radioimmunoassay.

References

1. Bjork J, Arfors KE: Oxygen free radicals and leukotriene B₄ induce increase in vascular leakage is mediated by polymorphonuclear leukocytes. *Agents Actions (Suppl)* 7:63-72, 1982
2. Black KL: Leukotriene C₄ induces vasogenic cerebral edema in rats. *Prostaglandins Leukotrienes Med* 14:339-340, 1984
3. Black KL, Hoff JT: Leukotrienes increase blood-brain barrier permeability following intraparenchymal injections in rats. *Ann Neurol* 18:349-351, 1985
4. Black KL, Hsu S, Radin NS, Hoff JT: Effect of intravenous eicosapentaenoic acid on cerebral blood flow, edema and brain prostaglandins in ischemic gerbils. *Prostaglandins* 28:545-556, 1984
5. Blackwell GJ, Carnuccio R, Di Rosa M, et al: Macrocortin: a polypeptide causing the antiphospholipase effects of glucocorticoids. *Nature* 287:147-149, 1980
6. Chan PH, Fishman RA, Caronna J, et al: Induction of brain edema following intracerebral injection of arachidonic acid. *Ann Neurol* 13:625-632, 1983
7. Hamberg M, Hamberg G: On the mechanism of the oxygenation of arachidonic acid by human platelet lipoxygenase. *Biochem Biophys Res Commun* 95:1090-1097, 1980
8. Homa ST, Conroy DM, Smith AD: Unsaturated fatty acids stimulate the formation of lipoxygenase and cyclooxygenase products in rat spleen lymphocytes. *Prostaglandins Leukotrienes Med* 14:417-427, 1984
9. Lindgren JA, Hokfelt T, Dahlen SE, et al: Leukotrienes in the rat central nervous system. *Proc Natl Acad Sci USA* 81:6212-6216, 1984
10. Michelassi F, Landa L, Hill RD, et al: Leukotriene D₄: a potent coronary artery vasoconstrictor associated with impaired ventricular contraction. *Science* 217:841-843, 1982
11. Moskowitz MA, Kiwak KJ, Hekimian K, Levine L: Synthesis of compounds with properties of leukotrienes C₄ and D₄ in gerbil brains after ischemia and reperfusion. *Science* 224:886-888, 1984
12. Rehncrona S, Westerberg E, Akesson B, Siesjo BK: Brain cortical fatty acids and phospholipids during and following complete and severe incomplete ischemia. *J Neurochem* 38:84-93, 1982
13. Samuelsson B: Leukotrienes: mediators of immediate hypersensitivity reactions and inflammation. *Science* 220:568-575, 1983
14. Samuelsson B, Paoletti R (eds): *Leukotrienes and Other Lipoxygenase Products*. New York, Raven, 1982
15. Siegel MI, McConnell RT, Abrams SL, et al: Regulation of arachidonate metabolism via lipoxygenase and cyclo-oxygenase by 12-HPETE, the product of human platelet lipoxygenase. *Biochem Biophys Res Commun* 89:1273-1280, 1979
16. Soter NA, Lewis RA, Corey EJ, Austen KF: Local effects of synthetic leukotrienes (LTC₄, LTD₄, LTE₄, and LTB₄) in human skin. *J Invest Dermatol* 80:115-119, 1983
17. Tagari P, Du Boulay GH, Aitken V, Boullin DJ: Leukotriene D₄ and the cerebral vasculature *in vivo* and *in vitro*. *Prostaglandins Leukotrienes Med* 11:281-297, 1983
18. Ueno A, Tanaka K, Katori M, et al: Species difference in increased vascular permeability by synthetic leukotriene C₄ and D₄. *Prostaglandins* 21:637-647, 1981
19. Yamada K, Ushio Y, Hayakawa T, et al: Effects of methylprednisolone on peritumoral brain edema. *J Neurosurg* 59:612-619, 1983

Kernicterus in an Adult

Marco Waser, MD,* Paul Kleihues, MD,* and Paul Frick, MD†

A 43-year-old woman was initially seen because of icterus. Clinical investigations revealed severe hepatic damage probably due to non-A, non-B hepatitis. She was treated with extracorporeal charcoal-column perfusion but died two weeks later in a hepatic coma. At autopsy, the brain showed kernicterus with typical discoloration of the hippocampus, the subthalamic nuclei, and the cerebellar dentate nuclei. Kernicterus in an adult is very rare. In this case, extracorporeal charcoal-column perfusion treatment led repeatedly to severe depletion of fibrinogen, with extensive hemorrhages. Overload of the already reduced hepatic glucuronyl-transferase capacity resulted in high serum levels of unconjugated bilirubin, an apparent prerequisite for the development of bilirubin encephalopathy.

Waser M, Kleihues P, Frick P: Kernicterus in an adult. *Ann Neurol* 19:595-598, 1986

The term *kernicterus* refers to bilirubin encephalopathy in children with icteric discoloration of the basal ganglia, especially the globus pallidus, the hippocampus,

From the *Laboratory of Neuropathology, Institute of Pathology, and †Department of Medicine, University Hospital, 8091 Zürich, Switzerland.

Received July 7, 1985, and in revised form Sept 24. Accepted for publication Oct 27, 1985.

Address reprint requests to Dr Kleihues, Institut für Pathologie, Universitätsspital, 8091 Zürich, Switzerland.