

## Case Reports

# Superior Vena Cava Thrombectomy with the X-SIZER<sup>®</sup> Catheter System in a Child with Fontan Palliation

Jeffrey G. Gossett, MD, Albert P. Rocchini, MD, and Aimee K. Armstrong,\* MD

**A 4-year-old female with hypoplastic left heart syndrome and Fontan palliation presented with severe neurologic impairment from thrombosis of the superior vena cava (SVC). She underwent successful SVC thrombectomy with the X-SIZER<sup>®</sup> Thrombectomy Catheter System, followed by balloon angioplasty. She demonstrated rapid improvement in her neurologic deficits after the procedure. This represents the first published use of the X-SIZER in a child and its first published use for SVC thrombectomy.** © 2006 Wiley-Liss, Inc.

**Key words:** thrombectomy; X-SIZER<sup>®</sup> catheter system; SVC syndrome; Fontan; hypoplastic left heart syndrome; stroke

## INTRODUCTION

The final stage in surgical palliation for children with univentricular hearts is the Fontan procedure. During this surgery, the systemic venous return is connected directly to the pulmonary circulation. Since the flow within this circuit is passive, even a small degree of obstruction can have significant clinical impact on pulmonary blood flow and cardiac output [1]. Venous thromboses and superior vena cava (SVC) obstruction in Fontan patients have been reported with significant morbidity and mortality [2–5]. In addition, obstruction to SVC flow can cause elevation in the venous pressure of the head, upper extremities, and thorax, leading to SVC syndrome. With severe obstruction, venous infarction can occur [6].

The X-SIZER<sup>®</sup> Thrombectomy Catheter System (ev3, Inc., Plymouth, MN) consists of a rotating helical cutter attached to a vacuum reservoir. The catheter is advanced through a thrombus over a wire, and clot and debris are deposited into the vacuum container. The device has been used in adults for thrombectomy in saphenous vein grafts and native coronary arteries [7–9]. To date, there has been no report of the use of the X-SIZER in a pediatric patient or in the SVC. We present a case of SVC thrombectomy with the X-SIZER, followed by balloon angioplasty, in a child with Fontan palliation and complete SVC occlusion.

## CASE REPORT

### History

The patient is a 4-year-old girl who was prenatally diagnosed with hypoplastic left heart syndrome (HLHS) and electively delivered at our institution. Because of

necrotizing enterocolitis, the Norwood procedure was delayed until 17 days of age. She required reoperation on the same day for residual ascending aortic obstruction and could not be weaned from cardiopulmonary bypass. She was transitioned to extracorporeal membrane oxygenation (ECMO) via thoracic cannulae. After four days, she weaned from ECMO and was discharged 6 weeks later.

She returned at 7 months of age for Hemi-Fontan surgery, after which she required right hemi-diaphragm plication for diaphragmatic paralysis and thoracic duct ligation for persistent chylous effusions. Prior to discharge, echocardiogram revealed a possible thrombus in the Hemi-Fontan baffle. Therefore, she underwent cardiac catheterization, which did not show an obvious thrombus in the baffle but did show the left innominate, left internal jugular (IJ), and left subclavian veins to be partially occluded with thrombus. She was discharged 6 weeks postoperatively on aspirin therapy. At 30 months of age,

Division of Pediatric Cardiology, Department of Pediatrics and Communicable Diseases, University of Michigan Health System, Ann Arbor, Michigan

\*Correspondence to: Aimee K. Armstrong, MD, L1242 Women's, Box 0204, University of Michigan Health System, 1500 East Medical Center Drive, Ann Arbor, MI 48109-0204, USA.  
E-mail: aimeearm@umich.edu

Received 14 June 2006; Revision accepted 2 August 2006

DOI 10.1002/ccd.20927

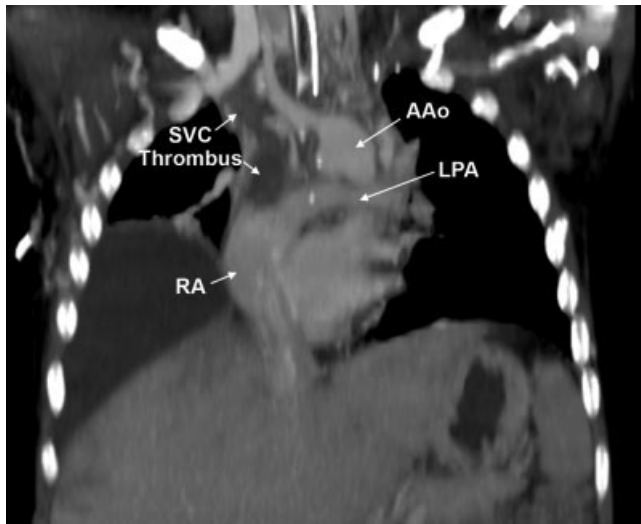
Published online 30 November 2006 in Wiley InterScience (www.interscience.wiley.com).

a lateral tunnel Fontan was performed with creation of a 4 mm fenestration. Preoperatively, her SVC was shown to be widely patent by echocardiogram. Her postoperative course was unremarkable, and low velocity, unobstructed flow was documented by echocardiogram in her SVC prior to discharge.

The patient was diagnosed with protein losing enteropathy 6 months after the Fontan operation. Then, at 4 years of age, she developed the acute onset of neurologic changes, consisting of involuntary movements of her right arm and leg and speech deficits. Evaluation at a referring institution included multiple head CTs, which were all normal, despite clinical concern for a cerebral vascular accident. A tunneled central venous catheter

was placed in the right IJ vein, which led to swelling of the right arm and head. After 3 weeks, the catheter was removed with prompt resolution of the swelling, but the neurologic symptoms worsened with loss of head control and the ability to sit. She also developed choreoathetoid movements and progressive dysarthria and oral apraxia. At that time, echocardiogram and CT revealed possible thrombus in her Fontan pathway and pulmonary arteries. Therefore, she was referred to our institution for further evaluation.

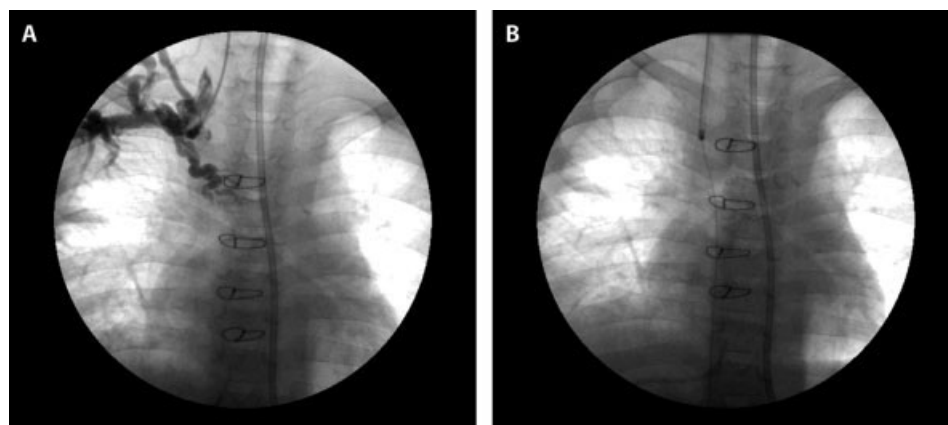
Our evaluation included a chest CT, which demonstrated complete occlusion of the SVC with thrombus (Fig. 1). The left IJ and innominate veins were also occluded. An MRI of the brain was obtained and was normal without evidence of edema, hemorrhage, or ischemic insult. As there was no evidence to support either ischemic or hemorrhagic stroke, other etiologies of her neurologic symptoms were ruled out, including toxicities, vitamin deficiencies, infection, neoplasm, and rheumatologic disorders. With no identifiable etiology, it was hypothesized that impairment of brain function, particularly in the basal ganglia, could be caused by elevated cerebral venous pressure from SVC thrombosis. The patient was referred to the cardiac catheterization laboratory for attempted thrombectomy of her SVC.



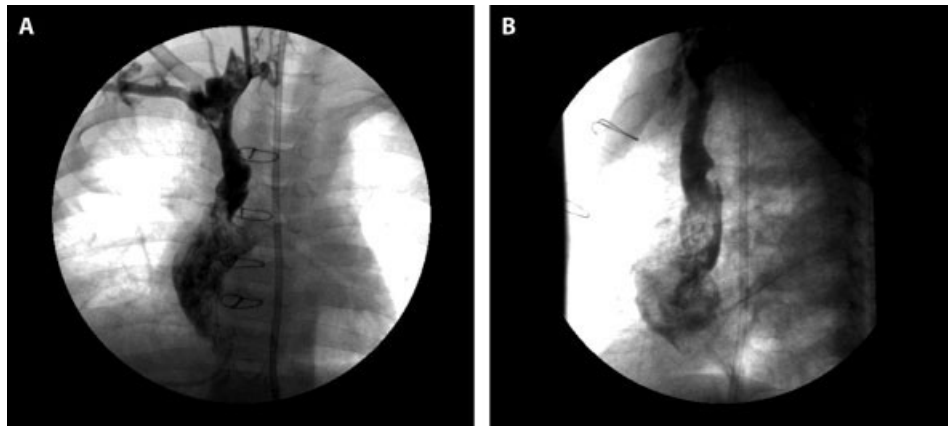
**Fig. 1.** Chest CT before intervention documenting occlusion of the SVC by thrombus. SVC, superior vena cava; RA, right atrium; LPA, left pulmonary artery; AAO, ascending aorta. Incidental note is made of the large right pleural effusion.

### Procedure

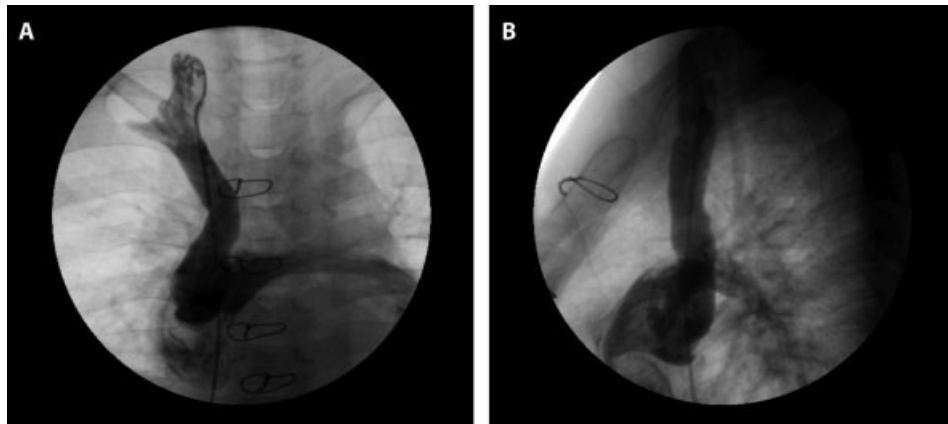
Continuous arterial pressure monitoring was performed through an existing arterial line. A 7 French sheath was placed in her right IJ vein, using ultrasound guidance. The mean pressure in her right IJ vein was 25 mm Hg. A hand injection of contrast was performed through the sheath, documenting occlusion of her SVC and a small, tortuous collateral vessel supplying minimal decompression (Fig. 2A). A 4 French Bentson–Hanaford–Wilson 1 glide catheter (Terumo Medical, Somerset



**Fig. 2.** Angiography immediately before thrombectomy. (A) Complete occlusion of the SVC is seen. A tortuous collateral vessel partially decompresses the cerebral venous circulation. (B) The X-SIZER in the right IJ vein with a 0.014" wire through the area of thrombosis.



**Fig. 3.** Angiography of the SVC after thrombectomy in the AP (A) and lateral (B) projections showing patency of the SVC with brisk flow into the Fontan pathway. There are small residual filling defects at the SVC/Fontan junction.



**Fig. 4.** Angiography obtained 3 months after thrombectomy in the AP (A) and lateral (B) projections showing the widely patent SVC and Fontan pathway with the resolution of the filling defects.

NJ) and a 0.035" 180 cm stiff angled glide wire (Terumo Medical, Somerset NJ) were advanced easily through the occluded SVC into the inferior vena cava (IVC). The mean pressure in the Fontan pathway and IVC was 15 mm Hg. The glide wire was exchanged for a 0.014" Steerable Stabilizer XS wire with a 3 cm tip (Cordis Corp., Miami Lakes, FL), and the catheter was exchanged for a 2 mm X-SIZER (Fig 2B). Multiple passes through the SVC thrombus were made with the X-SIZER until the 100 cc vacuum bottle was filled. Because of the blood loss, 100 cc of packed red blood cells (PRBC) were transfused into the patient. A repeat angiogram was performed and demonstrated flow into the Fontan pathway from the SVC but with residual thrombus. Additional passes were made with the X-SIZER until another 60 ml of debris and blood were removed. A third angiogram showed continued increase in the caliber of the SVC with flow into the left pulmo-

nary artery. Serial balloon dilations of the SVC were then performed, first with a Tyshak II 8 mm × 2 cm balloon (B. Braun Medical Inc., Bethlehem, PA), then with a 10 mm × 3 cm balloon.

Repeat angiogram of the right IJ vein demonstrated residual thrombus at the right IJ/SVC junction. Multiple passes were made with the X-SIZER with removal of an additional 30 ml of clot and blood from the right IJ, followed by static dilation with the 8 mm angioplasty balloon. An additional 100 cc of PRBC were transfused to the patient. At that point, the mean pressure in the right IJ was 20 mm Hg with a Fontan pathway pressure of 16 mm Hg. A final angiogram was performed showing a patent SVC with brisk flow into the Fontan pathway and pulmonary arteries with a few areas of small filling defects (Fig. 3A and B). The patient tolerated the procedure well with no complications. The total procedure time was 127 min with 26 min of fluoroscopy time and

28 cc of contrast delivered. The IJ venous sheath was removed, and the patient was transported back to the intensive care unit, where a heparin infusion was restarted.

### Follow-up

During the following few days, her speech began to improve, and the involuntary movements decreased. She was transitioned from heparin infusion to warfarin, and aggressive rehabilitation was undertaken. After a 6 week hospitalization, she was discharged home ambulating and speaking in short sentences with no involuntary movements.

The patient returned to the cardiac catheterization laboratory 3 months later for removal of a trans-hepatic peripherally inserted central catheter. Her SVC mean pressure was 16 mm Hg with a Fontan pathway pressure of 15 mm Hg. SVC angiography showed a widely patent SVC with no filling defects (Fig. 4A and B).

At the most recent follow-up, she was able to run and to follow multi-step commands. Her speech was fluent, but she exhibited some persistent, mild speech delay.

### DISCUSSION

Embolic cerebrovascular accidents in patients with single ventricles have been well described [3,10,11]. In addition, obstruction of the SVC in patients with Fontan circulation can lead to pulmonary embolism, which can be catastrophic [3]. Neurologic changes due to SVC obstruction, however, have not been reported in patients with Fontan circulation. In our patient's case, once cerebrovascular accident had been ruled out, we hypothesized that the elevation of cerebral venous pressure from SVC thrombosis was causing her neurologic symptoms that mimicked a stroke.

Given the severity of her neurologic deficits, we felt that rapid relief of the obstruction was indicated. There are limited data available on the optimal approach to thrombectomy in the single ventricle patient. Surgical and thrombolytic approaches have been attempted with mixed results [1–5,12]. While these therapies were considered, the overall risks were felt to be higher than for percutaneous intervention. We did not believe that balloon angioplasty alone would adequately relieve the obstruction, without preceding it by thrombectomy. We also felt that SVC stenting might lead to later development of thrombus within the stent [13]. Therefore, we elected to attempt percutaneous thrombectomy, followed by balloon angioplasty, in order to lower the cerebral venous pressure.

The AngioJet<sup>®</sup> system (Possis Medical, Minneapolis, MN) and the X-SIZER Thrombectomy Catheter System

were considered for the trans-catheter approach. There have been two reports of the use of the AngioJet in patients with Fontan circulation, including one adult patient in whom it successfully removed a large pulmonary embolism [14] and one child in whom it removed a thrombus within a pulmonary artery stent [13]. The major disadvantage of this system, however, is the sizable financial outlay necessary. In a pediatric catheterization laboratory, where the use of the device is limited, the cost may be prohibitive. As the X-SIZER is a self-contained, disposable system, no capital outlay is necessary.

Using the same technique as has been described for smaller vessels, the X-SIZER thrombectomy, followed by balloon angioplasty, successfully relieved the SVC obstruction with only minimal residual thrombus. The patient's rapid neurologic improvement, after decrease in right IJ mean pressure, validates our diagnosis and suggests that elevation in cerebral venous pressure was the etiology for her neurologic changes. Repeat angiography 3 months later documented excellent durability of the results with no residual thrombus or stenosis.

A potential limitation of thrombectomy catheters is that a wire must be passed through the lesion. In our case, we were able to easily advance a glide wire through the thrombus. Care must be taken to assure that the wire does not perforate the vessel wall, as severe hemorrhage could occur if the device were to be advanced through the vessel wall. Another potential limitation of the X-SIZER is the blood loss associated with the vacuum technology. While this serves to remove clot and debris, whole blood is also removed. In our 16 kg patient, we removed a total of 200 cc of clot and debris mixed with whole blood, which represents ~13% of our patient's total blood volume. We opted to replace the loss with 200 cc of PRBC.

### CONCLUSIONS

We report the successful use of the X-SIZER Thrombectomy Catheter System for SVC thrombectomy in a child with Fontan palliation for HLHS. Severe neurologic impairment, due to elevated cerebral venous pressure from SVC thrombosis, was reversed after the thrombectomy. To our knowledge, this is the first report of neurologic complications from this etiology in a pediatric patient with Fontan circulation. This is also the first report of the use of the X-SIZER in a child and its first use for SVC thrombectomy. Further investigation and long-term follow-up is warranted to assess the use of this device in the SVC and in children with congenital heart disease.

## REFERENCES

1. Marcelletti CF, Hanley FL, Mavroudis C, McElhinney DB, Abella RF, Marianeschi SM, Seddio F, Reddy VM, Petrossian E, de la Torre T, et al. Revision of previous Fontan connections to total extracardiac cavopulmonary anastomosis: A multicenter experience. *J Thorac Cardiovasc Surg* 2000;119:340–346.
2. Fletcher SE, Case CL, Fyfe DA, Gillette PC. Clinical spectrum of venous thrombi in the Fontan patient. *Am J Cardiol* 1991;68:1721, 1722.
3. Seipelt RG, Franke A, Vazquez-Jimenez JF, Hanrath P, Bernuth GV, Messmer BJ, Muhler EG. Thromboembolic complications after Fontan procedures: Comparison of different therapeutic approaches. *Ann Thorac Surg* 2002;74:556–562.
4. Monagle P. Thrombosis in children with BT shunts, Glenns and Fontans. *Prog Pediatr Cardiol* 2005;21:17–21.
5. Rosenthal DN, Friedman AH, Kleinman CS, Kopf GS, Rosenfeld LE, Hellenbrand WE. Thromboembolic complications after Fontan operations. *Circulation* 1995;92:287–293.
6. Bozzao A, Gallucci M, Marsili L, Cerone G. Recurrent cerebral venous infarcts and superior vena obstruction: Case report. *Neuroradiology* 1997;39:414–417.
7. Constantinides S, Lo TSN, Been M, Shiu MF. Early experience with a helical coronary thrombectomy device in patients with acute coronary thrombosis. *Heart* 2002;87:455–460.
8. Stone GW, Cox DA, Babb J, Nukta D, Bilodeau L, Cannon L, Stuckey TD, Hermiller J, Cohen EA, Low R, et al. Prospective, randomized evaluation of thrombectomy in diseased saphenous vein grafts and thrombus-containing coronary arteries. *J Am Coll Cardiol* 2003;42:2007–2013.
9. Stone GW, Cox DA, Low R, Cates CU, Satler L, Bailey SR, Kuntz RE, Lansky AJ. Safety and efficacy of a novel device for treatment of thrombotic and atherosclerotic lesions in native coronary arteries and saphenous grafts: Results from the multicenter X-Sizer for treatment of thrombus and atherosclerosis in coronary applications trial (X-Tract) study. *Catheter Cardiovasc Interv* 2003;58:419–427.
10. Barker PCA, Nowak C, King K, Mosca RS, Bove EL, Goldberg CS. Risk factor for cerebrovascular events following Fontan palliation in patients with a functional single ventricle. *Am J Cardiol* 2005;96:587–591.
11. du Plessis AJ, Chang AC, Wessel DL, Lock JE, Wernovsky G, Newburger JW, John EM. Cerebrovascular accidents following the Fontan operation. *Pediatr Neurol* 1995;12:230–236.
12. Hedrick M, Elkins RC, Knott-Craig CJ, Razoook JD. Successful thrombectomy for thrombosis of the right side of the heart after the Fontan operation. Report of two cases and review of the literature. *J Thorac Cardiovasc Surg* 1993;105:297–301.
13. Vincent RN, Dinkins J, Dobbs MC. Mechanical thrombectomy using the AngioJect (sic) in a child with congenital heart disease. *Catheter Cardiovasc Interv* 2004;61:253–255.
14. Brenes JC, Ferreira A, Galindo A. A pulmonary embolism treated with the AngioJet technique in a patient with double outlet right ventricle. *J Invasive Cardiol* 2004;16:42–44.