

MISCELLANEOUS PUBLICATIONS
MUSEUM OF ZOOLOGY, UNIVERSITY OF MICHIGAN, NO. 124

**The Comparative Myology of Four
Dipodoid Rodents (Genera *Zapus*,
Napaeozapus, *Sicista*, and *Jaculus*)**

BY
DAVID KLINGENER

ANN ARBOR
MUSEUM OF ZOOLOGY, UNIVERSITY OF MICHIGAN
SEPTEMBER 30, 1964

MISCELLANEOUS PUBLICATIONS
MUSEUM OF ZOOLOGY, UNIVERSITY OF MICHIGAN

The publications of the Museum of Zoology, University of Michigan, consist of two series—the Occasional Papers and the Miscellaneous Publications. Both series were founded by Dr. Bryant Walker, Mr. Bradshaw H. Swales, and Dr. W. W. Newcomb.

The Occasional Papers, publication of which was begun in 1913, serve as a medium for original studies based principally upon the collections in the Museum. They are issued separately. When a sufficient number of pages has been printed to make a volume, a title page, table of contents, and an index are supplied to libraries and individuals on the mailing list for the series.

The Miscellaneous Publications, which include papers on field and museum techniques, monographic studies, and other contributions not within the scope of the Occasional Papers, are published separately. It is not intended that they be grouped into volumes. Each number has a title page and, when necessary, a table of contents.

A complete list of publications on Birds, Fishes, Insects, Mammals, Mollusks, and Reptiles and Amphibians is available. Address inquiries to the Director, Museum of Zoology, Ann Arbor, Michigan

LIST OF MISCELLANEOUS PUBLICATIONS ON MAMMALS

No. 24.	A comparative life history study of the mice of the Genus <i>Peromyscus</i> . By ARTHUR SVIHLA. (1932) 39 pp.	\$0.50
No. 25.	The moose of Isle Royale. By ADOLPH MURIE. (1934) 44 pp., 7 pls....	\$0.70
No. 26.	Mammals from Guatemala and British Honduras. By ADOLPH MURIE. (1935) 30 pp., 1 pl., 1 map	\$0.35
No. 32.	Following fox trails. By ADOLPH MURIE. (1936) 45 pp., 6 pls., 6 figs...	\$1.00
No. 38.	Revision of <i>Sciurus variegatoides</i> , a species of Central American Squirrel. By WILLIAM P. HARRIS, JR. (1937) 39 pp., 3 pls., (2 colored), 3 figs., 1 map	\$0.50
No. 39.	Faunal relationships and geographic distribution of mammals in Sonora, Mexico. By WILLIAM H. BURT. (1938) 77 pp., 26 maps	\$0.75
No. 45.	Territorial behavior and populations of some small mammals in southern Michigan. By WILLIAM H. BURT. (1940) 58 pp.	out of print
No. 46.	A contribution to the ecology and faunal relationships of the mammals of the Davis Mountain Region, southwestern Texas. By W. FRANK BLAIR. (1940) 39 pp., 3 pls., 1 map	\$0.35
No. 51.	Mammals of the lava fields and adjoining areas in Valencia County, New Mexico. By EMMET T. HOOPER. (1941) 47 pp., 3 pls., 1 map	\$0.50
No. 52.	Type localities of pocket gophers of the Genus <i>Thomomys</i> . By EMMET T. HOOPER. (1941) 26 pp., 1 map	\$0.25
No. 58.	A systematic review of the Neotropical water rats of the Genus <i>Nectomys</i> (Cricetinae). By PHILIP HERSHKOVITZ. (1944) 88 pp., 4 pls., 5 figs., 2 maps	\$1.15
No. 59.	San Francisco Bay as a factor influencing speciation in rodents. By EMMET T. HOOPER. (1944) 89 pp., 5 pls., 18 maps	\$1.25
No. 72.	Faunal relationships of Recent North American rodents. By EMMET T. HOOPER. (1949) 28 pp.	\$0.35
No. 73.	A study of small mammal populations in northern Michigar. By RICHARD H. MANVILLE. (1949) 83 pp., 4 pls., 6 figs., 1 map	\$1.25
No. 77.	A systematic review of the harvest mice (Genus <i>Reithrodontomys</i>) of Latin America. By EMMET T. HOOPER. (1952) 255 pp., 9 pls., 24 figs., 12 maps	\$4.00
	Cloth bound	\$4.60

MISCELLANEOUS PUBLICATIONS
MUSEUM OF ZOOLOGY, UNIVERSITY OF MICHIGAN, NO. 124

**The Comparative Myology of Four
Dipodoid Rodents (Genera *Zapus*,
Napaeozapus, *Sicista*, and *Jaculus*)**

BY
DAVID KLINGENER

ANN ARBOR
MUSEUM OF ZOOLOGY, UNIVERSITY OF MICHIGAN
SEPTEMBER 30, 1964

CONTENTS

	PAGE
INTRODUCTION	5
ACKNOWLEDGMENTS	7
MATERIALS AND METHODS	8
TREATMENT AND TERMINOLOGY OF THE MUSCLES	9
DESCRIPTIONS OF MUSCLES	10
Branchiomeric Musculature	10
Myotomic Musculature	25
Appendicular Musculature	39
Muscles of the Pectoral Girdle and Limb	39
Extensor System	39
Flexor System	45
Muscles of the Pelvic Girdle and Limb	50
Extensor System	50
Flexor System	57
DISCUSSION	69
Muscular Variation within the Dipodoidea	70
The Relationships of Dipodoids to other Rodents	76
Literature Cited	81

ILLUSTRATIONS

FIGURE	PAGE
1. Masticatory muscles of dipodoids	86
2. Superficial facial muscles of dipodoids	87
3. Dorsal view of superficial facial muscles of <i>Zapus</i>	88
4. Lateral views of the rostral muscles	89
5. Ventral views of muscles of the hyoid region in <i>Zapus</i>	90
6. Ventral views of muscles of the hyoid region in <i>Jaculus</i>	91
7. Epaxial muscles of the lumbosacral region	92
8. Diagrammatic transverse sections through the trunk of <i>Zapus</i>	93
9. Lateral views of the anterior half of <i>Zapus</i>	94
10. Lateral views of the pectoral limb in <i>Zapus</i>	95
11. Muscles of the pectoral limb in <i>Zapus</i>	96
12. Lateral views of superficial muscles of the pelvic limb	97
13. Lateral views of deeper muscles of the pelvic limb of <i>Zapus</i>	98
14. Medial views of muscles of the thigh of <i>Zapus</i>	99
15. Muscles of the leg of <i>Zapus</i>	100

INTRODUCTION

THE SUBORDINAL classification of the Order Rodentia is currently in a state of flux. Fairly distinctive families and superfamilies are recognizable, but these are difficult to group in subordinal taxa. Dissatisfied with classical arrangements which are based heavily on morphology of the masseter muscle, many taxonomists have turned to other avenues of information for indications of relationship among families and superfamilies. While the most desirable information consists of a well-documented fossil history of each group, it is unlikely that adequate histories of certain groups will ever be available. Fossil rodents are not numerous, or at least they have not been as actively sought and studied as have the remains of larger mammals.

Study of the anatomy of Recent forms is desirable as a supplement to fossil evidence and as a check on the validity of the paleontologist's hypotheses, particularly in orders such as the Rodentia where the fossil history is not well known. The use of myological characters in subordinal rodent classification has been restricted because so few genera have been studied. We have no concept of the sort of variation to be expected within a family or superfamily, and we yet have little basis for deciding whether muscular similarities are owing to inheritance from a common ancestor or, instead, represent parallel developments in different stocks. The aims of the present study were to analyze the muscular variations within the dipodoid superfamily, to correlate as many of the differences as possible with the habits of the animals, and to indicate the relationships of dipodoids to other rodent superfamilies.

Recent rodents of the superfamily Dipodoidea (Simpson, 1945) include a spectrum of genera in various stages of adaptation for bipedal leaping. Four of these are the subject of the present report. *Sicista*, the bush mouse of the forests and steppes of Europe and Asia, is a small longtailed quadrupedal mouse which rarely if ever leaps on its hind legs. The hind feet are not elongate, as they are in all other living dipodoid genera. The long tail in *Sicista* seems to be prehensile, and the animal is scansorial to some degree. The jumping mice of the genera *Eozapus*, *Zapus*, and *Napaeozapus* have long tails and rather elongate hind feet. They progress at least sometimes on their hind legs and use the tail in balancing. *Eozapus* is a relict form now confined to high mountain forests in Szechwan and Kansu, China. Specimens of this genus were not available for dissection. *Zapus* and *Napaeozapus* are found in the meadows and forests of the United States and Canada. In these four genera the five metatarsals are always present and

unfused, the molars are low crowned and the auditory bullae are not greatly inflated.

More highly adapted for bipedal leaping are the jerboas of the Eurasian and African steppes and deserts. In these forms the hind feet are greatly elongate, the auditory bullae inflated and the tail long and tufted. The three central metatarsals tend to fuse and the first and fifth metatarsals tend to disappear. *Jaculus* is one of the more advanced jerboas since the first and fifth metatarsals are absent, and the second, third, and fourth are fused into a single central structure.

The bipedal kangaroo rats (Heteromyidae) of western North America bear close resemblance to some of the jerboas and occupy comparably arid habitats. In these forms, however, the three central metatarsals never fuse. Present evidence indicates that heteromyids evolved in the New World entirely independently of the jerboas in the Old.

Living dipodoids share a number of cranial characters which are peculiar to them. The infraorbital foramen is enlarged, but no masseteric plate is developed from the inferior zygomatic root. From the dorsal surface of that root a small lamella grows dorsomedial to meet or fuse with the rostral surface of the maxilla. The channel or canal thus formed serves to conduct the infraorbital branch of the maxillary nerve and the infraorbital blood vessels to the snout. The jugal bone is L-shaped in all genera. The ascending ramus either closely approaches or meets the lacrimal bone dorsally.

Winge (1887) and Thomas (1896) grouped the bush mouse, jumping mice, and jerboas as the family Dipodidae. Lyon (1901) compared the skulls and skeletons of *Sminthus* (= *Sicista*), *Zapus*, *Allactaga*, and *Dipus* (= *Jaculus*) and found that in the first two genera the metatarsals are unfused and unreduced, the cervical vertebrae are unfused and the auditory bullae are not hypertrophied. Using these and other differences he separated *Sicista* and *Zapus*, as the family Zapodidae, from the jerboas (family Dipodidae). Vinogradov (1937), however, observed that Lyon's criteria for familial separation break down when certain rare Asian jerboas are considered. Thus, in *Cardiocranius* all five metatarsals are present and unfused, and in *Salpingotus* the second, third, and fourth are present and unfused. In the remainder of the jerboas the three central metatarsals are fused into a single bone; the first and fifth may be present or absent. In *Allactaga*, *Alactagulus*, and *Euchoreutes* the cervical vertebrae are unfused. The auditory bullae are inflated to some degree in all jerboas, and this inflation seems to be greatest in *Salpingotus* and *Cardiocranius*. Vinogradov concluded that the gap between living zapodids and dipodids is not as great as Lyon had supposed, and he reunited these groups as the family

Dipodidae. Ellerman (1940) and Ognev (1948) concurred with Vinogradov.

American mammalogists and paleontologists, on the other hand, have continued to follow Lyon in separating zapodids from dipodids within the superfamily Dipodoidea (for example, Simpson, 1945; A. E. Wood, 1955). In the present paper I follow the classification of Vinogradov (1937) and Ognev (1948), though I did not in an earlier paper (Klingener, 1963).

The jerboas have attracted the attention of some anatomists, but the bush mice and jumping mice have been less popular as subjects for investigation, possibly because they are small and difficult to study in detail. Parsons (1894) described some of the muscles of *Dipus aegyptius* (= *Jaculus orientalis*) and *Dipus hirtipes* (= *Jaculus jaculus*). Méhely (1913) studied the skulls of *Sicista* and *Jaculus* and part of the distal male reproductive tract of the former genus. Hatt (1932) compared the vertebral columns of dipodoids and several other rodents, with particular reference to bipedal forms. Vinogradov (1937) summarized much of the earlier work and provided new osteological data on forms not seen by previous authors. Howell (1932) compared the skeletons and muscles of *Scirtopoda orientalis* (= *Jaculus orientalis*), *Allactaga mongolica longior* (= *Allactaga sibirica*), and *Dipodomys spectabilis*. He also dissected a specimen of *Zapus* but described few of the muscles. Howell's specimens were poorly preserved, and some of his observations on the myology of *Zapus* and *Jaculus* are erroneous. To my knowledge, the myology of *Sicista* has never been fully described. Authors who have described single muscles or single groups of muscles in various dipodoids are referred to in the following accounts.

ACKNOWLEDGMENTS

I am indebted to the members of my committee, Drs. Emmet T. Hooper, William H. Burt, James N. Cather, and Claude W. Hibbard, for their guidance during the study and for their careful reading of the manuscript. During all phases of the work, Dr. George C. Rinker gave me the benefit of his extensive knowledge of mammalian myology and dissection techniques; his assistance and encouragement are appreciated. William L. Brudon, artist for the Department of Anatomy, University of Michigan, provided much helpful advice on the preparation of illustrations, and Jean Musser typed the manuscript. I am grateful to them for their aid. Fellow graduate students, especially Guy G. Musser and Dr. Calvin B. DeWitt, provided stimulating discussion and have read parts of the manuscript.

Collections and facilities of the University of Michigan Museum of Zoology were freely opened to me by Drs. Hooper and Burt. For additional specimens of critical forms I am grateful to Dr. Zdzislaw Pucek of the

Mammals Research Institute, Polish Academy of Sciences, Bialowieza, Poland, and to Joan Stadler of the Department of Zoology, University of Michigan.

During most of the work, I was supported by National Science Foundation Cooperative Graduate Fellowships.

MATERIALS AND METHODS

Preserved specimens of the following species were dissected.

Zapus hudsonius: two specimens, Washtenaw County, Michigan; two specimens, Crawford County, Pennsylvania.

Zapus princeps: three specimens, Gunnison County, Colorado.

Napaeozapus insignis: five specimens, Crawford County, Pennsylvania.

Sicista betulina: five specimens, Bialowieza National Park, Poland.

Jaculus jaculus: four specimens, Giza, Egypt.

Peromyscus leucopus: two specimens, Crawford County, Pennsylvania.

Peromyscus maniculatus nubiterrae: two specimens, Crawford County, Pennsylvania.

Mesocricetus auratus: one specimen, laboratory stock.

Microtus pennsylvanicus: one specimen, Washtenaw County, Michigan.

Dipodomys merriami: two specimens, Otero County, New Mexico.

Perognathus fallax: one specimen, San Diego County, California.

Thomomys talpoides: two specimens, Park County, Montana.

Tamias striatus: one specimen, Crawford County, Pennsylvania.

These specimens are from the collections of the Museum of Zoology, University of Michigan, from the Mammals Research Institute of the Polish Academy of Sciences, Bialowieza, Poland, and from my personal collection. Specimens of *Zapus* and *Napaeozapus* were preserved by injecting the body cavities with weak formalin (1 part commercial formalin to 18 parts water) saturated with NaCl. This method was advocated by Raven (Schultz, 1924) and Rinker (1954), and gives best results if dissection of the musculature is the primary objective. The specimens of *Sicista* and *Jaculus* had been stored in alcohol and were not as satisfactory. Specimens of the other rodents examined had been preserved by a variety of methods.

Skeletons of most of the genera listed above were also studied. These are contained in the Museum of Zoology, University of Michigan.

The entire skeletal musculature was dissected in three or more specimens of each dipodoid genus. Questionable points were checked in additional specimens. The other rodents were not completely dissected, but were used to verify statements in the literature and to provide data on certain muscle groups not given by other authors. All dissection was done under a binocular microscope, using magnifications of 5X, 15X and 30X.

Specimens were allowed to drain before dissection. Between periods of use, they were stored in glass jars with damp paper towels. If a specimen started to dry too much, it was immersed in fluid for a day or two. Specimens stored in alcohol require more frequent re-immersion than those stored in formalin.

The superficial facial muscles present a special problem. Dissection of these muscles is difficult, particularly in forms as small as *Sicista* and *Zapus*. First, large specimens of *Z. princeps* were dissected; then specimens of *Z. hudsonius*, *Sicista*, *Napaeozapus*, and *Jaculus*. The fur was shaved from head and neck and the skin removed with a new razor blade. Animals with prime skins are best for dissection of facial muscles; fat animals are to be avoided. Preservation and permanent storage in weak formalin and salt renders the facial muscles tough but rather colorless. In most specimens stored in alcohol, facial muscles are more densely colored but break when touched. For best results, specimens should be allowed to dry during dissection. The fascicles of the superficial layers then become visible, permitting the removal of a single layer to expose the layers beneath.

The most useful reference for dissection of rodents is Rinker's (1954) paper on four cricetid genera. Also useful in the present context are Howell's (1932) study of *Dipodomys* and two jerboas and Hill's (1937) work on the anatomy of the pocket gopher. In the following descriptive section I have included information on innervations, on theories of derivation of muscle groups, and on distribution of muscular characters among rodent groups only when data derived from the dipodoids require such discussion. For information on these and other myological problems in rodents, the reader is referred to the papers mentioned above.

The illustrations are mostly of muscles important in systematic or functional considerations and of regions presenting special problems in dissection. Scales are not uniform.

TREATMENT AND TERMINOLOGY OF THE MUSCLES

In describing the muscles of dipodoids I have followed Rinker's (1954) classification and nomenclature, except when changes in the BNA require the use of different names. Because frequent comparison is made with Howell's (1932) study of jerboas and kangaroo rats, I have given synonyms for names of muscles when the names used here differ from his. Traditional groupings of muscles are based heavily on position and innervation in the adult animal. These groupings do not always coincide with groupings based on embryonic derivation (Cheng, 1955), but use of the traditional system is justified here if only because it makes finding the description of a

given muscle easier, and because embryological studies of the derivation of muscles in mammals apply as yet to few muscle groups in few animals.

The musculature of *Zapus* is taken as a standard for comparison. Unless indicated otherwise in the sections on "Remarks," the condition of each muscle in *Sicista*, *Napaeozapus*, and *Jaculus* is similar enough to *Zapus* to require no special treatment.

Certain muscle groups which proved to be refractory are not described; these groups are the intrinsic muscles of the pinna of the ear, the intrinsic muscles of the manus, the muscles of the larynx, and the extrinsic ocular muscles.

DESCRIPTIONS OF MUSCLES

BRANCHIOMERIC MUSCULATURE

Masticatory Group (Fig. 1)

In many rodents the masseter is divisible into three layers, the superficial, lateral, and medial. Lateral and medial layers may be further subdivided into anterior and posterior parts. Because these parts are differentiated on the basis of changes in fiber direction they are not necessarily exactly comparable from one rodent group to another. Hill (1937) listed synonyms of the parts of the masseter in rodents. His terminology is followed here.

Tullberg (1899) described very briefly the masticatory muscles of *Sicista*, *Zapus*, and two genera of jerboas. He found that in dipodoids no part of the superficial masseter is reflected onto the inner side of the mandible, that the superficial masseter is incompletely separated from the lateral, and that the rostral origin of the medial masseter is enlarged and the temporalis reduced in jerboas. My observations confirm all except the first of his findings, as indicated below.

M. masseter superficialis

ORIGIN.—By tendon from the tubercle on the ventral surface of the inferior zygomatic root of the maxilla.

INSERTION.—On the ventral edge of the angular process and on the medial surface of the mandible, including the angular process and the area below the root of the incisor.

REMARKS.—In dipodoids this part is incompletely differentiated from *M. masseter lateralis profundus*. Distinct at origin in most specimens, the tendon broadens postero-ventrally, and the posterior muscular fibers of lateral and superficial masseters are here inseparable. In *Zapus* and *Jaculus* the superficial masseter seems to be more distinct than in *Sicista*. Tullberg (1899) separated superficial and lateral masseters, but Miller and Gidley (1918) and Howell (1932) considered the two muscles a single element in these rodents. I have followed Tullberg because the tendon of pars superficialis is distinct,

even though most of the muscle fibers are not. The superficial masseter is more distinct in muroids and geomyids (Hill, 1937; Rinker, 1954).

M. masseter lateralis profundus

ORIGIN.—From the ventrolateral surface of the entire zygomatic arch.

INSERTION.—On the lateral surface of the mandible; primarily on the lower half and lower border of the masseteric fossa and on the angular and supra-angular processes.

REMARKS.—The line of origin is visible as a slight ridge extending laterad and curving posteriad from the tubercle that gives origin to the tendon of the superficial masseter. In dipodoids the lateral masseter is not divisible into anterior and posterior parts, as it is in some other rodents.

M. masseter medialis pars anterior

ORIGIN.—From the fossa on the side of the rostrum on the maxillary and premaxillary bones, from the inner edge of the outer rim of the infraorbital foramen, and from the ventromedial surface of the zygomatic arch back to the arch's posterior root.

INSERTION.—On the tuberosity at the anterior end of the masseteric scar and on the upper part of the masseteric fossa and its upper border.

REMARKS.—The rostral fibers pass posteroventrad through the infraorbital foramen and at the level of the inferior zygomatic root form a round tendon. This tendon inserts on the tuberosity. Fibers from the zygomatic arch form on their medial surface a flat tendon that inserts mainly on the upper masseteric ridge posterior to the tuberosity. The more posterior fibers run anteromedial and dorsomedial to insert on the coronoid process. In *Jaculus* the rostral and infraorbital fibers are more distinct from the rest of the muscle than they are in *Zapus* and *Sicista*.

In *Sicista* the rostral origin extends only one quarter of the distance from orbit to rhinarium, in *Zapus* between one-third and one-half this distance, and in *Jaculus* more than one-half.

M. masseter medialis pars posterior

ORIGIN.—From the ventromedial surface of the zygomatic process of the squamosal.

INSERTION.—On the lateral surface of the mandible between the bulge over the incisor's root and the mandibular notch.

REMARKS.—The fibers of this part run almost horizontally and are separated ventrally from pars anterior of the medial masseter by the masticatory nerve and vessels, which emerge over the mandibular notch. In *Thomomys* and *Sigmodon* the masticatory nerve penetrates the fibers of pars posterior (Hill, 1937; Rinker, 1954).

M. temporalis

ORIGIN.—From the orbital surfaces of the frontal and parietal bones, and from the lateral surfaces of the parietal and squamosal bones in the area bounded dorsally by the temporal crest and posteriorly by the lambdoidal crest.

INSERTION.—On the tip and anteromedial surface of the coronoid process of the mandible.

REMARKS.—I distinguish with certainty no separate parts of this muscle corresponding to the parts recognized in *Sigmodon* and *Neotoma* by Rinker (1954) and in *Reithrodontomys* by Rinker and Hooper (1950).

In *Sicista* the orbital origin seems to be more extensive than in *Zapus*. In *Jaculus*

the temporalis muscle is greatly reduced, corresponding to the posteroventral part only of the sicistine and zapodine muscle, the anterodorsal part being absent. Rinker has suggested (*in litt.*) that the posterior fibers are more important in grinding, and the anterior fibers in crushing food. Hence, the progressive disappearance of the anterior fibers of the temporalis seen in jerboas could be associated with the transformation of the molars from tuberculate to flat, high-crowned teeth, and with the probable shift from crushing to grinding movements of the mandible during mastication.

M. pterygoideus externus

ORIGIN.—From the alisphenoid bone and from the lateral surface of the lateral pterygoid plate.

INSERTION.—On the medial side of the articular process (condyloid process) of the mandible.

Internal Pterygoid Group

M. pterygoideus internus

ORIGIN.—From the walls of the pterygoid fossa.

INSERTION.—On the medial surface of the angular process of the mandible.

M. tensor tympani

ORIGIN.—From the bony wall of the canal occupied by the auditory tube.

INSERTION.—On a tubercle on the medial surface of the manubrium of the malleus.

M. tensor veli palatini

This muscle was not found; it may have been overlooked.

Mylohyoid Group (Figs. 5, 6)

M. mylohyoideus

ORIGIN.—From the medial surface of the mandible, ventral to the molar toothrow.

INSERTION.—Into a median raphe and fascially into the body of the hyoid skeleton.

REMARKS.—The posterior part of this muscle is visible behind the tendinous arcade formed by the digastric muscles. The origin is confined to the region ventral to the toothrow.

M. transversus mandibulae

ORIGIN.—From the ventral edge of the mandible, deep to the insertion of the anterior belly of *M. digastricus* and anterior to the mylohyoideus.

INSERTION.—Into its fellow at the ventral midline.

M. digastricus (anterior belly)

ORIGIN.—As a direct continuation of the tendon of the posterior digastric, and from the anterior surface of the tendinous arch.

INSERTION.—On the ventral edge of the mandible posterior to the mental symphysis.

REMARKS.—In all dipodoids dissected the anterior bellies are in close contact in the midline, a feature of the sciuromorphic type of digastric (Parsons, 1894).

Superficial Facial Group (Figs. 2, 3, 4, 9A)

Huber (1930, 1931) summarized the anatomy of the superficial facial muscles of mammals. In most marsupials and placentals, three muscular layers are shed from the primitive sphincter colli and migrate forward over the neck and head. The deepest and most superficial of these, *M. sphincter colli profundus* and *M. sphincter colli superficialis*, respectively, tend to run in circular paths around the head. The intermediate sheet, *M. platysma myoides*, runs longitudinally on the sides of the head. Specialized elements, such as the muscles controlling movement of the pinnae, eyelids, lips, and vibrissae, have been derived from *M. platysma myoides* and *M. sphincter colli profundus*. *M. sphincter colli superficialis* has given rise to no specialized elements and is probably absent altogether in rodents.

Meinertz (1932, 1935*a, b*, 1936*a, b*, 1941*a, b*, 1942, 1943*a, b, c*, 1944*a, b*, 1951) and Rinker (1954) described in detail the superficial facial muscles of several rodents and lagomorphs. Meinertz (1941*b*) included a valuable summary of the anatomy of these muscles in sciurid, castorid, microtine, murine, dipodoid, caviomorph and hystricomorph forms. His later papers include comparisons with bathyergids and *Pedetes*. In the present study I have followed Rinker's classification and arrangement of this muscle group, as outlined below:

A. Platysma and derivatives

1. Platysma

M. platysma myoides

Pars buccalis

Pars mentalis

Pars auricularis

M. platysma cervicale

2. Retroauricular musculature

Mm. cervicoauricularis et cervico-occipitalis

M. cervicoauricularis medius

M. cervicoauricularis posterior profundus

M. mandibulo-auricularis

B. Sphincter colli profundus and derivatives

1. Pars auris

2. Pars intermedia and derivatives

Pars intermedia ventralis

Pars intermedia dorsalis and derivatives

Preauricular musculature

Pars intermedia dorsalis

M. zygomaticolabialis

M. auriculo-occipitalis

M. frontalis (auricular part)

- M. auricularis anterior superior
- M. auricularis anterior inferior
- Orbitonasal musculature
 - M. frontalis (orbital part)
 - M. orbicularis oculi
 - M. nasolabialis
 - M. nasolabialis superficialis
- 3. Pars palpebralis
- 4. Pars oris and derivatives
 - M. maxillolabialis
 - M. dilator nasi
 - M. nasolabialis profundus
 - Pars interna
 - Pars media superior
 - Pars media inferior
 - Pars anterior
 - Pars anterior profunda
 - Pars maxillaris superficialis
 - Pars maxillaris profunda
 - M. bucco-naso-labialis
 - M. buccinatorius
 - Pars intermaxillaris
 - Pars intermaxillaris superficialis
 - Pars mandibularis
 - Pars orbicularis
 - Pars orbicularis oris
 - Pars longitudinalis posterior dorsalis
 - Pars longitudinalis posterior ventralis

A. Platysma and Derivatives

1. Platysma

M. platysma myoides

This muscle originates primarily at the dorsal nuchal midline and over the shoulders; it sweeps forward over the sides of the head. It is divisible into three parts on the basis of points of origin and insertion of fibers. Pars auricularis consists of a few fibers originating on the anteroventral surface of the auricular cartilage and running anteriorly to insert behind the eye, overlying pars intermedia dorsalis of *M. sphincter colli profundus*. Pars buccalis originates fascially at the dorsal nuchal midline and passes forward to insert in the upper lip near the angle of the mouth. In *Jaculus* it is reduced to a narrow strip. Pars mentalis in *Sicista* and *Zapus* originates entirely over the shoulder and is continuous dorsally with pars buccalis. In *Alactagulus* (Meinertz, 1941b) and in *Jaculus* pars mentalis originates instead seemingly as part of *M. sphincter colli profundus* and emerges together with pars auris of that muscle at the ventral border of pars buccalis. Pars mentalis lies superficial to partes intermedia ventralis, palpebralis, and oris of *M. sphincter colli profundus*.

M. platysma cervicale

ORIGIN.—From the nuchal midline deep to the superficial layers of the cervicoauricular muscles and posterior to *M. cervicoauricularis posterior profundus*.

INSERTION.—Into *M. platysma myoides* in the throat region.

2. Retroauricular Musculature

Meinertz (1941a) divided these muscles into two groups—*Mm. auriculares proprii* and the cervicoauricular muscles. Only *M. mandibulo-auricularis* of the first group is treated here. My dissections of the cervicoauricular muscles in *Jaculus* were not satisfactory, so I have included no description of them for that genus.

Mm. cervicoauricularis et cervico-occipitalis

ORIGIN.—From the nuchal ligament behind the occiput.

INSERTION.—On the dorsomedial surface of the auricular cartilage and on the surface of the skull deep to *M. auriculo-occipitalis*, the "intermediate plate," and the auricular part of *M. frontalis*.

REMARKS.—These muscles are separate in some rodents, but in dipodoids they are inseparable except on the basis of point of insertion of fibers. Those inserting on the auricular cartilage constitute *M. cervicoauricularis*; those inserting on the cranium are *M. cervico-occipitalis*. Auricular insertion is by a number of slips, usually two. Meinertz (1941b) indicated that the cervico-occipital component is minute in *Alactagulus*.

M. cervicoauricularis medius

ORIGIN.—From the nuchal midline, deep to the origin of *M. cervico-occipitalis*.

INSERTION.—On the dorsomedial surface of the auricular cartilage.

REMARKS.—This muscle forms the middle of three planes of the cervicoauricular muscles. It is single in *Zapus*. In *Sicista*, anterior and posterior parts are present and seem to originate relatively farther forward than in *Zapus*. Meinertz (1941b) found separable anterior and posterior parts also in *Alactagulus*.

M. cervicoauricularis posterior profundus

ORIGIN.—From the nuchal midline, partly deep to the origin of *M. cervicoauricularis medius*.

INSERTION.—Onto the medial surface of the auricular cartilage.

REMARKS.—This muscle, which forms the deepest plane of cervicoauricular muscles, is usually separated by a small hiatus from *M. platysma cervicale*.

M. mandibulo-auricularis

ORIGIN.—From the notch between condyloid and supra-angular processes of the mandible, mainly from the edge and medial surface.

INSERTION.—Into the dorsomedial region of the base of the auricular cartilage.

B. Sphincter colli profundus and Derivatives

Primitively, this muscle forms a continuous ventral sheet extending from the lower lip to the sternum, and between eye and ear it forms a continuous circumcranial sphincter. Elsewhere, the sphincter is incomplete dorsally. In hystricomorphs and caviomorphs, five parts may be distinguished, but the posteriormost of these (*pars cervicalis*) is absent in all other rodents. *M. mandibulo-labialis*, a probable derivative of *M. sphincter colli*

profundus, is absent in dipodoids and in all other rodents except hystricomorphs, cavio-morphs, and bathyergids (Meinertz, 1941a, 1951). In rodents, the ventral fibers of *M. sphincter colli profundus* may decussate and pass dorsad around the opposite side of the head. They lie superficial to all parts of *M. platysma myoides*, constituting a false superficial sphincter colli. They are omitted in all illustrations of the facial muscles in the present paper.

1. *Pars auris* (*M. sterno-auricularis* Howell, 1932)

ORIGIN.—From the midline of the manubrium sterni.

INSERTION.—On the ventral surface of the auricular cartilage.

REMARKS.—In *Sicista* this slip is continuous anteriorly with *pars intermedia ventralis*. This is probably the primitive condition. In *Zapus* the two parts are separated by a fascial hiatus. In *Jaculus*, where *pars intermedia ventralis* is absent, *pars auris* appears as a distinct muscle. Rinker (1954) found a tendency toward separation of this part from the remainder of *M. sphincter colli profundus* in some cricetines.

2. *Pars Intermedia* and Derivatives

Pars intermedia ventralis

In *Sicista* these fibers are continuous posteriorly with those of *pars auris*. They pass dorsad deep to *M. platysma myoides* and together with fibers of *pars intermedia dorsalis* form the "intermediate plate" in the region between ear and eye. In *Jaculus*, as in *Alactagulus* (Meinertz, 1944a), *pars intermedia ventralis* is absent.

Pars intermedia dorsalis and Derivatives

Preauricular Musculature

Pars intermedia dorsalis

This sheet is found only in *Sicista* and *Zapus* where it originates fascially over the cranium and passes ventrad to interdigitate with ascending fibers of *pars intermedia ventralis* to form the "intermediate plate." In *Sicista* the "intermediate plate" occupies most of the area between ear and eye; in *Zapus* it is more restricted anteriorly and is more fascial, and in *Jaculus* the "intermediate plate" and *pars intermedia dorsalis* are absent.

M. zygomaticolabialis (*M. auriculolabialis* Howell, 1932)

ORIGIN.—Apparently from the anteroventral corner of the "intermediate plate."

INSERTION.—Into the angle of the mouth, penetrating *M. orbicularis oris* and lying partly deep to *pars buccalis* of *M. platysma myoides*.

REMARKS.—In *Sicista* and *Zapus* this band passes ventral to the fibers of *M. orbicularis oculi* and is covered by *pars palpebralis* of *M. sphincter colli profundus*. In *Jaculus*, *M. zygomaticolabialis* is much more slender and lies deep to *M. orbicularis oculi* as it runs ventral to the eye. It originates in fascia behind the eye. Meinertz (1941a, 1943b) interpreted the connection of *M. zygomaticolabialis* and the "intermediate plate" as a primary one because the two muscles have the same innervation and they are almost indistinguishable at origin in *Sciurus*. Howell (1932) was mistaken when he listed the auricular cartilage as the origin of this muscle.

M. auriculo-occipitalis

ORIGIN.—By fascia from the surface of the cranium posterior to *pars intermedia dorsalis*.

INSERTION.—On the dorsomedial surface of the auricular cartilage.

REMARKS.—In *Sicista* and *Zapus* this muscle appears as the posterior continuation of pars intermedia dorsalis. In *Jaculus* and *Alactagulus* where the latter element is missing, pars auriculo-occipitalis appears as an independent muscle.

M. frontalis (auricular part)

ORIGIN.—From the anterodorsal surface of the auricular cartilage.

INSERTION.—Into the fibers of the orbital part of *M. frontalis* midway between ear and eye.

REMARKS.—This muscle is best developed in *Sicista*, slightly reduced in *Zapus* and greatly reduced in *Jaculus*. In all dipodoids dissected it runs forward deep to the "intermediate plate," as in *Sigmodon* and *Oryzomys*. In *Peromyscus*, *Neotoma*, *Rattus*, and *Dicrostonyx* this muscle is superficial to the "intermediate plate" (Meinertz, 1941a, b; Rinker, 1954). In dipodoids, as in *Sigmodon* (Rinker, 1954), the auricular part of *M. frontalis* is superficial to *M. cervico-occipitalis*, but the fibers of the two muscles appear to fuse anteriorly.

M. auricularis anterior superior and *M. auricularis anterior inferior*

I did not find these muscles in dipodoids; they may have been overlooked.

Orbitonasal Musculature

M. frontalis (orbital part)

ORIGIN.—From the orbital surface of the frontal bone at the point of greatest interorbital constriction.

INSERTION.—Into the fibers of the auricular part of *M. frontalis* midway between eye and ear.

M. orbicularis oculi

ORIGIN.—From the medial palpebral ligament.

INSERTION.—Into the skin of the eyelid.

REMARKS.—This muscle is weakly developed in dipodoids. Anteriorly, a well-developed band of fibers runs dorsomedial, ascending over the origin of *M. nasolabialis* and the lacrimal bone to spread out weakly on the dorsum of the skull. I did not find decussation and radiation of the fibers at the posterior corner of the eye as illustrated for *Alactagulus* by Meinertz (1941b).

M. nasolabialis

ORIGIN.—From the orbital surface of the frontal bone, approximately at the narrowest part of the interorbital constriction, anterior and dorsal to the origin of the orbital part of *M. frontalis*.

INSERTION.—Into the skin of the rostrum, the mystacial pad, and the upper lip.

REMARKS.—The dorsal fibers run directly anteriorly, crossing onto the surface of the nasal bone distally. The remainder of the fibers cross the tendon of *M. dilator nasi*, the lacrimal bone, and part of the rostral origin of *M. masseter medialis pars anterior* before they enter the mystacial pad. There the fibers wind among the bases of the vibrissae. In *Sicista* and *Zapus*, *M. nasolabialis* is a fairly heavy muscle, but it is extremely heavy in *Jaculus*. The great development of this muscle in the jerboa is probably

associated with the large size of the vibrissae, which were as long as 9.5 cm. in the specimens dissected. Meinertz (1944a) also found this muscle to be heavy in *Alactagulus*.

M. nasolabialis superficialis

ORIGIN.—From the dorsum of the rostrum.

INSERTION.—Into the skin on the side of the rostrum.

REMARKS.—This muscle is weakly developed in dipodoids and is closely united with the skin of the rostrum. In sciurids, *M. nasolabialis superficialis* is not differentiated from *M. nasolabialis* (Meinertz, 1941b).

3. *Pars palpebralis*

ORIGIN.—From the ventral midline (excluding the decussating fibers).

INSERTION.—Into the skin, ventral and anterior to the eye.

REMARKS.—In *Sicista* and *Zapus* this muscle is continuous posteriorly with *pars intermedia ventralis* and anteriorly with *pars oris*. It is narrow in *Jaculus*. In all dipodoids it is closely associated with the skin and is easily removed with it during dissection.

4. *Pars Oris and Derivatives*

M. maxillolabialis

ORIGIN.—From the anterior surface of the inferior zygomatic root of the maxilla.

INSERTION.—Into the posteroventral part of the mystacial pad.

REMARKS.—The fibers wind among the bases of the vibrissae. The muscle is better developed in *Jaculus* than in *Sicista* and *Zapus*.

M. dilator nasi

ORIGIN.—By aponeurosis from the outer surface of the entire outer rim of the infraorbital foramen.

INSERTION.—By a flat tendon on the dorsal part of the nasal cartilage.

REMARKS.—This is a large muscle in dipodoids. In *Zapus* it covers most of the origin of the rostral part of *M. masseter medialis anterior*. In *Sicista* and *Jaculus* the origin of *M. dilator nasi* occupies only the upper half of the external rim of the infraorbital foramen, and more of the rostral masseteric origin is left uncovered. Origin in *Alactagulus* is similar (Meinertz, 1941b). In all forms the tendon broadens before inserting.

In the hystricomorph, caviomorphs and bathyergids dissected by Meinertz (1941b, 1951), *M. dilator nasi* is entirely fleshy. In muroids, dipodoids, and sciurids, an insertional tendon is developed.

M. nasolabialis profundus

This muscle consists of several well-differentiated parts, each concerned primarily with movement of the mystacial pad, the rhinarium, and the dorsal skin of the rostrum.

Pars interna

ORIGIN.—From the posterolateral surface of the nasal cartilage.

INSERTION.—Into the dorsal skin of the rostrum and into the tendon of *M. dilator nasi*.

REMARKS.—This muscle is separable into two parts. The deeper and smaller part consists of a few fibers which insert into the tendon of *M. dilator nasi* near that muscle's

insertion. The superficial and larger part consists of fibers that cross the tendon of *M. dilator nasi* to insert in the skin of the dorsum of the rostrum. In *Zapus* the superficial part is especially large and its posterior border is closely related to the anterior border of *pars media superior*. In *Sicista* and *Jaculus* the superficial part is smaller.

Pars media superior

ORIGIN.—From the premaxilla between the incisors and above the incisive alveolus.

INSERTION.—Into the skin of the rostrum posterior to the insertion of *pars interna*, and into the fascia on the underside of the origin of *M. dilator nasi*.

REMARKS.—This muscle is partly overlapped at origin by *pars media inferior*, and as it passes dorsad it is crossed by the tendons of *partes maxillaris superficialis* and *maxillaris profunda* and *M. dilator nasi*. In some specimens of *Zapus* a few fibers insert on the outer surface of the origin of *M. dilator nasi*, but in other specimens the entire muscle passes deep to *M. dilator nasi*. In *Sicista* and *Zapus*, *pars media superior* fans out rather broadly from its origin, whereas in *Jaculus* the muscle is a narrow strip, well separated from both the superficial fibers of *pars interna* and the origin of *M. dilator nasi*. *Pars media superior* in *Alactagulus*, as figured by Meinertz (1941*b*, fig. 61), is similar to that in *Jaculus*.

Pars media inferior

ORIGIN.—From the premaxilla between the incisors, anterior to the origin of *pars media superior*.

INSERTION.—Into the upper lip and anteroventral part of the mystacial pad, the fibers winding among the bases of the vibrissae.

REMARKS.—At origin this muscle is overlapped by *pars anterior* and it overlaps the ventral part of the origin of *pars media superior*. It is relatively heavier in *Jaculus* than in *Sicista* and *Zapus*.

Pars anterior

ORIGIN.—From the ventral part of the premaxillary ridge between the incisors.

INSERTION.—On the lateral surface of the nasal cartilage.

Pars anterior profunda

This small muscle was not found, but might have been overlooked. Meinertz (1941*b*) found it in *Alactagulus*.

Pars maxillaris superficialis

ORIGIN.—From the lamella which springs from the inferior zygomatic root of the maxilla and roofs the canal for the infraorbital nerve and artery, and from the maxilla immediately dorsal to the lamella's junction with the rostrum.

INSERTION.—By tendon into the nasal cartilage posterior to the external naris.

REMARKS.—In *Sicista*, where the lamella is poorly developed, the origin is restricted to the rostral part of the maxilla. In *Jaculus* conditions resemble those described for *Zapus*. The tendon of insertion is round in *Zapus* and *Jaculus* and rather flat in *Sicista*.

Pars maxillaris profunda

ORIGIN.—From the lamella (see above) ventral and medial to the origin of *pars maxillaris superficialis*.

INSERTION.—By tendon into the posteroventral part of the nasal cartilage, ventral to the insertion of pars maxillaris superficialis.

REMARKS.—In *Sicista*, origin is from the rostral part of the maxilla anterior and slightly dorsal to the inferior zygomatic root; the tendon is flatter than in *Zapus* and *Jaculus*.

The origins of both partes maxillaris superficialis and maxillaris profunda emerge from beneath the rostral fibers of *M. masseter medialis anterior*. These muscles closely resemble those described in muroids (*Dicrostonyx*, *Arvicola*, *Rattus*, *Sigmodon*, *Oryzomys*, *Peromyscus*, and *Neotoma*) by Meinertz (1941a, 1941b) and Rinker (1954). They were found in *Alactagulus* by Meinertz (1944a), but were absent in the castorid, sciurids, caviomorphs, hystricomorph and bathyergids he dissected. Neither Meinertz (1942) nor Priddy and Brodie (1948) mentioned these muscles in *Cricetus* and *Mesocricetus*. In a specimen of *Mesocricetus*, which I dissected, both parts were present. They both originate in the mystacial pad and insert on the nasal cartilage in that genus.

M. bucco-naso-labialis (*M. buccinatorius* Howell, 1932)

ORIGIN.—From a fossa on the side of the rostrum anterior to the rostral origin of *M. masseter medialis anterior*.

INSERTION.—Into the upper lip and mucous membrane of the mouth, interdigitating with the fibers of pars intermaxillaris of *M. buccinatorius*.

REMARKS.—The fossa of origin, which lies ventral to the bulge formed by the root of the incisor, indents the premaxilla and maxilla. In *Sicista* and *Zapus* the muscle forms a simple, fan-like sheet. In *Jaculus* an anterior slip is partly separated from the remainder of the muscle. Similar conditions are found in *Alactagulus* (Meinertz, 1941b). In *Jaculus*, the rostral origin of *M. masseter medialis anterior* covers part of the origin of *M. bucco-naso-labialis*. I did not find in *Jaculus*, *Zapus*, or *Sicista* the horizontal part of this muscle described in *Alactagulus*.

M. buccinatorius

This muscle also is composed of a number of fairly separate elements, but differentiation is far less extensive in dipodoids than in muroids.

Pars intermaxillaris

ORIGIN.—From the palatal surface of the premaxilla between the point of emergence of the incisor and the level of the junction of the anterior and middle thirds of the incisive foramen.

INSERTION.—Into the upper lip, the fibers interlacing with the inserting fibers of *M. bucco-naso-labialis*.

REMARKS.—I could not trace the insertion of the posterior fibers of this muscle.

Pars intermaxillaris superficialis

This small muscle was not found; it may have been overlooked.

Pars mandibularis

ORIGIN.—From the dorsal surface of the diastema of the mandible.

INSERTION.—Into the lining of the mouth and upper lip.

REMARKS.—This muscle is penetrated by *M. zygomaticolabialis* and pars buccalis of *M. platysma myoides*.

Pars orbicularis

ORIGIN.—From the dorsal surface of the mandible in the symphyseal region.

INSERTION.—Into the skin of the mental region, and into its fellow at the ventral midline.

Pars orbicularis oris

ORIGIN.—From the skin of the upper lip.

INSERTION.—Into the skin of the lower lip.

REMARKS.—This muscle is weakly developed and lies anterior and superficial to *M. orbicularis*.

Pars longitudinalis posterior dorsalis

ORIGIN.—From the maxilla, lateral to the premolar and molars.

INSERTION.—Into the lining of the mouth, penetrating the posterior fibers of *pars mandibularis*.

Pars longitudinalis posterior ventralis

ORIGIN.—From the mandible, lateral to the molars.

INSERTION.—Into the lining of the mouth, penetrating the posterior fibers of *pars mandibularis*.

REMARKS.—In dipodoids, *M. buccinatorius* displays in the cheek region none of the differentiation found in cricetines and microtines.

Hyoid Constrictor Group (Figs. 5, 6)

M. digastricus (posterior belly)

ORIGIN.—From the paroccipital (jugular) process.

INSERTION.—By a round tendon into the anterior belly of *M. digastricus* and fascially onto the body of the hyoid skeleton.

REMARKS.—At origin, this muscle overlies *M. jugulothyoideus*. As it approaches the hyoid bone it narrows into a round tendon. Lateral and anterior to the hyoid bone the tendon fans out; the medial fibers meet their fellows in the midline anterior to the hyoid. Attachment of the tendon to the hyoid bone is by loose fascia; it does not constitute a true insertion.

Parsons (1894) described two types of digastric muscle in rodents. In his sciuromorphic type, anterior and posterior bellies are separated by a tendon that attaches to the hyoid bone and forms an arch across *M. mylohyoideus*. The two anterior bellies are in contact for most or all of their length. In the hystricomorphine type the anterior and posterior bellies are not interrupted by tendon, the attachment to the hyoid bone is not strong, and right and left anterior bellies are separate. Parsons did note that in some caviomorphs (chinchillas) the digastric attaches strongly to the hyoid bone but otherwise is of the hystricomorphine type. Dipodoids, as Parsons noted, have a sciuromorphic digastric, though I find that attachment to the hyoid bone is weak. The sciuromorphic type is also found in *Castor* and sciurids (Parsons, 1894), *Aplodontia* (Hill, 1937) and some muroids (Rinker, 1954). Some muroids approach the hystricomorphine type in some characters (Rinker, 1954). Geomyoids also tend toward the hystricomorphine type (Hill, 1937).

Hill (1937) regarded the sciuromorphic type as primitive. If this interpretation is correct, dipodoids retain a rather primitive digastric structure, and geomyoids and some muroids have evolved toward an hystricomorphine type.

M. stylohyoideus

ORIGIN.—From the anterior surface of the stylohyal cartilage.

INSERTION.—On the thyrohyal bone.

REMARKS.—None of the fibers seem to originate on the paroccipital process and cross the stylohyal, as in *Neotoma* (Rinker, 1954). In *Jaculus* *M. stylohyoideus* originates on the stylohyal and from an aponeurosis over the bulla lateral and slightly dorsal to the stylohyal. Howell (1932) incorrectly gave the paroccipital process as the origin of this muscle in jerboas. He was doubtless misled by the attachment of the stylohyal to this process. No fibers of *M. stylohyoideus* originate on the process itself.

M. jugulohyoideus

ORIGIN.—From the paroccipital process deep to the origin of the posterior belly of *M. digastricus*.

INSERTION.—On the posterior surface of the stylohyal cartilage.

REMARKS.—This muscle is present in *Sicista* and *Zapus*. In these genera the well-developed stylohyal cartilage approaches the stylo mastoid foramen, probably connecting by a ligament with the tympanohyal in the foramen's wall. In *Jaculus* the stylohyal attaches to the paroccipital process instead of the stylo mastoid foramen, and *M. jugulohyoideus* is consequently absent.

In some other rodents the stylohyal may disappear, and the muscles primitively originating from it either disappear or originate from other structures. In *Dipodomys* *M. jugulohyoideus* is lost, and *M. stylohyoideus* and *M. styloglossus* originate by long, thin tendons from the paroccipital process. *M. stylopharyngeus* originates more anteriorly from fascia over the surface of the bulla. Hill's (1937) description of these muscles in geomyids indicates that they differ from *Dipodomys* only in that *M. stylopharyngeus* originates from the paroccipital process. A similar arrangement is present in the gerbils, *Tatera* and *Meriones* (Sharma and Sivaram, 1959). In *Sigmodon* and *Oryzomys*, *M. styloglossus* and *M. stylopharyngeus* originate from a flat aponeurosis lying on the ventral surface of the auditory bulla and attaching posteriorly to the paroccipital process, while *M. stylohyoideus* originates from the paroccipital process itself (Rinker, 1954). Buried in the posterior part of the aponeurosis is a small piece of cartilage, interpreted by Rinker as the remnant of the stylohyal. A small group of muscle fibers running between this remnant and the paroccipital process probably represents *M. jugulohyoideus* in these forms. I have found similar conditions in *Mesocricetus* and *Microtus*.

The stylohyal and its primitive set of muscles are retained in sciurids, *Aplodontia*, and *Peromyscus* (Hill, 1937; Bryant, 1945; Rinker, 1954) in addition to *Sicista* and *Zapus*. In *Neotoma*, however, some fibers of *M. stylohyoideus* originate on the paroccipital process and cross the stylohyal (Sprague, 1942; Rinker, 1954). The shift of the stylohyal attachment in jerboas cannot be taken as a prelude to loss of the stylohyal. In *Sigmodon* and *Oryzomys* the vestige of the stylohyal still connects with the stylo mastoid foramen (Rinker, 1954), indicating that shift of attachment to the paroccipital process did not precede loss of the remainder of the stylohyal.

The deeper muscles of the hyoid region are best dissected by cutting the intermediate tendon of *M. digastricus* and reflecting the anterior belly forward and the posterior belly

backward. This procedure exposes *M. stylohyoideus* without damaging it. *M. stylohyoideus* can then be cut at its insertion on the posterior horn of the hyoid and reflected backwards, exposing the stylohyal, *M. styloglossus*, and *M. stylopharyngeus*. The external carotid artery runs between *M. stylohyoideus* and the deeper muscles and serves as a convenient marker.

M. stapedius

ORIGIN.—From a fossa between the mastoid bone and the cochlea.

INSERTION.—By a thin tendon on the posterior crus of the stapes.

Glossopharyngeal Group (Figs. 5, 6)

M. stylopharyngeus

ORIGIN.—From the medial surface of the stylohyal cartilage.

INSERTION.—Into the musculature of the pharynx.

Trapezius Group (Fig. 9A)

M. sternomastoideus

ORIGIN.—From the anterior edge of the manubrium sterni.

INSERTION.—By tendon on a tubercle in the posterior rim of the external auditory meatus.

M. cleidomastoideus

ORIGIN.—From the anterior edge of the clavicle, deep and medial to the origin of *M. cleido-occipitalis*.

INSERTION.—On the skull behind the insertion of *M. sternomastoideus*.

REMARKS.—The origin of this muscle is difficult to separate from the origin of *M. sternomastoideus*, but the tendinous insertion lies just behind the insertion of *M. sternomastoideus*. The insertion is covered by the inserting fibers of *M. cleido-occipitalis*. The muscle seems to be absent in *Jaculus*. Howell (1932) found it in *Allactaga* but not in *Jaculus*.

M. cleido-occipitalis

ORIGIN.—From the middle third of the clavicle, partly superficial to the origin of *M. cleidomastoideus*.

INSERTION.—On the lambdoidal crest, between the insertion of *M. sternomastoideus* and the crest's junction with the superior temporal line. Some fibers may insert fascially onto the surface of *M. splenius*.

REMARKS.—This muscle, termed "*M. clavotrapezius*" by some authors, lies ventral to the point of emergence of the greater auricular nerve in dipodoids as in many other rodents. Therefore, it is properly called *M. cleido-occipitalis*. It is considered part of the sterno-cleido-mastoid complex rather than of the trapezius (Hill, 1937; Rinker, 1954).

Howell (1932) included both *M. cleido-occipitalis* and *M. cleidomastoideus* under the name "*M. cleidomastoideus*." He referred to *M. cleido-occipitalis* in *Jaculus* as a "*calvotrapezius*" [*sic*] and thought that the rodents he dissected illustrated the origin of

the clavotrapezius from the trapezius sheet. Since the true clavotrapezius of these rodents is embodied in the acromiotrapezius, the rodents Howell dissected show nothing but the loss of the cleidomastoideus and the approximation of cleido-occipitalis and acromiotrapezius in *Jaculus*.

M. acromiotrapezius

ORIGIN.—From the dorsal midline between a point 4 mm. behind the superior nuchal line and a point level with the spine of the scapula.

INSERTION.—On the anterior surface of the tubercle of the scapular spine (see below), the anterior surface of the scapular spine below the tubercle, the dorsal surface of the acromion, and the dorsal surface of the lateral end of the clavicle.

REMARKS.—The clavicular insertion is small, confined to the lateralmost part of the bone. In *Jaculus* the origin has expanded anterolaterad onto the occiput and the dorsal surface of the bulla. It closely approaches *M. cleido-occipitalis*, from which it is separated by the greater auricular nerve.

M. spinotrapezius

ORIGIN.—From the dorsal midline over the first to third lumbar vertebrae.

INSERTION.—On the posterior surface of a tubercle developed in the crest of the scapular spine, approximately midway between the acromion and the vertebral border of the scapula.

REMARKS.—The muscle is slender in dipodoids. In *Sicista* it is relatively broader than in the other genera, and the origin includes the posterior thoracic vertebrae in addition to the anterior lumbar. In *Zapus* the muscle gives off a ventral band of fibers shortly before it crosses the posterior border of the scapula. This band, the auricular slip, runs cranial and slightly dorsad and enters the nuchal platysma behind and below the ear. In *Sicista* the separation of the auricular slip from the remainder of *M. spinotrapezius* takes place farther posteriorly, well behind the scapula. The auricular slip was not found in *Jaculus*.

The auricular slip of *M. spinotrapezius* has been found in many other rodents, including representatives of the sciurids, murines, microtines, cricetines and bathyergids (Meinertz, 1951; Rinker, 1954, and cited references). In hamsters (*Cricetus* and *Mesocricetus*) the retractor of the cheek pouch is probably homologous with this slip (Priddy and Brodie, 1948). In geomyids and heteromyids the pouch retractor is probably partly homologous with the auricular slip (Hill, 1935, 1937; Rinker, 1954), since in the geomyids the superficial facial musculature also participates in forming the retractor of the pouch. In sciurids, the pouch retractor is formed by the superficial facial muscles without the aid of *M. spinotrapezius* (Hill, 1935). In some cricetines (*Peromyscus leucopus*, *Ochrotomys nuttalli*) a cheek pouch is present, but no retractor muscle is developed (Rinker, 1963).

The sciurids, bathyergids, microtines, cricetines and dipodoids that possess the auricular slip are thus preadapted for the evolution of a cheek pouch retractor of the sorts seen in hamsters and geomyids. This explanation is to me preferable to supposing that the ancestors of all of these rodents had cheek pouches and retractors developed from *M. spinotrapezius*, and that the pouches were lost, the retractor persisting as the auricular slip of *M. spinotrapezius*. The diversity of pouch retractors among living rodents argues against this hypothesis.

MYOTOMIC MUSCULATURE

Lingual Group (Figs. 5, 6)

M. genioglossus

ORIGIN.—From the medial surface of the mandible near the symphysis, in common with the tendon of *M. geniohyoideus*.

INSERTION.—On the anterior surface of the body of the hyoid bone and part of the thyrohyal, deep to the origin of *M. hyoglossus*, and into the medial part of the tongue.

M. hyoglossus

ORIGIN.—From the anterior surface of the basihyal and thyrohyal.

INSERTION.—Into the lateral part of the tongue.

REMARKS.—This muscle lies deep to *M. geniohyoideus*, from which it is separated by the hypoglossal nerve. At insertion, *M. hyoglossus* runs medial to *M. styloglossus*, with which it fuses.

M. styloglossus

ORIGIN.—From the stylohyal cartilage, and fascially over the ventral surface of the bulla.

INSERTION.—Into the lateralmost part of the tongue.

REMARKS.—See remarks under *M. jugulohyoideus*.

Superficial Spino-occipital Group

M. splenius

ORIGIN.—From the ligamentum nuchae, from a point behind the occiput to a point over the first few thoracic vertebrae.

INSERTION.—On the lateral part of the suture between the parietal and interparietal bones and on the lambdoidal crest.

REMARKS.—In *Sicista* the insertion is on the interparietal and does not reach the parietal-interparietal suture. In *Jaculus* the insertion spreads laterad onto the surface of the bulla.

Sacrospinalis Group (Fig. 7, Fig. 8A-C)

The sacrospinalis group includes the two lateral columns of deeper epaxial muscles, *M. longissimus* and *M. iliocostalis*. Primitively, these lie lateral to the vertebral zygapophyses, but in many mammals the superficial origin of *M. longissimus* extends medial to the zygapophyses, invading the territory of the medial column, *M. transversospinalis* (Slijper, 1946). In addition, parts of *M. longissimus* and *M. iliocostalis* share common deeper origins. In dipodoids as in many other mammals, though *M. iliocostalis* and *M. longissimus* are well differentiated from one another in thoracic and cervical regions, they are fused in the lumbar region and are referred to

there as *M. sacrospinalis*. *M. longissimus* continues in the sacral region as the medial part of *M. extensor caudae lateralis*. The differences in names applied to the longissimus mass at different levels along the vertebral column in Fig. 8A-C are, therefore, arbitrary.

The epaxial muscles are delimited by aponeuroses and heavy fascial layers. The lumbosacral aponeurosis is formed by the fusion of a superficial sheet of flat tendons, which run anterolaterad from the neural spines of sacral and lumbar vertebrae, with a deep sheet of heavy tendons running anterodorsad from the metapophyses of lumbar vertebrae. Posteriorly, these tendinous sheets extend into the sacral region as heavy fascial sheets. The space medial to their junction, bounded dorsally by the spinal tendons and ventrally by the metapophyseal tendons, is occupied by *M. transversospinalis*. (Cf. Fig. 8A-C).

The spinal contribution to the lumbosacral aponeurosis is less important in dipodoids than in cricetids as described by Rinker (1954). In *Zapus* these tendons originate on neural spines of fifth lumbar through second sacral vertebrae. In *Jaculus* the origin may be even more restricted, since no tendons are formed in the sacral region. Limits could not be determined in *Sicista*. In *Sigmodon*, in contrast, the spinal tendons originate from second lumbar through fourth sacral vertebrae; in *Neotoma* origin extends as far forward as the third lumbar spine (Rinker, 1954). That the spinal sheet is much thinner in dipodoids than in cricetids is obvious on gross inspection of comparably preserved specimens, for example, of *Peromyscus* and *Zapus*. In *Peromyscus*, *M. transversospinalis* in the sacral and posterior lumbar regions is completely hidden by the shiny, white, spinal sheet of the lumbosacral aponeurosis. In *Sicista*, *Zapus* and *Jaculus* most of the transversospinal system is visible because the sheet is smaller, thin, and transparent.

The metapophyseal contribution to the lumbosacral aponeurosis in *Zapus* consists of tendons from the metapophyses of the fourth lumbar through second sacral vertebrae. In *Sigmodon* origin is from the second lumbar through second sacral vertebrae (Rinker, 1954). Metapophyseal tendons are present anterior to the fourth lumbar vertebra in *Zapus*, but these do not contribute to the lumbosacral aponeurosis. Slijper (1946, Table 3) indicated that in *Jaculus* the spinal sheet is heavier than the metapophyseal sheet. I disagree; the metapophyseal tendons in all dipodoids I dissected are much heavier than the spinal tendons. In any event, in dipodoids the spinal tendons are thinner relative to the metapophyseal tendons than in cricetids.

In the lumbar region *M. sacrospinalis* originates from the deep surface of the lumbosacral aponeurosis lateral to the junction of the two component

sheets, from the ventrolateral surfaces of the metapophyseal tendons, from the metapophyses of lumbar vertebrae, from the spine of the ilium and from the superficial surface of the lumbosacral aponeurosis. The fibers turn anteroventrad to insert on transverse processes of anterior vertebrae. A small bundle of superficial fibers in the anterior two-thirds of the lumbar region courses more directly anteriorly to insert on ribs. This bundle constitutes the only separable part of *M. iliocostalis lumborum*.

M. iliocostalis lumborum

ORIGIN.—From the lateral part of the superficial surface of the lumbosacral aponeurosis in the anterior two-thirds of the lumbar region.

INSERTION.—On the posterior surfaces of the last two or three ribs.

REMARKS.—This part of the muscle is not always separable from *M. iliocostalis dorsi*. In *Sicista* the separation is usually clear, and insertion is on the last three ribs (11 through 13). In *Zapus* the manner of insertion is individually variable but is usually on ribs 10 through 12. *M. iliocostalis dorsi* may originate on the anterodorsal surface of rib 9 or 10. If origin is on rib 9, there is a hiatus of one intercostal space between *M. iliocostalis dorsi* and *M. iliocostalis lumborum*, and the muscles are clearly separable. If origin is from rib 10, the dorsal surface of that rib may be bare of muscle. The muscles are also separable in this case. In other specimens, however, *M. iliocostalis lumborum* continues without a break into *M. iliocostalis dorsi*, and in such instances separation of the two muscles is arbitrary. In *Jaculus* the two muscles are also difficult to separate.

M. iliocostalis dorsi

This part of the muscle is distinct only in *Sicista*, where it lies over ribs 4 through 11. In *Zapus* and *Jaculus* it is difficult to separate posteriorly from *M. iliocostalis lumborum* and anteriorly from *M. iliocostalis cervicis*.

M. iliocostalis cervicis

This part originates from ribs as far anteriorly as rib 4. In *Zapus* and *Jaculus* it is indistinguishable from *pars dorsi*. In *Sicista* it is separable; it originates on ribs 3 through 9. Insertion in *Zapus* is on the transverse processes of cervical vertebrae 7 and 6, in *Sicista* on the transverse processes of several cervical vertebrae, and in *Jaculus* on the transverse processes of the fused cervical vertebrae.

M. iliocostalis is largest, relative to *M. longissimus*, in *Sicista*, smaller in *Zapus*, and smallest in *Jaculus*. According to Howell (1932) *M. iliocostalis* is also reduced in *Dipodomys*.

M. longissimus dorsi

ORIGIN.—As a continuation of the medial part of *M. sacrospinalis* of the lumbar region; and from the lateral surfaces of tendons arising from metapophyses of the last thoracic through third lumbar vertebrae.

INSERTION.—On all ribs except the first, on the accessory processes (anapophyses) of the lumbar and last thoracic vertebrae, on the fused metapophyses and accessory processes of thoracic vertebrae 7 through 12, and on the transverse processes of the last three cervical vertebrae.

REMARKS.—This muscle is very large in *Jaculus*, where it completely overshadows *M. iliocostalis*. The metapophyseal tendons from the first four lumbar and the last thoracic vertebrae do not join the lumbosacral aponeurosis, but instead lie deep and medial to it. These tendons, like the more posterior metapophyseal tendons, give rise on their medial surfaces to fibers of *M. transversospinalis*.

I detected no fibers of *M. longissimus dorsi* inserting on metapophyses in the anterior lumbar and posterior thoracic regions (Rinker, 1954), but they might have been overlooked.

In *Sicista* the insertion includes the transverse processes of only the last two cervical vertebrae. In *Jaculus* cervical insertion is on the transverse processes of the fused cervical vertebrae.

M. longissimus cervicis

ORIGIN.—From the tubercles of ribs 4, 3, and 2.

INSERTION.—On the transverse processes of cervical vertebrae 5, 4, and 3.

REMARKS.—This slender muscle lies just medial to the anterior part of *M. longissimus dorsi*. In *Sicista* it is better developed, originating from ribs 5 through 2 and inserting on the last six cervical vertebrae. Origin in *Jaculus* is from ribs 4 through 2, as in *Zapus*, and insertion is on the transverse processes of the fused cervical vertebrae.

M. longissimus capitis (*M. trachelomastoideus* Howell, 1932)

ORIGIN.—From ribs 4, 3, and 2 and from the transverse processes of the first and second thoracic vertebrae.

INSERTION.—On the lowermost part of the lambdoidal crest.

REMARKS.—This muscle is apparently absent in *Sicista*.

M. extensor caudae lateralis

Howell (1932) divided this muscle into three parts. I follow his divisions, but with revised nomenclature. The deepest part is *pars medialis* (*pars entalis* of Howell), which is the direct continuation of *M. longissimus*. It originates from the accessory processes of the last four lumbar vertebrae in *Sicista* and *Zapus*, from the last five in *Jaculus*, from the dorsal surfaces of the transverse processes of all sacral and the first few caudal vertebrae and from the neural arches below the zygapophyses of the sacral vertebrae. *Pars medialis* is thus completely covered by the iliac and aponeurotic parts of *M. sacrospinalis*. In the sacral region, *pars medialis* lies deep to the fascial continuation of the metapophyseal sheet. *Pars intermedia* (*pars intermedius* of Howell) originates on the superior iliac crest (from the iliac spine back to the sciatic notch) and from the deep surface of the fascial continuation of the lumbosacral aponeurosis. *Pars superficialis* (*pars ectalis* of Howell) originates on tips of the transverse processes of the last two or three sacral and the first few caudal vertebrae and from fascia between itself and *pars intermedia*. This fascia is continuous externally with the lumbosacral fascia. The lateral caudal extensor is relatively small in *Sicista*, larger in *Zapus*, and largest in *Jaculus*. Its enlargement might be associated with the reduction in saltators of *M. extensor caudae medialis*. Insertion is by long tendons running out on the dorsum of the tail.

Semispinalis Group (Fig. 7, Fig.8A-C)

M. transversospinalis et *M. extensor caudae medialis*

Usage of the term "M transversospinalis" follows that of Slijper (1946) and Rinker (1954). Primitively, this muscle is confined to the region between the zygapophyses and neural spines (excepting *M. semispinalis capitis*). In *Sicista* and in quadrupedal cricetids the muscle occupies this position. In saltatorial dipodoids and geomyoids, however, the lumbosacral part of the muscle has enlarged; it spreads laterad, extending almost to the iliac spine in jerboas. Primitively also, *M. transversospinalis* is continuous posteriorly with *M. extensor caudae medialis*. In saltators some differentiation occurs, along with a reduction of the medial extensor.

M. transversospinalis of the lumbar and sacral regions is composed of short fibers little differentiated into separate fascicles. The deepest fibers are the spinales and interspinales, running between neural spines, and the intertransversarii, running between transverse processes. Spinales occur in *Sicista* only between the spines of the last few lumbar vertebrae and the first sacral vertebra. The more superficial fibers originate in the lumbar region on the medial surfaces of the metapophyseal tendons and in the sacral region on the dorsomedial surface of the fascia continuous with the metapophyseal tendons. These fibers insert on neural spines of vertebrae anterior to the vertebra of origin.

In *Sicista* *M. transversospinalis* is confined to the area medial to the zygapophyses and is continuous posteriorly with *M. extensor caudae medialis*. Fibers of the latter muscle originate from neural spines of caudal, sacral, and the last lumbar vertebrae. In *Zapus*, *M. transversospinalis* lies medial to the zygapophyses only anterior to the fifth lumbar vertebra; caudal to this point it broadens and partly overlaps the lateral caudal extensor and the rest of the sacrospinalis group. In *Zapus* the lumbosacral transversospinalis is continuous anteriorly with the rest of *M. transversospinalis*, but posteriorly it terminates on the postzygapophysis of the last sacral vertebra and does not continue directly into the medial caudal extensor. Fibers of the latter muscle originate as far forward as the spine of the second sacral vertebra. In *Jaculus*, *M. transversospinalis* is confined to the space medial to the zygapophyses anterior to the fourth lumbar vertebra. Behind this point it broadens greatly, almost reaching the superior iliac spine laterally and completely overlying *M. extensor caudae lateralis* at one point. In the posterior sacral region it narrows and terminates on the postzygapophysis of the last sacral vertebra, as in *Zapus*. Anteriorly, it originates as far forward as the spine of the third lumbar vertebra where it is slightly differentiated from the remainder of *M. transversospinalis*. In *Jaculus*, *M. extensor caudae medialis* is a small, entirely separate muscle originating as far forward as the spine of the last sacral vertebra. Howell (1932) termed the lumbosacral transversospinalis "*M semispinalis pars lumborum*." The non-committal "*transversospinalis*" is a better name for the muscle.

The lumbosacral transversospinalis is also broadened in *Dipodomys*, though not to the same extent as in *Jaculus*. In *Dipodomys* the muscle extends posteriorly beyond the postzygapophysis of the last sacral vertebra, but it does not attach directly to caudal vertebrae. The mass is also slightly broadened at the level of the anterior superior iliac spine in *Perognathus*, but the muscle is not broadened at all in *Thomomys*.

Hatt (1932, p. 677) identified the lumbosacral transversospinalis in *Jaculus* as *M. extensor caudae lateralis*, stating that insertion is into the tail. Pulling out individual fascicles shows, however, that the muscle terminates on the last sacral vertebra and has no direct connection with the caudal extensor tendons emerging at its posterior border.

The function of the expanded lumbosacral transversospinalis is probably to support the head and body by pulling against the sacrum and innominate bone via the lumbosacral fascia. The progressive expansion of the muscle in dipodoids and heteromyids is associated with progressive bipedalism, since the pectoral limb serves less and less as a support for the anterior part of the body.

In many ricochetal rodents the neural spines of the sacral vertebrae tend to disappear, starting with the spine of the first sacral. Hatt (1932, fig. 20) illustrated the sacral vertebrae of several rodent genera, showing that the spines are not reduced in *Sicista*, the first (of four) is lost in *Zapus*, the first two (of four or five) in *Dipodomys*, and the first three (of four) in *Allactaga* and *Jaculus*. This reduction is associated with progressive posterior displacement of *M. extensor caudae medialis*. In *Sigmodon* and *Oryzomys*, as in *Sicista*, this muscle originates from neural spines as far forward as the last lumbar, and in *Neotoma* and *Peromyscus* origin extends as far forward as the fourth or fifth lumbar (Rinker, 1954). As the lumbosacral transversospinalis differentiates and expands, the origin of the medial caudal extensor is displaced posteriorly to the second sacral spine in *Zapus* and to the fourth sacral spine in *Jaculus*. The functionless neural spines disappear, leaving a median space which can be probed from the exterior down to the bone. The walls of this cavity in *Zapus*, *Dipodomys*, and *Jaculus* are formed by heavy transversospinalis fascicles originating on the anterior surface of the last sacral spine and inserting on the posterior surface of the last lumbar spine. These fascicles may be called semispinales.

The tail in these advanced ricochetors is probably extended by *M. extensor caudae lateralis* and by heavy caudal strips of *M. cutaneus maximus*. Expansion of the lumbosacral transversospinalis, reduction of *M. extensor caudae medialis*, and disappearance of the sacral neural spines has probably occurred independently in ricochetal dipodoids and geomyoids, since quadrupedal representatives of both of these superfamilies have the primitive, unmodified condition.

In the prediaphragmatic region, *M. transversospinalis* is differentiated into separate fascicles. Semispinalis fascicles, spanning four or more intervertebral spaces, are present from the second lumbar vertebra on forward. Transversospinalis fascicles take origin from medial surfaces of the metapophyseal tendons from the first two lumbar and the last two thoracic vertebrae. Anterior to the eleventh thoracic vertebra, these fibers originate on the fused metapophyses and accessory processes of the vertebrae without formation of tendons.

M. semispinalis capitis is present in all dipodoids. In *Sicista* and *Zapus* it originates from the tubercles and necks of ribs 3 to 7, from the transverse processes of the first four thoracic vertebrae, and from the laminae of the last five cervical vertebrae. It inserts on the occipital crest. The component parts, "biventer cervicis" and "complexus" of authors, are fused, but they can be distinguished on the basis of point of origin of fibers and by the fact that a tendinous inscription crosses the "complexus" but not the "biventer cervicis."

The deeper part of *M. transversospinalis* continues into the cervical region medial to *M. semispinalis capitis* as *M. semispinalis cervicis*. This muscle corresponds to the "spinalis dorsi" of Hatt and some other authors. In *Sicista* and *Peromyscus*, *M. semispinalis cervicis* is an undifferentiated rope-like mass running from the thorax into the neck and terminating on the spine of the axis. Fibers originate on transverse processes and insert on spinous processes of vertebrae anterior to the vertebra of origin. In *Zapus* the muscle is partly differentiated into a horizontal part, which inserts on neural spines as far forward as the sixth cervical vertebra, and a vertical part, which originates on the

laminae of the first two thoracic vertebrae and inserts on the spines of the fifth through second cervicals. In *Jaculus* separation of the muscle is complete and its two parts cross each other at a right angle. Hatt (1932) observed the same differentiation in *Jaculus* as compared with *Rattus*. He interpreted the differentiation as "due to the necessity of staggering the direction of muscle slips along a sharp concavity," the concavity resulting from sharp flexion of the neck in advanced ricochetors. Differentiation of *M. semispinalis cervicis* into horizontal and vertical parts has not occurred in *Dipodomys*, however, even though the neck is sharply flexed in that genus.

In *Dipodomys*, *M. transversospinalis* is expanded in the thoracic region (Howell, 1932). Such expansion is not found in dipodoids.

Mm. intertransversarii dorsales

These fibers run from the sides of cervical vertebrae anterolaterad to the transverse processes of cervical vertebrae anterior to the vertebra of origin. They lie medial to *M. levator scapulae* and *M. longissimus cervicis*, and lateral to *M. semispinalis capitis*, as in the muroids dissected by Rinker (1954). They were not sought in *Sicista* and *Jaculus*.

Suboccipital Group

M. rectus capitis posterior major

ORIGIN.—From the tip of the spine of the axis.

INSERTION.—On the supraoccipital region, dorsal to the insertion of *M. rectus capitis posterior minor*.

REMARKS.—This muscle completely covers *M. rectus capitis posterior minor*.

M. rectus capitis posterior minor

ORIGIN.—From the anterodorsal surface of the dorsal arch of the atlas.

INSERTION.—On the supraoccipital region, deep to the insertion of *M. rectus capitis posterior major*.

REMARKS.—In *Jaculus* this muscle seems to be poorly developed by comparison with *Sicista* and *Zapus*.

M. obliquus capitis superior

ORIGIN.—From the transverse process of the atlas.

INSERTION.—On the occiput, lateral to the insertion of *M. rectus capitis posterior major*.

REMARKS.—Howell (1926, 1932), following Reighard and Jennings (1901), described two parts of this muscle: *M. obliquus capitis superior* and "*M. rectus capitis lateralis*." Both parts originate on the atlantal transverse process, and both insert on the occiput lateral to the insertions of the major and minor recti posterior. The two parts should be considered *M. obliquus capitis superior*. They are variably differentiated in dipodoids.

M. obliquus capitis inferior

ORIGIN.—From the lateral surface of the axial spine and from part of the dorsal surface of the lamina of the axis.

INSERTION.—On the transverse process of the atlas.

REMARKS.—More fibers may originate on the axial lamina in *Jaculus* than in the other genera.

Cervical Prevertebral Group

M. rectus capitis anterior

ORIGIN.—From the anterior edge of the transverse process of the atlas.

INSERTION.—On the ventral surface of the basioccipital, deep and lateral to the insertion of *M. longus capitis*.

M. longus colli

Superior and inferior parts of this muscle are difficult to separate. The superior part originates on the carotid tubercle of the sixth cervical vertebra, on the transverse processes of cervicals 5 through 2, and from the bodies of the last cervical and the first three thoracics. Insertion is on the bodies of the last six cervicals and on the midventral tubercle of the ventral arch of the atlas. The insertion on the tubercle forms the bulk of the muscle. The inferior part originates by heavy fascia on the ventral surfaces of the bodies of the anterior thoracic vertebrae; muscular fibers are absent posterior to the level of the fourth thoracic. Insertion is primarily on the carotid tubercle of the sixth cervical vertebra.

M. longus capitis

ORIGIN.—From the carotid tubercle of the sixth cervical vertebra and from the ventral surfaces of the transverse processes of the fifth through third and the seventh cervicals.

INSERTION.—On the ventral surface of the basioccipital as far anteriorly as the suture between that bone and the basisphenoid.

Lumbar Prevertebral Group (Fig. 14)

M. quadratus lumborum

ORIGIN.—By short tendons from the transverse processes of the first sacral and third through seventh lumbar vertebrae.

INSERTION.—On the bodies of the first two lumbar and last three thoracic vertebrae.

M. psoas minor

ORIGIN.—From the body of the third lumbar vertebra.

INSERTION.—By a thin tendon on the iliopectineal eminence.

REMARKS.—In *Jaculus*, origin is from the first three lumbar.

Caudal Flexor Group

M. flexor caudae lateralis (*M. flexor caudae externus* Howell, 1932)

ORIGIN.—From the bodies and transverse processes of the third lumbar through the second caudal vertebrae.

INSERTION.—On the ventral surfaces of caudal vertebrae.

M. flexor caudae medialis (*M. flexor caudae internus* Howell, 1932)

ORIGIN.—From the bodies of seventh lumbar through fourth sacral vertebrae.

INSERTION.—On the ventral surfaces of caudal vertebrae.

REMARKS.—This complex muscle is divisible into a number of separate parts and is difficult to separate from *M. flexor caudae lateralis*. No attempt is made here to distinguish the parts seen in this muscle by Howell (1932).

Medial Ventral Cervical Group

M. geniohyoideus

ORIGIN.—From the medial surface of the mandible near the symphysis, in common with the tendon of *M. genioglossus*.

INSERTION.—On the anterior surface of the basihyal and thyrohyal bones, superficial to the origin of *M. hyoglossus*.

REMARKS.—This muscle lies deep to *M. mylohyoideus* and superficial to *M. hyoglossus*. Anteriorly, it is separated from the latter muscle by the hypoglossal nerve.

M. sternohyoideus

ORIGIN.—From the second costal cartilage, in common with the origin of *M. sternothyroideus*.

INSERTION.—On the posterior surface of the basihyal bone.

REMARKS.—Just anterior to the first rib, an oblique tendinous inscription crosses the common origin of *M. sternohyoideus* and *M. sternothyroideus*. Anterior to this inscription the two muscles are distinct.

M. sternothyroideus

ORIGIN.—From the second costal cartilage, in common with *M. sternohyoideus*.

INSERTION.—On the thyroid cartilage of the larynx.

M. thyrohyoideus

ORIGIN.—From the thyroid cartilage of the larynx.

INSERTION.—On the posterior surface of the basihyal, deep to the insertion of *M. sternohyoideus*.

M. omohyoideus

ORIGIN.—From the cranial border of the scapula near the coracoid process.

INSERTION.—On the posterolateral surface of the hyoid bone, partly deep to the insertion of *M. sternohyoideus* and superficial to the insertion of *M. thyrohyoideus*.

REMARKS.—Howell (1932) found this muscle in *Allactaga* and *Jaculus*, but not in *Zapus*. I found it in all dipodoids I dissected. It is easily broken during dissection because of the close approximation of head and shoulders in small ricochetal rodents, and I assume that Howell overlooked the muscle in his specimen of *Zapus*. The tendency toward reduction and loss of *M. omohyoideus* is present in caviomorph rodents (Parsons, 1896).

Lateral Cervical Group (Fig. 9B)

M. rectus capitis lateralis

ORIGIN.—From the anterior surface of the ventral part of the arch of the atlas.

INSERTION.—On the posterior surface of the jugular process.

M. scalenus

ORIGIN.—From the transverse processes of cervical vertebrae.

INSERTION.—On the first through fourth ribs.

REMARKS.—The ventral part of this muscle, originating on the axial transverse process and inserting on the first rib, is always distinct. The remainder of the muscle splits into a variable number of strips which interlace with slips of *M. serratus anterior*.

M. scalenus in dipodoids is entirely dorsal to the cervical and brachial plexus; the homologue of the human anterior scalene is probably not present in these rodents.

M. intertransversarius lateralis longus

ORIGIN.—From the first rib and from transverse processes of the last three or four cervical vertebrae.

INSERTION.—On the transverse processes of the anterior cervical vertebrae.

REMARKS.—This muscle lies medial to *M. scalenus* and lateral to *M. levator scapulae*. Anteriorly, it shares common tendons of insertion with *M. scalenus*. Identification of this muscle follows Rinker (1954).

Medial Thoracoabdominal Group (Fig. 9B)

M. rectus abdominis

ORIGIN.—From the pubis, in the symphyseal region, and from the ventromedial third of the inguinal ligament.

INSERTION.—On the lateral and posterior surfaces of the manubrium sterni and the posterior surface of the first rib.

REMARKS.—Posteriorly, *M. rectus abdominis* is divided into two parts. The medial part originates from the pubis, its fibers decussating slightly with fibers from the other side of the animal. As it passes anteriorly, this part of the muscle broadens somewhat and diverges from the midline. The greatest deviation from the midline occurs at the level of the xiphisternum. Anterior to the xiphisternum the muscle approaches the midline again and inserts on the manubrium and first rib. The lateral part originates from the inguinal ligament and is there inseparable from the fibers of *M. obliquus abdominis externus*. The lateral part joins the medial part over rib cartilages 12 through 5. Here the fibers of the lateral part run at a right angle to the fibers of *M. obliquus abdominis externus*. Over the cartilage of rib 4, the combined rectus muscles become narrow, and lateral and medial parts are inseparable.

Lateral and medial parts of this muscle seem to be present in *Sicista* and *Jaculus* also. Howell (1932) found a well-developed lateral part in *Dipodomys*, and Hill (1937) found it in *Thomomys* and *Geomys*, but not in squirrels and *Aplodontia*. Rinker (1954) found no lateral part in his cricetids.

The medial part is enclosed in a sheath formed by the ventral fasciae of the external and internal obliques and *M. transversus abdominis*. The fascia of *M. obliquus abdomi-*

nis externus is everywhere superficial to the medial part of *M. rectus abdominis*. The fascia of *M. obliquus abdominis internus* occurs in two layers. The deeper of these becomes superficial to the medial rectus about 1.5 cm. posterior to the xiphisternum; the superficial fascia becomes superficial somewhere between this point and the xiphisternum. The fascia of *M. transversus abdominis* becomes superficial to the medial rectus about 1 cm. anterior to the pubis in *Zapus*, so that the medial rectus posterior to this point lies deep to the fasciae of all three abdominal muscles. These relationships could not be determined in the other dipodoids dissected. The origin in *Sicista* and *Jaculus* was not determined.

M. pyramidalis

This muscle was probably overlooked.

Lateral Thoracoabdominal Group (Fig. 9B)

M. serratus posterior superior

ORIGIN.—From the ligamentum nuchae, deep to the origin of *M. rhomboideus*.

INSERTION.—On ribs 6, 7, and 8.

REMARKS.—This muscle is thicker in *Sicista* than in *Zapus*, and inserts on ribs 5, 6, and 7. In *Jaculus* insertion is on ribs 4, 5, and 6.

M. serratus posterior inferior

ORIGIN.—By aponeurosis in the dorsal midline in the posterior thoracic region.

INSERTION.—On the last four or five ribs.

REMARKS.—As in many other rodents (Rinker, 1954), the posterior border of this muscle is continuous with the anterior border of *M. obliquus abdominis internus*. Contrary to Howell (1932), this muscle is easily discerned in *Zapus*. The aponeurosis by which it originates lies superficial to the lumbosacral aponeurosis.

M. sternocostalis

ORIGIN.—By aponeurosis over the ventral midline at the level of the sternum's junction with the cartilages of ribs 3 and 4.

INSERTION.—On the posterior surface of the first rib, the costochondral junction, and the costal cartilage.

REMARKS.—As in some cricetids (Rinker, 1954) this muscle passes dorsolaterad superficial to *M. rectus abdominis*. The insertional half is fleshy in all dipodoids dissected.

Mm. intercostales externi

Fibers run posteroventrad from one rib to another. Their origins occur in the region between the tubercles of the ribs dorsally and points just below the costochondral junctions ventrally. Dorsally, the fibers are indistinguishable from those of *Mm. levatores costarum*. Some fibers originating on the first rib insert on the third and fourth ribs.

Mm. levatores costarum

ORIGIN.—From the transverse processes or anapophyses of all thoracic vertebrae.

INSERTION.—On the angles of all ribs.

M. obliquus abdominis externus

ORIGIN.—From the last seven or eight ribs (6 through 12 or 5 through 12) and from part of the aponeurosis of origin of *M. obliquus abdominis internus*.

INSERTION.—Into the linea alba at the midline, on the pubis near the symphysis and into a tendon (Poupart's ligament of Howell) attaching to the symphysis pubis and the anterior superior iliac spine.

REMARKS.—The median insertion of this muscle is everywhere superficial to *M. rectus abdominis*. At origin, the muscle interdigitates with some of the inserting slips of *M. serratus anterior*. The extent of the interdigitation depends on the anterior extent of *M. obliquus abdominis externus* and the posterior extent of *M. serratus anterior*, both of which vary.

The cranial fibers of *M. obliquus abdominis externus* are transverse; as one progresses caudad over the abdomen the fibers assume a more caudal direction, running almost entirely caudad at insertion on the pubis and tendon. In the posterior thoracic and anterior abdominal regions this muscle is entirely distinct from the lateral part of *M. rectus abdominis*. In the posterior abdominal region, fibers of the two muscles are confused.

The ligament running between ilium and pubis coincides with the inguinal border of *M. obliquus abdominis internus* and *M. transversus abdominis* in its dorsolateral half. Rinker (1954) found that in cricetids the ligament and border coincide in their ventromedial third.

Origin of this muscle is from the last nine ribs (5 through 13) in *Sicista* and from the last eight ribs (5 through 12) in *Jaculus*.

M. obliquus abdominis internus

ORIGIN.—Aponeurotically from the dorsal midline over the third to seventh lumbar vertebrae, from the anterior superior iliac spine and from an inguinal border which coincides with the dorsolateral half of the inguinal insertion of *M. obliquus abdominis externus*.

INSERTION.—On the posterior surfaces of the last two ribs, on the cartilages of ribs 10 through 7, and into the linea alba.

REMARKS.—The anterior border of this muscle is continuous with the posterior border of *M. serratus posterior inferior*. As in some cricetids, the fibers of *M. obliquus abdominis internus* inserting on rib 11 are inseparable from the fibers of *M. intercostalis internus* which span the space between ribs 11 and 12. The fibers of this muscle run mainly anteroventrad deep to the lateral part of *M. rectus abdominis*.

Mm. intercostales interni

These muscles occupy the region between the angles of ribs and the sternum. Fibers run anteroventrad from rib to rib.

Mm. subcostales

Rinker (1954) found these muscles to differ from one side of an animal to the other. They are present in dipodoids but were not dissected in detail.

M. transversus thoracis

ORIGIN.—From the internal surface of the xiphisternum and all sternabrae except the first.

INSERTION.—On the second to seventh costal cartilages.

REMARKS.—In *Sicista* the origin does not seem to cover the first two sternbrae.

M. transversus abdominis

ORIGIN.—From the caudal edge of the rib cage, from a dorsal aponeurosis shared with the origin of *M. obliquus abdominis internus*, and from the inguinal ligament except for its ventromedial half.

INSERTION.—Into the ventral midline at the linea alba.

M. cremaster

This muscle is of the usual conformation in males. Fibers derived from *M. obliquus abdominis internus* and from *M. transversus abdominis* form a two-layered sheath for the testis, the fibers crossing at right angles. The muscle is most visible when the testes are scrotal.

Diaphragma

The posterior limit of attachment of the crura varies among dipodoids. In *Jaculus* and *Zapus* the crura arise from the last thoracic through fourth lumbar vertebrae, and in *Sicista* from the last thoracic through the third lumbar. The remainder of the muscle arises from the posterior border of the thoracic cage and from the xiphisternum.

Perineal Group

M. ischiocavernosus, *M. bulbocavernosus*, and *M. sphincter ani externus* were studied in males only.

M. iliococcygeus (*M. iliocaudalis* Howell, 1932)

ORIGIN.—From the internal surface of the ilium, from a point behind the sacroiliac joint to the level of the acetabulum.

INSERTION.—On the transverse processes of caudal vertebrae posterior to the fourth caudal.

REMARKS.—This muscle seems to be relatively larger in *Jaculus* than in *Sicista* and *Zapus*. At its terminus it forms several heavy tendons that run out along the tail.

M. pubococcygeus (*M. pubocaudalis* Howell, 1932)

ORIGIN.—From the internal surface of the horizontal ramus of the pubis, between the iliopectineal eminence and the symphysis.

INSERTION.—On the transverse processes of the third and fourth caudal vertebrae, superficial to the insertion and tendons of *M. iliococcygeus*.

M. coccygeus (*M. sacrospinus* Howell, 1932)

ORIGIN.—From the dorsal part of the internal surface of the ilium just posterior to the acetabulum.

INSERTION.—On the transverse processes of the first three caudal vertebrae.

REMARKS.—No part of this muscle was seen to originate on the obturator membrane.

M. ischiocavernosus

ORIGIN.—From almost the entire posterior border of the inferior ischial ramus.

INSERTION.—On the crus of the corpus cavernosum penis close to its attachment to the ischium.

REMARKS.—The insertion seems to be confined to the lateral and dorsal surfaces of the crus.

M. bulbocavernosus

As in some cricetids (Rinker, 1954), the bulbar urethra is bilobate, and *M. bulbocavernosus* is separated into left and right halves. Fibers take origin dorsally and posteriorly from a raphe in the cleft between the lobes of the bulbous urethra. The more ventral fibers pass almost directly ventrad; more dorsal fibers pass caudoventrad and turn anteriorly and medially to insert on the crus of the corpus cavernosum penis and on the bulbar part of the urethra. No distinct ventral part is separate in *Zapus*, as it is in some cricetids. The state of development of this muscle is highly dependent on the reproductive condition of the animal when killed.

M. sphincter ani externus

In *Sicista* this muscle seems to be fairly distinct from *M. bulbocavernosus*. Fibers originate on the dorsal surface of the bulbus penis and pass dorsomedially dorsal to the rectum. At the midline, they pass into fibers of *M. sphincter ani externus* of the other side. Some fibers continue directly across, while others seem to show a tendinous intersection in the median line. This intersection is more visible on the ventral surface than on the dorsal surface of the muscle.

The apparent distinctness of this muscle from *M. bulbocavernosus* seems to vary with the reproductive state of the male. But even when males with fully scrotal testes are compared, distinctness seems to be greater in *Sicista* than in *Zapus*. In all specimens of *Jaculus* dissected, the two muscles could be distinguished only by insertion of their fibers, but none of the jerboas had scrotal testes. Tullberg (1899) considered both muscles part of *M. bulbocavernosus* in rodents, and his figures (Plate XLIX, 10, 14, 17, 18) indicate that the muscles are externally inseparable in *Zapus* and *Jaculus*. He did not state the reproductive condition of his specimens, however.

Rinker (1954) applied the term "*M. sphincter ani externus*" to this muscle with "considerable reservation," and I apply it with similar reservation. Rinker outlined the reasons why this muscle is probably not homologous to the human muscle of the same name. In dipodoids, as in cricetids, there is a more distal group of circular fibers around the rectum which may represent the true external sphincter. Greene (1935) incorrectly termed the sphincter ani externus "*M. levator ani*" in *Rattus*. The human muscle of that name corresponds to the rodent *M. pubococcygeus* and *M. iliococcygeus*, and not to the rodent *M. bulbocavernosus* or *M. sphincter ani externus*.

APPENDICULAR MUSCULATURE

MUSCLES OF THE PECTORAL GIRDLE AND LIMB

Extensor System

Costo-Spino-Scapular Group (Fig. 9)

M. levator scapulae et *M. serratus anterior* (*M. serratus magnus* and *M. atlantoscapularis superior* Howell, 1932)

ORIGIN.—From the transverse processes of all cervical vertebrae and from ribs 1 through 7 or 8.

INSERTION.—On the medial side of the vertebral border of the scapula below the insertion of *M. rhomboideus*.

REMARKS.—As in many rodents, two components of this sheet are not separable on any basis other than innervation. Howell (1932) referred to *M. levator scapulae* as the "depressor scapulae" part of *M. serratus magnus*. He separated the slip originating on the atlantal transverse process as "*M. atlantoscapularis superior*."

The posterior limit of origin of this muscle varies within species. In *Zapus* the most caudal slip of origin may be on rib 7 or rib 8, both conditions being common. In *Sicista* all specimens dissected show the last origin on rib 7. In *Jaculus* the caudalmost origin is from rib 6 in my specimens, and Howell (1932) reported caudalmost origin on rib 5 in his specimen. The fibers originating on the atlantal transverse process are present in all dipodoids I dissected. They are also present in heteromyids (Howell, 1932) and geomyids (Hill, 1937), but not in cricetids (Rinker, 1954).

As in cricetids, the relationship of this muscle to *M. scalenus* is complex and individually variable. In dipodoids the fibers originating on the post-atlantal cervical transverse processes and on ribs 1 and 2 are deep to *M. scalenus*. The slip from rib 3 may or may not be crossed by one slip of *M. scalenus*, but is otherwise superficial to that muscle. In *Zapus*, but not in *Sicista* and *Jaculus*, the ventral part of the slip from rib 3 is deep to *M. rectus abdominis*. The fibers from the ribs posterior to the third are all superficial to *M. scalenus*.

M. rhomboideus (*M. rhomboideus dorsi* Howell, 1932)

ORIGIN.—From the cranial 7 mm. of the nuchal ligament, the anterior point of origin coinciding with the anterior point of origin of *M. splenius*.

INSERTION.—On the vertebral border of the scapula, including the posterior half of the supraspinous border and the entire infraspinous border.

REMARKS.—This muscle is not divisible into two parts, as it is in some other rodents. In *Jaculus* it is fused with *M. occipitoscapularis*.

M. occipitoscapularis (*M. rhomboideus capitis* Howell, 1932)

ORIGIN.—From the lambdoidal crest opposite the lower half of the lambdoidal origin of *M. temporalis*.

INSERTION.—On the vertebral border of the scapula, including the posterior part of the supraspinous region and a small part of the infraspinous region of the border.

REMARKS.—No part of this muscle is reflected onto the medial side of the scapula as in *Sigmodon* (Rinker, 1954), and no fibers attach to the scapular spine.

M. omocervicalis (*M. atlantoscapularis inferior*, Howell, 1932)

ORIGIN.—From the ventral surface of the body of the atlas and from the midventral tubercle.

INSERTION.—On the dorsal edge of the acromion and fascially on the lateral end of the clavicle, overlapping the insertion of *M. acromiotrapezius*.

Latissimus-subscapular Group (Figs. 9, 10, 11)

M. latissimus dorsi

ORIGIN.—By aponeurosis over the last thoracic and first two lumbar vertebrae, deep to the origin of *M. spinotrapezius*.

INSERTION.—On the humerus behind the crest of the lesser tuberosity, in common with *M. latissimus dorsi*.

REMARKS.—The origin is broader in *Sicista*, extending over the last four thoracic and the first two lumbar vertebrae, than in *Zapus* and *Jaculus*. In cricetids the origin is much broader even than in *Sicista*, overlying the posterior half of the thoracic series and most of the lumbar series (Rinker, 1954). According to Howell (1932) *M. latissimus dorsi* is not reduced in *Dipodomys*.

M. teres major

ORIGIN.—From the lateral and medial surfaces of the posterior angle of the scapula, and from the axillary border of the scapula and the surface of *M. infraspinatus* in the proximal third of the scapula.

INSERTION.—In common with the tendon of *M. latissimus dorsi* on the humerus behind the crest of the lesser tuberosity.

REMARKS.—*M. latissimus dorsi* forms a flat tendon which is applied to the surface of *M. teres major* near insertion. In *Zapus* fusion of the two insertions usually occurs distal (ventral) to the origin of *M. dorsoepitrochlearis* from *M. teres major*. In *Jaculus* fusion usually occurs proximal (dorsal) to this point. The common tendon of *M. teres major* and *M. latissimus dorsi* is crossed by the inserting fibers of *M. coracobrachialis profundus*.

M. subscapularis

ORIGIN.—From the entire subscapular fossa of the scapula and the septum between *M. subscapularis* and *M. supraspinatus*.

INSERTION.—On the caudal and dorsal surfaces of the lesser tuberosity of the humerus.

REMARKS.—This muscle is composed of a number of bipennate fascicles. The distal part of the subscapular fossa is bare of fibers, since the muscle is fascial there. The tendon of insertion is crossed by the tendon of *M. coracobrachialis*.

Deltoid Group (Figs. 9, 10)

M. clavo-acromiodeltoideus

ORIGIN.—From the lateral half of the clavicle and the ventral edge of the acromion.

INSERTION.—On the dorsal tip and both sides of the deltoid crest of the humerus.

REMARKS.—Acromial and clavicular parts of this muscle are not distinct.

M. spinodeltoideus

ORIGIN.—From the tuberosity in the crest of the scapular spine and from the spine itself between the tuberosity and the acromion.

INSERTION.—On the posterior surface of the deltoid crest of the humerus.

REMARKS.—The acromial fibers of *M. clavo-acromiodeltoideus* overlap the insertion of *M. spinodeltoideus*, and the latter is entirely tendinous in the region of overlap. In *Jaculus*, *M. spinodeltoideus* seems to be less distinct from *M. clavo-acromiodeltoideus* than in the other genera.

M. teres minor

ORIGIN.—From the distal half of the axillary border of the scapula.

INSERTION.—On the greater tuberosity of the humerus below the insertion of *M. infraspinatus*.

REMARKS.—This muscle is small in all dipodoids and is mostly hidden beneath *M. infraspinatus*. Just before inserting, its tendon becomes visible in lateral view.

Suprascapular Group (Fig. 10)

M. supraspinatus

ORIGIN.—From the dorsal border and cavity of the supraspinous fossa, from the dorsal border of the scapular spine and from the septum between this muscle and *M. subscapularis*.

INSERTION.—On the dorsocranial surface of the greater tuberosity.

REMARKS.—As in some cricetids (Howell, 1926; Rinker, 1954), this muscle is separable into two parts. In the dipodoids the fibers from the tuberosity and that part of the spine distal to the tuberosity form a rather distinct mass superficial to the remainder of the muscle. The fibers of the superficial part insert mainly on the aponeurosis between the two parts; few fibers insert on the greater tuberosity. In the proximal region of the spine, dorsal to the tuberosity, the separation between the two parts does not exist, in contrast to the condition seen in cricetids. In general, the two parts seem to be better differentiated in *Peromyscus* than in *Zapus*.

M. infraspinatus

ORIGIN.—From the infraspinous fossa and the caudal surface of the scapular spine.

INSERTION.—On the caudal surface of the greater tuberosity of the humerus.

REMARKS.—This muscle is bipennate in dipodoids as in many other rodents. The size of the supraspinous fossa is smaller, relative to the infraspinous fossa, than in *Zapus* and *Sicista*, but *M. supraspinatus* does not seem to be relatively larger in *Jaculus*.

According to Cheng (1955), *M. supraspinatus* and *M. infraspinatus* represent the reptilian *M. supracoracoideus*. They could justifiably be grouped with the ventral, rather than dorsal muscles.

Triceps Group (Figs. 10, 11)

M. dorsoepitrochlearis

ORIGIN.—From *M. teres major*.

INSERTION.—Fascially on the medial surface of the olecranon.

REMARKS.—Strongest attachment at origin is always to *M. teres major*, but a fascial connection to *M. latissimus dorsi* is usually present. No attachment to the scapula was seen.

M. dorsoepitrochlearis and the bellies of *M. triceps* are served by the radial nerve. Cheng (1955), however, claimed that in the opossum embryo *M. dorsoepitrochlearis* (his *omoanconeus*) is derived from the same primordium as *M. latissimus dorsi* rather than from the primordium of *M. triceps*.

M. triceps brachii, caput lateralis

ORIGIN.—From the greater tuberosity and proximal half of the deltoid crest of the humerus and from the head of the humerus posterior to the greater tuberosity.

INSERTION.—On the lateral surface of the olecranon.

REMARKS.—The origin from the posterior part of the greater tuberosity and the head of the humerus is fibrous; the remainder of the origin is aponeurotic. The anterior border of this muscle crosses the lateral epicondylar ridge and *M. anconeus*.

M. triceps brachii, caput medialis

ORIGIN.—From the posteromedial surface of the distal two-thirds of the humerus.

INSERTION.—On the medial surface of the olecranon.

M. triceps brachii, caput longus

ORIGIN.—From the distal fifth of the axillary border of the scapula, from the inferior lip of the glenoid socket, and from the scapular spine in the acromial region.

INSERTION.—On the posterior surface of the olecranon.

REMARKS.—In *Sicista* the origin occupies the distal fourth of the axillary border. The origins from the scapular blade are fleshy; that from the acromion is ligamentous. In many rodents an aponeurosis runs ventrad from the metacromion (or from the acromion when the metacromion is not developed) and curves around the distal parts of *M. teres minor* and *M. infraspinatus* to attach to the axillary border of the scapula. It encloses these muscles and separates them from *M. teres major*. This aponeurosis occurs in *Lagostomus* (Parsons, 1894), *Rhizomys* (Parsons, 1896), *Sigmodon*, *Oryzomys* (Rinker, 1954), *Dipodomys* (Howell, 1932), and *Sicista*, *Zapus*, and *Jaculus*. In some of these forms, including the dipodoids, part of *caput longus* of *M. triceps* takes origin from the aponeurosis. In dipodoids, as in some other rodents, the part of the aponeurosis between acromion and triceps is thickened into a distinct ligament, particularly visible in very dry specimens.

M. anconeus

ORIGIN.—From the posterior surface of the lateral epicondyle and epicondylar ridge of the humerus.

INSERTION.—Into a groove on the lateral surface of the olecranon.

REMARKS.—This muscle is distinct from *M. triceps caput lateralis* which overlies it,

but it is inseparable from caput medialis. *M. anconeus* and caput medialis are supplied by different branches of the radial nerve. But for this difference, distinction between the two muscles in dipodoids is lacking. A true anconeus element supplied by the radial nerve is not present on the medial side of the elbow.

Extensor Group of the Forearm (Figs. 10, 11)

M. brachioradialis

ORIGIN.—From the lateral epicondylar ridge of the humerus, proximal and partly medial to the origin of *M. extensor carpi radialis longus*.

INSERTION.—Over the carpals, primarily on the radial side of the wrist.

REMARKS.—This muscle is present in all dipodoids dissected by Howell (1932) and by me. The tendon of insertion fans out and seems to attach to the dorsal ligaments of the intercarpal joints beyond the radial-carpal articulation. A radial extension of this tendon runs ventrad to insert in the skin behind the thenar pad. Parsons (1894) gave the insertion of this muscle (his "supinator longus") in *Jaculus* as "into the base of the metacarpal bone of the pollex." The pollical insertion in *Jaculus* probably corresponds to the thenar insertion in *Sicista* and *Zapus*.

The tendon of *M. brachioradialis* crosses the wrist immediately to the radial side of the tendon of *M. extensor carpi radialis longus*, lying somewhat deeper than that tendon in the same compartment.

M. brachioradialis also occurs in *Erethizon* (Parsons, 1894) and in sciurids (Hill, 1937; Bryant, 1945). It is absent in *Castor*, *Aplodontia*, geomyoids, muroids, hystricomorphs, and caviomorphs other than erethizontids (Hill, 1937; Rinker, 1954; Parsons, 1894, 1896). When present in mammals, insertion is usually on the distal part of the radius, but in dipodoids, monotremes, marsupials, and some Xenarthra, a carpal insertion is present instead (Straus, 1941). Since this muscle occurs widely among mammals other than rodents, its persistence in a few rodent groups may be taken as the survival of a primitive character.

M. extensor carpi radialis longus

ORIGIN.—From the lateral epicondylar ridge between the origins of *M. brachioradialis* and *M. extensor carpi radialis brevis*, partly overlapping the origin of the former.

INSERTION.—On the dorsomedial side of the second metacarpal.

REMARKS.—The belly of this muscle is about twice the bulk of the belly of *M. brachioradialis* and slightly greater than that of *M. extensor carpi radialis brevis*.

M. extensor carpi radialis brevis

ORIGIN.—From the lateral epicondylar ridge between the origins of *M. extensor carpi radialis longus* and *M. extensor digitorum superficialis*.

INSERTION.—On the medial side of the third metacarpal.

REMARKS.—Howell (1932) gave the insertion as on the second metacarpal. Though the tendon of insertion runs over the second metacarpal, it does not attach there.

M. supinator

ORIGIN.—From the capsule of the humero-radial joint and from the capitulum of the humerus.

INSERTION.—On the proximal half of the radius.

REMARKS.—In *Jaculus*, insertion is on the proximal third of the radius.

M. extensor pollicis brevis (*M. extensor metacarpi pollicis* Howell, 1932, part)

ORIGIN.—From the ulna and the interosseous membrane in the middle third of the forearm.

INSERTION.—On the falciform bone.

M. abductor pollicis longus (*M. extensor metacarpi pollicis* Howell, 1932, part)

ORIGIN.—From the proximal third of the radius, and from the ulna between a point opposite the semilunar notch and a point halfway from the notch to the carpus.

INSERTION.—On the first metacarpal.

REMARKS.—The tendons of this muscle and the preceding one run distad and laterad over the tendons of *Mm. extensores carpi radialis longus* and *brevis* and *M. brachioradialis*, and pass through the first (radialmost) compartment of the wrist. At the compartment, the tendon of *M. abductor pollicis longus* lies deep to the tendon of *M. extensor pollicis brevis*.

M. extensor digitorum (*M. extensor digitorum communis* Howell, 1932)

ORIGIN.—From the lateral epicondylar ridge between the origins of *M. extensor carpi radialis brevis* and *M. extensor digiti minimi*.

INSERTION.—On the dorsal surfaces of digits 2 through 5.

REMARKS.—This muscle is composed of four parts. The radial superficial head inserts on the second digit; the ulnar superficial head on the fourth and fifth. The two deeper heads have very small, thin bellies and insert on digits 3 and 4. Dipodoids resemble cricetids in structure of this muscle, except that the ulnar superficial head inserts on digits 3 and 5 in cricetids (Howell, 1926; Rinker, 1954).

The tendons of *M. extensor digitorum* pass through a compartment on the wrist in common with the tendons of *M. extensor indicis* and *M. extensor digiti tertii proprius*. Over the dorsum of the manus, the tendons of *M. extensor digitorum* are connected by fascial bands.

M. extensor indicis

ORIGIN.—From the middle fifth of the ulna.

INSERTION.—On the dorsum of the second digit.

M. extensor digiti tertii proprius

ORIGIN.—From the lateral epicondylar ridge, deeply between the bellies of *M. extensor digitorum* and *M. extensor digiti minimi*.

INSERTION.—On the dorsum of the third digit.

REMARKS.—The tendon of this muscle passes through the same compartment as the tendons of the two preceding muscles, and the origin is intimately related to the bellies of *M. extensor digitorum*. Bryant (1945) described the probable homologue of this muscle in squirrels as the radial part of *M. extensor digiti minimi* (his *M. extensor digiti quinti proprius*). In a specimen of *Tamias* which I dissected the muscle arose as a thin aponeurosis between the origins of *M. extensor digitorum* and *M. extensor digiti minimi*. Midway down the forearm, a belly was formed. Insertion was on the dorsum of the third metacarpal.

This muscle is absent in the cricetids described by Rinker (1954) and in geomyids described by Hill (1937). Howell (1932) did not mention it for *Dipodomys*, and I was unable to find it in specimens of that genus.

M. extensor digiti minimi (*M. extensor digiti quinti* Howell, 1932)

ORIGIN.—From the lateral epicondylar ridge between the origins of *M. extensor digitorum* and *M. extensor carpi ulnaris*.

INSERTION.—On the dorsal surfaces of the fourth and fifth digits.

REMARKS.—Insertion in *Jaculus* is on digit 5 only. Howell (1932) reported insertion on digits 4 and 5 in *Allactaga* and on digit 5 in *Jaculus*. In all dipodoids dissected the tendon of this muscle crosses the wrist in a compartment slightly superficial to and ulnarward of the compartment occupied by the tendons of *M. extensor digitorum*, *M. extensor digiti tertii proprius*, and *M. extensor indicis*. In some squirrels, including *Sciurus*, *Tamiasciurus*, *Glaucomys* (Bryant, 1945), and *Tamias*, the tendon of *M. extensor digiti minimi* passes through the same compartment as the other muscles.

Insertion in cricetids is on digits 4 and 5 (Rinker, 1954). In geomyids and heteromyids, as in *Jaculus*, insertion is on digit 5 alone (Howell, 1932; Hill, 1937).

M. extensor indicis, *M. extensor digiti tertii proprius*, and *M. extensor digiti minimi* probably represent the primitive deep extensors of digits 2 through 5. They occur as separate slips in many primates. In the rhesus monkey the deep extensors to digits 2 and 3 pass through the same compartment with the tendons of the superficial extensor, while the deep extensor of digits 4 and 5 passes through a separate compartment, as in dipodoids (Howell and Straus, 1933). Dipodoids and squirrels thus agree in retaining a full set of these deep extensors except that the extensor of digit 4 is lost in *Jaculus*. In muroids the extensor of digit 3 is lost, and in geomyoids the extensors of digits 3 and 4 are lost. Loss of the extensor to digit 4 probably occurred in *Jaculus* independent of loss in geomyoids.

M. extensor carpi ulnaris

ORIGIN.—From the lateral epicondyle and from 2 mm. of the lateral ridge of the ulna opposite the semilunar notch.

INSERTION.—On the base of metacarpal 5.

REMARKS.—The fibers of epicondylar origin are barely distinguishable from the fibers of *M. anconeus*; those of ulnar origin partly overlap the insertion of *M. anconeus*. The tendon passes toward the wrist through a special compartment over the ulna.

Flexor System

Pectoral Group

At insertion, the pectoral mass in dipodoids is separable into two layers. *M. pectoralis major*, which constitutes the superficial layer, inserts on the lateral crest. The deeper common tendon of the other pectorals and *M. cutaneus maximus* inserts on the base of the lateral crest, on the shaft of the humerus proximal to the crest and into fascia over the head and joint capsule.

Howell (1932) divided the pectoral muscles (excluding *M. cutaneus maximus* and *M. subclavius*) into four parts. His part *a* of the superficial pectoral corresponds to *M. pectoralis major*, his part *a'* of the same muscle to the posterior part of *M. pectoralis minor*, his part *b* of the deep pectoral to the anterior part of *M. pectoralis minor*, and his part *b'* of the deep pectoral to *M. pectoralis abdominalis* as here used.

M. subclavius

ORIGIN.—From the lateral third of the first costal cartilage.

INSERTION.—On the dorsocaudal surface of the middle third of the clavicle.

M. pectoralis major

ORIGIN.—From the midline of the manubrium sterni and from the sternebrae not including the xiphisternum.

INSERTION.—By a flat tendon on the distal half of the lateral crest of the humerus.

REMARKS.—This muscle is thinner than *M. pectoralis minor*, particularly in the posterior region of origin where its fibers are also somewhat fused with those of *M. pectoralis minor*.

M. pectoralis minor

ORIGIN.—From the sternebrae posterior to the manubrium and from the xiphisternum, partly deep to *M. pectoralis major*.

INSERTION.—By the common tendon of the deep pectoral layer.

REMARKS.—In most specimens, two parts of this muscle are recognizable, and in a few individuals a distinct hiatus is present between the parts. The anterior part originates from the sternebrae and contributes to the insertional tendon over the head of the humerus. The fibers of the posterior part originate from the xiphisternum and contribute to the common tendon in the area of insertion on the lateral crest. The common tendon in the region between humeral head and lateral crest is probably composed entirely of fibers from *M. pectoralis abdominalis* and *M. cutaneus maximus*.

M. pectoralis abdominalis

ORIGIN.—From the xiphisternal cartilage and from the abdomen lateral to the cartilage.

INSERTION.—By the common tendon of the deep layer.

REMARKS.—At origin this muscle is medial and anterior to the most ventral fibers of *M. cutaneus maximus*. Midway between origin and insertion it is partly overlapped by the ventral edge of *M. cutaneus maximus*. Anteriorly, however, *M. pectoralis abdominalis* crosses the edge of the other muscle, becomes superficial to it and inserts into the common tendon over the proximal part of the insertion of *M. cutaneus maximus*, deep to the insertion of the anterior part of *M. pectoralis profundus*.

M. cutaneus maximus (*M. panniculus carnosus* Howell, 1932)

Dorsal fibers take origin from the skin of the dorsum, from a point at the level of the scapular spine on backward over the vertebral column. Over the thorax, the fibers of one side (usually the right) may overlap those of the other side. The anterior border

of the muscle is distinct dorsally; no interlacing with the nuchal platysma occurs. In the caudal region a heavy band emerges onto the rump from each side of the dorsum of the tail. More ventral fibers run anteriorly from the lateral surface of the thigh, from the inguinal region, and from the ventral midline as far forward as the origin of *M. pectoralis abdominalis*. Over the other pectoral muscles, *M. cutaneus maximus* is represented by fascia, if present at all. Converging toward the axilla, the fibers overlap part of *M. pectoralis abdominalis* and then pass deep to that muscle to insert as the deepest layer of the common pectoral tendon on the humerus. The insertion seems to be reflected upon itself at insertion. The most ventral fibers insert proximally, deep to the caudal edge of the anterior part of *M. pectoralis profundus* and deep to *M. pectoralis abdominalis*. The lateral fibers insert more distally, mainly into the lateral crest deep to the insertion of the posterior part of *M. pectoralis profundus*. The dorsal fibers insert more proximally into the fascia of the shaft and head of the humerus, deep to the insertion of the ventral fibers.

In dipodoids, *M. cutaneus maximus* is not separable into distinct dorsal, thoraco-abdominal, femoral, and pudendal parts as it is in some caviomorphs (Langworthy, 1925; Meinertz, 1932; Enders, 1934), though a few scattered inguinal fibers in *Zapus* may represent an incipient pars pudenda. In heteromyids and geomyids *M. cutaneus maximus* is separable into dorsal (humeral) and ventral parts (Howell, 1932; Hill, 1937). The dipodoid muscle resembles most closely that described in muroids (Howell, 1926; Langworthy, 1925; Meinertz, 1941a; Rinker, 1954) in that the entire undifferentiated muscle passes into the axilla to insert on the humerus, barring the exception of the slip to the lateral side of the humerus in *Dicrostonyx*. The caudal part seems to be better developed in dipodoids than in muroids, however.

Flexor Group of the Arm (Fig. 11)

M. coracobrachialis

ORIGIN.—By tendon from the tip of the coracoid process.

INSERTION.—On the crest of the lesser tuberosity of the humerus and on the medial surface of the humerus above the medial epicondylar ridge.

REMARKS.—The tendon of origin arches down over the inserting tendon of *M. subscapularis*. The fibers of the short, or profundus, part develop on the deep surface of the tendon of origin and pass anteroventrad over the common tendon of *M. latissimus dorsi* and *M. teres major* to insert on a pronounced ridge below the lesser tuberosity just anterior to the insertion of the common tendon. Below the short part the tendon of origin narrows, and the distal part of the muscle develops as a slender direct continuation of the tendon. The distal part inserts on a small area, 1.5 mm. long in *Zapus*, above the medial epicondylar ridge and separated by a long hiatus from the insertion of the short part. Distal and short parts are separated by the path of the musculocutaneous nerve.

The short part is present in sciurids, *Aplodontia*, geomyids, and heteromyids (Howell, 1932; Hill, 1937; Bryant, 1945), and, among muroids, only in *Cricetus*, *Cricetomys* (Parsons, 1896), *Neotoma*, and *Peromyscus* (Rinker, 1954).

Homology in dipodoids of the distal part with either the medius or longus parts discussed by J. Wood (1867) and Parsons (1894, 1896) is dubious. I have, therefore, used the noncommittal term "distal" for the part superficial to the musculocutaneous nerve.

In cricetids the insertion of the distal part is far more extensive along the humerus than in dipodoids (cf. Rinker, 1954).

In *Sicista* the tendon of origin also gives rise to the short head of *M. biceps brachii*.

M. biceps brachii

ORIGIN.—From the base of the coracoid process (long head only).

INSERTION.—On the brachial ridge of the ulna and possibly on the tuberosity of the radius.

REMARKS.—In *Zapus* the tendon of the long head runs through the joint capsule and bicipital groove of the humerus. The short head is absent in *Zapus*, *Jaculus*, and (fide Howell, 1932) *Allactaga*. It is present in *Sicista*, taking origin from the anteromedial surface of the tendon of *M. coracobrachialis* and fusing with the long head close to the insertion.

Absence of the short head has been reported in one subgenus of *Citellus* (Bryant, 1945), and in *Hystrix*, *Dasyproctidae*, *Caviidae*, and *Castor* (Parsons, 1894). To my knowledge, the short head is invariably present in muroids and geomyoids (Howell, 1932; Hill, 1937; Rinker, 1954). Because the short head is present in *Sicista*, the least modified living dipodoid, I suspect that the loss of the short head in other dipodoids was independent of the comparable loss in other groups.

Insertion of the tendon of *M. biceps brachii* on the radius, if present, is very small. No separate tendon to the radius is developed.

M. brachialis

ORIGIN.—From the posterolateral surface of the proximal third of the humeral shaft and from the anteromedial side of the deltoid crest and the region of the humeral shaft at the base of the deltoid crest.

INSERTION.—On the brachial crest of the ulna, proximal to the insertion of *M. biceps brachii*.

REMARKS.—The two heads of this muscle are separate almost to insertion. The lateral head is partly covered by caput lateralis of *M. triceps brachii* and is about twice the bulk of the medial head.

The brachial muscles in *Jaculus* are very short and thick, as the arm is relatively very short in that genus.

Flexor Group of the Forearm (Fig. 11)

M. epitrochleoanconeus

ORIGIN.—From the posterior surface of the medial epicondyle.

INSERTION.—On the medial surface of the olecranon.

REMARKS.—This small muscle is distinct from the triceps mass. It overlies the ulnar nerve and receives a branch from that nerve on its underside. No trace of radial innervation was seen in any specimen.

M. flexor carpi ulnaris

ORIGIN.—From the medial surface of the olecranon.

INSERTION.—On the pisiform bone.

REMARKS.—This muscle is fascially bound to the medial epicondyle, but no true epicondylar origin is present.

M. palmaris longus

ORIGIN.—From the most distal part of the medial epicondyle, distal to the origin of the superficial head of *M. flexor digitorum profundus* and superficial to the origin of *M. flexor digitorum superficialis*.

INSERTION.—Into the palmar fascia on the ulnar side of the hand.

REMARKS.—The size of the belly of this muscle is individually variable.

M. flexor carpi radialis

ORIGIN.—From the medial epicondyle distal to the origin of *M. pronator teres* and proximal to the origin of the superficial head of *M. flexor digitorum profundus*.

INSERTION.—On the base of the second metacarpal.

REMARKS.—As the tendon runs distad, it becomes fascially bound to the surface of the radius over the distal third of the bone.

M. pronator teres

ORIGIN.—From the medial epicondyle.

INSERTION.—On the middle third of the radius.

M. flexor digitorum superficialis (*M. flexor digitorum sublimis* Howell, 1932)

ORIGIN.—From the medial epicondyle deep to the origins of *M. palmaris longus* and the epicondylar head of *M. flexor digitorum profundus*.

INSERTION.—On the second phalanges of digits 2, 3 and 4.

REMARKS.—The origin is hidden to a variable extent, and the belly becomes visible partway down the forearm. In *Jaculus* the belly is usually more visible. The insertional tendons are perforated by the tendons of *M. flexor digitorum profundus* to those digits.

M. flexor digitorum profundus

ORIGIN.—By four heads: (1) from the medial epicondyle between the origins of *M. palmaris longus* and *M. flexor carpi radialis*, superficial to the origin of *M. flexor digitorum superficialis*; (2) by tendon from the side of the trochlea of the humerus; (3) from the middle third of the ulna and the adjacent interosseous membrane; (4) from the middle third of the radius and adjacent interosseous membrane.

INSERTION.—On the distal phalanges of digits 1 through 5, penetrating the tendons of *M. flexor digitorum superficialis* to digits 2 through 4.

REMARKS.—In *Sicista* the radial and ulnar heads are separate, and their tendons unite only at the wrist. In *Zapus* and *Jaculus* the radial and ulnar heads give rise to a single tendon. Howell (1932) reported that the radial head is absent in *Allactaga*.

In *Zapus* the tendon formed by the trochlear head attaches to the superficial surface of the radio-ulnar tendon, and the tendon of the epicondylar head attaches to the superficial surface of the trochlear tendon at the same point. In *Sicista* the tendons of epicondylar and trochlear heads join the radio-ulnar tendon on its radial, rather than superficial, surface. In *Jaculus* the epicondylar and trochlear heads are small and slender and separable from one another with difficulty. They form no separate tendons, but insert directly on an aponeurosis on the superficial surface of the radio-ulnar head.

Howell (1932) and Hill (1937) reported ulnar innervation of the ulnar head in the rodents they dissected. Rinker (1954) found only median innervation of this head in muroids. In dipodoids the ulnar nerve runs on the surface of the ulnar head for most

of the length of the forearm, but I detected no branches entering the muscle. Instead, the ulnar head, like the other heads, seems to be innervated solely by the median nerve.

M. pronator quadratus

I did not find this muscle in any dipodoid.

MUSCLES OF THE PELVIC GIRDLE AND LIMB

Extensor System

Iliacus Group (Fig. 14)

M. iliacus

ORIGIN.—From the ventral part of the iliac fossa.

INSERTION.—On the lesser trochanter of the femur, just distal to the insertion of *M. psoas major*.

M. psoas major

ORIGIN.—From the bodies and transverse processes of the last five lumbar vertebrae.

INSERTION.—On the proximal part of the lesser trochanter of the femur.

REMARKS.—The insertions of this muscle and *M. iliacus* are distinguishable, but the bellies are in close contact and occasionally difficult to separate.

M. pectineus

ORIGIN.—From the ventral border of the pubis ventral to the acetabulum.

INSERTION.—On the caudomedial surface of the proximal third of the shaft of the femur, between the lesser trochanter and the level of the distal limit of the lateral crest.

REMARKS.—In *Sicista* the insertion is on the proximal half of the femoral shaft, and in *Jaculus* on the proximal quarter. In all four genera the insertion is flat, the line of insertion lying medial to the insertion of the femoral part of *M. adductor brevis*. In all four genera this muscle is innervated by the femoral nerve; no obturator innervation was found.

Gluteal Group (Figs. 12, 13, 14)

The postural difference between rodents and man has caused some difficulty in homologizing rodent gluteal muscles with their human counterparts. Hill (1937) and Rinker (1954) used as criteria for identification of these muscles the paths of the superior and inferior gluteal nerves. I have used these criteria also, and my identification of muscles is rather different from that which Howell (1932) provided for jerboas. Howell's *M. gluteus superficialis* corresponds to my *M. gluteus maximus* plus *M. tensor fasciae latae*. My *M. gluteus medius* includes his *M. gluteus maximus*, *M. gluteus medius*, *M. gemellus superior*, and part of his *M. gluteus minimus*. My *M. gluteus minimus* corresponds to only part of his muscle of that name.

As Rinker (1954) noted, the gluteal mass in rodents is roughly separable into two layers. The superficial layer includes *M. tensor fasciae latae*, *M. gluteus maximus*, *M. femorococcygeus* and *M. tenuissimus*. The deeper layer is composed of *M. pyriformis*, *M. gluteus medius*, and *M. gluteus minimus*.

M. tensor fasciae latae

ORIGIN.—From the lumbodorsal fascia over the last lumbar and first sacral vertebrae, from the iliac spine and from the anterior quarter of the ventral iliac border.

INSERTION.—Into the fascia of the lateral and anterior surfaces of the quadriceps femoris.

REMARKS.—The medial part of this sheet is absent in *Sicista* and *Zapus*. In *Jaculus* the fibers from the iliac border run distad on the medial surface of the thigh, becoming fascial partway to the knee, and forming a medial sheet like that found in some other rodents. In *Zapus* the fibers from the iliac border twist as they run laterad and insert, together with dorsal fibers, on the fascial layers over the quadriceps femoris. In *Sicista* no origin from the ventral iliac border is present, and no fibers insert on the fasciae latae. Instead, they run caudad to insert on the anterior surface of the lateral crest of the femur. In *Jaculus* the lateral part of the muscle is poorly developed by comparison with *Zapus*.

M. gluteus maximus

ORIGIN.—From the lumbodorsal fascia over the first and second sacral vertebrae and fleshily from the dorsal midline between the spines of the second to fourth sacral vertebrae.

INSERTION.—Into the anterior surface and proximal end of the lateral crest of the femur.

REMARKS.—In dipodoids as in many other rodents, the anterior border of this muscle is continuous with the posterior border of *M. tensor fasciae latae*, and the two muscles appear as one. They are separable, however, on the basis both of point of insertion of fibers and by differences in innervation; *M. gluteus maximus* is served by the inferior gluteal nerve and *M. tensor fasciae latae* by the superior gluteal. In *Sicista*, where the fibers of both muscles insert on the lateral crest, the muscles must be distinguished on the basis of innervation alone. In *Jaculus*, *M. gluteus maximus* is represented by a few fibers inserting fascially on the aponeurosis formed on the posterior surface of *M. rectus femoris*. Direct insertion on the femur could not be demonstrated. The lateral crest of the femur is absent in *Jaculus* and in most other jerboas except *Salpingotus* (Vinogradov, 1937). It is present in *Sicista* and *Zapus*. The reduction of *M. gluteus maximus* and *M. tensor fasciae latae* seen in *Jaculus* is not paralleled in *Dipodomys* (Howell, 1932).

Posteriorly, the fleshy origin of *M. gluteus maximus* in *Sicista* and *Zapus* is difficult to distinguish from the origin of *M. femorococcygeus*. In *Jaculus* the posterior part of the origin of *M. gluteus maximus* is fascial and easily distinguished from *M. femorococcygeus*.

M. femorococcygeus (*M. biceps femoris anticus* Howell, 1932)

ORIGIN.—Fascially from the spine of the fourth sacral and first caudal vertebrae.

INSERTION.—On the lateral surface of the patella.

REMARKS.—In *Sicista* origin is similar to that in *Zapus*. In both, the origin is completely covered by the caudal head of *M. semitendinosus*, and is difficult to distinguish from the posterior part of the origin of *M. gluteus maximus*. Both *M. gluteus maximus* and *M. femorococcygeus* are innervated by the inferior gluteal nerve. In *Jaculus* the origin of *M. femorococcygeus* is distinct and extensive; from the deep lumbosacral fascia at the level of the last sacral and first caudal vertebrae, from the strong sacrotuberous ligament between the spine of the last sacral vertebra and the dorsal spine of the ischium, and from the dorsal ischial spine itself. The origin is crossed by the origin of the caudal head of *M. semitendinosus*, but it is not completely covered by that muscle. The sacrotuberous ligament is not developed in *Sicista* and *Zapus*.

Insertion in *Sicista* is on the posterolateral surface of the distal half of the femur and fascially on the lateral surface of the patella. Insertion on the femoral shaft, probably a primitive trait, is not seen in *Zapus*. In *Jaculus* insertion is on a heavy aponeurosis developed on the posterior surface of *M. rectus femoris* and on the patella. Howell (1932) distinguished three parts of this muscle in jerboas, but I was unable to do so.

This muscle is separated from *M. biceps femoris* by the path of the posterior femoral cutaneous nerve. This manner of separation holds true also in muroids and geomyoids. In *Aplodontia* and squirrels, however, the nerve penetrates *M. biceps femoris* (Hill, 1937). Distally *M. femorococcygeus* lies lateral to the tibial and common peroneal nerves. Rinker (1954) noted that the names "*M. caudofemoralis*" and "*M. biceps anticus*" have been applied to this muscle by some authors. Howell (1938) and Fry (1961) called it "*M. gluteus longus*."

M. tenuissimus

This muscle is present only in *Sicista*. It originates fascially over the first caudal vertebra posterior to the origin of *M. gluteus maximus*. It runs distad superficial to the posterior femoral cutaneous nerve and *M. caudofemoralis*. It lies, near origin, on the underside of *M. femorococcygeus* and then crosses to the underside of *M. biceps femoris* to insert on the fascia of the lateral surface of the shank musculature just under the distal edge of the insertion of *M. biceps femoris*. In *Sicista* it is a slender muscle, its width being less than a quarter of a millimeter. Its relationships to nerves and other muscles apparently are similar to those described in geomyoids and muroids by Hill (1937) and Rinker (1954). Innervation in other mammals is usually by a branch of the common peroneal nerve, but innervation could not be determined in *Sicista*. Fry (1961) grouped this muscle with the hamstrings, but the innervation indicates that it belongs with the extensors rather than with the flexors of the thigh.

M. tenuissimus has a rather scattered distribution among rodents. Howell (1932) found it in *Dipodomys*, and I have verified its presence there. Hill (1937) found it to be present, but rarely, in *Thomomys* and absent in *Geomys*. Rinker (1954) saw it in *Neotoma* and *Peromyscus* but not in *Sigmodon* and *Oryzomys*. Since the muscle is present in the most generalized living dipodoid and absent in the remainder, and since distribution within other families is sporadic, I suspect that loss of the muscle in dipodoids has occurred independently of loss in other groups.

M. gluteus medius

ORIGIN.—From the deep lumbosacral fascia from a point between the spines of the sixth and seventh lumbar vertebrae back to the level of the third sacral vertebra, from the spine and dorsal ridge of the ilium, from the dorsal part of the gluteal fossa, and from the anteroventral part of the iliac fossa.

INSERTION.—On the posterior surface of the femoral shaft proximal to the lateral crest, and on the greater trochanter.

REMARKS.—Rinker (1954) separated three poorly differentiated parts in his cricetids. In dipodoids I find two strongly differentiated parts. The superficial part takes origin from the deep lumbosacral fascia and from the spine and dorsal ridge of the ilium. It inserts on the posterior surface of the femur (below the greater trochanter) and on the posterior and posterolateral surfaces of the greater trochanter. The fibers inserting on the shaft originate from the lumbosacral fascia between the first and third sacral vertebrae and overlie anteriorly the remainder of the superficial part, which inserts on the greater trochanter. The dipodoid superficial part thus corresponds to Rinker's "dorsolateral part" and "second superficial part."

In dipodoids the deep part of the muscle takes origin from the gluteal crest and fossa and inserts with the tendon of *M. gluteus minimus* on the anteromedial surface of the greater trochanter. In cricetids this deep part is clearly associated with the superficial parts of *M. gluteus medius*; in dipodoids it fuses with *M. gluteus minimus*. In both cricetids and dipodoids, however, the muscle's origins are similar and its deep part is separated from *M. gluteus minimus* by the passage of the superior gluteal nerve, which emerges at the lateral border of the deep part and enters the underside of *M. tensor fasciae latae*.

Posteriorly, the deep part of *M. gluteus medius* is contiguous with *M. pyriformis*. These muscles are separable on the bases of point of origin of their fibers, a slight difference in fiber direction, and the passage of an ascending branch of the superior gluteal nerve between them.

Parsons (1894, 1896) and Howell (1926, 1932) both ignored the path of the superior gluteal nerve, and their divisions of the deep gluteal mass into *M. gluteus medius* and *M. gluteus minimus* are not to be trusted. In most cases Parsons considered the deep *M. gluteus medius* to be a part of *M. gluteus minimus*; this mistake accounts for his statements that *M. pyriformis* and *M. gluteus minimus* are closely related in some rodents. Howell evidently viewed the deep part of *M. gluteus medius* as a part of *M. gluteus medius* in *Neotoma* and a part of *M. gluteus minimus* in *Dipodomys*, *Allactaga*, and *Jaculus*. Howell's "M. gemellus superior" originates from the dorsal iliac border and is closely related to *M. pyriformis* in all four of the above genera. His muscle is probably part of the deep *M. gluteus medius* rather than of *M. gluteus minimus* as inferred by Rinker (1954). Alezais (1900) separated his "petit fessier" into anterior (iliac) and posterior (sciatic) parts; he further distinguished a "scansorius" in all the rodents he dissected. I agree with Rinker that the anterior part belongs with *M. gluteus medius*, and that the posterior part and scansorius together constitute *M. gluteus minimus*. Alezais noted that in rodents the "petit fessier" and "scansorius" may be united or separate. He found them united in *Jaculus* and *Marmota* and separate in *Cavia*, *Sciurus*, *Mus*, and *Rattus*. The observation corresponds well with my observations of dipodoids, since the deep part of *M. gluteus medius* and *M. gluteus minimus* are fused in that superfamily. Alezais' statements that *M. pyriformis* (his "pyramidal") is related to the "petit fessier" can be interpreted as a relationship of *M. pyriformis* with the deep *M. gluteus medius* rather than with *M. gluteus minimus*.

In some mammals, including ungulates, the superficial part of *M. gluteus medius* originates from the lumbodorsal fascia well forward of the ilium. Slijper (1946) described this "gluteal tongue" in *Cuniculus paca*, and Alezais (1900) figured it (his "faisceau posterieur du moyen fessier") in *Cavia*. Rinker (1954) found that in *Sigmodon* the superficial part of *M. gluteus medius* originates as far forward as the interval between the spines of the fourth and fifth lumbar vertebrae, and that this extension is not well

developed in the other three genera he dissected. In *Zapus* the "gluteal tongue" is apparently even more poorly developed, since the muscle originates only as far forward as the interval between the sixth and seventh lumbar spines. In *Jaculus* the "gluteal tongue" is not developed at all, since no fibers originate anterior to the iliac spine.

M. gluteus minimus

ORIGIN.—From the posterior part of the gluteal fossa, from the lateral crest, and from the upper part of the iliac fossa of the ilium.

INSERTION.—On the anteromedial and medial surfaces of the greater trochanter.

REMARKS.—This muscle is fused with the deep part of *M. gluteus medius* in dipodoids; the two elements insert by a common tendon.

A small slip of fibers originates from the inferior border of the ilium about half-way between the acetabulum and the iliac spine and runs posterolaterad to insert on the lateral side of the tendon of the fibers arising from the iliac fossa. Rinker (1954) found this bundle to be better developed in *Neotoma* and *Peromyscus* than in *Sigmodon* and *Oryzomys*. It is well developed in all dipodoids I dissected.

No true *M. scansorius* could be detected, though Parsons (1894) and Howell (1932) reported that muscle in *Jaculus*.

M. pyriformis

ORIGIN.—From the ends and ventral surfaces of the transverse processes of the second through fourth sacral vertebrae.

INSERTION.—On the medial surface of the greater trochanter in common with the posterior fibers of the deep *M. gluteus medius*.

REMARKS.—This muscle is closely related to the deep *M. gluteus medius* (cf. remarks regarding that muscle).

Quadriceps Femoris Group (Figs. 12, 13, 14)

The muscles of this group are innervated by the femoral nerve. A true *M. sartorius*, innervated by the femoral nerve, is absent in dipodoids as in many other rodents.

M. rectus femoris

ORIGIN.—From the femoral tubercle of the ilium (straight head) and from the dorsal margin of the acetabulum (reflected head).

INSERTION.—On the cranial surface of the patella.

REMARKS.—In *Sicista* and *Zapus* the reflected head is a round tendon curving around the anterior border of the acetabulum and lying along the main axis of the muscle. The straight head is a flat band of connective tissue that joins the reflected head at an angle of about 80° at the point where the muscular fibers of the reflected head begin. In *Jaculus* the reflected head is absent.

M. vastus lateralis

ORIGIN.—From the anterior surface of the greater trochanter and from the anterior surface of the lateral ridge of the femur proximal to the level of the insertion of *M. adductor magnus*.

INSERTION.—On the lateral surface of the patella.

REMARKS.—In *Zapus* this large muscle encloses *M. rectus femoris* laterally and medially and is distinct from *M. vastus intermedius*. In *Sicista* the anterior edge of *M. vastus lateralis* does not cover the anterior part of *M. rectus femoris*, and *M. vastus lateralis* and *M. vastus intermedius* are inseparably fused.

M. vastus medialis

ORIGIN.—From the anteromedial surface of the proximal third of the femoral shaft.

INSERTION.—On the medial surface of the patella.

M. vastus intermedius (*M. vastus femoris* Howell, 1932)

ORIGIN.—From the distal three-quarters of the anterior surface and from the distal half of the lateral and medial surfaces of the femoral shaft.

INSERTION.—On the anterior surface of the patella, the medial insertion being partly deep to the insertion of *M. vastus medialis*.

REMARKS.—In *Sicista* and *Zapus*, *M. vastus intermedius* is separable from *M. vastus medialis* only on the basis of a slight difference at insertion.

No *M. articularis* genu is differentiated in any of the dipodoids dissected.

Tibial Extensor Group (Fig. 15)

M. extensor digitorum longus

ORIGIN.—From the lateral femoral epicondyle anterior to the fibular collateral ligament.

INSERTION.—On the dorsal surfaces of digits 2 through 4.

REMARKS.—The origin of this muscle in *Sicista* and *Zapus* is entirely from the femoral tendon. Above the transverse crural retinaculum the tendon of insertion splits into three parts. These pass through the retinaculum and through the ligamentous trochlea on the dorsal surface of the calcaneus and diverge toward their insertions. Part of the belly of this muscle is hidden by the fibular fibers and fascia of *M. tibialis anterior*. In *Sicista* some of the fibers originate from the heads of fibula and tibia. Insertion is onto digits 2 through 5 instead of 2 through 4.

In *Jaculus* the femoral tendon of origin passes through a fibro-osseous foramen formed by the tibia, fibula, fibular collateral ligament, and the external ligament connecting the heads of tibia and fibula (cf. remarks under *M. tibialis anterior*). *M. extensor digitorum longus* in *Jaculus* is also differentiated into three parts. The first of these, *M. extensor digitorum longus proprius* of Howell (1932), takes origin from the caudal surface of the femoral tendon. The tendon of insertion splits just proximal to the metatarsal-phalangeal joint and inserts on digits 2 and 4. The second part, *M. extensor digiti tertii longus* of Howell, takes origin from the anterior face of the femoral tendon. The tendon of insertion of this second part lies at first superficial to the tendon of the first part, then distal to the crural retinaculum its tendon passes to the medial side and then deep to the tendon of the first part where it is entirely hidden over the distal part of the metatarsal bone. It emerges to view only where the tendon of the first part splits to insert on digits 2 and 4. The tendon of the second part inserts on digit 3. The third part, *M. extensor digiti secundi longus* of Howell (1932), takes origin from the tibia, fibula, and ligament between them, deep to the origin of *M. tibialis anterior*. Its tendon

lies superficial to the tendon of the second part under the crural retinaculum and diverges medially to insert on the medial side of the distal phalanx of the second digit. The tendons of all three parts pass through the trochlear ring. Howell (1932) found that the muscle is similar in *Allactaga*, except that the first part inserts on digits 2 through 4, and a small, separate extensor of the fifth digit is also present.

M. extensor hallucis longus

ORIGIN.—From the septum between the tibial extensor and the peroneal muscles, and from the interosseous membrane at the level of the middle third of the free part of the fibula.

INSERTION.—On the dorsum of the terminal phalanx of the hallux.

REMARKS.—The slender insertional tendon of this muscle is closely bound to the tendon of *M. tibialis anterior*, diverging from it above its insertion. The muscle is absent in *Jaculus*, where the hallux is absent. Howell (1932) found it present but very small in *Allactaga*, and in *Dipodomys spectabilis*, where the hallux is absent, insertion is transferred to the second digit.

M. tibialis anterior

ORIGIN.—From the proximal fifth of the lateral fossa of the tibia, from the lateral and anterior edges of the tibial epiphysis, from a small area on the medial surface of the tibia anterior to the insertion of *M. popliteus*, and fascially from the head of the fibula.

INSERTION.—On the ventrolateral surface of the medial cuneiform bone, with a few fibers of the tendon spreading forward onto the first metatarsal.

REMARKS.—In *Sicista* the origin does not include the head of the fibula or the medial surface of the tibia, and the insertion is confined to the medial cuneiform bone. In *Jaculus* the origin is likewise confined to the lateral side of the shank, but the fibular origin is much stronger than in *Zapus*. In *Jaculus* a strong ligament connects the heads of tibia and fibula externally. Fibers of *M. tibialis anterior* originate from the ligament as well as from both bones. The ligament probably represents a thickening of the fascial fibular origin of *M. tibialis anterior* seen in *Zapus*. In *Jaculus* the insertion is confined to the medial cuneiform bone; no fibers spread onto the metatarsal bone.

In all forms the tendon of this muscle passes under the transverse crural retinaculum, lying medial to the tendon of *M. extensor digitorum longus*, and closely associated with the tendon of *M. extensor hallucis longus*. The transverse crural retinaculum is partly ossified in *Zapus* and *Jaculus*. Extent of ossification seems to be individually variable.

Mm. extensores breves

In *Sicista* as in some cricetids two muscles are present. They originate by tendon from the dorsum of the calcaneus at the posterior end of the base of the trochlear process (not to be confused with the ligamentous trochlear ring penetrated by the tendons of *M. extensor digitorum longus*). They insert by long, thin tendons on digits 2 and 3. The belly of the medial muscle is mostly covered by that of the lateral one. Only one muscle, inserting on digit 3, is present in *Zapus*, and the entire muscle is absent in *Jaculus*.

Peroneal Group (Fig. 15)

M. peroneus longus

ORIGIN.—From the peroneal process of the fibula, from the septum between itself and *M. extensor digitorum longus*, and fascially from the surface of the other peroneal muscles medial to the common peroneal nerve.

INSERTION.—On a lateral process at the base of the first metatarsal.

REMARKS.—The tendon passes distad and curves around the lateral malleolus in a compartment lateral to and separate from the compartment occupied by the other peroneal tendons. The insertional tendon crosses the trochlear process of the calcaneus in a groove and passes deeply in front of the calcaneus and cuboid toward its insertion on the medial side of the foot. In *Jaculus* the tendon inserts on a large medial process on the fused metatarsals; this process probably represents the base of the first metatarsal.

In *Sicista* this muscle is fleshy for one-half the distance from the peroneal process to the malleolus, in *Jaculus* the fleshy part composes only the proximal one-third, and in *Zapus* an intermediate condition obtains.

The fascial origin medial to the common peroneal nerve which is found in *Zapus* is not seen in *Sicista* and *Jaculus*.

M. peroneus brevis

ORIGIN.—From the posterolateral surface of the free part of the fibula and from the interosseous membrane.

INSERTION.—On the base of the fifth metatarsal.

REMARKS.—This is the deepest of the peronei. Its tendon passes distad and emerges between the tendons of *M. peroneus digiti quarti* and *M. peroneus digiti minimi*. With the tendons of those muscles it passes behind the lateral malleolus and over the trochlear process of the calcaneus. The muscle is absent in *Allactaga* and *Jaculus* (Howell, 1932); I have confirmed its absence in *Jaculus*.

M. peroneus digiti quarti

ORIGIN.—From the middle third of the free part of the fibula.

INSERTION.—On the dorsum of the fourth digit.

M. peroneus digiti minimi (*M. peroneus digiti quinti* Howell, 1932)

ORIGIN.—From the proximal third of the free part of the fibula, and from the fibular head.

INSERTION.—On the dorsum of the fifth digit.

REMARKS.—This muscle is absent in *Allactaga* and *Jaculus* (Howell, 1932).

Flexor System

Adductor Group (Figs. 13, 14)

The adductor muscles of rodents have been misinterpreted by many anatomists. Hill (1937) provided the first satisfactory identification of these muscles in rodents by using their origins and their relationships to the

branches of the obturator nerve as guides for establishing homologies. The branch of the obturator nerve to *M. gracilis* emerges between *M. adductor longus* and *M. adductor brevis*, and the branch to *M. adductor magnus* passes between that muscle and *M. adductor brevis*. The insertions in rodents depart widely from the human condition, however. Rinker (1954) followed Hill's concept of the identities of these muscles in muroids, and I agree with their interpretation. I disagree, however, with Hill's identification of *M. gracilis* in certain other rodents. My interpretation of these muscles also differs from those of Howell (1926, 1932), which are not consistent. A table setting forth my interpretation of the synonymies of the names applied to the adductor muscles in rodents by Howell, Hill, and Rinker is appended.

I also disagree with Greene's (1935) interpretation of the adductor muscles in *Rattus*, but I have not included her system in the table. Her "M. adductor magnus" corresponds to my *M. adductor brevis pars genicularis*, and her "M. adductor brevis" includes both my *M. adductor magnus* and *M. adductor brevis pars femoralis*. Unfortunately, some of her illustrations (Greene, 1935, figs. 96, 97) are inconsistent with her own descriptions, since she labeled *M. quadratus femoris* as "obturator externus" and *M. adductor magnus* as "quadratus femoris." In the same figure, her "obturator internus" includes the tendon of that muscle and the bellies of the gemelli.

M. gracilis (*M. gracilis posterior* Howell, 1932)

ORIGIN.—From the inferior tuberosity and most ventral part of the inferior ramus of the ischium.

INSERTION.—Into the fascia of the medial surface of the shank immediately proximal to the insertion of *M. semitendinosus*.

REMARKS.—In *Sicista* and *Zapus* origin of this muscle is superficial to parts of the origins of *M. adductor magnus* and *M. adductor brevis*, and caudal to the origin of *M. adductor longus*. It agrees in position with *M. gracilis posterior* of muroids (Rinker, 1954). In *Sicista* and *Zapus*, *M. gracilis* lies at insertion between the insertions of *M. semitendinosus* and *M. semimembranosus*, but is separated from the latter by a distinct hiatus. In *Jaculus*, *M. gracilis* is a much broader muscle, and its origin has apparently extended forward, being partly covered anteriorly by the origin of *M. adductor longus*. Posteriorly, part of the origin of *M. adductor magnus* is exposed. In *Allactaga*, according to Howell (1932, fig. 14), the origin of *M. gracilis* is completely covered by the origin of *M. adductor longus*. The relationships at insertion in *Jaculus* are similar to those in *Sicista* and *Zapus* except that *M. gracilis* overlies part of the insertion of *M. semimembranosus*. In jerboas, *M. gracilis* bears a closer resemblance to the anterior, rather than posterior, part in muroids, but I think the distinction unnecessary unless both elements are present in the same animal.

M. gracilis is single in dipodoids and geomyoids; the muscle termed "M. gracilis anterior" by Howell (1932) is part of *M. adductor brevis* in jerboas and *Dipodomys*. In

TABLE I
SUGGESTED SYNONYMY OF TERMS APPLIED TO THE ADDUCTOR MUSCLES OF RODENTS

Howell, 1926 <i>Neotoma</i>	Howell, 1932 <i>Dipodomys</i>	Hill, 1937 <i>Thomomys</i>	Rinker, 1954 <i>Sigmodon</i>	This paper <i>Zapus</i>
M. gracilis post. M. gracilis ant. }	M. gracilis post.	M. gracilis post.	{ M. gracilis post. M. gracilis ant. }	M. gracilis
M. add. magnus (part)	M. gracilis ant.	M. gracilis ant.	M. add. brevis (part)	M. add. brevis, genicular part
M. add. magnus (part)	M. add. longus primus	M. add. brevis	M. add. brevis (part)	M. add. brevis, femoral part
M. add. brevis	{ M. add. brevis M. add. magnus }	M. add. minimus M. add. magnus }	M. add. magnus	M. add. magnus
M. add. longus	M. add. longus accessorius	M. add. longus	M. add. longus	M. add. longus
M. obt. extern.	M. obt. extern.	M. obt. extern.	M. obt. extern.	M. obt. extern.

geomyids, Hill (1937) found an "anterior gracilis" in a few specimens of *Thomomys* and in none of *Geomys*. His identification of this muscle is incorrect, however (cf. remarks under *M. adductor brevis*).

M. adductor longus

ORIGIN.—From the ventral border of the pubis between the origin of *M. pectineus* and the anterior edge of the pubic symphysis.

INSERTION.—By a narrow, flat tendon on the medial surface of the femur about midway between head and condyles.

REMARKS.—The origin of this muscle overlies part of the origin of *M. gracilis* in *Jaculus* but not in *Sicista* and *Zapus*. In *Jaculus* insertion is more proximal, being between the proximal and middle thirds of the femur. The nerve to *M. gracilis* emerges between this muscle and *M. adductor brevis*.

M. adductor brevis

ORIGIN.—From the lateral surface of the pubis dorsal (deep) to the origin of *M. adductor longus* and ventral (superficial) to part of the origin of *M. adductor brevis*.

INSERTION.—On the posteromedial part of the femur, between the level of the distal end of the lateral crest and the medial epicondyle, and into the capsule of the knee joint.

REMARKS.—Two distinct parts of this muscle are present in dipodoids. The superficial part, here termed the genicular part (distal part of Fry, 1961), inserts on the medial surface of the knee; the deep part, here termed the femoral part (proximal part of Fry, 1961), inserts on the femoral shaft. The popliteal vessels run between the two parts, and the genicular part encloses the inserting end of *M. caudofemoralis*. Both parts are also present in *Dipodomys*, *Aplodontia*, *Rattus*, *Sigmodon*, *Oryzomys*, *Peromyscus*, and *Neotoma* (Hill, 1937; Rinker, 1954; Fry, 1961). The genicular part is absent in squirrels and usually in geomyids (Hill, 1937).

Howell (1932) termed the genicular part "*M. gracilis anterior*." I attribute the genicular part to *M. adductor brevis* rather than to *M. gracilis* because of the relationships of this muscle to the nerve to the gracilis in muroids, where a true anterior gracilis is present. In *Peromyscus* the nerve to *M. gracilis posterior* emerges onto the medial surface of the thigh between *M. adductor longus* and *M. adductor brevis*. It runs caudad superficial (medial) to the genicular part of *M. adductor brevis* and deep (lateral) to *M. gracilis anterior*. At the anterior edge of *M. gracilis posterior*, it breaks up into a number of branches to that muscle. In dipodoids and *Dipodomys* this nerve emerges between *Mm. adductores longus* and *brevis*, runs caudad superficial to the genicular *M. adductor brevis* (Howell's "*gracilis anterior*") and splits into a number of branches which enter *M. gracilis* at its anterior border. Since this nerve runs superficial rather than deep to Howell's "*gracilis anterior*," I think that Howell's muscle cannot be homologous to the cricetid muscle of the same name. In addition, the cricetid *M. gracilis anterior* inserts on the shank superficial to the insertion of *M. gracilis posterior*, between the insertions of *M. semimembranosus* and *M. semitendinosus*. Howell's "*gracilis anterior*" inserts in the same position as the cricetid genicular part of *M. adductor brevis*, that is, between the insertions of *M. semimembranosus* and *M. vastus medialis*. It appears, therefore, that *M. gracilis* is divided into anterior and posterior parts in muroids, and that a single element is present in dipodoids and geomyoids.

Hill (1937) mentioned an anterior gracilis of variable occurrence in *Thomomys*. In the

two specimens of *Thomomys* which I dissected the muscle was absent on both sides in one specimen and present on both sides in the other. Its origin, insertion and relationships to the nerve of the gracilis and to the popliteal vessels are similar to Howell's "M. gracilis anterior," and the muscle, therefore, represents the genicular part of M. adductor brevis in *Thomomys*, as in *Dipodomys*. The genicular part of M. adductor brevis is narrow in *Thomomys* and *Dipodomys*, but it is a broad muscle in *Perognathus*.

In *Jaculus* the genicular part of M. adductor brevis is slender and is covered for most of its length by the anterior edge of M. gracilis. The femoral part of M. adductor brevis is relatively short in *Jaculus*, being restricted to the posteromedial surface of the proximal two-thirds of the femoral shaft.

M. adductor magnus

ORIGIN.—From the posterior part of the lateral surface of the pubis, from the inferior ischial tuberosity, and from the lower third of the inferior ramus of the ischium.

INSERTION.—On the posterior surface of the lateral crest of the femur.

REMARKS.—In *Zapus* the origin of this muscle lies anterodorsal (deep) to the origin of M. gracilis, dorsal (deep) to part of the origin of M. adductor brevis, and caudoventral to the origin of M. obturator externus. The branch of the obturator nerve to M. adductor magnus passes between that muscle and M. adductor brevis.

In *Sicista* insertion resembles that in *Zapus*. In *Jaculus* the lateral crest of the femur is absent and the insertion of M. adductor magnus has extended distad along the femur to the level of the epicondyles. The line of insertion lies lateral to the line of insertion of the femoral part of M. adductor brevis. Moreover, M. adductor magnus is larger relative to the rest of the adductors in *Jaculus* than in *Sicista* and *Zapus*.

In geomyids, heteromyids, *Citellus*, and *Aplodontia*, M. adductor magnus is divided into M. adductor minimus and M. adductor magnus proprius (Hill, 1937). M. adductor minimus in these forms probably corresponds to M. adductor magnus of *Zapus* and cricetids, since the insertion of M. adductor minimus is confined to the lateral crest of the femur. The insertion of M. adductor magnus proprius in those forms in which M. adductor magnus is divided is on the shaft of the femur distal to the lateral crest. The distal extension of the insertion of M. adductor magnus in *Jaculus* thus resembles M. adductor magnus proprius of geomyoids, but in the jerboas there is no differentiation of the proximally inserting fibers into a separate M. adductor minimus. In *Aplodontia*, M. adductor magnus proprius is apparently further divided into deep and superficial parts (Fry, 1961).

In jerboas, as Parsons (1894) and Howell (1932) noted, some fusion occurs between the adductor group and the hamstring group. In *Jaculus* this fusion involves the origins of M. semimembranosus and M. adductor magnus. These muscles may be distinguished by the difference in innervation, since M. adductor magnus is served by a branch of the obturator nerve, and M. semimembranosus by the hamstring branch of the tibial nerve. M. adductor magnus is readily distinguished from both parts of M. adductor brevis.

M. obturator externus

ORIGIN.—From the lateral surface of the border of the obturator foramen and from the external surface of the obturator membrane.

INSERTION.—Into the trochanteric fossa caudal to the insertion of M. obturator internus and the gemelli.

Ischiotrochanteric Group (Fig. 13C)

M. obturator internus

ORIGIN.—From the medial surfaces of the inferior ramus and the posterior half of the dorsal ramus of the ischium and from the caudal half of the obturator membrane.

INSERTION.—Into the intertrochanteric fossa.

REMARKS.—In *Sicista* and *Zapus* the tendon of this muscle passes anterodorsad to the horizontal ramus of the ischium, crosses the ramus, and, before inserting, receives some fibers from *M. gemellus superior* and *M. gemellus inferior*. In *Jaculus*, *M. obturator internus* is absent. Howell (1932) stated that this muscle is "very decadent" in *Allactaga* and *Jaculus*, though I believe that he included the true *M. gemellus superior* in his *M. obturator internus*.

M. gemellus superior (not *M. gemellus superior* of Howell, 1932)

ORIGIN.—From the dorsal ischial margin between the level of the acetabulum and the point where the tendon of *M. obturator internus* crosses the ischium.

INSERTION.—Into the tendon of *M. obturator internus* and into the intertrochanteric fossa of the femur.

REMARKS.—Hill (1937) and Rinker (1954) noted that Howell's "*M. gemellus superior*" is actually part of the gluteal mass.

M. gemellus inferior

ORIGIN.—From the dorsal ischial margin between the point where the tendon of *M. obturator internus* crosses the ischium and the superior ischial tuberosity.

INSERTION.—Into the tendon of *M. obturator internus*.

REMARKS.—A few fibers may insert directly into the intertrochanteric fossa. In *Jaculus* origin does not extend back to the superior ischial tuberosity. In that genus, *M. obturator internus* is absent, and the gemelli are fused into a single muscle taking origin from the dorsal ischial border.

M. quadratus femoris

ORIGIN.—From the lateral surfaces of the superior ischial ramus and the dorsal half of the inferior ischial ramus.

INSERTION.—On the lesser trochanter.

REMARKS.—In *Sicista* origin includes the lateral surface of the superior ischial tuberosity, as in muroids and geomyoids (Hill, 1937; Howell, 1932; Rinker, 1954), while in *Jaculus*, as in *Zapus*, the origin does not include the tuberosity. Dipodoids do not show the tendency toward differentiation of this muscle into two parts that is seen in geomyoids and muroids. In *Jaculus* the origin extends farther down the inferior ischial ramus than in *Zapus*, reaching the level of the inferior border of the obturator foramen.

Hamstring Group (Fig. 13)

M. caudofemoralis (*M. semimembranosus*, anterior division, Howell, 1932)

ORIGIN.—From the fourth sacral and first caudal vertebrae by the same fascia that gives rise to *M. femorococcygeus*.

INSERTION.—On the posterolateral surface of the femur proximal to the lateral condyle, and on the medial condyle.

REMARKS.—At origin this muscle lies anterior to *M. biceps femoris*, deep to *M. femorococcygeus* and superficial to the nerve to the hamstrings. Between the origins of *M. femorococcygeus* and *M. caudofemoralis* runs the posterior femoral cutaneous nerve. As *M. caudofemoralis* runs distad, the tibial and common peroneal nerves come to lie on its lateral surface, and *M. semimembranosus* on its caudal surface. Between its middle and distal thirds, *M. caudofemoralis* is pierced by the popliteal vessels, distal to which the two insertions are separate, the lateral insertion being smaller than the medial. If a probe be placed between the insertions and passed proximad, the muscle splits fairly cleanly into two parts. The part giving rise to the medial insertion lies posterior to the other part at origin. Both parts originate fascially from the vertebrae, however. There is no attachment to the ischium.

In *Sicista*, the muscle is similar, except that there is no lateral insertion; the popliteal vessels cross lateral to the medial insertion and, thus, do not pierce the muscle.

In *Jaculus* origin is from the ischium by tendon from a crest on the horizontal ramus. Most of the tendon lies ventral to the nerve to the hamstrings, but some fibers are dorsal. Both insertions are present, and the popliteal vessels run between them.

Rinker (1954) summarized the comparative anatomy of the mammalian *M. caudofemoralis* and *M. presemimembranosus*. A muscle originating on the caudal vertebrae or the ischium dorsal (superficial) to the nerve to the hamstrings is called *M. caudofemoralis*. If the origin is from the ischium ventral (deep) to the nerve, the muscle is called *M. presemimembranosus*. The insertion of *M. caudofemoralis* is typically on the femur proximal to the lateral epicondyle, while that of *M. presemimembranosus* is on the medial epicondyle. Hill (1934) found a single muscle occupying this position in the rodents he dissected. In his geomyoids and muroid the origin has the relationships of *M. caudofemoralis*, in *Aplodontia* and *Citellus* the relationships of *M. presemimembranosus*. In *Dipodomys spectabilis*, Hill found that some of the fibers originate ventral to the nerve, though most are dorsal. I have confirmed this in dissection of *Dipodomys merriami*. In *Sciurus griseus* (Hill, *op. cit.*) the muscle originates from the ischium and from a tendinous arch between the ischium and the first caudal vertebra. The nerve to the hamstrings passes through this arch and, thus, lies ventral to the caudal origin and dorsal to the ischial origin. Hill interpreted this condition as an intermediate between the situations found in *Aplodontia* and the geomyids. He suggested that *M. presemimembranosus* and *M. caudofemoralis* are homologous, and that the single muscle has changed its relationship to the nerve to the hamstrings in some forms.

Rinker (1954) found that both muscles are present in *Mustela*, as in certain other mammals. In *Tamiasciurus hudsonicus* and *Sciurus vulgaris*, he found that the structure of these muscles resembles that described by Hill for *Sciurus griseus*, and that the muscles seem to split along a fascial plane when separated from insertion to origin. Fibers inserting on the medial side of the femur originate on the ischium, while the lateral fibers originate either on the tendinous arcade or on an aponeurosis developed on the surface of the ischial origin. Rinker (1954:103) suggested that: “. . . it is not a question here of the caudofemoralis muscle shifting its origin from the vertebra dorsal to the nerve of the hamstring muscles to a position on the ischium ventral to that nerve, as Hill thought, but that it is rather a situation wherein two discrete muscles have begun to fuse.” Rinker also discussed some drawbacks to his working hypothesis, including the manner of innervation of the muscle in rodents and the variety of insertional relationships among the insectivores.

This muscle (or muscles) seems to be in a state of flux in the dipodoids. Both insertions are present in *Zapus* and *Jaculus*, but the lateral insertion is absent in *Sicista* as it is in cricetids. The origin in *Sicista* and *Zapus* resembles that described in cricetids, but in *Jaculus* the origin resembles that of *Citellus* and to an extent that of *Dipodomys*. If Rinker's hypothesis is correct, the common ancestor of *Sicista*, *Zapus* and *Jaculus* must have possessed both origins, and the dorsal one must have been lost in *Jaculus* and the ventral one in *Sicista* and *Zapus*. If Hill's hypothesis is correct, the muscle found in *Jaculus* could have been derived directly from one like that found in *Zapus*.

M. semitendinosus

ORIGIN.—From the spines of the fourth sacral and first caudal vertebrae.

INSERTION.—On the medial ridge of the tibia.

REMARKS.—Apparently there is no ischial head of this muscle in *Sicista* and *Zapus*, but the tendinous inscription that crosses the muscle at the point where the two heads fuse in other rodents is present. In *Jaculus* the ischial head is present and is less than half the bulk of the caudal head. It joins the underside of the caudal head at the inscription.

Some of the fibers of *M. semitendinosus* seem to leave that muscle at the level of the inscription and continue as part of *M. biceps femoris* to insert on the lateral side of the shank. Rinker (1954) found that in cricetids, where both heads are present, the inscription crosses *M. semitendinosus* and part of *M. biceps femoris*. Thus, the caudal head is attached mainly to the ischial head of *M. semitendinosus*, but partly to *M. biceps femoris*. The comparative anatomy of this muscle has been reviewed by Appleton (1928). If Appleton's and Rinker's ideas are correct, the absence of the ischial head in *Sicista* and *Zapus* is certainly secondary.

A small hook-like cartilaginous projection from the tibia is developed in the insertion of this muscle in *Zapus*. The insertion is shifted proximad in *Jaculus* and attaches on the tibia no farther distad than the distal limit of the pronounced crest.

M. semimembranosus

ORIGIN.—From the superior ischial tuberosity and the dorsal half of the inferior ischial ramus.

INSERTION.—On the medial surface of the shank proximal to the insertion of *M. gracilis*.

REMARKS.—Relationships of this muscle to *M. presemimembranosus* and *M. adductor magnus* are covered in the descriptions of those muscles. In *Jaculus* the insertion has migrated proximad so that it seems to attach to the fascia of the knee joint rather than to the tibia.

M. biceps femoris

ORIGIN.—From the lateral surface of the superior tuberosity of the ischium.

INSERTION.—Into the fascia of the lateral surface of the shank musculature.

REMARKS.—In *Sicista* the insertion occupies the proximal third of the shank, in *Zapus* the proximal two-fifths or half, and in *Jaculus* the proximal quarter. In *Sigmodon*, in contrast, the insertion occupies the proximal three-quarters of the shank (Rinker, 1954).

Relationships of this muscle to *M. femorococcygeus* and *M. caudofemoralis* are discussed in the description of those muscles.

Flexor Group of the Leg (Fig.15)

M. gastrocnemius

ORIGIN.—From the caudal surface of the medial epicondyle of the femur, from the caudal surface of the lateral epicondyle of the femur, and from the fascia of the shank muscles.

INSERTION.—On the calcaneus.

REMARKS.—As in many other mammals, a sesamoid bone is present in each of the origins. The two heads enclose the origin of *M. plantaris* and are fused with one another in the distal two-thirds of the belly. In *Sicista* the heads are more distinct.

In *Zapus* the proximal three-quarters of the muscle is fleshy; in *Sicista* the proximal three-fifths and in *Jaculus* the proximal half.

M. plantaris

ORIGIN.—From the sesamoid of the origin of the lateral head of *M. gastrocnemius*.

INSERTION.—Continues in the foot as *M. flexor digitorum brevis*.

REMARKS.—Near the origin, the tendon of this muscle lies deep to the tendon of *M. gastrocnemius*. Distally, it crosses the medial side of the tendon of *M. gastrocnemius* and comes to lie on the posterior surface, passing around the attachment of the tendon of *M. gastrocnemius* on the calcaneus. In *Sicista* the tendon divides after passing onto the foot. The superficial part continues as the superficial plantar aponeurosis, inserting into the three central digits. The deeper tendon continues as *M. flexor digitorum brevis*. In *Zapus* and *Jaculus* the tendon does not divide, and the superficial plantar aponeurosis is not developed.

M. soleus

ORIGIN.—From the posterior surface of the head of the fibula.

INSERTION.—Into the tendon of *M. gastrocnemius*.

REMARKS.—In *Sicista*, little of the proximal part of this muscle is tendinous. In *Zapus* the proximal quarter is tendinous, and in *Jaculus* the proximal sixth.

M. popliteus

ORIGIN.—From the lateral condyle of the femur, anterior to the femoral attachment of the fibular collateral ligament.

INSERTION.—On the medial surface of the proximal quarter of the tibia and on fascia of the belly of *M. flexor digitorum fibularis*.

REMARKS.—In *Sicista* the insertion occupies slightly less than the proximal third of the medial tibial surface, while in *Jaculus* it is confined to the proximal fifth or less. In all forms the proximal third of the anterior edge of the insertion is covered by the tibial collateral ligament.

M. flexor digitorum tibialis

ORIGIN.—From the medial ridge of the tibia in its second fourth and from the fascia of *M. tibialis posterior*.

INSERTION.—By two tendons: into the tendon of *M. flexor digitorum fibularis* in the sole of the foot and into a semilunar sesamoid bone behind the first plantar tubercle.

REMARKS.—In *Sicista* this muscle originates in the tibia's third sixth, in *Jaculus* in

the second sixth. In *Sicista*, as in *Zapus*, the muscle splits below the medial malleolus to form two insertional tendons. In *Jaculus* the insertional tendon is undivided and fuses with the tendon of *M. flexor digitorum fibularis*.

In *Zapus* the tendon of this muscle lies in a special groove on the medial malleolus, between the grooves of the tendons of *M. flexor digitorum fibularis* and *M. tibialis posterior*. In *Sicista* and *Jaculus* the tendons of *M. flexor tibialis* and *M. tibialis posterior* are more closely associated at the malleolus.

Dobson (1882, 1883) distinguished two basic types of insertion of this muscle in rodents. In his "hystricomorphous type" the tendon of *M. flexor digitorum tibialis* joins the tendon of *M. flexor digitorum fibularis* in the foot. In his "myomorphous and sciuriformous type" the tendon of *M. flexor digitorum tibialis* is entirely independent and inserts on the first digit or in the plantar fascia. Dobson's categories are too simple to include observed variations among rodents, and his "hystricomorphous type" and variations of it occur sporadically among many groups of rodents. In heteromyids the tendon of *M. flexor digitorum tibialis* is apparently undivided and joins that of *M. flexor digitorum fibularis*, corresponding well to Dobson's "hystricomorphous type" (Parsons, 1896; Howell, 1932). In geomyids, the tendon of *M. flexor digitorum tibialis* splits, part going to the tendon of *M. flexor fibularis*, and part to the first metatarsal (Hill, 1937). In Rinker's cricetids the arrangement corresponds roughly to Dobson's "myomorphous and sciuriformous type." Rinker (1954) found some variation in insertion among these genera, but in no case do the tendons of the two muscles fuse in the foot. In *Rhizomys*, family Rhizomyidae, the tendons are fused (Parsons, 1896).

Conditions in *Sicista* and *Zapus* are reminiscent of both of Dobson's types since in those the tendon splits; the greater part joins the tendon of *M. flexor digitorum fibularis* and the lesser inserts on a sesamoid near the base of the first metatarsal. Union of the two tendons may be a primitive placental mammalian characteristic (Dobson, 1883; Hill, 1937), and *Sicista* and *Zapus* could represent the primitive dipodoid condition in regard to these muscles. Loss of the insertion to the metatarsal area in *Zapus* would produce the fully "hystricomorphous" condition seen in the jerboas. Since geomyids retain both insertions, it seems probable to me that heteromyids, through a stage represented by living geomyids, have arrived at a fully "hystricomorphous" condition independently of jerboas.

In squirrels and *Aplodontia* the tendons are unfused (Hill, 1937).

M. tibialis posterior

ORIGIN.—From the second quarter of the medial crest of the tibia and from fascia over the belly of *M. flexor digitorum fibularis*.

INSERTION.—On the posterior surface of the medial tarsal bone.

REMARKS.—The tendon of insertion passes under the deltoid ligament. Relationships of the tendon of this muscle to the other flexor tendons at the medial malleolus are described under *M. flexor digitorum tibialis*.

M. flexor digitorum fibularis

ORIGIN.—From the caudal surfaces of the heads of tibia and fibula, from the entire interosseous membrane, and from the caudal surfaces of the free parts of the tibia and fibula adjacent to the membrane.

INSERTION.—On the terminal phalanges of the five digits.

REMARKS.—This is a strong, bipennate muscle. Relationships of its tendon to the tendons of the other flexor muscles are described under *M. flexor digitorum tibialis*. In

Jaculus, insertion is into the terminal phalanges of digits 2 through 4. In all four genera the tendons to these digits penetrate the tendons of *M. plantaris* to the corresponding digits (cf. *M. plantaris* and *M. flexor digitorum brevis*).

Flexor Group of the Pes

In dipodoids the toes of the hind foot progressively lose their capacity for independent movement. In *Sicista* the pes resembles that of a quadrupedal cricetid such as *Peromyscus* in that all five metatarsals are present, and they may be moved with respect to one another even in the dead animal. In *Zapus* the five metatarsals are also present, but they are so closely bound by fascia that they cannot be separately manipulated in a dead specimen. In *Jaculus* the three central metatarsals are fused and the lateral and medial ones are lost.

Concordant with this restriction of independent metatarsal movement is the reduction in number of intrinsic pedal muscles and the conversion of those remaining into tendons. The loss of *Mm. extensores breves* has been described above. In *Sicista* the pedal muscles are fleshy and well represented. These are either lost or reduced to tendons in *Jaculus*. *Zapus* is intermediate in that most of the flexors are retained, but they are heavily fascial.

Because the pedal muscles are well developed only in *Sicista*, the smallest of the forms dissected, the details of their structure are in some cases uncertain. Innervations were not traced.

M. flexor digitorum brevis

ORIGIN.—As a continuation of the deep tendon of *M. plantaris* in the foot.

INSERTION.—On the bases of the second phalanges of digits 2 through 4.

REMARKS.—This muscle is fleshy and well developed only in *Sicista*. In that genus a distinct belly is present, and the muscle is well differentiated from the superficial plantar aponeurosis. In *Zapus* few if any muscle fibers are present, and the tendon attaches strongly to the calcaneus as it passes. In *Jaculus* no muscle fibers are present; a single strong tendon (which essentially is a continuation of the tendon of *M. plantaris*) runs down the length of the fused metatarsals to the metatarso-phalangeal joint. There it splits into three insertional tendons. In *Jaculus* the tendon also seems to be fascially bound to the calcaneus.

Mm. flexores breves accessorii

Rinker (1954) found these muscles in *Neotoma* and *Peromyscus*. They have been described in a number of other rodents also, under different names by different authors. I did not find them in dipodoids. If present in *Sicista*, they are certainly not as well developed as in *Peromyscus*. They are definitely not present in *Zapus* or *Jaculus*.

M. abductor hallucis brevis

ORIGIN.—From the plantar surface of the navicular (scaphoid) bone.

INSERTION.—On the medial sesamoid bone at the metatarsophalangeal joint of the hallux.

REMARKS.—This muscle is fleshy in *Sicista*, mostly tendinous in *Zapus* and absent in *Jaculus*.

M. abductor ossis metatarsi quinti

ORIGIN.—From the ventromedial surface of the proximal end of the calcaneus.

INSERTION.—On the base of metatarsal 5.

REMARKS.—Howell (1932) described this muscle under this name, but called it "M. quadratus plantae" in 1926.

In *Sicista*, *Zapus*, *Jaculus*, and (*vide* Howell, 1932) *Allactaga* this muscle is represented by a tendon only. In *Jaculus* it inserts on the vestige of the base of the fifth metatarsal. It is entirely fleshy in many rodents, such as squirrels, *Aplodontia*, *Neotoma*, *Oryzomys*, and *Sigmodon* (Hill, 1937, Rinker, 1954). Partial transformation of the muscle into tendon has taken place in *Peromyscus* and *Dipodomys* (Howell, 1932; Rinker, 1954). Complete transformation has occurred in *Thomomys* and *Geomys* in addition to the dipodoids (Hill, 1937). Such transformation has apparently taken place independently in many rodents, and it cannot be correlated alone with bipedal leaping.

M. abductor digiti minimi

ORIGIN.—By tendon from the distal end of the calcaneus, from a sesamoid in the tendon of origin at the level of the base of the fifth metatarsal and from the surface of *M. flexor digiti minimi brevis*.

INSERTION.—On the lateral sesamoid bone at the metatarso-phalangeal joint of the fifth digit.

REMARKS.—The sesamoid in the tendon of origin is connected to the calcaneus by a heavy tendon in addition to the tendon giving rise to muscle fibers. This muscle is difficult to separate from *M. flexor digiti minimi brevis* except at insertion.

M. abductor digiti minimi is fleshy in *Sicista*, rather tendinous in *Zapus*, and absent in *Jaculus*.

M. flexor hallucis brevis

I did not find this muscle in dipodoids.

M. flexor digiti minimi brevis

ORIGIN.—From the sesamoid in the origin of *M. abductor digiti minimi* and from the fascia of that muscle.

INSERTION.—Into the medial sesamoid bone at the metatarso-phalangeal joint of the fifth digit.

REMARKS.—Some fibers of this muscle may originate on the calcaneus in some specimens; dissection of the area was not satisfactory. The muscle is fleshy in *Sicista*, fascial in *Zapus*, and absent in *Jaculus*.

M. abductor hallucis

ORIGIN.—From the medial edge of the common deep palmar tendon (cf. *Mm. interossei*).

INSERTION.—On the lateral side of the lateral sesamoid at the metatarsophalangeal joint of the hallux, and possibly into the base of the first phalanx of that digit.

REMARKS.—This is a slender muscle in *Sicista*. In *Zapus* it is mostly fascia, if present. Identification of this muscle is tentative; its origin and insertion agree better with those of *M. adductor hallucis* than with those of *M. flexor hallucis brevis* of cricetids (cf. Rinker, 1954). The muscle is probably absent in *Jaculus*.

M. adductor digiti secundi and *M. adductor digiti quinti*

I did not find these muscles in any dipodoid.

Mm. lumbricales

ORIGIN.—From the tendon of *M. flexor digitorum fibularis* in the angles formed by the divergence of the inserting tendons.

INSERTION.—On the medial sides of the tendons of *M. extensor digitorum longus* to the lateral four digits.

REMARKS.—In *Sicista* these are well developed and fleshy. In *Zapus* they are more slender and fascial, and the muscle to digit 3 may be almost entirely tendinous. Howell (1932) found two lumbricales in *Allactaga* and none in *Jaculus*. I found none in *Jaculus*.

Mm. interossei

Individual interosseous muscles could not be separated. They insert on lateral and medial sides of the three central digits in *Sicista* and *Zapus*. The fibers inserting on digit 4 seem to originate from the sesamoid in the origin of *M. abductor digiti minimi*. The fibers to the other digits arise from a common deep plantar tendon which originates on the base of the first metatarsal, the navicular, and the cuboid.

The interossei are fleshier in *Sicista* than in *Zapus*. Howell (1932) described "Mm. flexores breves" in *Dipodomys*, and at least some of these muscles are interossei. He noted that these "short flexors" were reduced to three strong tendons in *Jaculus*. These originate from the lateral tarsal sesamoid (corresponding to the sesamoid in the origin of *M. abductor digiti minimi* in *Zapus*?) and insert on all three digits. Presumably, these strong tendons were derived from the interossei. In *Allactaga* the tendons to digits 4 and 5 originate on the lateral tarsal sesamoid; the tendons to digits 2 and 3 originate on a sesamoid at the base of the first metatarsal (Howell, 1932). The tendon to the first digit was probably derived from one of the flexors of the hallux.

DISCUSSION

The following summary treats only selected muscles, those important in the analysis of adaptation to different modes of life and analysis of the relationships of rodent groups. Extended discussion of these and other muscles, and references to the literature, are embodied in the descriptive section of this paper.

The morphology of a living animal is the result of numerous compromises among various selective forces operating now and in the past on both embryo and adult. Hence muscular characters seen in Recent forms are not necessarily associated with obvious peculiarities of the given animal's

present way of life. Furthermore, electromyographic studies of the actions of human muscles (Basmajian, 1962) have not always supported ideas on function derived from the study of cadavers. I have therefore approached the question of function of individual muscles cautiously and have suggested possible selective value of differences only when the functional significance seems obvious.

Hill (1937) and Rinker (1954, 1963) used myological characters in investigating the relationships of rodents at the subfamilial, generic, and subgeneric levels. They both assumed that similarities among the genera they studied were attributable to "heritage" from a common ancestor, and they both observed that this assumption is probably invalid at higher levels in classification. Use of myological characters at higher levels has been restricted by the lack of detailed descriptions of the muscles of enough genera to provide an understanding of the sort of variation to be expected within superfamilies and families. In addition, knowledge of a larger number of forms permits inferences about parallelism and convergence in the evolution of the musculature. For this sort of inference, knowledge of the anatomy of the less specialized genera in a superfamily is crucial. If, for example, a muscular character occurs in ricochetal geomyoids and dipodoids, but not in quadrupedal representatives of both groups, it can be inferred that the ricochetors have developed the character independently, assuming that geomyoids and dipodoids each constitute a natural group. The inference is strengthened if the functional significance of the character can be correlated with adaptation for bipedal leaping.

Retention of the primitive condition of a muscle in two or more groups is less indicative of relationship than the presence in different groups of the same advanced condition. Resemblance of a given muscle in rodent and in non-rodent mammals is taken as evidence of primitiveness. If an advanced condition is constant in two or more rodent groups, it must be inferred that the structure was inherited from a common ancestor. Such distribution of a character among living forms does not permit the inference that the groups have developed the structure independently, unless independent development can be demonstrated by the bony structures of fossils.

MUSCULAR VARIATION WITHIN THE DIPODOIDEA

The cranial muscles show some variation among dipodoid genera. The rostral and infraorbital origin of *M. masseter medialis anterior* is least extensive in *Sicista* and most extensive in *Jaculus*. As this part of the muscle hypertrophies, it also becomes better differentiated from the remainder of pars anterior. *M. temporalis* is relatively largest in *Sicista*, slightly

reduced in *Zapus* and greatly reduced in *Jaculus*. This reduction involves progressive loss of the anterodorsal part of the muscle and retention of the posteroventral part. In *Jaculus* the muscle consists of a narrow, almost horizontal tendon on which the short muscle fibers insert. The coronoid process, on which the tendon of *M. temporalis* inserts, is greatly reduced in *Jaculus*. While the hypertrophy of the rostral and infraorbital origin of *M. masseter medialis anterior* might be associated either with differences in gnawing or differences in mastication, the variation in *M. temporalis* likely is associated with differences in mastication. The molariform teeth in *Sicista* are tuberculate and brachydont; in *Zapus* they are higher-crowned and ridged, and in *Jaculus* they are flat-surfaced subhypsodont structures. Vertical crushing movements of the mandible are probably more important than horizontal grinding movements in *Sicista*, and *M. temporalis* probably pulls the mandible upward. In *Jaculus* horizontal movement of the mandible probably predominates, and *M. temporalis* probably pulls the mandible backwards.

The sheet-like components of the superficial facial musculature are integral and well developed in *Sicista* and *Zapus*, as in most other rodents. In jerboas the sheets are lost or reduced. Thus, in *Jaculus*, *M. platysma myoides pars buccalis* and *M. zygomaticolabialis* are reduced to narrow strips. *M. platysma myoides pars mentalis* is fairly narrow and originates from the auricular cartilage instead of from fascia over the shoulder. *M. sphincter colli profundus partes intermedia ventralis* and *intermedia dorsalis* are lost or reduced to fascia, leaving *partes palpebralis* and *auris* as independent strips of muscle. Disappearance of *partes intermedia ventralis* and *intermedia dorsalis* is foreshadowed in *Zapus*, where *partes dorsalis* is rather narrow, and *partes intermedia ventralis* and *auris* are separated by a fascial hiatus. The reduction of these facial muscles is not readily explained, unless it is associated in some way with the general broadening of the head in jerboas. *Dipodomys* shows no such reduction.

In contrast, the muscles inserting in the mystacial pad and winding among the bases of the mystacial vibrissae (*M. nasolabialis*, *M. maxillo-labialis*, and *M. nasolabialis profundus pars media inferior*) are hypertrophied in *Jaculus*. Some of the mystacial vibrissae are very long and thick in jerboas, and the hypertrophy of the mystacial muscles is evidently correlated with the development of the vibrissae. In *Jaculus* these long vibrissae are directed ventrally during bipedal leaping and maintain contact with the ground (Hackinger, 1959). The long vibrissae in *Dipodomys* and *Microdipodops* are used similarly during slow leaping, but contact with the ground is interrupted during rapid bipedal locomotion (Eisenberg, 1963).

The auricular slip of *M. spinotrapezius* is present in *Sicista* and *Zapus*,

but not in *Jaculus*. The auricular slip is also present in some sciurids, murines, microtines, cricetines, and bathyergids (Meinertz, 1951; Rinker, 1954, and included references). It is probably homologous with the retractor of the cheek pouch in hamsters (Priddy and Brodie, 1948) and partly homologous with the retractor of the cheek pouch in geomyoids. In sciurids, in contrast, the cheek pouch retractor develops from the superficial facial musculature, and muscles innervated by the accessory nerve are not involved (Hill, 1935). The dipodoids, muroids, sciurids and bathyergids that have the slip are probably preadapted for the evolution of a retractor of the sorts seen in geomyoids and hamsters. An alternative explanation, namely that the ancestors of these rodents had cheek pouches and lost them, is less likely. The function of the auricular slip when not associated with a cheek pouch is unexplained, however.

The stylohyal cartilage, part of the anterior horn of the hyoid, is present in all dipodoids dissected. *Sicista* and *Zapus* show the primitive arrangement of the musculature attached to the anterior horn (Mm. jugulo-hyoideus, stylohyoideus, styloglossus, and stylopharyngeus). In *Jaculus* the stylohyal is present but attaches to the paroccipital process, and M. jugulo-hyoideus is lost. The rest of the muscles retain their primitive origins, however. Functional significance of the shift of the stylohyal's attachment is not apparent, unless the shift is associated with the ventral expansion of the auditory bulla.

The epaxial muscles of dipodoids and geomyoids show a great deal of modification in the forms adapted for bipedal leaping. M. iliocostalis is reduced in both *Jaculus* and *Dipodomys*, and M. longissimus is relatively massive. In ricochetors the anterior part of the body is deprived of the support of the pectoral limbs. Support is provided instead by the lumbosacral transversospinal mass, which is largest in advanced ricochetors. In *Sicista* the transversospinalis is a narrow column confined to the area between the zygapophyses and neural spines and continuous posteriorly with M. extensor caudae medialis. Fibers of the latter muscle originate as far anteriorly as the posterior lumbar spines, as in quadrupedal cricetids. In ricochetors the lumbosacral transversospinalis expands laterad, covering part of M. extensor caudae lateralis, and becoming differentiated from M. extensor caudae medialis posteriorly. The latter muscle is crowded to the posterior sacral region and the root of the tail. The anterior sacral neural spines, which primitively gave rise to tendons of origin of the medial caudal extensor, disappear when the muscle is excluded from the anterior part of the sacrum. In *Zapus* the lumbosacral transversospinalis is moderately expanded and the first sacral spine is lost. In *Jaculus* the muscle is greatly expanded, and the first three sacral spines are lost. *Perognathus* shows very slight expan-

sion, *Dipodomys* expansion to a degree intermediate between *Zapus* and *Jaculus*, and *Thomomys* no expansion at all. Since this muscle is not broadened in quadrupedal geomyoids and dipodoids, the expansion must have occurred independently in the ricochetal representatives of the two superfamilies.

In ricochetal dipodoids and geomyoids the short neck is sharply flexed against the thorax. The post-atlantal cervical vertebrae may fuse, the fusion may include the first thoracic vertebra (Vinogradov, 1937). In *Jaculus* the cervical transversospinalis mass (*M. semispinalis cervicis*) is sharply differentiated into vertical and horizontal parts (Hatt, 1932). This differentiation is also seen in *Zapus*, but not in *Sicista* or quadrupedal muroids such as *Peromyscus* and *Rattus*. Surprisingly, differentiation into horizontal and vertical parts is not found in *Dipodomys* either.

In jerboas, the extrinsic musculature of the pectoral limb shows some reduction and fusion by comparison with *Zapus* and *Sicista*. *M. acromiotrapezius* does not originate on the skull in the last two genera, and is well separated from *M. cleido-occipitalis* by the posterior triangle of the neck. In *Jaculus* some fibers of *M. acromiotrapezius* originate cranially, and the muscle's ventral border is close to the dorsal border of *M. cleido-occipitalis*. *M. cleidomastoideus* is evidently lost in *Jaculus*. *M. serratus anterior* usually originates from fewer ribs in jerboas, though the extent of origin seems to be individually variable in some dipodoid species. The rhomboidei and *M. occipitoscapularis* fuse in *Jaculus*.

Very little variation was noted in the intrinsic musculature of the pectoral limb, and few of the observed differences seem to have functional significance. *M. latissimus dorsi* is somewhat narrower in *Sicista* than in quadrupedal cricetids, and it is extremely narrow in *Zapus* and *Jaculus*. The brachial muscles are short and thick in *Jaculus*, since the humerus is relatively short. The short head of *M. biceps brachii* is absent in all dipodoids except *Sicista*. Its loss in *Zapus* and the jerboas probably occurred independently of loss in some other rodents. The deep extensor of the fourth digit is absent in *Jaculus*, but present in *Allactaga* and other dipodoids. The four heads of *M. flexor digitorum profundus* tend to coalesce in jerboas, and the two superficial heads are reduced.

As would be expected, the greatest muscular variation among dipodoids occurs in the pelvic limb. The abductors of the thigh (the lateral part of *M. tensor fasciae latae* and *M. gluteus maximus*) are greatly reduced in *Jaculus* by comparison with *Zapus*. No such reduction seems to have occurred in *Dipodomys*. *M. femorococcygeus* originates from posterior sacral and anterior caudal vertebrae in *Sicista* and *Zapus*. In *Jaculus* the origin has migrated posteriorly along the sacrotuberous ligament to the superior

ischial spine. The insertion is partly on the fascia of the knee joint and partly on the aponeurosis of the quadriceps femoris. The muscle probably acts as a more powerful retractor of the thigh in *Jaculus* than in *Zapus*. The origin in both *Dipodomys* and *Thomomys* resembles that in *Jaculus*, so the condition is not necessarily correlated with the ricochet habit. *M. obturator internus*, which probably acts as a medial rotator of the thigh in *Sicista* and *Zapus*, is absent in *Jaculus*. *M. adductor magnus* inserts on the posterior surface of the lateral crest of the femur in *Sicista* and *Zapus* and probably acts partly as a lateral rotator of the thigh. In *Jaculus*, as in most other jerboas, the lateral crest is absent (Vinogradov, 1937), and *M. adductor magnus* inserts along the posterior surface of the femur, lateral to the line of insertion of the femoral part of *M. adductor brevis*. The muscle therefore has less leverage for acting as a lateral rotator of the thigh in the jerboas, and the rotatory function is probably reduced. Vinogradov (1937) noticed that the head of the femur is spherical in sicistines and zapodines but tends to be cylindrical in jerboas. These osteological and myological features probably indicate that movement of the thigh is restricted to the sagittal plane in jerboas. Such restriction of the movement of an appendage is characteristic of ricochet and cursorial mammals (Howell, 1944).

M. tenuissimus is present in *Sicista* and absent in *Zapus* and jerboas. Its loss in zapodines and jerboas probably occurred independently of loss in certain other rodents.

The deeper gluteal muscles (*M. gluteus medius* and *M. gluteus minimus*), which act as retractors of the thigh in mammals, are not particularly enlarged in ricochet rodents. The "gluteal tongue" is actually reduced in ricochet dipodoids. It seems to be best developed in cursorial quadrupeds, such as some caviomorphs and ungulates.

Vinogradov (1937) observed that the ratio of preacetabular to postacetabular length of the pelvis decreases in ricochet dipodoids. The relative lengthening of the ischium increases the angle of insertion of the hamstring muscles on the femur and leg, if the ratio of pelvic length to femoral length remains unchanged. These muscles are probably more powerful retractors of the thigh in jerboas than in *Zapus* and *Sicista*. The insertions of the adductor and hamstring muscles tend to be restricted to the proximal part of the leg in ricochet dipodoids. This restriction both lightens the distal part of the limb and results in a more rapid but less powerful stroke. It is characteristic of ricochet and cursorial mammals (Howell, 1944). Otherwise, the adductors of *Sicista*, *Zapus*, and *Jaculus* are fairly similar, except for the difference in insertion of *M. adductor magnus* and the relationships of that muscle to *M. semimembranosus*. The hamstring muscles, in contrast, seem to be in a state of flux in the dipodoids as in other rodents, since con-

siderable variation in origins and relationships to nerves is found in *M. caudofemoralis* and *M. semitendinosus*.

The muscles of the leg in jerboas tend to have relatively shorter bellies and relatively longer tendons than in *Zapus* and *Sicista*. But the bellies of certain muscles may be relatively shorter and the tendons relatively longer in *Sicista* than in *Zapus*. Concentration of the belly at the proximal end of a leg muscle lightens the distal part of the appendage and probably results in a shorter but more powerful stroke. *M. extensor digitorum longus* is relatively larger and more differentiated in *Jaculus* than in *Zapus* and *Sicista*, but the other leg muscles of jerboas show no tendency toward differentiation.

The intrinsic muscles of the foot tend to be reduced in ricochetal dipodoids. In *Sicista* there are two intrinsic extensors (*Mm. extensores digitorum breves*), in *Zapus* one, and in *Jaculus* none. The intrinsic pedal flexors are numerous and fleshy in *Sicista*. In *Zapus* they are slightly reduced in number, and the remaining muscles are heavily fascial. In *Jaculus* the intrinsic flexors are either absent or transformed into heavy tendons. These myological differences are associated with the progressive restriction of independent movement of the toes in ricochetors. The foot acts mostly as a monodactyl unit in these animals, and in many jerboas the three central metatarsals fuse and the first and fifth are lost (Vinogradov, 1937; Howell, 1944).

In summary, the dipodoid genera dissected are similar myologically. Some of the differences, particularly those in the epaxial muscles and the muscles of the pelvic limb, can be associated with adaptation for bipedal leaping in the jumping mice and jerboas. Heteromyids have developed some of these features, probably independently. The myological data derived from the present study provide no new information on the relationships of *Sicista* and *Zapus* to the jerboas. The critical intermediate forms, especially *Salpingotus* and *Cardiocranius*, must be dissected before the validity of separation of zapodids from dipodids can be tested myologically. On osteological grounds (Vinogradov, 1937), continued separation of the two groups seems to me to be unwarranted.

No constant myological differences were found between *Zapus* and *Napaeozapus*. Rinker (1963) found 17 to 24 differences between subgenera of *Peromyscus*, and by the same standard it would seem that continued separation of *Zapus* from *Napaeozapus* at the generic level is unwarranted. Two considerations mitigate against considering these forms congeneric, however. One is that my standard for considering a muscle as different in two forms is probably different from Rinker's. The other is that some dental differences exist between the two forms.

THE RELATIONSHIPS OF DIPODOIDS TO OTHER RODENTS

The masseter in dipodoids is hystricomorphous. *M. masseter lateralis profundus* does not extend anterodorsad on a zygomatic plate, as it does in myomorphous and sciuromorphic types. Part of *M. masseter medialis anterior* originates from the rostrum anterior to the infraorbital foramen and passes posteroventrad through the foramen to insert on the mandible, in contrast to the sciuromorphic and protrogomorphic types. The hystricomorphous masseter probably developed from the protrogomorphic type several times in the Rodentia. If A. E. Wood (1949) is correct, independent development of the hystricomorphous masseter in caviomorph rodents can be inferred from the fossil record. Dipodoids have a sciurognathous mandible, in contrast to the hystricognathous mandible of hystricomorphs, caviomorphs and certain other rodents.

The myomorphous masseter of muroids could have evolved from protrogomorphic, sciuromorphic, or hystricomorphous types. Origin from the protrogomorphic type would involve simultaneous penetration of the infraorbital foramen by the medial masseter and upgrowth along the edge of a zygomatic plate by the lateral masseter. I consider this method of origin possible but unlikely. Origin from the sciuromorphic type would involve penetration of the infraorbital foramen by fibers of the medial masseter, with some concomitant reduction in the zygomatic plate and the mass of the anterior lateral masseter. In sciuromorphic types, however, the infraorbital foramen is small and low on the skull; compressed, so to speak, between the zygomatic plate and the rostrum. Derivation of the myomorphous type from a sciuromorphic type would involve a considerable dorsal migration and enlargement of the foramen. I consider this method of origin also possible but unlikely. A third method of origin, from the hystricomorphous type, would involve upgrowth of the lateral masseter on a zygomatic plate and consequent ventral compression of the infraorbital foramen. In most living muroids, the infraorbital foramen is narrow ventrally and largest dorsally. Fibers of the medial masseter penetrate the foramen only dorsally. Among living myomorphous rodents, some genera show a zygomasseteric structure intermediate between hystricomorphous and advanced myomorphous types. In *Spalax*, *Myospalax*, and *Oxymycterus*, for example, the lateral masseter and zygomatic plate do not extend far dorsad along the rostrum. The infraorbital foramen is large in these forms and is not restricted ventrally. Structure of the masseter in living rodents, then, would seem to indicate that the myomorphous masseter was derived from the hystricomorphous type.

Stronger support for this method of derivation is found in the fossil

record. Wilson (1949b:123, 124) pointed out that the zygomatic plate is poorly developed in Oligocene cricetodonts by comparison with Miocene cricetodonts and many younger muroids. In the Mongolian Oligocene *Cricetops* (Matthew and Granger, 1923), the zygomatic plate is also poorly developed. Wilson suggested that the myomorphous masseter of muroids was derived from a dipodoid-like type. Part of his argument was based on *Simimys* from the Sespe Eocene of California. In that genus the zygomatic plate is barely indicated, and the zygomaseteric structure strongly resembles that of living dipodoids (Wilson, 1949a). The zygomaseteric resemblance between *Simimys* and the dipodoids is even closer than Wilson supposed, since he inferred the presence of *M. masseter superficialis* in *Simimys* from the bony structure of the inferior zygomatic root and was misled by Miller and Gidley (1918) into thinking that the muscle is not distinct in dipodoids. According to Tullberg (1899), and the results of the present study, *M. masseter superficialis* in the dipodoids is recognizable, though its fibers are difficult to separate from those of *M. masseter lateralis profundus* in the posteroventral part of the jaw. *M. masseter superficialis* seems to be most highly differentiated in sciuriformous and myomorphous types, since its origin remains ventral in position as the lateral masseter extends past it on the zygomatic plate. Wilson described *Simimys* as a muroid, and the genus was later transferred to the Dipodoidea by Stehlin and Schaub (1951). I now think that I was mistaken when I considered *Simimys* a dipodoid in an earlier paper (Klingener, 1963). Evidence from the structure of the masseter in living forms and its inferred structure in the fossils thus indicates that the myomorphous masseter of the muroids was probably derived from an hystricomorphous condition as seen in the dipodoids. If this hypothesis be true, the dipodoids are more closely related to the muroids than to any of the rodents having a sciuriformous masseter. Further indications of relationship are found in the structure of muscle groups other than the masseter.

Dipodoids show a number of myological similarities to sciurids. These similarities are: (1) the retention of the stylohyal and its primitive arrangement of musculature (*Mm. stylohyoideus*, *styloglossus*, *stylopharyngeus*, and *jugulohyoideus*, except as modified in *Jaculus*), (2) the "sciuriformous" digastric, (3) the retention of a full set of deep digital extensors of the forearm (*Mm. extensor indicis*, *extensor digiti tertii proprius*, and *extensor digiti minimi*) except for the loss of the tendon to the fourth digit in *Jaculus*, and (4) the presence of *M. brachioradialis*. These characters are all considered to be primitive. The first is shared also with cricetids and with *Aplodontia*, the second with some cricetids, and the fourth with erethizontids.

The presence of *M. brachioradialis* in dipodoids is puzzling. The function of this muscle in humans has been subject to some controversy. In 1867 Duchenne (Duchenne, 1959) thought that the muscle acted in flexion of the forearm and in supination of the prone forearm and pronation of the supine forearm. One of the old names given the muscle, "*M. supinator longus*," referred to one of its supposed functions. Later anatomists viewed *M. brachioradialis* as a "reserve" for actions placing a strain on the forearm, or as a "shunt" muscle operating in conjunction with *M. brachialis* and *M. biceps brachii* in flexion of the forearm. Electromyographic studies tend to support the hypothesis that the muscle acts as a synergist during flexion, and lend no support to the hypothesis that it normally acts during pronation and supination (Basmajian, 1962). In brachiating mammals, *M. brachioradialis* would seem to have an obvious function. A heavy strain is placed on the forearm in such arboreal mammals, and flexion must be powerful. But what actions performed by rodents involve powerful flexion of the forearm? Erethizontids and squirrels are arboreal, but they are not brachiators. Possibly the muscle is of use in climbing, but its persistence in dipodoids clearly cannot be laid to its use in climbing.

Dipodoids share very few myological characters with hystricomorphs (*sensu lato*). Parsons (1896) listed the following: (1) the large size of the anterior deep part of the masseter passing through the infraorbital foramen, (2) the presence of *M. scalenus anterior* rising from the basioccipital, (3) the presence of only one head of *M. biceps brachii*, (4) the non-decussation of *M. rectus abdominis* with the muscle of the opposite side at origin, and (5) the union of the tendons of *M. flexor digitorum tibialis* and *M. flexor digitorum fibularis* in the sole. Parsons recognized that the fifth character is primitive. I agree. Resemblances in zygomasseteric structure have been dealt with above. I find no true anterior scalene in dipodoids. Loss of the short head of *M. biceps brachii* is probably a parallelism between dipodoids, hystricomorphs, and certain other rodents. Non-decussation of *M. rectus abdominis* is shared with most other rodent groups.

Howell's (1932) report of the absence of *M. omohyoideus* in *Zapus* is erroneous. Tendency toward reduction and loss of this muscle is present in caviomorphs.

The studies of Meinertz (1941*b*, 1944*b*, 1951, and included references) on the superficial facial muscles of rodents indicate that hystricomorphs and caviomorphs are distinct from dipodoids and most other rodents. He listed the following characters for hystricomorphs (*s.l.*): (1) supraorbital innervation of *M. nasolabialis*, *M. nasolabialis superficialis*, the medial part of *M. orbicularis oculi* and *M. retractor anguli oculi medialis profundus*, (2) the presence of *M. sphincter colli profundus pars cervicis*, (3) the pres-

ence of *M. mandibulo-labialis*, and (4) the fleshy insertion of *M. dilator nasi*. The third character is shared with lagomorphs and bathyergids, and fourth is shared with bathyergids and possibly with castorids. The first two characters are shared with no other rodents and with no lagomorphs. The present study of the facial muscles of *Sicista*, *Zapus*, and *Jaculus* agrees with Meinertz' findings on *Alactagulus* with regard to dissimilarity of dipodoids and hystricomorphs.

Dipodoids show the following myological similarities to muroids: (1) the undifferentiated condition of *M. cutaneus maximus*, (2) the morphology of the superficial facial muscles, (3) the presence of the genicular part of *M. adductor brevis*, (4) the lack of differentiation of *M. adductor magnus* into *M. adductor minimus* and *M. adductor magnus proprius*, (5) the separation of the tendons of *M. flexor digitorum tibialis*, *M. flexor digitorum fibularis*, and *M. tibialis posterior* at the medial malleolus, and (6) the separation of *M. femorococcygeus* from *M. biceps femoris* by the posterior femoral cutaneous nerve. The first of these is primitive and is not shared with geomyoids. No statement about primitiveness can be made for the fourth and sixth characters. The third is shared with *Dipodomys*, *Perognathus*, and *Aplodontia*, but not with squirrels. It is variable in geomyids. The fifth and sixth are shared with geomyoids, but not with squirrels. The fourth is not shared with *Aplodontia*, geomyoids, or the squirrels. The second requires extended comment.

Meinertz (1941*b*, 1944*a*) dissected a specimen of *Alactagulus* and recognized a strong similarity between the jerboa and the muroids he dissected. Further work on the facial muscles of muroids by Rinker (1954), and the results of the present study of *Sicista*, *Zapus*, and *Jaculus* affirm Meinertz' statements. In *Sicista* and *Zapus*, as in muroids, *M. sphincter colli profundus* forms a continuous sphincter around the head between the ear and eye. Relationships of the parts of *M. sphincter colli profundus* to the parts of *M. platysma myoides* are similar also. The greatest similarities appear in the rostral muscles associated with the nasal cartilage. These are complex in muroids and dipodoids and are unlike those found in any other rodents. *Partes maxillaris superficialis* and *maxillaris profunda* of *M. nasolabialis profundus* occur nowhere else among the Rodentia. Relationships of these muscles to *partes media superior* and *media inferior* of *M. nasolabialis profundus* and to *M. dilator nasi* are the same in muroids and dipodoids, including the jerboas. Comparison cannot be extended at the present time to the geomyoids. Meinertz (1941*b*) noted that Howell's (1932) and Hill's (1937) interpretations of the facial muscles of heteromyids and geomyids are certainly erroneous.

Dipodoids share some characters with the geomyoids to the exclusion of

the muroids: (1) the division of *M. rectus abdominis* into lateral and medial parts, (2) the union of the tendons of *M. flexor digitorum tibialis* and *M. flexor digitorum fibularis* in the sole of the foot, (3) the origin of a slip of *M. levator scapulae* from the transverse process of the atlas, and (4) the lack of division of *M. gracilis* into anterior and posterior parts. The second, third, and fourth of these are probably primitive; no statement about primitiveness can be made for the first.

Differences between dipodoids and muroids are included in the discussion of the masseter and the lists of the characters shared with hystricomorphs (*s.l.*), sciurids, and geomyoids. In every case of difference save one (the division of *M. rectus abdominis* into lateral and medial parts) the dipodoids have the probable primitive condition and the muroids the advanced. Dipodoids share several advanced conditions with the muroids, but few or none with other rodents to the exclusion of the muroids.

Many muscles have been omitted from the preceding discussion. Some of them seem to vary widely within superfamilies and are hence of little immediate use in investigating subordinal relationships. For others, adequate comparative data on other rodents are not available.

Different authors have proposed various theories on the relationships of dipodoids to other rodent superfamilies. These authors may be grouped for convenience in three schools.

One school, including Dobson (1882) and Parsons (1894), held that dipodoids are most closely related to hystricomorphs (*s.l.*). Parsons (1896) later changed his opinions on hystricomorph affinities. Increased knowledge of the paleontology and anatomy of dipodoids and hystricomorphs has not supported their earlier claims.

A second school is typified by Zittel (1893) and Miller and Gidley (1918). Zittel grouped the dipodoids along with the ischyromyids, pseudosciurids, theridomyids, gliroids, aplodontids, and pedetids in a provisional and indefinable suborder *Protrogomorpha*, which is not comparable to A. E. Wood's (1937) suborder of the same name. Miller and Gidley grouped the dipodoids with paramyids, graphiurids, aplodontids, cylindrodonts, pseudosciurids, mylagaulids, anomalurids, idiurids, sciuravids, ctenodactylids, and pedetids in an equally indefinable superfamily *Dipodoidea*. This superfamily, like Zittel's suborder, consisted mostly of forms that would not fit elsewhere in the classification.

A third school, exemplified by Winge (1887), Forsyth Major (1896), Thomas (1896), Tullberg (1899), M  hely (1913), Meinertz (1941*b*) and Wilson (1949*b*), thought that dipodoids are most closely related to muroids. Wilson (1949*b*, fig. 6) suggested that dipodoids and muroids evolved in the early Tertiary from a sciuravid stock, and that the geomyoids probably

evolved from sciuravids along a line separate from the dipodoid-muroid line. Wilson indicated that the gliroids might have evolved from a pre-sciuravid ancestry. Slightly different opinions were offered by Stehlin and Schaub (1951) and A. E. Wood (1959). Stehlin and Schaub grouped the dipodoids, muroids and gliroids as "Myomorpha," but denied any special relationship between dipodoids and muroids. Wood grouped dipodoids, geomyoids, and muroids, along with certain other rodents, in the sub-order Myomorpha because of supposed common derivation from the sciuravids, but implied no closer relationship between dipodoids and muroids than between dipodoids and geomyoids.

The myological data derived from the present study affirm the opinions of the workers listed as the third group. These data are consistent with the suggestion of Wilson and others that dipodoids and muroids are closely related and that they evolved from a common ancestor more recent than the common ancestor of dipodoids, muroids, geomyoids, and other Myomorpha.

LITERATURE CITED

- ALEZAIS, H.
1900 Contribution a la myologie des rongeurs. Thèses présentées a la faculté des sciences de Paris. Paris: Ancienne Librairie Germer Baillère et Cie. Pp. 395.
- APPLETON, A. B.
1928 The muscles and nerves of the post-axial region of the tetrapod thigh. Jour. Anat., 62:364-438.
- BASMAJIAN, J. V.
1962 Muscles alive, their functions revealed by electromyography. Baltimore: Williams and Wilkins Co. Pp. xi + 267.
- BRYANT, M. D.
1945 Phylogeny of Nearctic Sciuridae. Amer. Midl. Nat., 33:257-390.
- CHENG, C.
1955 The development of the shoulder region of the opossum, *Didelphys virginiana*, with special reference to the musculature. Jour. Morph., 97:415-71.
- DOBSON, G. E.
1882 On the natural position of the family Dipodidae. Proc. Zool. Soc. London, 640-41.
1883 On the homologies of the long flexor muscles of the feet of Mammalia, with remarks on the value of their leading modifications in classification. Jour. Anat. and Physiol., 17:142-79.
- DUCHENNE, G. B.
1959 Physiology of motion. Translated from the French by E. B. Kaplan. Philadelphia: Saunders Co. Pp. xxiii + 612.

- EISENBERG, J. F.
 1963 The behavior of heteromyid rodents. Univ. Calif. Publ. in Zoology, 69:iv + 100.
- ELLERMAN, J. R.
 1940 The families and genera of living rodents. Vol. I. Rodents other than Muridae. London: British Museum (Nat. Hist.). Pp. xxvi + 689.
- ENDERS, R. K.
 1934 The panniculus carnosus in an octodont rodent. Anat. Rec., 59:153-56.
- FRY, J. F.
 1961 Musculature and innervation of the pelvis and hind limb of the mountain beaver. Jour. Morph., 109:173-98.
- GREENE, E. C.
 1935 Anatomy of the rat. Trans. Amer. Phil. Soc., N. S., 27:xi + 370.
- HACKINGER, A.
 1959 Beobachtungen über die Fortbewegungsweisen der Wüstenspringmaus (*Jaculus jaculus* L.). Mitt. Biol. Stat. Wilhelminenberg, 2:56-7.
- HATT, R. T.
 1932 The vertebral columns of ricochetal rodents. Bull. Amer. Mus. Nat. Hist., 63:599-738.
- HILL, J. E.
 1934 The homology of the presemimembranosus muscle in some rodents. Anat. Rec., 59:311-13.
 1935 The retractor muscle of the pouch in the Geomyidae. Science, N. S., 81:160.
 1937 Morphology of the pocket gopher mammalian genus *Thomomys*. Univ. Calif. Publ. in Zoology, 42:81-172.
- HOWELL, A. B.
 1926 Anatomy of the woodrat. Baltimore: Williams and Wilkins Co. Pp. x + 225.
 1932 The saltatorial rodent *Dipodomys*: the functional and comparative anatomy of its muscular and osseous systems. Proc. Amer. Acad. Arts and Sciences, 67:377-536.
 1938 Morphogenesis of the architecture of hip and thigh. Jour. Morph., 62:177-218.
 1944 Speed in animals. Chicago: University of Chicago Press. Pp. xii + 270.
- HOWELL, A. B., AND W. L. STRAUS, JR.
 1933 The muscular system. In C. G. Hartman and W. L. Straus, Jr., The Anatomy of the Rhesus monkey. Baltimore: Williams and Wilkins Co. Pp. ix + 383. Reprinted with corrections by Hafner, New York, 1961.
- HUBER, E.
 1930 Evolution of facial musculature and cutaneous field of trigeminus. Quart. Rev. Biol., 5:133-88, 389-437.
 1931 Evolution of facial musculature and facial expression. Baltimore: Johns Hopkins University Press. Pp. xii + 184.
- KLINGENER, D.
 1963 Dental evolution of *Zapus*. Jour. Mamm., 44:248-60.

LANGWORTHY, O. R.

- 1925 A morphological study of the panniculus carnosus and its genetical relationship to the pectoral musculature in rodents. *Amer. Jour. Anat.*, 35:283-302.

LYON, M. W.

- 1901 A comparison of the osteology of the jerboas and jumping mice. *Proc. U. S. Natl. Mus.*, 23:659-68.

MAJOR, C. I. F.

- 1896 On the general results of a zoological expedition to Madagascar in 1894-96. *Proc. Zool. Soc. London*, Pp. 971-81.

MATTHEW, W. D., AND W. GRANGER

- 1923 Nine new rodents from the Oligocene of Mongolia. *Amer. Mus. Novitates*, No. 102:1-10.

MÉHELY, L. VON

- 1913 Die Streifenmäuse (Sicistinae) Europas. *Ann. Musei Natl. Hungarici*, 11:220-56.

MEINERTZ, T.

- 1932 Die Hautmuskulatur der Säugetiere. Untersuchungen über die Hautmuskulatur der Säugetiere mit besonderer Rücksicht auf das oberflächliche Facialisgebiet I. *Cavia cobaya*. *Morph. Jahrb.*, 69:110-220.
- 1935a Die Hautmuskulatur der Säugetiere. Untersuchungen über die Hautmuskulatur der Säugetiere mit besonderer Rücksicht auf das superfizielle Fazialisgebiet II. Das Kaninchen 1. *Cutaneus maximus*, *Sphincter colli superficialis* samt *Platysma* und seine Derivate beim Kaninchen. *Ibid.*, 75:15-61.
- 1935b Die Hautmuskulatur der Säugetiere. Untersuchungen über die Hautmuskulatur der Säugetiere mit besonderer Rücksicht auf das superfizielle Facialisgebiet II. Das Kaninchen 2. *Sphincter colli profundus* und seine Derivate beim Kaninchen. *Ibid.*, 75:1-51.
- 1936a Die Hautmuskulatur der Säugetiere. Untersuchungen über die Hautmuskulatur der Säugetiere mit besonderer Rücksicht auf das superfizielle Facialisgebiet. II. Das Kaninchen. 3. *Nervus facialis*. *Ibid.*, 77:124-78.
- 1936b Die Hautmuskulatur der Säugetiere. Untersuchungen über die Hautmuskulatur der Säugetiere mit besonderer Rücksicht auf das superfizielle Facialisgebiet. III. Der Hase mit dem Kaninchen verglichen. *Ibid.*, 77:400-18.
- 1941a The skin musculature of the Greenland lemming *Dicrostonyx groenlandicus* (Traill.). *Medd. om Grönland*, 131(3):1-77.
- 1941b Das oberflächliche Facialisgebiet der Nager. *Zool. Jahrb., Abt. für Anat. und Ontogenie der Tiere*, 67:119-270.
- 1942 Das superfizielle Fazialisgebiet der Nager. IV. Die Muriden. 1. *Epimys norvegicus* (Erxleben) und *Cricetus cricetus* (L.). *Morph. Jahrb.*, 87:254-324.
- 1943a Das superfizielle Fazialisgebiet der Nager IV. Die Muriden. 2. *Arvicola terrestris* (L.) und *Dicrostonyx groenlandicus* (Traill.). *Ibid.*, 88:397-467.
- 1943b Das superfizielle Facialisgebiet der Nager. VI. Die Sciuriden. 1. *Sciurus vulgaris* L. *Zeit. für Anat. und Entwicklungsgeschichte*, 112:105-35.
- 1943c Das superfizielle Facialisgebiet der Nager. VI. Die Sciuriden. 2. *Marmota marmota* (L.). *Ibid.*, 112:350-81.
- 1944a Das superfizielle Fazialisgebiet der Nager. V. Die Dipodiden. *Alactagulus pumilio* Kerr. *Morph. Jahrb.*, 89:313-70.

- 1944b Das superfizielle Facialisgebiet der Nager. VII. Die hystricomorphen Nager. Zeit. für Anat. und Entwicklungsgeschichte, 113:1-38.
- 1951 Das Fazialisgebiet der Nager. VIII. Bathyergini Winge, sowie einige Bemerkungen über *Pedetes caffer* (Pall.). Morph. Jahrb., 90:105-47.
- MILLER, G. S., JR., AND J. W. GIDLEY
- 1918 Synopsis of the supergeneric groups of rodents. Jour. Wash. Acad. Sci., 8:431-48.
- OGNEV, S. I.
- 1948 Mammals of the U.S.S.R. and adjacent territories (Mammals of Eastern Europe and northern Asia), Vol. VI (title translated). Moscow-Leningrad: Publ. House of the Academy of Sciences of the U.S.S.R. Pp. 559. (In Russian).
- PARSONS, F. G.
- 1894 On the myology of the sciuromorphic and hystricomorphic rodents. Proc. Zool. Soc. London, Pp. 251-96.
- 1896 Myology of rodents. II. An account of the myology of the myomorpha, together with a comparison of the muscles of the various suborders of the rodents. *Ibid.*, Pp. 159-92.
- PRIDY, R. B., AND A. F. BRODIE
- 1948 Facial musculature, nerves and blood vessels of the hamster in relation to the cheek pouch. Jour. Morph., 83:149-80.
- REIGHARD, J., AND H. S. JENNINGS
- 1901 Anatomy of the cat. Second edition. New York: Henry Holt and Co. Pp. xx + 498.
- RINKER, G. C.
- 1954 The comparative myology of the mammalian genera *Sigmodon*, *Oryzomys*, *Neotoma*, and *Peromyscus* (Cricetinae), with remarks on their intergeneric relationships. Misc. Publ. Mus. Zool. Univ. Mich., No. 83:1-124.
- 1963 A comparative myological study of three subgenera of *Peromyscus*. Occ. Pap. Mus. Zool. Univ. Mich., No. 632:1-18.
- RINKER, G. C., AND E. T. HOOPER
- 1950 Notes on the cranial musculature in two subgenera of *Reithrodontomys* (harvest mice). Occ. Pap. Mus. Zool. Univ. Mich., No. 528:1-11.
- SCHULTZ, A. H.
- 1924 Preparation and preservation of anatomical and embryological material in the field. Jour. Mamm., 5:16-24.
- SHARMA, D. R., AND S. SIVARAM
- 1959 On the hyoid region of the Indian gerbils. Mammalia, 23:149-67.
- SIMPSON, G. G.
- 1945 The principles of classification and a classification of mammals. Bull. Amer. Mus. Nat. Hist., 85:xvi + 350.
- SLIJPER, E. J.
- 1946 Comparative biologic-anatomical investigations on the vertebral column and spinal musculature of mammals. Verhandl. Koninkl. Nederl. Akad. Wetensch., Sec. 2, 42, No. 5:1-128.

- SPRAGUE, J. M.
1942 The hyoid apparatus of *Neotoma*. Jour. Mamm., 23:405-11.
- STEHLIN, H. G., AND S. SCHAUB
1951 Die Trigonodontie der simplicidentaten Nager. Schweiz. Paleontol. Abh., 67:1-385.
- STRAUS, W. L., JR.
1941 The phylogeny of the human forearm extensors. Human Biology, 13:23-50, 203-38.
- THOMAS, O.
1896 On the genera of rodents: an attempt to bring up to date the current arrangement of the order. Proc. Zool. Soc. London, Pp. 1012-28.
- TULLBERG, T.
1899 Ueber das System der Nagethiere, eine phylogenetische Studie. Nova Acta Reg. Soc. Upsaliensis, ser. 3, 18:v + 514 + A18.
- VINOGRADOV, B. S.
1937 Fauna of the U.S.S.R., N.S., No. 13. Mammals, Vol. 3, part 4. Jerboas. (title translated). Moscow-Leningrad: Publ. House of the Academy of Sciences of the U.S.S.R. Pp. viii + 196. (In Russian, with English summary).
- WILSON, R. W.
1949a Additional Eocene rodent material from southern California. Carnegie Inst. Wash. Publ., Contr. to Paleontol., 584, part I, Pp. 1-25.
1949b Early Tertiary rodents of North America. *Ibid.*, part IV, Pp. 67-164.
- WINGE, H.
1887 Jordfundne og nulevende Gnavere (Rodentia) fra Lagoa Santa, Minas Geraes, Brasilien. Museo Lunds, Copenhagen, vol. 1, No. 3:1-178.
- WOOD, A. E.
1937 Part II. Rodentia. In W. B. Scott and G. L. Jepsen, The mammalian fauna of the White River Oligocene. Trans. Amer. Phil. Soc., N.S., 28:155-269.
1949 A new Oligocene rodent genus from Patagonia. Amer. Mus. Novitates, No. 1435:1-54.
1955 A revised classification of the rodents. Jour. Mamm., 36:165-87. Note of correction, same volume, P. 588.
1959 Eocene radiation and phylogeny of the rodents. Evolution, 13:354-61.
- WOOD, J.
1867 On the human muscular variations and their relation to comparative anatomy. Jour. Anat. and Physiol., 1:44-59.
- ZITTEL, K. A.
1893 Handbuch der Palaeontologie. 1 Abt. Palaeozoologie. IV. Mammalia. Munich and Leipzig: R. Oldenbourg. Pp. xi + 799.

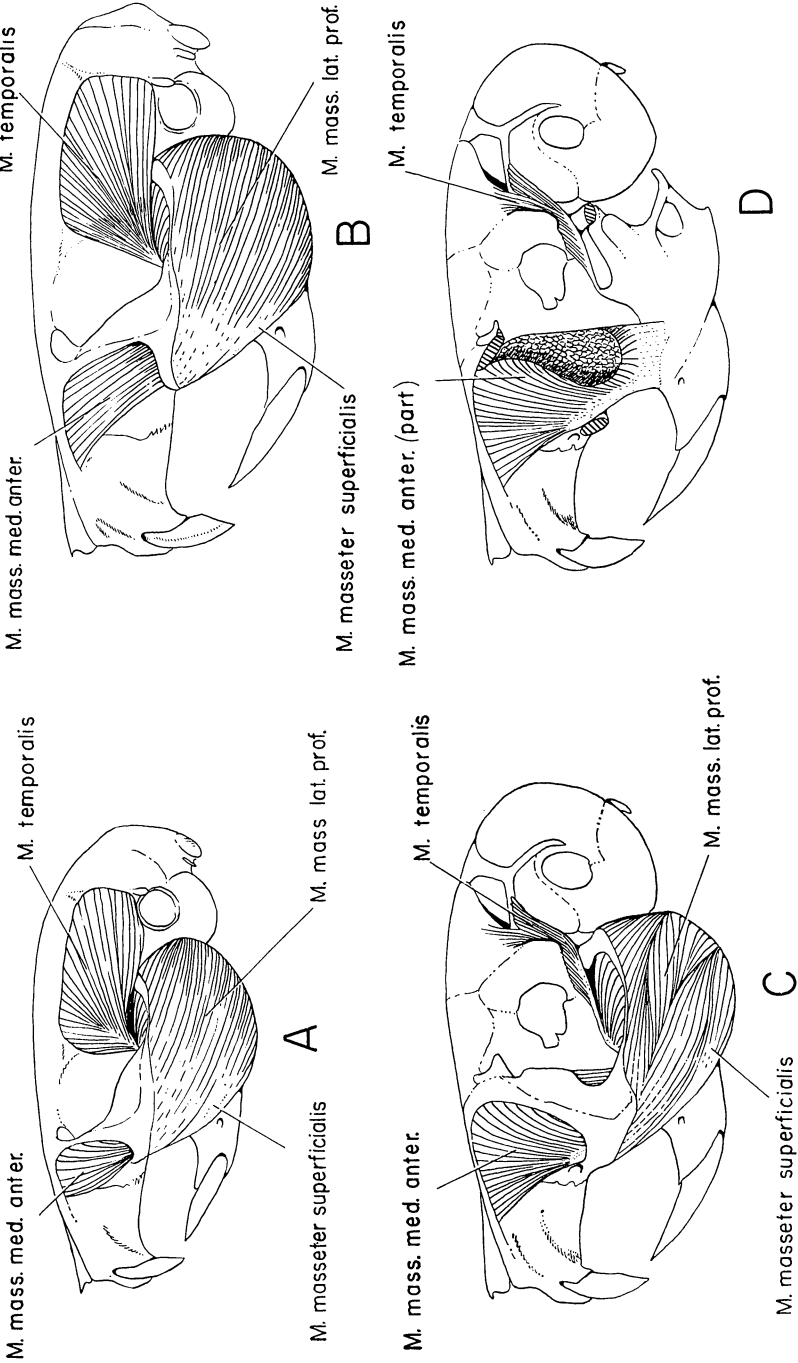


FIG. 1. Masticatory muscles of dipodoids: A, *Sicista*; B, *Zapus*; C, *Jaculus*, superficial muscles; D, *Jaculus*, deeper muscles.

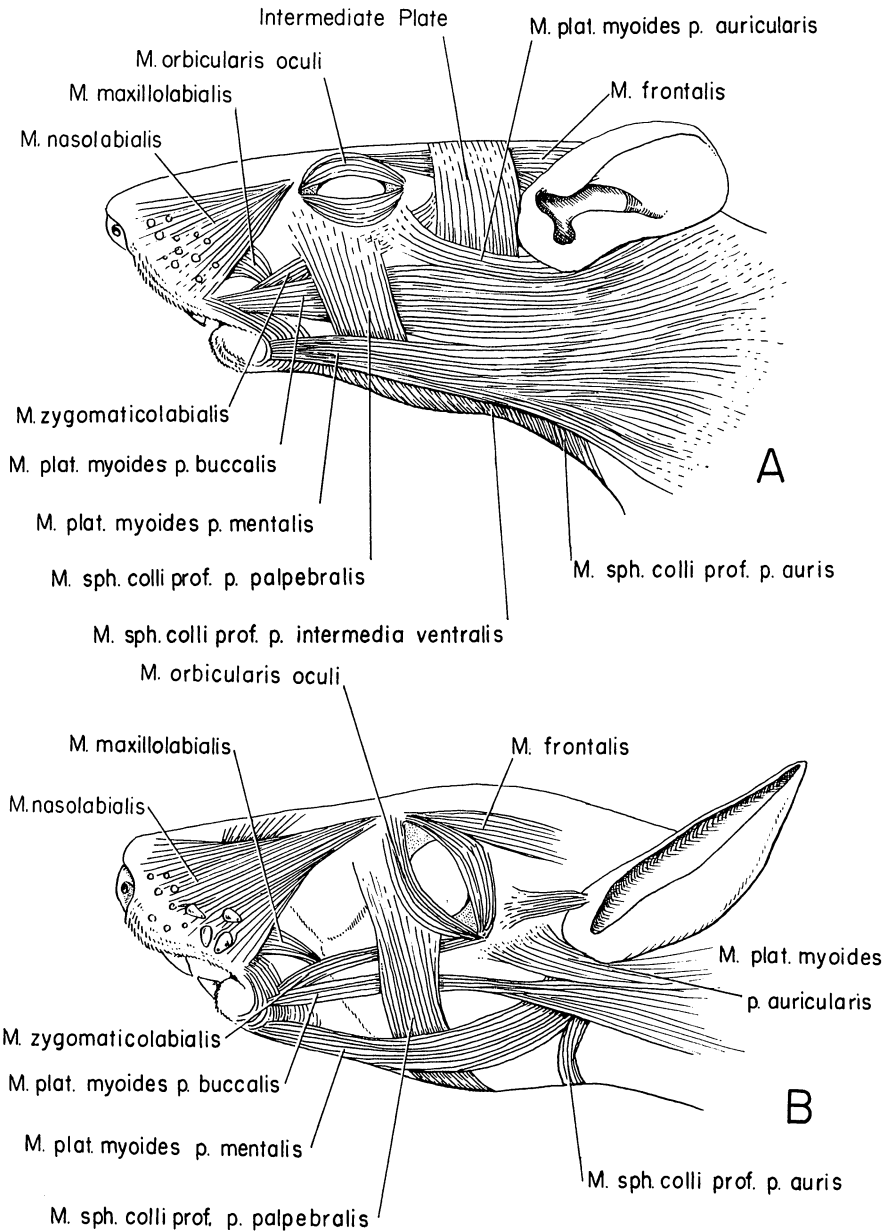


FIG. 2. Superficial facial muscles of dipodoids: A, *Sicista*; B, *Jaculus*.

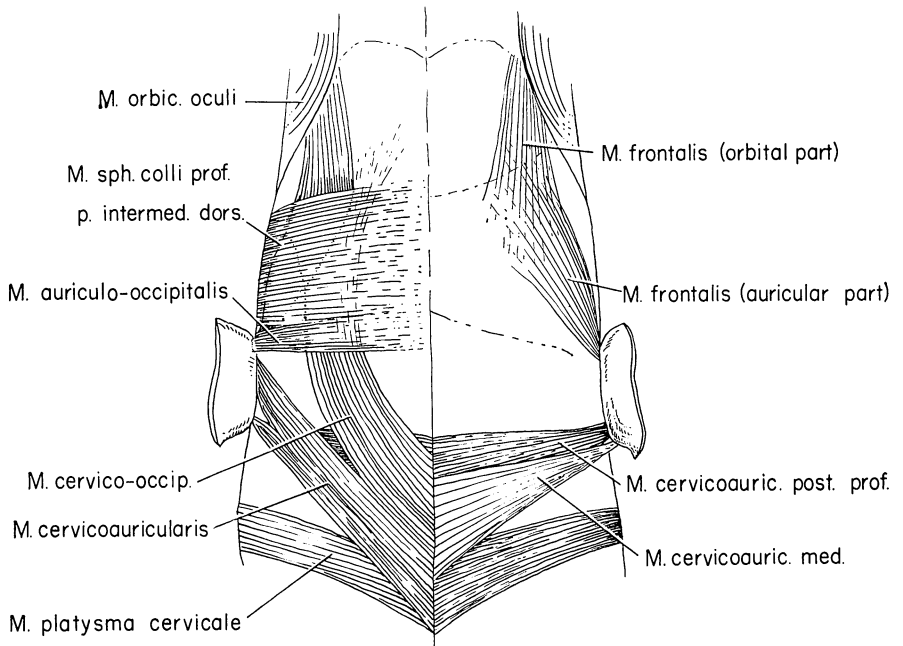


FIG. 3. Dorsal view of superficial facial muscles of *Zapus*; superficial muscles on left, deeper muscles on right.

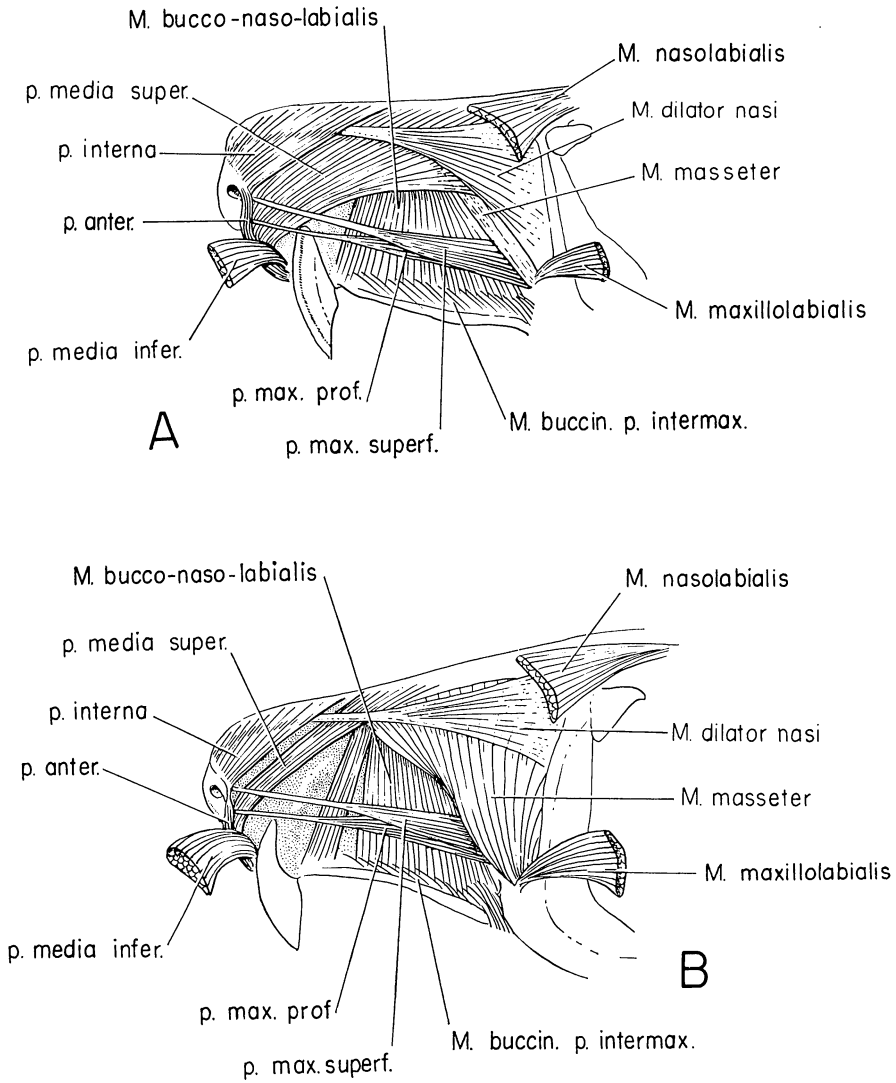


FIG. 4. Lateral views of the rostral muscles: A, *Zapus*; B, *Jaculus*.

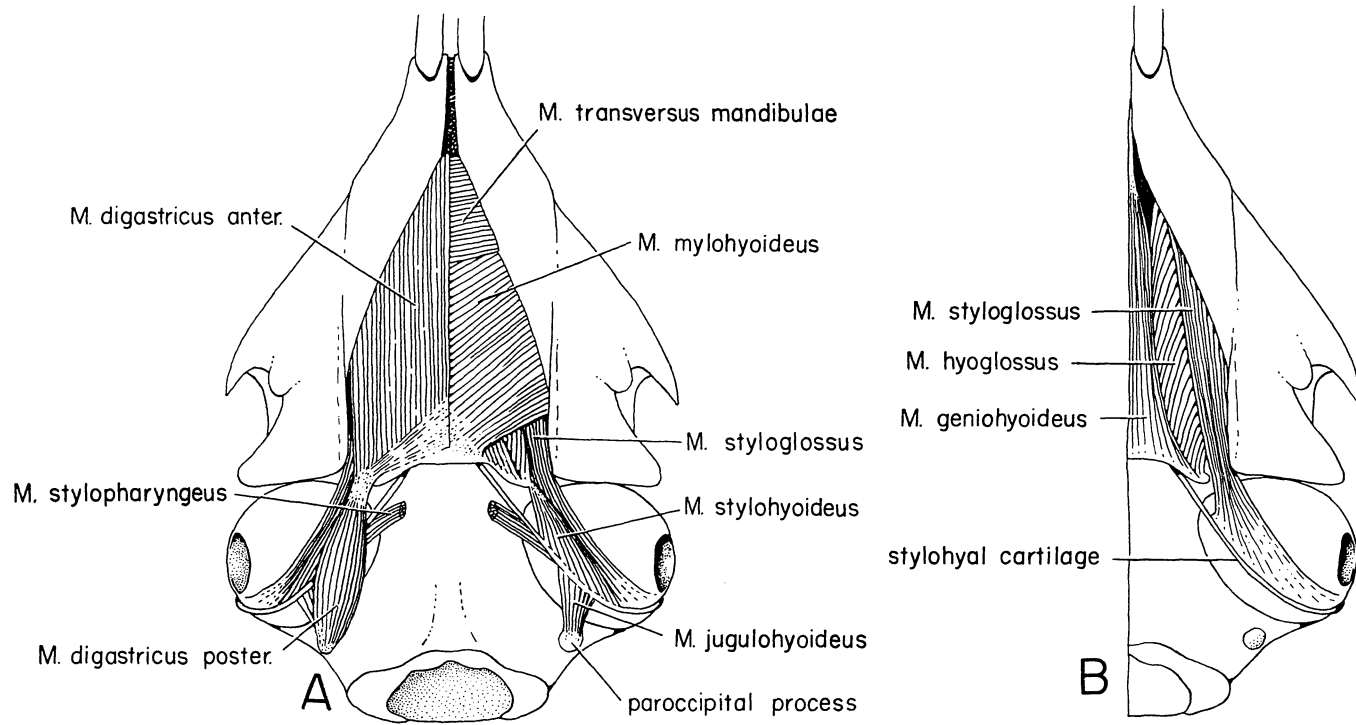


FIG. 5. Ventral views of muscles of the hyoid region in *Zapus*: A, superficial muscles on left, deeper muscles on right; B, deepest muscles.

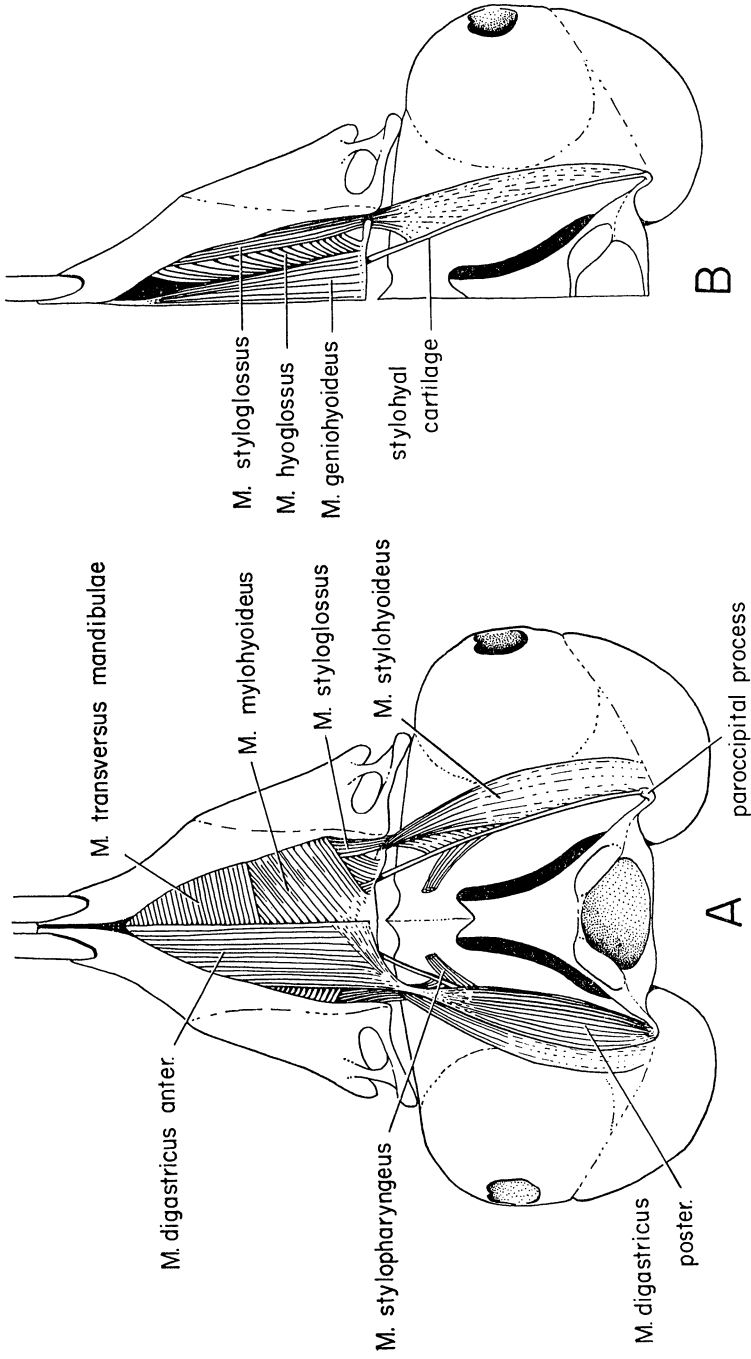


FIG. 6. Ventral views of muscles of the hyoid region in *Jaculus*: A, superficial muscles on left, deeper muscles on right; B, deeper muscles.

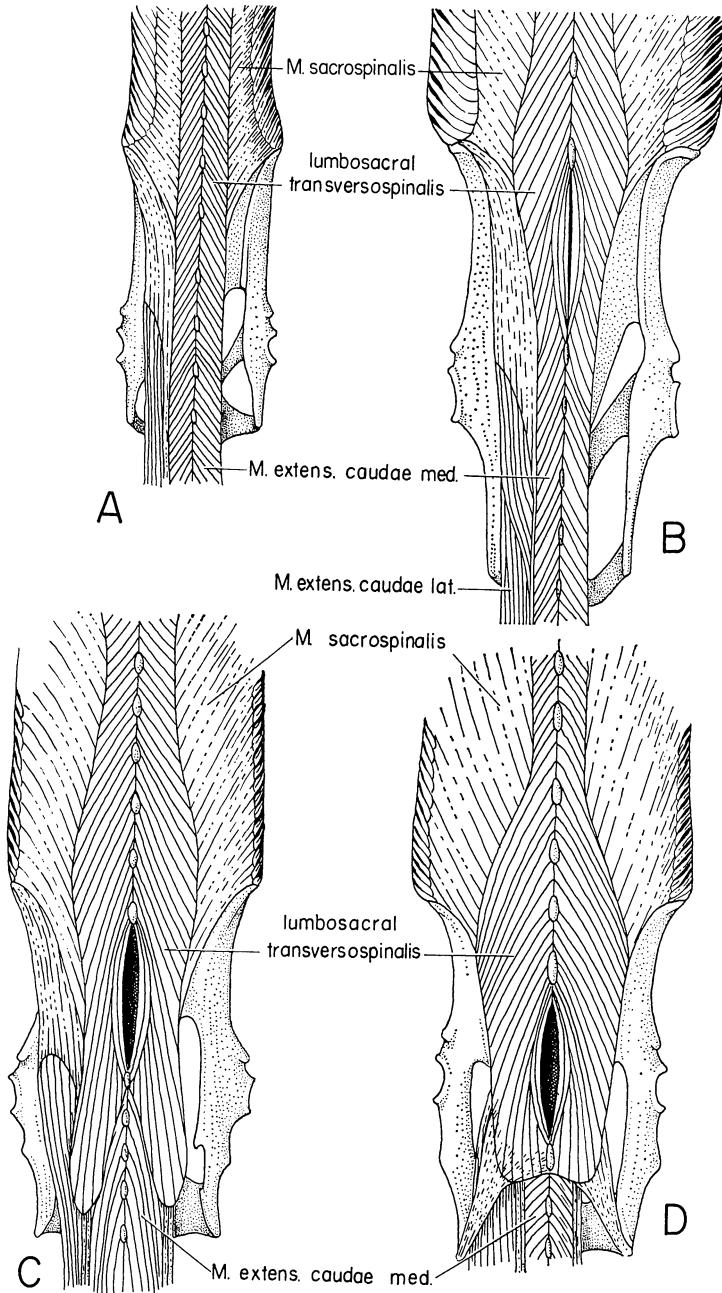


FIG. 7 Epaxial muscles of the lumbosacral region: A, *Sicista*; B, *Zapus*; C, *Dipodomys*; D, *Jaculus*.

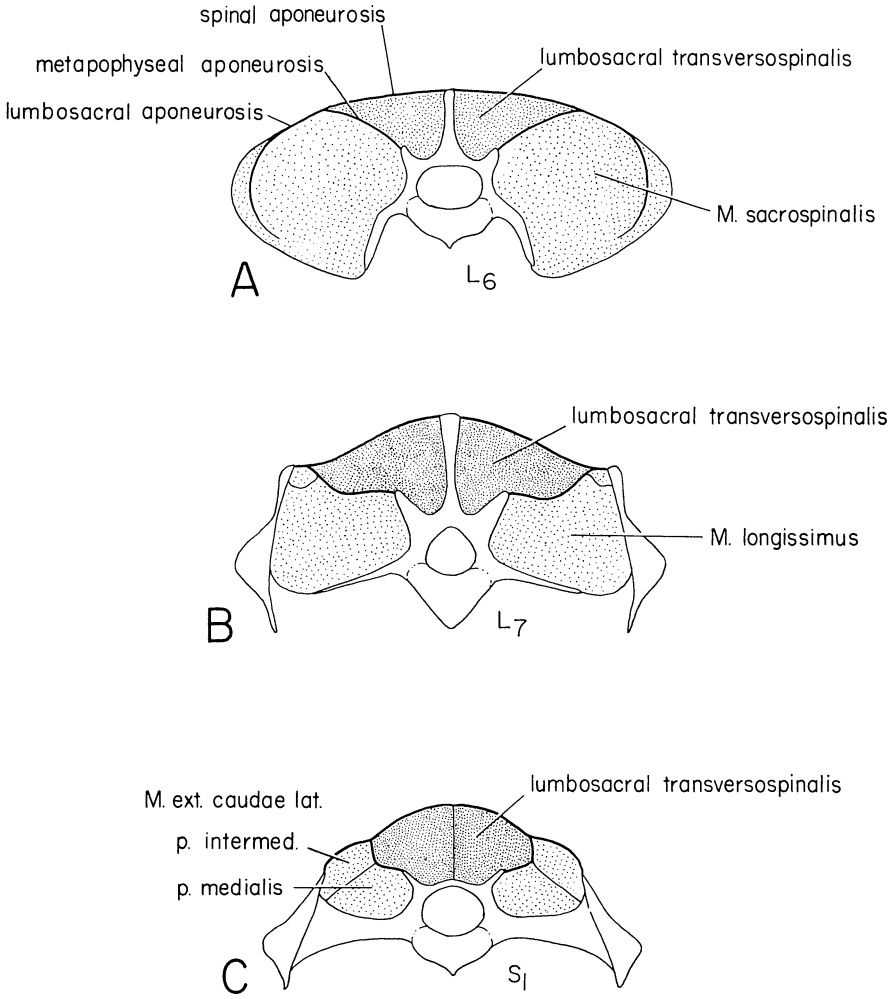


FIG. 8. Diagrammatic transverse sections through the trunk of *Zapus*, showing vertebral column and epaxial muscles. Levels are as follows: A, section through sixth lumbar vertebra; B, section through seventh lumbar vertebra; C, section through first sacral vertebra.

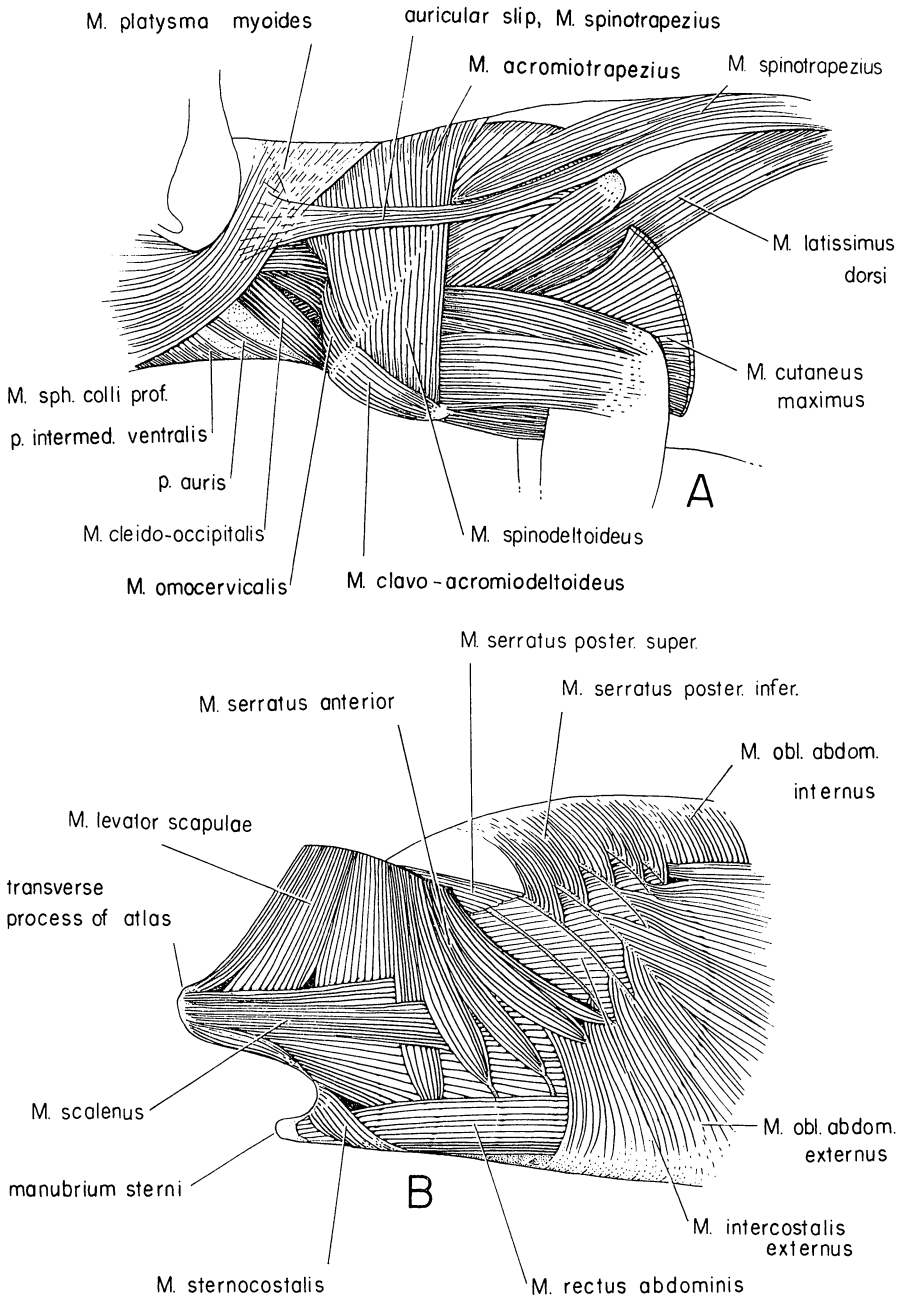


FIG. 9. Lateral views of anterior half of *Zapus*: A, superficial muscles of the pectoral limb; B, appendicular and axial muscles after removal of the scapula.

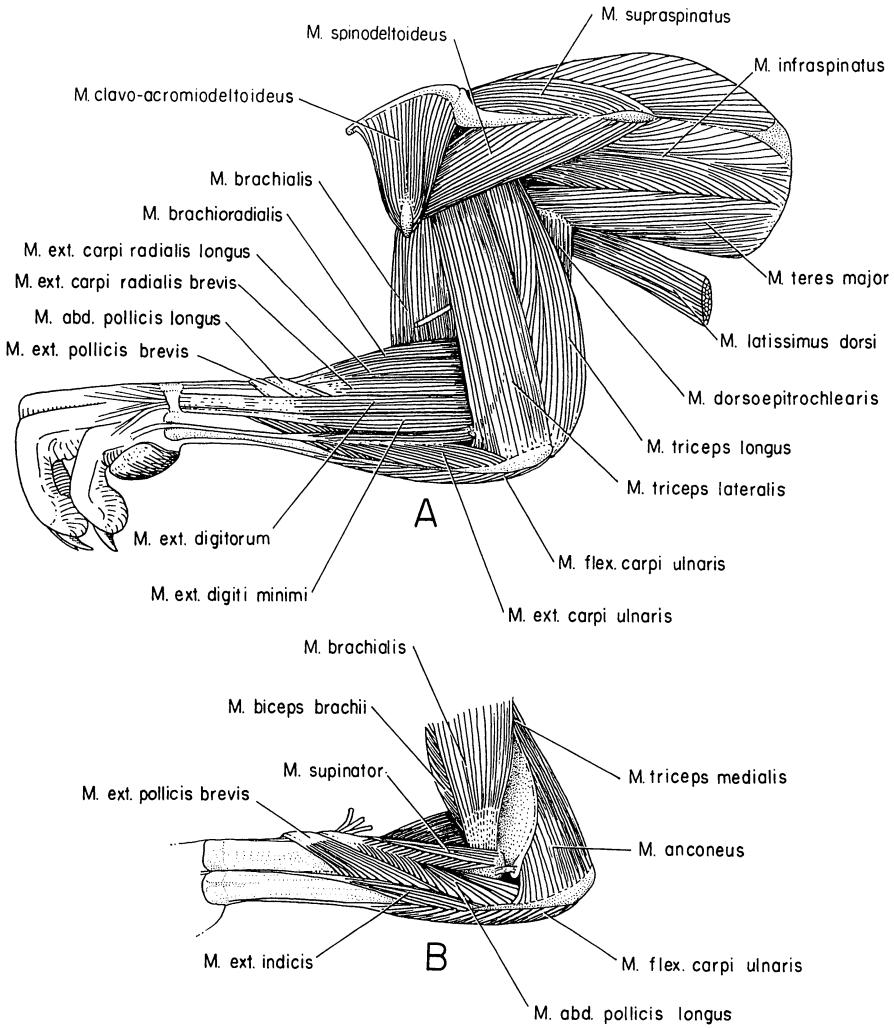


FIG. 10. Lateral views of the pectoral limb in *Zapus*: A, superficial muscles; B, deeper muscles.

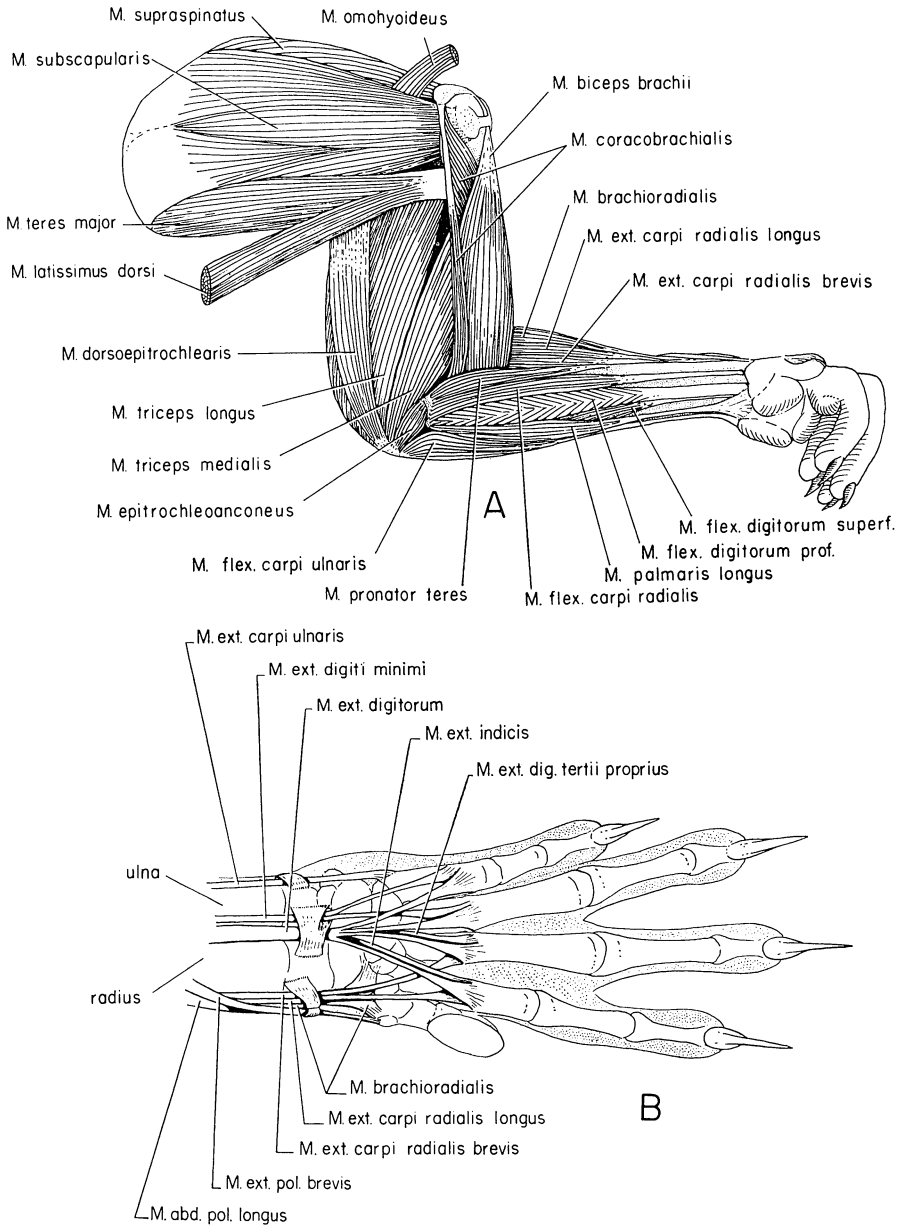


FIG. 11. A, medial view of muscles of the pectoral limb in *Zapus*; B, dorsal view of the wrist and hand in *Zapus*.

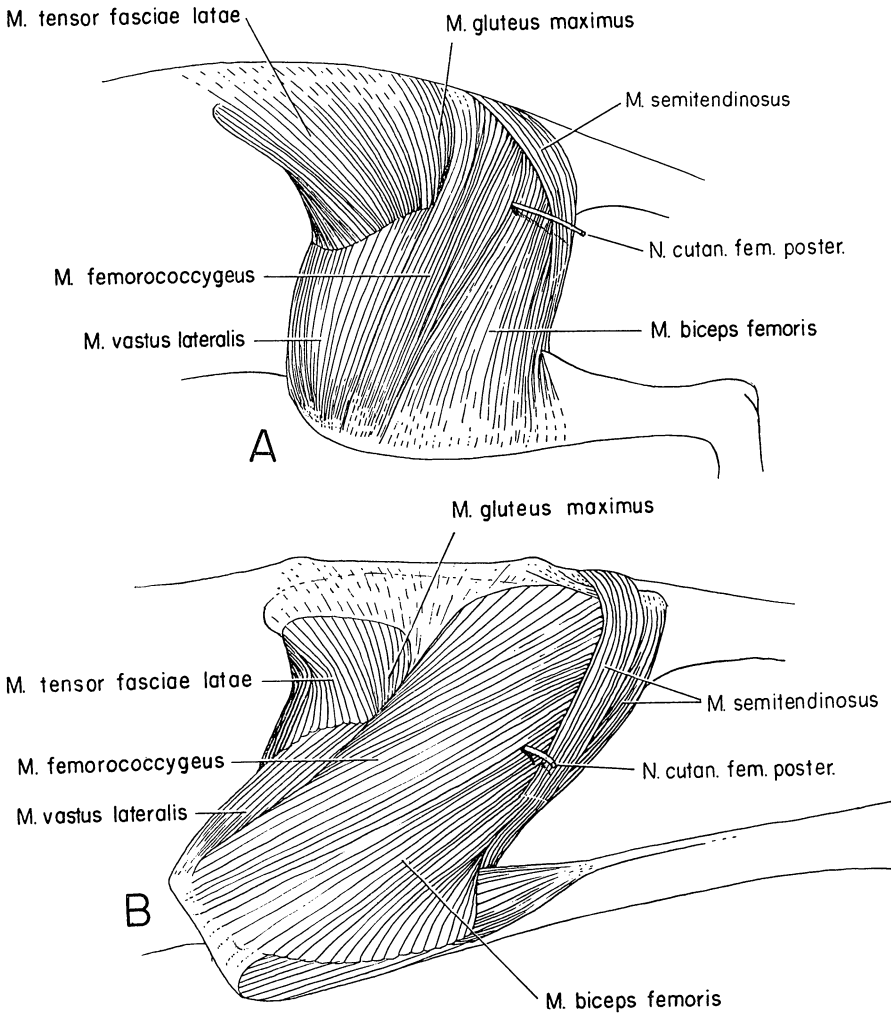


FIG. 12. Lateral views of superficial muscles of the pelvic limb: A, *Zapus*; B, *Jaculus*.

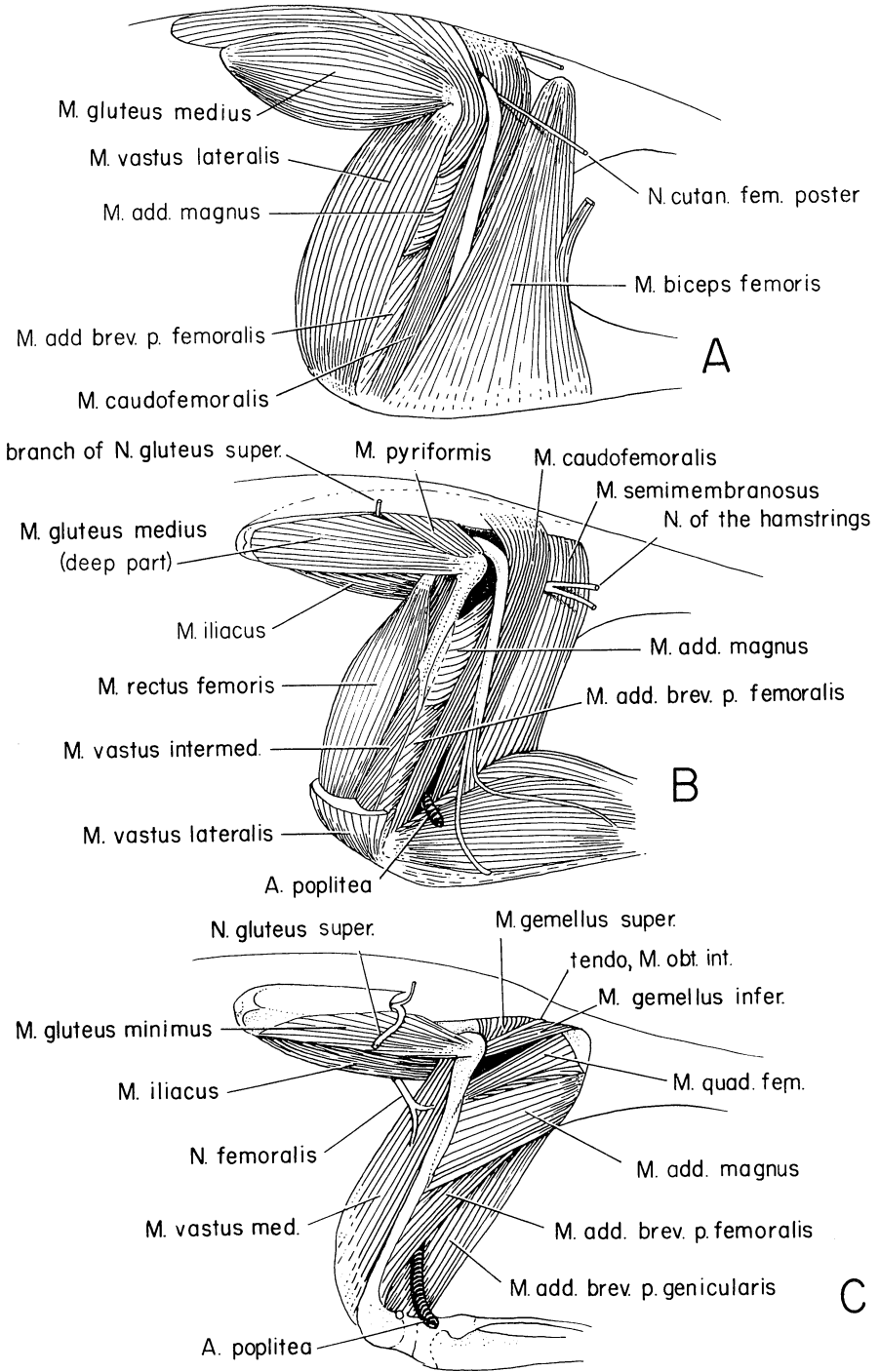


FIG. 13. Lateral views of deeper muscles of the pelvic limb of *Zapus*.

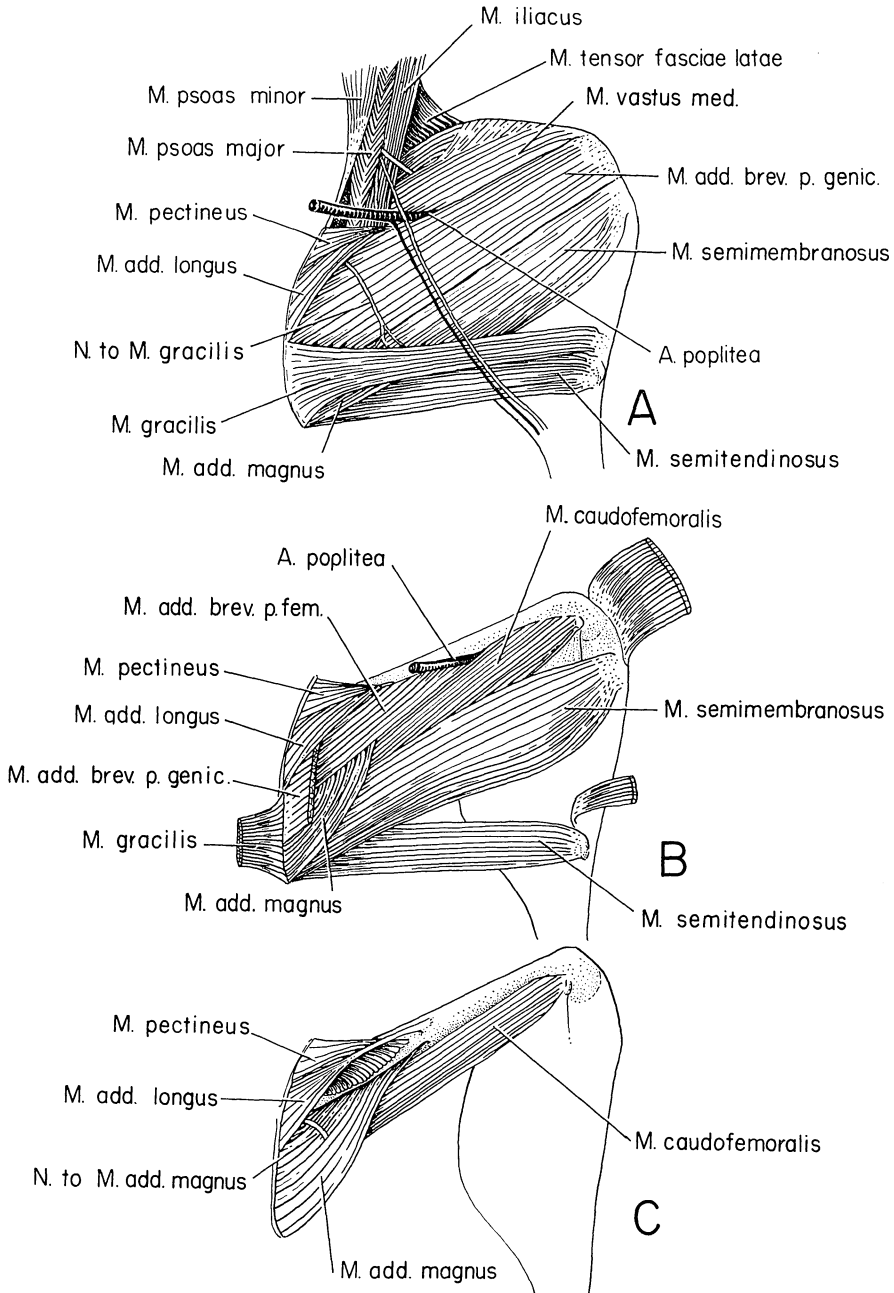


FIG. 14. Medial views of muscles of the thigh of *Zapus*.

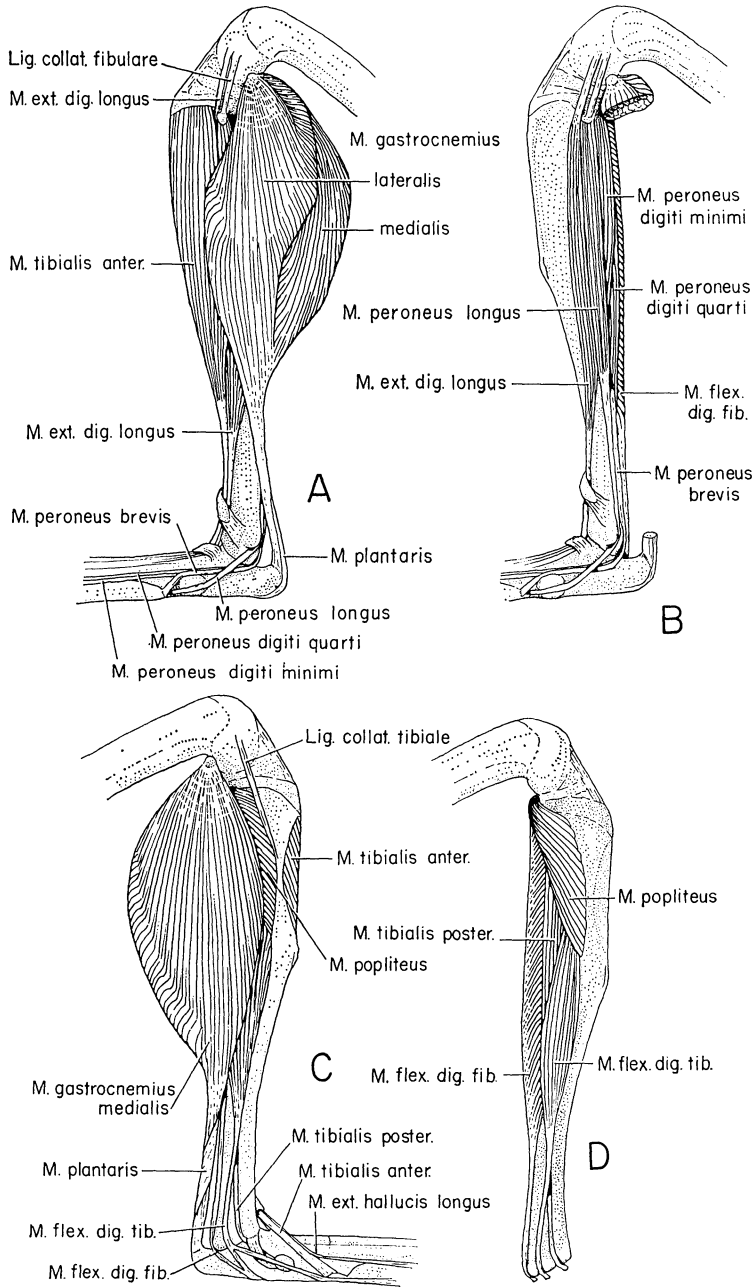


FIG. 15. Muscles of the leg of *Zapus*: A, lateral view of superficial muscles; B, lateral view of deeper muscles; C, medial view of superficial muscles; D, medial view of deeper muscles.

No. 79.	An analysis of some physical factors affecting the local distribution of the shorttail shrew (<i>Blarina brevicauda</i>) in the northern part of the Lower Peninsula of Michigan. By WILLIAM O. PRUITT, JR. (1953) 39 pp., 9 figs.	\$0.75
No. 80.	A comparative study of the osteology and myology of the cranial and cervical regions of the shrew, <i>Blarina brevicauda</i> , and the mole, <i>Scalopus aquaticus</i> . By GEORGE R. L. GAUGHRAN. (1954) 82 pp., 67 figs.	\$1.00
No. 82.	The meibomian glands of voles and lemmings (Microtinae). By WILBUR B. QUAY. (1954) 24 pp., 3 pls., 3 figs.	\$0.25
No. 83.	The comparative myology of the mammalian Genera <i>Sigmodon</i> , <i>Oryzomys</i> , <i>Neotoma</i> , and <i>Peromyscus</i> (Cricetinae), with remarks on their intergeneric relationships. By GEORGE C. RINKER. (1954) 124 pp., 18 figs.	\$1.50
No. 86.	The anatomy of the diastemal palate in microtine rodents. By WILBUR B. QUAY. (1954) 41 pp., 4 pls., 12 figs.	\$0.50
No. 95.	Survival rates, longevity, and population fluctuations in the white-footed mouse, <i>Peromyscus leucopus</i> , in southeastern Michigan. By DANA P. SNYDER. (1956) 33 pp., 3 figs.	\$0.50
No. 99.	Dental patterns in mice of the Genus <i>Peromyscus</i> . By EMMET T. HOOPER. (1957) 59 pp., 24 figs.	\$0.75
No. 103.	Life history and ecology of the chipmunk, <i>Eutamias amoenus</i> , in eastern Washington. By HAROLD E. BROADBOOKS. (1958) 48 pp., 3 pls., 6 figs.	\$0.95
No. 105.	The male phallus in mice of the Genus <i>Peromyscus</i> . By EMMET T. HOOPER. (1958) 24 pp., 14 pls., 1 fig.	\$1.15
No. 106.	The mammals of Iraq. By ROBERT T. HATT. (1959) 113 pp., 6 pls., 1 map	\$1.50
No. 109.	Microclimates and local distribution of small mammals on the George Reserve, Michigan. By WILLIAM O. PRUITT, JR. (1959) 27 pp., 6 figs.	\$0.60
No. 113.	Bacula of North American mammals. By WILLIAM HENRY BURT. (1960) 75 pp., 25 pls.	\$3.00
No. 117.	The mammals of El Salvador. By WILLIAM HENRY BURT AND RUBEN A. STIRTON. (1961) 69 pp., 2 figs.	\$1.60
No. 120.	A Synopsis of Recent North American microtine rodents. By EMMET T. HOOPER AND BARBARA S. HART. (1962) 68 pp., 11 figs.	\$1.30
No. 123.	The glans penis in Neotropical cricetines (Family Muridae) with comments on classification of muroid rodents. By EMMET T. HOOPER AND GUY G. MUSSER. (1964) 57 pp., 9 figs.	\$1.35
No. 124.	The comparative myology of four dipodoid rodents (Genera <i>Zapus</i> , <i>Napaeozapus</i> , <i>Sicista</i> , and <i>Jaculus</i>). By DAVID KLINGENER (1954) 100 pp., 15 figs.	\$1.85

