

Review

Update On Minimally Invasive Management of Ureteral Strictures

KHALED S. HAFEZ, M.D., and J. STUART WOLF, JR., M.D.

ABSTRACT

Purpose: To review the role of minimally invasive management in ureteral stricture disease.

Materials and Methods: A literature search was performed on the MEDLINE database through 2002 concerning endoscopic treatment of patients with ureteral strictures.

Results: Many endourologic methods are available for ureteral strictures. Ureteral dilation may be accomplished in most cases, with various rates of success depending on stricture etiology, location, and length. Endouretotomy also leads to long-term patency in properly selected cases and appears to be superior to dilation alone.

Conclusions: Significant advances in technique and technology have improved our ability to treat ureteral strictures without the need for open surgery in most patients.

HISTORY AND BACKGROUND

PAWLICK FIRST DESCRIBED ENDOSCOPIC URETERAL DILATION in 1891, when he used bougies to dilate strictures secondary to tuberculosis.¹ In 1907, Nitze² designed a catheter with a terminal inflatable balloon to dilate the ureter. In 1926, Dourmashkin^{3,4} reported dilation of the ureter with a series of rubber bags attached to hollow bougies. Ureteral dilatation up to 20F resulted in a stone expulsion rate of 68%. In 1978, Grüntzig⁵ described percutaneous transluminal coronary angioplasty using a dilating catheter with a 3.0- to 3.8-mm balloon at the tip; these balloons were later used to dilate ureteral strictures. The development of smaller ureteroscopes by Perez-Castro and Martinez-Pineiro⁶ led to a renewed interest in the endourologic treatment of ureteral strictures. With improved visual capabilities and smaller instrumentation came diagnostic and therapeutic upper tract endoscopy.

Treatment of ureteral strictures has changed dramatically as less invasive surgical techniques have been introduced. However, the widespread use of upper urinary tract endoscopy has also led to an increase in the incidence of iatrogenic ureteral strictures, as well as improvement in the ability to treat such strictures in a minimally invasive manner. While a variety of

open surgical techniques, including renal mobilization, psoas hitch, Boari flap, ureteroneocystostomy, transureteroureterostomy, intestinal interposition, renal autotransplantation and nephrectomy, can be used to treat patients with ureteral strictures, all involve major abdominal surgery with its associated morbidity, hospitalization, and long recovery.^{7,8}

Marshall in 1964⁹ described the use of fiberoptic endoscopy to examine the kidney and ureter. Others advanced the application of fiberoptics with the development of the flexible ureteroscope with deflecting tips to allow examination of the entire renal collecting system.^{10,11} Huffman and associates¹² demonstrated that endoscopes could be used in the upper urinary tract for therapeutic as well as diagnostic purposes. Karlin¹³ and Motola¹⁴ and their colleagues popularized endopyelotomy for the treatment of ureteropelvic junction (UPJ) obstruction. Initially, this technique was applied only to patients with secondary obstruction. Because patients in whom open pyeloplasty failed or who have acquired UPJ obstruction are similar in many respects to most patients with ureteral stricture, endourologic techniques that have been successful in the treatment of UPJ obstruction have been applied to stricture. We review these techniques and the outcomes that have been achieved with minimally invasive treatment of ureteral strictures.

ETIOLOGY AND PATHOGENESIS

Strictures of the upper urinary tract are either congenital or acquired. Congenital ureteral strictures are most commonly located at the UPJ. With the exception of primary UPJ obstruction, most ureteral strictures are acquired and usually are iatrogenic.¹⁵ The most common etiology of iatrogenic ureteral stricture disease is injury during endoscopic, open, or laparoscopic surgical procedures. The advent of ureteroscopic manipulation has led to a higher incidence of ureteral strictures.^{16,17} A 1% to 11% incidence of stricture formation has been reported after upper-tract endoscopy.^{16–22} Gynecologic procedures, most commonly radical hysterectomy, also carry a high risk of ureteral injury, and ureteral injury has been described during various general and vascular surgical procedures. Ureteroileal strictures arising after urinary diversion or kidney transplantation represent special types of lesions and are addressed separately. Non-iatrogenic acquired ureteral strictures include those that follow spontaneous passage of calculi or chronic inflammatory ureteral involvement, as in tuberculosis and schistosomiasis.^{23–26}

Benign strictures

Benign ureteral strictures can be ischemic or non-ischemic. Wolf and coworkers¹⁵ define a stricture as ischemic when it follows open surgery or radiation therapy, whereas the stricture is considered non-ischemic if it is secondary to stone passage or a congenital abnormality. Ischemic strictures tend to be associated with fibrosis and scar formation and thus are less likely to respond to endoureterotomy.^{15,27} Post-endoscopy strictures may be either ischemic or non-ischemic, depending on the mechanism of injury (i.e., mechanical or thermal trauma).^{28,29}

Malignant strictures

Ureteral strictures that are caused by recurrence of a primary malignancy or extrinsic mechanical compression by a tumor are a special subgroup of strictures that do poorly with endoscopic incision. They are best treated with open surgery, indwelling stents, or percutaneous nephrostomy tubes.

MANAGEMENT

Animal studies by Davis in the early 1940s provided the foundation for current endourologic management of ureteral stricture. In his description of the "intubated ureterotomy," Davis noted that a stented incision of the UPJ epithelialized completely in 1 week. Within 6 weeks, muscular regeneration had occurred.^{30,31}

The general consensus is that endourologic techniques for managing ureteral strictures do not achieve success rates comparable to those of open surgery, yet these minimally invasive approaches are often preferred because of their lower morbidity, reduced operative time, shorter hospitalization, and decreased cost compared with open reconstruction. Moreover, failure of a minimally invasive technique does not preclude a successful open operative repair.

Balloon dilation

Since the introduction of transluminal balloon dilation for coronary artery disease by Grüntzig in 1978,⁵ balloons have been used to dilate the ureter as an adjunct to ureteroscopy. Balloon dilation of the ureter involves four steps: (1) accessing the upper urinary tract; (2) placing the dilating balloon catheter; (3) inflating the balloon; and (4) inserting a ureteral stent. Fluoroscopy is essential to ensure appropriate positioning and inflation of the dilating balloon catheter.

Clayman et al³² studied the effects of rapid and slow balloon dilation of the distal ureter to 24F in the pig model and showed that such dilation of the ureter was safe. Slow dilation, over a 10-minute period, produced less residual inflammation at 6 weeks than did rapid dilation. However, the two groups of animals had similar epithelial denudation, inflammation, and submucosal hemorrhage immediately after the dilation. Selmy and associates³³ studied the effect of balloon dilation of the ureter on upper-tract dynamics and ureteral wall morphology in a pig model. One week after dilation, circumferential edema in the lamina propria and thinning of the muscularis propria were evident, and these findings correlated with obstructive urodynamic changes and reflux. Over a 6-week period, there was gradual resolution of the pathologic inflammatory changes and obstruction and return to radiographically normal ureters. On the basis of their observations, those authors favored a 6-week stenting period.

Several investigators have reported favorable results with balloon dilation of ureteral strictures. Success rates range from 48% to 88%, with an overall mean of 55%^{34–41} (Table 1). However, there appears to be no consensus among the practitioners of balloon dilation on the optimal balloon size and technique for the procedure. In the literature, balloon size ranges from 4 to 10 mm, the number of inflation cycles from 1 to 10, and the duration of inflation from 30 seconds to 10 minutes. There is likewise no agreement on the size of stents or duration of stenting following dilation: stent sizes range from 6F to 16F, and stenting duration ranges from 2 days to 12 weeks.

Overall, balloon dilation of benign ureteral strictures has lower reported success rates than endoureterotomy, often necessitating multiple procedures to achieve the desired outcome. Balloon dilation is probably best applied to very short, non-ischemic strictures. Otherwise, most urologists currently advocate an endoscopic incision as the initial management for most ureteral strictures.⁴²

Endoureterotomy

The development of the small rigid (7.5F) and flexible (6.9F) ureteroscopes and ancillary instruments has made viewing and manipulation of the ureter and upper urinary tract easier and safer. Cutting modalities for incision of a ureteral stricture include the cold knife, electrosurgical probes, and the Ho:YAG laser.

Antegrade Approach. A percutaneous antegrade approach is generally reserved for treatment of proximal or midureteral strictures in the presence of pathology in the kidney (e.g., renal stones). Antegrade endoureterotomy should be performed through an upper or middle posterior calyx to provide direct access to the stenotic segment with a semirigid instrument. A direct posterior or posterolateral incision of the stricture is car-

TABLE 1. BALLOON DILATION FOR BENIGN URETERAL STRICTURES

<i>Series</i>	<i>Stricture location</i>	<i>Success (%)</i>	<i>Follow-up (mos.)</i>
Banner et al ³⁴	Proximal (4)	N/A	N/A
	Mid (2)	N/A	
	Distal (18)	N/A	
	Total (24)	48	
Chang et al ³⁶	Proximal (2)	100	10
	Mid (2)	50	
	Distal (7)	71	
	Total (11)	82	
Johnson et al ³⁷	Prox/mid (13)	69	21
	Distal (11)	50	
	Total (24)	63	
Lang et al ³⁹	Total (127)	50	N/A
O'Brien et al ⁴¹	Proximal (3)	33	17
	Mid (5)	80	
	Distal (9)	56	
	Total (17)	60	
Beckman et al ³⁵	Prox/mid (5)	60	15
	Distal (12)	83	
	Total (17)	76	
Kramolowsky et al ²⁸	Proximal (3)	33	22
	Mid (2)	50	
	Distal (9)	78	
	Total (14)	64	
Netto et al ⁴⁰	Proximal (2)	50	24
	Mid (3)	67	
	Distal (14)	57	
	Total (19)	58	
Total	Proximal (14)	57	10–29
	Prox/mid (18)	67	
	Mid (14)	64	
	Distal (80)	53	
	Total (253)	67	

ried full thickness through the ureter until retroperitoneal fat is seen. The caudal extent of the incision should be 1 cm beyond the area of the stricture, and the cephalad portion of the incision extends into the renal pelvis.

Midureteral strictures may be approached in an antegrade or a retrograde fashion. The antegrade approach is identical to an antegrade endopyelotomy except that the cephalad extent of the incision travels 1 cm proximal into normal ureter rather than entering the UPJ. For a midureteral stricture above the iliac vessels, flexible ureteroscopy is recommended. The flexible ureteroscope necessitates the use of 2F or 3F electrosurgical or $\leq 400\text{-}\mu\text{m}$ Ho:YAG laser probe. Periureteral damage from use of electrosurgical devices with a $>400\text{-}\mu\text{m}$ tip is similar to a cold-knife incision.⁴³ Using visual orientation in combination with fluoroscopy in two planes, a full-thickness incision is made laterally for proximal ureteral strictures above the iliac crossing, anteriorly for strictures in the midureter overlying the iliac

vessels, or anteromedially for strictures below the iliac vessels. Retroperitoneal or periureteral fat should be exposed by the incision, which extends 1 cm proximal and 1 cm distal to the stricture. If the stricture is particularly tight, preliminary balloon dilation may be required to provide adequate access to the entire extent of the stricture. Although dilation may create a linear tear in the stricture, usually, this tear occurs at the desired site in the ureter.

Retrograde Approach. The choice of a retrograde rather than an antegrade approach to manage a ureteral stricture is tailored to the individual patient and the surgeon's preference. However, decreased morbidity and hospitalization and the ease with which the upper urinary tract can be accessed with available ureteroscopic equipment make the retrograde approach the route of choice for endoureterotomy for most patients with ureteral strictures.

The retrograde approach is used most commonly for distal

ureteral strictures. Such strictures usually occur at the ureteral orifice, the intramural ureter, or just at or slightly proximal to the ureterovesical junction. These strictures are incised such that the lower extent of the incision extends through the ureteral orifice.⁴⁴ A right-angle Orandi or Collings electrocautery knife attachment is fitted into the resectoscope sheath. Using 50 W of pure cutting current, the surgeon initiates the incision at the 12 o'clock position at the ureteral orifice and extends it cephalad through the ureteral tunnel for a distance of 1 cm cephalad to the area of stricture. For more proximal strictures, a flexible (in some cases, a rigid) ureteroscope can be used as described above (Fig. 1).

The Acucise cutting balloon also has been used in the management of proximal and distal ureteral strictures.⁵¹ The balloon is positioned across the stricture under fluoroscopic control. In the proximal ureter above the iliac vessels, the cutting wire is oriented posterolaterally, whereas below the iliac vessels, the wire is directed anteromedially to avoid the branches of the internal iliac artery and vein, which course lateral to the ureter. Strictures lying directly over the iliac vessels should not be treated with the cutting balloon device and are better approached using direct ureteroscopic viewing.

Combined Antegrade and Retrograde Approach. For complex ureteral strictures, especially those located at ureteroenteric anastomoses, a combined antegrade/retrograde approach affords optimal access to the stenotic site. Through-and-through access enables the rapid identification of the stenotic area that is usually hidden between mucosal folds of the diversion and is often difficult to identify when approached exclusively from below.

A more challenging problem is complete ureteral obstruction. The extent of the stricture can be estimated through a simultaneous antegrade nephrostogram and retrograde ureterogram. In these cases, the flexible ureteroscope can be passed with the patient positioned prone, and a "cut-to-the-light" procedure can be done. A short (<1-cm) occlusion may be approached endoscopically. Bagley⁴⁶ and Conlin and Bagley⁴⁷ have reported recanalization of complete ureteral obstructions up to 5 cm in length. However, in general, ureteral occlusions >2 cm are managed more successfully with an open surgical procedure.

Types of cutting devices

Cold Knife. A cold-knife incision necessitates the use of a rigid ureteroscope. Knife blades are available in variety of configurations, including straight, half-moon, and hook. Because of the size of the ureteroresectoscope, cold-knife incision is generally limited to the distal ureter via a retrograde approach. If the stricture is located in the proximal ureter, the incision can be performed through a nephroscope with an antegrade approach. For optimal control under direct endoscopic vision, knife blades can be mounted over a guidewire running through the resectoscope.⁴⁷

Electrocautery. Electroincision is usually achieved with 2F or 3F electrodes, which are available in a variety of configurations. An advantage of electroincision over cold-knife incision is that the small-caliber probes can be placed through small semirigid and flexible ureteroscopes, thereby enabling the incision to be made anywhere along the course of the ureter.⁴⁷

The issue of electrocautery damage to the tissue is addressed below.

Lasers. The primary advantage of laser endoureterotomy is the small caliber and flexibility of fibers. Available lasers include the Nd:YAG (neodymium:yttrium-aluminum-garnet), the semiconductor diode with contact fibers, the KTP Nd:YAG (potassium titanyl-phosphate Nd:YAG), and the Ho:YAG. The Ho:YAG laser provides the finest, most precise incision that provokes the least peripheral damage. Although these lasers are equally effective in incising strictures, only the Ho:YAG additionally permits stone fragmentation. This laser therefore appears to be the most versatile for endourologic purposes. The preferred power setting for laser endoureterotomy is 10 W.^{48,49}

Acucise device. The Acucise cutting balloon catheter, which incorporates both a monopolar electrocautery cutting wire and a low-pressure balloon,^{50,51} has been used for the management of proximal and distal ureteral strictures.⁵¹ The device has radiopaque markers on the catheter body that assist in determining the position of the balloon and the cutting wire; therefore, fluoroscopy is necessary for proper spatial placement of the cutting wire within the ureter. The device is passed to the strictured segment over a working guidewire in either a retrograde or an antegrade fashion.⁵² The balloon not only defines the area of stenosis but also carries the cutting wire into the strictured area. The electrically active surface on the cutting wire measures 2.8 cm in length and 150 μm in diameter. The wire should be activated for 5 seconds at 75 W of pure cutting current.

RESULTS OF ENDOURETEROTOMY

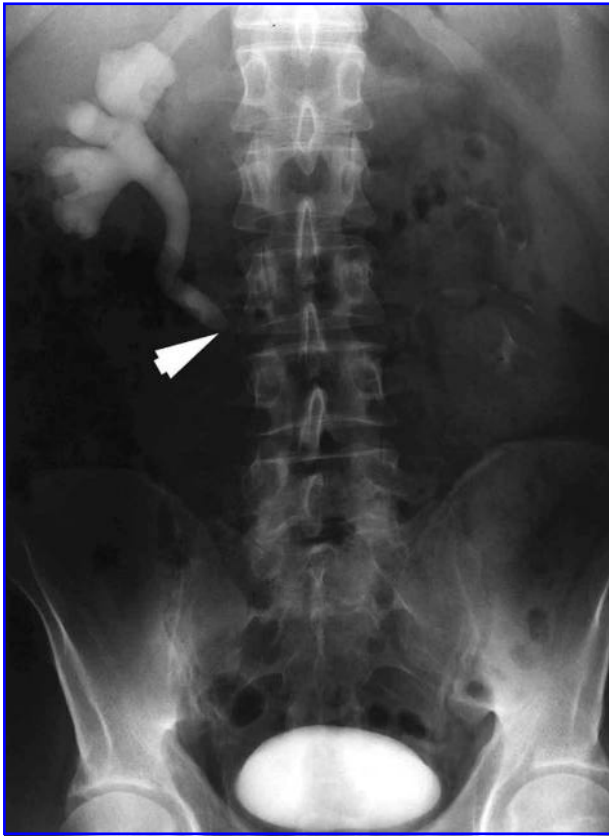Endoureterotomy success rates range from 55% to 85% for benign ureteral strictures^{44,53} (Table 2). However, comparisons between series are problematic because of the variability in cutting modalities, length of follow-up, etiology, stricture location and length, and stent size and duration of stenting.

Endoureterotomy for middle and distal ureteral strictures is associated with success rates ranging from 66% to 88%. The overall success rate for 156 patients in combined series was 78%, which is better than the overall 67% success rate reported for balloon dilation.^{15,48,51-56}

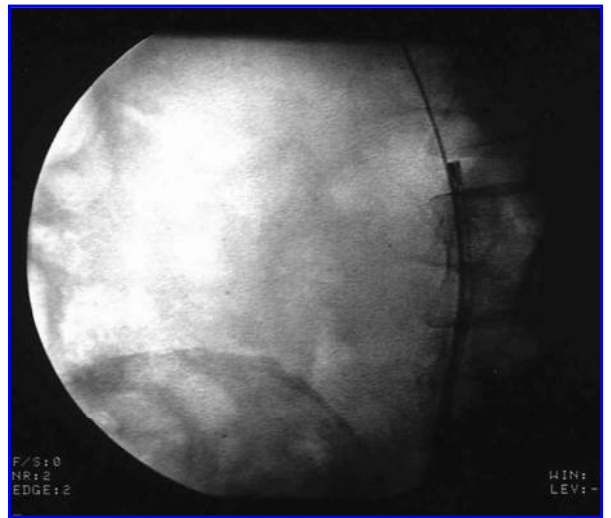
One series of 21 endoureterotomies in 19 patients had a mean follow-up of 18 months. The strictures were either primary or secondary to previous surgery, urolithiasis, or endometriosis, and the mean stricture length was 3.4 cm. Strictures were located in the proximal ureter in five cases, in the midureter in six, and in the distal ureter in 12. The endoureterotomy was performed with a cold knife after balloon dilation of the narrowed segment. A 12F ureteral stent was left postoperatively in all patients for 28 to 54 days (mean 46 days). An overall success rate of 85% was achieved.

Preminger and colleagues⁵⁴ reported the results of a multicenter trial involving the use of the Acucise balloon catheter for the management of 40 ureteral and 9 ureteroenteric strictures. A 7F/14F endopyelotomy stent was used in 57% of the endoureterotomy patients. The mean duration of stenting was 5 weeks, and patients were followed for an average of 8.7 months (range 1.2-17 months). Acucise incision of the distal ureter had a success rate of 58%, while incision of the proximal and midureter was associated with success rates of 50%

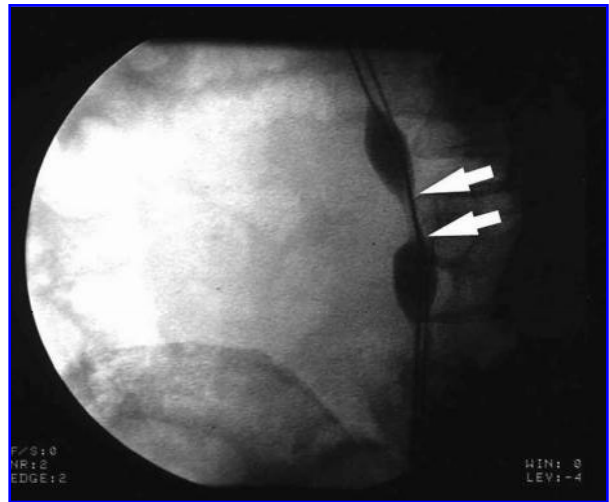
A



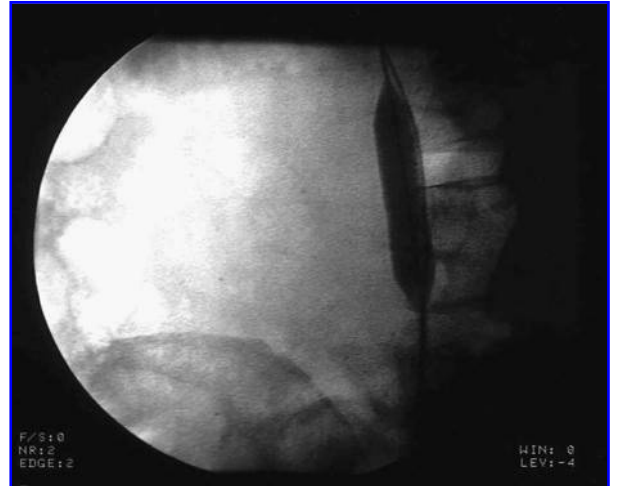C



B



D



E

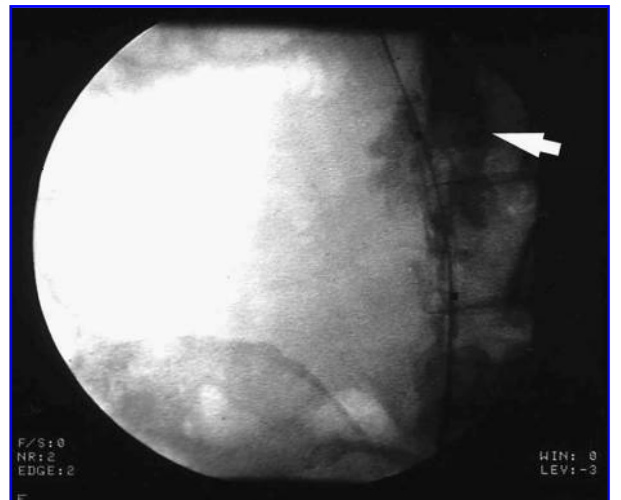


FIG. 1. Retrograde approach to proximal stricture. (A) Intravenous urogram demonstrating high-grade proximal right ureteral stricture (white arrowhead). (B) Prior to retrograde ureteroscopic incision, stricture (arrowheads) is defined with low-pressure inflation of ureteral dilating balloon. (C) Ureteroscope proximal to stricture following incision laterally. (D) A 10-mm balloon fully inflated at stricture site. (E) Contrast material injected through distal balloon port after deflation of balloon reveals desired extravasation (arrowhead).

TABLE 2. ENDOURETEROTOMY FOR BENIGN URETERAL STRICTURES

<i>Series</i>	<i>Stricture location</i>	<i>Success (%)</i>	<i>Follow-up (mos.)</i>
Lopatkin et al ¹⁰¹	Proximal (3)	67	22
	Mid (0)	N/A	
	Distal (4)	100	
	Total (7)	86	
Eshghi et al ¹⁰²	Total (20)	88	N/A
Schneider et al ⁵⁶	Proximal (0)	N/A	15
	Mid (0)	N/A	
	Distal (12)	83	
	Total (12)	83	
Chandhoke et al ⁵¹	Prox/mid (3)	67	4
	Distal (5)	80	
	Total (8)	75	
Cohen et al ⁵²	Proximal (3)	67	29
	Mid (0)	N/A	
	Distal (5)	80	
	Total (8)	75	
Preminger et al ⁵⁴	Total (40)	71	9
Wolf et al ¹⁵	Proximal (4)	75	28
	Mid (5)	100	
	Distal (29)	78	
	Total (38)	82	
Singal et al ⁴⁸	Prox/mid (2)	50	11
	Distal (10)	70	
	Total (12)	67	
Total	Proximal (10)	70	4–29
	Prox/mid (5)	60	
	Middle (7)	86	
	Distal (65)	78	
	Total (145)	78	

each. The overall success rate for Acucise incision of benign ureteral strictures was 55%.

The largest reported series of endoureterotomies included 38 benign ureteral and 30 benign ureteroenteric strictures in renal units with >25% of total renal function. Various cutting modalities were employed. The median follow-up for the ureteral strictures was 28.4 months, and all failures occurred within 11 months of the procedure, with a 3-year success rate of 80%.¹⁵

FACTORS DETERMINING OUTCOME

Several studies have suggested that superior results are achieved when endoureterotomy is applied to strictures in the terminal portions of the ureter (i.e., distal or proximal), in non-ischemic strictures, and in short strictures. Ipsilateral renal func-

tion has also been identified as an important predictor of outcome.^{27,28,40,53,57–60}

Stricture location

Endoureterotomy for proximal and distal ureteral strictures has a higher success rate than that for midureteral strictures.^{53,59} Opening the stricture widely by marsupialization into a larger cavity such as the renal pelvis or bladder may account for this finding. Some authors have proposed that distal reflux after stricture marsupialization into the bladder could provide additional distention of the incised ureter that could contribute to the higher success rates.⁵³

Smith⁵⁸ found that in a series of 28 patients with ureteral stricture disease, all 4 patients with a midureteral stricture failed balloon dilation. Similarly, Meretyk and coworkers⁵³ noted a

25% success rate for endourologic incision of midureteral strictures compared with 80% for distal strictures. Likewise, proximal ureteral strictures, specifically secondary UPJ obstructions, respond well (i.e., 80%) to an endoincision.

Stricture type

The cause of the ureteral stricture also has a significant impact on the success of the procedure. The most common cause (23%) of ureteral stricture in one series was postoperative fibrosis following open pelvic surgery or ureteroscopy procedures.⁵³ These relatively nonischemic lesions respond better to endoscopic treatments than do poorly vascularized strictures.^{34,36,39,40,53}

Ureteral strictures secondary to radiation therapy or resulting from extraluminal metastatic malignancies causing periureteral compression respond poorly to endoureterotomy.⁴⁰ In contrast, patients with a concomitant ureteral stone and an apparent stricture usually have resolution of the stricture following removal of the stone and alleviation of the inflammatory response to it.

Stricture length

Several investigators have noted that long ureteral strictures tend to be associated with poorer success rates despite the use of balloon dilation or endoincision. Beckmann et al³⁵ reported that in 25 patients with strictures <2 cm, balloon dilation was successful in 84%. Conversely, among patients with strictures >2 cm, dilation succeeded in only 50%. Chang and colleagues³⁶ and Netto and coworkers⁴⁰ independently concluded that strictures >1 cm rarely respond well to balloon dilation. The same observation has been noted in the literature for incision of ureteral strictures. Meretyk and associates⁵³ found that the best results with endoureterotomy were in those patients with strictures <2 cm. Schneider et al⁵⁶ reported that the longest stricture they treated by cold knife incision was 2.5 cm, and this patient had reobstruction 24 hours after removal of the ureteral stent. Therefore, it would appear appropriate to apply endosurgical management only to strictures <2 cm.

Stricture duration

Contrary to earlier reports, it now appears that the duration of a ureteral stricture before treatment has no significant effect on the success of therapy. When the factors of stricture length, location, and type are controlled, the duration of the stricture does not alter the outcome. Successful endosurgical therapy has been reported in strictures with durations ranging from 8 weeks to 18 months.⁴⁰

Renal function

The function of the affected renal unit is an important predictor of success. Patients with renal units contributing <25% of overall function are more likely to fail endoureterotomy. The explanation lies in the fact that low urine flow through the ureter may prevent the incised area from remaining patent. Moreover, a poorly functioning kidney may produce lesser amounts of epidermal growth factors. Production of various growth factors appears to correlate well with the glomerular filtration rate, irrespective of the cause of decreased renal function. Thus, poor

stricture healing may be caused by lack of sufficient mitogenic stimulation.⁶¹

CONTROVERSIAL ISSUES

Controversial issues in stricture management include the size of the stent, the duration of stenting, and the choice of cutting modality. Moreover, the value of long-acting steroids injected into the incised stricture bed and of urothelial grafts is still undetermined.

Stent size

Stents ranging from 5F to 16F have been utilized after endoureterotomy.⁵³ The optimal stent size remains unclear. Moreover, it is not known whether certain sizes of stents might provide better results with particular types of strictures. It is not known whether the stent acts as a mold around which the ureter reforms or as a scaffold that guides ureteral healing.

Some authors prefer to use the largest possible stent, while others fear that larger stents could mechanically compromise the vascularity of the ureteral segment.⁶²⁻⁶⁶ A retrospective report¹⁵ suggests that benign ureteral strictures of any length benefited from the use of a stent 12F or larger, yet other studies of endopyelotomy suggest that smaller stents (6F-8F) provide results similar to those of a 7F/14F endopyelotomy stent.⁶⁷⁻⁶⁹

Duration of stenting

The rationale for the use of stents after ureteral dilation or incision is to promote ureteral healing, prevent extravasation of urine, and avoid re-stricturing. Most authors agree with the need for stenting to promote healing after endoureterotomy. However, if left for a long period of time, stents can cause inflammation that may prevent adequate healing or promote the formation of hyperplastic muscle or scar tissue. Kerbl et al⁷⁰ found no difference in the healing of ureteral strictures regardless of whether a 1-, 3-, or 6-week period of stenting was selected. The optimal duration for stenting is still undetermined.

Choice of cutting modality

Cold-knife incision of ureteral strictures appears to be as efficacious as electrosurgery and the Ho:YAG laser in performing endoureterotomy.^{48,51,54,56} Figenshau and colleagues⁷¹ investigated the acute tissue changes in the pig ureter after balloon dilation, cutting balloon, and endoscopic incision with a cold knife, Nd:YAG laser, or electrocautery. Using 250- μ m and 660- μ m electrocautery probes, they found no significant difference in the degree of tissue injury among the various cutting modalities except for the larger (660- μ m) electrosurgical probe. Unlike a ureteral incision, balloon dilation resulted in injury to the lamina propria but did not appear to split the muscularis or adventitial layer.^{71,72} The Ho:YAG laser is currently the cutting modality of choice for many urologists, as it provides a well-controlled, hemostatic incision, with success rates that appear comparable to those achieved with other cutting modalities.^{48,73}

Adjunctive steroids

Triamcinolone in a dose of 120 to 200 mg (3 to 5 mL at 40 mg/mL) has been injected endoscopically with a 3F Greenwald needle into the incised stricture bed in selected patients with long or ischemic strictures, in whom endoureterotomy alone is less likely to be effective. Often, these patients have complex medical issues that prompt the selection of endoureterotomy over open surgical correction. The long-term utility of triamcinolone in the management of stricture disease remains unknown.^{15,53}

Several investigators have described the injection of a long-acting steroid, which appears to be clinically beneficial in patients undergoing incision of urethral and bladder neck contractures.^{74,75} One of the actions of triamcinolone is to block collagen formation. In three patients with recurrent stricture after endoscopic ureterotomy, Schmeller and coworkers⁷⁶ demonstrated that the treated area consisted of collagen-rich connective tissue with few fibroblasts and a scarcity of smooth-muscle fibers. The application of triamcinolone to the incised bed of the ureteral stricture may inhibit collagen formation and improve the success of endoureterotomy.

Adjunctive urothelial graft and metal stents

Urothelial grafts have been used in a small number of patients to improve healing of ureteral strictures after endoureterotomy. Experimental results with free tissue grafts (i.e., tunica vaginalis) to repair the ureter have been inconsistent and complicated by hydronephrosis and graft sloughing.^{77,78} However, a free graft of bladder urothelium has worked well for urethral stricture disease⁷⁹ and could be of value for ureteral replacement.⁸⁰ In the series reported by Urban and associates,⁸¹ among six patients who underwent a free urothelial graft for ureteral strictures, a patency rate of 83% was achieved with a mean follow-up of 30 months.

The use of metal ureteral stents is another controversial issue. Cussenot et al⁸² reported on the use of a flexible, expandable, tantalum-wire stent in the management of ureteral stricture disease. All patients had complicated pathology, including periureteral malignancy and several failed endourologic balloon dilation attempts. At follow-up, mucosal hyperplasia of various intensities was evident in all four patients, and obstruction recurred in three. In contrast, Pauer and Lugmayr⁸³ used a self-expanding, stainless steel-alloy, 7-mm stent to treat ureteral obstruction secondary to metastatic retroperitoneal tumor. Hyperplasia and edema of the urothelium was observed in all cases; however, the hyperplasia appeared to resolve after the initial 4 weeks. With a mean follow-up of 27 weeks, 87% of the stents remained patent.

URETEROENTERIC ANASTOMOTIC STRICTURES

Ureteroenteric strictures are a late complication of urinary diversion. There is no correlation between the type of urinary diversion and the rate of development of stenosis at the ureteroenteric anastomosis, which ranges from 4% to 8%.^{84,85} The mechanism of stenosis is usually ischemic; recurrent tu-

mor or inflammation secondary to radiation therapy is a rare cause of late stricture formation.

Ureteroenteric strictures may be approached from an antegrade or a retrograde access or by a combined antegrade and retrograde approach (Fig. 2). The largest single-center series⁸⁶ involved use of balloon dilation to treat 37 ureteroenteric anastomotic strictures in 29 patients. Most of these patients had undergone cystectomy and diversion for bladder or uterine/cervical carcinoma and had received adjuvant radiation therapy before cystectomy. All of the ureteroenteric strictures were dilated in an antegrade fashion. Most of the ureters were intubated with an 8.3F or 10F stent that was maintained for 1 to 6 weeks. In short-term follow-up, only 30% of the cases were considered to be clinical successes. At 1 year of follow-up, only 16% of strictured areas were patent.

Several other investigators have reported on balloon dilation of ureterointestinal anastomotic strictures.^{35-37,41,87} In these other series, the success rates for balloon dilation ranged from 16% to 67%. Among all series, the overall average success rate was 29% at an average follow-up of 14 months. Of note, the highest success rate, 67%, occurred among pediatric patients with a conduit and a benign etiology of the stricture.⁸⁷

The experience with endosurgical incision of ureterointestinal anastomotic strictures also is limited. This procedure may be performed in an antegrade or a retrograde fashion, although most investigators have used the antegrade technique.^{15,48,88-91} The largest single-center study was reported by Wolf et al¹⁵ and consisted of 30 strictures in 25 patients. Of these strictures, 16 occurred less than 24 months and 13 occurred more than 24 months from the time of the diversion procedure. A variety of approaches to the endoureterotomy were taken, including antegrade, retrograde, and combined antegrade and retrograde. The success rates of endoureterotomy at 1, 2, and 3 years were 72%, 51%, and 32%, respectively. There was a better outcome for right- than left-sided strictures (68% v 17% 3-year success rate, respectively) and for strictures treated less than 24 months after the etiologic insult. Stricture length and diameter and previous treatment did not alter the results. More favorable results were also noted with the use of 12F or larger stents (38% compared with a 0% 3-year success rate when using smaller stents) and stenting longer than 4 weeks.

Endoscopic incision of a ureterointestinal stricture provides a less invasive, less morbid approach that is successful in alleviating the problem in as many as 75% of patients who otherwise are candidates for open surgery.⁴⁸

URETERAL STRICTURES AFTER RENAL TRANSPLANTATION

After renal transplantation, the frequency of a ureteral complication is closely associated with the type of reimplantation. Thus, with Leadbetter-Politano reimplantation, urinary tract complications occur in 5% to 11% of patients,⁹² whereas with the adaptation of extravesical ureteroneocystostomy, the incidence of urologic complications has fallen to <4%.⁹² However, as many as two thirds of these problems are still attributable to ureteral obstruction. The obstruction may be either intrinsic (i.e., ureteral stricture) or extrinsic (i.e., perirenal fluid collec-

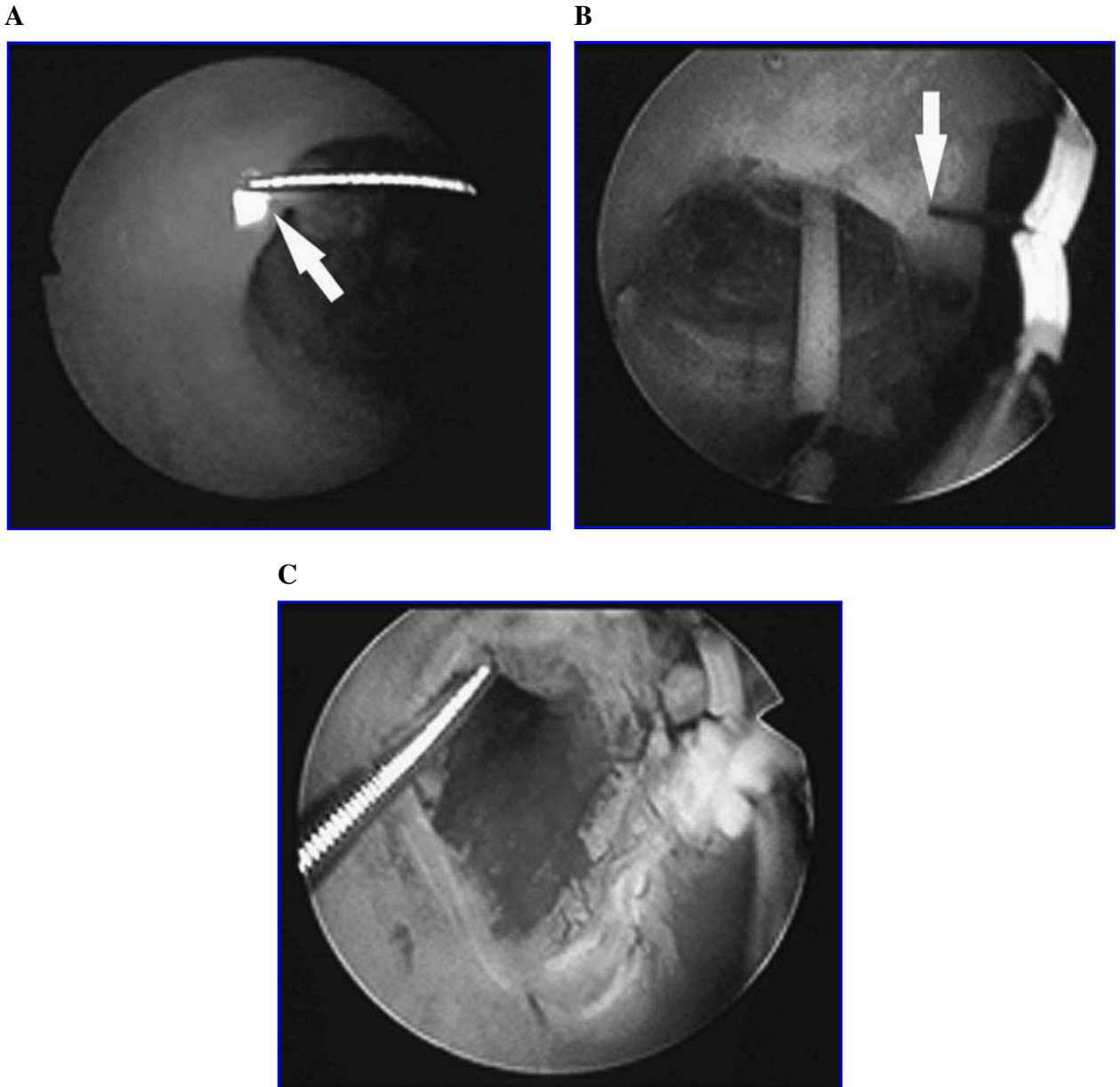


FIG. 2. Relief of ureteroenteric stricture. (A) Endoscopic view from ileal conduit aspect shows anastomotic stricture. Wire has been placed through stricture using ureteroscope passed antegrade. Arrowhead indicates light from ureteroscope. (B) Ureteral dilating balloon has been placed over wire. Resectoscope with Colling's knife (arrowhead) is used to incise stricture over the balloon. (C) Appearance of stricture after incision, showing ureter proximal to stricture marsupialized into ileal conduit.

tion, such as lymphocele, urinoma, abscess, or hematoma). Strictures usually develop early in the postoperative course, but stricture formation may occur as late as 5 years postoperatively.⁹²⁻⁹⁴

Ureteral strictures after renal transplantation have most commonly been treated with balloon dilation and ureteral stenting for 4 to 14 weeks with a 7F/14F stent. The success rate with this approach is 40% to 70% at an average follow-up of 2 years. Overall, strictures in the distal ureter or at the ureterovesical anastomotic site are more common than upper-ureteral stric-

tures and appear to respond better to endourologic management. In one study, the success rate with distal strictures was 75%; however, only 16% of proximal ureteral strictures responded favorably to balloon dilation.⁹⁵⁻⁹⁸

An alternative approach to ureteral strictures is endoureterotomy. Conrad and coworkers⁹⁹ used cold-knife endoincision to treat 11 transplant patients with a ureteral stricture; all but two of the strictures were in the distal ureter. An indwelling 14F stent was placed for a period of 4 to 6 weeks. Success was achieved in 82% of patients with a mean follow-

up of 28 months. Of interest, both patients with UPJ obstruction and all six with distal ureteral obstruction responded favorably to endoureterotomy, whereas only two of the four patients with middle or lower ureteral strictures had a favorable outcome. A similarly high rate of success has been reported by Youssef et al¹⁰⁰ using the Acucise device to cut the area of obstruction; a successful outcome was noted in five of six patients. Overall, it would appear that an endourologic approach with balloon dilation or incision is a reasonable first step when dealing with post-transplant ureteral strictures.

CONCLUSIONS

Although balloon dilation and endoureterotomy for ureteral strictures have impressive success rates, these do not duplicate the very high (91%–97%) rates achieved with open surgical repair.^{28,40} There may be several reasons for the discrepancies noted in these comparisons. The success of any treatment modality may depend on the length of the ureteral stricture, the cause of the stenosis, and the location of the stricture; until now, strictures of similar nature have not been studied in an effort to cull from the general category of "ureteral stricture" those that would best respond to an endourologic approach.

Endoureterotomy is the procedure of choice for the initial management of benign ureteral strictures. This technique has consistently been associated with higher success rates for these lesions than for ureteroenteric strictures, and in the former situation, most failures appear within the first year. Repeat endoureterotomy has a high likelihood of success if radiologic improvement was noted after the initial procedure. In contrast, endoscopic or fluoroscopic incision of ureteroenteric strictures appears to be less successful, with failures continuing for the first 3 years. Repeat incisions are more likely to fail, and therefore, open repair or long-term stenting is recommended.

Clearly, the success of endosurgical treatment depends to some extent on the previously described characteristics of the stricture: cause, length, and location. Unfortunately, rarely do study reports subdivide the patient groups according to their stricture characteristics. This factor, when combined with the inconsistencies of the technique of balloon dilation or endoincision and the variability in post-treatment stent size and duration of stenting, results in a significant amount of clinical confusion such that cumulative data on the endosurgical management of ureteral stricture can be judged only in a broad manner.

In conclusion, endourologic management of ureteral strictures has not acquired the same degree of acceptance as has endourologic management of UPJ obstruction. Overall, the endosurgical management of distal and upper ureteral strictures <2 cm and not associated with radiation or other ischemic injury is highly successful and results in minimal morbidity. Also, failure to establish patency does not preclude a subsequent open reconstructive repair. Strictures >2 cm and those associated with radiation or ischemic injury or a midureteral location may be managed more appropriately by open reconstruction because of the high failure rate in this group of patients treated endosurgically. Further clinical studies are necessary to determine the long-term feasibility and success of adjuvant therapy, such as triamcinolone injection and free urothelial grafting.

REFERENCES

- Morris H. Surgical diseases of the kidney and ureter. London: Cassell, 1901.
- Nitze M. Lehrbuch der Kystoscopie. Wiesbaden, 1907, p 410.
- Dourmashkin RL. Dilation of ureter with rubber bags in treatment of ureteral calculi: Presentation of modified operating cystoscope; Preliminary report. *J Urol* 1926;15:449.
- Dourmashkin RL. Cystoscopic treatment of stones in the ureter. *J Urol* 1945;54:245.
- Grüntzig A. Transluminal dilatation of coronary artery stenosis. *Lancet* 1978;1:263.
- Perez-Castro EE, Martinez-Pineiro JA. Transurethral ureteroscopy: A current urologic procedure. *Arch Esp Urol* 1980;33:445.
- Silverstein JL, Libby C, Smith AD. Management of ureteroscopic ureteral injuries. *Urol Clin North Am* 1988;15:515.
- Fry DE, Milholen L, Harbrecht PJ. Iatrogenic ureteral injury. *Arch Surg* 1983;118:454.
- Marshall VF. Fiber optics in urology. *J Urol* 1964;91:110.
- Takagi T, Go T, Takayasu H, Aso Y. Fiberoptic pyeloureteroscope. *Surgery* 1971;70:661.
- Takayasu H, Aso Y. Recent development for pyeloureteroscopy: Guide tube method for its introduction into the ureter. *J Urol* 1974;112:176.
- Huffman JL, Bagley DH, Lyon ES, et al. Endoscopic diagnosis and treatment of upper tract urothelial tumors: A preliminary report. *Cancer* 1985;55:1422.
- Karlin GS, Smith AD. Endopyelotomy. *Urol Clin North Am* 1988;15:433.
- Motola JA, Badlani GH, Smith AD. Results of 212 consecutive endopyelotomies: An 8-year follow-up. *J Urol* 1993;149:453.
- Wolf JS Jr, Elashry OM, Clayman RV. Long-term results of endoureterotomy for benign ureteral and ureteroenteric strictures. *J Urol* 1997;158:759.
- Weinberg IJ, Ansong K, Smith AD. Complications of ureteroscopy in relation to experience: Report of survey and author experience. *J Urol* 1987;137:384.
- Assimos DG, Patterson LC, Taylor CL. Changing incidence and etiology of iatrogenic ureteral injuries. *J Urol* 1994;152:2240.
- Kramolowsky EV. Ureteral perforation during ureterorenoscopy: Treatment and management. *J Urol* 1987;138:36.
- Chang R, Marshall FF. Management of ureteroscopic injuries. *J Urol* 1987;137:1132.
- Blute ML, Segura JW, Patterson DE. Ureteroscopy. *J Urol* 1988;139:510.
- Lytton B, Weiss RM, Green DF. Complications of ureteral endoscopy. *J Urol* 1987;137:649.
- Selzman AA, Spirnak JP. Iatrogenic ureteral injuries: A 20-year experience in treating 165 injuries. *J Urol* 1996;155:878.
- Ghoneim MO, Nabeeh A, El-Kappany H. Endourologic treatment of ureteral strictures. *J Endourol* 1988;2:263.
- Sabha M, Nilsson T, Bahar RH, et al. Endoscopic balloon dilation of bilharzial ureteric strictures. *J Endourol* 1988;2:23.
- Ward AS, Karanjia ND, Russell AJ. Ureteral obstruction following aortobifemoral bypass: Management by endoscopic balloon dilation. *J Urol* 1992;147:120.
- Ramanathan LT, Kumar A, Kapoor R, et al. Relief of urinary tract obstruction in tuberculosis to improve renal function: Analysis of predictive factors. *Br J Urol* 1998;81:199.
- Thomas R. Choosing the ideal candidate for endoscopic endoureterotomy [abstract]. *J Urol* 1993;149:314A.
- Kramolowsky EV, Tucker RD, Nelson CM. Management of benign ureteral strictures: Open surgical repair or endoscopic dilation? *J Urol* 1989;141:285.

29. Motola JA, Smith AD. Complications of ureteroscopy: Prevention and treatment. *AUA Update Series* 1992;11:162.
30. Davis DM. Intubated ureterotomy: A new operation for ureteral and ureteropelvic stricture. *Surg Gynecol Obstet* 1943;76:513.
31. Davis DM, Strong GH, Drake WM. Incubated ureterotomy: Experimental work and clinical results. *J Urol* 1948;59:851.
32. Clayman RV, Elbers J, Palmer JO, et al. Experimental extensive balloon dilatation of the distal ureter: Immediate and long-term effects. *J Endourol* 1987;1:19.
33. Selmy G, Hassouna M, Begin LR, et al. Effect of balloon dilatation of ureter on upper tract dynamics and ureteral wall morphology. *J Endourol* 1993;7:211.
34. Banner MP, Pollack HM. Dilatation of ureteral stenoses: Techniques and experience in 44 patients. *AJR Am J Roentgenol* 1984;143:789.
35. Beckman CF, Roth RA, Bihrl W III. Retrograde balloon dilation for pelviureteric junction obstruction. *Br J Urol* 1993;71:152.
36. Chang R, Marshall FF, Mitchell S. Percutaneous management of benign ureteral strictures and fistulas. *J Urol* 1987;137:1126.
37. Johnson DC, Oke EJ, Dunnick RN. Percutaneous balloon dilation of ureteral strictures. *AJR Am J Roentgenol* 1987;148:181.
38. Kim SH, Yoon HK, Park JH, et al. Tuberculous stricture of the urinary tract: Antegrade balloon dilation and ureteral stenting. *Abdom Imaging* 1993;18:186.
39. Lang EK, Glorioso LW II. Antegrade transluminal dilation of benign ureteral strictures: Long-term results. *AJR Am J Roentgenol* 1988;150:131.
40. Netto NR Jr, Ferreira U, Lemos GC, et al. Endourological management of ureteral strictures. *J Urol* 1990;144:631.
41. O'Brien WM, Maxted WC, Pahlira JJ. Ureteral stricture: Experience with 31 cases. *J Urol* 1988;140:737.
42. Kwak S, Leef IA, Rosenblum JD. Percutaneous balloon catheter dilatation of benign ureteral strictures: Effect of multiple dilatation procedures on longterm patency. *AJR Am J Roentgenol* 1995;65:97.
43. Dierks SM, Clayman RV, Kavoussi LR, et al. Intraureteral surgery: Appropriate cutting modality [abstract]. *J Endourol* 1990;4:S114.
44. Yamada S, Ono Y, Ohshima S, et al. Transurethral ureteroscopic ureterotomy assisted by a prior balloon dilation for relieving ureteral strictures. *J Urol* 1995;153:1418.
45. Cubelli V, Smith AD. Transurethral ureteral surgery guided by fluoroscopy. *J Endourol* 1987;2:8.
46. Bagley DH. Endoscopic ureteroureterostomy [abstract]. *J Urol* 1990;143:234A.
47. Conlin MJ, Bagley DH. Incisional treatment of ureteral strictures. In: Smith AD, Badlani GH, Bagley DH, et al (eds): *Smith's Textbook of Endourology*. St. Louis: K Berger, 1996, p 497.
48. Singal RK, Denstedt JD, Razvi HA, et al. Holmium:YAG laser endoureterotomy for treatment of ureteral stricture. *Urology* 1997;50:875.
49. Kourambas J, Delvecchio FC, Preminger GM. Low power holmium laser for the management of urinary tract calculi, tumors and strictures. *J Endourol* 2000;16:337.
50. Aronson WL, Barbaric Z, Fain J, et al. Cautery-wire/balloon catheter for fluoroscopically guided incision of ureteral strictures: A phase I study in pigs. *J Endourol* 1991;5:337.
51. Chandhoke PS, Clayman RV, Stone AM, et al. Endopyelotomy and endoureterotomy with the Acucise ureteral cutting balloon device: Preliminary experience. *J Endourol* 1993;7:45.
52. Cohen TD, Gross MB, Preminger GM. Long-term follow-up of Acucise incision of ureteropelvic junction obstruction and ureteral strictures. *Urology* 1996;47:317.
53. Meretyk S, Albala DM, Clayman RV, et al. Endoureterotomy for treatment of ureteral strictures. *J Urol* 1992;147:1502.
54. Preminger GM, Clayman RV, Nakada SY, et al. A multicenter clinical trial investigating the use of a fluoroscopically controlled cutting balloon catheter for the management of ureteral and ureteropelvic junction obstruction. *J Urol* 1997;157:1625.
55. Delvecchio FC, Preminger GM. Endourologic management of upper urinary tract strictures. *AUA Update Series* 2000;14(32).
56. Schneider AW, Conrad S, Busch R, et al. The cold-knife technique for endourological management of stenosis in the upper urinary tract. *J Urol* 1991;146:961.
57. Johnson CD, Oke EJ, Dunnick NR, et al. Percutaneous balloon dilatation of ureteral strictures. *AJR Am J Roentgenol* 1987;148:181.
58. Smith AD. Management of iatrogenic ureteral strictures after urological procedures. *J Urol* 1988;140:1372.
59. Fuchs GJ, Patel A, Gutierrez J, et al. Endourological treatment of ureteral strictures: Experience of 2 referral centers [abstract]. *J Urol* 1996;155:474A.
60. Beckmann CF, Roth RA, Bihrl W. Dilation of benign ureteral strictures. *Radiology* 1989;172:437.
61. Jabbour ME, Goldfischer ER, Anderson AE, et al. Endopyelotomy failure is associated with reduced transforming growth factor-beta. *J Urol* 1998;160:1991.
62. Siegel JF, Smith AD. The ideal ureteral stent for antegrade and retrograde endopyelotomy: What would it be like? *J Endourol* 1993;7:151.
63. Mahoney SA, Koletsky S, Persky L. Approximation and dilatation: The mode of healing of an unintubated ureterostomy. *J Urol* 1962;88:197.
64. Ramsay WA, Payne SR, Gosling PT, et al. The effects of double J stenting on unobstructed ureters. *Br J Urol* 1985;57:630.
65. Weaver RG. Ureteral regeneration: Experimental and clinical. *J Urol* 1957;77:164.
66. Hwang TK, Yoon JY, Alm JH, et al. Percutaneous endoscopic management of upper ureteral stricture: Size of stent. *J Urol* 1996;155:882.
67. Kletscher BA, Segura JW, LeRoy AI, et al. Percutaneous antegrade endoscopic pyelotomy: Review of 50 consecutive cases. *J Urol* 1995;153:701.
68. Moon YT, Kerbl K, Pearle MS, et al. Evaluation of optimal stent size after endourologic incision of ureteral strictures. *J Endourol* 1995;9:15.
69. Pearle MS. Use of ureteral stents after endopyelotomy. *J Endourol* 1996;10:169.
70. Kerbl K, Chandhoke PS, Figenschau RS, et al. Effect of stent duration on ureteral healing following endoureterotomy in an animal model. *J Urol* 1993;150:1302.
71. Figenschau RS, Clayman RV, Wick MR, et al. Acute histologic changes associated with endoureterotomy in the normal pig ureter. *J Endourol* 1991;5:357.
72. Gelet A, Cuzin B, Dessouki T, et al. Percutaneous endopyelotomy: Comparison between cold knife and electrode incisions [abstract P6-6]. Presented at the 7th World Congress on Endourology and SWL. November 1989.
73. Kuo RL, Asian P, Fitzgerald KB, et al. Use of ureteroscopy and holmium:YAG laser in patients with bleeding diatheses. *Urology* 1998;2:609.
74. Damico CF, Mebust WK, Valk WL, et al. Triamcinolone: Adjuvant therapy for vesical neck contractures. *J Urol* 1973;110:203.
75. Farah RN, DiLoreta RR, Cerny JC. Transurethral resection combined with steroid injection in treatment of recurrent vesical neck contractures. *Urology* 1979;13:395.
76. Schmeller N, Leitl F, Arnholdt H. Histology of ureter after unsuccessful endoscopic intubated incision. *J Urol* 1992;147:450.
77. Gardiner RA, Weedon D, Sing J, et al. Replacement of ureteric segments by intubated neoureterotomies (modified Davis technique) using autologous bladder and omentum in dogs. *Br J Urol* 1984;56:354.
78. Hovnanian AP, Javadpour H, Gruhn JG. Reconstruction of the

- ureter by free autologous bladder mucosa graft. *J Urol* 1965; 93:455.
79. Hendren WH, Reda EF. Bladder mucosa graft for construction of male urethra. *J Pediatr Surg* 1986;21:189.
 80. Greenberg R, Coleman JW, Quiguyan CC, et al. Bladder mucosal grafts: Experimental use as a ureteral substitute and observation of certain physical properties. *J Urol* 1983;129:634.
 81. Urban DA, Kerbl K, Clayman RV, et al. Endo-ureteroplasty with a free urothelial graft. *J Urol* 1994;152:910.
 82. Cussenot O, Bassi S, Desgrandchamps F, et al. Outcomes of non-self-expandable metal prosthesis in strictured human ureter: Suggestions for future developments. *J Endourol* 1993;7:250.
 83. Pauer W, Lugmayr H. Metallic Wallstents: A new therapy for extrinsic ureteral obstruction. *J Urol* 1992;148:281.
 84. Guiliiani L, Giberti C, Martovana G, et al. Results of radical cystectomy for primary bladder cancer: A retrospective study of more than two thousand cases. *Urology* 1985;26:243.
 85. Schmidt JD, Hawtrey CE, Flocks RH, et al. Complications, results and problems of ileal diversion. *J Urol* 1973;109:210.
 86. Shapiro MJ, Banner MP, Amendola MA, et al. Balloon catheter dilation of ureteroenteric strictures: Long-term results. *Radiology* 1988;168:385.
 87. Aliabadi H, Reinberg Y, Gonzalez R. Percutaneous balloon dilation of ureteral strictures after failed surgical repair in children. *J Urol* 1990;144:486.
 88. Ahmadzadeh M. Use of a prototype 3-Fr needle electrode with flexible ureteroscopy of antegrade management of stenosed ureteroileal anastomosis. *Urol Int* 1992;49:215.
 89. Cornud F, Mendelsberg M, Chretien Y, et al. Fluoroscopically guided percutaneous transrenal electroincision of ureterointestinal anastomotic strictures. *J Urol* 1992;147:578.
 90. Germinale F, Bottino P, Caviglia C, et al. Endourologic treatment of ureterointestinal strictures. *J Endourol* 1992;6:439.
 91. Lin DW, Bush WH, Mayo ME. Endourological treatment of ureteroenteric strictures: Efficacy of Acucise endoureterotomy. *J Urol* 1999;162:696.
 92. Thiounn N, Benoit G, Osphal C, et al. Urological complications in renal transplantation. *Prog Urol* 1991;1:531.
 93. Kashi SH, Lodge JPA, Giles GR, et al. Ureteric complications of renal transplantation. *Br J Urol* 1992;70:139.
 94. Kinnaert P, Hall M, Janssen F, et al. Ureteral stenosis after kidney transplantation: True incidence and long-term followup after surgical correction. *J Urol* 1985;133:17.
 95. Farah NB, Roddie M, Lord RHH, et al. Ureteric obstruction in renal transplants: The role of percutaneous balloon dilatation. *Nephrol Dial Transplant* 1991;6:977.
 96. Jones JW, Hunter DW, Matas AJ. Percutaneous treatment of ureteral strictures after renal transplantation. *Transplantation* 1991;55:1193.
 97. Pardalidis NP, Waltzer WC, Tellis VA, et al. Endourologic management of complications in renal allografts. *J Endourol* 1994; 8:321.
 98. Shokeir AA, El-Diasry AT, Ghoneim MA. Endourologic management of ureteric complications after live-donor kidney transplantation. *J Endourol* 1993;7:487.
 99. Conrad S, Schneider AW, Tenschert W, et al. Endo-urological cold-knife incision for ureteral stenosis after renal transplantation. *J Urol* 1994;105:906.
 100. Youssef NI, Jindal R, Babayan RI, et al. The Acucise catheter: A new endourological method for correcting transplant ureteric stenosis. *Transplantation* 1994;57:1398.
 101. Lopatkin NA, Martov AG, Gushchin BL. An endourologic approach to complete ureteropelvic and ureteral strictures. *J Endourol* 2000;14:721.
 102. Eshghi M. Endoscopic incisions of the urinary tract. *AUA Update Series* 1989;8(37).

Address reprint requests to:

J. Stuart Wolf, Jr., M.D.

University of Michigan

1500 E. Medical Center Drive

TC 2916

Ann Arbor, MI 48109-0330

E-mail: wolfs@umich.edu

This article has been cited by:

1. Paul M. Milhoua , Nicole L. Miller , Michael S. Cookson , Sam S. Chang , Joseph A. Smith , S. Duke Herrell . 2009. Primary Endoscopic Management Versus Open Revision of Ureteroenteric Anastomotic Strictures After Urinary Diversion—Single Institution Contemporary SeriesPrimary Endoscopic Management Versus Open Revision of Ureteroenteric Anastomotic Strictures After Urinary Diversion—Single Institution Contemporary Series. *Journal of Endourology* **23**:3, 551-555. [[Abstract](#)] [[PDF](#)] [[PDF Plus](#)]
2. Leonardo de Albuquerque Dos Santos Abreu , Milton Tanaka , Sidney Castro de Abreu , Paulo Roberto Kawano , Hamilto Yamamoto , Rodrigo Arthur Pereira Otsuka , Marcelo Rosa Travassos , João Luiz Amaro , Oscar Eduardo Fugita . 2008. Laparoscopic Management of Iatrogenic LesionsLaparoscopic Management of Iatrogenic Lesions. *Journal of Endourology* **22**:6, 1279-1284. [[Abstract](#)] [[PDF](#)] [[PDF Plus](#)]
3. Andrzej Koziak, Maciej Salagierski, Adam Marcheluk, Ryszard Szcześniewski, Marek Sosnowski. 2007. Early experience in reconstruction of long ureteral strictures with allogenic amniotic membrane. *International Journal of Urology* **14**:7, 607-610. [[CrossRef](#)]
4. Tibet Erdogru, Omer Kutlu, Türker Koksall, Ahmet Danisman, Mustafa F. Usta, Erdal Kukul, Mehmet Baykara. 2005. Endoscopic Treatment of Ureteric Strictures: Acucise, Cold-Knife Endoureterotomy and Wall Stents as a Salvage Approach. *Urologia Internationalis* **74**:2, 140-146. [[CrossRef](#)]
5. Scott B. Farnham, Michael S. Cookson. 2004. Surgical complications of urinary diversion. *World Journal of Urology* **22**:3, 157-167. [[CrossRef](#)]