

Management of Difficult Cases in Female Urology and Neurourology at the Reed M. Nesbit Society Meeting Festschrift in Honor of Edward J. McGuire, MD

Jerry Blaivas,¹ Edward J. McGuire,² Manfred Stöhrer,³ George D. Webster,⁴ and Anne P. Cameron^{5*}

¹Clinical Professor of Urology at Weill Cornell Medical School, New York, New York

²Reed Nesbit Professor of Urology, University of Michigan Medical Center, Ann Arbor, Michigan

³Professor Urology, Neurourology, Department of Urology, University of Essen, Munich, Germany

⁴Professor Urologic Surgery, Duke University Medical Center, Durham, North Carolina

⁵Clinical Lecturer, Department of Urology, University of Michigan Medical Center, Ann Arbor, Michigan

This is a panel discussion of seven complex urologic cases in female urology and neurourology. Differences in diagnosis and management are discussed by this international panel of experts. *Neurourol. Urodynam.* 29:S2–S12, 2010. © 2010 Wiley-Liss, Inc.

Key words: bladder extrophy; multiple sclerosis; neurogenic bladder; spina bifida; spinal cord injuries; urinary bladder neck obstruction; urinary incontinence; urodynamics

INTRODUCTION

Dr. Webster: First, let me say how honored I am to be here to honor Ed McGuire. I am proud to have been associated with him for almost 30 years and I know the other panel members will agree, Ed “wrote the book” on neurourology, urodynamics, and female urology. This event is not Ed’s retirement, but when he does retire he is going to leave a tremendous void in our field.

Dr. Blaivas: First, I’d like to express my gratitude for being invited as part of this distinguished panel and my gratitude to my good friend Ed McGuire here. Whether the rest of you realize it or not, so far, all of the answers to the questions that have been posed and the answers to the subsequent questions that are being posed, those answers are based on physiological principles that Ed taught us. For those of you (it looks like most of you) in the audience too young to know what it was like practicing the specialty before Ed McGuire was around, these concepts didn’t exist. Most of us build on concepts from an earlier time. Most of our great original ideas are really the original ideas of our forefathers. The same really can’t be said of Ed. The kinds of problems that you are describing and the words that we’re using today, such as compliance and leak point pressure and concepts like the effects of the compliance on the upper tract are all things that didn’t exist in our knowledge base, before Ed, and for that I really personally owe you a great deal of gratitude as does the rest of the scientific community.

Dr. Stohrer: Let me first say I’m very much honored to be here today and thank you very much for inviting me. The previous speakers have already mentioned aspects about Ed. I would add that Ed McGuire is one of the urologists who have had a great influence on German Neurourology, and we are all very happy to know him and to have had his help whenever we needed him. We have invited him several times to come to Germany to discuss most difficult cases, and we always benefited from his knowledge and his vast experience.

We appreciate his opinion as that of an honest, critical and committed scientist. Also we have always enjoyed his special sense of humor and his ability to get straight to the point. We thank you very much, Ed!

CASE #1 PRESENTATION—MALE PATIENT WITH OBLITERATED BLADDER NECK

The patient is a 65-year-old gentleman who had a radical retropubic prostatectomy 6 years ago for localized prostate cancer. Post-operatively he was continent. Two years after his procedure he developed a PSA recurrence, and he underwent salvage external beam radiation. One year after radiation therapy he developed recurrent bladder neck contractures, and he was treated with multiple urethrotomies and transurethral resections. For the past 2 years, his bladder has been managed with a suprapubic (SP) tube due to an impassible bladder neck. His most recent PSA was undetectable. He has had recurring urinary infections since the SP tube was placed as well as one admission for pyelonephritis. He is otherwise healthy besides being obese with a body mass index (BMI) of 36.

Evaluation of this gentleman consisted of: Cystourethroscopy, which revealed a completely obliterated bladder neck; and cystoscopy through his SP tract, which revealed normal bladder mucosa and no other pathology. A cystogram revealed

a

Conflicts of interest: none.

Christopher Chapple led the review process.

University of Michigan, Biomedical Science Research Building, 109 Zina Pritcher Drive, Ann Arbor, Michigan, Thursday, October 23, 2008.

*Correspondence to: Dr. Anne P. Cameron, MD, 3875 Taubman Center, 1500 E Medical Center Drive, Ann Arbor, MI 48109-5330.

E-mail: annepell@med.umich.edu

Received 12 May 2009; Accepted 6 July 2009

Published online 15 April 2010 in Wiley InterScience

(www.interscience.wiley.com)

DOI 10.1002/nau.20795

bladder capacity of 200 ml. He had poor bladder compliance with a peak storage pressure of 80 cm water. There was no evidence of detrusor overactivity or vesicoureteral reflux. No contrast was seen entering the urethra.

To Dr. Webster: In this case would you try to re-open his urethra, and if so, how would you accomplish this?

Dr. Webster: Yes, I would try and open the bladder neck first. To re-establish continuity, I have a variety of techniques and usually, but not always, I can accomplish my goal. I leave a catheter in for variable time periods depending on how much damage I leave at the time of my reestablishment of continuity. Upon removal of the catheter there's going to be a period of self-calibration to let the system declare its stability, and how long I will do that is determined by where on the spectrum of complexity this man's outlet resides. Some ultimately prove to be recalcitrant even though I've established continuity. By recalcitrant ones, I mean they'll re-obstruct, or they can't do self-cath. In these instances, I will consider stenting with Urolume[®] as a means to keep it open. I probably have a cadre of about 50–60 men who advanced to the point of where they ultimately require stenting.

There are other complexities to this man's case, obviously. He's got a seemingly bad bladder, but that may be a combination of things that may be improved if one could get his SP catheter out. It's possible that his very limited capacity is a fixed change due to the radiation. But I think a lot of his bad bladder appearance may well be the result of a SP tube being in for two years. The SP tube in of itself would not deter me from re-establishing continuity. I'd try to get him on self-catheterization, and then consider stenting. Regardless of stenting or not stenting he may still require an artificial sphincter as well. So I'm going to walk down a path with this man, and each man is going to be a little different.

Dr. Cameron: Are there any factors that would make you decide not to pursue this path of trying to open up his urethra: The small bladder, urethral appearance, or anything else?

Dr. Webster: I remember one man who had an obliteration that looked as though it was recanalizable using my standard up and down endoscopic approach. Intraoperatively with endoscope in place I did a rectal exam and realized that actually the rectal wall was adherent to the retro-symphysis and the urethra stopped below it and the bladder was above it. So any attempt at recanalization would have traversed his rectum.

So there are some circumstances, particularly, where there was a separation of anastomosis at the time post-prostatectomy where the defect is catastrophic. Establishing continuity, in this case, means that all you've created is a channel through scar. Nothing is going to keep that open. Stenting won't help that; the scar can grow through it. So there are certain circumstances related to the length of defect and other intraoperative findings that perhaps would deter you. The urethra obviously isn't going to be a candidate for an artificial sphincter subsequently.

Also, not all patients want to go through what is obviously multistage management. My honest counseling to them is that there is a 50 percent re-operation rate even for the successful candidate. However, these are not frequent re-operations and they're endoscopically achievable, and so depending on the patient it might be a worthwhile price to pay.

Dr. Cameron: If the urethra is not salvageable, what would you do? Would you divert this person, or keep him with a SP tube?

Dr. Webster: I would present the options: Live with your SP catheter or have a diversion. The diversion can be appliance dependent or a non-appliance dependent catheterizable

one. For the appliance dependent, I would usually favor an ileovesicostomy as opposed to a ureterostomy or ileal loop.

If the patient wanted a continent catheterizable system, my own personal experience is that I prefer to do a continent reservoir separate from the bladder. I know that seems like an anathema because while you've got good uretero-vesical anastomosis, then why not put a catheterizable stoma down to that bladder augmenting at the same time if needed.

I've always found that to be so much more difficult to do, to get the stoma in the correct location. I have so much more confidence in an isolated continent catheterizable ileocecal right colon pouch that I generally try and go that way. The problem then is if I do a continent catheterizable separate system, I've got a de-functioned obstructed bladder at the bottom. I've got to think about the cystectomy and that's going to play into my decision making. If this is going to be a difficult post-radiation cystectomy in a patient who is not a good candidate for that big a procedure, I'm going to be leaning back toward leaving that bladder in place and doing something to the bladder, an ileovesicostomy versus some sort of catheterizable augmented system to the bladder.

Dr. Cameron: When you're planning to reconstruct the bladder, what factors do you use to decide if the bladder is suitable for this?

Dr. Webster: I don't think I have ever done a simple Mitrofanoff type using whatever appendage one wishes as a catheterizable stoma to an intact bladder. I have always augmented the bladder at the time. So how good or bad the bladder is doesn't make much difference to me because I'm going to make the bladder bigger by augmenting it anyway, and my preference if I'm going to do a continent catheterizable augment to the bladder, is to use the right colon with the ileocecal valve as the continent mechanism. It is a system that lends itself much more easily to placing the stoma where you want it to be.

Dr. Cameron: Continent catheterizable stomas can be a challenge in obese adults like this gentleman. What surgical tips can you give to the audience regarding performing continent catheterizable stoma in an obese patient?

Dr. Webster: For an isolated continent diversion, obesity makes little difference to the difficulty or success of the catheterizable stoma because with a right colon pouch using a staple-reduced ileal limb as your efferent system you just leave it a little longer, it comes straight out through the abdomen, and obesity doesn't make any difference to the technicalities of it.

If you're leaving the bladder intact and you're making a continent catheterizable system attached to the bladder, then I would agree, it's a different kettle of fish altogether. It's going to lead me more toward making an isolated continent reservoir system as opposed to a continent or vented system.

Dr. Cameron: And do you aim for the stoma to be at the umbilicus?

Dr. Webster: Never. The umbilicus has always been a special part for me. I can't desecrate it with a hole that may leak.

Dr. Cameron: Do any other of the panel members have any comments they would like to add?

Dr. Blaivas: I'm not so disinclined to use the umbilicus. I do think that in some patients, and particularly in obese patients, that it offers the straightest and shortest path to the pouch and that makes catheterizing easier.

In my experience, there is about a 30 percent chance of the patient developing stomal problems over time. I'm not talking necessarily about the first few years; some patient's have come back, 5, 10, and 15 years later with either stomal stenosis or a difficulty catheterizing. The difficulty catheterizing is very

often right at the junction of the efferent limb with the pouch or bladder. For that reason, I think it's really important to have the shortest possible distance from the skin to the pouch, and that often is in the umbilicus, but not invariably. Having said this I mostly don't put it in the umbilicus. I put it wherever I can get the shortest and straightest path; I think that's what makes the difference.

Dr. Webster: When I was making Kocks, I think I had easily a 70 percent stoma revision rate or efferent limb revision rate. In the last 18 years since I've been doing right colon pouches I have to say my revision rate for stenosis or catheterization difficulties is certainly less than 5 percent.

Dr. Cameron: Dr. Webster, how do you treat a leaking continent catheterizable stoma?

Dr. Webster: I don't try injecting them with things to bulk the stoma. I'll re-explore them, take it apart and put it back together again the way it was supposed to be. Most often what I'll end up doing is sort of wrapping part of the cecum around the efferent ileal segment. It's almost enveloped and the hydrostatic compression helps to compresses the limb.

I take it apart and I look at it and I put it back together in a fashion that makes it look like it will work, and usually it will.

Dr. Cameron: Do any of the other panel members have any suggestions to correct the leaking continent catheterizable stoma?

Dr. McGuire: I sometimes will repair them with a sling. I can put a rectus fascial sling around them, but you have to make a slit and pull the sling through so that you can adjust the tension, and that often works and it's a pretty easy operation to do. I would do that with an appendix, certainly.

CASE #2 PRESENTATION—SPINIA BIFIDA AND INCONTINENCE

This is a 28-year-old man with spina bifida whose bladder is managed with self-catheterization and an oral anticholinergic medication. He is incontinent only with transfers and with physical activity. He has no prior history of bladder or bladder neck surgery. He is employed, compliant with treatment, and highly motivated to become dry. He is otherwise healthy and has no urinary tract infections or stones.

On physical examination the patient is seated in a wheelchair. He has a normal GU exam. He has a favorable body habitus with a BMI of 20. His 24-hr pad weight test is 400 g and his urinalysis is normal.

On video-urodynamics, he has normal compliance up to 600 ml, and no evidence of detrusor overactivity or reflux. With a cough there is intrinsic sphincter deficiency (ISD) with a leak point pressure of 50 cm of water.

This is an image from his video-urodynamics. Note the open bladder neck at rest. The bladder is filled to only 100 cc with a cough test, although the patient can easily fill to 600 ml. The catheter is removed to better assess leakage and the leak point pressure is 50 cm of water (Fig. 1).

Dr. Cameron: Dr. McGuire does his pad weight of 400 g in 24 hr affect your surgical plan?

Dr. McGuire: No, it doesn't.

Dr. Cameron: Even if his pad weight were 800 g?

Dr. McGuire: It wouldn't make any difference.

Dr. Cameron: How do you manage ISD in a male who does intermittent catheterization?

Dr. McGuire: There are basically four ways. You can do a physical sling around the bladder neck. You could do a sling at

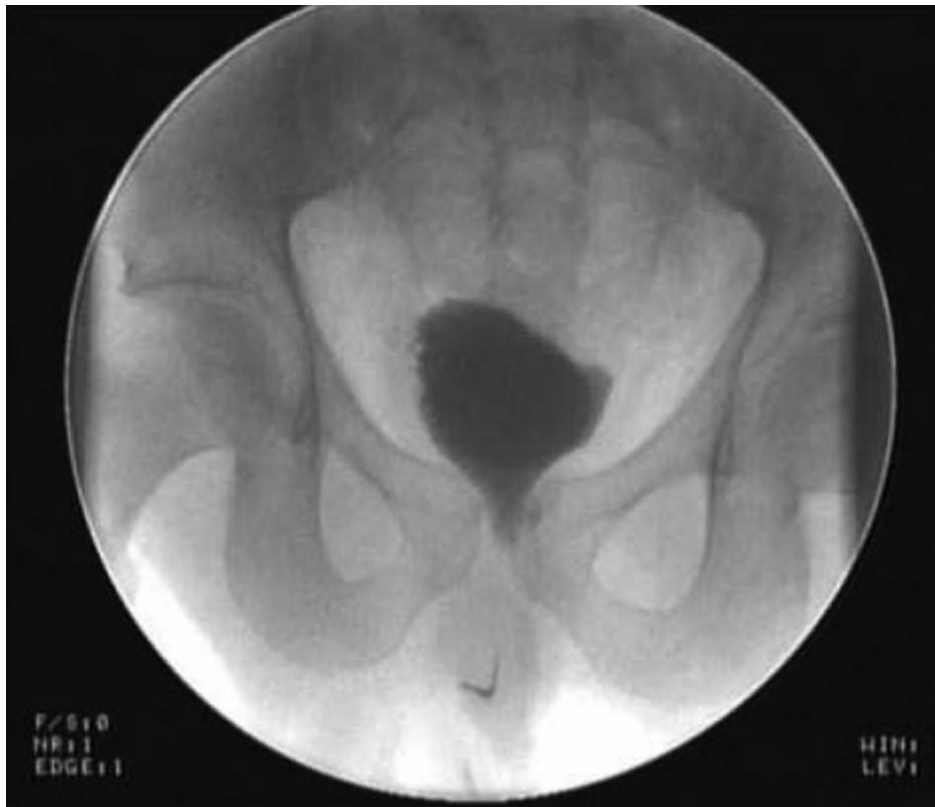

Fig. 1. Bladder filled to 100 ml and catheter removed. Note the open bladder and urine leakage into urethra after cough.

the bulb. You could do an artificial sphincter implanted around the prostatic urethra, or you could do a bone anchored perineal sling. It would depend on their body habitus. Myelodysplastic patients sometimes have a small pelvis, but any one of those ways would work. The problem with a bulbous urethral sphincter is that if they are doing an intermittent catheterization it often erodes.

Dr. Cameron: Do any of the other panel members have anything they would like to add to that?

Dr. Stöhrer: We are doing fascial slings in these cases, and they are very effective. I am not so much in favor of bone anchors. I think it's much better to have your own tissue in these cases because these are mostly young people and if it's not effective, you could later do an artificial sphincter. This is what we are currently doing. We start with a fascial sling and then the next step would be to do a sphincter.

Dr. McGuire: Actually our data for bone anchored slings in patients with myelodysplasia is excellent. I'm not sure why that is. It's better than for postprostatectomy incontinence, and they're stable for years. We have 6-year data. I'm sort of torn between a standard fascial sling or a periprostatic sling and a bone anchored sling because the bone anchored sling is not very invasive and I can do it in about 30 min and our results are excellent. I wouldn't have thought that it's possible in this patient group since they don't have normal bones, but the results are good.

Dr. Cameron: Dr. McGuire, how do you feel about synthetic materials implanted in a person who does self-catheterization?

Dr. McGuire: Well, I don't think you're going to get away with a bulbous urethral sling, but the bone anchored slings are not an impediment to re-instrumentation of the urethra. A bone anchored sling will let you get a rigid or a flexible scope into the bladder, and it's not a problem with intermittent catheterization, but neither really is a prostatic urethral artificial sphincter. They do erode, but it takes a long time.

Dr. Webster: I have no experience with Invance[®] slings in this population because I always put a bladder neck sphincter in this population. I must say bladder neck sphincters, other than the difficulty of the dissection for placement, have the same difficulty as doing a bladder neck sling. I hate to do a bladder neck sling thinking I could end up in that location placing a sphincter because I've messed up that field and the dissection is going to be that much more difficult the next time around to put a bladder neck cuff in. So I've invariably gone with a sphincter cuff, and they are the longest surviving of all sphincters. I've got some 14–16 years still functioning, unlike the customary 5–10 years survival of the bulbar urethral cuffs and they do work pretty well.

Dr. McGuire: I certainly agree, although I have seen bladder neck sphincters erode in time, and I've salvaged those with a fascial wrap sling. Not an easy operation, but I salvage them. So you can do it.

Dr. Blaivas: Like George, I predominantly place the sphincter around the prostatic urethra for these patients. The other advantage to the sphincter is occasionally there are people who can void and don't need to catheterize themselves.

You mentioned a leak point pressure of 50 cm of water, which is fairly high for this condition and that patient might not be able to void, but some of the patients have so little resistance you can put in an artificial sphincter and they can void to an acceptable degree with reasonable pressures and they don't even need to catheterize.

Dr. Cameron: If your artificial sphincter fails, and you've tried slings and they've failed, would you consider a bladder neck closure and a continent catheterizable stoma in this man?

Dr. McGuire: I wouldn't do that. I think the difficulty in getting him dry with a sphincter or a sling is surmountable. There are issues in this person of fertility and so forth.

CASE #3 PRESENTATION—FEMALE URETHRAL EROSION

This is a 45-year-old woman who has progressive multiple sclerosis (MS). She is functionally tetraplegic and is unable to perform self-catheterization. She had a urethral catheter placed 5 years ago to manage her urinary incontinence. She developed leaking around the catheter and over the course of the 5 years the catheter was gradually up-sized from 16 French up to 24 French with continued leakage around the catheter. Later the volume in the balloon was increased. Her urethra became destroyed to the point where the catheter, even with 30 ml in the balloon, was repeatedly falling out.

Other than the progressive MS and her recurrent urinary tract infections, her past medical history is unremarkable. She has normal renal function with a creatinine of 0.6 mg/dl. On physical exam, her urethra is essentially wide open and would admit two fingers (Fig. 2).

Dr. Cameron: Dr. Blaivas, how would you manage an open bladder neck and a destroyed urethra in a woman who is incontinent and cannot self-catheterize?

Dr. Blaivas: Managing a destroyed urethra in this kind of woman to me is not easy, but it's fairly straightforward because there is only one technique that I use. I don't try to reconstruct the urethra in someone like this because I think it's doomed to failure. So I would just close the bladder neck and do an ileovesicostomy.

Dr. Cameron: So what if she was able to learn self-catheterization?

Dr. Blaivas: Well, this wouldn't be an MS patient with tetraplegia because in this kind of a situation even if she could catheterize now, I wouldn't want that burden to fall on somebody else in the future. So let's just pretend for the

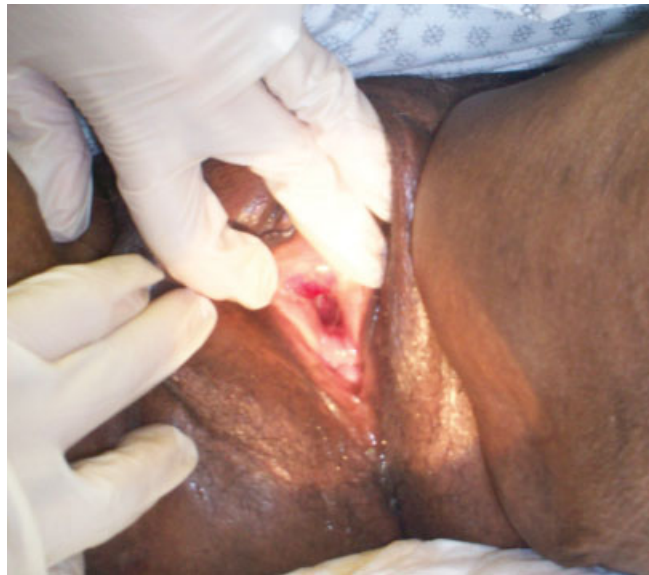

Fig. 2. Female urethra destroyed by urethral catheter.

moment we just want to fix the urethra that someone could catheterize, and then that depends on a couple of factors.

If it's a quadriplegic or a paraplegic woman who has spasticity in her legs and can't catheterize through the urethra, that's probably the single most important consideration. No matter how we reconstruct it and no matter how good her hands are if she can't get her legs apart to get the catheter in, it's simply not going to work. So if we're going to fix the urethra, then it has to be in someone that not only has good hand function, but can physically assume the position that she can catheterize herself. If that's the case, what I do is I reconstruct the urethra using adjacent vaginal tissue flaps. So we have to assume that there's enough local tissue in the vagina to do that. There are a variety of different ways to do it. I would find tissue in the vagina to roll into a tube or perhaps make two rectangular flaps and bring them together and make them into a tube and then wrap that tube with a Martius flap from one side or the other and then put a sling around that. I would expect her to be continent and able to catheterize herself but not necessarily be able to void.

As for closing the urethra, what I do in a situation like this is to do it from above as part of an augmentation cystoplasty either along with a catheterizable stoma or in this lady we'd probably use an ileovesicostomy where the urine just drains into a bag. I transect what's left of the urethra at the bladder neck and then I dissect underneath between the bladder neck and the vagina and make a little flap of the posterior part of the bladder wall and then I use that as part of the closure for the augmentation part of creating the reservoir. So the posterior part of the bladder would come up, and we would just anastomose it to whatever piece of bowel we're using for the cystoplasty. In this fashion, there is no longer a tubular anatomy to what was the urethra, so if the muscle contracts, it will not cause urine leakage.

Dr. Cameron: Any comments from the panel?

Dr. Webster: In a patient like this, I like to close the bladder neck as well. However, bladder neck closures fail frequently, no matter how well you seem to do it. Water finds its way back out to the urethra and I've had a significant number of failures in my career in bladder neck closures from above to the point now where, providing the patient doesn't have tremendous spasticity, I will do a urethrectomy in lithotomy position to start with. Then I will perform the ileovesicostomy from the top. I'm not averse to doing it abdominally, but I will definitely think hard about a urethrectomy done through an elliptical incision around the meatus.

Dr. Cameron: Dr. Blaivas, do you have experience with an ileovesicostomy versus an ileal conduit?

Dr. Blaivas: Yes, I do. The ileovesicostomy really works very well. I did my first one in the mid-1980s after speaking to Ed about what should I do with this type of patient, and this happened to be a man who was quadriplegic and couldn't care for himself at all. That was over 20 years ago and I still see him once a year. Stomal stenosis is practically unheard of after ileovesicostomy and there is no chance of ureteral obstruction. On the other hand, the incidence of ureteral obstruction after ileal conduits is at least in the single digit percents and that is not insignificant.

Dr. Webster: I think it was you and Ed wrote a paper about urodynamics in ileovesicostomy systems, wasn't it?

The interesting thing is an ileovesicostomy doesn't always turn out to be the totally safe system with a very low leak point that you imagine. Maybe there's some physical principle by which that occurs, but certainly the fact that you've done an ileovesicostomy and converted a low compliance bad system into what you think is a free leak system doesn't mean

you can forget about the patients. Sometimes these things don't have a low leak point pressure. Ed could comment on that.

Dr. McGuire: It is still our standard technique, but they don't always drain perfectly and the bladder neck closure can fail and then you have a disappointed person who has had a big operation. I've become more and more careful about making the anastomosis as big as possible, to put a flap of bladder into the anastomosis and make them as low as possible. Don't make the anastomosis on the dome, bring them down farther.

But I agree with Jerry and George that the loop and cystectomy is a lot of surgery in a patient who's fragile.

Dr. Stöhrer: I have a question. Does anyone see any indication to leave in a catheter for 5 years? Because we have seen so many of those patients, always with the same problem.

Dr. McGuire: Well, the problem is that the person who makes the decision to put the catheter in is never the person that has to look after the problem. It's always somebody else. Once you lose a patient like this for 5 years with a catheter, the damage is done. Then they risk the skin, and if the skin breaks down, they risk osteomyelitis and then they risk their life.

CASE #4 PRESENTATION: REFRACTORY DETRUSOR SPHINCTER DYSSYNERGIA

This is a 24-year-old gentleman who suffered a C7 spinal cord injury 4 years ago. He has adequate upper extremity function to be able to perform intermittent self-catheterization. He catheterizes every 3 hr and is on oxybutin 15 mg daily. He is wet between catheterizations, but is otherwise healthy.

As part of a workup his ultrasound showed no bladder stones, but mild bilateral renal dilation. His urine culture was negative and his creatinine was normal at 1.2 mg/dl.

On urodynamics, he has a small capacity low compliance bladder with an intravesical pressure of 34 cm of water with only 130 ml of filling. He also has left grade 1 vesicoureteral reflux. During the voiding phase there is detrusor sphincter dyssynergia (DSD) (Fig. 3).

Dr. Cameron: Dr. Stöhrer, what would your initial management be of this problem?

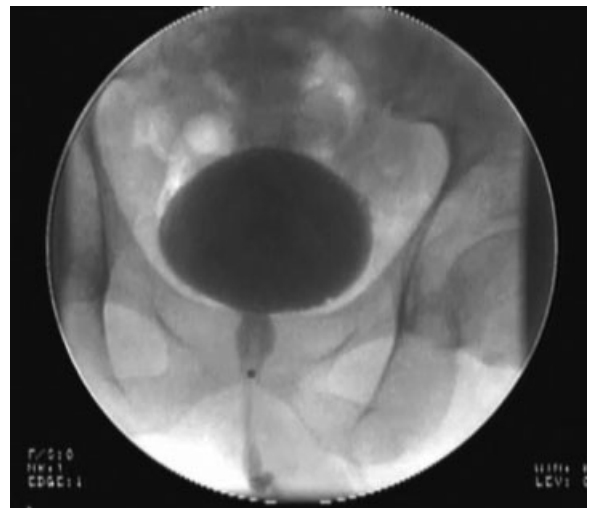


Fig. 3. Fluorourodynamic image at 130 ml of filling with a detrusor contraction and detrusor sphincter dyssynergia.

Dr. Stöhrer: This is a common situation in a patient with a C7 spinal cord injury. What we would do first is urodynamics. In this case, we would try to decrease the bladder pressure during storing phase by anticholinergics. If this works, the patient has to do catheterization, and this is something he could do indefinitely. But many of the patients are not very satisfied with their clinical response to anticholinergics. This may be due to side effects or lack of efficacy, or both. In these instances, we consider botulinum toxin injections. At the moment, we have about 500 patients we are following up who have had botulinum toxin, and I think this is a good second step. Then if it's not working, we have some other options, including perhaps an auto-augmentation.

Dr. Cameron: In an ideal world where cost and insurance coverage weren't an issue, what would your treatment be?

Dr. Stöhrer: My treatment would be to put the patient on aseptic intermittent catheterization four to five times a day and perhaps botulinum toxin. From my personal point of view, I would recommend botulinum toxin.

Dr. Cameron: Do any of the panel members have anything to add to that?

Dr. McGuire: No. I would do that. I learned from Manfred. The first long-term series published was the combined Murnau, Zurich experience with botulinum toxin in this patient population. This patient is an ideal candidate for that therapy.

Dr. Blaivas: I certainly agree with the efficacy of botulinum toxin and Dr. Stöhrer's studies in particular have shown that.

An augmentation cystoplasty, though, is an awfully good solution as well. If I were the patient, I think I might prefer augmentation cystoplasty, and catheterization. I have personally followed over 100 of my patients after enterocystoplasty for 10 years or more, and aside from two men who developed urethral strictures that had to be managed endoscopically, I find it a very trouble-free existence. They catheterize three to four times in 24 hr, and the problem of cancer I think is practically nonexistent in this patient population.

What do you think about that?

Dr. Webster: When I think of this particular practice, the spinal cord injury practice, I see a case being presented to me by residents or fellow as a great candidate for an augmentation cystoplasty. When you actually look at the cases individually, you've got to be sure that this rather large operation is the appropriate choice.

It can be challenging to get a spinal cord injury patient who has a limited cystometric and functional capacity to accept the fluid limitations that it's going to take to have to only be able to catheterize every 3–4 hr and to take medications that carry side effects and to have the compliance to buy and take the medication. However, if one does all those things, you actually don't need to do as many cystoplasty procedures that we resort to appease a noncompliant patient. If I was the patient, I wouldn't like to catheterize that often and take all those meds and I'd like to drink more fluids. So perhaps it's okay to say, "You could be better on your own, but since you can't

comply with maximal conservative therapy, we're going to augment you, or inject you with botulinum toxin." But I'd like our residents to understand that line of thinking, that's why we're doing this and not because we've failed.

Just one other thing, Manfred— in using botulinum toxin for neurogenic overactivity, accepting its function in hyperactivity with involuntary contractions, do you see the same sorts of results with this sort of low compliance system?

Dr. Stöhrer: Yes, because there is usually not an organized fibrosis. Instead, there is detrusor overactivity which causes the compliance abnormality, and this is something you can help with the botulinum toxin. At the moment, we are treating more than 70 percent of our patients from this population conservatively. We don't need many subsequent procedures. Personally, I wouldn't want a piece of my bowel as a bladder because this is not a normal bladder. It is a good surgical procedure, but I think from the patient's point of view, most say they would prefer to be on conservative management as long as possible. This is my experience. They do catheterize four to five times a day, have few fluid problems, and drink normally (about one and a half liters per day).

Dr. Cameron: Dr. Stöhrer, what are your feelings about the long-term use of botulinum toxin in this patient population?

Dr. Stöhrer: We now have 11 years of experience—some of the patients have had up to 12 injections. In my hospital last week, I checked how many of our patients had developed antibodies, and there were only six patients out of > 500.

So I think it is a very small number. The only side effect we have seen is that some of the patients (<2%) had a systemic reaction of 2 weeks maybe, 3, 4 weeks where they feel lethargic (without any necessity for an intervention). This is the only complication we have seen up to now.

Dr. Cameron: How many injections do you do and where do you do the injections in the bladder?

Dr. Stöhrer: I am not sure that the specific technique has a significant effect on the outcomes, but here is what we do. We usually inject 300 units of Botox[®] using 30 injections, which equals one milliliter for ten units or 750–1000 units of Dysport[®]. We inject it at random sites throughout the bladder, but I believe that if you do it 15 times over the whole bladder, there's no difference in the outcomes.

CASE #5 PRESENTATION: MESH EROSION INTO THE URETHRA

This is a 75-year-old female who has incontinence after undergoing a trans-obturator tape (TOT) procedure. Initially she had stress incontinence using four light pads per day. After evaluation at an outside facility she underwent TOT placement. Unfortunately, the incontinence was much worse after the procedure, so that the patient, required diapers. She did not complain of any hesitancy or straining, nor did she note any dysuria, urgency, or urge incontinence.

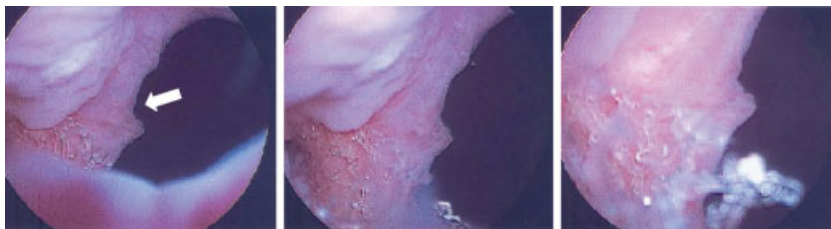

Fig. 4. Mesh erosion in urethra. White arrow is bladder neck.

On pelvic exam, the tape was non-palpable. There was no fistula found. Incontinence was seen only via the urethra with Valsalva. Significant atrophy of the vagina was also noted and there was no post void residual. The urinalysis was notable only for microhematuria. On cystoscopy, one can clearly see the polypropylene mesh which was eroding through the lateral wall of the urethra right at the bladder neck (Fig. 4).

She subsequently underwent urodynamics. Her leak point pressure was 55 cm of water. There was no detrusor over-activity noted.

Dr. Cameron: How would you surgically manage this case?

Dr. McGuire: Well, you have to take the tape out, and I think if there's any controversy, it's what you have to do subsequently. I normally would take the tape out, close the injury site in the urethra, and let it settle down a bit before I did a fascial sling. I've been tempted to do the sling at the same time, but I have not yet done that.

Dr. Cameron: What would you counsel her about her risk of incontinence after removal of the tape?

Dr. McGuire: 100 percent.

Dr. Cameron: So you would not prophylactically implant a new sling?

Dr. McGuire: Normally I'm most worried about what the urethra looks like. The tape is through the middle of it. Here it's right on the side of the bladder, and I think you're better off getting it out of there before you put a sling in. Even though there'll be scarring and difficulty at the time of the next surgery, generally speaking I wouldn't put a sling in now. I'm not sure why I do that, but I do.

Dr. Cameron: There are reports of people simply excising the tape endoscopically with a zero degree lens on a cystoscope and scissors or actually using a nasal speculum and trimming the tape and not opening up the urethra. How do you feel about that method?

Dr. McGuire: I don't know how you would do that at the bladder neck and be sure you got it all out.

Dr. Webster: I think this one's interesting: Looking at the endoscopic image it is located at the side of the bladder neck (Fig. 4). It looks more like it was a trochar passage problem where they skived the edge of the bladder neck as they traversed it with the trochar rather than the customary problem that we see more often, which is the sling rising through the floor of the urethra almost as a gate either across the middle of the urethra or rising up from the floor of the urethra. I think that's either a tension problem or more likely I think it's a dissection problem.

Dr. McGuire: I think this is a dissection problem. It's an unusual place for a sling erosion. Usually they're posterior.

Dr. Cameron: Dr. McGuire, why do you think her incontinence is worse after the TOT?

Dr. McGuire: I think the tape does something to the urethral continence mechanism it's in it or it's around it and it doesn't work as well. So when you take the tape out and you look, they have gone from a simple types 1 or 2 incontinence to type 3 with ISD. They get worse.

Dr. Cameron: In this case, the tape was excised widely from the urethra and then the urethra was reconstructed. She was advised of the high risk of incontinence, but she simply wanted the tape removed due to overall poor health and did not want any abdominal or SP incision. Her incontinence actually improved somewhat, but she is still using heavy pads.

Do we have any other comments from the panel about managing this differently?

Dr. Blaivas: Yes. I see a fair number of these. I do what I call a radical slingectomy, and what that means is we get the tape

on either side of the urethra and just excise it as if it were a cancer, and that means we take a good bit of healthy urethra with it, and then at the same operation the urethra is reconstructed, a Martius flap is placed over the repair and an autologous rectus fascial sling is positioned over the Martius flap.

We haven't reported this data yet. We're putting it together now, and it's not a large series. We haven't had any fistulas, and virtually all of the patients have been cured or much improved with respect to continence. The most difficult to manage problems in these patients has been pelvic pain and overactive bladder.

Dr. Webster: I take the other end of the spectrum. I try to be as non-radical as possible actually and do as little further damage to the urethra as possible. So, like you, I do try and identify the sling on each side of the urethra because going for it in the middle you will actually cause further injury to the urethra. If you can identify the sling laterally on each side you can cut it on both sides and then peel it out. You'll end up then with a much cleaner posterior urethral defect, which I close with interrupted 5-0 Vicryls and get as many layers over as possible.

To inject a little of what I know will be controversial, I don't do a second sling at the same sitting, and I rarely put in a Martius flap unless there is just nothing to cover the defect with. I'd rather redeploy a flap of vaginal wall over the urethra so that when I come back for a second sling I am operating through more normal vaginal wall. Fortunately with mid-urethral slings done the way they are today, generally the injury is going to be quite localized and luckily the proximal third of the urethra is probably going to be okay.

So I most frequently still use a trochar delivered synthetic sling as my second procedure. Because the patient was snake bit with a synthetic sling one time, should one blame the synthetic material or could it be operator dissection error? Most times I think it is the latter and I therefore feel comfortable using a synthetic the second time providing I'm in a new location and tissues are healthy and I can get good vaginal wall cover.

Dr. Blaivas: I should have qualified what I said. Most of the patients that I'm talking about don't just have the sling erosion. They have the erosion and they have stress incontinence and they complain of pain. There are lots of components that we're treating other than just the stress incontinence. I often see patients that have already had one attempt at removing the sling. When you go back there are still strands of sling all over the place and they're getting recurring infections. If it was just a really simple straightforward case of only stress incontinence and no other problems, I might be more willing to do a more minimalist approach. But maybe not!

Dr. McGuire: It is an inexact science because where they're supposed to be, they may not be. You may find a mid-urethral retropubic sling up by the bladder neck. You may find a TOT where you don't expect it. If there's any doubt about where it is, you can find it with a transvaginal or perineal ultrasound. The tape lights up and it's a huge advantage.

We have 12 people in our series of 80 takedowns that supposedly had already had the sling removed and nine of them still had a perfectly intact sling. So someone had gone in, looked for it and couldn't, find it or mistakenly concluded that they must have cut it. You have to be absolutely sure to find it.

Dr. Webster: I think my series is the same. Twenty percent of our sling takedowns are already supposedly taken down and there's still an intact sling there.

CASE #6 PRESENTATION: URETEROSIGMOIDOSTOMIES AND RENAL FAILURE

Our next case is a 40-year-old patient with a history of bladder exstrophy. She underwent a cystectomy and bilateral ureterosigmoidostomies as a child. As an adult she has had a progressive increase in her creatinine up to 3.7 mg/dl, although she has remained off of dialysis. She is being evaluated for a living related renal transplantation and has a potential donor. She was referred for urologic evaluation due to pyelonephritis two to three times a year as well as recurrent nephrolithiasis. These are thought to be the causes of her chronic renal insufficiency.

As part of her urologic evaluation she underwent a CT scan, which showed a normal right kidney except for mild dilatation. However, the left kidney showed atrophy with a staghorn calculus. Her renal scan showed greater than 90 percent of her function on the right.

Dr. Cameron: Dr. Stöhrer, what other evaluations would you perform on this woman before deciding on a treatment plan?

Dr. Stöhrer: I think the most important thing is to make a scan of the kidneys to see the function, and if you see there's only 10 percent on one side with a staghorn and on the other side they are 90 percent, you should remove the kidney. I think 3.7 mg/dl for creatinine is not so bad. We could perhaps wait a little bit and see how her creatinine progresses. The recurrent infections may also improve after removing the left kidney.

Dr. Cameron: Since she is being worked up for a transplant, how would you manage her other than the nephrectomy? Would you do anything differently before her transplant?

Dr. Stöhrer: It's probably good to have a side which is clear for transplantation. If one does do anything, one should do it so as not to interfere with where the transplant will be placed.

Dr. Cameron: This woman had a sigmoidoscopy done by gastroenterology and had biopsies taken of her sigmoid colon.

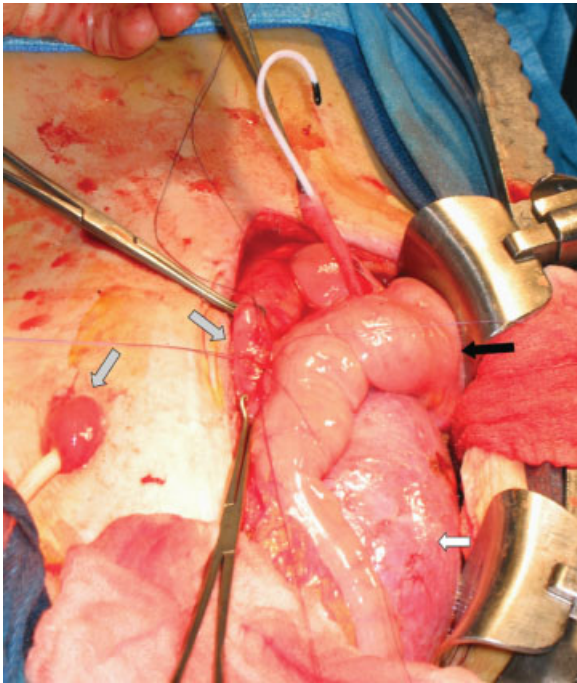


Fig. 5. Ileocecal pouch at time of renal transplant. Transplant kidney on left side (white arrow) before ureter (with stent in place) tunneled under sigmoid (black arrow) to the ileocecal pouch (grey arrows).

There was no dysplasia, and she then underwent a laparoscopic left-sided nephrectomy. Later her ureterosigmoidostomy was taken down. The ureters were taken off of the sigmoid colon with a small cuff of bowel resected with them. She had an ileocecal pouch created with the right native right ureter implanted into the ileocecal pouch to drain her urine. After waiting for a year with her creatinine remaining stable she underwent the transplant (Fig. 5). She never required dialysis.

Does the panel have anything to add to this case?

Dr. McGuire: No. I think that's the right thing to do. Take out the left kidney. Put the right kidney into the pouch to drain. That'll keep the pouch healthy while you wait for the transplant, and then the transplant should go into the pouch. That's a good solution because you can't put the transplant into the ureterosigmoidostomy. The question in my mind is, if you take the ureters out of the sigmoid, is the potential for malignant transformation completely gone because you do that or does it still stay there?

Dr. Webster: I think if you take the cuff with it, as they did, then it's gone.

Dr. McGuire: It should be gone.

Dr. Webster: I think this is a very elegant sequence of surgical events. It is also likely what I would do given the circumstances. However, one has to step back and accept it's a potentially morbid sequence of events. While the continent reservoir is a good potential receptacle for a transplant kidney, simpler might have been an appliance dependent ostomy carrying less morbidity with it than constructing the colon pouch, and I might have tried to persuade the patient that way, but on the other hand, she's 40 years old and she's accustomed to having no ostomy.

CASE #7 PRESENTATION: FEMALE BLADDER OUTLET OBSTRUCTION

This is a woman who has an anatomic bladder outlet obstruction. She is a 50-year-old woman who presented with a 2-week history of bloating, malaise, and some hypertension. She feels that she has not been emptying her bladder completely for the past several months. Otherwise, she is very healthy. She had a cystoscopy done at age 20 after a urine infection, and was told that it was normal.

She saw her primary care physician who palpated a 15 cm right lower quadrant abdominal mass. Blood work showed that her creatinine was 3.8 mg/dl where it had previously been 0.8 mg/dl.

She was sent to the emergency department by her primary care physician. In the emergency department, she was able to void and did so twice for a total of 600 mm. An ultrasound was performed and bilateral hydronephrosis was found, as well as this mass. The mass measured 15 by 10 cm. It was located in her pelvis and was found to have mural nodularity. A CT scan confirmed bilateral hydronephrosis and the pelvic mass with mural nodularity. The mass had septations and was complex (Fig. 6A and B).

Urology was then consulted because of the hydronephrosis and attempts were made to place a urethral catheter. The catheter was not able to be passed because of significant pain, but also because there seemed to be an obstruction in her urethra.

She underwent bilateral percutaneous nephrostomy tubes, and over the next 4 days while she was in the hospital her creatinine decreased to 1.4 mg/dl and her blood pressure returned to normal. Since she was now medically stable she was taken to the operating room. On examination under

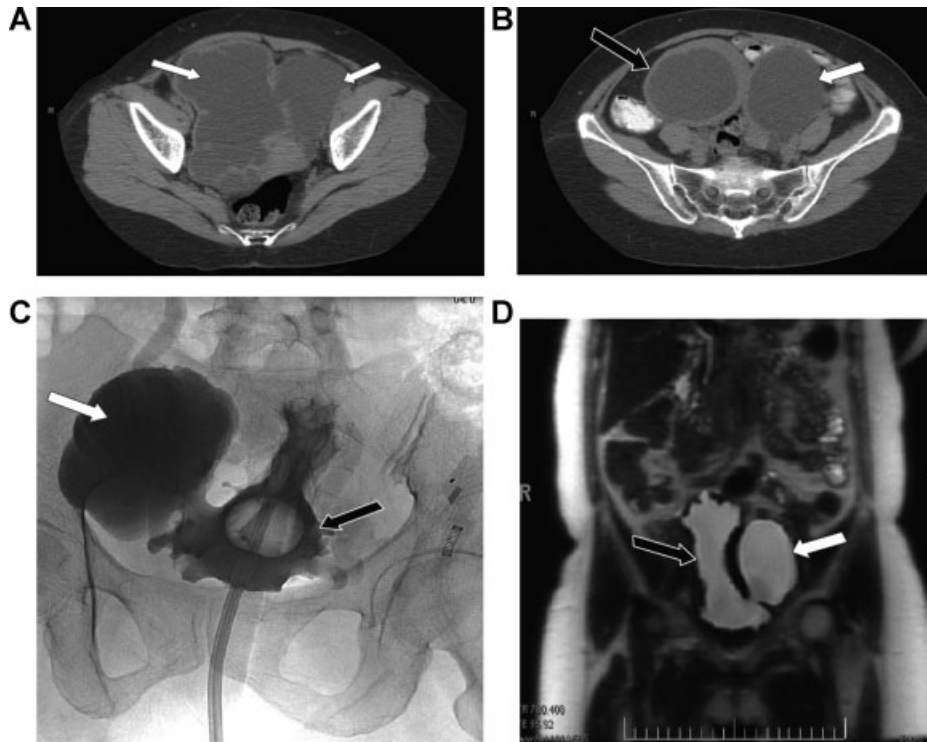


Fig. 6. Woman with bladder outlet obstruction. All white arrows indicate multiple bladder diverticula black arrows indicate bladder. A&B CT scan of pelvis, C cystogram, D MRI of pelvis.

anesthesia there was a membrane-like structure that required dilation. It was dilated up to 16 French and then a catheter was placed.

Her intra-op cystogram showed an interesting picture. One can see a huge diverticulum off of this central area of contrast, which is actually her bladder with the catheter in place (Fig. 6C). With a repeat filling there was also a large diverticulum seen on the other side.

After several weeks of catheter drainage she was brought back as an outpatient for urodynamic studies.

Dr. Cameron: This is a voiding phase of her urodynamic study. Here is her detrusor pressure. You can see her pressure goes up to 195 cm of water and her flow is very slow (Fig. 7). There is around 250 ml noted to be in her bladder after she voided, and on fluoroscopy there are diverticula seen on both sides.

Dr. Cameron: Dr. Blaivas, how would you manage her bladder with obstruction now? She has a catheter in place and she's seeing you in the clinic.

Dr. Blaivas: To just back up, you said that at the time of cystoscopy you saw this membrane kind of obstruction. I've seen about 10 patients with something like this and in all of them, at the time of cystoscopy, I couldn't be sure of what I was seeing. I was never really confident in any of my patients that I understood what was causing the obstruction. Some of them did have things that I thought was a membrane or a flap but in retrospect I thought that it might be due to a false passage.

So I'm not confident of the cystoscopic appearance in someone like this but if you use the word membrane, the first thing you think of is valves, and there have been very rare reports in girls with female valves. I'm not sure any of them

ever exist, but that's one possibility. I've never seen a female valve, though.

In my experience, there is a limited differential diagnosis: Primary bladder neck obstruction, urethral stricture or tumor and acquired voiding dysfunction. The bladder neck obstructions have been overtly obvious at videourodynamics—there is high voiding pressure and low flow and obstruction at the bladder neck on the voiding film. Further, bladder neck obstructions have not been difficult to catheterize. Treatment is straightforward—you cut the bladder neck (transurethral incision or resection) and they're better, but that's only a handful of patients—it's quite rare. Urethral strictures are rare as well unless there has been prior urethral surgery. In my experience, most have been at the mid urethra, but some are at the distal urethra. The mid-urethral obstructions have been all women between 30 and 45; the distal ones have been older women with severe atrophic vaginitis.

The first part of management is to have a clear understanding of the anatomy, and for that I would take advantage of the fact that I have a catheter in, and immediately upon taking the catheter out I would get another urodynamic study and see what anatomy I have now. If it is a bladder neck obstruction I would recommend surgical treatment as I previously described. If not, I would leave the catheter out and let her void on her own at home, and I would bring her back within a month. I would then check her flow rates at monthly intervals, and I would expect within a month or two the obstruction will recur. At the time of recurrence, we will do another videourodynamic study and based on that, we should be able to see exactly what the anatomy is. Depending upon what the anatomy is, that's how I would decide what to do next. I'd have her voiding and coming back very frequently

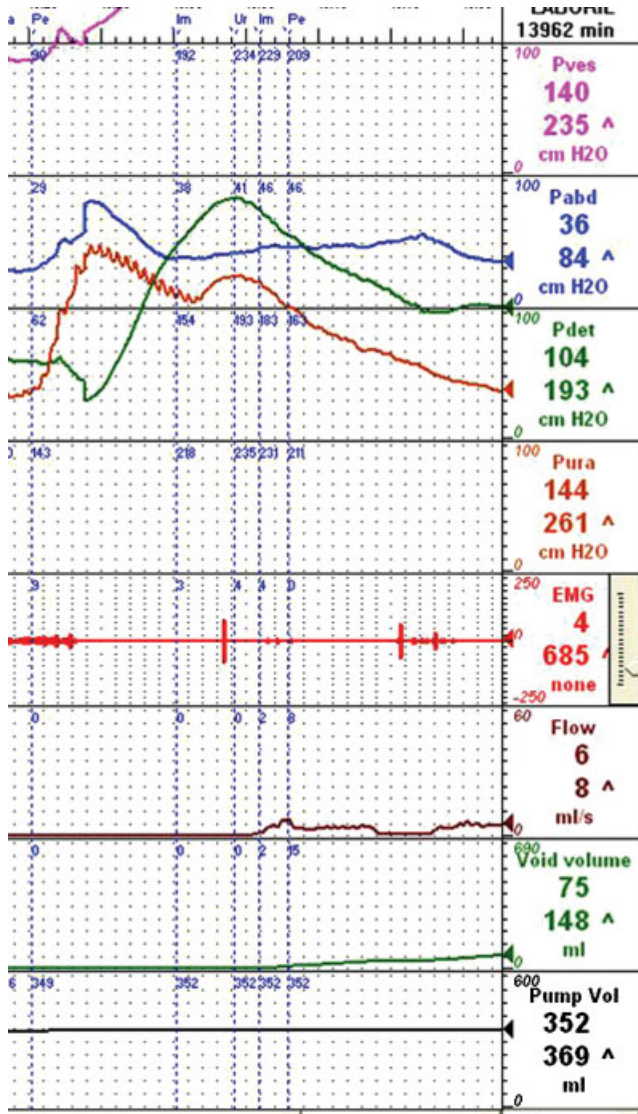


Fig. 7. Urodynamics tracing of voiding phase. Note detrusor pressure rise to 195 cm of water with a flow of 6 ml/sec at a volume of 362 ml.

for flow rates and if she's reporting she's having difficulty voiding, come back sooner for retesting.

Dr. Cameron: She had a spine X-ray to rule out any neurologic component to this and it was completely normal. She was started on clean intermittent catheterization and had a repeat urodynamics done 3 months later and she's still having these high pressure, low flow, voiding, and incomplete emptying.

Dr. Cameron: Dr. Blaivas, how do you define bladder outlet obstruction on a woman?

Dr. Blaivas: Almost everybody bases the diagnosis of obstruction in women and in men on high pressure and low flow, but there is some controversy about what the exact cutoff numbers are, but certainly this case with a detrusor pressure of 195 cm H₂O of water and a flow of 3 to 4 ml/sec is obstruction.

Most experts are in agreement that somewhere between 20 and 30 cm H₂O detrusor pressure associated with a low

flow in a woman is obstruction. We base this on a nomogram that Asnat Groutz, a brilliant urogynecologist from Israel, and I devised. It relates pressure and flow, but unlike previous nomograms, we think it's very important in women (and in men) to look at the unintubated flow as well because we think that the catheter and the act of voiding with a catheter has a variable effect on flow in these people. In some people, it doesn't affect them at all and they void the same with or without the catheter and then other people have a perfectly normal flow without a catheter and a very obstructed looking flow with the catheter.

So we use as our criteria the detrusor pressure at maximum flow with the urethral catheter in and we compare that to the best flow with or without a urethral catheter in place. These two numbers are plotted on the nomogram. But for everyday diagnosis, it's still high pressure and low flow and, you can use some of these cutoffs that we've talked about.

Dr. Cameron: Do any of the panel members have any comments?

Dr. Webster: May I go back to the case itself? The problem here is we're looking at things from the wrong side. We're cystoscoping going back in and we can't see an obstruction and the catheter goes back in and it doesn't hit any impediment and yet no urine comes out when she voids. So either she has profound pelvic floor problems, which I doubt, or she has a significant structural obstruction. This is a long-standing problem based on the appearance of her bladder and the diverticula. What kind of structural obstructions could we have? We need to look at it from the other side.

I've had two cases that were variations on this theme where I eventually performed antegrade endoscopy with a flexible cystoscope. One turned out to be a periurethral diverticulum in the era before we regularly did MRIs. The scope went down through the bladder neck into a blind pocket, and a catheter came up from below through a flap on the side of it, and her problem was related to this diverticulum.

Now, this is too chronic, I think, for that diagnosis, but what this experience does tell me is I would do an MRI of the urethra and I would consider antegrade endoscopy to see just where the structural obstruction is. It may not help you, but it seems that stone is still left unturned.

Dr. Blaivas: I think certainly the MRI is a good idea. When I said we'd do a voiding cystogram it would be just part of the urodynamics. Cystourethrogram in our experience discloses most but not all urethral diverticula. Was she to get worse, we'd have a clearer understanding of where the obstruction is, and an MRI would be helpful if you think there's an extrinsic obstruction, but sometimes we see a stricture. About half of the people ended up having a stricture. Whether the stricture was caused by the catheterization in the first place to undo whatever the obstruction was, I don't know, but half of my patients do end up with mid urethral strictures.

Dr. Cameron: She did have an MRI. It showed a bladder diverticulum, but her urethra looked normal (Fig. 6D).

Dr. Webster: I would say the vast majority of the women referred to us as urethral strictures turn out to have pelvic floor dysfunction and behavioral voiding disorders although this has more the appearance of neurogenic phenomena if there's no identifiable structural abnormality.

Dr. Cameron: So, Dr. Blaivas, do you think her voiding function will ever return to normal?

Dr. Blaivas: If you remove the obstruction, I think there's a very good chance it will—almost for sure. Again, the concept

of following her sequentially after treating the obstruction is very important.

Dr. Cameron: This woman had very large bladder diverticula. Would you try to excise these to improve her bladder function and emptying?

Dr. Blaivas: Perhaps, but not until you've resolved the other concerns. First and foremost, you must settle the issue of the urethral obstruction. She's clearly obstructed, and I wouldn't do anything about the diverticulum or even consider

that until such time as I'm confident that I've fixed the obstruction.

ACKNOWLEDGMENTS

We thank Dr. J. Quentin Clemens and Dr. Julian Wan for their assistance in preparing this panel and for submitting cases, we would also like to thank Dr. John Park and Dr. Humphrey Atiemo for submitting cases.