

---

**HPV-POSITIVE/P16-POSITIVE/EBV-NEGATIVE  
NASOPHARYNGEAL CARCINOMA IN WHITE  
NORTH AMERICANS**

Jessica H. Maxwell, MD, MPH,<sup>1,2</sup> Bhavna Kumar, MS,<sup>3,4</sup> Felix Y. Feng, MD,<sup>5</sup>  
Jonathan B. McHugh, MD,<sup>6</sup> Kitrina G. Cordell, DDS,<sup>6,7</sup> Avraham Eisbruch, MD,<sup>5</sup>  
Francis P. Worden, MD,<sup>8</sup> Gregory T. Wolf, MD,<sup>2</sup> Mark E. Prince, MD,<sup>3</sup> Jeffrey S. Moyer, MD,<sup>3</sup>  
Theodoros N. Teknos, MD,<sup>3,4</sup> Douglas B. Chepeha, MD,<sup>3</sup> Jay Stoerker, PhD,<sup>9</sup>  
Heather Walline, MA,<sup>9</sup> Thomas E. Carey, PhD,<sup>3,10</sup> Carol R. Bradford, MD<sup>3</sup>

<sup>1</sup>University of Michigan Medical School, The University of Michigan Health System and Comprehensive Cancer Center, Ann Arbor, MI

<sup>2</sup>Department of Otolaryngology/Head and Neck Surgery, University of Pittsburgh Medical Center, Pittsburgh, PA

<sup>3</sup>Departments of Otolaryngology–Head and Neck Surgery, The University of Michigan Health System and Comprehensive Cancer Center, Ann Arbor, MI. E-mail: careyte@umich.edu

<sup>4</sup>Department of Otolaryngology/Head and Neck Surgery, Ohio State University, Columbus, OH

<sup>5</sup>Radiation Oncology, The University of Michigan Health System and Comprehensive Cancer Center, Ann Arbor, MI

<sup>6</sup>Pathology, The University of Michigan Health System and Comprehensive Cancer Center, Ann Arbor, MI

<sup>7</sup>Periodontics and Oral Medicine, The University of Michigan Health System and Comprehensive Cancer Center, Ann Arbor, MI

<sup>8</sup>Internal Medicine, The University of Michigan Health System and Comprehensive Cancer Center, Ann Arbor, MI

<sup>9</sup>SensiGen, LLC, Ann Arbor, MI; Sequenom, Inc, San Diego, CA

<sup>10</sup>Pharmacology, The University of Michigan Health System and Comprehensive Cancer Center, Ann Arbor, MI

*Accepted 17 June 2009*

*Published online 15 September 2009 in Wiley InterScience (www.interscience.wiley.com). DOI: 10.1002/hed.21216*

---

*Correspondence to:* T. E. Carey

This study was supported by Grants No. R01 DE13346 from the National Institutes of Health (NIH) NIDCR, P30 DC 05188 from the NIH NIDCD, and R01 CA83087 from the NIH National Cancer Institute; Head and Neck Cancer SPORE Grant No. P50 CA97248 from the NIH-NCI NIDCR; NCI National Cancer Center Support Grant No. P30 CA46592 and Grant No. MEDC-410, and Loan No. MEDC-239 (to SensiGen LLC) from the state of Michigan.

The authors Jay Stoerker, Heather Walline, and Thomas E. Carey have a conflict of interest. Jay Stoerker and Heather Walline are employed with the Sequenom Center for Molecular Medicine; Thomas E. Carey serves as the member of the Sequenom Clinical Advisory Board and presented some of the work to a group of Sequenom officials and other researchers and received a honorarium of \$1000 and reimbursement for travel.

© 2009 Wiley Periodicals, Inc.

**Abstract:** *Background.* Human papillomavirus (HPV) has been detected in keratinizing nasopharyngeal carcinomas (NPCs); however, the relationship between HPV and Epstein–Barr virus (EBV) among whites with nonkeratinizing NPCs remains unclear. The HPV, p16, and EBV status was examined in current University of Michigan patients with NPC.

*Methods.* From 2003 to 2007, 89 patients, 84 with oropharyngeal cancer (OPC) and 5 with NPC, were enrolled in an organ-sparing trial. Biopsy tissues from all 89 patients were evaluated for HPV and p16 expression. A separate HPV analysis of the 84 OPC patients is in progress. Among the patients with NPC, tumor tissue was also analyzed for EBV-encoded RNA (EBER).

*Results.* Five of 89 patients (5.6%) had NPC, all with nonkeratinizing histology. The 4 white patients with NPC were HPV(+) (subtype-16, subtype-18 [2 patients], and subtype-59)/p16(+)/EBER(-). One Asian patient with NPC had an HPV(-)/p16(-)/EBER(+) NPC tumor that developed distant metastases.

*Conclusion.* We postulate that HPV may be the etiologic factor in some EBV-negative, nonkeratinizing NPCs among whites. © 2009 Wiley Periodicals, Inc. *Head Neck* 32: 562–567, 2010

**Keywords:** nasopharyngeal carcinoma; human papillomavirus; Epstein-Barr virus; white North Americans

**N**asopharyngeal carcinoma (NPC) is a rare disease in the United States, with an incidence rate of less than 1 per 100,000.<sup>1–3</sup> However, NPC occurs much more frequently in certain parts of the world, notably in Southern China with a reported incidence of 15 to 30 per 100,000 among men and women in Hong Kong.<sup>3</sup> Interestingly, the incidence of NPC remains higher among Chinese people who immigrated to North America than Chinese people who were born in North America.<sup>4</sup> Thus, the etiology of NPC is multifactorial, including environmental factors, genetics, and infectious agents, particularly the Epstein–Barr virus (EBV).<sup>1,3</sup> In the United States, the overall 5-year survival is approximately 60%<sup>5</sup> with an annually declining mortality rate of 4.1%<sup>6</sup> among whites. The reasons for this decline in mortality are unclear, but may be attributable to novel treatments or changes in the etiology of NPC in the United States.

NPC is classified by the World Health Organization (WHO) according to histologic subtype. Type I (WHO-I NPC) is characterized by keratinizing, well-differentiated tumor cells; whereas type II (WHO-II NPC) is characterized by nonkeratinizing, differentiated tumor cells. Type III (WHO-III NPC) denotes nonkeratinizing, undifferentiated carcinoma (so-called lymphoepitheliomas) and represents 63% to 95% of NPC tumors worldwide.<sup>3</sup> Some investigators have detected human papillomavirus (HPV) in NPCs,<sup>7–10</sup> particularly in the keratinizing WHO-I NPC type.<sup>7,11,12</sup> However,

the role of HPV in WHO-II and WHO-III NPC is less understood. Although HPV is less commonly found in WHO-II or WHO-III NPCs, coinfection with HPV and EBV has been reported in these nonkeratinizing NPC types.<sup>7–10</sup> Isolated HPV infection among EBV-negative nonkeratinizing, WHO-II or WHO-III, NPC has not been reported in the white North American populations.

Given the rarity of NPC in the United States, there are few studies investigating its relationship to HPV and EBV in this area.<sup>7,8</sup> In patients from the United States, HPV has been detected in up to 73% of those with tonsillar cancer<sup>13</sup> and has been implicated in the rising incidence of oropharyngeal cancers.<sup>14–17</sup> In a recent clinical trial for patients with oropharyngeal cancers and NPC, all of the tumor specimens were examined for the presence of high-risk HPV. There were 5 patients with NPC included in the trial. The purpose of this study was to examine the HPV, p16, and EBV status among all 5 patients with NPC included in this trial.

## MATERIALS AND METHODS

Eighty-nine patients with previously untreated, advanced (stage III and IV) oropharyngeal and nasopharyngeal squamous cell carcinoma who presented to the University of Michigan from 2003 through 2007 were enrolled in an organ-sparing trial. All provided written informed consent and participated in the University of Michigan Head and Neck SPORE program which was approved by the Institutional Review Board of the University of Michigan. The patients were treated with concomitant carboplatin, docetaxel, and intensity-modulated radiation therapy (IMRT). A tissue microarray (TMA) was constructed from pretreatment biopsies of primary tumor sites for all 89 patients. All biopsies contained sufficient tumor for a core sample to be taken for DNA extraction and HPV analysis. HPV type and copy number were assessed with a sensitive, specific, quantitative method<sup>18</sup> by SensiGen LLC of Ann Arbor, MI. In brief, HPV analysis involved multiplex competitive polymerase chain reaction and matrix-assisted laser desorption/ionization-time of flight mass spectroscopy separation of products on a matrix-loaded silicon chip array. This method uses primers designed to amplify the E6 region to detect and quantify 15 high-risk HPV types 16, 18, 31, 33, 35, 39, 45, 51, 52, 56, 58, 59, 66, 68, and 73 as well as low-risk types 6 and 11.<sup>18,19</sup> A complete analysis of the

**Table 1.** Information on patients with nasopharyngeal carcinoma.

Patient no.	Race or ethnicity	Age	TNM classification	WHO type/ differentiation	Tobacco history/ pack-years	HPV/ subtype	P16 expression	EBER
1	White	58	T3N2cM0	II/NK SCC, differentiated	Current/34	Positive/16	Positive	Negative
2	White	75	T4N2cM0	III/NK SCC, undifferentiated	Former pipe for 23 years	Positive/18	Positive	Negative
3	White	76	T4N0M0	III/NK SCC, undifferentiated	Never/0	Positive/59	Positive	Negative
4	White	58	T2bN2M0	II/NK SCC, differentiated	Former/20	Positive/18	Positive	Negative
5	Asian	50	T4N2cM1	III/NK SCC, undifferentiated	Never/0	Negative	Negative	Positive

Abbreviations: WHO, World Health Organization; HPV, human papillomavirus; EBER, Epstein-Barr virus encoded RNA in situ hybridization; NK, non-keratinizing; SCC, squamous cell carcinoma.

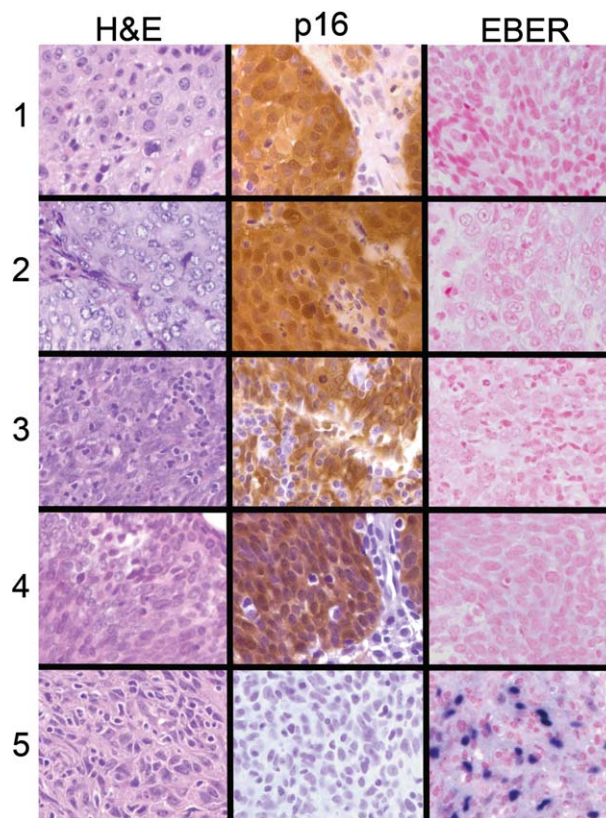
HPV data and patient outcome for the 84 patients with oropharyngeal cancer is in progress.

During analysis, it was determined that among the 5 NPC patients, 4 were positive for HPV. To follow up this observation, the charts of these 5 patients were reviewed for date of initial diagnosis, tumor stage, tumor location, WHO grade, evidence of local recurrence, and distant metastases through the most recent follow-up. All 5 patients were confirmed to have primary tumors originating high in the nasopharynx. Tissue sections from the NPC patients were analyzed in the pathology department for histology and degree of differentiation, p16 (CDKN2A) expression by immunohistochemistry and for EBV encoded RNA (EBER) using in situ hybridization. In situ hybridization for EBER (Ventana INFORM EBER, Tucson, AZ) was performed on all cases according to the manufacturer's protocol on the Bench-Mark automated system.<sup>20</sup> EBER staining was scored as positive or negative. The CDKN2A protein, p16, is often used as a surrogate for HPV infection because the HPV oncoprotein, E7, binds to the retinoblastoma protein releasing the transcription factor E2F which upregulates p16, leading to its overexpression. P16 antibody (Biocare Medical, Concord, CA; dilution 1:200) binding was scored for proportion and intensity of tumor cell staining (cytoplasmic and nuclear) by a pathologist (J.B.M.) on a scale of 1 to 4: 1 was less than 5%; 2, 5% to 20%; 3, 21% to 50%; and 4, 51% to 100% tumor staining. Intensity of p16 expression was scored as 1 equal to no staining; 2, low intensity; 3, moderate; and 4, high intensity. Proportion and intensity scores were added to give a total staining score.

## RESULTS

Of the 89 patients enrolled in the organ-sparing trial, 75 (84.3%) were HPV-positive; of those, 65

(65/75; 86.7%) had HPV-16, 4 had HPV-18 (5.3%), 3 had HPV-35 (4%), and 1 had HPV-59 (1.3%). Of the 5 patients with NPC, 4 (80%) were HPV-positive. This manuscript focuses only on those NPC cases. The clinical characteristics of the 5 NPC patients are depicted in Table 1. Among the 4 patients with HPV-positive NPC, 1 had HPV-16, 2 had HPV-18, and 1 had HPV-59 in their tumors (Table 1). All 4 HPV-positive NPCs stained positive (high intensity and high proportion; total staining score = 8) for p16, and all 4 were negative for EBER (Figure 1).



**FIGURE 1.** Histologic sections ( $\times 400$ ) of NPC tumors from patients 1–5 (corresponds to Table 1). (Left panel) Hematoxylin-Eosin (H&E)-stained sections. (Center panel) p16-stained sections. (Right panel) In situ hybridization for Epstein-Barr virus encoded RNA (EBER).

All of these 4 patients with HPV(+)/p-16(+)/EBER(-) NPC were white North Americans. The remaining patient with NPC was from Korea, and her tumor tissue was negative for HPV and p16, but positive for EBER (Table 1, Figure 1) and had high EBV titers (1500 EBV DNA copies/mL plasma) at the time of primary diagnosis (not shown).

All 5 patients with NPC achieved an initial complete response with carboplatin, docetaxel, and concurrent IMRT. Referring to Table 1, the HPV-16–positive patient with WHO-II NPC (patient no. 1) recently developed recurrence at the primary site after approximately 5 years and is alive at 5.4 years following primary diagnosis. The HPV-18–positive patient with WHO-III NPC (patient no. 2) is alive without disease 4.3 years after primary diagnosis. The patient with HPV-59–positive WHO-III NPC (patient no. 3) is alive without disease 5.8 years after primary diagnosis. The other patient with HPV-18–positive WHO-II NPC (patient no. 4) is also alive without disease 1.4 years following primary diagnosis. The Asian patient with HPV(-)/p16(-)/EBER(+) WHO-III NPC (patient no. 5) developed lung metastases after approximately 2 years (24.6 months) and was alive at last follow-up 2.6 years after primary diagnosis.

## DISCUSSION

The etiology of NPC in white populations remains largely unknown. Although EBV is considered to be the primary etiologic factor for NPC, particularly WHO-II and WHO-III disease, NPCs are occasionally EBV-negative.<sup>7-9</sup> This has contributed to the investigation of other potential etiologic agents for NPC, such as HPV. The recent observation that oropharyngeal cancers are frequently positive for HPV<sup>13,21,22</sup> is linked to the presence of lymphoid tissue at these sites. Since HPV has a proclivity for the epithelium overlying the lymphoid tissue of the lower portions of Waldeyer's ring, it is plausible that the upper components of the ring—the faucial tonsils and adenoids—also provide a site for HPV-induced cancer of the nasopharynx.

To the best of our knowledge, this is the first clinical report of HPV-positive/EBV-negative NPCs of nonkeratinizing (WHO-II or WHO-III) histologic subtype among white patients in the United States. Two prior studies have investigated NPC in patients from the United States.<sup>7,8</sup> One study by Punwaney et al<sup>7</sup> investi-

gated HPV and EBV in NPCs from 7 North American patients; 6 white Americans, and 1 Chinese American. They found that among the 6 white Americans, 4 had WHO-II or WHO-III NPC, all of which were EBV-positive (2 were coinfecting with HPV and 2 were negative for HPV). Among the 2 white Americans with keratinizing (WHO-I) NPC, there was 1 HPV-positive/EBV-negative case. None of our patients had WHO-I NPC; all 5 had WHO-II or WHO-III NPC.

In another study by Rassekh et al<sup>8</sup> from the University of Texas, the HPV and EBV status of 17 patients (7 WHO-III and 10 WHO-I) was investigated; however, the patients' ethnicities were not reported. Nine patients (9/17; 52.9%) were HPV-positive—5 WHO-III patients and 4 WHO-I patients. All patients with HPV-positive NPC were coinfecting with EBV, including the 5 patients with HPV-positive WHO-III NPC. Because of the high degree of HPV and EBV coexistence among both keratinizing and nonkeratinizing NPC types, it was suggested that EBV infection may facilitate HPV infection.<sup>8</sup> This suggestion is not supported by our results, given that there was no HPV and EBV coinfection among the 5 NPC patients in our cohort.

In fact, our limited results raise the possibility that HPV may act alone as an etiologic factor in at least a subset of NPCs. However, given the rare occurrence of NPC in our patient population and in the United States as a whole, no definitive conclusions about viral etiology can be drawn from this report. For example, it cannot be excluded that HPV could be a benign infection, noncontributory to the development or progression of NPC. Smoking is a possible etiologic factor in 3 cases, but patient no. 3 and patient no. 5 were never smokers. It could also be suggested that these cases might be true oropharyngeal neoplasms, misdiagnosed as NPC. However, we reviewed the charts for every patient and all had primary tumors originating high in the nasopharynx; therefore, misdiagnosis is unlikely.

HPV-59 is genetically related to high-risk HPV types 18 and 45. Although it is an uncommon HPV type, it is categorized as high-risk, ie, an oncogenic HPV type, along with HPV types 16, 18, 31, 45, and at least 9 other high-risk types. A meta-analysis by Munoz et al<sup>23</sup> pooled data from 11 case-control studies involving nearly 2000 women with SCC of the cervix and

nearly 2000 control women. Based on its association with cervical cancer, HPV-59 was identified as a high-risk HPV type. Furthermore, HPV-59 isolated from a patient with condyloma accuminata was shown to be capable of transforming normal human foreskin keratinocytes and producing virus in vitro.<sup>24</sup> The transformed cells eventually lost most of the episomal copies and cells with approximately 2 copies of integrated HPV-59 persisted.<sup>25</sup> Because viral integration is a common finding in HPV-positive human cancers, this observation further supports the assignment of HPV-59 to the high-risk category. Of interest, patient no. 3 in our cohort who was HPV-59 positive was a non-smoker, leaving HPV-59 as a likely factor in his disease.

The properties of HPV-positive oropharyngeal cancers that lead to high response to treatment<sup>19</sup> and good survival<sup>21</sup> may similarly affect the prognosis of patients with HPV-positive NPC. The 4 patients with HPV-positive NPC in our cohort had very advanced disease, yet all responded well to treatment, although 1 had a local recurrence at 5 years (patient no. 1). Of note, this patient remained a current smoker. The patient of Asian descent (patient no. 5) with HPV(-)/p16(-)/EBER(+) NPC developed distant metastases after 2 years. The declining mortality rate from NPC among whites in the United States,<sup>6</sup> while not dramatic, is nonetheless interesting. This could be due to advances in treatment modalities, such as the use of IMRT, or if HPV is an emerging etiologic factor in NPC among whites, then these tumors as a group may be more responsive to treatment than the EBV-induced tumors.

Our data and other published studies<sup>7,8</sup> raise the hypothesis that HPV is a possible etiologic factor in white North Americans who develop NPC. Due to the relative paucity of NPC cases at any one institution in the United States, it would be of interest to carry out a multi-centered trial to determine the true incidence of high-risk HPV involvement in this disease entity. In a multi-centered trial it may be possible to determine if HPV-induced NPC is more or less responsive to current treatments than those induced by EBV. Epidemiology studies would also be of interest to determine if the incidence of HPV-positive NPC is increasing in concert with the increased frequency of HPV-positive oropharyngeal cancers.

**Note added in Proof:** An additional white male patient with advanced NPC presented to our clinic since this paper was accepted for publication. This patient's tumor is HPV(+)/p16(+)/EBER(-), raising our total to 5 HPV(+)/EBER(-) NPC cases within the past 6 years.

## REFERENCES

1. Chang ET, Adami HO. The enigmatic epidemiology of nasopharyngeal carcinoma. *Cancer Epidemiol Biomarkers Prev* 2006;15:1765-1777.
2. Parkin DM, Bray F, Ferlay J, Pisani P. Global cancer statistics, 2002. *CA Cancer J Clin* 2005;55:74-108.
3. Wei WI, Sham JS. Nasopharyngeal carcinoma. *Lancet* 2005;365:2041-2054.
4. Dickson RI, Flores AD. Nasopharyngeal carcinoma: an evaluation of 134 patients treated between 1971-1980. *Laryngoscope* 1985;95:276-283.
5. SEER Cancer Statistics Review - Table I-4: Age-adjusted SEER incidence and U.S. death rates and 5-year relative survival rates by primary cancer site, sex and time period all races; Survival (1996-2004). In: SEER Cancer Statistics Review 1975-2005; National Cancer Institute.
6. SEER Cancer Statistics Review - Table I-8: SEER Incidence and U.S. Mortality Trends by Primary Cancer Site and Sex, Whites 1996-2005, U.S. Mortality, APC. In: SEER Cancer Statistics Review 1975-2005; National Cancer Institute.
7. Punwaney R, Brandwein MS, Zhang DY, et al. Human papillomavirus may be common within nasopharyngeal carcinoma of Caucasian Americans: investigation of Epstein-Barr virus and human papillomavirus in eastern and western nasopharyngeal carcinoma using ligation-dependent polymerase chain reaction. *Head Neck* 1999;21:21-29.
8. Rassekh CH, Rady PL, Arany I, et al. Combined Epstein-Barr virus and human papillomavirus infection in nasopharyngeal carcinoma. *Laryngoscope* 1998;108:362-367.
9. Tung YC, Lin KH, Chu PY, Hsu CC, Kuo WR. Detection of human papilloma virus and Epstein-Barr virus DNA in nasopharyngeal carcinoma by polymerase chain reaction. *Kaohsiung J Med Sci* 1999;15:256-262.
10. Tyan YS, Liu ST, Ong WR, Chen ML, Shu CH, Chang YS. Detection of Epstein-Barr virus and human papillomavirus in head and neck tumors. *J Clin Microbiol* 1993;31:53-56.
11. Giannoudis A, Ergazaki M, Segas J, et al. Detection of Epstein-Barr virus and human papillomavirus in nasopharyngeal carcinoma by the polymerase chain reaction technique. *Cancer Lett* 1995;89:177-181.
12. Hørding U, Nielsen HW, Daugaard S, Albeck H. Human papillomavirus types 11 and 16 detected in nasopharyngeal carcinomas by the polymerase chain reaction. *Laryngoscope* 1994;104(1 Pt 1):99-102.
13. Kim SH, Koo BS, Kang S, et al. HPV integration begins in the tonsillar crypt and leads to the alteration of p16, EGFR and c-myc during tumor formation. *Int J Cancer* 2007;120:1418-1425.
14. Fakhry C, Gillison ML. Clinical implications of human papillomavirus in head and neck cancers. *J Clin Oncol* 2006;24:2606-2611.
15. Ringström E, Peters E, Hasegawa M, Posner M, Liu M, Kelsey KT. Human papillomavirus type 16 and squamous cell carcinoma of the head and neck. *Clin Cancer Res* 2002;8:3187-3192.

16. Sturgis EM, Cinciripini PM. Trends in head and neck cancer incidence in relation to smoking prevalence: an emerging epidemic of human papillomavirus-associated cancers? *Cancer* 2007;110:1429–1435.
17. Tran N, Rose BR, O'Brien CJ. Role of human papillomavirus in the etiology of head and neck cancer. *Head Neck* 2007;29:64–70.
18. Yang H, Yang K, Khafagi A, et al. Sensitive detection of human papillomavirus in cervical, head/neck, and schistosomiasis-associated bladder malignancies. *Proc Natl Acad Sci U S A* 2005;102:7683–7688.
19. Worden FP, Kumar B, Lee JS, et al. Chemoselection as a strategy for organ preservation in advanced oropharynx cancer: response and survival positively associated with HPV16 copy number. *J Clin Oncol* 2008;26:3138–3146.
20. Franchi A, Moroni M, Massi D, Paglierani M, Santucci M. Sinonasal undifferentiated carcinoma, nasopharyngeal-type undifferentiated carcinoma, and keratinizing and nonkeratinizing squamous cell carcinoma express different cytokeratin patterns. *Am J Surg Pathol* 2002;26:1597–1604.
21. Gillison ML, Koch WM, Capone RB, et al. Evidence for a causal association between human papillomavirus and a subset of head and neck cancers. *J Natl Cancer Inst* 2000;92:709–720.
22. Kumar B, Cordell KG, Lee JS, et al. EGFR, p16, HPV Titer, Bcl-xL and p53, sex, and smoking as indicators of response to therapy and survival in oropharyngeal cancer. *J Clin Oncol* 2008;26:3128–3137.
23. Muñoz N, Bosch FX, de Sanjosé S, et al. Epidemiologic classification of human papillomavirus types associated with cervical cancer. *N Engl J Med* 2003;348:518–527.
24. Lehr EE, Qadadri B, Brown CR, Brown DR. Human papillomavirus type 59 immortalized keratinocytes express late viral proteins and infectious virus after calcium stimulation. *Virology* 2003;314:562–571.
25. Spartz H, Lehr E, Zhang B, Roman A, Brown DR. Progression from productive infection to integration and oncogenic transformation in human papillomavirus type 59-immortalized foreskin keratinocytes. *Virology* 2005;336:11–25.