

Concomitant Use of a High-Energy Pulsed CO₂ Laser and a Long-Pulsed (810 nm) Diode Laser for Squamous Cell Carcinoma in Situ

DARRELL J. FADER, MD*[†] AND LORI LOWE, MD*[‡]

Departments of *Dermatology, [†]Otolaryngology, and [‡]Pathology, University of Michigan Medical Center and University of Michigan Comprehensive Cancer Center, Ann Arbor, Michigan

Case Reports

Patient 1 is a 70-year-old woman that presented with a biopsy-proven lesion of Bowen's disease [squamous cell carcinoma (SCC) in situ] on the left arm. She was 17 years status post-renal transplantation for which she was taking imuran and prednisone. She recently had a lentigo maligna excised from her cheek. Physical examination revealed a 3 cm × 3 cm mildly hyperkeratotic pink/red plaque on the left dorsal arm. Multiple fine black hairs were noted on her arm, including those within the lesion.

Patient 2 is a 78-year-old man that presented with a biopsy-proven lesion of Bowen's disease on the left arm. His past medical history was significant for multiple facial basal cell carcinomas (BCCs). Physical examination revealed a 3.5 cm × 4 cm red plaque on the volar surface of the left forearm against a background of dark brown hairs.

Patient 3 is a 71-year-old man that presented with a biopsy-proven lesion of Bowen's disease on the midchest. His past medical history was unremarkable. Physical examination revealed a 2.5 cm × 2.5 cm inflamed red plaque on the midchest with multiple, predominantly black hairs emanating from it and the surrounding skin (Figure 1).

Each patient was considered for Mohs micrographic surgery versus wide local excision of the Bowen's disease. Due to a lesion size and a lesion location at risk for hosting a hypertrophic scar (patient 3), a less invasive modality—CO₂ laser resurfacing—was discussed. Each lesion occurred in a hair-bearing region, however, which raised concerns regarding treatment efficacy because of the possibility of follicular epithelial extension of Bowen's disease too deep for the CO₂ laser to destroy.

D.J. Fader, MD and L. Lowe, MD have indicated no significant interest with commercial supporters.

Address correspondence and reprint requests to: D.J. Fader, MD, Skin Cancer Clinic of Seattle, Inc., 1801 NW Market St., Suite 107, Seattle, WA 98109.

Therapeutic Challenge

We sought a method to optimize the cure rate in the laser treatment of in situ SCC in hair-bearing skin.

Solution

Each lesion was treated with three passes of the CO₂ laser utilizing a 3 mm handpiece at 500 mJ. A surrounding 5 mm margin was included in the laser treatment field. Immediately thereafter a diode laser was used as a final pass at 60 J/cm², a 30-msec pulse duration, and a 9 mm × 9 mm spot size. Four millimeter punch biopsy specimens were obtained before laser treatment, immediately after, 2 weeks, and 2 months postoperatively and sent for routine histologic examination.

Preoperative biopsies revealed full-thickness epidermal atypia and focal areas of follicular extension consistent with Bowen's disease. Skin biopsies obtained immediately following the dual laser regimen demonstrated that CO₂ laser-induced epidermal ablation was evident. In addition, deeper ablation of follicular epithelium was demonstrated, at times extending down to the hair bulb near the subcutaneous tissue. These follicular sites of thermal necrosis could not be accounted for by the CO₂ laser and were likely caused by the diode system. By 2 weeks postoperatively, epidermal and follicular epithelium were restored and maintained at 2 months (Figure 2). There was no clinical evidence of Bowen's diseases recurrence at 4 months. All sites healed uneventfully.

Discussion

Traditional modalities to treat in situ SCC, including electrodesiccation and curettage, excision, radiation, and cryotherapy, all have various cure rates and aesthetic outcomes. Although Mohs micrographic surgery attains a high cure rate while minimizing the excision size, large repairs for wide superficial defects may still prove necessary. Continuous wave CO₂ laser tech-

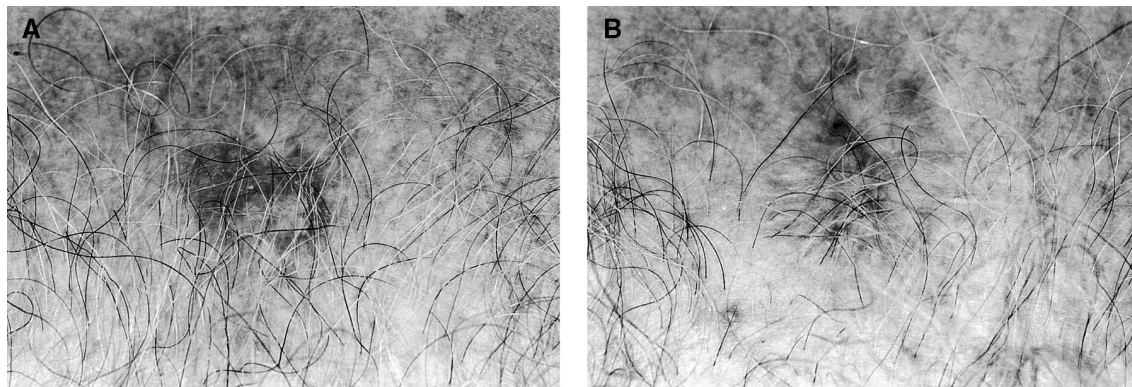


Figure 1. A) Bowen's disease on the midchest with multiple hairs extending from it and the surrounding skin. B) Four months after CO₂ and diode laser ablation. Erythema is fading, hair growth has resumed, with no evidence of persistent or current disease to date.

nology of the 1980s and early 1990s provided another approach to manage superficial BCCs and in situ processes, such as actinic cheilitis and Bowen's disease.¹⁻⁶ Tissue charring from extreme laser heating, however, results in unacceptable cosmetic outcomes since thermal injury extends beyond the intended target.⁷⁻⁹

High-energy, short-pulsed CO₂ laser technologies have been able to achieve vaporization with narrower zones of thermal damage, providing a risk-benefit ratio favorable enough to fuel the aesthetic resurfacing explosion in recent years.¹⁰⁻¹² Case reports utilizing high-energy, short-pulsed CO₂ lasers to treat in situ SCC and superficial BCC suggest that lesions confined to the epidermis and papillary dermis might be effectively removed in a cosmetically acceptable manner.^{13,14}

Humphreys et al.¹⁵ investigated the use of a high-energy, short-pulsed CO₂ laser to ablate superficial BCCs and in situ SCCs. Thirty neoplasms were treated with a pulsed CO₂ laser using 3 mm margins and either two or three passes. Each neoplasm was then immediately excised. Histologic assessment confirmed complete ablation of superficial BCCs with three passes, corresponding to laser damage to the upper reticular dermis. Persistent in situ SCC was seen at the deep margins in three of seven patients treated with three passes. Lesions treated with only two passes showed higher rates of incomplete removal at the deep margins for both BCC and Bowen's disease. One BCC and three in situ SCC specimens in their study maintained positive peripheral margins after laser treatment. It was concluded that while three laser passes may be an effective modality for treating superficial BCCs, in situ SCCs were variably responsive. Residual in situ SCC disease was associated with lesions that were hyperplastic, hyperkeratotic, or demonstrated follicular extension.

In all of our cases the in situ SCC lesions were minimally hyperkeratotic, yet all were situated on hair-

bearing surfaces. Given the propensity for Bowen's disease to extend into the follicular infundibula,¹⁶ we were concerned about the recurrence rate following CO₂ laser ablation alone.

Laser-assisted hair removal has rapidly gained popularity over the last several years and now includes a variety of technologies from solid crystal systems (ruby, alexandrite, Nd:YAG) to diode and intense pulsed light sources.¹⁷ Laser hair ablation utilizes dark terminal hair as the chromophore to rupture the follicular unit. Heat is generated in the hair shaft which is transmitted to the surrounding follicular epithelium.¹⁸ Biopsies following laser treatment have demonstrated heat-induced follicular damage to the outer root sheath at high fluences (ie. >40 J/cm²), at times to the level of the hair bulb.¹⁹⁻²¹

We proposed that the cure rate of laser removal of in situ SCCs in nonglabrous skin might increase by employing both ultrapulsed CO₂ laser and hair ablative systems. Three passes with the ultrapulsed CO₂ laser with 5 mm margins were utilized to ablate the bulk of the lesion and provide a more uniform surface for a high-fluence diode hair removal pass. The diode laser caused damage to the follicular epithelium too deep and target-specific for the CO₂ laser to achieve. Since follicular reepithelialization without atypia was the sufficient endpoint, additional diode laser sessions were not pursued since prolonged hair removal was not necessary or desired. We chose the highest settings available on our diode laser (60 J fluence, 30-msec pulse duration) in order to maximize the chance that laser-induced thermal injury at the follicular level would be detectable in this preliminary study.

We conclude that these cases suggest at least a theoretical basis for introducing concomitant CO₂ laser and hair ablation in the treatment of in situ SCCs in nonglabrous skin in order to enhance the cure rate. Long-term clinical and histologic follow-up is neces-

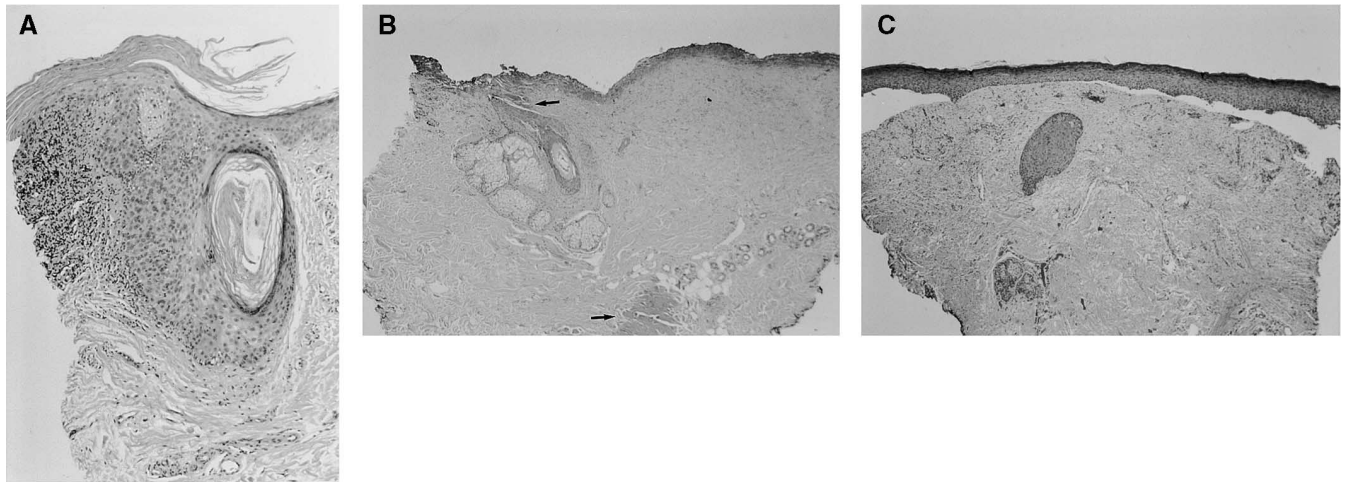


Figure 2. A) Preoperative biopsy shows full-thickness epidermal atypia and focal areas of follicular involvement consistent with Bowen's disease (Hematoxylin and eosin; magnification 20 \times .) B) Immediately after CO₂ and diode laser ablation, epidermal ablation is apparent. Deeper ablation of follicular epithelium is demonstrated as well, at times extending to the subcutaneous tissue (arrows). These foci of thermal necrosis cannot be accounted for by CO₂ laser alone and were likely caused by the diode system. (Hematoxylin and eosin; magnification 10 \times .) C) Two months after the dual laser regimen, epidermal and follicular epithelium are restored. (Hematoxylin and eosin; magnification 10 \times .)

sary. The percentage increase in cure rate needs to be quantified. Additional prospective trials comparing the recurrence rate with CO₂ plus diode treatment versus CO₂ treatment alone are warranted. It should be noted, however, that this approach is currently limited to those lesions with dark and relatively coarse terminal hairs, which provide effective chromophore targets for the currently available hair removal lasers.

References

- David LM. Laser vermilion ablation for actinic cheilitis. *J Dermatol Surg Oncol* 1985;11:605-8.
- Whitaker DC. Microscopically proven cure of actinic cheilitis by CO₂ laser. *Lasers Surg Med* 1987;7:520-23.
- Johnson TM, Sebastian TS, Lowe L, Nelson BR. Carbon dioxide laser treatment of actinic cheilitis. *J Am Acad Dermatol* 1992;27:737-40.
- Adams EL, Price NM. Treatment of basal-cell carcinomas with a carbon-dioxide laser. *J Dermatol Surg Oncol* 1979;5:803-6.
- Gordon KB, Garden JM, Robinson JK. Bowen's disease of the distal digit. Outcome of treatment with carbon dioxide laser vaporization. *Dermatol Surg* 1996;22:723-8.
- Wheeland RG, Bailin PL, Ratz JL, Roenigk RK. Carbon dioxide laser vaporization and curettage in the treatment of large or multiple superficial basal cell carcinomas. *J Dermatol Surg Oncol* 1987;13:119-25.
- Zweig AD, Meierhofer B, Muller OM, et al. Lateral thermal damage along pulsed laser incisions. *Lasers Surg Med* 1990;10:262-74.
- Ross EV, Domankevitz Y, Shrobal M, Anderson RR. Effects of CO₂ laser pulse duration in ablation and residual thermal damage: implications for skin resurfacing. *Lasers Surg Med* 1996;19:123-9.
- Olbricht SM, Stern RS, Tang SV, Noe JM, Arndt KA. Complications of cutaneous laser surgery. A survey. *Arch Dermatol* 1987;123:345-9.
- Hruza GJ, Dover JS. Laser skin resurfacing. *Arch Dermatol* 1996;132:451-5.
- Herd RM, Dover JS, Arndt KA. Basic laser principles. *Dermatol Clin* 1997;15:355-75.
- Bernstein LJ, Kauvar AN, Grossman MC, Geronemus RG. The short and long-term effects of carbon dioxide laser resurfacing. *Dermatol Surg* 1997;23:519-25.
- Kilner S, Chotzen V. Ultrapulse laser treatment of basal cell carcinomas [abstract]. *Am Soc Laser Med Surg* 1996;(202)36.
- Fitzpatrick RE, Goldman M. Treatment of superficial squamous cell carcinomas using the ultrapulse CO₂ laser: a case report. *Dermatol Laser Surg* 1993;(3):2.
- Humphreys TR, Malhotra R, Scharf MJ, Marcus SM, Starkus L, Calegari K. Treatment of superficial basal cell carcinoma and squamous cell carcinoma in situ with a high-energy pulsed carbon dioxide laser. *Arch Dermatol* 1998;134:1247-52.
- Brownstein MH, Rabinowitz AD. The precursors of cutaneous squamous cell carcinoma. *Int J Dermatol* 1979;18:1-16.
- Nanni CA, Alster TS. A practical review of laser-assisted hair removal using the Q-switched Nd:YAG, long-pulsed ruby, and long-pulsed alexandrite lasers. *Dermatol Surg* 1998;24:1399-405.
- Grossman MC, Dierickx C, Farinelli W, Flotte T, Anderson RR. Damage to hair follicles by normal-mode ruby laser pulses. *J Am Acad Dermatol* 1996;35:889-94.
- McCoy S, Evans A, James C. Histological study of hair follicles treated with a 3-msec pulsed ruby laser. *Lasers Surg Med* 1999;24:142-50.
- Bencini PL, Luci A, Galimberti M, Ferranti G. Long-term epilation with long-pulsed neodymium:YAG laser. *Dermatol Surg* 1999;25:175-8.
- Chu CT, Grekin RC, Leboit PE, Zachary CB. Long-pulsed Nd:YAG for hair removal: early histological changes. *Laser News Net* 2000;1:3-6.

Commentary

Fader et al. demonstrate an interesting synergy between two laser modalities for the treatment of squamous cell carcinoma. While the CO₂ laser can ablate superficial epithelium and minimize the risk of thermal damage to the dermis, deeper follicular epithelium is spared. When treating SCC in situ, a reservoir of abnormal keratinocytes extending down to the follicular epithelium can lead to recurrence after CO₂ laser ablation. Concomitant use of the diode laser to ablate abnormal follicular epithelium is a clever technique that may synergistically enhance the cure rate.

Limitations of using the diode laser, however, include 1) it will only be effective on body areas with large dark terminal hairs since light-colored or vellous hairs are not likely to be affected; and 2) only anagen follicular hairs will be affected, so catagen follicles may harbor abnormal keratinocytes that will be unaffected. This is an interesting clinical report, but a larger study with longer-term follow-up is needed to further evaluate this combined technique.

TATYANA HUMPHREYS, MD
Philadelphia, Pennsylvania