

Campylobacter pylori in Patients with Dyspeptic Symptoms and Endoscopic Evidence of Erosion(s)

Grace H. Elta, M.D., Rosanne Murphy, M.D., Elizabeth M. Behler, Jeffrey L. Barnett, M.D., Timothy T. Nostrant, M.D., Scott Kern, M.D., and Henry Appelman, M.D.

Division of Gastroenterology, Department of Internal Medicine, and Department of Pathology, University of Michigan, Ann Arbor, Michigan

The relationship between *Campylobacter pylori* (CP), histologic gastritis, and dyspeptic symptoms is becoming gradually clearer, but there is still a lack of knowledge of the natural history of treated or untreated gastritis. We examined serial biopsies from the gastric fundus, body, and antrum, and from the duodenum in 16 dyspeptic patients. Patients with concomitant peptic ulcers, alcoholism, or nonsteroidal anti-inflammatory drug use were excluded. CP was present in the biopsies of 50% of patients at presentation. When CP was present, the antrum was always infected, and often had the highest density of organisms. In the duodenum, CP was found only in areas of gastric metaplasia. The presence of CP was highly correlated with gastritis activity (neutrophilic infiltrate).

A 4-yr follow-up study of symptoms, endoscopic appearance, and histologic findings including the presence of CP was performed in 10 of the original 16 patients. After 4 yr, both the severity and frequency of epigastric pain remained the same in seven patients, worsened in one, and improved in two. All patients who had CP at initial presentation retained the organism (5/10), whereas none of the previously noninfected patients acquired the infection (5/10). Both CP-positive and -negative patients were treated for 3 wk with 524 mg bismuth subsalicylate qid, and for the first 2 of 3 wk with 250 mg metronidazole qid. One patient who was CP positive was lost to follow-up. In three of the remaining four patients on this regimen, the organism was eradicated. Of the nine patients who completed the treatment program, two had no change in symptoms and seven improved. CP was present in three of seven with improved symptoms and in one of two with no change in symptoms. After treatment, the only change in histology was the disappearance of activity in the CP-positive patients who lost the organism. In conclusion, CP was present in 50% of dyspeptic patients with endoscopic evidence of at least one erosion. Both the symptoms and CP persisted for 4 yr. Dyspeptic symptoms improved after bismuth subsalicylate/metronida-

zole therapy, regardless of the presence or absence of CP, although the regimen did succeed in eradicating the organism in three of the four CP-positive patients who completed the study.

INTRODUCTION

The relationship between endoscopically diagnosed gastroduodenitis, histologic gastritis, and dyspeptic symptoms remains unclear. It has been demonstrated that the endoscopic diagnosis of gastritis often correlates poorly with histologic inflammation (1, 2). In addition, there has been controversy as to whether treatment of dyspeptic symptoms by reducing gastric acid in the absence of documented ulcer disease is of benefit (3, 4). This lack of benefit may be due to the heterogeneous nature of the population labeled as non-ulcer dyspepsia. One subgroup of patients who might respond to specific therapy are those with *Campylobacter pylori* (CP)-associated gastritis. Previous studies have demonstrated a 40–70% incidence of CP and gastritis in non-ulcer dyspeptic patients (5–7). To examine the relationship between symptoms, CP, and gastritis, we studied 16 patients with the endoscopic diagnosis of erosive gastroduodenitis. The presence of gastritis and CP infection was determined by histologic examination of biopsies in all patients. Ten of the original 16 patients had a 4-yr follow-up examination for persistence of symptoms, endoscopic and histologic changes, and CP infection. After this 4-yr follow-up evaluation, these 10 patients were treated with bismuth subsalicylate and metronidazole and then reassessed.

METHODS

Of patients who underwent routine esophagogastroduodenoscopy for persistent dyspeptic symptoms, 16 were chosen for this study on the basis of the endoscopic diagnosis of erosive gastroduodenitis defined as at least one erosion in either the stomach or duodenum. Dyspepsia was defined as chronic or recurrent epigastric pain or nausea. Erosions were defined as breaks in

mucosa (<5 mm) with no appreciable depth. Patients were excluded if they had used aspirin or nonsteroidal anti-inflammatory drugs (NSAIDs) within 48 h of endoscopy, had a history of alcoholism, prior gastric surgery, or concomitant ulcer disease, or had used antacids, H₂-blockers, or sucralfate within 4 days of entry. The age range of the 16 patients was 18–77 yr, with a mean age of 48.6 yr for the patients with CP infection and a mean age of 44.1 yr for those without histological evidence of CP infection. Symptom questionnaires at each patient visit graded daytime and nocturnal epigastric pain, nausea, anorexia, and bloating on a 0–4 scale of severity (0 = none, 1 = mild, 2 = moderate, 3 = severe, and 4 = unbearable) and a 0–4 scale of frequency (0 = none, 1 = few or pain on 1–2 days/wk, 2 = several or pain on 3–4 days/wk, 3 = many or pain on 5–6 days/wk, and 4 = continual).

At endoscopy, biopsies were taken from the gastric fundus, body, and antrum, as well as the duodenum. Biopsies were stained with both Warthin-Starry and hematoxylin and eosin. They were graded on the severity of plasma cell infiltration (chronic inflammation) with 0 = normal, 1 = focal superficial involving the pit compartment, 2 = diffuse superficial, 3 = midmucosal, extending into the middle of the mucosa and 4 = transmucosal, presence of polymorphonuclear cells in the pit epithelium (none = –, few = +, many = ++), and presence of CP (– = absent, + = present) (Figs. 1 and 2). Four years later, we attempted to contact these 16 patients for follow-up examination. Ten of the original 16 patients returned for endoscopy with four-site biopsies and symptom assessment. All 10 patients then were treated for 3 wk with bismuth subsalicylate tablets, 524 mg qid, and for the first 2 of the 3 wk with

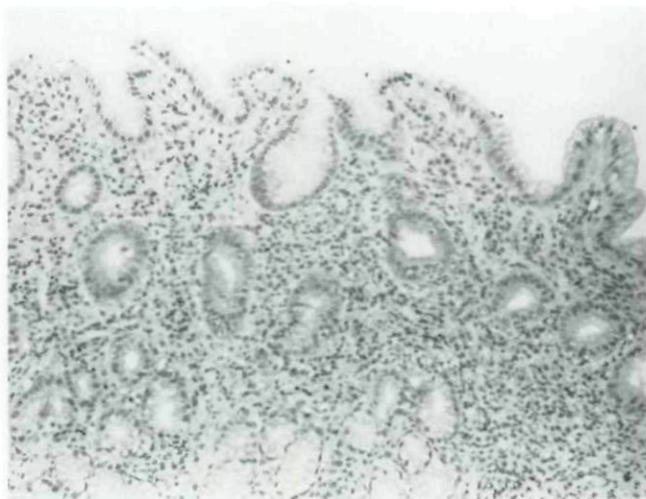


FIG. 1. Antral mucosa before treatment in a patient with grade 3 chronic inflammation and CP. Note the neutrophils in the epithelium of the necks (activity). The dense cellularity in the lamina propria consists mostly of plasma cells (hematoxylin and eosin, $\times 132$).

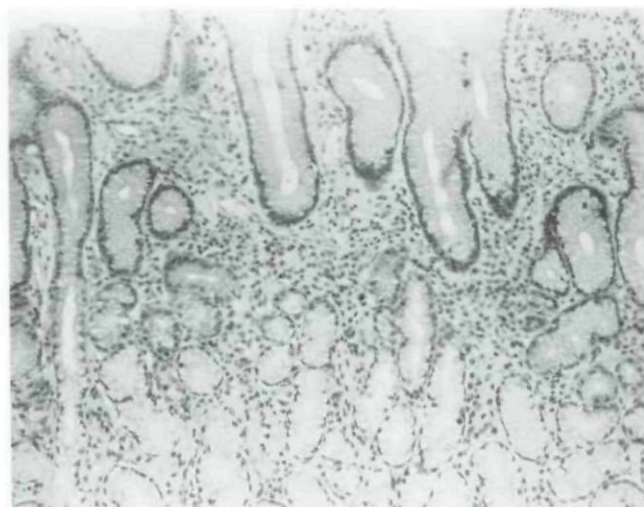


FIG. 2. Antral mucosa from the same patient in Figure 1 after bismuth subsalicylate and metronidazole treatment with grade 2 chronic inflammation and no activity (hematoxylin and eosin, $\times 132$).

metronidazole 250 mg qid. Endoscopy with biopsies was repeated in all patients at the study conclusion. Symptom questionnaires identical to that given 4 yr previously were filled out before and after treatment. An improvement or worsening in pain score was defined as a change of 2 or more points. Due to the previously reported high CP relapse rate within the first month post-treatment, we restudied the patients who initially cleared the organism immediately after treatment, 6–8 months later, to look for relapses of infection. This project was approved by the human use committee at the University of Michigan in June 1987.

RESULTS

CP were found in eight of the original 16 patients. Neither the presence of symptoms considered typical of dyspepsia or the severity of symptoms were predictive of CP infection. At 4 yr of follow-up, five of the original eight CP-positive patients and five of the original eight CP-negative patients were restudied. After four yr, CP persisted in all five CP-positive patients, and none of the five CP-negative patients newly acquired the organism. The treatment regimen successfully eradicated the organism in three of four CP-positive patients; one patient was lost to follow-up. The one patient who failed to clear had poor compliance with the bismuth subsalicylate. Follow-up biopsies from the three patients who cleared the organism at 6–8 months after completion of treatment showed continued absence of CP infection in two, with evidence for relapse in one.

After 4 yr, both the severity and frequency of epigastric pain remained the same in seven of 10 patients, worsened in one of 10, and improved in two of 10. After the metronidazole and bismuth subsalicylate treatment trial, two of nine had no change in symptoms,

whereas seven of nine improved. Symptom improvement in the nine patients did not correlate with CP presence or eradication (Fig. 3).

The endoscopic appearance of the mucosa improved in the majority of patients after 4 yr; only one of 10 patients had persistent erosions and three of 10 had erythema. No patient developed interval ulcer disease. Following the treatment regimen, there was no change in the endoscopic appearance. The histologic findings of chronic inflammation, presence of activity, and presence of CP was examined in 152 specimen sites. CP infection was never found on normal mucosa. In the duodenum, it involved only areas of gastric metaplasia. In our CP-positive patients, the antrum was always infected, and often had the highest density of organisms (Table 1). The presence of CP correlated perfectly with activity in gastritis in the antrum, but the correlation was somewhat less perfect in the body, and especially in the fundus. The severity of the histologic chronic inflammation was unchanged over 4 yr. After the 3-wk treatment period, the only change in histology was disappearance of PMNs in the CP-positive patients. At

TABLE 1
Histologic Scores in the Antrum*

Patients	Initial	4 Yr F/U	Post-RX	6 Mo Post-TX
#1 CP +	3+++†	3+	3-	0-
#2 CP +	4+	2+	Lost	
#3 CP +	3++	3++	3+	
#4 CP +	3+	3+	2-	0-
#5 CP +	3++	3+	3-	3+
#6 CP -	0-	0-	0-	
#7 CP -	0-	0-	0-	
#8 CP -	0-	0-	0-	
#9 CP -	1-	1-	0-	
#10 CP -	1-	0-	0-	

* Chronic inflammatory infiltrate is scored 0-4 and activity is scored +, ++, or -.

† Scores underlined had CP identified on Warthin-Starry stain.

the 6- to 8-month follow-up in the three patients who initially cleared the organism, there was normalization of gastric mucosa in the two patients who remained free of CP.

DISCUSSION

Chronic epigastric pain in the absence of ulcer disease is a common clinical problem. Some of these patients have endoscopic evidence of gastroduodenitis, but many have a normal endoscopic appearance (8). Although endoscopic and histologic inflammation correlate well in the duodenum, this is not true in the stomach (1). Furthermore, the association between abnormal histology and symptoms remains unclear. Several studies have shown poor symptomatic response rates to standard ulcer therapy in nonulcer dyspepsia (3, 4, 9, 10). One explanation for this result would be that non-ulcer dyspepsia patients comprise a heterogeneous group. This series of 16 patients limited inclusion by requiring the endoscopic diagnosis of erosions and excluding patients taking aspirin or NSAIDs.

Over the past few years, gastric mucosal infection with CP has been shown to have a strong correlation with both peptic disease and histologic active gastritis. In this study, we have shown that CP and its associated histologic gastritis were present in 50% of the patients with dyspepsia and endoscopically diagnosed gastric or duodenal erosions. This 50% incidence is similar to the 50-70% incidence of CP infection reported in patients with non-ulcer dyspepsia (11, 12). It has been suggested that the higher incidence of CP infection in non-ulcer dyspeptic patients than in asymptomatic controls (10-20%) may point to a causal role of this organism for these dyspeptic symptoms (13). However, this causal role is thrown into question by the increased incidence of CP infection with aging (14). The mean age of our patients with and without CP infection was 48.6 and 44.1 yr, respectively. A 50% incidence of CP infection

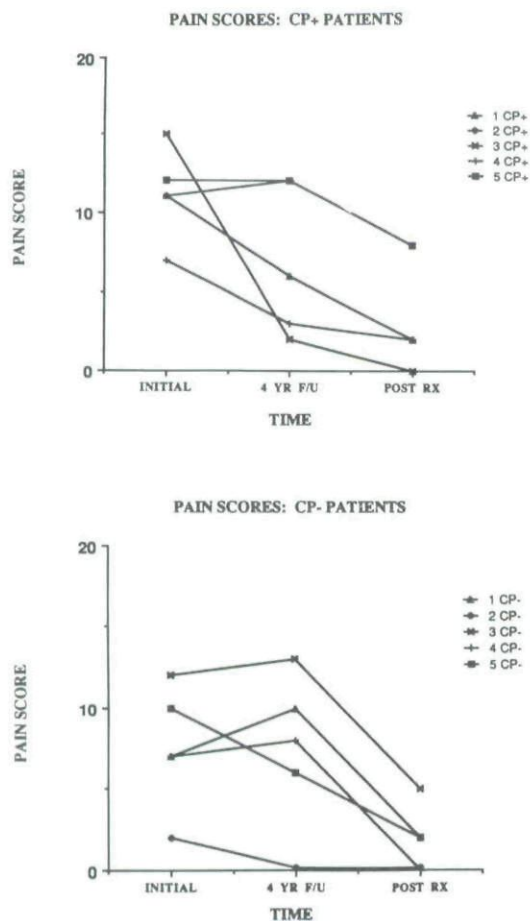


FIG. 3. The pain score is the sum of 4 scores for both severity and frequency of both daytime and nighttime pain (0-4 each). This is plotted against time for patients with and without CP infection at the initial evaluation.

in patients of this age group may not be significantly different than an age-matched asymptomatic control group (15). In our patients, dyspeptic symptoms persisted for 4 yr regardless of whether they had gastritis or CP, and improved on bismuth subsalicylate and metronidazole, also regardless of the presence of CP. Other trials involving patients with non-ulcer dyspepsia have reported improvement in symptoms with bismuth therapy, compared with placebo, but have not studied the symptom response to bismuth of the dyspeptic CP-negative patients (5, 6). Perhaps bismuth compounds are effective in relieving dyspeptic symptoms unrelated to CP eradication. Of course, our study may be too small to show a difference in symptom response between CP-negative and CP-positive patients.

Many of our histologic results agree with previous investigators in finding: 1) the antrum was always infected when CP was present and often had the highest density of organisms, 2) CP was never found on normal mucosa, 3) CP infection in the duodenum was only in areas of gastric metaplasia, and 4) the presence of CP correlates with activity in gastritis (16, 17). The disappearance of polymorphonuclear cell infiltrate after CP eradication without change in the underlying chronic inflammatory infiltrate is unlike the report of Rauws *et al.* (18). They showed improvement and even normalization of gastric histology in CP-eradicated patients. However, their gastritis scoring system was heavily weighted in favor of polymorphonuclear cells and erosions (8 out of 10 potential points) with only 2 out of 10 points for the chronic inflammatory infiltrate. Their actual post CP treatment mean gastritis score was 1 (out of 2 potential points for chronic inflammation) and did not return to 0 (normal) until 12 months post-treatment. Therefore, our results of no change in chronic inflammation post CP treatment are probably consistent with theirs. Two of the three patients in our study who cleared the organism did have normalization of gastric mucosa at 6–8 months of follow-up.

A 4-yr follow-up of 10 of the original 16 patients showed persistence of CP infection in the five patients who had it originally, with no new appearance of CP in the remaining five patients who were negative initially. Prior studies have not looked for persistence of CP beyond 2 yr (19). It appears that CP causes chronic infection with chronic histologic changes.

In conclusion, CP infection and its characteristic histologic gastritis was present in 50% of patients with endoscopically diagnosed erosive gastroduodenitis. Dyspeptic symptoms and CP infection persisted over 4 yr of follow-up. Treatment of both CP-positive and CP-negative patients with bismuth subsalicylate and metronidazole improved symptoms, regardless of CP presence. This treatment result does not support a role for CP infection or histologic gastritis in causing dyspeptic symptoms, although our sample size was small. Large

trials of non-ulcer dyspepsia are needed to pursue this issue further.

ACKNOWLEDGMENTS

Grant support: Proctor & Gamble, Co., Cincinnati, Ohio.

Presented in part at the American Gastroenterological Association Meetings in Chicago, IL, in May 1987, and in New Orleans, LA, in May 1988.

Reprint requests: Grace Elta, M.D., 3912 Taubman Center, University of Michigan, Ann Arbor, MI 48109-0362.

REFERENCES

1. Elta GH, Appelman HD, Behler EM, *et al.* A study of the correlation between endoscopic and histological diagnosis in gastroduodenitis. *Am J Gastroenterol* 1987;82:749–53.
2. Gad A. Erosion: A correlative endoscopic histopathologic multicenter study. *Endoscopy* 1986;18:76–9.
3. Nyren O, Adami H, Bates S, *et al.* Absence of therapeutic benefit from antacids or cimetidine in non-ulcer dyspepsia. *N Engl J Med* 1986;314:339–43.
4. Talley NJ, McNeil D, Hayden A, *et al.* Randomized, double-blind, placebo-controlled crossover trial of cimetidine and pirenzepine in non-ulcer dyspepsia. *Gastroenterology* 1986;91:149–56.
5. Lambert JR, Borromeo M, Korman MG, *et al.* Role of *Campylobacter pyloridis* in non-ulcer dyspepsia. A randomized controlled trial. *Gastroenterology* 1986;92:1488 (Abstract).
6. Rokkas T, Pursey C, Simmons NA, *et al.* Non-ulcer dyspepsia and colloidal bismuth subcitrate therapy: The role of *Campylobacter pyloridis*. *Gastroenterology* 1987;92:1899 (Abstract).
7. Dooley CP, Cohen H. The clinical significance of *Campylobacter pylori*. *Ann Intern Med* 1988;108:70–9.
8. Greenlaw R, Sheahan DG, DeLuca V, *et al.* Gastroduodenitis: A broader concept of peptic ulcer disease. *Dig Dis Sci* 1980;25:660–72.
9. Lance P, Wastell C, Schiller KF. A controlled trial of cimetidine for the treatment of non-ulcer dyspepsia. *J Clin Gastroenterol* 1986;8:414–8.
10. Kelback H, Linde J, Eriksen J, *et al.* Controlled clinical trial of treatment with cimetidine for non-ulcer dyspepsia. *Acta Med Scand* 1985;217:281–7.
11. Marshall BJ, McGeachie DB, Rogers PA, *et al.* Pyloric *Campylobacter* infection and gastroduodenal disease. *Med J Aust* 1985;142:439–44.
12. Pettross CW, Cohen H, Appleman MD, *et al.* *Campylobacter pyloridis*: Relationship to peptic disease, gastric inflammation and other conditions. *Gastroenterology* 1986;90:1585 (Abstract).
13. Talley NJ, Phillips SF. Non-ulcer dyspepsia. Potential causes and pathophysiology. *Ann Intern Med* 1988;108:865–79.
14. Graham DY, Klein PD, Opekun AR, *et al.* Epidemiology of *Campylobacter pyloridis* infection. *Gastroenterology* 1987;92:1411 (abstract).
15. Jones DM, Eldridge J, Fox AJ, *et al.* Antibody to the gastric *Campylobacter*-like organism ("*Campylobacter pyloridis*"), Clinical correlations and distribution in the normal population. *J Med Microbiol* 1986;22:57–62.
16. Goodwin CS, Armstrong JA, Marshall BJ. *Campylobacter pyloridis*, gastritis, and peptic ulceration. *J Clin Pathol* 1986;39:353–65.
17. Barthel JS, Westblom TU, Havey AD, *et al.* Gastritis and *Campylobacter pylori* in healthy, asymptomatic volunteers. *Arch Intern Med* 1988;148:1149–51.
18. Rauws EAJ, Langenberg W, Houthoff HJ, *et al.* *Campylobacter pyloridis*-associated chronic active antral gastritis. *Gastroenterology* 1988;94:33–40.
19. Langenberg W, Rauws E, Widjojokusumo A, *et al.* Identification of *Campylobacter pyloridis* isolates by restriction endonuclease DNA analysis. *J Clin Microbiol* 1988;24:414–7.

This document is a scanned copy of a printed document. No warranty is given about the accuracy of the copy. Users should refer to the original published version of the material.