

THYROIDITIS*

William H. Beierwaltes

*Department of Internal Medicine (Nuclear Medicine Section),
University of Michigan Medical School, Ann Arbor, Mich.*

For my paper on the "thyroiditis" section, it seemed appropriate to present and illustrate with clinical examples a scheme of events in the pathogenesis and course of progression of thyroid "autoimmune" diseases that has proved helpful in the management of these patients. This scheme is not original or presented as dogma but merely as a clinical outline for the more imaginative and original presentations and discussions to follow.

Pathogenesis

Basement membrane leak. Perhaps the first step in the development of thyroid autoimmune disease is the inheritance or acquisition of a fault in the basement membrane of the follicular cells of the thyroid gland. FIGURE 1a, from the article of Sommers and Meissner shows the normal basement membrane in the McManus-Mowry preparation. FIGURE 1b shows the thinning and discontinuities found in the thyroid gland of a patient with "chronic thyroiditis." These defects were found in the thyroid gland early in the course of this disease, only in this disease, and not only in areas invaded by lymphocytes but also where there were no lymphocytes.

Nonmetabolically active iodinated protein appears to leak out of the follicles in Hashimoto's struma since De Groot and coworkers² found "abnormal" iodinated protein in the serum as well as in the follicles of the thyroid glands of affected individuals in a family with an increased incidence of Hashimoto's struma. This "leak" of iodinated protein appears to be capable of sustaining a normal serum protein-bound iodine but not a normal "thyroxine-like" iodine. The pituitary apparently responds to this deficiency by secreting thyroid stimulating hormone, TSH, to stimulate the thyroid as manifested by an elevation of the 24-hour thyroid I¹³¹ uptake and thyroid hyperplasia.

Thyroidal hyperplasia. The thyroidal hyperplasia initially resulting from increased TSH effect has been found to appear before characteristic changes of Hashimoto's struma develop as exemplified by the following case of E. F. who was found to have thyroid hyperplasia antedating clinical Hashimoto's struma by 14 years.

FIGURE 2 shows the early hyperplasia seen in the thyroid gland of a 42-year-old male subjected to a subtotal thyroidectomy in 1943 for suspected, but not documented, Grave's disease.

*This work was supported by U.S.P.H.S. Grant CA-05174-04 and U.S.P.H.S. Grant MH-02399-06.

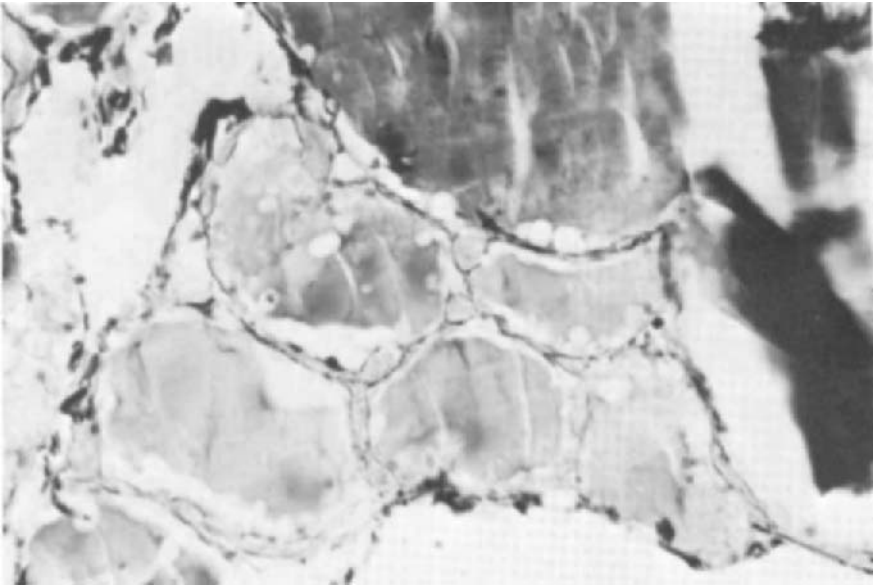


FIGURE 1a. Normal basement membrane in a normal thyroid gland.

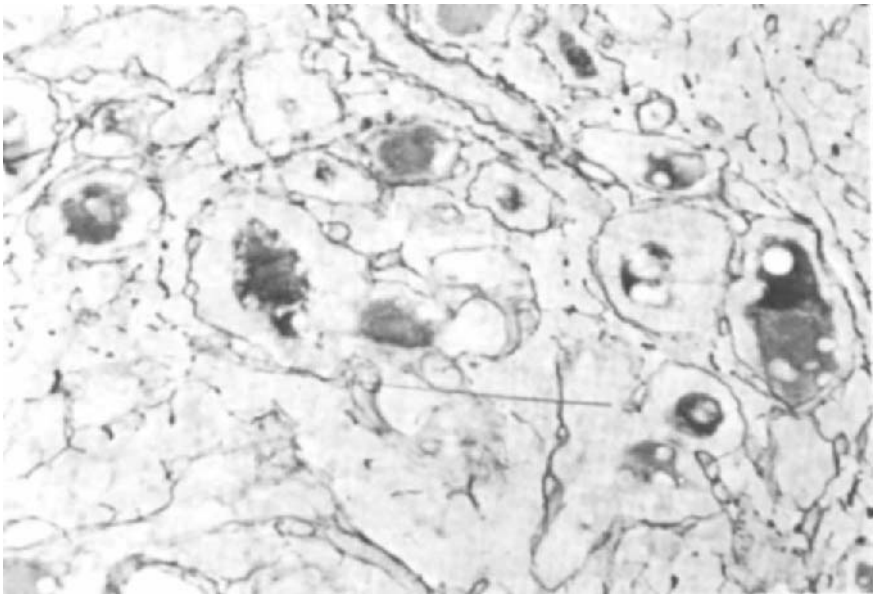


FIGURE 1b. Thinning and discontinuities in basement membrane of thyroid gland of a patient with "chronic thyroiditis" (McManus-Mowry preparation). Courtesy of Sommers & Meissner, 1954. (*Am. J. Clin. Pathol.* **24**: 434.)

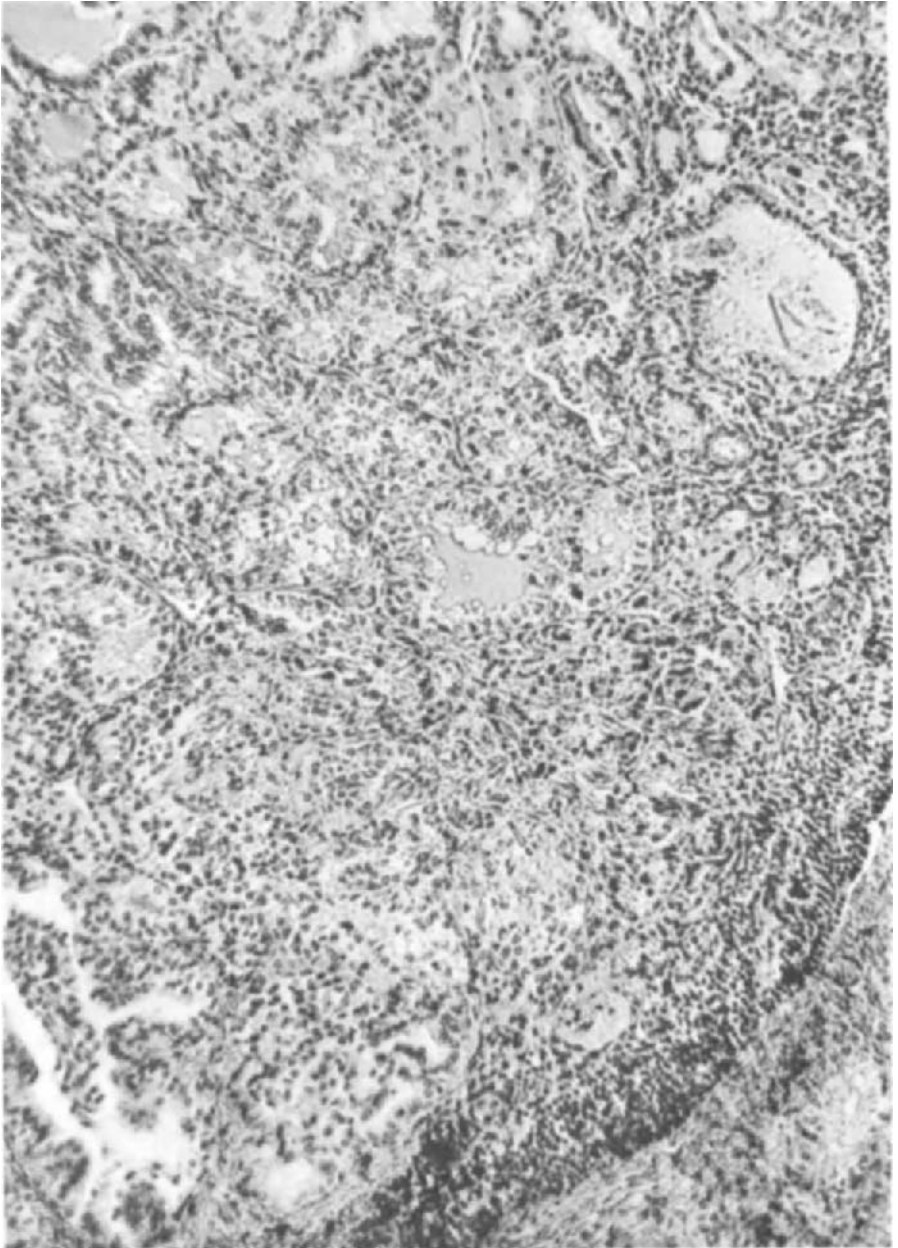



FIGURE 2. Histology of the thyroid gland of E. F.

In 1957 he was referred to us because he had developed a goiter, myxedema, a subnormal serum PBI of $2.9\mu\text{g}$ per cent, and a 24 hour thyroidal I^{131} uptake of 11 per cent. He had the typical clinical picture of Hashimoto's struma with a tanned cell antithyroglobulin antibody (A.A.B.) titer of 1:32,000. The myxedema and the goiter disappeared upon the administration of three grains of desiccated thyroid per day.

This early picture of hyperplastic goiter with symptoms suggestive of hyperthyroidism with an elevated thyroidal I^{131} uptake but a normal serum



H. Howlett #584027
Twin of I. Wilson. Goiter. Sol.
nodule. 24 hr uptake = 59%.
PBI = $4.4\ \mu\text{g}\ \%$. Tx 10/26/62
Dx Hashimoto's Struma.

FIGURE 3a. Scintiscan of the thyroid gland of H. H.

PBI is so common and provocative that it has been called "Hashitoxicosis." It is of interest that this long history of thyroid hyperactivity ended in severe thyroid insufficiency.

Immunologically competent host. It is possible that when these events occur in an immunologically competent host that an "immune" response to released antigen occurs with a resultant characteristic superadded infiltrate in the thyroid gland and diffuse goiter formation. Hall, Owen and

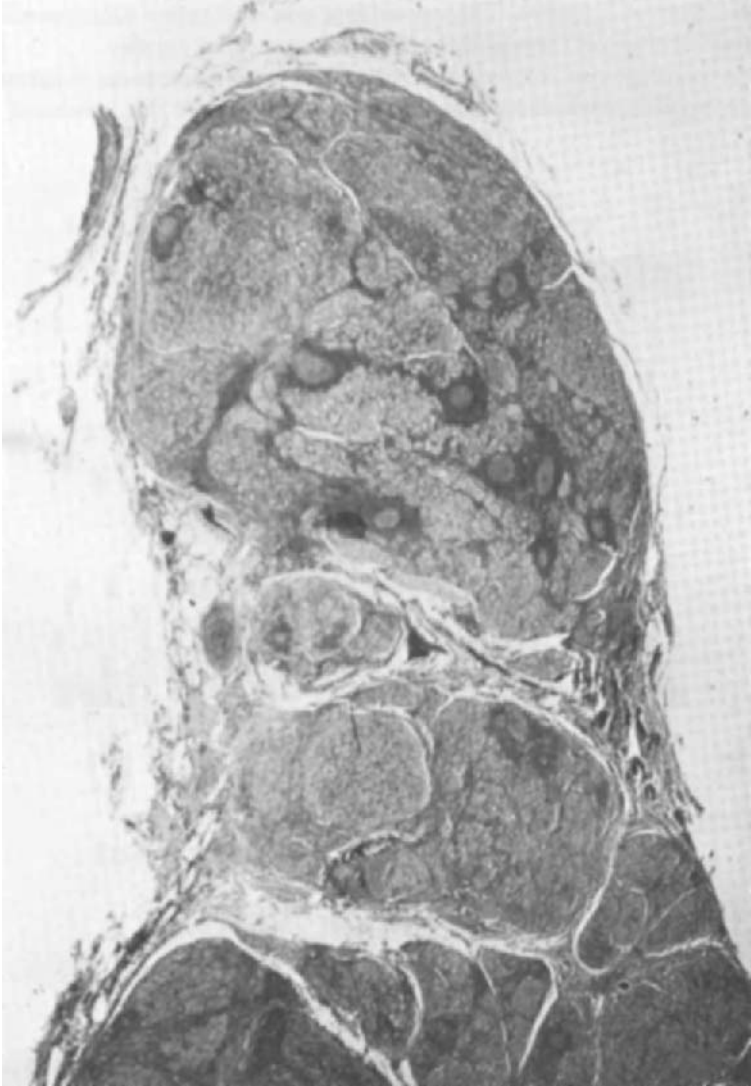
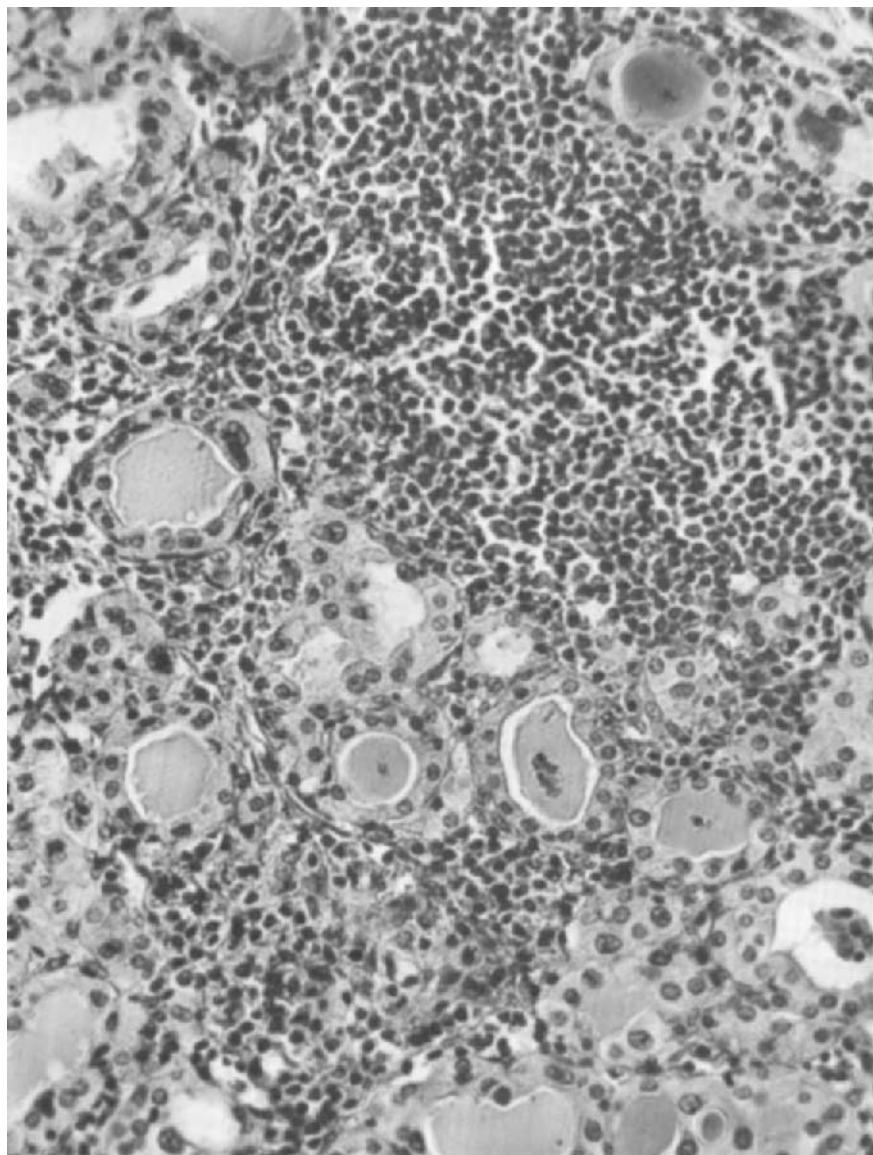


FIGURE 3b. Low and high-power views of



the histology of the thyroid gland of H. H.

Smart³ demonstrated that the tendency to develop antibodies to thyroglobulin in families of patients with Hashimoto's struma is inherited as a codominant. The following observation of the occurrence of Hashimoto's struma in twins lends further support to the concept of a pre-existing constitutional predisposition to the development of this disease.

FIGURE 3 presents the scintillation scan of the thyroid gland of H. H. seen on 10-19-62 because of a goiter.




FIGURE 4a. Scintiscan of the thyroid gland of I. W.

The lower half of both lobes of the thyroid gland were diffusely and symmetrically enlarged and hard. A nodule 2.3×1.4 cm. in diameter was located in the lower part of the right lobe of the thyroid gland. Her 24 hour I^{131} uptake was elevated to 59 per cent but her serum PBI was low normal at $4.4 \mu\text{g}$ per cent. The surgeon reported that the gland was filled with "innumerable large and small thyroid nodules." The pathologist reported the characteristic changes of Hashimoto's struma shown in FIGURE 3b.

FIGURE 4 shows the (a) scintiscan and (b) microscopic sections of the thyroid gland of the twin sister of H. H.

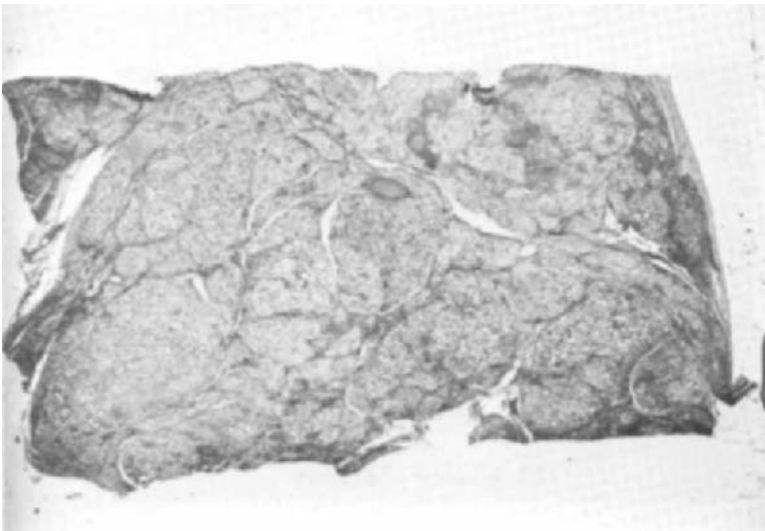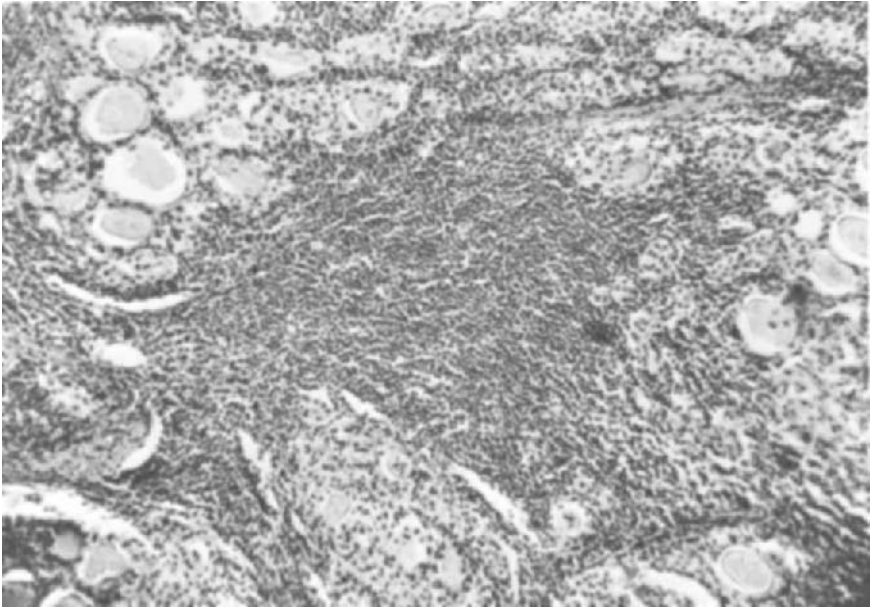


FIGURE 4b. Microscopic sections of the thyroid gland of I. W.

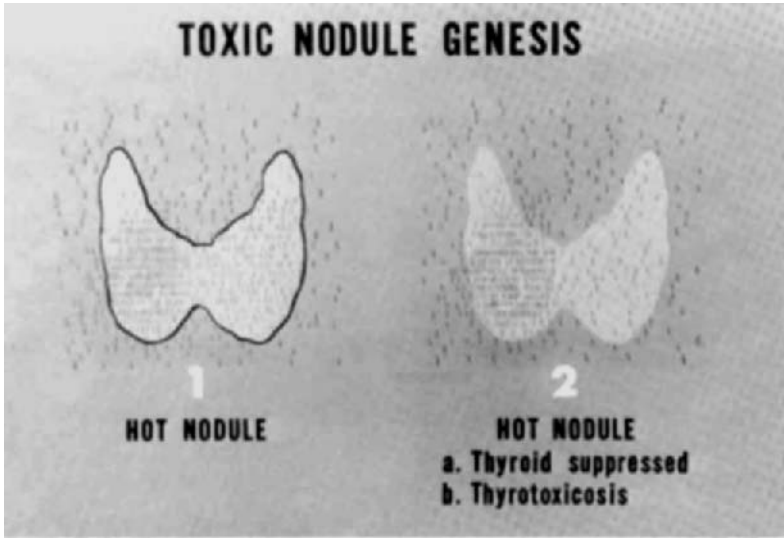


FIGURE 5a. Scintiscan of the thyroid gland of a patient developing an autonomously functioning "hot" nodule showing first, a₁, increased uptake in nodule as compared to the surrounding normal thyroid gland, and a₂ later suppression of uptake of I^{131} in the extranodular tissue by excessive production of thyroid hormone by the "hot" nodule.

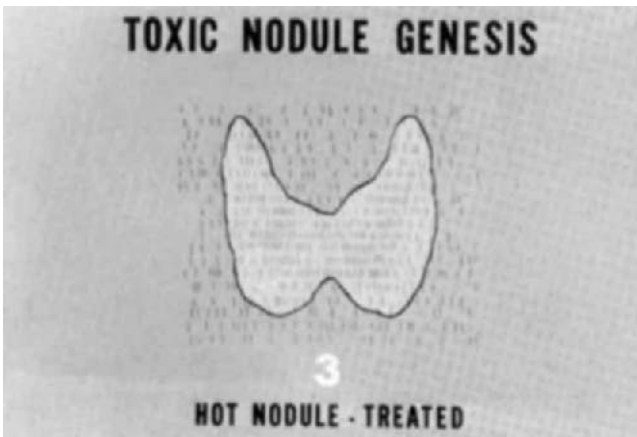


FIGURE 5b. Return of I^{131} concentration in extranodular tissue after suppression of function of the "hot" nodule by treatment with I^{131} .

She had had a surgical thyroidectomy for a very similar goiter at age 57 in 1957 with an uptake of 55 per cent on 9-27-57 and a PBI of 4.3 μg per cent.

Progression

No change. Although it is estimated that at least half of the patients with Hashimoto's struma show no progression of their disease, we have observed at least two courses of progression of this disease clinically.

Autonomous nodules with necrosis and fibrous replacement in euthyroid individuals. R. H. Parker and I¹ recognized this entity while studying the pathogenesis of the much more common type of "hot" nodule of the more common colloid nodular goiter. FIGURES 5a₁ and a₂ are pictures of the scintiscans of the thyroid gland of a patient developing an autonomously functioning "hot nodule" in a colloid nodular goiter, not the site of autoimmune disease.

This type of nodule usually appears after not less than six months of thyroid stimulation secondary to iodine deficiency and/or a biochemical defect in the thyroid gland. At first, the nodule is called "hot" because it merely concentrates iodine more avidly than the surrounding normal thyroid tissue as shown in FIGURE 5a₁. Later it may become the only area of iodine concentration by scintiscan because its function has increased to the point where its excessive production of thyroid hormone is sufficient to suppress TSH stimulation of I¹³¹ concentration of thyroid tissue outside the nodule as shown in FIGURE 5a₂. The fact that this lack of uptake in extranodular tissue is merely a result of suppression of TSH by excessive thyroid hormone production by the nodule is documented by (a) demonstration of a high normal to elevated serum PBI in such patients, (b) I¹³¹ uptake restored to extranodular tissue after an injection of 10 units of beef thyrotropin, or (c) slowing the function of the "hot" nodule with a treatment dose of I¹³¹ as shown in FIGURE 5b, with resultant return of I¹³¹ uptake in the remainder of the thyroid gland. The I¹³¹ uptake in such a nodule, however, shows relatively autonomous function in that it is neither significantly increased by an injection of TSH nor suppressed by thyroid hormone treatment.

In studying such patients with autonomously *hyperfunctioning* nodules with a lack of uptake of I¹³¹ in the remainder of the thyroid gland, we found a different group of thyroid gland "hot" nodules characterized by: (a) low normal or subnormal serum PBI concentrations, (b) *lack of uptake in the remainder of the thyroid gland even after an injection of 10 units of TSH*, (c) lack of suppression of uptake of the nodule after the administration of desiccated thyroid, (d) surgical specimen showing a colloid nodule as the "hot" nodule and the tissue of the remainder of the thyroid gland consisting only of necrosis, and lymphomatous infiltration in a fibrous remnant. The

following case presentation serves to illustrate this course of progression of Hashimoto's struma in a euthyroid individual.

FIGURE 6a presents the scintiscan of patient L. C., with a hot nodule in the left lobe of the thyroid gland without uptake in the isthmus or right lobe of the thyroid, a high normal I^{131} uptake and a normal serum PBI.

It is evident that the lack of uptake in the right lobe cannot be due to a suppression of pituitary TSH by an excess of thyroid hormone because the

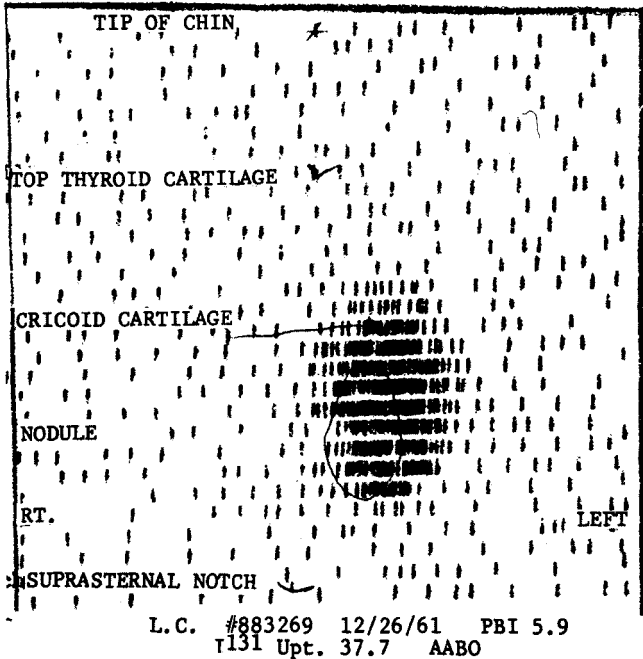


FIGURE 6a. Scintiscan of the thyroid gland of patient L. C. with a "hot" nodule in the left lobe of the thyroid gland and no uptake in the isthmus and right lobe.

serum PBI is normal. Furthermore, FIGURE 6b shows that no uptake of I^{131} was produced 48 hours after an injection of 10 units of TSH and 24 hours after a tracer dose of I^{131} . FIGURE 6c shows that the uptake of the nodule could not be suppressed by prolonged administration of three grains of desiccated thyroid a day, sufficient to produce a rise in the serum PBI to the supernormal level of 13.5 μ g per cent.

FIGURES 6d and e are photomicrographs of the "hot nodule" in the left lobe and the inactive right lobe respectively. The hot nodule is a "colloid nodule" without signs of hyperactivity while the right lobe is a necrotic fibrous remnant with histologic changes compatible with thyroid autoimmune disease.

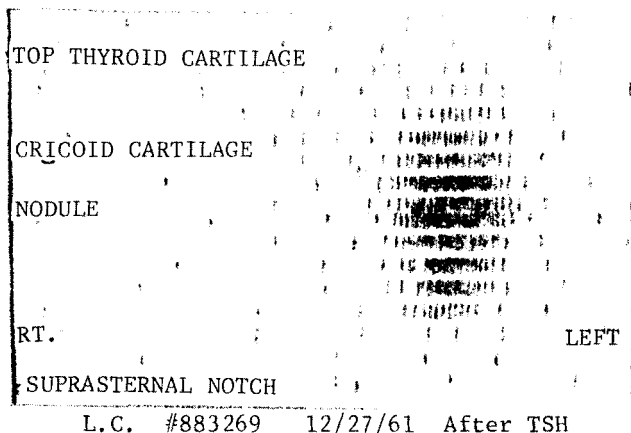


FIGURE 6b. No uptake in the extranodular tissue after 10 units of TSH.

Necrosis sufficient to produce myxedema

More commonly we have had patients with nodular remnants in thyroid tissue with necrosis sufficient to produce frank myxedema, with or without a goiter and palpable nodules in the thyroid gland.

FIGURE 7 is a photomicrograph of the thyroid gland of a 57-year-old male (A. H.) who died with acquired hemolytic anemia of unknown etio-

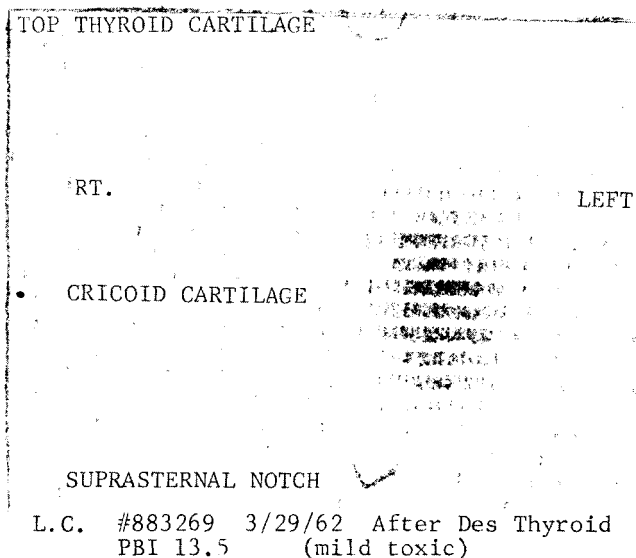


FIGURE 6c. No suppression of uptake in the "hot nodule" after desiccated thyroid administration with a rise in the serum PBI to supernormal levels.

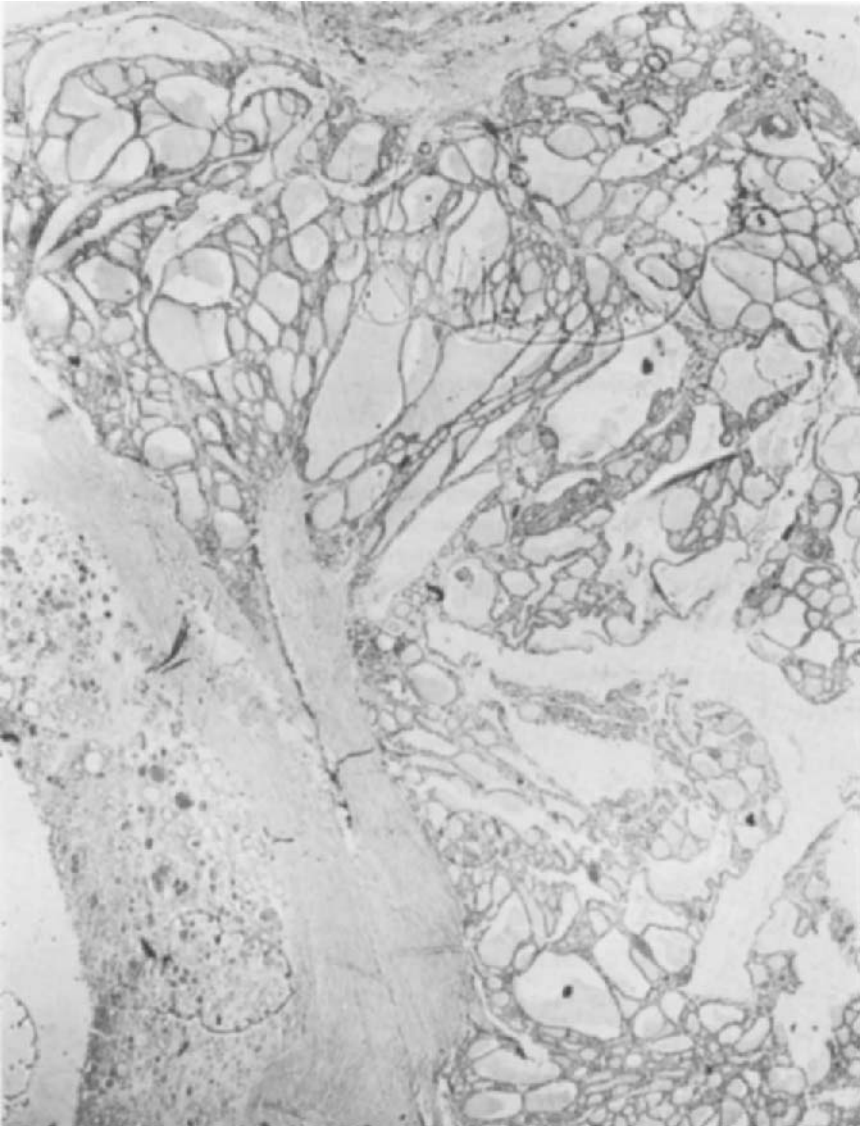


FIGURE 6d. Photomicrograph of the "hot" nodule.

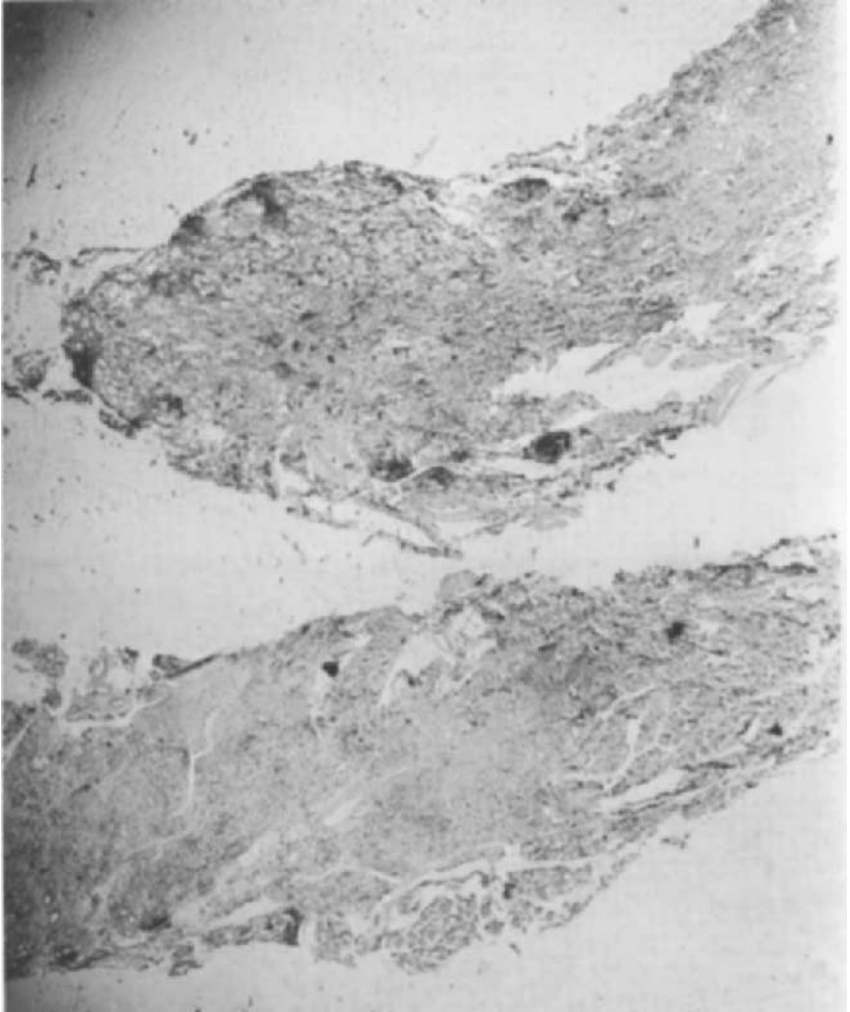


FIGURE 6e. Photomicrograph of the nonactive right lobe of the thyroid gland.

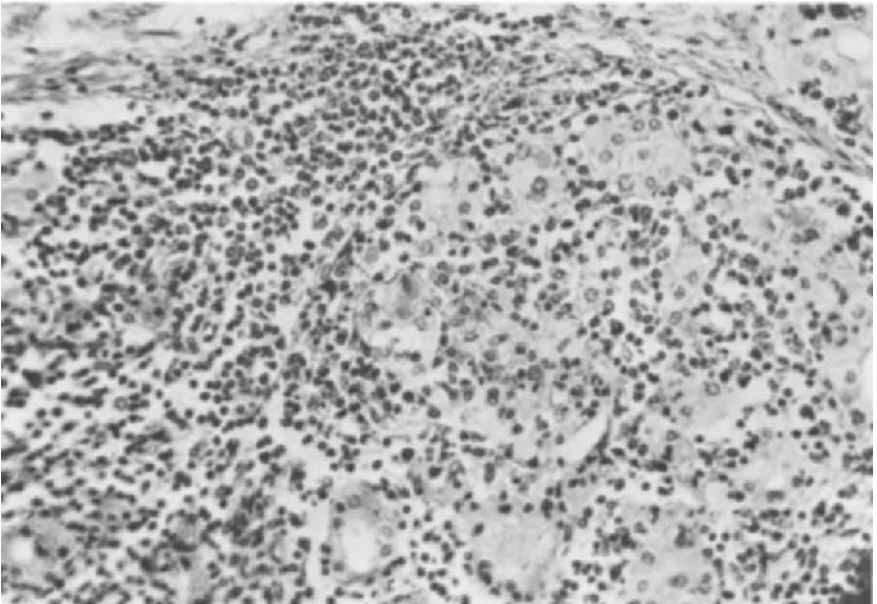
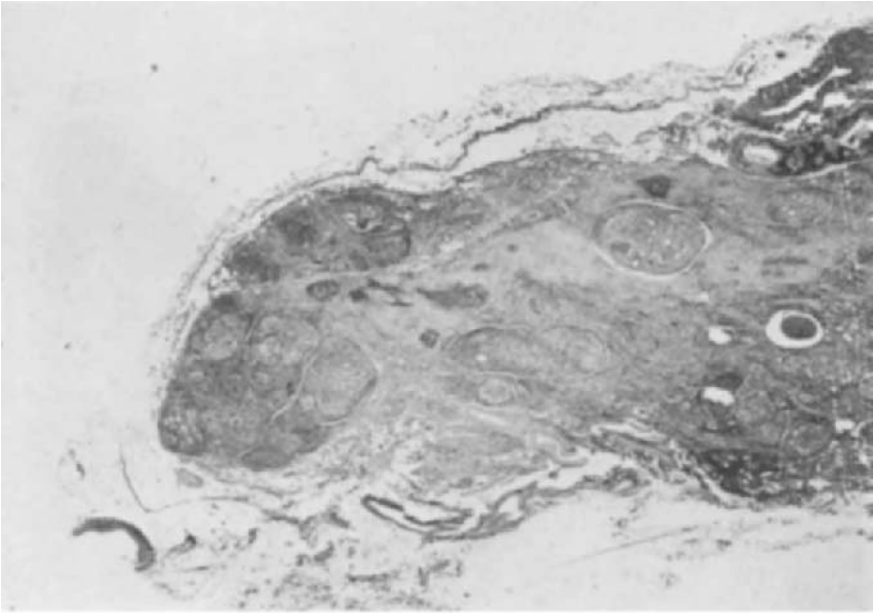


FIGURE 7. Histology of the thyroid gland of A. H. dying with idiopathic thrombocytopenic purpura and myxedema (two photomicrographs).

logy, idiopathic thrombocytopenic purpura with secondary intracranial bleeding, and coincident myxedema. Cryoglobulins were positive at 1:256. He had had a proved episode of pancreatitis in 1961. His serum PBI was subnormal at 1.9 μg per cent and his serum cholesterol concentration was 417 mg per cent. The few islands of remaining functional thyroid tissue are surrounded by changes seen in Hashimoto's struma while most of the gland shows necrosis and fibrous tissue. It is easy to picture a progression, from L. C. to A. H., in thyroid necrosis associated with thyroid autoimmune disease. All patients dying with myxedema at our University Hospital in the last two years have exhibited much the same thyroïdal histologic picture.

Riedel's struma. A third course of progression of Hashimoto's struma is that of a rapidly progressive fibrous variant of Hashimoto's struma, indistinguishable from Riedel's struma. The case of J. K. (FIGURE 8a), serves to illustrate this course of events. This woman was 32-years-old when seen by us on 10-28-58. She had nervousness of two and one-half years' duration and goiter of one year's duration. Her 24 hour I^{131} uptake was slightly elevated at 42 per cent and her PBI was normal at 5.3 μg per cent. Her thyroid gland was symmetrically and diffusely enlarged, firm to hard in consistency, and asymptomatic; a picture compatible with Hashimoto's struma. Thyroid antibody titers (T.R.B.C.) increased rapidly from 1:12 on May, 1958 to 1:768 two months later and over 1:1536 four months later while on three grains of desiccated thyroid. The gland increased rapidly in size during this interval and became rock hard. She experienced a decrease in the size of her goiter and in the height of her antibody titers when given large doses of oral cortisone. Both the goiter and antibody titers increased, however, when the dosage of steroids was tapered. A surgical thyroidectomy 1-8-59 was carried out with difficulty because of adhesions to the surrounding neck. Postoperatively she developed parathyroid tetany and left vocal cord paralysis. The pathological diagnosis was Riedel's struma (FIGURE 8b). Rose and Royster have reported an almost identical case.⁵

Relationship to thyroid carcinoma

In Woolner's 605 cases of struma lymphomatosa⁶ there were 18 cases of associated carcinoma (about 3 per cent) and 12 cases of associated lymphosarcoma (about two per cent). All the carcinomas were papillary and of low malignancy, but showed definite invasion of adjacent parenchyma. Obviously, these figures represent the maximum incidence of carcinoma since the physician elected to remove the goiter surgically, frequently because of a strong suspicion that carcinoma might be present. We have seen only two instances of severe generalized Hashimoto's struma with high antithyroid antibody titers associated with carcinoma of the thyroid gland. Almost always the antithyroid antibody titer is relatively low and the lymphomatous infiltration is focal (FIGURE 9). Frequently

EFFECT OF TREATMENT ON A PATIENT
WITH ANTI-THYROID ANTIBODY TITERS (J.K.)

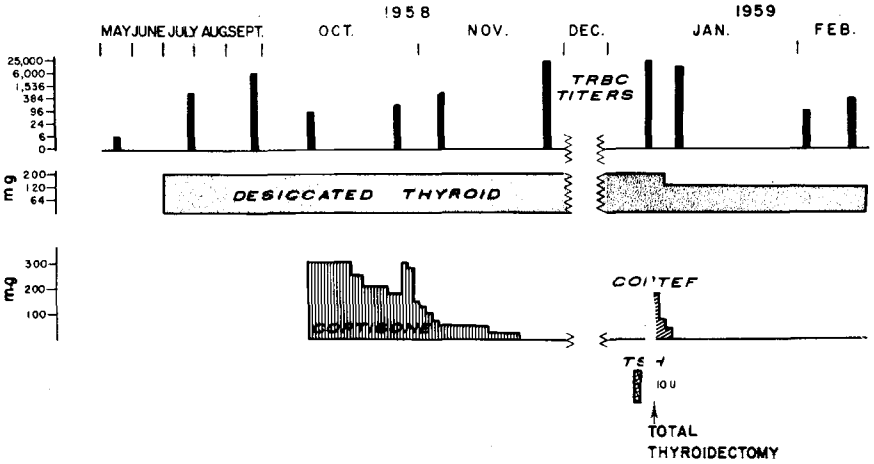


FIGURE 8a. Clinical course of J. K.

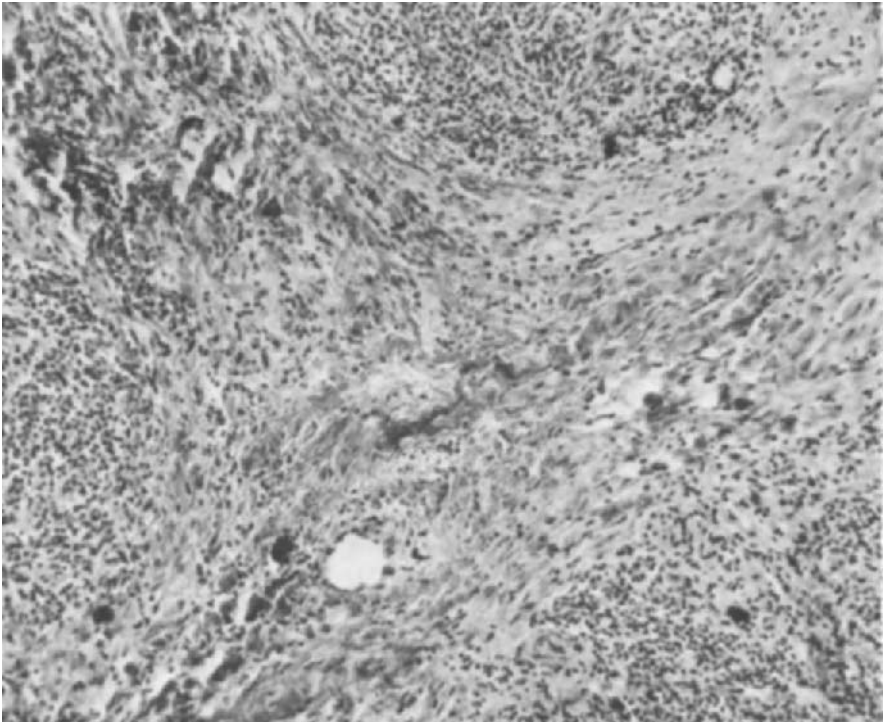
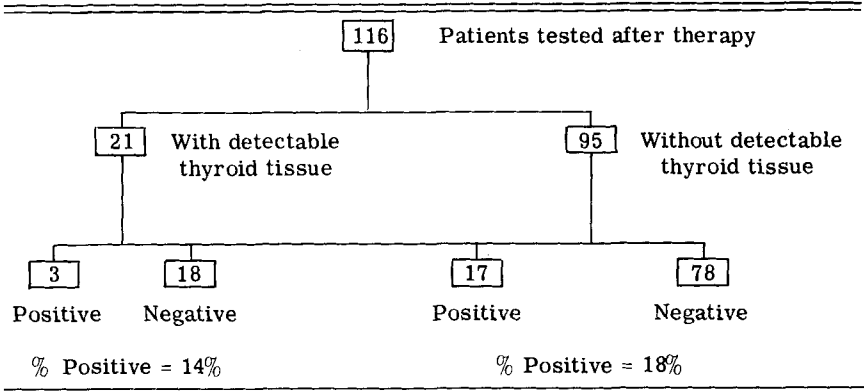


FIGURE 8b. Histology of thyroid of J. K.

TABLE I
ANTITHYROID ANTIBODY TITERS AND RESIDUAL FUNCTIONING CARCINOMA



Relation of persistence of antithyroid antibody titers to remaining thyroid tissue after treatment of carcinoma of the thyroid gland with surgery and irradiation.

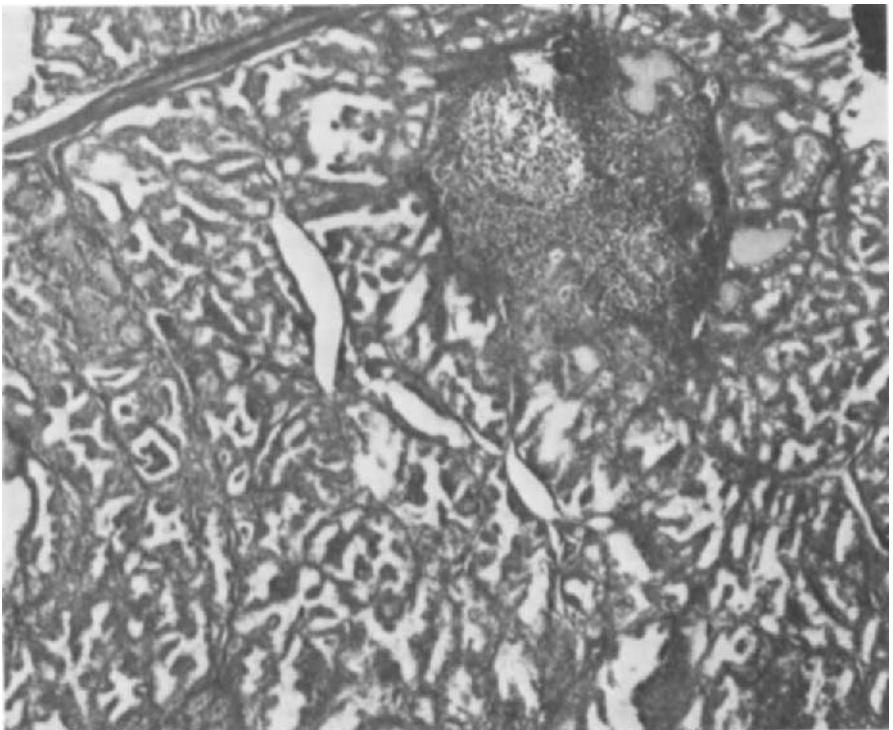


FIGURE 9. Focal lymphomatous infiltration in a man with papillary carcinoma of the thyroid gland.

the focal infiltration is near a necrotic papillary frond as though it represented a local "immune" reaction to an altered or "new" antigen in the carcinoma.

We tested the sera of 116 patients with thyroid carcinoma, using the tanned-cell antithyroglobulin antibody test, who were treated by surgical extirpation of the normal thyroid gland and thyroid carcinoma followed by I¹³¹ therapy as shown in TABLE 1.

Of 95 patients tested after they were apparently freed of all thyroid tissue, 18 per cent had demonstrable circulating antithyroglobulin antibodies (A.A.B.). Fourteen per cent of 21 patients with detectable residual thyroid tissue had circulating A.A.B. The incidence of A.A.B. in the sera of 100 women seen for any complaint in the gynecology clinic at the same hospital during this same period was four per cent.⁷ The incidence of A.A.B. in these patients tested after treatment did not differ significantly at any interval from the incidence in 29 patients tested before treatment. Circulating A.A.B. were demonstrable through the 10 years of follow-up after treatment. The etiologic relationship between circulating A.A.B. and papillary and follicular carcinoma is unknown. One possible, but unproved, cause for the persistence of A.A.B. after apparent ablation of all thyroid tissue is that the tanned-cell test is a more sensitive index of the persistence of functioning thyroid tissue than all other methods of testing in common use at present. Another possible explanation is that the papillary carcinoma may arise in a type of thyroid gland or a host that has an unusual tendency to develop antithyroglobulin antibodies. It is conceivable that the host might continue to produce antibodies to thyroglobulin after all thyroglobulin antigen was removed, either through a mechanism of a "shared" antigen elsewhere in the host or because subsequent generations of lymphocytes in the host carried the genetic information necessary to elaborate this antibody.

References

1. SOMMERS, S. C. & W. A. MEISSNER. 1954. Basement membrane changes in chronic thyroiditis and other thyroid diseases. *Am. J. Clin. Pathol.* **24**: 434-440.
2. DE GROOT, L. J., R. HALL, W. V. McDERMOTT & A. M. DAVIS. 1962. Hashimoto's thyroiditis: a genetically conditioned disease. *N. Eng. J. Med.* **267**: 267-273.
3. HALL, R., S. G. OWEN & G. A. SMART. 1960. Evidence for genetic predisposition to formation of thyroid autoantibodies. *Lancet* **2**: 187-188.
4. BEIERWALTES, W. H. & R. H. PARKER. The morphological pathogenesis of "hot" nodules in colloid nodular goiter. Unpublished observations.
5. ROSE, E. & H. P. ROYSTER. 1961. Invasive fibrous thyroiditis (Riedel's struma). *J. Am. Med. Assoc.* **176**: 224-226.
6. WOOLNER, L. B., W. M. McCONAHEY & O. H. BEAHR. 1959. Struma lymphomatosa (Hashimoto's thyroiditis) and related thyroidal disorders. *J. Clin. Endocrinol. Metabol.* **19**: 53-83.
7. PARKER, R. H. & W. H. BEIERWALTES. 1961. Thyroid antibodies during pregnancy and in the newborn. *J. Clin. Endocrinol. Metabol.* **21**: 792-798.