

## Fibromuscular Arterial Disease

### Experimental Studies\*

NEVILLE J. H. ROTHFIELD, M.B., B.S., M.C.R.A.

*Assistant Professor, Department of Radiology, University of Michigan, Ann Arbor, Michigan ;  
Associate Radiologist, Wayne County General Hospital, Eloise, Michigan, 48132*

Fibromuscular arterial disease would appear to occupy a unique place in aetiological concepts of vascular disease. It has been described as enigmatic (McIntosh *et al.*, 1965), but despite its vagaries, surgical approaches (Kaufman, 1965 ; Page and McCubbin, 1968) to localized disease in the renal artery are probably the most successful. Long-term studies are needed to evaluate the life history of both surgical results and conservative management, and although pathological observation dates from Leadbetter and Burkland (1938) radiographic investigational methods and the reconstructive arterial surgical measures have only gained impetus since Palubinskas and Wylie (1961) documented the radiological diagnostic criteria.

Two major long-term studies at present available show a slight discrepancy. Kincaid (Kincaid *et al.*, 1968) showed progressive change in six of 16 patients, while Meaney (Meaney *et al.*, 1968) indicated that only two of 40 cases with medial fibroplasia demonstrated change in appearances between successive examinations. In the same series these latter authors defined progressive change in seven of eight cases with other varieties of fibrous arterial disease.

The aetiology of fibromuscular arterial disease has not been established, but hypotheses include :

- (1) Stretching, especially in pregnancy (Kaufman *et al.*, 1964 ; Palubinskas, 1963).
- (2) Abnormal renal mobility associated with vascular injury (Derrick and Hanna, 1963).
- (3) Haemorrhage and thrombosis (Hunt *et al.*, 1962).
- (4) Association with aneurysmal dilatations (Palubinskas *et al.*, 1965 ; Belber *et al.*, 1968 ; Harrison *et al.*, 1967).

\* Supported in part by the Medical Staff Research and Education Fund of Wayne County General Hospital, Eloise, Michigan, and NIH research grant 5 S01 FR-5383-06, The University of Michigan, Ann Arbor, Michigan, and HE-12532-01, Wayne County General Hospital, Eloise, Michigan.

- (5) Loss of segmental innervation (Wylie *et al.*, 1962).
- (6) Turbulence in arterial walls lacking stiffness (Twig *et al.*, 1965).
- (7) Increased oscillatory backflow (Lehrer, 1967).

This list is by no means complete, but includes those only from which an experimental animal approach can be easily made. Many associations with intrinsic deficiency of the elastic tissue, cystic medial necrosis, mesenchymal tumour, infection and a prominent hereditary association have been documented.

The association with stretching and the tendency to the disorder may well be clinically pertinent in cases of cadaveric renal transplantation where, because the kidney is placed caudally, stretching of the grafted artery may ensue. Morbid cases of subarachnoid haemorrhage prove an important source of cadaver kidneys, and if an intrinsic tissue defect association between cerebral aneurysm and renal fibromuscular arterial disease could exist it is conceivable that stretching may allow development of arterial changes. Smellie (Smellie *et al.*, 1969) have shown angiographic stenosis in transplantation cases with subsequent hypertension, but attribute the changes to intimal fracture and trauma.

The animal experimental approach in the study includes :

- (1) Stretching of the renal artery (27 animals).
- (2) Observations in pregnancy (three animals).
- (3) Hormonal supplements in animals with stretched arteries (13 animals).
- (4) Production of dissecting aneurysm (one animal).
- (5) Denervation of the renal artery (five animals).
- (6) Haemorrhage and thrombosis (18 animals).
- (7) Turbulence within vessels (six animals).

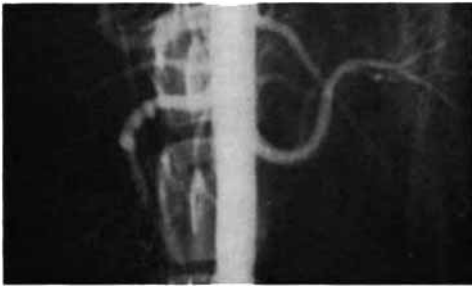


FIGURE 1.—Arteriographic appearance 12 days post-stretching.




FIGURE 3.—Small areas of intimal thickening with disruption of internal elastic membrane (arrow).

(1) *Stretching of the Renal Artery*

The biggest group has been reported previously (Rothfield, 1969), and although further long-term studies are still in progress the preliminary experimentally produced radiographic appearances (Figure 1) and pathological changes (Rothfield, 1968) have not been sustained.

The relation between stretching of the renal artery and the production of irregular arteriographic change has not been well established. In all cases where stretching had been maintained for a considerable period thickening of the intima and collagenous fibrosis could be seen, especially when comparison was made between this portion of the renal artery and that close to the aortic origin. At times minimal irregularity of arteriographic appearances (Figure 2) coincided with small areas of intimal thickening (Figure 3) with disruption of the internal elastic membrane. In one case with a

stretching period of 358 days a thickening of fibrous type (Figure 4) correlated well with well-marked intimal thickening and disruption of the internal elastic layer (Figure 5). This non-specific fibrosis has been seen in other situations. It bears resemblance to the intimal fibrosis described by Dahl (Dahl *et al.*, 1961) after adventitial trauma. Intimal thickenings were shown in hypertensive rats by Still (1968)

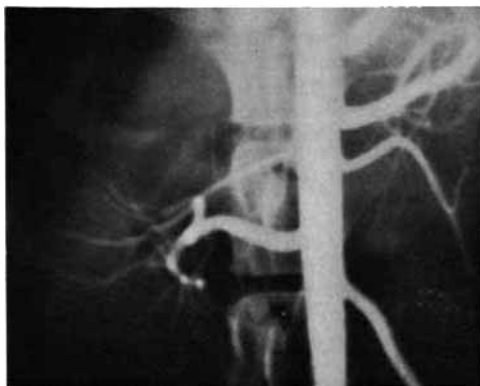


FIGURE 2.—Minimal arteriographic irregularity near bifurcation.

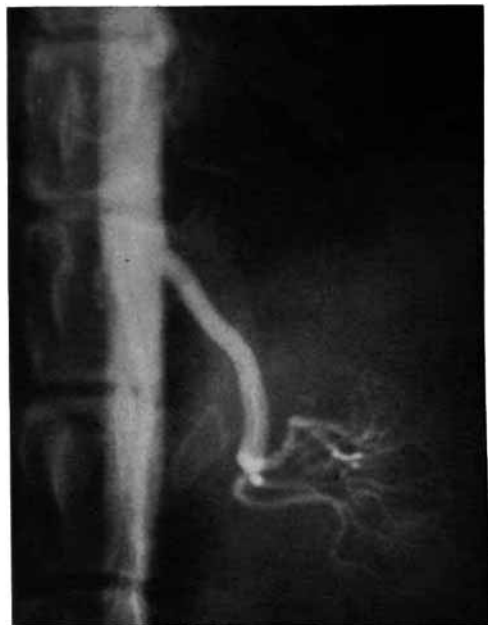

FIGURE 4.—Fibrous type thickening with narrowing of portion of contrast column near bifurcation.

with marked mononuclear infiltration associated with fibrinoid necrosis and fibrous deposition. Obliterative intimal fibrosis of major renal arteries was shown by Tolnai (Tolnai *et al.*, 1969) in patients dialysed for renal failure. They suggest that these changes represent an adaptation to the replacement of renal function by dialysis as well as anoxia of the intima with decreasing blood flow.

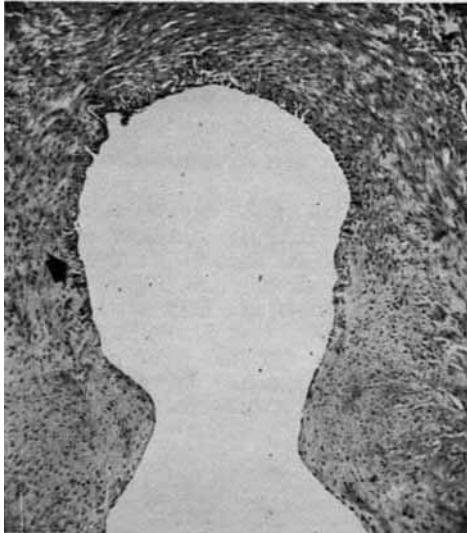

FIGURE 5.—Well-marked intimal thickening with disruption of internal elastic layer (arrow).

This fibrotic change produced by this type of stretching probably represents a reaction of the fibroblast within the arterial wall to stress, with the associated production of collagen. The absence of progressive arteriographic change following stretching is noteworthy, and although the pathological changes of intimal thickening and fibrosis were better seen in cases of long standing, the resolution of many early changes and the lack of serially demonstrable arteriographic deformity as a constant phenomenon suggests that stretching only produced a temporary change with an additional factor being responsible.

#### (2) Observations in Pregnancy

With the high female incidence of the complaint, the occasional occurrence of renovascular hypertension with pregnancy (Zanchetti, 1965) and the many cases seen in women following recent pregnancy, a small

number of dogs were examined during and after pregnancy. No definite irregular changes could be defined or any change in appearance shown.

#### (3) Hormonal Supplements in Animals with Stretched Arteries

Male and female animals were given a hormonal supplement of Depoestrin 5 mg. (Upjohn) every six weeks. This included dogs with stretched arteries (25 arteries) and those with non-stretched arteries (eight arteries).

The number of minor irregularities seen in later examination for this group is compared with those without hormonal supplements (Table 1).

TABLE I

Degree of Stretching	Stretching With Hormonal Supplement	Stretching Without Hormonal Supplement
Group I ..	1 out of 4	1 out of 4
Group II ..	2 out of 9	3 out of 15
Group III ..	2 out of 8	2 out of 8
Group IV ..	1 out of 4	0 out of 3

No significant increase in the extent of irregular change with hormone supplement was shown. But again where minimal change was seen arterial thickenings were demonstrated pathologically. However, no progressive change was ever demonstrated over a period of up to 380 days.

#### (4) Production of Dissecting Aneurysm

Inadvertent production of a dissecting aneurysm within the renal artery was obtained, but no progressive change was seen. Clinical associations of renal artery aneurysm, splenic aneurysm, intracranial aneurysm, and arteriovenous fistula (Bron *et al.*, 1968) may be coincidentally associated with the renal angiographic procedure and not truly causally related.

#### (5) Denervation of the Renal Artery

Denervation was carried out in one case on an accessory artery in a kidney that was stretched, but no irreversible change was seen, the irregularity following the arterial stripping soon disappearing. In similar strippings of single renal arteries no definite change resulted.

#### (6) Haemorrhage and Thrombosis

Haemorrhages and thrombosis were produced in many cases, but appearance soon resolved

and it would appear that such a reaction is not primarily contributory. In clinical studies their role may well be important in the alteration of appearances seen following these complications, but there is little to suggest their importance as a primary aetiological concept.

#### (7) *Turbulence within Vessels*

Turbulence in vessels, especially where the wall is not fixed, has been cited by Twigg (Twigg *et al.*, 1965) to be a possible aetiological factor. This may relate to increased oscillatory backflow that Lehrer (1967) suggests may be responsible for early changes, initially reversible but later fixed.

Such an hypothesis was attempted to be tested *in vivo* by an experimental approach in which the lateral genicular branch of the femoral artery was displaced without interference to the superficial femoral vessel. Such alteration in the flow would certainly alter the lateral pressure at the branch site and possibly cause turbulence and backflow. Angiographic visualization of the femoral vessel proximal to the branch was made over periods of up to 175 days with the following different parameters:

- (1) Different pressure of injection.
- (2) Type of contrast medium varying from 30% Sodium Diatrizoate to 76% Renografin.
- (3) The site of catheter placement was varied from an antegrade position in the common iliac artery to an antegrade position in the common femoral or a retrograde position in the posterior tibial.
- (4) Under influences of the following drugs: papaverine hydrochloride 15 mg., isoxsuprine hydrochloride 5 mg., phentolamine 5 mg., metaraminol 5 mg., propranolol 0.5 mg., tolazoline 12.5 mg., pentolinium tartrate 5 mg., levarterenol bitartrate 1 mg., methacholine chloride 12.5 mg., dibenzylamine 10 mg.

No significant permanent findings have been achieved possibly because of reactive hyperaemia which may limit oscillatory backflow (Lehrer, 1967). It would appear that the larger vessels than the femoral may be required to create sufficient turbulence. An experimental protocol involving such vessels is proceeding.

#### SUMMARY AND CONCLUSIONS

All of the experimental areas are still under study with no progressive changes being recorded at this time. Some of the non-specific pathology changes of intimal thickening and collagenous fibrosis with disruption of internal elastic membrane are encouraging enough to allow long-term studies to be continued.

It is hoped that with long-term study a definite statement about the significance of stretching in the aetiology of fibromuscular dysplasia can be made.

#### REFERENCES

- Belber, C. J., and Hoffman, R. D. (1968): *J. Neurosurg.*, **28**, 556.
- Bron, K. M., and Redman, H. (1968): *Ann. intern. Med.*, **68**, 1039.
- Dahl, E. V., Edwards, E. C., Grindlay, J. H., and Edwards, J. E. (1961): *Surgery*, **50**, 533.
- Derrick, J. R., and Hanna, E. (1963): *Amer. J. Surg.*, **106**, 623.
- Harrison, E. G., Hunt, J. C., and Bernatz, P. E. (1967): *Amer. J. Med.*, **43**, 97.
- Hunt, J. C., Harrison, E. G., Jr., Kincaid, O. W., Bernatz, P. E., and Davis, G. D. (1962): *Proc. Staff Meet. Mayo Clinic*, **37**, 181.
- Kaufman, J. J. (1965): *J. Urol.*, **94**, 211.
- Kaufman, J. J., Hanafec, W., and Maxwell, M. H. (1964): *J. Amer. med. Ass.*, **187**, 977.
- Kincaid, O. W., Davis, G. D., Hallermann, F. J., and Hunt, J. C. (1968): *Amer. J. Roentgenol.*, **104**, 271.
- Leadbetter, W. F., and Burkland, C. E. (1938): *J. Urol.*, **39**, 611.
- Lehrer, H. (1967): *Radiology*, **89**, 11.
- McIntosh, D. A., McPhaul, J. J., Williams, L. F., and Gritti, E. J. (1966): *Arch. Surg.*, **92**, 60.
- Meaney, T. F., Dustan, H. P., and McCormack, L. J. (1968): *Radiology*, **91**, 881.
- Page, I. H., and McCubbin, J. W. (1968): *Renal Hypertension*. Year Book Pub., Chicago, p. 336.
- Palubinskas, A. J. (1963): *Excerpta med. Internat. Congress Series*, **78**, 382.
- Palubinskas, A. J., Perloff, D., and Newton, T. H. (1965): *Radiology*, **98**, 907.
- Palubinskas, A. J., and Wylie, E. J. (1961): *Radiology*, **76**, 634.
- Rothfield, N. J. H. (1968): *Radiology*, **91**, 1233.
- Rothfield, N. J. H. (1969): *Radiology*, **93**, 1291.
- Smellie, W. A. B., Vinik, M., and Hume, D. M. (1969): *Surg. Gynec. Obstet.*, **128**, 963.
- Still, W. J. (1968): *Lab. Invest.*, **19**, 84.
- Tolnai, G., Sarkar, K., Jaworski, Z. F., *et al.* (1969): *Canad. med. Ass. J.*, **100**, 116.
- Twigg, H. L., and Palmisano, P. J. (1965): *Amer. J. Roentgenol.*, **95**, 418.
- Wylie, E. J., Perloff, D., and Wellington, J. S. (1962): *Ann. Surg.*, **156**, 592.
- Zanchetti, A. (1966): *Antihypertensive Therapy Principle and Practice*. F. Gross (Ed.). Springer-Verlag, New York, p. 337.