

# Maternal Intrachromosomal Insertional Translocation Leads to Recurrent 1q21.3q23.3 Deletion in Two Siblings

Shane C. Quinonez,<sup>1</sup> Peter Hedera,<sup>2</sup> Mason Barr,<sup>3</sup> Todd Ackley,<sup>1</sup> Cindy Lam,<sup>4</sup> Anjali Purkayastha,<sup>4</sup> Thomas W. Glover,<sup>1,5</sup> and Jeffrey W. Innis<sup>1,5\*</sup>

<sup>1</sup>Division of Genetics, Department of Pediatrics, University of Michigan, Ann Arbor, Michigan

<sup>2</sup>Division of Movement Disorders, Department of Neurology, Vanderbilt University, Nashville, Tennessee

<sup>3</sup>Teratology Unit, Division of Genetics, Departments of Pediatrics, Pathology, and Obstetrics, University of Michigan, Ann Arbor, Michigan

<sup>4</sup>Department of Pathology, The University of Michigan, Ann Arbor, Michigan

<sup>5</sup>Department of Human Genetics, The University of Michigan, Ann Arbor, Michigan

Manuscript Received: 9 May 2012; Manuscript Accepted: 17 June 2012

We identified a novel 6.33 Mb deletion of 1q21.3q23.3 (hg18; chr1: 153035245–159367106) in two siblings presenting with blepharophimosis, ptosis, microbrachycephaly, severe psychomotor, and intellectual disability. Additional common features include small corpus callosum, normal birth length and head circumference, postnatal growth restriction, low anterior hairline, upturned nose, bilateral preauricular pits, widely spaced teeth, gingival hypertrophy, left ventricular dilatation with decreased biventricular systolic function, delayed bone age, 5th finger clinodactyly, short 3rd digit, hyperconvex nails, obstructive and central sleep apnea, and bilateral heel contractures. Fluorescence in situ hybridization (FISH) performed in the mother of both children showed an apparently balanced, intrachromosomal insertional translocation of 1q21.3q23.3 to 1q42.12. The sibling recurrence likely arose by a maternal meiotic crossing over on the rearranged chromosome 1 between the deleted region and the insertion. We hypothesize that the decreased cardiac function and contractures may be related to *LMNA* haploinsufficiency. This case illustrates the importance of FISH when attempting to determine inheritance of a copy-number variation and emphasize the value of evaluating known haploinsufficiency phenotypes for genes in deleted regions.

© 2012 Wiley Periodicals, Inc.

**Key words:** blepharophimosis; developmental delay; chromosome 1q deletion; Ohdo-like syndrome; BMR syndrome

## INTRODUCTION

The use of array-comparative genomic hybridization (CGH) has allowed clinicians to detect pathogenic copy number losses and gains with ever increasing sensitivity. Abnormal results require further laboratory investigation not only for confirmation purposes, but also to investigate whether the genomic gain or loss occurred de novo or was the result of a parental chromosomal

### How to Cite this Article:

Quinonez SC, Hedera P, Barr M, Ackley T, Lam C, Purkayastha A, Glover TW, Innis JW. 2012. Maternal intrachromosomal insertional translocation leads to recurrent 1q21.3q23.3 deletion in two siblings. *Am J Med Genet Part A* 158A:2591–2601.

abnormality. Fluorescence in situ hybridization (FISH) may provide critical information about parental balanced insertional translocations or other chromosomal rearrangements that may otherwise be missed and can impact recurrence risk significantly. Insertional translocations can be: (a) simple intrachromosomal or interchromosomal insertional translocations or (b) complex insertional translocations [Kang et al., 2010]. Nowakowska et al. [2011] found that 2.1% of array abnormalities were the consequence of a parental balanced insertional translocation. This may be an underestimate since not all parents were available for evaluation in their study and very small array abnormalities were not fully evaluated given the limitations of FISH. However, this supports the importance of FISH confirmation when faced with an array abnormality.

There are multiple patients described in the literature with deletions that include part or all of 1q21–q23 [Estevez de Pablo et al., 1980; Schinzel and Schmid, 1980; Moghe et al., 1981; Martin and Simpson, 1982; Taysi et al., 1982; Silengo et al., 1984; Beemer

\*Correspondence to:

Jeffrey W. Innis, M.D., Ph.D., Department of Human Genetics, 4811 Med Sci. II, 1241 E. Catherine St., Ann Arbor, MI 48109-5618.

E-mail: innis@umich.edu

Article first published online in Wiley Online Library (wileyonlinelibrary.com): 17 August 2012

DOI 10.1002/ajmg.a.35563

et al., 1985; Franco et al., 1991; Leichtman et al., 1993; Lo et al., 1993; Melis et al., 1998; Waggoner et al., 1999; Pallotta et al., 2001; Monica et al., 2007; Reddy et al., 2009]. Variable sizes and deletion endpoints on 1q21-q23 give rise to a wide variety of clinical problems.

We present a male proband and his female sibling with highly similar features including blepharophimosis, ptosis, developmental intellectual disability, postnatal growth restriction, numerous dysmorphic features, obstructive/central sleep apnea, and seizures. Initial karyotypes performed prior to the advent of chromosomal microarrays showed normal G-banded results. Re-evaluation of these children with chromosomal microarray studies showed a 6.33 Mb loss of chromosome 1q21.3q23.3 (hg18; chr1: 153035245–159367106) in both children, that resulted from the unbalanced product inherited from a maternal insertional translocation. We describe the clinical, cytogenetic, and molecular features of these siblings, and we compare their phenotypes to deletion 1q21-q23 cases in the literature.

## MATERIALS AND METHODS

Research was approved by the Institutional Review Board for Human Subject Research at the University of Michigan. Informed consent was obtained from the family. Chromosomal microarray analyses were conducted in the Michigan Medical Genetics Laboratories (MMGL) at the University of Michigan using two oligonucleotide-based array platforms with whole genome coverage: a custom-designed EMArray Cyto6000 chip, implemented on the Agilent 44K platform [Baldwin et al., 2008], which originally identified a 6.5 Mb deletion, and the Agilent human genome G4411B 244K array platform (Agilent Technologies Inc., Santa Clara, CA) to refine the boundaries of the deletion interval to 6.33 Mb (the latter is shown in Fig. 2). The procedures for DNA digestion, labeling, and CGH were as described in Agilent oligonucleotide-based array CGH for genomic DNA analysis, Protocol version 4.0 June 2006 (Agilent Technologies, Inc.) with some modifications [Baldwin et al., 2008]. The fluorescent signals on the array slides were detected and scanned into image files using the GenePix 4200A scanner and GenePix-Pro 6.1 software (Axon Instruments/Molecular Devices Corp., Union City, CA). The array images were imported and converted for display by Agilent Feature Extraction 9.5 software. Data were analyzed by Agilent's CGH Analytics 3.5 software to determine copy number variation between experimental DNA and a sex mismatched control DNA preparation. Numbering of the Cyto6000 44K EMArray and 244K Agilent array results utilized the UCSC hg18 (Build 36.1, March 2006) assembly. The resultant data were extracted using Feature Extraction software, version 9.5.1.1, and analyzed and plotted using CGH Analytics version 3.5.14 or DNA analytics version 4.0.81 (both from Agilent Technologies) using ADM-1 algorithm with a sensitivity threshold of 6.7 (for Agilent 244k arrays the settings are ADM-2 algorithm with a sensitivity threshold of 6.0). Gains and losses were called according to interpretation criteria established by the International Standard Cytogenomic Array (ISCA) Consortium, as described in Baldwin et al. [2008]. The resulting log<sub>2</sub> derivatives of the patient:control signal intensity ratios were plotted relative to the genomic location of the corresponding probes. For detection of gains or losses the thresholds for the log<sub>2</sub> ratios were set at -0.32

for losses and 0.26 for gains. A minimum of four contiguous oligonucleotide probes showing loss or gain of signal intensity was required to make an aberration call. The deletion was verified in the patients using BAC probe RP11-101J8 (Bluegenome, Cambridge, UK) in metaphase FISH. This same probe was used for parental FISH analysis. To determine the orientation of the insertion in the maternal chromosome 1, an additional BAC RP11-307C12 probe (Bluegenome), mapping within the deleted region, was used. Metaphase FISH was performed by standard methods in the University of Michigan Clinical Cytogenetics Laboratory.

## CLINICAL REPORT

Patient 1 was the product of an uncomplicated first pregnancy to a 29-year-old woman whose prenatal ultrasounds exams were normal. He was born at 41 weeks gestation via cesarean due to failure to progress. At birth, weight, occipitofrontal head circumference (OFC), and length were at the 28th, 25th, and 25th centiles, respectively. Dysmorphic features observed at birth included: bilateral preauricular pits, low set and small ears which measured 3.0 cm (right; -3.5 SD) and 3.2 cm (left; -3.5 SD), overfolded helices, wide nasal bridge with an inner canthal distance of 2.5 cm (+2 SD), short palpebral fissures of 1.4 cm (-3 SD), bulbous nose with nasal septum extending below the nasal alae, right eyelid ptosis, and retrognathia. Figure 1 shows facial features of Patient 1 at 7, 9, and 16 years of age. Echocardiogram showed a secundum atrial septal defect (ASD) and apical muscular ventricular septal defect (VSD), a dilated left ventricle, and patent ductus arteriosus (PDA), which was closed by coil occlusion at 17 months of age; ASD and VSD, closed spontaneously. Bilateral inguinal hernias were surgically corrected on day of life 2 by herniorrhaphy. A persistent undescended right testicle was surgically corrected by orchiopexy at 2 years of age. A gastric feeding tube and Thal fundoplication were performed at 6 months of age. At 16 months of age, his weight, OFC, and height were 9.9 kg (11th centile), 45 cm (3rd centile), and 70.5 cm (<3rd centile; 50th centile for an 11-month-old), respectively. Exam showed bilateral blepharophimosis and ptosis. At 16 months he began sitting unsupported, pulling to stand briefly with the assistance of furniture and began rolling over in both directions. Radiographic evaluation at 16 months showed a bone age of 1 year; radiographs also showed mild shortening of the middle phalanges of the 5th fingers, consistent with bilateral clinodactyly. At 35 months of age he began cruising and following simple commands but had not developed a pincer grasp.

The patient developed tonic seizures twice at 3.5 years of age. Brain magnetic resonance imaging (MRI) indicated the presence of a small corpus callosum and a small volume brain stem. Brain computed tomography (CT) showed microcephaly with low-density white matter. Gray matter irregularities were also noted with increased gyrations present consistent with possible heterotopia and cortical dysplasia. Electroencephalogram (EEG) showed left frontal central epileptiform activity with mild diffuse neuronal dysfunction. He was treated for only 1.5 months with the anti-convulsant Phenytoin (Dilantin), after which it was discontinued. He subsequently experienced two seizures at 8 years of age with an EEG showing multifocal spikes and background slowing. He was treated with the anti-convulsant Levetiracetam (Keppra) from 8 to

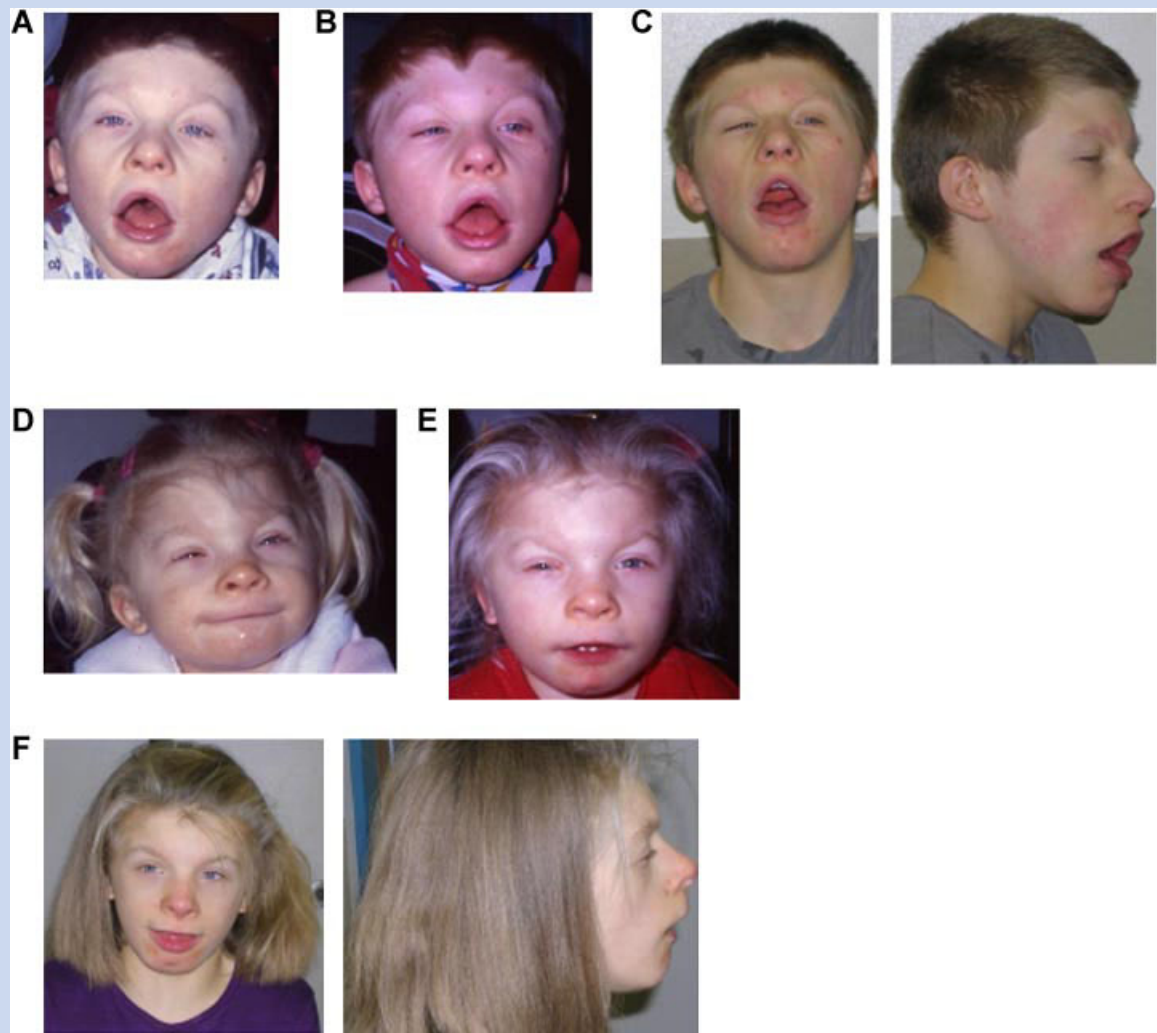


FIG. 1. Facial features of male at (A) 7 years of age, (B) 9 years, and (C) 16 years. Facial features of female at (D) 2 years of age, (E) 4 years, and (F) 9 years. Note low anterior hairline, blepharophimosis, low set ears, corpuscular lobules, upturned nose, and thin vermilion border.

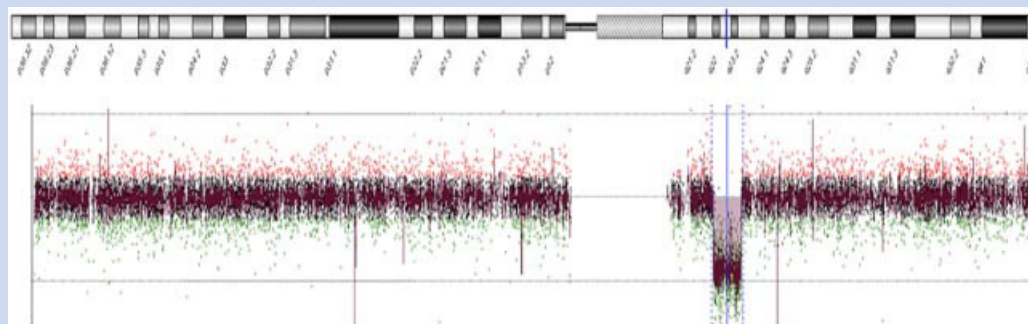


FIG. 2. Chromosomal microarray (CMA) results detailing a 6.33 Mb deletion on chromosome 1 q21.3q23.3 (hg18; chr1: 153035245–159367106).

10 years of age and then weaned off of all anti-epileptic medication, with no further seizures to date. He ambulated with assistance at 7 years of age. At 7 years, all growth centiles were <5th centile, sleep studies showed both obstructive and central apneas, which improved with oxygen supplementation, and a trial of continuous positive airway pressure (CPAP) was unsuccessful. Increased tone was noted in his lower extremities at 8 years.

At 16 years of age he was walking independently and following simple commands, yet he had no expressive language. His weight, OFC, and height were 37.9 kg ( $-3$  SD), 51.7 cm (<3rd centile; 50th centile for a 4-year-old), and 130 cm (<3rd centile; 50th centile for 8-year-old), respectively. His ears were normally set and measure 5.7 cm (left;  $-1$  SD) and 5.4 cm (right;  $-1.5$  SD). Eye exam demonstrated an interpupillary distance of 5.5 cm (25th centile), inner canthal length of 3.2 cm (50th centile), and an outer canthal distance of 8.0 cm (10th centile). Palpebral fissures measured 2.4 cm (left;  $-5$  SD) and 2.3 cm (right;  $-5$  SD). He had slightly arched eyebrows, a flat philtrum of normal length, a tented upper lip, widely spaced teeth, and prominent gingival hypertrophy. He drooled persistently. Extremity exam showed limitation of extension and supination of his arms bilaterally. His left palm measured 10.5 cm (30th centile) with total hand length of 17.0 cm (15th centile). His right palm measured 10.5 cm (30th centile) with a total hand length of 17.2 cm (20th centile). Middle finger lengths measured 6.5 cm (left; <3rd centile, ~50th centile for 9.5-year-old) and 6.7 cm (right; <3rd centile, ~50th centile for 10-year-old). Bilateral 2nd toenails and right 5th toenail were hyperconvex. Toes were short with bilateral distal valgus positioning of the 1st toe. The feet measured 22.3 cm (left;  $-3$  SD) and 21.5 cm (right;  $-4$  SD). The patient walked with both hips and knees flexed. He had bilateral heel contractures, treated with ankle-foot orthoses, limitation of full knee extension, and a  $37^\circ$  curvature of the lumbar-thoracic to low lumbar spine on radiographs.

Recent cardiac evaluation and echocardiography at 17 years of age showed Patient 1 to have mildly diminished right ventricular and mild-moderately diminished left ventricular systolic function with mild dilation of the left ventricle ( $Z$ -score  $+2.5$ ). Electrocardiographic evaluation, including Holter monitoring, showed no conduction abnormalities. Given the decreased systolic function Patient 1 was started on Enalapril (Vasotec) for afterload reduction.

Following the birth of Patient 1 the mother experienced two spontaneous miscarriages at 17 weeks gestation and between 14 and 15 weeks gestation. Fetal autopsy of the latter showed no major malformations and the cause of the demise was not identified.

Patient 2 is the younger female sibling of Patient 1. The pregnancy was complicated by intrauterine growth restriction and premature and prolonged rupture of membranes. The patient was born at 35 weeks gestation via vaginal delivery. Upon delivery, Apgar scores were 3, 6, and 9 at 1, 5, and 10 min, respectively. At birth, her weight, OFC and length were at the 3rd, 30th, and 5th centiles, respectively. Figure 1 shows facial features of Patient 2 at 2, 4, and 9 years of age. She remained in the neonatal intensive care unit for 15 days secondary to preterm delivery and hyperbilirubinemia (maximum of 9.1 mg/dl) that was treated successfully with phototherapy. She was also diagnosed with transient thrombocytopenia requiring 1 platelet transfusion. The patient's growth centiles progressively fell during infancy. The patient began using

oxygen supplementation between 3 and 4 months of age following a viral infection. Since then, she has continued with nighttime oxygen via nasal cannula with sleep studies showing obstructive and central apneas, which improved on oxygen. Like her brother, a trial of CPAP was unsuccessful. At 6 months of age she required gastrostomy tube placement and Nissen fundoplication due to poor weight gain and gastroesophageal reflux. She had severe global developmental delay, sitting at 15 months of age but unable to roll over. Dysmorphic facial features include microcephaly, prominent metopic ridge, blepharophimosis, upturned nose, bilaterally overfolded and thickened helices and high palate. The patient experienced a generalized tonic-clonic seizure at 2 years. EEG at that time showed left frontal lobe hyperactivity. No other seizures have been recorded. Brain MRI showed mildly diminutive corpus callosum and Arnold-Chiari malformation with cerebellar tonsils extending 6–7 mm below the foramen magnum. Increased tone was noted in the lower extremities.

At 11 years of age, she walked independently and followed simple commands but had no expressive language. Her weight was 26.4 kg (1st centile) and head circumference was 47.6 cm (<3rd centile,  $-4$  SD). She had not yet entered puberty. She had coarse golden-brown hair, a low anterior hairline, and preauricular pits bilaterally. Her ears measured 5.0 cm (left;  $-2.5$  SD) and 4.8 cm (right;  $-2.5$  SD) and they were normally set. She had blepharophimosis and ptosis. Her interpupillary distance measured 5.4 cm (50th centile); inner canthal distance was 3.3 cm ( $+1$  SD); outer canthal distance was 7.8 cm ( $-1.5$  SD) and palpebral fissures measured 2.2 cm (left;  $-5$  SD) and 2.0 cm (right;  $-5$  SD). She had anteverted nares, a flattened philtrum, thin upper lip vermilion, gingival hypertrophy, and widely spaced teeth. She had normal range of motion of the upper extremities. Her left palm measured 9.0 cm (45th centile) with a total left hand length of 15.2 cm (25th centile). The right palm measured 8.7 cm (35th centile) with a total right hand length of 15 cm (15th centile). Middle finger lengths measured 6.2 cm (left; 15th centile) and 6.3 cm (right; 20th centile). She had hyperconvex 2nd and 5th toenails bilaterally, and bilateral 5th finger clinodactyly. Her left foot measured 18.0 cm ( $-4$  SD) and right foot was 19.5 cm ( $-3$  SD). She had bilateral heel contractures treated with ankle-foot orthoses.

At 12 years of age Patient 2 underwent formal cardiology evaluation. Echocardiography showed mildly diminished right and left ventricular systolic function as well as a mildly dilated left ventricle ( $Z$ -score  $+2.3$ ). Electrocardiogram showed a first degree atrio-ventricular (AV) block confirmed by Holter monitoring showing as well an isolated sinus node exit block with occasional junctional escape. Given the diminished systolic function Patient 2 was placed on Enalapril (Vasotec) for afterload reduction.

## RESULTS

Both siblings had normal peripheral blood G-banded karyotypes and normal subtelomeric FISH analysis. Because Patient 1 had features similar to blepharophimosis, ptosis, and epicanthus inversus syndrome (BPES; OMIM 110100) we performed *FOXL2* DNA sequencing and FISH for a 3q23 microdeletion at the *FOXL2* locus given that 12% of patients with BPES have a deletion of *FOXL2* [Beysen et al., 2009; D'haene et al., 2010]. Both studies were normal



in Patient 1. A maternal blood karyotype performed in 1997 showed a probable paracentric inversion  $46,XX,inv(1)(q42.11q42.3)$ , which was not studied further. Combined microarray and FISH analyses of new maternal samples obtained because of the discovery of deletions in her offspring, showed this instead to be an intra-chromosomal insertional translocation involving chromosome 1. Both siblings showed a 6.33 Mb single copy deletion of  $1q21.3q23.3$  by chromosomal microarray (CMA; Fig. 2), which was confirmed by metaphase FISH with BAC probe RP11-101J8 (Fig. 3). Parental FISH analysis with probe RP11-101J8 showed normal paternal studies and an insertion of  $1q21.2q23.3$  material at  $1q42.12$  on one maternal chromosome 1 homologue. The insertion was determined to be direct (same orientation), by FISH using BAC probes RP11-101J8 and RP11-307C12, which map within the inserted region. Maternal peripheral blood CMA (Agilent, 244K) was normal indicating that, at the resolution of the CMA used, the insertion appears balanced. Figure 3 shows the results of FISH studies for the mother and Patient 2. These results suggest that the occurrence of  $del(1)(q21.3q23.3)$  in both siblings likely occurred via recurrent maternal meiotic crossing over between  $1q21.3q23.3$  and the insertional translocation at  $1q42$ .

## DISCUSSION

We describe two siblings with a unique combination of features associated with a 6.33 Mb deletion of  $1q21.3q23.3$  (hg18; chr1: 153035245–159367106). The major features shared by them include severe intellectual disability, normal birth length and head circumference, postnatal growth restriction, microbrachycephaly, blepharophimosis, ptosis, upturned nose, bilateral preauricular pits, widely spaced teeth, gingival hypertrophy, left ventricular dilatation with decreased biventricular systolic function, delayed bone age, 5th finger clinodactyly, short 3rd digit, heel contractures, short feet, and hyperconvex nails. Both patients also exhibit central and obstructive sleep apnea, requiring oxygen therapy, and seizures with brain imaging showing a small corpus callosum. Congenital heart defects (ASD, VSD, and PDA) were seen only in Patient 1.

The deletions in Patients 1 and 2 resulted from inheritance of a meiotic recombination product involving a maternal chromosome carrying an apparently balanced insertion of 6.33 Mb of material from  $1q21.3q23.3$  inserted into  $1q42.12$ . Maternal meiotic recombination likely occurred between the deletion and insertion sites on

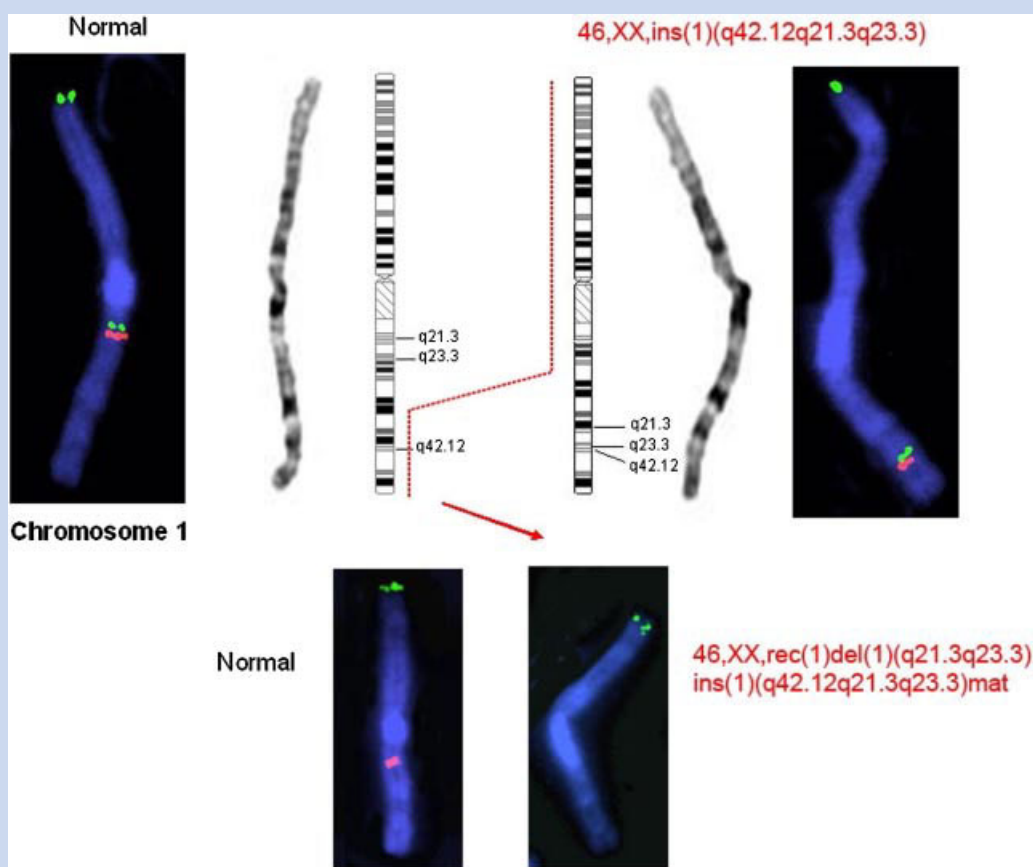


FIG. 3. Chromosome 1 metaphase FISH studies in mother [top] showing normal and insertional translocation chromosomes, and normal and recombinant chromosome [with deletion] in daughter [bottom]. Control chr1 telomeric BAC probe [green telomeric signal], and BAC probes for  $1q21.3q23.3$  [green and red interstitial signals, RP11-101J8 and RP11-307C12, which allowed for assessment of directionality of the insertion].





TABLE II. OMIM Disease Genes in Deleted Interval

OMIM-disease Gene	Gene/Protein	Disorder (OMIM #)	Clinical Characteristics	Inheritance
605951	<i>DPM3</i> /Dolichyl-phosphate mannosyltransferase 3	Congenital disorder of glycosylation, type 1c [612937]	Mild proximal muscle weakness, low-normal IQ, DCM, increased CK and LFTs, mild skeletal MD	AR
606463	<i>GBA</i> /Glucosidase, beta, acid	Gaucher disease, perinatal [608013], I [230800], II [230900], III [231000], IIIc [231005]	HSM, ocular/skeletal/neurologic abnormalities. Variable phenotype	AR
609712	<i>PKLR</i> /Pyruvate kinase, liver and RBC type	Adenosine triphosphate, elevated, of erythrocytes [102900], Pyruvate kinase deficiency [266200]	102900: Polycythemia	102900:AD
610389	<i>MAPBP</i> /MAPBP-interacting protein	Immunodeficiency due to defect in MAPBP-interacting protein [610798]	266200: HA	266200: AR
607292	<i>SEMA4A</i> /Semaphorin 4A	Cone-rod dystrophy [610283], Retinitis Pigmentosa 35 [610282]	Short stature, coarse facial features, pulmonary infections, hypopigmented skin, low IgM and PMN count	610283: AR
150330	<i>LMNA</i> /Lamin A/C	Cardiomyopathy, dilated 1A [115200] Charcot-Marie-Tooth disease, type 2B1 [60588], Emery-Dreifuss muscular dystrophy [181350/604929] Hutchinson-Gilford progeria [176670] Lipodystrophy, familial partial [151660] Mandibuloacral dysplasia [248370] Muscular dystrophy, limb-girdle, type 1B [159001]	6.10282: Progressive loss of visual acuity/vision, macular degeneration 6.10282: Progressive vision loss, bone corpuscle-like pigmentation in equatorial and peripheral areas 115200: Congestive cardiomyopathy, Adams-Stokes attacks	610282: AD/AR 115200: AD/AR 605588: AR
			60588: Peripheral neuropathy, onset in 20's	*181350: AD (1 family with a nonsense mutation others with missense or codon deletions)
			181350/604929: DCM, progressive muscle weakness/atrophy, onset early childhood	604929: AR
			176670: Postnatal growth retardation, premature aging, early onset death	176670: AD
			151660: Partial lipodystrophy (facial/neck sparing), DM, muscular hypertrophy	151660: AD
			248370: Postnatal growth retardation, mandibular hypoplasia, bird-like facies, partial alopecia, DM	248370: AR
			159001: DCM, muscle weakness	159001: AD



179755	<i>PRCC</i> /Proline-rich protein <i>PRCC</i>	Renal Cell carcinoma, papillary, 1 (605074)	t(X;1)(p11.2;q21.2), causes fusion of <i>PRCC</i> with the gene <i>TFE3</i> and loss of normal <i>TFE3</i> transcripts	N/A
191315	<i>NTRK1</i> /Neutrophilic tyrosine kinase, receptor, type 1	Insensitivity to pain, congenital, with anhidrosis (256800), Medullary thyroid carcinoma, familial (155240)	256800: Decreased sensation to pain, osteomyelitis, anhidrosis, palm lichenification, dystrophic nails, ID, episodic fever. 155240: Medullary thyroid carcinoma 130600: Elliptocytosis, HA	256800: AR 155240: AD 130600: AD
182860	<i>SPTA1</i> /Spectrin, alpha, erythrocytic-1	Elliptocytosis-2, Rhesus unlinked type (130600) Pyropoikilocytosis (266140) Spherocytosis, type 3 (270970)	266140: Pyropoikilocytosis HA 270970: Spherocytosis, HA 110700: Resistance to vivax malaria	266140: AR 270970: AR *110700: AD
110700	<i>DARC</i> /Duffy chemokine receptor	Blood group, Duffy system (110700), WBC count QTL (611862) Malaria, Varivax protection against (611162)	611862: Lower WBC count 611162: Protection from malaria	611862: AR *611162: AD
610273	<i>PIGM</i> /Phosphatidylinositol, glycan class M	Glycosylphosphatidylinositol deficiency (610293)	Seizure disorder, thrombosis, HSM	AR
602208	<i>KCNJ10</i> /Potassium channel, inwardly rectifying, subfamily J, member 10	Enlarged vestibular aqueduct, digenic (600791)	600791: Sensorineural hearing loss, vestibular abnormalities	600791: AR/Digenic
182340	<i>ATP1A2</i> /ATPase, Na/K transporting, Alpha-2 polypeptide	SESAME syndrome (612780) Alternating hemiplegia of childhood (104290) Migraine, familiar basilar (602481)	612780: Seizure disorder, sensorineural hearing loss, ataxia, intellectual disability, electrolyte imbalance 104290: Episodic hemi- or quadriplegia, choreoathetoid movements, nystagmus, progressive cognitive impairment 602481: Migraine headaches, hemiplegic	612780: AR 104290: AD (missense mutations) 602481: AD (missense mutations)
600279	<i>PEX19</i> /Peroxisome biogenesis factor 19	Zellweger syndrome (21411)	Neurologic dysfunction, craniofacial abnormalities and liver dysfunction	AR
605254	<i>NCSTN</i> /Nicastrin	Acne inversa, familial 1 (142690)	Chronic acne	AD*
180300	<i>CD244</i> /CD244 Antigen	Rheumatoid arthritis, susceptibility to (180300)	Susceptibility to rheumatoid arthritis	AD (dbSNP 132: rs3766379)
191523	<i>USF1</i> /Upstream Stimulatory Factor 1	Hyperlipidemia, familial combined, susceptibility to (602491)	Susceptibility to hyperlipidemia	AD (linkage association)
609607	<i>PVLR4</i> /Poliovirus receptor-like 4	Ectodermal dysplasia-syndactyly syndrome 1 (613573)	Hair and teeth abnormalities with cutaneous syndactyly of the hands and/or feet	AR

AR = Autosomal recessive, AD = Autosomal dominant, ID = Intellectual disability, EEG = Electroencephalogram, DCM = Dilated cardiomyopathy, CK = Creatine kinase, LFT = Liver function test, MD = Muscular dystrophy, HSM = Hepatosplenomegaly, HA = Hemolytic anemia, PMN = Polymorphonuclear leukocyte, DM = Diabetes mellitus, CGH = Comparative genomic hybridization, WBC = White blood cell.  
\*indicates disorder where heterozygous loss of function mutation is associated with the disease. Derived from [OMIM, 2012].

ventricular dilation in both and AV conduction abnormalities in Patient 2. Irrespective of whether haploinsufficiency for *LMNA* may also explain this cardiac pathology, it was ultimately the review of the phenotypes caused by heterozygous losses in the deleted interval that led to consideration of the potential for cardiac involvement. Haploinsufficiency for other genes in this interval are likely contributors to abnormal CNS development and function as well as craniofacial dysmorphisms.

For many years prior to the identification of the deletion in our patients, our differential diagnosis based on their clinical features included Blepharophimosis-ptosis-epicanthus inversus syndrome (BPES), 17q21 microdeletions, and the blepharophimosis-mental retardation (BMR) family of syndromes previously known as Ohdo syndrome [Ohdo et al., 1986; White et al., 2003; Verloes et al., 2006; Koolen et al., 2008; Beysen et al., 2009]. Evaluation of patients with BPES-like phenotypes or BMR spectrum should include array CGH because the distinctions between BMR types is not always clear. Recent work in the field of Ohdo syndrome/BMR syndromes showed mutations in *KAT6B*, a histone acetyltransferase encoded on chromosome 10q22, in the Say-Barber-Biesecker variant of Ohdo syndrome [Clayton-Smith et al., 2011]. Future work will help to define whether genes in the 1q21.3q23.3 interval reported here contribute to a fraction of uncharacterized BMR syndrome cases.

## REFERENCES

- Baldwin EL, Lee JY, Blake DM, Bunke BP, Alexander CR, Kogan AL, Ledbetter DH, Martin CL. 2008. Enhanced detection of clinically relevant genomic imbalances using a targeted plus whole genome oligonucleotide microarray. *Genet Med* 10:415–429.
- Beemer FA, Klep-de Pater JM, Sepers GJ, Janssen B. 1985. Two cases of interstitial deletion of the long arm of chromosome 1: del(1)(q21q25) and del(1)(q41q43). *Clin Genet* 27:515–519.
- Benedetti S, Menditto I, Degano M, Rodolico C, Merlini L, D'Amico A, Palmucci L, Berardinelli A, Pegoraro E, Trevisan CP, Morandi L, Moroni I, Galluzzi G, Bertini E, Toscano A, Olive M, Bonne G, Mari F, Caldara R, Fazio R, Mammi I, Carrera P, Toniolo D, Comi G, Quattrini A, Ferrari M, Previtalli SC. 2007. Phenotypic clustering of lamin A/C mutations in neuromuscular patients. *Neurology* 69:1285–1292.
- Beysen D, De Paepe A, De Baere E. 2009. FOXL2 mutations and genomic rearrangements in BPES. *Hum Mutat* 30:158–169.
- Bonne G, Rffaele Di Barletta M, Varnous S, Becane HM, Hammouda EH, Merlini L, Muntoni F, Greenberg CR, Gary F, Urtizbera JA, Duboc D, Fardeau M, Toniolo D, Schwartz K. 1999. Mutations in the gene encoding lamin A/C cause autosomal dominant Emery-Dreifuss muscular dystrophy. *Nat Genet* 21:285–288.
- Bonne G, Mercuri E, Muchir A, Urtizbera A, Becane HM, Recan D, Merlini L, Wehnert M, Boor R, Reuner U, Vorgerd M, Wicklein EM, Eymard B, Duboc D, Penisson-Besnier I, Cuisset JM, Ferrer X, Desguerre I, Lacombe D, Bushby K, Pollitt C, Toniolo D, Fardeau M, Schwartz K, Muntoni F. 2000. Clinical and molecular genetic spectrum of autosomal dominant Emery-Dreifuss muscular dystrophy due to mutations of the lamin A/C gene. *Ann Neurol* 2:170–180.
- Clayton-Smith J, O'Sullivan J, Daly S, Bhaskar S, Day R, Anderson B, Voss AK, Thomas T, Biesecker LG, Smith P, Fryer A, Chandler KE, Kerr B, Tassabehji M, Lynch SA, Krajewska-Walasek M, McKee S, Smith J, Sweeney E, Mansour S, Mohammed S, Donnai D, Black G. 2011. Whole-exome-sequencing identifies mutations in histone acetyltransferase gene *KAT6B* in individuals with the Say-Barber-Biesecker variant of Ohdo syndrome. *Am J Hum Genet* 89:675–681.
- D'haene B, Nevado J, Pugeat M, Pierquin G, Lowry RB, Reardon W, Delicado A, Garcia-Minaur S, Palomares M, Courtens W, Stefanova M, Wallace S, Watkins W, Shelling AN, Wiczorek D, Veitia RA, De Paepe A, Lapunizina P, De Baere E. 2010. FOXL2 copy number changes in molecular pathogenesis of BPES: Unique cohort of 17 deletions. *Hum Mutat* 31:E1332–E1347.
- Estevez de Pablo C, Garcia Sagredo JM, Ferro MT, Ferrando P, San Roman C. 1980. Interstitial deletion in the long arms of chromosome 1:46, XY,del(1)(pterq22;q25qter). *J Med Genet* 17:483–486.
- Franco B, Lai LW, Patterson D, Ledbetter DH, Trask BJ, van den Engh G, Iannaccone S, Frances S, Patel PI, Lupski JR. 1991. Molecular characterization of a patient with del(1)(q23-q25). *Hum Genet* 87:269–277.
- Kang S-H, Shaw C, Ou Z, Eng PA, Cooper L, Pursley AN, Sahoo T, Bacino CA, Chinault AC, Stankiewicz P, Patel A, Lupski JR, Cheung SW. 2010. Insertional translocation detected using FISH confirmation of array-comparative genomic hybridization (aCGH) results. *Am J Med Genet Part A* 152A:1111–1126.
- Koolen DA, Sharp AJ, Hurst JA, Firth HV, Knight SJL, Goldenberg A, Saugier-Verber P, Pfundt R, Vissers LELM, Destree A, Grisart B, Rooms L, Van der Aa N, Field M, Hackett A, Bell K, Nowaczyk MJM, Mancini GMS, Poddighe PJ, Schwartz CE, Rossi E, De Gregori M, Antonacci-Fulton LL, McLellan MD II, Garrett JM, Wiechert MA, Miner TL, Crosby S, Ciccone R, Willatt L, Rauch A, Zenker M, Aradhya S, Manning MA, Strom TM, Wagenstaller J, Krepischi-Santos AC, Vianna-Morgante AM, Rosenberg C, Price SM, Stewart H, Shaw-Smith C, Brunner HG, Wilkie AOM, Veltman JA, Zuffardi O, Eichler EE, de Vries BBA. 2008. Clinical and molecular delineation of the 17q21.31 microdeletion syndrome. *J Med Genet* 45:710–720.
- Leichtman LG, Strum D, Brothman AR. 1993. Multiple craniofacial anomalies associated with an interstitial deletion of chromosome 1(q21q25). *Am J Med Genet* 45:677–678.
- Lo LJ, Noordhoff MS, Huang CS, Chen CSH, Chen KT, Chen YR. 1993. Proximal deletion of the long arm of chromosome 1: [del(1)(q23-q25)]. *Cleft Palate Craniofac J* 30:586–589.
- Martin AO, Simpson JL. 1982. Interstitial deletion 46,XY,del(1)(q23q25). *Hum Genet* 61:277.
- Melis D, Perone L, Sperandio MP, Sabbatino MS, Tuzzi MR, Romano A, Parenti G, Andria G. 1998. Mild phenotype associated with an interstitial deletion of the long arm of chromosome 1. *J Med Genet* 35:1047–1049.
- Moghe M, Patel ZM, Peter JJ, Ambani LM. 1981. Cytogenetic studies in a selected group of mentally retarded children. *Hum Genet* 58:184–187.
- Monica MD, Lonardo F, Faravelli F, Pierluigi M, Luquetti DV, De Gregori M, Zuffardi O, Scarano G. 2007. A case of autism with an interstitial 1q deletion (1q23.3-24.2) and a de novo translocation of chromosomes 1q and 5q. *Am J Med Genet Part A* 143A:2733–2737.
- Nowakowska BA, de Leeuw N, Ruivenkamp CAL, Sikkema-Raddatz B, Crolla JA, Thoelen R, Koopmans M, den Hollander N, van Haeringen A, van der Kevie-Kersemaekers AM, Pfundt R, Mieloo H, van Essen T, de Vries BBA, Green A, Reardon W, Fryns JP, Vermeesch JR. 2011. Parental insertional balanced translocations are an important cause of apparently de novo CNVs in patients with developmental anomalies. *Eur J Hum Genet* 20:166–170.
- Ohdo S, Madokoro H, Sonoda T, Hayakawa K. 1986. Mental retardation associated with congenital heart disease, blepharophimosis, blepharoptosis, and hypoplastic teeth. *J Med Genet* 23:242–244.
- Online Mendelian Inheritance in Man, OMIM (TM). Johns Hopkins University, Baltimore, MD. MIM Number: 602483; 7/11/2012. World Wide Web URL: <http://www.ncbi.nlm.nih.gov/omim/>

- Pallotta R, Dalpra L, Ehresmann T, Fusilli P. 2001. A patient defines the interstitial 1q deletion syndrome characterized by Antithrombin III deficiency. *Am J Med Genet* 104:282–286.
- Reddy S, Dolzhanskaya N, Krogh J, Velinov M. 2009. A novel 1.4 Mb de novo microdeletion of chromosome 1q21.3 in a child with microcephaly, dysmorphic features and mental retardation. *Eur J Med Genet* 52: 443–445.
- Schinzel A, Schmid W. 1980. Interstitial deletion of the long arm of chromosome 1, del(1)(q21q25) in a profoundly retarded 8-year-old girl with multiple anomalies. *Clin Genet* 18:305–313.
- Schinzel A. 2001. Catalogue of unbalanced chromosomal aberrations in man. Berlin: Walter de Gruyter. p 44–46.
- Silengo MC, Davi GF, Bianco R, Biagioli M, Guala A, Franceschini P, Novelli G. 1984. Interstitial deletion of chromosome 1(q23-q25). Report of a case. *Clin Genet* 25:549–552.
- Taysi K, Sekhon GS, Hillman RE. 1982. A new syndrome of proximal deletion of the long arm of chromosome 1: 1q21-231q25. *Am J Med Genet* 13:423–430.
- Verloes A, Bremond-Gignac D, Isidor B, David A, Baumann C, Leroy MA, Stevens R, Gillerot Y, Heron D, Heron B, Benzacken B, Lacombe D, Brunner H, Bitoun P. 2006. Blepharophimosis-mental retardation (BMR) syndromes: A proposed clinical classification of the so-called Ohdo syndrome, and delineation of two new BMR syndromes, one X-linked and one autosomal recessive. *Am J Med Genet Part A* 140A: 1285–1296.
- Waggoner DJ, Ciske DJ, Dowton SB, Watson MS. 1999. Deletion of 1q in a patient with acrofacial dystosis. *Am J Med Genet* 82:301–304.
- White SM, Ades LC, Amor D, Liebelt J, Bankier A, Baker E, Wilson M, Savarirayan R. 2003. Two further cases of Ohdo syndrome delineate the phenotypic variability of the condition. *Clin Dysmorphol* 12:109–113.