

## A Quantitative Study of Intervertebral Disc Morphologic Changes Following Plasma-Mediated Percutaneous Discectomy

Matthew Smuck, MD,\* Joshua Levin, MD,\*  
Eric Zemper, PhD,<sup>†</sup> Adil Ali, MD,<sup>‡</sup> and  
David J. Kennedy, MD\*

\*PM&R Section, Department of Orthopaedic Surgery,  
Stanford University, Redwood City, California;

<sup>†</sup>Department of Physical Medicine and Rehabilitation,  
University of Michigan, Ann Arbor, Michigan;

<sup>‡</sup>Associates in Physical Medicine and Rehabilitation,  
PC, Ypsilanti, Michigan, USA

Reprint requests to: Matthew Smuck, MD, Stanford  
University Spine Center, Department of Orthopaedic  
Surgery, 450 Broadway St., Redwood City, CA 94063,  
USA. Tel: (650)721-7627; Fax: (650)721-3470;  
E-mail: msmuck@stanford.edu.

This research was not supported by any institutional  
or industry funds. All authors contributed significantly  
to and approved the contents of the article. The  
article has not been previously published.

Conflict of Interest: Dr. Matthew Smuck has served as  
a consultant for Arthrocare Corp. He has research  
support from Cytonics Inc. He receives honoraria and  
travel payment for positions held in the North  
American Spine Society.

Dr. Joshua Levin receives honoraria and travel  
payment for positions held in the NASS as an  
instructor. For the remaining authors, none were  
declared.

### Abstract

**Objective.** To quantitatively evaluate interval mag-  
netic resonance imaging (MRI) changes in disc mor-  
phology following plasma-mediated percutaneous  
discectomy.

**Design/Setting.** A retrospective comparison of pre-  
treatment and posttreatment MRIs at a single univer-  
sity spine clinic.

**Subjects.** From a group of 60 consecutively treated  
patients, 15 met the study inclusion and exclusion  
criteria. All had either failed treatment or had other  
clinical reasons for a posttreatment MRI.

**Methods.** Two independent physicians electroni-  
cally measured disc protrusion size and disc height  
at the treatment discs and adjacent discs on pre-  
and posttreatment MRI scans. Additionally, images  
were compared for gross anatomic changes includ-  
ing disc degeneration by Pfirrmann classification,  
new disc herniations, high intensity zone (HIZ), ver-  
tebral endplate changes, post-contrast enhance-  
ment, and changes in segmental alignment. Pearson  
*r* correlation was used to determine interobserver  
reliability between the two physicians' MRI measure-  
ments. Paired *t*-tests were calculated for compari-  
sons of pre- and posttreatment MRI measurements,  
and an ANOVA was performed for comparison of  
pre- to posttreatment changes in disc height mea-  
surements at treatment levels relative to adjacent  
levels.

**Results.** Correlation was high for measurement of  
disc height change ( $r=0.89$ ;  $P<0.0001$ ) and good  
for anteroposterior protrusion size change ( $r=0.51$ ;  
 $P=0.0512$ ). Disc height at treated discs demon-  
strated a small but statistically significant mean  
interval reduction of 0.48 mm ( $P=0.0018$ ). This  
remained significant when compared with the adja-  
cent control discs ( $P<0.0001$ ). Pretreatment mean  
disc protrusion size (4.74 mm; range 3.75–6.55 mm)  
did not differ significantly ( $P=0.1145$ ) from post-  
treatment protrusion size (4.42 mm; range 2.55–  
7.95 mm). Gross anatomic changes at treatment  
levels included reduced disc protrusion size ( $N=6$ ),  
enlarged protrusion ( $N=3$ ), resolution of HIZ ( $N=3$ ),  
and improvement in endplate signal changes ( $N=1$ ).  
Also, 11/15 posttreatment MRIs included post-  
contrast images that showed epidural fibrosis  
( $N=1$ ), rim enhancement ( $N=2$ ), and enhancement  
of the posterior annulus ( $N=4$ ).

**Conclusions.** Based on MRI examinations,  
subtle anatomic changes may occur following

**plasma-mediated percutaneous discectomy. Further study is required to determine the clinical relevance of these changes.**

**Key Words. Percutaneous; Nucleoplasty; Radiculopathy; Protrusion**

## Introduction

The majority of patients with radiculopathy from an extrusion-type lumbar disc herniation can expect their symptoms to resolve with conservative care [1]. When conservative treatments fail, surgical microdiscectomy is a highly successful treatment [2]. Alternatively, radicular pain from smaller disc protrusions responds less favorably to surgical microdiscectomy [2]. Percutaneous discectomy has been utilized as a less invasive surgical treatment for radicular pain from small lumbar disc protrusions.

One application approved by the U.S. Food and Drug Administration for performance of percutaneous discectomy is "Nucleoplasty" (Arthrocare Spine, Austin, TX). This technology involves the specialized application radiofrequency energy to create a plasma field. Details about the formation of a plasma field with radiofrequency energy within a conductive medium, and how this creates tissue ablation have been published [3]. In short, the process is not heat driven and the by-products are low molecular weight gases. The result is removal of a portion of the target disc nucleus with minimal immediate damage to surrounding tissues [4,5].

Prospective and retrospective observational cohort studies of plasma-mediated percutaneous discectomy in patients with radicular pain from a lumbar disc protrusion have been mostly favorable, with improvement in quality of life, reduced low back and leg pain, reduced use of analgesic medications, and high patient satisfaction [6–12]. Recently, the results of a multicenter prospective randomized trial showed favorable results at 2-year follow-up in the treatment of patients with predominately radicular pain [13]. Still, longer-term studies are lacking. The side effects and complications related to plasma-mediated percutaneous discectomy include epidural fibrosis [14], short-term pain at the needle insertion site, transient numbness and tingling, and increased back pain [15].

A variety of chemically, mechanically, and thermally based percutaneous discectomy techniques exist. The goal of each is to cause a volumetric reduction in the disc nucleus adjacent to the symptomatic disc protrusion. A small reduction in volume in the hydrostatic environment of the disc causes a decline in the resting intradiscal pressure [16–20]. Some have suggested that this reduction in pressure is the primary mechanism for the relief of pain by changing the forces acting on the disc protrusion, thereby reducing irritation of the adjacent nerve root [19,21,22]. This has led researchers to evaluate for posttreatment morphologic changes in disc protrusions treated by

various forms of percutaneous discectomy. Results have been variable with some demonstrating a reduction in the size of the protrusion [23], while others did not [24]. None have been able to demonstrate a correlation between radiographic changes and clinical outcomes.

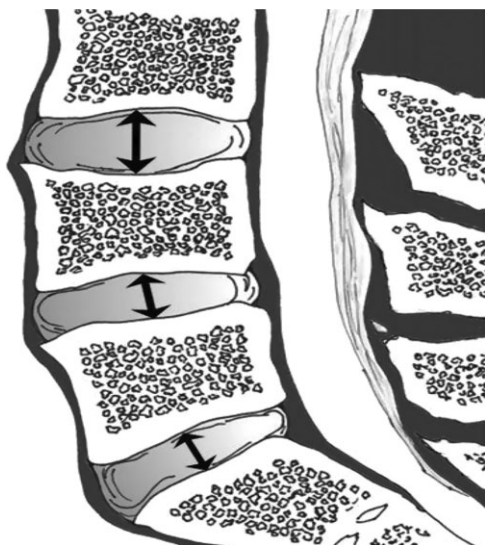
To date, no study has quantitatively examined in vivo changes in disc morphology following plasma-mediated percutaneous discectomy in humans. One recent study reported posttreatment changes in Pfirrmann disc degeneration grade [25]. Other authors have commented on radiographic changes, but did not attempt to quantify these changes with any standardized technique [8,11,26]. Studies evaluating magnetic resonance imaging (MRI) changes following other forms of percutaneous discectomy have been published including chemonucleolysis [27–31]. Most showed small changes or no changes in disc morphology after treatment. How this compares with radiographic changes following plasma-mediated percutaneous discectomy remains unknown. The current study was undertaken to quantify changes in intervertebral disc morphology observed following treatment with plasma-mediated percutaneous discectomy.

## Materials and Methods

The study was Institutional Review Board approved and Health Insurance Portability and Accountability Act compliant. Records of all patients treated at a single university spine clinic over a predetermined 3 year period were reviewed to find subjects meeting the following inclusion criteria: treatment by plasma-mediated percutaneous discectomy and MRI of the spine completed both before (pretreatment MRI) and after the date of the plasma-mediated percutaneous discectomy treatment (posttreatment MRI). In order to ensure the pre- and posttreatment MRI studies were completed under a uniform protocol, and to ensure the images were available for computer-assisted measurements, subjects were excluded if one or both of the MRI studies were performed at an outside institution or facility. All patients were treated using the same procedural technique as previously described [13].

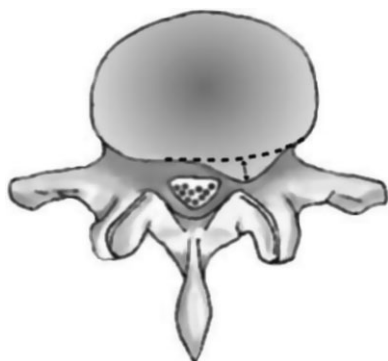
Each qualifying patient's medical record was reviewed to determine sex, age at the time of plasma-mediated percutaneous discectomy, disc level of treatment, dates of treatment and of the two MRI studies, clinical reason for the repeat MRI study, and long-term clinical outcome as documented in the electronic medical record. The MRI studies were obtained for evaluation. Two physicians (MS, JL) independently reviewed all 30 MRI studies (15 pretreatment and 15 posttreatment) on a single 20-inch digital monitor. The physicians were not blinded to the patients and MRI studies as patient identifiers are integral to the images in the software used. To reduce the bias caused by this, all 15 pretreatment MRI studies were reviewed and measured first, followed by the 15 posttreatment MRI studies. Using MagicView (Siemens, Erlangen, Germany) imaging software, each physician measured disc height at the treatment discs and adjacent disc(s) on the midline T1 sagittal view (Figure 1). They also measured

## Plasma-Mediated Percutaneous Discectomy



**Figure 1** An example of the method used to measure disc heights in a patient who had plasma-mediated percutaneous discectomy at L4-5. Mid-sagittal disc heights were measured perpendicular to the adjacent vertebral endplates at the treatment disc and each adjacent disc. Original artwork courtesy of Henry Huie, MD.

the anteroposterior (AP) size of the disc protrusions that required treatment. This measurement was made on T2 axial images (Figure 2). Each of the two physicians performed every disc height measurement and every disc



**Figure 2** An example of the method used to measure disc protrusion size. The measurement (between the two arrows) corresponded to the shortest line that could be drawn from the apex of the disc protrusion to the presumed normal contour of the disc (dotted line). Original artwork courtesy of Henry Huie, MD.

protrusion size measurement three times. The three scores were averaged for each physician, and these averages were used to calculate interobserver reliability. The average of the combined total six scores was used for data analysis of measurements.

Disc degeneration was graded using the Pfirrmann classification [32] and disagreement between the two physician reviewers was resolved by consensus. Only one physician reviewer (MS) determined the gross anatomic changes between the pretreatment and posttreatment MRI studies (i.e., those measures not quantified by measurement or Pfirrmann classification) including the presence of new disc herniations, high intensity zone (HIZ), vertebral endplate signal changes, post-contrast tissue enhancement, changes in vertebral alignment, and foraminal and canal patency.

The predetermined primary outcome measures were interval change in the measured AP size of the disc protrusions at the treatment levels, and interval change in disc height measurements at the treatment vs adjacent levels. Statistical analyses were performed using the SAS 8.0 software package (SAS Institute, Cary, NC). Basic descriptive analyses were performed on all variables. Pearson  $r$  correlation was used to determine interobserver reliability between the two physicians' MRI measurements. Paired  $t$ -tests were calculated for comparisons of pre- and post-treatment MRI height measurements and protrusion size measurements, and an ANOVA was performed for comparison of pre- to posttreatment changes in disc height measurements at treatment levels relative to adjacent levels.

## Results

Sixty consecutive patients treated with plasma-mediated percutaneous discectomy were identified from within the predetermined study time frame. All were treated for radicular pain with or without low back pain. Of these, only 15 met the inclusion and exclusion criteria and comprised the study population. The average age of the 15 patients at the time of treatment with plasma-mediated percutaneous discectomy was 38.5 (range, 24–61); 11 were female and 4 were male. Treated levels included L3-L4 (1), L4-L5 (7), and L5-S1 (7). No patients were treated at more than one disc level.

### *Indications for Repeat Imaging Studies*

All posttreatment MRI studies were obtained for clinical reasons (Table 1) as follows: consideration of additional surgery in the setting of no improvement ( $N = 2$ ), consideration of additional surgery for continued low back pain despite resolution of leg pain ( $N = 2$ ), initial worsening of radicular pain following treatment ( $N = 2$ ), initial improvement of pain followed later by return of previous radicular symptoms ( $N = 7$ ), new radicular symptoms ( $N = 1$ ), and new injury from a motor vehicle collision ( $N = 1$ ). Days between pretreatment MRI studies and treatment averaged 148 days (range, 11–392). Treatment to

**Table 1** Details of all 15 patients included in this study including disc level treated, clinical reason for posttreatment MRI, change in disc protrusion size from pre- to posttreatment MRI, and long-term clinical outcome\*  
 The post treatment MRI of this subject demonstrated a new disc herniation, a disc adjacent to the plasma-mediated percutaneous discectomy treatment level

	1	2	3	4	5	6	7	8	9	10	11	12	13	14	15	Subject Number
L5-S1	X	L4-5	L5-S1	L5-S1	L5-S1	L3-4	L5-S1	L5-S1	L4-5	L4-5	L4-5	L4-5	L4-5	L4-5	L5-S1	Disc treated Reason for
		X						X	X							post-treatment MRI No improvement evaluate for surgical options
			X	X				X				X				Symptoms worsened after treatment
	X										X	X				Initially improved then return of radicular symptoms
						X	X									New radicular symptoms New injury
					X			X								Radicular pain resolved, surgical evaluation for treatment of back pain
																Pre- to post-change in disc protrusion anteroposterior diameter
		X									X		X			Increased ( $\geq 0.75$ mm change)
									X	X						Unchanged (neither increased or decreased)
X				X	X	X*						X		X		Decreased ( $\geq 0.75$ mm change)
			X				X				X					Long-term outcome Additional Surgery
									X		X	X				Continues to have radicular pain
			X		X	X	X	X	X	X	X	X	X	X	X	Continues to have back pain

posttreatment MRI averaged 175 days (range, 37–531). Routine posttreatment imaging was not performed, thus patients with a good clinical response to treatment and those without a clinical reason to obtain a subsequent lumbar MRI were not imaged, and thus excluded from this study.

### Measurement Correlation

Correlation between the two physicians' MRI measurements was high for disc height change with  $r = 0.89$  ( $P < 0.0001$ ) and good for AP protrusion size change with  $r = 0.51$  ( $P = 0.0512$ ) in treated discs.

### Disc Height

Substantial loss of disc height is a relative contraindication to percutaneous discectomy. Previously published clinical outcome studies often exclude patients if disc height reduction is greater than 50%. On the pretreatment MRIs of the subjects in this study, mean loss of disc height at the disc to be treated was 13.1% (range –41.4% to +32.4%) relative to the height of the most normal adjacent disc. When comparing pretreatment with posttreatment images, disc height at treated discs demonstrated a small but statistically significant mean interval reduction of 0.48 mm ( $P = 0.0018$ ). No significant change was observed at the adjacent untreated disc levels during the same interval. The interval change in disc height of treated discs was highly statistically significant when compared with the lack of change at the adjacent discs ( $P < 0.0001$ ).

### AP Protrusion Size

The AP size of disc protrusions was considered to be unchanged if the mean pre- and posttreatment difference was less than 0.75 mm. Using this criterion, the AP size of disc protrusions was decreased in 6, unchanged in 6, and increased in 3 subjects. On pretreatment images, the treated discs had protrusions measuring a mean of 4.74 mm in AP size (range 3.75–6.55 mm). On posttreatment images, the mean AP size of disc protrusions was 4.42 mm (range 2.55–7.95 mm) for a statistically insignificant mean reduction of 0.32 mm ( $P = 0.1145$ ).

### Gross Anatomic Changes

Gross anatomic changes at the treated disc included reduced disc protrusion size in 6 (40–95% CI 15–65%), enlarged protrusion in 3 (20–95% CI 0–40%), resolution of HIZ in 3 (20–95% CI 0–40%), new HIZ in 1 (6.7–95% CI 0–19%), and worsening of one grade on the Pfirrmann classification in 1 (6.7–95% CI 0–19%). There were no new endplate signal changes, or changes in vertebral alignment. From the 15 posttreatment MRIs, 11 were done with contrast enhancement of which 2 demonstrated rim enhancement of the residual disc protrusion, 4 demonstrated enhancement of the full thickness of the posterior annulus adjacent to the residual disc protrusion, and 1 demonstrated epidural fibrosis. Gross anatomic

changes at the discs adjacent to the treated disc from pre- to posttreatment included a new herniation ( $N = 1$ ) and a new HIZ ( $N = 1$ ).

### Discussion

Although this study was limited to subjects who failed treatment or had other clinical reasons for a posttreatment MRI, changes in disc morphology following plasma-mediated percutaneous discectomy were observed in this cohort. Prior studies of radiographic changes following different forms of percutaneous discectomy have demonstrated inconsistent findings. Following percutaneous laser discectomy, reductions in disc protrusions were observed by computed tomography (CT) [23], but not by MRI [24]. Similarly, no changes were observed on MRI following automated percutaneous lumbar discectomy [33]. One study did demonstrate moderate improvement in pain and function as well as reductions in disc protrusions on MRI after electrothermal disc decompression [34]. None of these studies used quantitative measures of disc morphologic changes.

In regard to plasma-mediated percutaneous discectomy, several published studies have commented on posttreatment gross anatomic changes on MRI and/or CT. None of these studies used a specific methodology to quantify the changes, excluding one study that will be discussed in the next paragraph [25]. Rather, these studies used vague descriptive terminology to report radiographic changes, resulting in disparate findings [8,11,26]. Calisanellet al. reported significant reduction in pain in 29 treated patients and described “no changes in the type or amount of herniation” on 24 hour post-plasma-mediated percutaneous discectomy MRI examination [26]. Masala et al. demonstrated a similar and significant improvement in numeric pain scores in 79% of their patients, and found “a reduction in lesions in almost 80% of patients” based on MRI examination at 1 year post-plasma-mediated percutaneous discectomy [8]. In a study of over 1,300 patients, Alexandre et al. demonstrated significant clinical improvement (51% excellent and 31% good) at 6 months post-plasma-mediated percutaneous discectomy and observed that “bulging was eliminated in 34%, significantly reduced in 48% and unvaried in 18% of cases” based on CT and/or MRI [11].

Like this study, the previously mentioned study by Cuellar et al. was a small retrospective study evaluating pre- to posttreatment MRI changes with a similar follow-up period. Using one validated MRI measure, specifically the same Pfirrmann grading scale used in our study, 7/34 (20.5%) discs worsened from pre- to post-MRI. Limiting the analysis to the lumbar discs, 3/17 (17.6%) demonstrated progressive degeneration, nearly three times the rate observed in our study (1/15 or 6.7%). There are several possible reasons for this disparity. First, the authors had no knowledge of the care received by the patients prior to the plasma-mediated percutaneous discectomy treatment. Thus, some of these patients may have undergone discography prior to plasma-mediated

percutaneous discectomy, a test that may accelerate disc degeneration in approximately 1/3 of discs punctured [35]. The fact that many patients in the Cuellar study had normal discs on the pretreatment MRI implies that discography was used in the pre-plasma-mediated percutaneous discectomy evaluation. Discography was not used in the patients in our study. Furthermore, while a direct comparison of the MRIs between studies is not possible, it appears the study populations differed. According to the standard practice of plasma-mediated percutaneous discectomy in our center, all of the patients in our study were treated for radicular pain and had MRI evidence of a corresponding lumbar disc protrusion. The Cuellar study included patients with "normal" disc morphology or simply "bulging" discs, and only these disc categories demonstrated a worsening of Pfirrmann grade while no deterioration was observed in the "herniation" group. Thus, it is possible the discs prone to degeneration in the Cuellar study respond differently to plasma-mediated percutaneous discectomy than discs with a protrusion-type herniation as evaluated in our study (and theirs).

There are other important distinctions between these previous studies and this study. Most importantly, the Cuellar study used a single physician to subjectively evaluate for changes in disc morphology by directly comparing the pre- with posttreatment MRIs and rating the discs as "normal," "bulging," or "herniation." This is in stark contrast to this study, which included two independent physician examiners to separately perform measurements of the pretreatment MRIs, followed later by the posttreatment MRI studies. This study is also the first to use quantitative measures to document interval changes in disc height and disc protrusion size, demonstrating good inter-rater reliability in these measures. For further analysis, adjacent discs were included as controls. Furthermore, this study was designed to select patients with MRI studies from a single institution to ensure a uniform MRI study protocol was used on all studies. This was not normalized in the Cuellar study and may have impacted their findings.

One might have expected the rate of disc degeneration with plasma-mediated percutaneous discectomy to be higher than the rate reported for discography as plasma-mediated percutaneous discectomy uses a larger 17-gauge introducer needle to puncture the disc and as nucleus pulposus is intentionally depleted. Surprisingly, the rate observed here is lower (6.7%) than the rate reported following discography [35]. It is possible that this is simply an artifact of time as the average time between MRI studies was less than 1 year, while the cited discography study measured changes after 10 years. Another possibility is that the degeneration induced by discography may have more to do with the pressurization and medications injected than with the needle puncture of the disc, although multiple factors may be involved [35–38].

It is known that radiographic improvement does not always occur along with symptomatic improvement after a lumbar disc herniation [39,40]. Also, the contour of the

outer disc rarely returns to normal following open surgical discectomy, even in the setting of clinical improvement. In the present study, the AP size of disc protrusions on posttreatment MRI did not demonstrate a statistically significant change. Each of the subjects in the current study had the posttreatment MRI study for clinical reasons, some including new or recurrent radicular pain. This is the main limitation of this study and does present a selection bias in the cohort. If a reduction in the size of a disc protrusion is the primary mechanism for relief of symptoms, the subjects in this study are biased in the opposite direction, and three subjects in this study clearly demonstrated an enlargement on the posttreatment MRI. Currently, the re-herniation rate following plasma-mediated percutaneous discectomy is unknown, but is most likely equal to or less than the 20% (3/15) observed in this population because of the bias mentioned earlier.

Removal of a portion of the nucleus pulposus is expected to result in a reduction in disc height. In the current study, treated discs demonstrated a statistically significant mean reduction of 0.48 mm from the pretreatment to posttreatment studies. The fact that this change remained highly significant when compared with untreated adjacent discs is not surprising as these untreated discs demonstrated no significant interval change. The rationale for comparing disc height change of treated discs with untreated adjacent discs is to control for diurnal changes in disc height [41–43]. While this methodology eliminates the influence of diurnal changes on the measurements, it does not exclude another potential confounder. It is possible that the observed small interval reduction in disc height of the treated discs is due to the natural progression of degeneration, and not directly related to the treatment. We are aware of only one additional study to quantitatively measure disc height change following any form of percutaneous discectomy, showing a 15.8% average decrease in disc height following chemonucleolysis with chymopapain [27].

In the presence of a contained disc protrusion, some have suggested that reducing disc volume and pressure relieves pain by changing the forces acting on the disc protrusion and the adjacent spinal nerve [19,21,22]. The results of this study question the validity of this theory. Plus, local inflammation is currently considered to be more important than mechanical compression in the evolution of radicular pain [44,45]. Also, it is known that symptoms of radiculopathy can resolve without radiographic improvements in herniation size [46]. In addition, even with larger disc herniations, mechanical compression of the adjacent nerve is not universally present [47]. Therefore, it is unlikely that mechanical nerve compression is a common mechanism of pain related to the small disc protrusions treated by plasma-mediated percutaneous discectomy.

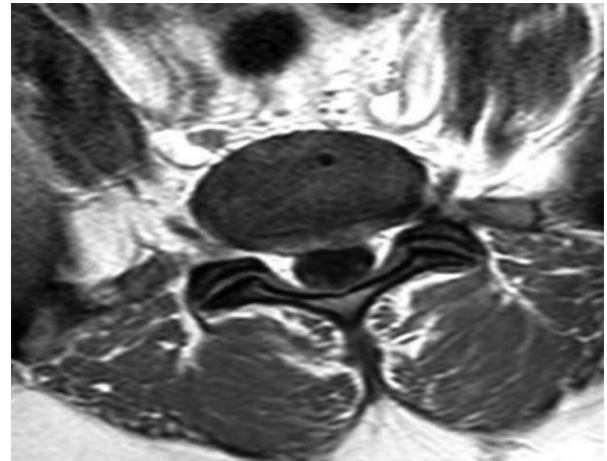
Another mechanism may be responsible for the clinical improvements observed in plasma-mediated percutaneous discectomy studies, namely, biochemical instead of biomechanical mechanisms [48]. Preclinical studies have lent credibility to this argument by demonstrating that

plasma-mediated percutaneous discectomy creates a shift in cytokine expression that can reduce inflammation and promote healing [49,50]. The current study lends further support to this theory by demonstrating radiographic changes that are potential anatomic reflections of these cellular mechanisms. Specifically, of the 11 patients who had posttreatment contrast-enhanced MRIs, 4 showed localized post-contrast enhancement of the annulus in the location of the disc protrusion. Local hemangiogenesis and tissues repair induced by alterations in cytokine activities may be responsible for this radiographic finding. Of course, as contrast was not routinely provided in this study cohort, especially on pretreatment MRIs, it can be argued that the post-contrast enhancement was a result of the underlying disease and was present prior to treatment with plasma-mediated percutaneous discectomy. Post-contrast rim enhancement is known to occur [51] and was observed in another two of our subjects. However, rim enhancement is a common finding in the setting of disc herniations, and is distinct from the wide area of enhancement visible within the substance of the annulus at the site of the disc protrusions observed here. Furthermore and fortuitously, one of these four patients did have both a pre- and posttreatment contrast-enhanced MRI allowing for a before and after comparison. This patient's MRI studies revealed enhancement of the annulus on the posttreatment images only (Figure 3).

There are several limitations to this study. First is the selection bias from the 15/60 subjects who met the inclusion criteria. All subjects who had a successful response to plasma-mediated percutaneous discectomy were excluded for this study, which limits the generalizability of these findings. Without proper controls, the exact cause and effect of the MRI changes observed here cannot be determined. The retrospective design did not allow for the inclusion of untreated patients with similar disc pathology as controls to test the reliability of the gross MRI changes. This study is also limited by the small sample size; however, the sample was sufficient to produce statistically significant findings. Again, the primary weakness of this study is the bias inherent to the study cohort as all subjects had posttreatment MRI for clinical reasons. Thus, these subjects may demonstrate anatomic changes that are not typical of a more generalized cohort that includes patients who respond favorably to treatment.

### Conclusion

This is the first quantitative in vivo study of radiographic changes in intervertebral disc morphology following plasma-mediated percutaneous discectomy. Treatment may result in a small but significant change in disc height but no significant change in disc protrusion size. Accelerated disc degeneration was observed in less than 10%. Gross anatomic changes to the treated discs, including resolution of HIZ and post-contrast annular enhancement, are potential radiographic representations of cellular



**Figure 3** T1 post-contrast axial image at L5-S1 from the posttreatment MRI showing enhancement of the disc annulus in the location of the broad central posterior disc protrusion. This patient also had a pretreatment contrast enhanced MRI that did not show enhancement of the L5-S1 disc. Additionally, another one of these four patients demonstrated post-contrast annular enhancement along with epidural fibrosis adjacent to the disc protrusion. We previously published the details of this case and proposed a mechanism for this occurrence [14]. In short, as plasma-mediated percutaneous discectomy treatment can alter the inflammatory cytokines in the disc by up-regulating those responsible for tissue healing [49], it is possible that this response is exaggerated in some causing an overproduction of granulation tissue at the site of injury.

mechanisms theorized to be responsible for clinical improvements following plasma-mediated percutaneous discectomy.

### References

- 1 Buttermann GR. Treatment of lumbar disc herniation: Epidural steroid injection compared with discectomy. A prospective, randomized study. *J Bone Joint Surg Am* 2004;86-A(4):670-9.
- 2 Carragee EJ, Kim DH. A prospective analysis of magnetic resonance imaging findings in patients with sciatica and lumbar disc herniation. Correlation of outcomes with disc fragment and canal morphology. *Spine* 1997;22(14):1650-60.
- 3 Stalder KR, Woloszko J, Brown IG, Smith CD. Repetitive plasma discharges in saline solutions. *Appl Phys Lett* 2001;79(27):4503-5.

**Smuck et al.**

- 4 Chen YC, Lee SH, Saenz Y, Lehman NL. Histologic findings of disc, end plate and neural elements after coblation of nucleus pulposus: An experimental nucleoplasty study. *Spine J* 2003;3(6):466–70.
- 5 Lee MS, Cooper G, Lutz GE, Doty SB. Histologic characterization of coblation nucleoplasty performed on sheep intervertebral discs. *Pain Physician* 2003; 6(4):439–42.
- 6 Mirzai H, Tekin I, Yaman O, Bursali A. The results of nucleoplasty in patients with lumbar herniated disc: A prospective clinical study of 52 consecutive patients. *Spine J* 2007;7(1):88–92. [Epub 2006 Nov 20]; discussion 92–3.
- 7 Sharps LS, Isaac Z. Percutaneous disc decompression using nucleoplasty. *Pain Physician* 2002;5(2): 121–6.
- 8 Masala S, Massari F, Fabiano S, et al. Nucleoplasty in the treatment of lumbar diskogenic back pain: One year follow-up. *Cardiovasc Intervent Radiol* 2007; 30(3):426–32.
- 9 Reddy AS, Loh S, Cutts J, Rachlin J, Hirsch JA. New approach to the management of acute disc herniation. *Pain Physician* 2005;8(4):385–90.
- 10 Singh V, Piryani C, Liao K. Role of percutaneous disc decompression using coblation in managing chronic discogenic low back pain: A prospective, observational study. *Pain Physician* 2004;7(4):419–25.
- 11 Alexandre A, Corò L, Azuelos A, Pellone M. Percutaneous nucleoplasty for discoradicular conflict. *Acta Neurochir Suppl* 2005;92:83–6.
- 12 Gerszten PC, Welch WC, King JT Jr. Quality of life assessment in patients undergoing nucleoplasty-based percutaneous discectomy. *J Neurosurg Spine* 2006;4(1):36–42.
- 13 Gerszten PC, Smuck M, Rathmell JP, et al. Plasma disc decompression compared with fluoroscopy-guided transforaminal epidural steroid injections for symptomatic contained lumbar disc herniation: A prospective, randomized, controlled trial. *J Neurosurg Spine* 2010;12(4):357–71.
- 14 Smuck M, Benny B, Han A, Levin J. Epidural fibrosis following percutaneous disc decompression with coblation technology. *Pain Physician* 2007;10(5): 691–6.
- 15 Bhagia SM, Slipman CW, Nirschl M. Side effects and complications after percutaneous disc decompression using coblation technology. *Am J Phys Med Rehabil* 2006;85:6–13.
- 16 Case RB, Choy DS, Altman P. Intervertebral disc pressure as a function of fluid volume infused. *J Clin Laser Med Surg* 1995;13:143–7.
- 17 Chen YC, Lee SH, Chen D. Intradiscal pressure study of percutaneous disc decompression with nucleoplasty in human cadavers. *Spine* 2003;28(7): 661–5.
- 18 Sasaki M, Takahashi T, Miyahara K, Hirose A. Effects of chondroitinase ABC on intradiscal pressure in sheep: An in vivo study. *Spine* 2001;26(5):463–8.
- 19 Choy DS, Altman P. Fall of intradiscal pressure with laser ablation. *J Clin Laser Med Surg* 1995;13(3):149–51.
- 20 Choy DS, Diwan S. In vitro and in vivo fall of intradiscal pressure with laser disc decompression. *J Clin Laser Med Surg* 1992;10(6):435–7.
- 21 Case RB, Choy DS, Altman P. Change of intradiscal pressure vs volume change. *J Clin Laser Med Surg* 1995;13(3):143–7.
- 22 Andreula C, Muto M, Leonardi M. Interventional spinal procedures. *Eur J Radiol* 2004;50(2):112–9. Review.
- 23 Hellinger J, Linke R, Heller H. A biophysical explanation for Nd:YAG percutaneous laser disc decompression success. *J Clin Laser Med Surg* 2001; 19(5):235–8.
- 24 Tonami H, Yokota H, Nakagawa T, et al. Percutaneous laser discectomy: MR findings within the first 24 hours after treatment and their relationship to clinical outcome. *Clin Radiol* 1997;52(12):938–44.
- 25 Cuellar VG, Cuellar JM, Vaccaro AR, Carragee EJ, Scuderi GJ. Accelerated degeneration after failed cervical and lumbar nucleoplasty. *J Spinal Disord Tech* 2010;23(8):521–4.
- 26 Calisaneller T, Ozdemir O, Karadeli E, Altinors N. Six months post-operative clinical and 24 hour post-operative MRI examinations after nucleoplasty with radiofrequency energy. *Acta Neurochir (Wien)* 2007;149(5):495–500. [Epub 2007 Apr 13]; discussion 500.
- 27 Leivseth G, Salvesen R, Hemminghytt S, Brinckmann P, Frobin W. Do human lumbar discs reconstitute after chemonucleolysis? A 7-year follow-up study. *Spine* 1999;24(4):342–7.
- 28 Bernhardt M, Gurganious LR, Bloom DL, White AA. Magnetic resonance imaging analysis of percutaneous discectomy. A preliminary report. *Spine* 1993;18(2): 211–7.



## Plasma-Mediated Percutaneous Discectomy

- 29 Delamarter RB, Howard MW, Goldstein T et al. Percutaneous lumbar discectomy. Preoperative and postoperative magnetic resonance imaging. *J Bone Joint Surg Am* 1995;77(4):578–84.
- 30 Sahlstrand T, Lonntoft M. A prospective study of preoperative and postoperative sequential magnetic resonance imaging and early clinical outcome in automated percutaneous lumbar discectomy. *J Spinal Disord* 1999;12(5):368–74.
- 31 Tonami H, Yokota H, Nakagawa T, et al. Percutaneous laser discectomy: MR findings within the first 24 hours after treatment and their relationship to clinical outcome. *Clin Radiol* 1997;52(12):938–44.
- 32 Pfirrmann CW, Metzdorf A, Zanetti M, Hodler J, Boos N. Magnetic resonance classification of lumbar intervertebral disc degeneration. *Spine* 2001;26(17):1873–8.
- 33 Sahlstrand T, Lönntoft M. A prospective study of preoperative and postoperative sequential magnetic resonance imaging and early clinical outcome in automated percutaneous lumbar discectomy. *J Spinal Disord* 1999;12(5):368–74.
- 34 Schaufele MK. Single level lumbar disc herniations resulting in radicular pain: Pain and functional outcomes after treatment with targeted disc decompression. *Pain Med* 2008;9(7):835–43.
- 35 Carragee EJ, Don AS, Hurwitz EL, et al. Does discography cause accelerated progression of degeneration changes in the lumbar disc: A ten-year matched cohort study. *Spine (Phila Pa 1976)* 2009;34(21):2338–45.
- 36 Kim KS, Yoon ST, Li J, et al. Disc degeneration in the rabbit: A biochemical and radiological comparison between four disc injury models. *Spine* 2005;30:33–7.
- 37 Lee H, Sowa G, Vo N, et al. Effect of bupivacaine on intervertebral disc cell viability. *Spine J* 2010;10(2):159–66.
- 38 Setton LA, Chen J. Mechanobiology of the intervertebral disc and relevance to disc degeneration. *J Bone Joint Surg Am* 2006;88(suppl 2):52–7.
- 39 Pope MH, Hanley EN, Matteri RE, Wilder DG, Frymoyer JW. Measurement of intervertebral disc space height. *Spine* 1977;2:282–6.
- 40 Strömqvist B, Jönsson B. Computerized follow-up after surgery for degenerative lumbar spine diseases. *Acta Orthop Scand* 1993;64(suppl 251):138–42.
- 41 Botsford DJ, Esses SI, Ogiilvie-Harris DJ. In vivo diurnal variation in intervertebral disc volume and morphology. *Spine* 1994;19(8):935–40.
- 42 Boos N, Wallin A, Aebi M, Boesch C. A new magnetic resonance imaging analysis method for the measurement of disc height variations. *Spine* 1996;21(5):563–70.
- 43 Park CO. Diurnal variation in lumbar MRI. Correlation between signal intensity, disc height, and disc bulge. *Yonsei Med J* 1997;38(1):8–18.
- 44 Yabuki S, Kawaguchi Y, Nordborg C, et al. Effects of lidocaine on nucleus pulposus induced nerve root injury. A neurophysiologic and histologic study in the pig cauda equina. *Spine* 1998;23:2383–90.
- 45 Takahashi N, Yabuki S, Aoki Y, Kikuchi S. Pathomechanisms of nerve root injury caused by disc herniation: An experimental study of mechanical compression and chemical irritation. *Spine* 2003;28(5):435–41.
- 46 Maigne JY, Rime B, Deligne B. Computed tomographic follow-up study of forty-eight cases of nonoperatively treated lumbar intervertebral disc herniation. *Spine* 1992;17(9):1071–4.
- 47 Takahashi K. Nerve root pressure in lumbar disc herniation. *Spine* 1999;24(19):2003–6.
- 48 Derby R, Kine G, Saal JA, et al. Response to steroid and duration of radicular pain as predictors of surgical outcome. *Spine* 1992;17(6 suppl):S176–83.
- 49 O'Neill CW, Liu JJ, Leibenberg E, et al. Percutaneous plasma decompression alters cytokine expression in injured porcine intervertebral discs. *Spine J* 2004;4(1):88–98.
- 50 Rhyu KW, Walsh A, O'Neill C, et al. The short-term effects of electrosurgical ablation on proinflammatory mediator production by intervertebral disc cells in tissue culture. *Spine J* 2007;7:451–8.
- 51 Hwang GJ, Suh JS, Na JB, Lee HM, Kim NH. Contrast enhancement pattern and frequency of previously unoperated lumbar discs on MRI. *J Magn Reson Imaging* 1997;7(3):575–8.