

Case Report

Comparison of Two Leukocytapheresis Protocols in a Case of Idiopathic Hypereosinophilic Syndrome

Michael L. Wang, Robertson D. Davenport, and Chisa Yamada*

Department of Pathology, Division of Transfusion Medicine, University of Michigan Health System, Ann Arbor, Michigan

Background: Hypereosinophilic syndrome (HEOS) is rare, and the efficacy of leukocytapheresis in this context is unclear. We here report the successful treatment of a patient with idiopathic HEOS with four leukocytapheresis procedures using two protocols. **Case:** A 4-year-old female presented with cardiac and respiratory dysfunction, and WBC of 225 K/ μ L with 96% eosinophils. Leukocytapheresis was started after initiation of methylprednisolone and hydroxyurea. She received two leukocytapheresis with polymorphonuclear cell (PMN) protocol, followed by initiation of imatinib therapy, then two leukocytapheresis with mononuclear cell (MNC) protocol. After the fourth leukocytapheresis, her WBC decreased to 69 K/ μ L with 82% eosinophils. She was discharged on hospital day 21 under stable condition with WBC of 22 K/ μ L with 86% eosinophils. WBC count and eosinophil percentage continued to decrease, and were 6.4 K/ μ L and 52% by 2 weeks and 3.9 K/ μ L and 4.9% by 3 months after discharge, respectively. **Findings:** WBC and absolute eosinophil (aEO) counts decreased by an average of 29.0 and 30.4% per leukocytapheresis, respectively. Normalized to estimated blood volume, procedures with PMN and MNC protocols changed, on average, WBC by -10.7 and -12.1% , aEO by -10.4 and -13.4% , platelet by -8.1 and -19.2% , and fluid balance by -129 and -47 mL, respectively. **Conclusion:** Leukocytapheresis was effective in decreasing WBC and aEO counts in HEOS, with PMN and MNC protocols achieving similar reductions. However, PMN protocol resulted in greater negative fluid balance and MNC protocol resulted in greater platelet loss. *J. Clin. Apheresis* 31:481–489, 2016. © 2015 Wiley Periodicals, Inc.

Key words: leukocytapheresis; hypereosinophilic syndrome

INTRODUCTION

Hypereosinophilic syndrome (HEOS) is a rare entity with an estimated prevalence at 0.36–6.3 per 100,000 [1]. Hypereosinophilia is defined as blood eosinophils >1.5 K/ μ L on two examinations separated in time by at least 1 month and/or tissue hypereosinophilia [2]. Tissue hypereosinophilia in turn is defined as $>20\%$ eosinophils in the bone marrow, extensive tissue infiltration by eosinophils, and/or marked deposition of eosinophil granule proteins in tissue [2]. HEOS is diagnosed when hypereosinophilia is associated with eosinophil-mediated organ damage/dysfunction [2]. It can be primary, secondary, or idiopathic [2]. Primary HEOS is neoplastic and monoclonal, often with increased blasts. Secondary HEOS is reactive and polyclonal, driven by increased eosinophilopoietic signaling [2]. Due to rarity of the disease, reports of treatment of HEOS with leukocytapheresis are limited to a handful of cases [3–8]. Therefore, details regarding the optimal apheresis procedure or the effectiveness of leukocytapheresis in the setting of HEOS remain unclear. We encountered a patient with idiopathic HEOS who received a total of four leukocytapheresis procedures using two dif-

ferent protocols as part of her treatment with favorable outcome. We analyzed the patient's response to each procedure and compared the two leukocytapheresis protocols.

METHODS

All leukocytapheresis procedures were performed using the COBE Spectra® apheresis system (Spectra, Terumo BCT, Lakewood, CO). The amount of anticoagulant citrate dextrose solution A (ACD-A) was calculated by the apheresis machine using the patient's total blood volume, which is calculated based on sex, height, and weight to meet the set infusion rate of 0.8

*Correspondence: Chisa Yamada, University of Michigan, Blood Bank/Transfusion Medicine, Department of Pathology, 1500 E. Medical Center Dr. SPC 5054, 2F228UH Ann Arbor, MI 48109-5054, USA. E-mail: yamadac@med.umich.edu.

Received 15 June 2015; Accepted 8 September 2015

Published online 14 October 2015 in Wiley Online Library (wileyonlinelibrary.com).

DOI: 10.1002/jca.21435

to 1.1 mL/min/L of total blood volume. The inlet: ACD-A ratio for the polymorphonuclear cell (PMN) and mononuclear cell (MNC) protocols are set as 13:1 and 12:1, respectively. The slight relative increase in ACD-A used in MNC protocol would result in a less negative fluid balance compared with PMN protocol. Our protocol for leukocytapheresis is based on the procedure guideline from Spectra (PMN and MNC protocols) and processes two total blood volumes, with allowance of up to three total blood volumes if tolerated by the patient. RBC prime was performed due to the patient's small estimated blood volume and rinse back was held. The PMN protocol is optimized for the removal of mature granulocytes (segmented cells including polymorphonuclear cells, eosinophils, and basophils), and should be performed with the use of hydroxyethyl starch (HES), a RBC sedimenting agent and volume expander. The MNC protocol is optimized for the removal of mononuclear cells or immature cells (lymphocytes and blasts); it is also used when HES is contraindicated due to cardiac or renal dysfunction, coagulopathies such as disseminated intravascular coagulation (DIC), or certain hereditary coagulation disorders. Since eosinophils are segmented and similar to polymorphonuclear cells in size, the first and second leukocytapheresis procedures were performed using PMN protocol. However, HES was held since our patient had signs of cardiac dysfunction. The third and fourth leukocytapheresis were performed using MNC protocol due to contraindication of HES and consideration of relatively large negative fluid balance with PMN protocol in her small body size. All procedures were performed through a non-tunneled double-lumen catheter (Sorenson, 10 French) placed in the patient's right internal jugular vein. Blood was drawn before and after the each procedure and white blood cell (WBC) count, hemoglobin (Hgb), platelet count, eosinophil percentage, and absolute eosinophil (aEO) count were recorded. Of note, preprocedure labs were drawn right before the first and second procedures, right before and 9 h prior (differential) for the third procedure, and 9 h before the fourth procedure. Postprocedure labs were drawn right after the procedure for the first and second procedures, 6 h after the third procedure, and 13 h after the fourth procedure. The calculated processed blood volume and fluid balance used by the apheresis machine were also recorded. The effect of each leukocytapheresis was analyzed and the two leukocytapheresis protocols are compared based on these laboratory data and the patient's clinical response. The laboratory data normalized to one blood volume processed in each procedure was also compared. Statistical analysis comparing PMN and MNC effects was not performed due to only having two data points for each parameter.

CASE

A 4-year-old female, height 115 cm, and weight 20.2 kg, with no significant medical history presented to an outside hospital emergency department after several weeks of malaise and pain in her hips and legs as well as 1 week of intermittent fevers, abdominal pain, and constipation. She was diagnosed with a urinary tract infection and constipation, and treated accordingly with amoxicillin and an enema. She was later found to have a WBC count of >200 K/ μ L and was transferred to our institution.

At our institution, she was febrile (39.4°C), mildly hypoxic (93% oxygen saturation on room air), tachycardic (139 BPM), and appeared dehydrated. She continued to have malaise and pain. Initial workup revealed cardiac dysfunction (troponin I up to 6.13 ng/mL and ECG showing ST depression concerning for ischemia). A blood count revealed leukocytosis with hypereosinophilia (WBC of 225 K/ μ L with 96% eosinophils). A peripheral blood smear revealed normal red blood cells and platelets without blast cells or evidence of myelodysplasia (Fig. 1A). She was admitted to the pediatric intensive care unit for further management. The bone marrow studies during admission showed marked eosinophilia (Table I and Fig. 2). Cytogenetic and molecular tests were all negative and chronic eosinophilic leukemia was excluded (Table I). Microbiology testing during her admission showed no evidence of infection, but mycoplasma IgM testing before admission was reported to be positive from primary care physician (Table I). Chest X-ray showed bilateral interstitial infiltrates. CT scans of the chest and abdomen revealed bilateral pulmonary edema or atypical infection, pleural effusions, compression of the distal sigmoid colon, and splenomegaly. Chest X-rays, CT scans, and ultrasound did not identify lymphadenopathy or masses to suggest lymphoma or other neoplastic processes. As her extensive diagnostic workup did not reveal either a clonal process or an attributable infectious process to explain her hypereosinophilia, she was clinically diagnosed as having idiopathic hypereosinophilic syndrome.

She was started on methylprednisolone (2 mg/kg \times 1 then 1 mg/kg \times 1 on hospital Day 1 and 0.5 mg/kg every 6 h on Day 2) and hydroxyurea (25 mg/kg on day 2). Although her WBC count decreased and stabilized between 144 and 180 K/ μ L on hospital days 2 and 3, she received leukocytapheresis on hospital day 4 since her WBC and eosinophil counts and troponin I remained high (1.51 ng/mL) and she still required supplemental oxygen, suggestive of cardiac and respiratory dysfunction caused by leukostasis. Between the two leukocytapheresis protocols available, the PMN protocol was favored as eosinophils were mature granulocytes. However, HES was not used due to the patient's

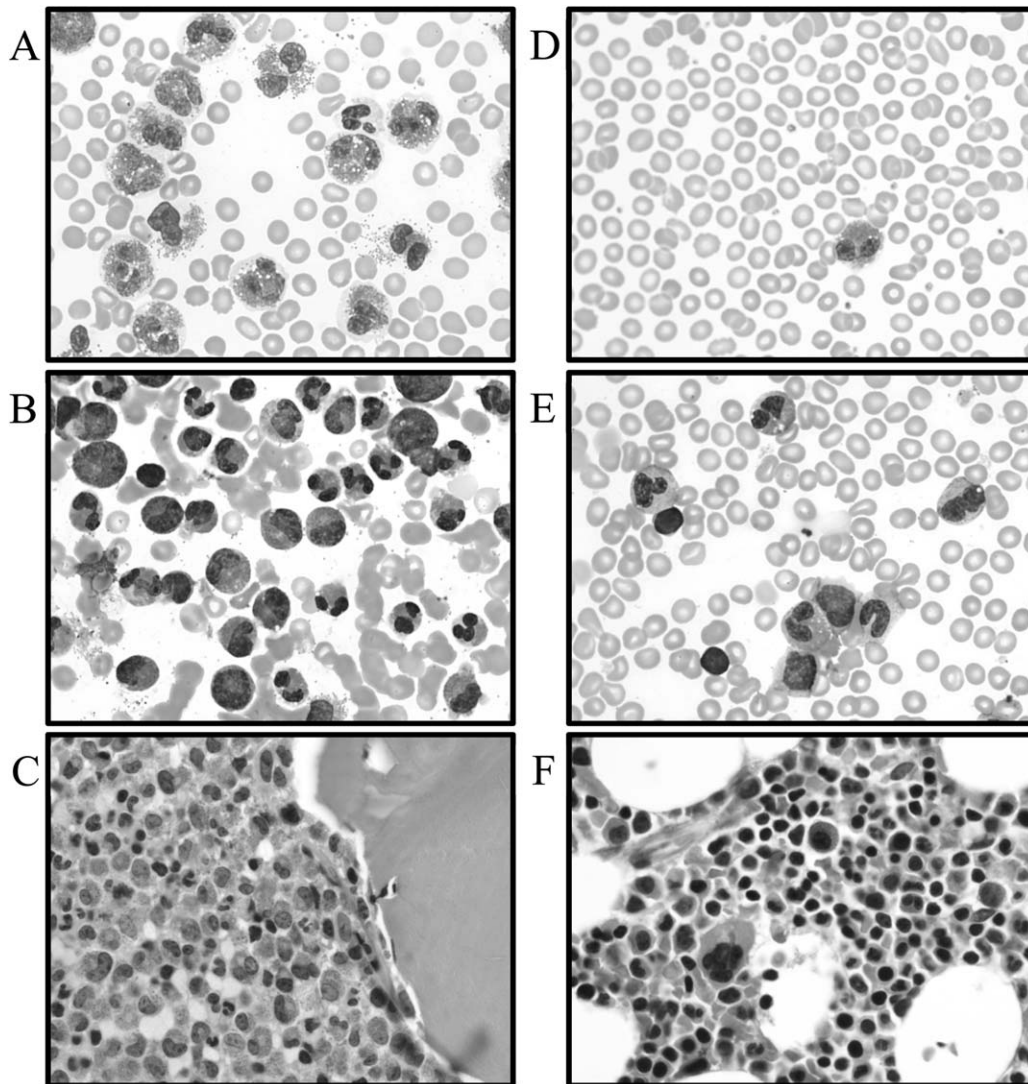


Fig. 1. Peripheral blood smear (A), bone marrow aspirate smear (B), and bone marrow core (C) at initial presentation showing marked hypereosinophilia (>90% eosinophils in bone marrow and peripheral blood). Peripheral blood smear (F), bone marrow aspirate smear (E), and bone marrow core (F) at 8 months after discharge was near normal (<5% eosinophils in bone marrow and peripheral blood). All images taken at $\times 1,000$ magnification.

cardiac dysfunction. Her WBC count decreased from 158 to 108 $K/\mu L$ and aEO count decreased from 144 to 96 $K/\mu L$ with only slight decrease of eosinophil percentage from 91% to 89% (Table II). Her WBC increased subsequently to 122 then back down to 109 $K/\mu L$, and she received a second leukocytapheresis with the PMN protocol without HES again the next day on hospital day 5. Her WBC count decreased from 109 to 84 $K/\mu L$ and aEO count decreased from 100 to 80 $K/\mu L$, but her eosinophil percentage slightly increased from 91 to 95%. These procedures resulted in a negative fluid balance of 329 mL on average, which was a concern given her small body size with an estimated total blood volume of 1,400 mL. She was showing signs and symptoms suggestive of dehydration, including prolonged capillary refill of >2 s, inter-

mittent tachycardia, transient increase in creatinine after the second leukocytapheresis (0.33 mg/dL, $\sim 2\times$ baseline), as well as a mild headache.

Her cardiac and respiratory dysfunction were resolving (down trending Troponin I, 1.19 ng/mL after second leukocytapheresis, weaned off milrinone without tachycardia, hypotension, or respiratory distress, O_2 saturation 94 to 99% on room air, though intermittently tachypneic to ~ 40 breaths/min) and she was clinically doing well with only mild constipation and abdominal pain. She was also started on imatinib therapy, currently a first line therapy for HEOS. However, with her WBC count increasing again to 147 $K/\mu L$ and abdominal pain possibly due to leukostasis, she received two more leukocytapheresis on hospital days 12 and 14 to prevent further leukostasis. For her third and fourth

TABLE I. Summary of Diagnostic Workup

Select admission labs
WBC 225 K/ μ L, Hgb 10.1 g/dL, Hct 27.4%, Plt 136
Eosinophil ratio 96.0%, absolute eosinophil 216 K/ μ L
Troponin 5.06 ng/mL, lactate dehydrogenase 877 IU/L
Ferritin 680 ng/mL, C-reactive protein 4.4 mg/dL
D-Dimer 1.73 mg/L
Cytogenetic, molecular, and other
Chromosomal microarray analysis—normal female profile
Negative for BCR/ABL1 or FIP1L1/PDGFR α gene fusions, PDGFR α , PDGFR β , or FGFR1 gene rearrangements, and MDS FISH Panel
Negative for CEBPA, NPM1, FLT3 D835, JAK2 V617F, KIT D816V, IDH1, and IDH2 mutations
Negative for BCR/ABL1 and indeterminate for PML/RARA transcripts
Negative transcriptome and whole genome sequencing
TCR-V β —normal
Tryptase—normal
Transcriptome sequencing—normal
Whole genome sequencing—normal
Infectious disease
Blood culture, urine cultures, C. difficile, O&P, parvovirus B19, CMV, EBV, <i>Varicella zoster</i> , respiratory panel, Aspergillus, Blastomycosis, Coccidioidomycosis, and Histoplasmosis—all negative
Mycoplasma IgM positive before admission per primary care physician
Cytokine panel
Elevated soluble IL2R, IL10, IL 13, interferon gamma
Normal TNF α , IL1 β , 2, 4, 5, 6, 8, 12
Bone marrow studies
Hospital day 1, day 9, 3 days after discharge: 95% cellularity with marked eosinophilia (bone marrow: 81 to 70%, peripheral blood: 92.5 to 80%)
At 8-month follow-up: 70 to 80% cellularity with slightly increased eosinophils (bone marrow: 4.4%, peripheral blood: 4.5%)

O&P: ova and parasite; CMV: cytomegalovirus; EBV: Epstein-Barr virus.

leukocytapheresis, the MNC protocol was used because we still wanted to avoid HES use and MNC protocol should theoretically result in a less negative fluid balance. After the third and fourth leukocytapheresis, her WBC decreased to 106 K/ μ L with 84% eosinophils and 69 K/ μ L with 82% eosinophils, respectively (Table II). Her WBC count continued to decrease and she was discharged on hospital Day 21 in stable condition with WBC of 22 K/ μ L with 86% eosinophils. Her WBC was within reference range at 6.4 K/ μ L by 2 weeks, aEO was within reference range at 0.5 K/ μ L by 2 months, and eosinophil percentage was within reference range at 4.9% by 3 months after discharge. Follow-up bone marrow study at 8 months after discharge showed a normocellular bone marrow with trilineage hematopoiesis and slightly increased eosinophils (4.4% on aspirate smears) and no morphologic evidence of dysplasia. She has remained well since.

In addition to leukocytapheresis, her clinical course involved multiple medications. Treatments included

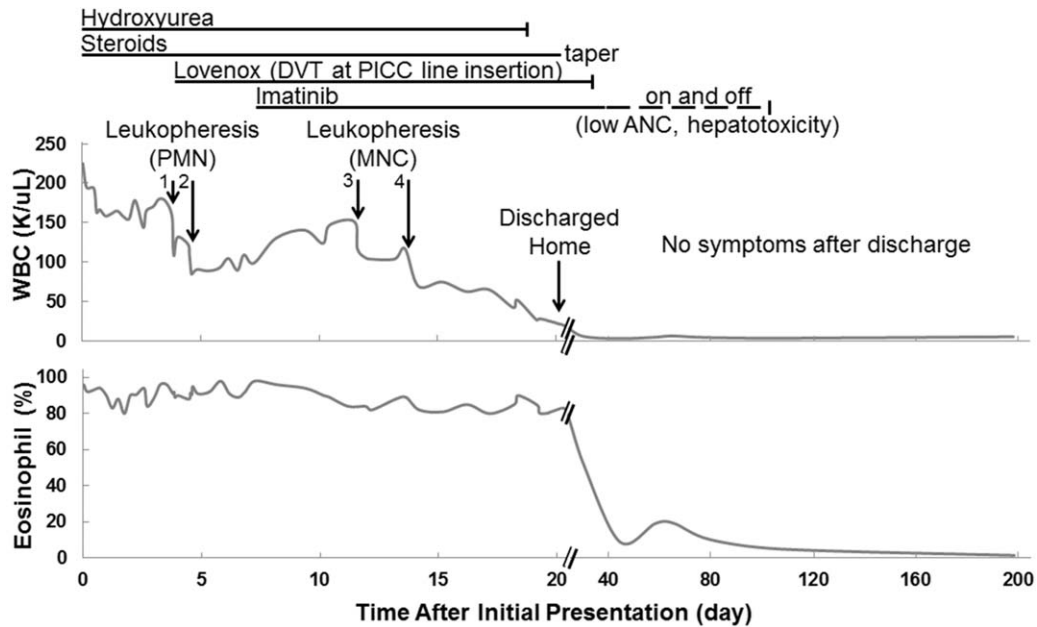
steroids (methylprednisolone and prednisolone) from hospital day 1 and weaned off by 2 weeks after discharge; hydroxyurea from hospital day 2 to day 19; enoxaparin for a peripherally inserted central catheter line associated deep vein thrombosis (DVT) in the left subclavian artery from hospital day 5 to 2 weeks after discharge; and imatinib from hospital Day 9 (between the second and third leukocytapheresis) until 2 weeks after discharge. Thereafter, she was on and off imatinib due to low absolute neutrophil count and mild hepatic toxicity until discontinuation 6 months after discharge, when her WBC and percent eosinophil were both stable and within reference ranges, at 5.7 K/ μ L and 1.4%, respectively. The duration of these various treatments and the leukocytapheresis procedures in relation to her WBC and peripheral eosinophil percentage is summarized in Figure 1. Other treatments include milrinone from hospital Day 1 to 5 and various antibiotic therapies, including cefepime, azithromycin, sulfamexazole-trimethoprim, and micafungin, during the first week of admission.

FINDINGS

The overall decrease of WBC and aEO counts by one leukocytapheresis procedure was on average 29.0% and 30.4%. Leukocytapheresis with the PMN protocol decreased WBC and aEO by an average of 27.3 and 26.7%, respectively; MNC protocol decreased WBC and aEO by an average of 30.8 and 34.2%, respectively (Table II). The mean change in eosinophil percentage, hemoglobin, platelet count, and fluid balance with the PMN and MNC protocols were +1.1 and -3.4%, +9.3 and -4.2%, -20.6 and -49.3%, and -329 and -113 mL, respectively. When the change of each laboratory result was normalized to one estimated blood volume processed, on average, the PMN and MNC protocols decreased WBC count by 14.9 and 14.6 K/ μ L (10.7 and 12.1%) and aEO count by 13.3 and 14.2 K/dL (10.4 and 13.4%), respectively (Table III); the mean change in eosinophil percentage, RBC, platelet count, and fluid balance were +0.4 and -1.5%, +4.8 and -0.9%, -8.0, and -19.2%, and -129 and -47 mL, respectively.

DISCUSSION

Leukostasis in the setting of hyperleukocytosis is a category I indication for leukocytapheresis based on American Society for Apheresis guidelines, and typically occurs at WBC counts of >100, >400, and <50 K/ μ L for AML, ALL, and monoblastic/monocytic variants of AML, respectively [9]. Since typical WBC counts resulting in leukostasis for hypereosinophilia is not available due to the rarity of the disease, leukocytapheresis is currently applied based on magnitude of



DVT: deep vein thrombosis, PICC: peripherally inserted central catheter, ANC: absolute neutrophil count

Fig. 2. Timeline of WBC count and peripheral eosinophil ratio with leukocytapheresis and medications. DVT: deep vein thrombosis, PICC: peripherally inserted central catheter, ANC: absolute neutrophil count.

TABLE II. Pre- and Postprocedure Values of each Leukocytapheresis for WBC Count, Absolute Eosinophil Count, Eosinophil Percentage, Hemoglobin, Platelet Count, and Fluid Balance

Protocol	PMN						MNC					
	1			2			3			4		
	Pre	Post	Change (%)	Pre	Post	Change (%)	Pre	Post	Change (%)	Pre	Post	Change (%)
WBC (K/μL)	158	108	-31.6	109	84	-22.9	147	106	-27.9	104	69	-33.7
Eosinophil (K/μL)	144	96	-33.2	100	80	-20.0	129	89	-31.0	91	57	-37.4
Eosinophil (%)	91	89	-2.2	91	95	+4.4	84	84	0	88	82	-6.8
Hemoglobin (g/dL)	10.2	10.6	3.9	8.9	10.2	+14.6	8.3	8.1	-2.4	8.3	7.8	-6.0
Platelet (K/μL)	204	157	-23.0	138	113	-18.1	290	156	-46.2	172	82	-52.3
Fluid balance (mL)		-321			-337			-24			-201	

Pre: preprocedure, Post: postprocedure.

leukocytosis, morphology of the increased cells, and signs and symptoms of end organ damage. Our patient experienced cardiac and respiratory complications earlier in her clinical course with WBC >200 K/μL, and developed a line associated DVT and had abdominal and leg pain while WBC was 100 to 150 K/μL.

There are only a handful of articles in the literature regarding the use of apheresis in the treatment of hypereosinophilic syndrome. In 1974, Ellman et al. reported a 25-year-old female with a hypereosinophilic drug reaction who was treated with leukocytapheresis. At presentation, her WBC was 13.6 K/μL with 82% eosinophils (70% eosinophils in bone marrow). Two

weeks later, while on prednisone 20 mg BID, her WBC increased to ~116 K/μL with ~85% eosinophils. She received leukocytapheresis and 22 × 10¹⁰ and 9.6 × 10¹⁰ eosinophils were removed on each of the 2 successive days. She responded well with improvement in her dyspnea, muscle tenderness, and sense of well-being within 2 days; resolution of her subungual petechiae and cutaneous microinfarcts and normalization of her serum aldolase, creatine phosphokinase, and lactic dehydrogenase in 1 week; and disappearance of S3 and S4 heart sounds and normalization of ECG by 2 months. A repeat bone marrow at 6 months after discharge showed 16% eosinophils. She remained well

TABLE III. Comparison of Effects of Leukocytapheresis Using PMN and MNC Protocols, Normalized to each Estimated Blood Volume Processed

Protocol Procedure #	PMN			MNC		
	1	2	Mean	1	2	Mean
No. processed blood volume (\times EBV)	2.56	2.56	2.56	2.91	2.32	2.61
WBC change/EBV (K/ μ L)	-19.5	-9.8	-14.9	-14.1	-15.1	-14.6
WBC change/EBV (%)	-12.4	-9.0	-10.7	-9.6	-14.5	-12.0
Absolute eosinophil change/EBV (K/ μ L)	-18.8	-7.8	-13.3	-13.7	-14.7	-14.2
Absolute eosinophil change/EBV (%)	-13.0	-7.8	-10.4	-10.7	-16.1	-13.4
Eosinophil percentage change/EBV (%)	-0.9	+1.7	+0.4	0	-2.9	-1.5
RBC change/EBV (%)	+2.2	+7.3	+4.8	+0.3	-2.0	-0.9
Platelet change/EBV (%)	-9.0	-7.1	-8.0	-15.9	-22.6	-19.2
End fluid balance/EBV (mL)	-125	-132	-129	-8	-87	-47

EBV: estimated blood volume.

during subsequent follow-up [3]. In 1977, Pineda et al. reported seven patients with moderate eosinophilia who were treated with leukocytapheresis from one to four times. The mean yield of eosinophils was 1.3×10^{10} per procedure, and there was no significant improvement in eosinophilia or symptoms in any of the patients [4]. In 1979, Blacklock et al. reported an 18-year-old male who presented with a WBC of 257 K/ μ L with 95% eosinophils that was treated with leukocytapheresis. In a one-month period, 12 leukocytapheresis was performed, removing a total of 1.38×10^{12} eosinophils (11.5×10^{10} per procedure), resulting in a decrease in blood eosinophil count that continued to decrease over the next 6 months to 2.5 K/ μ L. There was also clinical improvement with reduction in ischemic attacks, decrease in creatinine, reduction in splenomegaly, weight gain, and loss of night sweats [5]. In 1982, Davies et al. reported a comparison between plasmapheresis and leukocytapheresis in treating patients with hypereosinophilia. Each plasma exchange processed 2.5 to 4.0 L of plasma and each leukocytapheresis removed 200 mL of packed buffy coat cells. Plasmapheresis resulted in a 90, 83, and 35% decrease in eosinophil count, while leukocytapheresis resulted in a 38, 27, and 35% decrease in the same three patients, indicating that plasmapheresis was more effective at reducing eosinophils. In all patients, the eosinophil count returned to the previous high level after 7 to 18 h postprocedure, and none showed clinical improvement [6]. In 1990, Chambers et al. described a 26-year-old male with hypereosinophilia who was treated with both leukocytapheresis and plasmapheresis for >1 year, to remove both the cells and any etiologic eosinophil growth or differentiating factor, but in the end required cytotoxic therapy. After hydroxyurea was discontinued due to drug-induced thrombocytopenia, leukoplasmapheresis was started due to clinical exacerbation and increasing WBC, first in short intensive treatment periods and later as a twice weekly therapy over a period of at least 17 months. On average,

each procedure processed between 2.7 and 3.4 L of plasma, and removed between 1.0×10^{10} to 2.3×10^{10} eosinophils. He also required vincristine on two separate occasions during this period. Combined leukoplasmapheresis in this case contributed to the management of acute exacerbations and provided a degree of stabilization of his disease [7]. In 2005, Gwinner et al. reported life-threatening complications in a 42-year-old female with severe eosinophilia who received leukocytapheresis. The first procedure resulted in status asthmaticus within 30 min of leukocytapheresis and required intensive care therapy. A second leukocytapheresis led to progressive bronchospasm and circulatory failure, requiring artificial ventilation. Activation and degranulation of eosinophils through contact with the extracorporeal surface and by mechanical cell trauma was hypothesized to be the most plausible mechanism [8]. In summary, the six published case reports or series in the last 40 years provide conflicting data regarding the efficacy of leukocytapheresis in the treatment of hypereosinophilia, and highlight a potential risk that is specific to hypereosinophilia. Comparing to the previous reports above, we achieved similar reductions in eosinophils. In previous reports, 1.0 to 22×10^{10} eosinophils and 27% to 38% reductions were achieved per leukocytapheresis. We removed 6.7, 2.8, 5.6, and 4.8×10^{10} eosinophils for a 33.3, 20.0, 31.0, and 37.4% decrease for the first, second, third, and fourth leukocytapheresis, respectively.

We have two protocols for leukocytapheresis, the PMN and MNC. The PMN protocol is optimized to remove granulocytes, while the MNC protocol is optimized to remove mononuclear cells. The two protocols differ in three ways. First, the PMN protocol is optimized with the use of HES to allow for granulocyte harvest with minimal red cell content [10], while the MNC protocol is not [11]. Of note, use of HES is contraindicated in patients with impaired cardiac or renal function, underlying coagulopathies such as DIC, or certain hereditary coagulation disorders, because HES

expands blood volume and interferes with coagulation [12]. Due to our patient's impaired cardiac function, HES could not be used. Second, Spectra uses a deeper collection depth closer to the RBCs (hence the use of HES) for the PMN protocol, while it is shallower and closer to the platelet layer for the MNC protocol. Third, the inlet: anticoagulant (AC) ratio for the PMN and MNC protocols are 13:1 and 12:1, respectively, and thus the MNC protocol theoretically would result in a slightly less negative fluid balance.

In our case, leukocytapheresis was effective in reducing the WBC and aEO counts in the setting of hypereosinophilia. The extent of leukoreduction was comparable to leukocytapheresis for other causes of hyperleukocytosis [13]. Between the two protocols, the percent decrease in WBC and eosinophil counts was slightly greater with the MNC protocol compared with PMN protocol without HES. However, the larger negative fluid balance seen with the PMN protocol might have resulted in a relatively higher postprocedure WBC and eosinophil counts due to a concentration effect. And the difference in the timing of the blood draws also might have affected the lab data slightly as well. For both protocols, the WBC reduction was without much change in peripheral eosinophil percentage due to the fact that nearly all WBCs were eosinophils and the nature of the procedure being a non-selective reduction of WBC. The collection depth for the MNC protocol is shallower and nearer the platelets layer as discussed above, and did in fact result in a greater loss of platelets. The collection depth for the PMN protocol is deeper within the RBC layer, and especially without the use of HES, was expected to result in a greater RBC loss. However, hemoglobin (Hgb) levels remained the same or even increased after the procedure. Again, this may be due to the negative fluid balance after the procedure, resulting in a higher measured value due to a concentration effect. Also, due to her low estimated total blood volume (approximately 1,400 mL), RBC priming of the tubing (285 mL) [11] was performed with each procedure, and was effective in maintaining a steady hemoglobin level pre- and postprocedures.

While a thorough review of the medical management of HEOS is outside the scope of this case report, it is of note that a combination of medical therapy that included imatinib successfully treated the HEOS in our patient. Imatinib was designed to be a specific inhibitor to the aberrant BCR/ABL1 kinase in chronic myelogenous leukemia (CML), and is most commonly used for the treatment of CML. In addition, imatinib has also been found to be a potent inhibitor of Abl, c-kit, platelet-derived growth factor receptor alpha (PDGFRA), and platelet-derived growth factor beta (PDGFRB) kinase activities [14,15]. The FIP1L1-PDGFRB fusion is very sensitive to imatinib, requiring lower doses than those used for treating CML to induce molecular

remission, and the majority of patients with FIP1L1-PDGFRB-positive HEOS who are treated with imatinib achieve clinical, hematologic, and molecular remission [14,16–24]. As such, for FIP1L1/PDGFRB-positive HEOS, imatinib is currently the first line therapy. However, our patient had FIP1L1/PDGFRB-negative HEOS. For these patients, glucocorticoids are the first line therapy. If excessive glucocorticoids are required for a response, a second line therapy should be added [25]. For these patients, interferon-alpha is recommended for those that also have abnormal clonal T cells; imatinib is recommended for those with myeloproliferative features (some of which have mutations of PDGFRA or PDGFRB with other fusion partners); and hydroxyurea or interferon-alpha is recommended for those without either of the above findings [14,25–34]. Our patient did respond to initial treatment with methylprednisolone followed by hydroxyurea, but still required leukocytapheresis to further reduce WBC counts and improve leukostasis. Imatinib was then added, and after additional leukocytapheresis, our patient continued to improve with only medical therapy. After extensive workup, our patient did not bear any mutations that imatinib is known to be effective against, nor did she show evidence of a myeloproliferative disorder or other mutations involving PDGFRA or PDGFRB with other fusion partners (by both gene rearrangement and next-generation sequencing techniques). In short, no known target for imatinib therapy was found. FIP1L1/PDGFRB-negative HEOS has been reported to respond to imatinib therapy, with 23% (10 of 43 patients) achieving complete (six patients) or partial (four patients) response in one study [25]. In another study, 40% (6 of 15 patients) of chronic eosinophilic leukemia without known molecular aberration treated with imatinib achieved complete hematological remission [35]. These studies demonstrate some HEOS cases without known molecular aberrations may benefit from imatinib, as illustrated in our patient. It may be these cases harbor an undetected fusion of PDGFRA or PDGFRB with an alternate fusion partner. Our patient's clinical course improved in the weeks following initiation of imatinib therapy in combination with steroids, hydroxyurea, and leukocytapheresis. The patient achieved remission and was without symptoms or eosinophilia at her last follow-up visit 9 months after discharge.

CONCLUSIONS

We report a case of idiopathic hypereosinophilic syndrome in a previously healthy 4-year-old female that was successfully treated with leukocytapheresis and medications. Both the PMN without HES and MNC leukocytapheresis protocols were similarly effective in reducing WBC and aEO count. The extent of

eosinophil reduction achieved by both protocols per leukocytapheresis procedure is comparable to the extent of myelocyte and lymphocyte reduction in patients with various myeloid or lymphocytic leukemias, respectively. However, the PMN protocol resulted in a greater negative fluid balance and the MNC protocol resulted in greater platelet loss. Hemoglobin was stable with both protocols with RBC prime in our pediatric patient. The choice of which leukocytapheresis protocol to use should be made with the knowledge of these differences and the particular context of the patient.

REFERENCES

- Crane MM, Chang CM, Kobayashi MG, Weller PF. Incidence of myeloproliferative hypereosinophilic syndrome in the United States and an estimate of all hypereosinophilic syndrome incidence. *J Allergy Clin Immunol* 2010; 126:179–181.
- Valent P, Klion AD, Horny HP, Roufousse F, Gotlib J, Weller PF, Hellmann A, Metzgeroth G, Leiferman KM, Arock M, Butterfield JH, Sperr WR, Sotlar K, Vandenberghe P, Haferlach T, Simon HU, Reiter A, Gleich GJ. Contemporary consensus proposal on criteria and classification of eosinophilic disorders and related syndromes. *J Allergy Clin Immunol* 2012; 130:607–612.
- Ellman L, Miller L, Rapoport J. Leukocytapheresis therapy of a hypereosinophilic disorder. *JAMA* 1974; 230:1004–1005.
- Pineda AA, Brzica SM, Jr., Taswell HF. Continuous- and semicontinuous-flow blood centrifugation systems: therapeutic applications, with plasma-, platelet, lympho-, and eosinapheresis. *Transfusion* 1977; 17:407–416.
- Blacklock HA, Cleland JF, Tan P, Pillai VM. The hypereosinophilic syndrome and leukapheresis. *Ann Intern Med* 1979; 91:650–651.
- Davies J, Spry C. Plasma exchange or leukapheresis in the hypereosinophilic syndrome. *Ann Intern Med* 1982; 96:791.
- Chambers LA, Leonard SS, Whatmough AE, Weller PF, Bublely GJ, Kruskall MS. Management of hypereosinophilic syndrome with chronic plasma- and leukapheresis. *Prog Clin Biol Res* 1990; 337:83–85.
- Gwinner W, Menne J, Lonnemann G, Bahlmann F, Koch KM, Haller H. Life-threatening complications of extracorporeal treatment in patients with severe eosinophilia. *Int J Artif Organs* 2005; 28:1224–1227.
- Schwartz J, Winters JL, Padmanabhan A, Balogun RA, Delaney M, Linenberger ML, Szczepiorkowski ZM, Williams ME, Wu Y, Shaz BH. Guidelines on the use of therapeutic apheresis in clinical practice—evidence-based approach from the Writing Committee of the American Society for Apheresis: The sixth special issue. *J Clin Apher* 2013; 28:145–284.
- COBE Spectra Apheresis System Therapeutic Apheresis Guide. Part No. 777093-187. Reorder No. 701224-000. Gambro BCT, Inc.; 1999.
- COBE Spectra Apheresis System Essentials Guide. Part No. 777093-185. Reorder No. 701222-000. Gambro BCT, Inc.; 1999.
- University of Michigan Department of Pathology Blood Bank Document Number: BB-APU-PROC-0058 Revision: 02. Apheresis: Therapeutic WBC Depletion Using Spectra Effective. 2014. University of Michigan, Ann Arbor, MI.
- Bruserud Ø, Liseth K, Stamnesfet S, Cacic DL, Melve G, Kristoffersen E, Hervig T, Reikvam H. Hyperleukocytosis and leukocytapheresis in acute leukaemias: Experience from a single centre and review of the literature of leukocytapheresis in acute myeloid leukaemia. *Transfus Med* 2013; 23:397–406.
- Cools J, DeAngelo DJ, Gotlib J, Stover EH, Legare RD, Cortes J, Kutok J, Clark J, Galinsky I, Griffin JD, Cross NC, Tefferi A, Malone J, Alam R, Schrier SL, Schmid J, Rose M, Vandenberghe P, Verhoef G, Boogaerts M, Wlodarska I, Kantarjian H, Marynen P, Coutre SE, Stone R, Gilliland DG. A tyrosine kinase created by fusion of the PDGFRA and FIP1L1 genes as a therapeutic target of imatinib in idiopathic hypereosinophilic syndrome. *N Engl J Med* 2003; 348:1201.
- Griffin JH, Leung J, Bruner RJ, Caligiuri MA, Briesewitz R. Discovery of a fusion kinase in EOL-1 cells and idiopathic hypereosinophilic syndrome. *Proc Natl Acad Sci USA* 2003; 100:7830.
- Cortes J, Ault P, Koller C, Thomas D, Ferrajoli A, Wierda W, Rios MB, Letvak L, Kaled ES, Kantarjian H. Efficacy of imatinib mesylate in the treatment of idiopathic hypereosinophilic syndrome. *Blood* 2003; 101:4714.
- Pardanani A, Reeder T, Porrata LF, Li CY, Tazelaar HD, Baxter EJ, Witzig TE, Cross NC, Tefferi A. Imatinib therapy for hypereosinophilic syndrome and other eosinophilic disorders. *Blood* 2003; 101:3391.
- Klion AD, Noel P, Akin C, Law MA, Gilliland DG, Cools J, Metcalfe DD, Nutman TB. Elevated serum tryptase levels identify a subset of patients with a myeloproliferative variant of idiopathic hypereosinophilic syndrome associated with tissue fibrosis, poor prognosis, and imatinib responsiveness. *Blood* 2003; 101:4660.
- Klion AD, Robyn J, Akin C, Noel P, Brown M, Law M, Metcalfe DD, Dunbar C, Nutman TB. Molecular remission and reversal of myelofibrosis in response to imatinib mesylate treatment in patients with the myeloproliferative variant of hypereosinophilic syndrome. *Blood* 2004; 103:473.
- Jovanovic JV, Score J, Waghorn K, Cilloni D, Gottardi E, Metzgeroth G, Erben P, Popp H, Walz C, Hochhaus A, Roche-Lestienne C, Preudhomme C, Solomon E, Apperley J, Rondoni M, Ottaviani E, Martinelli G, Brito-Babapulle F, Saglio G, Hehlmann R, Cross NC, Reiter A, Grimwade D. Low-dose imatinib mesylate leads to rapid induction of major molecular responses and achievement of complete molecular remission in FIP1L1-PDGFRα-positive chronic eosinophilic leukemia. *Blood* 2007; 109:4635.
- Cervetti G, Galimberti S, Carulli G, Petrini M. Imatinib therapy in Hypereosinophilic Syndrome: A case of molecular remission. *Leuk Res* 2005; 29:1097.
- von Bubnoff N, Sandherr M, Schlimok G, Andreesen R, Peschel C, Duyster J. Myeloid blast crisis evolving during imatinib treatment of an FIP1L1-PDGFRα-positive chronic myeloproliferative disease with prominent eosinophilia. *Leukemia* 2005; 19:286.
- Baccarani M, Cilloni D, Rondoni M, Ottaviani E, Messa F, Merante S, Tiribelli M, Buccisano F, Testoni N, Gottardi E, de Vivo A, Giugliano E, Iacobucci I, Paolini S, Soverini S, Rosti G, Rancati F, Astolfi C, Pane F, Saglio G, Martinelli G. The efficacy of imatinib mesylate in patients with FIP1L1-PDGFRα-positive hypereosinophilic syndrome. Results of a multicenter prospective study. *Haematologica* 2007; 92:1173.
- Legrand F, Renneville A, Macintyre E, Mastrilli S, Ackermann F, Cayuela JM, Rousselot P, Schmidt-Tanguy A, Fain O, Michel M, de Jaureguiberry JP, Hatron PY, Cony-Makhoul P, Lefranc D, Sène D, Cottin V, Hamidou M, Lidove O, Baruchel A, Dubucquoi S, Blety O, Preudhomme C, Capron M, Prin L, Kahn JE, on behalf of the French Eosinophil Network. The Spectrum of FIP1L1-PDGFRα-associated chronic eosinophilic leukemia: new insights based on a survey of 44 cases. *Medicine* 2013; 92:1–9.
- Ogbogu PU, Bochner BS, Butterfield JH, Gleich GJ, Huss-Marp J, Kahn JE, Leiferman KM, Nutman TB, Pfaf F, Ring J, Rothenberg ME, Roufousse F, Sajous MH, Sheikh J, Simon D,

- Simon HU, Stein ML, Wardlaw A, Weller PF, Klion AD. Hypereosinophilic syndrome: a multicenter, retrospective analysis of clinical characteristics and response to therapy. *J Allergy Clin Immunol* 2009; 124:1319.
26. Butterfield JH, Weiler CR. Treatment of hypereosinophilic syndromes—the first 100 years. *Semin Hematol* 2012; 49:182–191.
 27. Malbrain ML, Van den Bergh H, Zachée P. Further evidence for the clonal nature of the idiopathic hypereosinophilic syndrome: Complete haematological and cytogenetic remission induced by interferon-alpha in a case with a unique chromosomal abnormality. *Br J Haematol* 1996; 92:176.
 28. Butterfield JH, Gleich GJ. Interferon-alpha treatment of six patients with the idiopathic hypereosinophilic syndrome. *Ann Intern Med* 1994; 121:648.
 29. Bockenstedt PL, Santinga JT, Bolling SF. Alpha-Interferon treatment for idiopathic hypereosinophilic syndrome. *Am J Hematol* 1994; 45:248.
 30. Canonica GW, Passalacqua G, Pronzato C, Corbetta L, Bagnasco M. Effective long-term alpha-interferon treatment for hypereosinophilic syndrome. *J Allergy Clin Immunol* 1995; 96: 131.
 31. Jain N, Cortes J, Quintás-Cardama A, Manshoury T, Luthra R, Garcia-Manero G, Kantarjian H, Verstovsek S. Imatinib has limited therapeutic activity for hypereosinophilic syndrome patients with unknown or negative PDGFRalpha mutation status. *Leuk Res* 2009; 33:837.
 32. Score J, Curtis C, Waghorn K, Stalder M, Jotterand M, Grand FH, Cross NC. Identification of a novel imatinib responsive KIF5B-PDGFR A fusion gene following screening for PDGFRA overexpression in patients with hypereosinophilia. *Leukemia* 2006;20:827.
 33. Cheah CY, Burbury K, Apperley JF, Huguet F, Pitini V, Gardembas M, Ross DM, Forrest D, Genet P, Rousselot P, Patton N, Smith G, Dunbar CE, Ito S, Aguiar RC, Odenike O, Gimelfarb A, Cross NC, Seymour JF. Patients with myeloid malignancies bearing PDGFRB fusion genes achieve durable long-term remissions with imatinib. *Blood* 2014;123:3574–3577.
 34. Curtis CE, Grand FH, Musto P, Clark A, Murphy J, Perla G, Minervini MM, Stewart J, Reiter A, Cross NC. Two novel imatinib-responsive PDGFRA fusion genes in chronic eosinophilic leukaemia. *Br J Haematol* 2007; 138:77.
 35. Metzgeroth G, Walz C, Erben P, Popp H, Schmitt-Graeff A, Haferlach C, Fabarius A, Schnittger S, Grimwade D, Cross NC, Hehlmann R, Hochhaus A, Reiter A. Safety and efficacy of imatinib in chronic eosinophilic leukaemia and hypereosinophilic syndrome: A phase-II study. *Br J Haematol* 2008; 143:707