

Transcatheter Valve Implantation for Right Atrium-to-Right Ventricle Conduit Obstruction or Regurgitation
After Modified Björk-Fontan Procedure

Ashish H Shah¹, Eric M Horlick¹, Andreas Eicken², Jeremy D Asnes³, Martin L Bocks⁴, Younes Boudjemline⁵, Allison K Cabalka⁶, Thomas E Fagan⁷, Stephan Schubert⁸, Vaikom S Mahadevan⁹, Danny Dvir¹⁰, Mark Osten¹, Doff B McElhinney¹¹

¹Toronto General Hospital, Toronto, Canada, ²German Heart Centre, Munich, Germany, ³Yale University, New Haven, Connecticut, USA ⁴University of Michigan, Ann Arbor, Michigan, USA, ⁵Necker Enfants Malades Hospital, Paris, France, ⁶Mayo Clinic, Rochester, Minnesota, USA, ⁷University of Tennessee Health Science Center and Le Bonheur Children's Hospital, Memphis, Tennessee, USA, ⁸Deutsches Herzzentrum, Berlin, Germany, ⁹University of California, San Francisco, California, USA, ¹⁰St. Paul's Hospital, Vancouver, Canada, ¹¹Stanford University, Palo Alto, California, USA

Correspondence: Doff B. McElhinney, MD
Department of Cardiothoracic Surgery
780 Welch Road, Suite CJ110
Stanford University Medical Center
Palo Alto, CA 94304
Phone: +1 650-736-6589
Fax: +1 650-736-6717
E-mail: doff.mcelhinney@gmail.com

Short title: RA-RV Fontan Transcatheter Valve

Total words: 4462

Disclosures:

Drs. Horlick, Eicken, Boudjemline, Mahadevan, Dvir, and McElhinney serve as proctors and/or consultants for Medtronic Inc. Drs. Horlick, Dvir, and Mahadevan serve as proctors and/or consultants for Edwards Lifesciences.

This is the author manuscript accepted for publication and has undergone full peer review but has not been through the copyediting, typesetting, pagination and proofreading process, which may lead to differences between this version and the [Version record](#). Please cite this article as [doi:10.1002/ccd.26648](https://doi.org/10.1002/ccd.26648).

Abstract:

Background: The most common reason for reintervention after a Björk modification of the Fontan procedure, in which the right ventricle (RV) is incorporated into the pulmonary circulation by connecting the right atrial (RA) appendage to the RV directly or with an extra-anatomic graft, is obstruction or regurgitation of the RA-RV connection. Transcatheter implantation of a valved stent is an appealing option for the treatment of RA-RV conduit dysfunction in these patients. In the present study, we assessed early and intermediate results after transcatheter valve implantation within an obstructed or regurgitant RA-RV modified Fontan pathway.

Methods: Through a retrospective multi-center registry, we collected data from 16 patients with a modified Fontan circulation who were treated with percutaneous Melody or Sapien valve implantation for dysfunction of an extra-anatomic RA-RV conduit or valve.

Results: All patients had successful and uncomplicated implantation of a Melody (n=15) or Sapien 3 (n=1) valve with hemodynamic and, in most cases, clinical improvement. During a median follow-up of 3.3 years, 3 patients died of cardiovascular causes unrelated to the procedure or the valve, and no major valve dysfunction was observed.

Conclusion: Percutaneous transcatheter valve deployment to treat a dysfunctional RA-RV connection after a Björk modification of the Fontan procedure is a viable alternative to surgery, with low procedural risk, and appears to offer good early and intermediate results.

Introduction

The Björk modification of the Fontan operation, performed primarily for tricuspid atresia with normally related great arteries, incorporates a pulsatile right ventricle (RV) into the cavopulmonary circuit by direct anastomosis of the right atrial (RA) appendage to the RV(1). Related modifications utilize a graft (either a valved xenograft conduit, a non-valved synthetic tube, or a valved or non-valved homograft) to connect the RA to the RV. Over time, RA-RV graft/conduit dysfunction is a common reason for symptoms after a modified Björk procedure, and revision or replacement of the RA-RV pathway is among the most common reinterventions in these patients(2-6). Although there are potential advantages to inclusion of the RV between the systemic venous and the pulmonary arterial compartments, obstruction of the RA-RV conduit and/or regurgitation of flow from the RV to the RA during ventricular contraction can impose an important hemodynamic burden. The Björk or modified Björk Fontan operation is rarely performed any longer, but there remain survivors of this procedure who may present with symptoms or consequences related to RA-RV conduit obstruction or regurgitation.

The morbidity and mortality associated with repeat surgeries in patients with congenital heart disease has markedly declined over the last 2-3 decades, but redo surgery continues to carry risks of mortality and various adverse outcomes(7,8), as well as further antigen exposure that may complicate suitability for cardiac transplantation in the future. Additionally, such surgery has inherent limitations for treatment of dysfunctional extracardiac RA-RV conduits, mainly due to the juxta-sternal position(9). Accordingly, there is a compelling interest in transcatheter management of RA-RV conduit obstruction and regurgitation. The Melody valve (Medtronic Inc., Minneapolis, MN) is approved for the treatment of RV outflow conduit dysfunction, and has been used for various other off-label applications(10), including treatment of RA-RV Fontan conduit obstruction or regurgitation(5,11-15). Similarly, successive generations of the Sapien valve (Edwards Lifesciences, Irvine, CA) have been extensively used in aortic and other valvular positions (16,17). In this study, we evaluated mid-term follow-up in a multi-center cohort of patients with a modified Björk Fontan procedure who underwent placement of a Melody or Sapien valve for RA-RV conduit dysfunction.

Methods

Patients:

Patients with a Björk (direct RA-RV connection) or modified Björk (RA-RV conduit) Fontan procedure who underwent placement of a transcatheter valve for obstruction or regurgitation of the RA-RV pathway were collected as part of a larger international registry of transcatheter tricuspid valve replacement.

The following data were collected by means of a standardized reporting form: demographics, diagnosis, valve/conduit type, age of valve/conduit, mechanism of conduit dysfunction, baseline clinical status, comorbidities, baseline echocardiographic and cardiac catheterization data, procedural details, acute hemodynamic and clinical outcomes, early complications, and information in regards to clinical, echocardiographic, valve function, and outcome at their latest clinic visit. Local Research and Ethics boards at each hospital approved the study.

Procedure:

Procedures were performed either under general or local anesthesia, through femoral venous access, and under fluoroscopy, with or without echocardiography guidance. The technical details of the procedure, including pre-dilation of the pathway, stent placement before valve implant and post-dilation after valve implant, were at the discretion of the operator. Technical success was defined as deployment of the Melody or Sapien valve in the intended location within the RA-RV conduit or valve without significant residual gradient or regurgitation. Vascular complications were defined as per the Valve Academic Research Consortium consensus document (18).

Data analysis:

Data are presented descriptively as frequency (%), median (minimum-maximum), or mean \pm standard deviation. Pre- and post-intervention pressures were compared using paired t-test, and paired categorical data on tricuspid regurgitation (mild or less vs moderate or severe) were compared with McNemar's test.

Results

Patients:

A total of 16 patients who underwent transcatheter valve implant within a RA-RV Fontan connection were identified from 10 centers in the US, Canada, and Europe. Six of these patients were included in case reports or series of transcatheter tricuspid valve replacement(5,11,12,14,15). Demographic, historical, and diagnostic data are summarized in Table 1. The median age at the time of intervention was 41 years (25–48 years). All patients had a total cavopulmonary connection with drainage of the inferior and superior caval veins to the RA, or a bidirectional Glenn anastomosis (n=3), along with a RA-RV connection and an intact atrial septum. The RA-RV connection consisted of a homograft conduit in 6 patients, a xenograft valved conduit in 4, a non-valved tube graft in 3, and a bioprosthetic valve within a direct connection in 3. The median nominal diameter of the valve or conduit at the time of surgical repair was 26 mm (14-31 mm; unknown in 1), and the median duration from surgical conduit/valve implant to percutaneous intervention was 16 years (1-32 years). Eleven patients had previously undergone revision or replacement of the RA-RV pathway/conduit.

All patients had impaired functional status, with 2 patients in New York Heart Association (NYHA) class 2, 13 in class 3, and 1 in class 4. Most patients (n=12) had a history of or active atrial flutter. Other co-morbidities are summarized in Table 1. Poor surgical candidacy due to multiple previous operations and co-morbidities was the most common reason for attempting percutaneous valve intervention. One patient who was severely debilitated with atrial flutter, chronic renal insufficiency, anemia, hypothyroidism, lung disease, and type 2 diabetes was severely ill and hospitalized prior to the procedure.

Baseline hemodynamics:

Fourteen patients had some degree of mixed obstruction and regurgitation of the conduit/valve, and 1 each had isolated stenosis or regurgitation. Hemodynamic details from the pre-catheterization echocardiogram and the catheterization are summarized in Figure 2 and Table 2.

Procedure:

All procedures in this series were performed through femoral venous access, with 14 under general anesthesia and 2 with local anesthesia. Adjunctive intra-procedural imaging was used in 9 patients, including transesophageal echocardiography in 7 and intracardiac echocardiography in 2. Details of the intervention are summarized in Table 3. Rapid pacing was not utilized. Pre-stenting of the conduit with 1 or more bare metal stents was performed in 8 patients, including 7 of the 9 with unsupported conduits (i.e., homografts and non-valved synthetic tube grafts). Thirteen of the 15 Melody valves were deployed on a 22mm Ensemble delivery system (Medtronic Inc., Minneapolis, Minnesota), and 1 each was delivered on a 20mm delivery system or a 24mm balloon. The Sapien 3 valve was a 29mm device implanted within a bioprosthetic valve in a direct RA-RV pathway. The only concomitant procedure (other than pre-stenting) was stent implantation for left pulmonary artery stenosis in 1 patient, which was performed prior to Melody valve deployment. All valves were implanted successfully, without embolization or malposition (Figure 1, Video 1a & 1b).

Early outcomes:

Acute hemodynamic outcomes are summarized in Table 2 and depicted in Figure 2. Immediately post-implant, there was significant improvement in the mean RA-RV inflow gradient ($p < 0.001$) and the severity of RA-RV conduit regurgitation ($p = 0.002$). The highest post-implant mean RA-RV gradient was 3 mmHg by invasive pressure measurement (median 1.5 mmHg) and 4 mmHg by Doppler echocardiography (median 2 mmHg), and regurgitation was reduced to none ($n = 12$) or trivial ($n = 3$) in all but 1 patient, in whom it was reported as mild. Two patients had trivial ($n = 1$) or mild ($n = 1$) paravalvular regurgitation. Immediately post-intervention, the mean RA pressure remained unchanged, whereas RV systolic and end-diastolic pressures were higher than pre-procedure.

Three patients had pre-existing pacemakers, 1 of which was transvenous with a lead across the conduit into the RV that was entrapped between the Melody and the previously implanted bioprosthetic valve without any change in function. One patient had minor vascular complications without any sequelae, but no other procedural or hospital complications were noted. The median hospital stay was 2 days (1–16 days). At the time of discharge, all patients were on some form of anti-platelet and/or anti-coagulant

therapy: 8 on warfarin alone, 5 on anti-platelet therapy alone, and 3 on a combination of anti-platelet and warfarin therapy.

Follow-up:

Patients were followed for a median of 3.3 years (0.1-7.1 years); 5 patients were followed for 4 years or longer. Three patients died, including the only patient in NYHA class 4 pre-implant, 1, 11 and 35 months post-intervention. All of the deaths were from cardiovascular causes but unrelated to the procedure or valve: 1 arrhythmia, 1 progressive heart failure, and 1 patient (described above) who was acutely ill and hospitalized pre-procedure but never improved.

During follow-up, no patients underwent valve-related reinterventions. However, 1 patient underwent Fontan revision due to refractory atrial flutter and the RA-RV conduit was replaced at that procedure. Another patient underwent percutaneous atrial flutter ablation and 1 required ongoing renal replacement therapy for chronic insufficiency. NYHA status was reported at follow-up for 11 of the 13 surviving patients, 10 of whom had improved by 1 (n=7) or 2 (n=3) grades. The median follow-up NYHA class was 2 (1-3), with 4 patients in class 1 and only 1 patient in class 3 (Figure 2). No patients were diagnosed with suspected or confirmed infective endocarditis. One patient, who had a valve implanted within a heavily calcified homograft conduit with a single pre-stent, was diagnosed with a Melody valve stent fracture approximately 2 years after implant, and was observed to have progression in the number of fractured struts over the subsequent 5 years but no evidence of valve dysfunction (mean gradient 5 mmHg at most recent follow-up) (Figure 3) (14).

As summarized in Table 2, transcatheter valve function remained good in most patients, although new onset moderate TR was observed in 1 patient 4.4 years post-intervention. The mean Doppler gradient on the most recent echocardiogram was modestly but significantly higher than on the early post-implant study by paired t-test (3.8 ± 2.3 vs 2.3 ± 1.1 , $p=0.002$), but still substantially lower than pre-implant (7.1 ± 5.0 , $p=0.011$). Six patients underwent cardiac catheterization 2.3-4.3 years after implant (median 3.4 years), with mean and phasic RA pressures that were lower than pre-implant and RV pressures that were similar.

The patient who received a Sapien 3 valve was followed for only 2.3 months. Video 2 demonstrates intracardiac echocardiography of a well functioning Melody valve during catheterization 3.5 years after implant.

Discussion

Patients born with tricuspid atresia are usually palliated with a modified Fontan circulation. Prior to the advent of lateral tunnel and extracardiac conduit strategies for total cavopulmonary connection, patients with tricuspid atresia and normally related great arteries often had a Björk or modified Björk Fontan procedure, in which the subpulmonary RV was incorporated into the Fontan circuit, allowing injection of kinetic energy into the pulmonary circulation. Although several studies from the 1980s suggest that there are benefits to incorporation of the RV in patients with tricuspid atresia, it is unclear if and in which patients this circulatory arrangement conferred a long-term survival or functional advantage (19-21). The RA-RV connection in a modified Björk procedure can vary in size, type, and configuration, but studies found that reintervention on the conduit/anastomosis was among the most common sources of late morbidity regardless of conduit type(4). This is reflected in the current study cohort, two-thirds of whom had undergone surgical revision of the RA-RV connection prior to Melody valve implant. Although, studies have demonstrated that a direct RA appendage-RV connection is associated with significantly less need for reintervention than pathways incorporating an extra-anatomic RA-RV conduit, patients with a valveless direct connection are more prone to complications of a failing Fontan circulation (4,22). Although the Björk procedure is rarely employed in the current era, there remain numerous patients with this circulation who present with the various complicating factors of a Fontan circulation and require management.

In this multicenter study, transcatheter implantation of a Melody or Sapien 3 valve was effective at restoring good hemodynamic function of the extra-anatomic RA-RV connection in patients with a Björk or modified Björk Fontan connection, with few procedural or late complications. It was encouraging to note excellent valve function over a relatively long duration of follow-up and stable clinical improvement in this complex patient population. However, some patients remained symptomatic, mainly due to atrial flutter,

and thus it was difficult to assess the true impact of valve implantation in these patients. Also, the relatively high mortality (n=3) during follow-up, despite successful valve implant, highlights the limitations of this modest hemodynamic intervention on the background of an inherently inefficient modified Fontan circulation. Although RA-RV conduit dysfunction is a rare problem in the current era, it is important to recognize that transcatheter therapy can be utilized to help improve the hemodynamic status of this circulation but that it has limitations.

There are no recent series of reoperation in patients with obstruction of a RA-RV Fontan connection, but studies published 15-20 years ago reported substantial mortality(4,9). It is likely that percutaneous intervention for RA-RV conduit dysfunction offers a number of advantages over reoperation in patients who do not require other surgical interventions, including avoidance of cardiopulmonary bypass and the other morbidity associated with re-sternotomy, freedom from blood transfusion which may help reduce sensitization that can interfere with suitability for cardiac transplantation, and earlier mobilization and shorter hospital stay. Of course, these benefits must be weighed against risks. There were few complications in this series, but potential risks may be inferred from the literature on Melody valve implant in RV outflow tract conduits. In particular, recent articles raised concern about infective endocarditis after transcatheter valve replacement(23,24). No cases of endocarditis or systemic infection were reported during follow-up of up to 7 years in this small cohort, all of whom were maintained on anti-platelet and/or anti-coagulant therapy, but close follow-up and a low threshold for investigating signs or symptoms of infection are critical in this population, as in any patient with a prosthetic valve or conduit.

As the RA-RV pathway is prone to external compression, pre-stenting the conduit/graft prior to the Melody valve may play a critical role maintaining valve integrity during follow-up. In the early experience with the Melody valve in the RV outflow tract, stent fracture and consequent obstruction was a problem, but this has been largely overcome with the routine use of bare metal stents to pre-stent the conduit before valve implant. (25). The anterior position of the RA-RV conduit or pathway in an RA-RV Fontan may impart similar risk for Melody valve stent fracture risk. Accordingly, pre-stenting may be important in Björk patients undergoing Melody valve implant, particularly in those with an unsupported RA-RV

connection (e.g., a homograft conduit or non-valved tube graft). Most of the patients in this series with an unreinforced conduit had pre-stents placed before valve implant, and one of these patients was diagnosed with a fractured pre-stent several years after Melody valve placement, with no evidence of valve dysfunction. Otherwise, there were no Melody valve stent fractures. Although the issue of conduit compression was not specifically addressed in the current study, using a projection that looks down the barrel of the conduit can help demonstrate residual compression and pre-stent implantation and help guide decision-making about placement of additional stents, as depicted in Figure 3.

In patients with intractable atrial arrhythmias or severe hemodynamic derangement after a modified Fontan procedure, simply relieving RA-RV conduit obstruction or regurgitation by implanting a transcatheter valve is unlikely to make a major difference. In such cases, heart transplant or Fontan conversion with arrhythmia surgery are likely necessary (26,27). However, Fontan conversion can be associated relatively high mortality (27), particularly in sicker patients, and many patients are deemed unsuitable candidates. RA-RV valve implantation may be of palliative benefit in such patients. Similarly, valve implant within an RA-RV conduit will not mitigate the deleterious pathophysiology of a Fontan circulation altogether, and in the current study cohort, RA pressures remained elevated even after Melody valve placement, due at least in part to high RV end-diastolic pressures. And in the sickest patient in this series, who died 1 month after implant despite an uncomplicated procedure and good valve function, valve implant made no difference, illustrating the importance of intervening before it is too late. Even though valve implant may yield only modest hemodynamic benefit, reduction of regurgitant flow and elimination of obstruction should nevertheless improve the efficiency of this circulation, which may be sufficient to reduce symptoms in some patients, as demonstrated in this study. It is also possible that valve implant will allow sufficient clinical improvement in some patients with symptomatic atrial flutter that they will become more favorable surgical candidates.

Limitations:

This is a retrospective multi-center registry with inherent limitations, including a small number of patients, incomplete data, and potential reporting and selection biases. While operators from each participating

center submitted data on all patients who underwent catheterization for intended valve implant in this patient population, there were likely similar patients at other centers who were not included in the registry. Moreover, generalization of the findings may not be appropriate. While RA-RV conduit function clearly improved and patients reported an improvement in functional status, the physiologic and clinical implications of valve implantation were not evaluated, making it difficult to determine the impact of these interventions. It would be of value to understand whether valve implant had a direct effect on right atrial volume, cardiac index and cardio-pulmonary exercise tests. However, such details were not obtained clinically in most patients or available in the registry. Although desired, inability to include all the important information is one of the known limitations of a retrospectively collected data in a multi-center registry.

Conclusions:

Percutaneous Melody or a Sapien valve deployment to treat obstruction and/or regurgitation of the RA-RV connection after a modified Björk Fontan procedure is a viable alternative to surgery that appears to be safe and offers good early and intermediate-term results. Further long-term follow-up of these patients will be required to evaluate longevity of the Melody or the Sapien valve in this position.

Accepted

References:

1. Bjork VO, Olin CL, Bjarke BB, Thoren CA. Right atrial-right ventricular anastomosis for correction of tricuspid atresia. *The Journal of thoracic and cardiovascular surgery* 1979;77:452-8.
2. Huddleston CB. The failing Fontan: options for surgical therapy. *Pediatric cardiology* 2007;28:472-6.
3. Driscoll DJ, Offord KP, Feldt RH, Schaff HV, Puga FJ, Danielson GK. Five- to fifteen-year follow-up after Fontan operation. *Circulation* 1992;85:469-96.
4. Fernandez G, Costa F, Fontan F, Naftel DC, Blackstone EH, Kirklin JW. Prevalence of reoperation for pathway obstruction after Fontan operation. *The Annals of thoracic surgery* 1989;48:654-9.
5. Eicken A, Fratz S, Hager A, Vogt M, Balling G, Hess J. Transcatheter Melody valve implantation in "tricuspid position" after a Fontan Bjork (RA-RV homograft) operation results in biventricular circulation. *International journal of cardiology* 2010;142:e45-7.
6. Kiraly L, Dalrymple-Hay MJ, Salmon AP, Keeton BR, Monro JL. The fate of antibiotic sterilized aortic allografts in Fontan circulation: results of the long-term follow-up. *European journal of cardio-thoracic surgery : official journal of the European Association for Cardio-thoracic Surgery* 1999;16:660-2.
7. Kirshbom PM, Myung RJ, Simsic JM et al. One thousand repeat sternotomies for congenital cardiac surgery: risk factors for reentry injury. *The Annals of thoracic surgery* 2009;88:158-61.
8. Morales DL, Zafar F, Arrington KA et al. Repeat sternotomy in congenital heart surgery: no longer a risk factor. *The Annals of thoracic surgery* 2008;86:897-902; discussion 897-902.
9. Dore A, Somerville J. Right atrioventricular extracardiac conduit as a fontan modification: late results. *The Annals of thoracic surgery* 2000;69:181-5.
10. Hasan BS, McElhinney DB, Brown DW et al. Short-term performance of the transcatheter Melody valve in high-pressure hemodynamic environments in the pulmonary and systemic circulations. *Circulation Cardiovascular interventions* 2011;4:615-20.
11. Tanous D, Nadeem SN, Mason X, Colman JM, Benson LN, Horlick EM. Creation of a functional tricuspid valve: novel use of percutaneously implanted valve in right atrial to right ventricular conduit in a patient with tricuspid atresia. *International journal of cardiology* 2010;144:e8-10.
12. Roberts PA, Boudjemline Y, Cheatham JP et al. Percutaneous tricuspid valve replacement in congenital and acquired heart disease. *Journal of the American College of Cardiology* 2011;58:117-22.
13. Butcher CJ, Plymen CM, Walker F. A novel and unique treatment of right ventricular inflow obstruction in a patient with a Bjork modification of the Fontan palliation before pregnancy. *Cardiology in the young* 2010;20:337-8.
14. Eicken A, Schubert S, Hager A et al. Percutaneous tricuspid valve implantation: two-center experience with midterm results. *Circulation Cardiovascular interventions* 2015;8.
15. Godart F, Baruteau AE, Petit J et al. Transcatheter tricuspid valve implantation: a multicentre French study. *Archives of cardiovascular diseases* 2014;107:583-91.
16. Durand E, Borz B, Godin M et al. Transfemoral aortic valve replacement with the Edwards SAPIEN and Edwards SAPIEN XT prosthesis using exclusively local anesthesia and fluoroscopic guidance: feasibility and 30-day outcomes. *JACC Cardiovascular interventions* 2012;5:461-7.
17. Wilson WM, Benson LN, Osten MD, Shah A, Horlick EM. Transcatheter Pulmonary Valve Replacement With the Edwards Sapien System: The Toronto Experience. *JACC Cardiovascular interventions* 2015;8:1819-27.
18. Kappetein AP, Head SJ, Genereux P et al. Updated standardized endpoint definitions for transcatheter aortic valve implantation: the Valve Academic Research Consortium-2 consensus document. *The Journal of thoracic and cardiovascular surgery* 2013;145:6-23.
19. Bull C, de Leval MR, Stark J, Taylor JF, Macartney FJ. Use of a subpulmonary ventricular chamber in the Fontan circulation. *The Journal of thoracic and cardiovascular surgery* 1983;85:21-31.
20. Coles JG, Leung M, Kielmanowicz S et al. Repair of tricuspid atresia: utility of right ventricular incorporation. *The Annals of thoracic surgery* 1988;45:384-9.

1. Ilbawi MN, Idriss FS, DeLeon SY et al. When should the hypoplastic right ventricle be used in a Fontan operation? An experimental and clinical correlation. *The Annals of thoracic surgery* 1989;47:533-8.
2. Burkhart HM, Dearani JA, Mair DD et al. The modified Fontan procedure: early and late results in 132 adult patients. *The Journal of thoracic and cardiovascular surgery* 2003;125:1252-9.
3. McElhinney DB, Benson LN, Eicken A, Kreuzer J, Padera RF, Zahn EM. Infective endocarditis after transcatheter pulmonary valve replacement using the Melody valve: combined results of 3 prospective North American and European studies. *Circulation Cardiovascular interventions* 2013;6:292-300.
4. Buber J, Bergersen L, Lock JE et al. Bloodstream infections occurring in patients with percutaneously implanted bioprosthetic pulmonary valve: a single-center experience. *Circulation Cardiovascular interventions* 2013;6:301-10.
5. McElhinney DB, Cheatham JP, Jones TK et al. Stent fracture, valve dysfunction, and right ventricular outflow tract reintervention after transcatheter pulmonary valve implantation: patient-related and procedural risk factors in the US Melody Valve Trial. *Circulation Cardiovascular interventions* 2011;4:602-14.
6. Deal BJ, Costello JM, Webster G, Tsao S, Backer CL, Mavroudis C. Intermediate-Term Outcome of 140 Consecutive Fontan Conversions With Arrhythmia Operations. *The Annals of thoracic surgery* 2016;101:717-24.
7. Ono M, Cleuziou J, Kasnar-Samprec J et al. Conversion to Total Cavopulmonary Connection Improves Functional Status Even in Older Patients with Failing Fontan Circulation. *The Thoracic and cardiovascular surgeon* 2015;63:380-7.

Accepted

Figure Legends

Figure 1

Frontal (A and C) and lateral (B and D) projection angiograms before (A and B) and after (C and D) Melody valve (M) implantation in a patient with a stenotic and regurgitant bioprosthetic valve (black arrows) in the proximal portion of the right atrium (RA) to right ventricle (RV) connection. The black arrows indicate the radiopaque markers on the commissural posts of the surgical valve. The white arrows in B indicate the narrow orifice of the valve and regurgitation into the RA. After Melody valve implant, the caliber of the orifice is larger and there is no regurgitation.

Figure 2

Panels top) and middle) depict top) the mean Doppler RA-RV gradient and middle) RA-RV conduit regurgitation severity determined by echocardiography pre-intervention, early post-intervention, and at latest follow-up. The p values in top) reflect comparison with the pre-intervention time point (pre- vs early post-intervention & pre- vs follow-up) by paired t-test. The column chart in bottom) depicts the distribution of NYHA functional status classification before implant (n=16) and at most recent follow-up (n=13). Two of the deceased patients are included in the follow-up column, including the 1 in NYHA class 4 and 1 of the 2 in class 3, both of whom were unchanged from pre-implant.

Figure 3

Top) This lateral projection chest x-ray demonstrates a Melody valve implanted within a heavily calcified homograft RA-RV conduit (HC), with multiple minor stent fractures (arrows indicate 2 of these). There is a single pre-stent. A indicates the anterior chest wall. Bottom) These lateral projection fluoroscopic images show a stented RA-RV conduit prior to Melody valve implant (left) and following placement of an additional pre-stent and a Melody valve (right). Note the significant anteroposterior compression of the stented conduit on the left, and the enlargement and relief of compression after stent and Melody valve implant on the right.

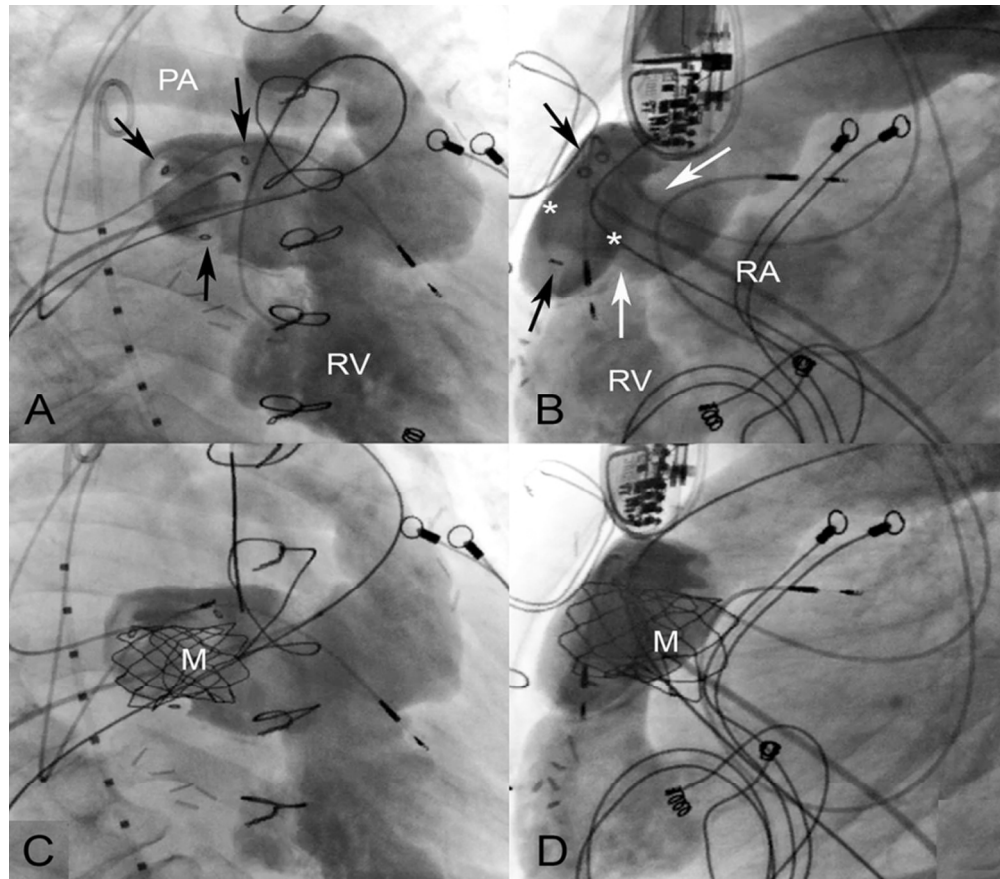
Video 1a & 1b

These angiograms demonstrate A) obstruction and regurgitation of a homograft RA-RV conduit before intervention, and B) after Melody valve implantation.

Video 2

These 2D and Doppler color flow intracardiac echocardiogram images obtained during catheterization 3.5 years after placement of a Melody valve in an RA-RV conduit demonstrate unobstructed flow, good leaflet coaptation, and trivial regurgitation. There is a small area of thickening or possibly thrombus attached to one of the leaflets.

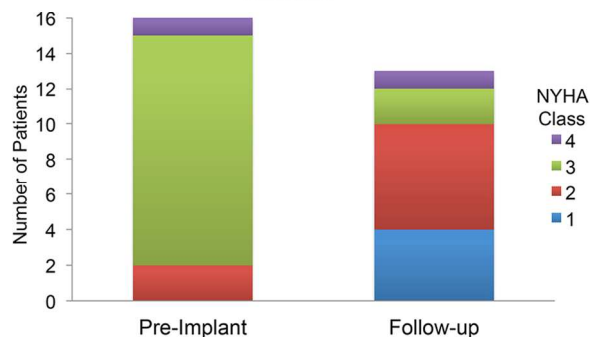
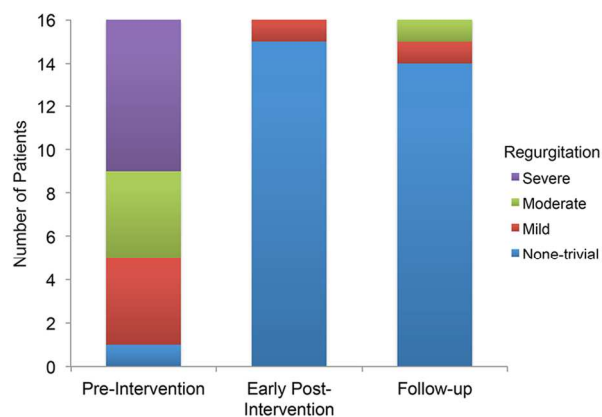
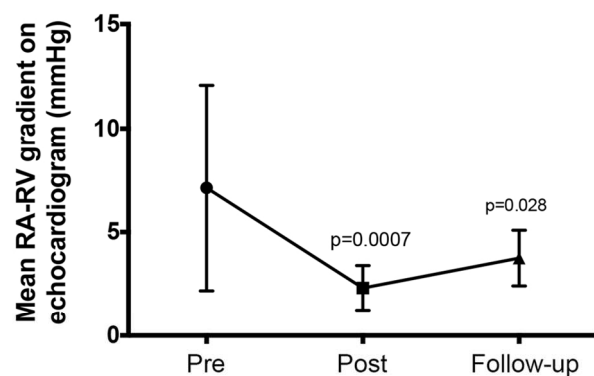
Accepted Article



Frontal (A and C) and lateral (B and D) projection angiograms before (A and B) and after (C and D) Melody valve (M) implantation in a patient with a stenotic and regurgitant bioprosthesis valve (black arrows) in the proximal portion of the right atrium (RA) to right ventricle (RV) connection. The black arrows indicate the radiopaque markers on the commissural posts of the surgical valve. The white arrows in B indicate the narrow orifice of the valve and regurgitation into the RA. After Melody valve implant, the caliber of the orifice is larger and there is no regurgitation.

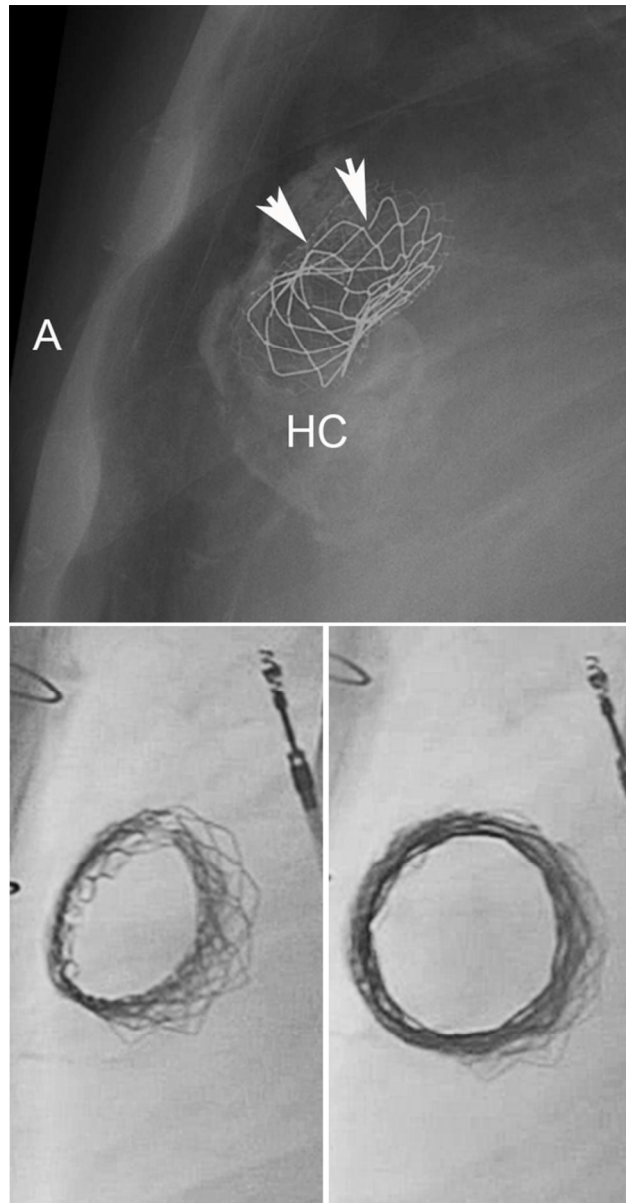
111x97mm (220 x 220 DPI)

ACI



Panels top) and middle) depict top) the mean Doppler RA-RV gradient and middle) RA-RV conduit regurgitation severity determined by echocardiography pre-intervention, early post-intervention, and at latest follow-up. The p values in top) reflect comparison with the pre-intervention time point (pre- vs early post-intervention & pre- vs follow-up) by paired t-test. The column chart in bottom) depicts the distribution of NYHA functional status classification before implant (n=16) and at most recent follow-up (n=13). Two of the deceased patients are included in the follow-up column, including the 1 in NYHA class 4 and 1 of the 2 in class 3, both of whom were unchanged from pre-implant.

76x152mm (300 x 300 DPI)



Top) This lateral projection chest x-ray demonstrates a Melody valve implanted within a heavily calcified homograft RA-RV conduit (HC), with multiple minor stent fractures (arrows indicate 2 of these). There is a single pre-stent. A indicates the anterior chest wall. Bottom) These lateral projection fluoroscopic images show a stented RA-RV conduit prior to Melody valve implant (left) and following placement of an additional pre-stent and a Melody valve (right). Note the significant anteroposterior compression of the stented conduit on the left, and the enlargement and relief of compression after stent and Melody valve implant on the right.
317x608mm (300 x 300 DPI)

Table 1: Baseline characteristics

Male / Female	8 / 8
Age, yrs	41 (25-48)
Weight, kg	74 (47-100)
Primary diagnosis	
Tricuspid atresia	15
Hypoplastic right ventricle/Ventricular septal defect	1
Type of RA-RV connection	
Homograft	6
Xenograft valved conduit	4
Non-valved tube graft	3
Bioprosthetic valve within direct RA-RV connection	3
Implanted diameter of the original conduit/valve (mm)	26 (14-31)
Age of the valve/conduit, yrs	16 (1-32)
Number of previous cardiac operations	3 (2-6)
Prior RA-RV conduit replacement or revision	11
Existing pacemaker	3
Co-morbidities	
Atrial flutter	12
Chronic obstructive or restrictive pulmonary disease	2
Liver cirrhosis	2
Acute or chronic renal failure	2
Previous history of infective endocarditis	1

Data are presented as median (minimum-maximum) or number

Table 2: Invasive hemodynamic data at baseline, early after transcatheter valve implant, and at follow-up

	Pre-procedure (N=15)	Immediately post- procedure (N=15)	Latest follow-up (N=6)
Mean RA pressure	17 (10 – 25)	15 (8 – 24)	13.5 (10 – 17)
RA 'a' wave pressure	19 (12 – 25)	17.5 (12 – 25)	15.5 (12 – 18)
RA 'v' wave pressure	15 (12 – 24)	17.5 (11 – 22)	13.5 (10 – 18)
Mean RA-RV inflow gradient	5 (2 – 12)	1.5 (0 – 3) ^{***}	2.0 (1 – 4)
RV systolic pressure	26.5 (16 – 37)	30 (24 – 39) [%]	25 (21 – 31)
RV end-diastolic pressure	10.5 (5 – 20)	13.5 (5 – 24) [#]	11 (8 – 13)

Data presented as median (minimum-maximum).

^{***}p=0.001, [%]p=0.02, [#]p=0.011 In comparison to pre-procedure values

Accepted Article

Table 3: Procedural information

General / local anesthesia	14 / 2
Access site, Femoral vein	16
Intraprocedure echocardiography	9
Transesophageal echocardiography	7
Intracardiac echocardiography	2
Pre-dilatation performed	10
Pre-dilation balloon diameter, mm	22 (14 – 26)
Pre-stent placed before valve implant	8
Implant delivery system size	
20 mm / 22 mm / 24 mm / 29 mm	1 / 13 / 1 / 1
Post-dilation of the implanted valve	6
Malposition, embolization, and/or need for second valve implant	0
Paravalvular leak	2
(None / trivial / mild / moderate / severe)	0 / 1 / 1 / 0 / 0
Complications	
Vascular complications	1
Major / minor	0 / 1
Others	0

Data presented as median (minimum-maximum) or number

Transcatheter Valve Implantation for Right Atrium-to-Right Ventricle Conduit Obstruction or Regurgitation
After Modified Björk-Fontan Procedure

Ashish H Shah¹, Eric M Horlick¹, Andreas Eicken², Jeremy D Asnes³, Martin L Bocks⁴, Younes Boudjemline⁵, Allison K Cabalka⁶, Thomas E Fagan⁷, Stephan Schubert⁸, Vaikom S Mahadevan⁹, Danny Dvir¹⁰, Mark Osten¹, Doff B McElhinney¹¹

¹Toronto General Hospital, Toronto, Canada, ²German Heart Centre, Munich, Germany, ³Yale University, New Haven, Connecticut, USA ⁴University of Michigan, Ann Arbor, Michigan, USA, ⁵Necker Enfants Malades Hospital, Paris, France, ⁶Mayo Clinic, Rochester, Minnesota, USA, ⁷University of Tennessee Health Science Center and Le Bonheur Children's Hospital, Memphis, Tennessee, USA, ⁸Deutsches Herzzentrum, Berlin, Germany, ⁹University of California, San Francisco, California, USA, ¹⁰St. Paul's Hospital, Vancouver, Canada, ¹¹Stanford University, Palo Alto, California, USA

Correspondence: Doff B. McElhinney, MD
Department of Cardiothoracic Surgery
780 Welch Road, Suite CJ110
Stanford University Medical Center
Palo Alto, CA 94304
Phone: +1 650-736-6589
Fax: +1 650-736-6717
E-mail: doff.mcelhinney@gmail.com

Short title: RA-RV Fontan Transcatheter Valve

Total words: 4462

Disclosures:

Drs. Horlick, Eicken, Boudjemline, Mahadevan, Dvir, and McElhinney serve as proctors and/or consultants for Medtronic Inc. Drs. Horlick, Dvir, and Mahadevan serve as proctors and/or consultants for Edwards Lifesciences.

Abstract:

Background: The most common reason for reintervention after a Björk modification of the Fontan procedure, in which the right ventricle (RV) is incorporated into the pulmonary circulation by connecting the right atrial (RA) appendage to the RV directly or with an extra-anatomic graft, is obstruction or regurgitation of the RA-RV connection. Transcatheter implantation of a valved stent is an appealing option for the treatment of RA-RV conduit dysfunction in these patients. In the present study, we assessed early and intermediate results after transcatheter valve implantation within an obstructed or regurgitant RA-RV modified Fontan pathway.

Methods: Through a retrospective multi-center registry, we collected data from 16 patients with a modified Fontan circulation who were treated with percutaneous Melody or Sapien valve implantation for dysfunction of an extra-anatomic RA-RV conduit or valve.

Results: All patients had successful and uncomplicated implantation of a Melody (n=15) or Sapien 3 (n=1) valve with hemodynamic and, in most cases, clinical improvement. During a median follow-up of 3.3 years, 3 patients died of cardiovascular causes unrelated to the procedure or the valve, and no major valve dysfunction was observed.

Conclusion: Percutaneous transcatheter valve deployment to treat a dysfunctional RA-RV connection after a Björk modification of the Fontan procedure is a viable alternative to surgery, with low procedural risk, and appears to offer good early and intermediate results.

Introduction

The Björk modification of the Fontan operation, performed primarily for tricuspid atresia with normally related great arteries, incorporates a pulsatile right ventricle (RV) into the cavopulmonary circuit by direct anastomosis of the right atrial (RA) appendage to the RV(1). Related modifications utilize a graft (either a valved xenograft conduit, a non-valved synthetic tube, or a valved or non-valved homograft) to connect the RA to the RV. Over time, RA-RV graft/conduit dysfunction is a common reason for symptoms after a modified Björk procedure, and revision or replacement of the RA-RV pathway is among the most common reinterventions in these patients(2-6). Although there are potential advantages to inclusion of the RV between the systemic venous and the pulmonary arterial compartments, obstruction of the RA-RV conduit and/or regurgitation of flow from the RV to the RA during ventricular contraction can impose an important hemodynamic burden. The Björk or modified Björk Fontan operation is rarely performed any longer, but there remain survivors of this procedure who may present with symptoms or consequences related to RA-RV conduit obstruction or regurgitation.

The morbidity and mortality associated with repeat surgeries in patients with congenital heart disease has markedly declined over the last 2-3 decades, but redo surgery continues to carry risks of mortality and various adverse outcomes(7,8), as well as further antigen exposure that may complicate suitability for cardiac transplantation in the future. Additionally, such surgery has inherent limitations for treatment of dysfunctional extracardiac RA-RV conduits, mainly due to the juxta-sternal position(9). Accordingly, there is a compelling interest in transcatheter management of RA-RV conduit obstruction and regurgitation. The Melody valve (Medtronic Inc., Minneapolis, MN) is approved for the treatment of RV outflow conduit dysfunction, and has been used for various other off-label applications(10), including treatment of RA-RV Fontan conduit obstruction or regurgitation(5,11-15). Similarly, successive generations of the Sapien valve (Edwards Lifesciences, Irvine, CA) have been extensively used in aortic and other valvular positions (16,17). In this study, we evaluated mid-term follow-up in a multi-center cohort of patients with a modified Björk Fontan procedure who underwent placement of a Melody or Sapien valve for RA-RV conduit dysfunction.

Methods

Patients:

Patients with a Björk (direct RA-RV connection) or modified Björk (RA-RV conduit) Fontan procedure who underwent placement of a transcatheter valve for obstruction or regurgitation of the RA-RV pathway were collected as part of a larger international registry of transcatheter tricuspid valve replacement.

The following data were collected by means of a standardized reporting form: demographics, diagnosis, valve/conduit type, age of valve/conduit, mechanism of conduit dysfunction, baseline clinical status, comorbidities, baseline echocardiographic and cardiac catheterization data, procedural details, acute hemodynamic and clinical outcomes, early complications, and information in regards to clinical, echocardiographic, valve function, and outcome at their latest clinic visit. Local Research and Ethics boards at each hospital approved the study.

Procedure:

Procedures were performed either under general or local anesthesia, through femoral venous access, and under fluoroscopy, with or without echocardiography guidance. The technical details of the procedure, including pre-dilation of the pathway, stent placement before valve implant and post-dilation after valve implant, were at the discretion of the operator. Technical success was defined as deployment of the Melody or Sapien valve in the intended location within the RA-RV conduit or valve without significant residual gradient or regurgitation. Vascular complications were defined as per the Valve Academic Research Consortium consensus document (18).

Data analysis:

Data are presented descriptively as frequency (%), median (minimum-maximum), or mean \pm standard deviation. Pre- and post-intervention pressures were compared using paired t-test, and paired categorical data on tricuspid regurgitation (mild or less vs moderate or severe) were compared with McNemar's test.

Results

Patients:

A total of 16 patients who underwent transcatheter valve implant within a RA-RV Fontan connection were identified from 10 centers in the US, Canada, and Europe. Six of these patients were included in case reports or series of transcatheter tricuspid valve replacement(5,11,12,14,15). Demographic, historical, and diagnostic data are summarized in Table 1. The median age at the time of intervention was 41 years (25–48 years). All patients had a total cavopulmonary connection with drainage of the inferior and superior caval veins to the RA, or a bidirectional Glenn anastomosis (n=3), along with a RA-RV connection and an intact atrial septum. The RA-RV connection consisted of a homograft conduit in 6 patients, a xenograft valved conduit in 4, a non-valved tube graft in 3, and a bioprosthetic valve within a direct connection in 3. The median nominal diameter of the valve or conduit at the time of surgical repair was 26 mm (14-31 mm; unknown in 1), and the median duration from surgical conduit/valve implant to percutaneous intervention was 16 years (1-32 years). Eleven patients had previously undergone revision or replacement of the RA-RV pathway/conduit.

All patients had impaired functional status, with 2 patients in New York Heart Association (NYHA) class 2, 13 in class 3, and 1 in class 4. Most patients (n=12) had a history of or active atrial flutter. Other co-morbidities are summarized in Table 1. Poor surgical candidacy due to multiple previous operations and co-morbidities was the most common reason for attempting percutaneous valve intervention. One patient who was severely debilitated with atrial flutter, chronic renal insufficiency, anemia, hypothyroidism, lung disease, and type 2 diabetes was severely ill and hospitalized prior to the procedure.

Baseline hemodynamics:

Fourteen patients had some degree of mixed obstruction and regurgitation of the conduit/valve, and 1 each had isolated stenosis or regurgitation. Hemodynamic details from the pre-catheterization echocardiogram and the catheterization are summarized in Figure 2 and Table 2.

Procedure:

All procedures in this series were performed through femoral venous access, with 14 under general anesthesia and 2 with local anesthesia. Adjunctive intra-procedural imaging was used in 9 patients, including transesophageal echocardiography in 7 and intracardiac echocardiography in 2. Details of the intervention are summarized in Table 3. Rapid pacing was not utilized. Pre-stenting of the conduit with 1 or more bare metal stents was performed in 8 patients, including 7 of the 9 with unsupported conduits (i.e., homografts and non-valved synthetic tube grafts). Thirteen of the 15 Melody valves were deployed on a 22mm Ensemble delivery system (Medtronic Inc., Minneapolis, Minnesota), and 1 each was delivered on a 20mm delivery system or a 24mm balloon. The Sapien 3 valve was a 29mm device implanted within a bioprosthetic valve in a direct RA-RV pathway. The only concomitant procedure (other than pre-stenting) was stent implantation for left pulmonary artery stenosis in 1 patient, which was performed prior to Melody valve deployment. All valves were implanted successfully, without embolization or malposition (Figure 1, Video 1a & 1b).

Early outcomes:

Acute hemodynamic outcomes are summarized in Table 2 and depicted in Figure 2. Immediately post-implant, there was significant improvement in the mean RA-RV inflow gradient ($p < 0.001$) and the severity of RA-RV conduit regurgitation ($p = 0.002$). The highest post-implant mean RA-RV gradient was 3 mmHg by invasive pressure measurement (median 1.5 mmHg) and 4 mmHg by Doppler echocardiography (median 2 mmHg), and regurgitation was reduced to none ($n = 12$) or trivial ($n = 3$) in all but 1 patient, in whom it was reported as mild. Two patients had trivial ($n = 1$) or mild ($n = 1$) paravalvular regurgitation. Immediately post-intervention, the mean RA pressure remained unchanged, whereas RV systolic and end-diastolic pressures were higher than pre-procedure.

Three patients had pre-existing pacemakers, 1 of which was transvenous with a lead across the conduit into the RV that was entrapped between the Melody and the previously implanted bioprosthetic valve without any change in function. One patient had minor vascular complications without any sequelae, but no other procedural or hospital complications were noted. The median hospital stay was 2 days (1–16 days). At the time of discharge, all patients were on some form of anti-platelet and/or anti-coagulant

therapy: 8 on warfarin alone, 5 on anti-platelet therapy alone, and 3 on a combination of anti-platelet and warfarin therapy.

Follow-up:

Patients were followed for a median of 3.3 years (0.1-7.1 years); 5 patients were followed for 4 years or longer. Three patients died, including the only patient in NYHA class 4 pre-implant, 1, 11 and 35 months post-intervention. All of the deaths were from cardiovascular causes but unrelated to the procedure or valve: 1 arrhythmia, 1 progressive heart failure, and 1 patient (described above) who was acutely ill and hospitalized pre-procedure but never improved.

During follow-up, no patients underwent valve-related reinterventions. However, 1 patient underwent Fontan revision due to refractory atrial flutter and the RA-RV conduit was replaced at that procedure. Another patient underwent percutaneous atrial flutter ablation and 1 required ongoing renal replacement therapy for chronic insufficiency. NYHA status was reported at follow-up for 11 of the 13 surviving patients, 10 of whom had improved by 1 (n=7) or 2 (n=3) grades. The median follow-up NYHA class was 2 (1-3), with 4 patients in class 1 and only 1 patient in class 3 (Figure 2). No patients were diagnosed with suspected or confirmed infective endocarditis. One patient, who had a valve implanted within a heavily calcified homograft conduit with a single pre-stent, was diagnosed with a Melody valve stent fracture approximately 2 years after implant, and was observed to have progression in the number of fractured struts over the subsequent 5 years but no evidence of valve dysfunction (mean gradient 5 mmHg at most recent follow-up) (Figure 3) (14).

As summarized in Table 2, transcatheter valve function remained good in most patients, although new onset moderate TR was observed in 1 patient 4.4 years post-intervention. The mean Doppler gradient on the most recent echocardiogram was modestly but significantly higher than on the early post-implant study by paired t-test (3.8 ± 2.3 vs 2.3 ± 1.1 , $p=0.002$), but still substantially lower than pre-implant (7.1 ± 5.0 , $p=0.011$). Six patients underwent cardiac catheterization 2.3-4.3 years after implant (median 3.4 years), with mean and phasic RA pressures that were lower than pre-implant and RV pressures that were similar.

The patient who received a Sapien 3 valve was followed for only 2.3 months. Video 2 demonstrates intracardiac echocardiography of a well functioning Melody valve during catheterization 3.5 years after implant.

Discussion

Patients born with tricuspid atresia are usually palliated with a modified Fontan circulation. Prior to the advent of lateral tunnel and extracardiac conduit strategies for total cavopulmonary connection, patients with tricuspid atresia and normally related great arteries often had a Björk or modified Björk Fontan procedure, in which the subpulmonary RV was incorporated into the Fontan circuit, allowing injection of kinetic energy into the pulmonary circulation. Although several studies from the 1980s suggest that there are benefits to incorporation of the RV in patients with tricuspid atresia, it is unclear if and in which patients this circulatory arrangement conferred a long-term survival or functional advantage (19-21). The RA-RV connection in a modified Björk procedure can vary in size, type, and configuration, but studies found that reintervention on the conduit/anastomosis was among the most common sources of late morbidity regardless of conduit type(4). This is reflected in the current study cohort, two-thirds of whom had undergone surgical revision of the RA-RV connection prior to Melody valve implant. Although, studies have demonstrated that a direct RA appendage-RV connection is associated with significantly less need for reintervention than pathways incorporating an extra-anatomic RA-RV conduit, patients with a valveless direct connection are more prone to complications of a failing Fontan circulation (4,22). Although the Björk procedure is rarely employed in the current era, there remain numerous patients with this circulation who present with the various complicating factors of a Fontan circulation and require management.

In this multicenter study, transcatheter implantation of a Melody or Sapien 3 valve was effective at restoring good hemodynamic function of the extra-anatomic RA-RV connection in patients with a Björk or modified Björk Fontan connection, with few procedural or late complications. It was encouraging to note excellent valve function over a relatively long duration of follow-up and stable clinical improvement in this complex patient population. However, some patients remained symptomatic, mainly due to atrial flutter,

and thus it was difficult to assess the true impact of valve implantation in these patients. Also, the relatively high mortality (n=3) during follow-up, despite successful valve implant, highlights the limitations of this modest hemodynamic intervention on the background of an inherently inefficient modified Fontan circulation. Although RA-RV conduit dysfunction is a rare problem in the current era, it is important to recognize that transcatheter therapy can be utilized to help improve the hemodynamic status of this circulation but that it has limitations.

There are no recent series of reoperation in patients with obstruction of a RA-RV Fontan connection, but studies published 15-20 years ago reported substantial mortality(4,9). It is likely that percutaneous intervention for RA-RV conduit dysfunction offers a number of advantages over reoperation in patients who do not require other surgical interventions, including avoidance of cardiopulmonary bypass and the other morbidity associated with re-sternotomy, freedom from blood transfusion which may help reduce sensitization that can interfere with suitability for cardiac transplantation, and earlier mobilization and shorter hospital stay. Of course, these benefits must be weighed against risks. There were few complications in this series, but potential risks may be inferred from the literature on Melody valve implant in RV outflow tract conduits. In particular, recent articles raised concern about infective endocarditis after transcatheter valve replacement(23,24). No cases of endocarditis or systemic infection were reported during follow-up of up to 7 years in this small cohort, all of whom were maintained on anti-platelet and/or anti-coagulant therapy, but close follow-up and a low threshold for investigating signs or symptoms of infection are critical in this population, as in any patient with a prosthetic valve or conduit.

As the RA-RV pathway is prone to external compression, pre-stenting the conduit/graft prior to the Melody valve may play a critical role maintaining valve integrity during follow-up. In the early experience with the Melody valve in the RV outflow tract, stent fracture and consequent obstruction was a problem, but this has been largely overcome with the routine use of bare metal stents to pre-stent the conduit before valve implant. (25). The anterior position of the RA-RV conduit or pathway in an RA-RV Fontan may impart similar risk for Melody valve stent fracture risk. Accordingly, pre-stenting may be important in Björk patients undergoing Melody valve implant, particularly in those with an unsupported RA-RV

connection (e.g., a homograft conduit or non-valved tube graft). Most of the patients in this series with an unreinforced conduit had pre-stents placed before valve implant, and one of these patients was diagnosed with a fractured pre-stent several years after Melody valve placement, with no evidence of valve dysfunction. Otherwise, there were no Melody valve stent fractures. Although the issue of conduit compression was not specifically addressed in the current study, using a projection that looks down the barrel of the conduit can help demonstrate residual compression and pre-stent implantation and help guide decision-making about placement of additional stents, as depicted in Figure 3.

In patients with intractable atrial arrhythmias or severe hemodynamic derangement after a modified Fontan procedure, simply relieving RA-RV conduit obstruction or regurgitation by implanting a transcatheter valve is unlikely to make a major difference. In such cases, heart transplant or Fontan conversion with arrhythmia surgery are likely necessary (26,27). However, Fontan conversion can be associated relatively high mortality (27), particularly in sicker patients, and many patients are deemed unsuitable candidates. RA-RV valve implantation may be of palliative benefit in such patients. Similarly, valve implant within an RA-RV conduit will not mitigate the deleterious pathophysiology of a Fontan circulation altogether, and in the current study cohort, RA pressures remained elevated even after Melody valve placement, due at least in part to high RV end-diastolic pressures. And in the sickest patient in this series, who died 1 month after implant despite an uncomplicated procedure and good valve function, valve implant made no difference, illustrating the importance of intervening before it is too late. Even though valve implant may yield only modest hemodynamic benefit, reduction of regurgitant flow and elimination of obstruction should nevertheless improve the efficiency of this circulation, which may be sufficient to reduce symptoms in some patients, as demonstrated in this study. It is also possible that valve implant will allow sufficient clinical improvement in some patients with symptomatic atrial flutter that they will become more favorable surgical candidates.

Limitations:

This is a retrospective multi-center registry with inherent limitations, including a small number of patients, incomplete data, and potential reporting and selection biases. While operators from each participating

center submitted data on all patients who underwent catheterization for intended valve implant in this patient population, there were likely similar patients at other centers who were not included in the registry. Moreover, generalization of the findings may not be appropriate. While RA-RV conduit function clearly improved and patients reported an improvement in functional status, the physiologic and clinical implications of valve implantation were not evaluated, making it difficult to determine the impact of these interventions. Although it would be of value to understand whether valve implant had a direct effect on RA volume, cardiac index, and exercise cardiopulmonary function, such details were not obtained clinically in most patients or available in the registry. The lack of such data limits our ability to assess the benefits of this therapy.

Conclusions:

Percutaneous Melody or a Sapien valve deployment to treat obstruction and/or regurgitation of the RA-RV connection after a modified Björk Fontan procedure is a viable alternative to surgery that appears to be safe and offers good early and intermediate-term results. Further long-term follow-up of these patients will be required to evaluate longevity of the Melody or the Sapien valve in this position.

Accepted Article

References:

1. Bjork VO, Olin CL, Bjarke BB, Thoren CA. Right atrial-right ventricular anastomosis for correction of tricuspid atresia. *The Journal of thoracic and cardiovascular surgery* 1979;77:452-8.
2. Huddleston CB. The failing Fontan: options for surgical therapy. *Pediatric cardiology* 2007;28:472-6.
3. Driscoll DJ, Offord KP, Feldt RH, Schaff HV, Puga FJ, Danielson GK. Five- to fifteen-year follow-up after Fontan operation. *Circulation* 1992;85:469-96.
4. Fernandez G, Costa F, Fontan F, Naftel DC, Blackstone EH, Kirklin JW. Prevalence of reoperation for pathway obstruction after Fontan operation. *The Annals of thoracic surgery* 1989;48:654-9.
5. Eicken A, Fratz S, Hager A, Vogt M, Balling G, Hess J. Transcatheter Melody valve implantation in "tricuspid position" after a Fontan Bjork (RA-RV homograft) operation results in biventricular circulation. *International journal of cardiology* 2010;142:e45-7.
6. Kiraly L, Dalrymple-Hay MJ, Salmon AP, Keeton BR, Monro JL. The fate of antibiotic sterilized aortic allografts in Fontan circulation: results of the long-term follow-up. *European journal of cardio-thoracic surgery : official journal of the European Association for Cardio-thoracic Surgery* 1999;16:660-2.
7. Kirshbom PM, Myung RJ, Simsic JM et al. One thousand repeat sternotomies for congenital cardiac surgery: risk factors for reentry injury. *The Annals of thoracic surgery* 2009;88:158-61.
8. Morales DL, Zafar F, Arrington KA et al. Repeat sternotomy in congenital heart surgery: no longer a risk factor. *The Annals of thoracic surgery* 2008;86:897-902; discussion 897-902.
9. Dore A, Somerville J. Right atrioventricular extracardiac conduit as a fontan modification: late results. *The Annals of thoracic surgery* 2000;69:181-5.
10. Hasan BS, McElhinney DB, Brown DW et al. Short-term performance of the transcatheter Melody valve in high-pressure hemodynamic environments in the pulmonary and systemic circulations. *Circulation Cardiovascular interventions* 2011;4:615-20.
11. Tanous D, Nadeem SN, Mason X, Colman JM, Benson LN, Horlick EM. Creation of a functional tricuspid valve: novel use of percutaneously implanted valve in right atrial to right ventricular conduit in a patient with tricuspid atresia. *International journal of cardiology* 2010;144:e8-10.
12. Roberts PA, Boudjemline Y, Cheatham JP et al. Percutaneous tricuspid valve replacement in congenital and acquired heart disease. *Journal of the American College of Cardiology* 2011;58:117-22.
13. Butcher CJ, Plymen CM, Walker F. A novel and unique treatment of right ventricular inflow obstruction in a patient with a Bjork modification of the Fontan palliation before pregnancy. *Cardiology in the young* 2010;20:337-8.
14. Eicken A, Schubert S, Hager A et al. Percutaneous tricuspid valve implantation: two-center experience with midterm results. *Circulation Cardiovascular interventions* 2015;8.
15. Godart F, Baruteau AE, Petit J et al. Transcatheter tricuspid valve implantation: a multicentre French study. *Archives of cardiovascular diseases* 2014;107:583-91.
16. Durand E, Borz B, Godin M et al. Transfemoral aortic valve replacement with the Edwards SAPIEN and Edwards SAPIEN XT prosthesis using exclusively local anesthesia and fluoroscopic guidance: feasibility and 30-day outcomes. *JACC Cardiovascular interventions* 2012;5:461-7.
17. Wilson WM, Benson LN, Osten MD, Shah A, Horlick EM. Transcatheter Pulmonary Valve Replacement With the Edwards Sapien System: The Toronto Experience. *JACC Cardiovascular interventions* 2015;8:1819-27.
18. Kappetein AP, Head SJ, Genereux P et al. Updated standardized endpoint definitions for transcatheter aortic valve implantation: the Valve Academic Research Consortium-2 consensus document. *The Journal of thoracic and cardiovascular surgery* 2013;145:6-23.
19. Bull C, de Leval MR, Stark J, Taylor JF, Macartney FJ. Use of a subpulmonary ventricular chamber in the Fontan circulation. *The Journal of thoracic and cardiovascular surgery* 1983;85:21-31.
20. Coles JG, Leung M, Kielmanowicz S et al. Repair of tricuspid atresia: utility of right ventricular incorporation. *The Annals of thoracic surgery* 1988;45:384-9.

1. Ilbawi MN, Idriss FS, DeLeon SY et al. When should the hypoplastic right ventricle be used in a Fontan operation? An experimental and clinical correlation. *The Annals of thoracic surgery* 1989;47:533-8.
2. Burkhart HM, Dearani JA, Mair DD et al. The modified Fontan procedure: early and late results in 132 adult patients. *The Journal of thoracic and cardiovascular surgery* 2003;125:1252-9.
3. McElhinney DB, Benson LN, Eicken A, Kreuzer J, Padera RF, Zahn EM. Infective endocarditis after transcatheter pulmonary valve replacement using the Melody valve: combined results of 3 prospective North American and European studies. *Circulation Cardiovascular interventions* 2013;6:292-300.
4. Buber J, Bergersen L, Lock JE et al. Bloodstream infections occurring in patients with percutaneously implanted bioprosthetic pulmonary valve: a single-center experience. *Circulation Cardiovascular interventions* 2013;6:301-10.
5. McElhinney DB, Cheatham JP, Jones TK et al. Stent fracture, valve dysfunction, and right ventricular outflow tract reintervention after transcatheter pulmonary valve implantation: patient-related and procedural risk factors in the US Melody Valve Trial. *Circulation Cardiovascular interventions* 2011;4:602-14.
6. Deal BJ, Costello JM, Webster G, Tsao S, Backer CL, Mavroudis C. Intermediate-Term Outcome of 140 Consecutive Fontan Conversions With Arrhythmia Operations. *The Annals of thoracic surgery* 2016;101:717-24.
7. Ono M, Cleuziou J, Kasnar-Samprec J et al. Conversion to Total Cavopulmonary Connection Improves Functional Status Even in Older Patients with Failing Fontan Circulation. *The Thoracic and cardiovascular surgeon* 2015;63:380-7.

Accepted

Figure Legends

Figure 1

Frontal (A and C) and lateral (B and D) projection angiograms before (A and B) and after (C and D) Melody valve (M) implantation in a patient with a stenotic and regurgitant bioprosthetic valve (black arrows) in the proximal portion of the right atrium (RA) to right ventricle (RV) connection. The black arrows indicate the radiopaque markers on the commissural posts of the surgical valve. The white arrows in B indicate the narrow orifice of the valve and regurgitation into the RA. After Melody valve implant, the caliber of the orifice is larger and there is no regurgitation.

Figure 2

Panels top) and middle) depict top) the mean Doppler RA-RV gradient and middle) RA-RV conduit regurgitation severity determined by echocardiography pre-intervention, early post-intervention, and at latest follow-up. The p values in top) reflect comparison with the pre-intervention time point (pre- vs early post-intervention & pre- vs follow-up) by paired t-test. The column chart in bottom) depicts the distribution of NYHA functional status classification before implant (n=16) and at most recent follow-up (n=13). Two of the deceased patients are included in the follow-up column, including the 1 in NYHA class 4 and 1 of the 2 in class 3, both of whom were unchanged from pre-implant.

Figure 3

Top) This lateral projection chest x-ray demonstrates a Melody valve implanted within a heavily calcified homograft RA-RV conduit (HC), with multiple minor stent fractures (arrows indicate 2 of these). There is a single pre-stent. A indicates the anterior chest wall. Bottom) These lateral projection fluoroscopic images show a stented RA-RV conduit prior to Melody valve implant (left) and following placement of an additional pre-stent and a Melody valve (right). Note the significant anteroposterior compression of the stented conduit on the left, and the enlargement and relief of compression after stent and Melody valve implant on the right.

Video 1a & 1b

These angiograms demonstrate A) obstruction and regurgitation of a homograft RA-RV conduit before intervention, and B) after Melody valve implantation.

Video 2

These 2D and Doppler color flow intracardiac echocardiogram images obtained during catheterization 3.5 years after placement of a Melody valve in an RA-RV conduit demonstrate unobstructed flow, good leaflet coaptation, and trivial regurgitation. There is a small area of thickening or possibly thrombus attached to one of the leaflets.

Accepted Article

Abstract:

Background: The most common reason for reintervention after a Björk modification of the Fontan procedure, in which the right ventricle (RV) is incorporated into the pulmonary circulation by connecting the right atrial (RA) appendage to the RV directly or with an extra-anatomic graft, is obstruction or regurgitation of the RA-RV connection. Transcatheter implantation of a valved stent is an appealing option for the treatment of RA-RV conduit dysfunction in these patients. In the present study, we assessed early and intermediate results after transcatheter valve implantation within an obstructed or regurgitant RA-RV modified Fontan pathway.

Methods: Through a retrospective multi-center registry, we collected data from 16 patients with a modified Fontan circulation who were treated with percutaneous Melody or Sapien valve implantation for dysfunction of an extra-anatomic RA-RV conduit or valve.

Results: All patients had successful and uncomplicated implantation of a Melody (n=15) or Sapien 3 (n=1) valve with hemodynamic and, in most cases, clinical improvement. During a median follow-up of 3.3 years, 3 patients died of cardiovascular causes unrelated to the procedure or the valve, and no major valve dysfunction was observed.

Conclusion: Percutaneous transcatheter valve deployment to treat a dysfunctional RA-RV connection after a Björk modification of the Fontan procedure is a viable alternative to surgery, with low procedural risk, and appears to offer good early and intermediate results.

Introduction

The Björk modification of the Fontan operation, performed primarily for tricuspid atresia with normally related great arteries, incorporates a pulsatile right ventricle (RV) into the cavopulmonary circuit by direct anastomosis of the right atrial (RA) appendage to the RV(1). Related modifications utilize a graft (either a valved xenograft conduit, a non-valved synthetic tube, or a valved or non-valved homograft) to connect the RA to the RV. Over time, RA-RV graft/conduit dysfunction is a common reason for symptoms after a modified Björk procedure, and revision or replacement of the RA-RV pathway is among the most common reinterventions in these patients(2-6). Although there are potential advantages to inclusion of the RV between the systemic venous and the pulmonary arterial compartments, obstruction of the RA-RV conduit and/or regurgitation of flow from the RV to the RA during ventricular contraction can impose an important hemodynamic burden. The Björk or modified Björk Fontan operation is rarely performed any longer, but there remain survivors of this procedure who may present with symptoms or consequences related to RA-RV conduit obstruction or regurgitation.

The morbidity and mortality associated with repeat surgeries in patients with congenital heart disease has markedly declined over the last 2-3 decades, but redo surgery continues to carry risks of mortality and various adverse outcomes(7,8), as well as further antigen exposure that may complicate suitability for cardiac transplantation in the future. Additionally, such surgery has inherent limitations for treatment of dysfunctional extracardiac RA-RV conduits, mainly due to the juxta-sternal position(9). Accordingly, there is a compelling interest in transcatheter management of RA-RV conduit obstruction and regurgitation. The Melody valve (Medtronic Inc., Minneapolis, MN) is approved for the treatment of RV outflow conduit dysfunction, and has been used for various other off-label applications(10), including treatment of RA-RV Fontan conduit obstruction or regurgitation(5,11-15). Similarly, successive generations of the Sapien valve (Edwards Lifesciences, Irvine, CA) have been extensively used in aortic and other valvular positions (16,17). In this study, we evaluated mid-term follow-up in a multi-center cohort of patients with a modified Björk Fontan procedure who underwent placement of a Melody or Sapien valve for RA-RV conduit dysfunction.

Methods

Patients:

Patients with a Björk (direct RA-RV connection) or modified Björk (RA-RV conduit) Fontan procedure who underwent placement of a transcatheter valve for obstruction or regurgitation of the RA-RV pathway were collected as part of a larger international registry of transcatheter tricuspid valve replacement.

The following data were collected by means of a standardized reporting form: demographics, diagnosis, valve/conduit type, age of valve/conduit, mechanism of conduit dysfunction, baseline clinical status, comorbidities, baseline echocardiographic and cardiac catheterization data, procedural details, acute hemodynamic and clinical outcomes, early complications, and information in regards to clinical, echocardiographic, valve function, and outcome at their latest clinic visit. Local Research and Ethics boards at each hospital approved the study.

Procedure:

Procedures were performed either under general or local anesthesia, through femoral venous access, and under fluoroscopy, with or without echocardiography guidance. The technical details of the procedure, including pre-dilation of the pathway, stent placement before valve implant and post-dilation after valve implant, were at the discretion of the operator. Technical success was defined as deployment of the Melody or Sapien valve in the intended location within the RA-RV conduit or valve without significant residual gradient or regurgitation. Vascular complications were defined as per the Valve Academic Research Consortium consensus document (18).

Data analysis:

Data are presented descriptively as frequency (%), median (minimum-maximum), or mean \pm standard deviation. Pre- and post-intervention pressures were compared using paired t-test, and paired categorical data on tricuspid regurgitation (mild or less vs moderate or severe) were compared with McNemar's test.

Results

Patients:

A total of 16 patients who underwent transcatheter valve implant within a RA-RV Fontan connection were identified from 10 centers in the US, Canada, and Europe. Six of these patients were included in case reports or series of transcatheter tricuspid valve replacement(5,11,12,14,15). Demographic, historical, and diagnostic data are summarized in Table 1. The median age at the time of intervention was 41 years (25–48 years). All patients had a total cavopulmonary connection with drainage of the inferior and superior caval veins to the RA, or a bidirectional Glenn anastomosis (n=3), along with a RA-RV connection and an intact atrial septum. The RA-RV connection consisted of a homograft conduit in 6 patients, a xenograft valved conduit in 4, a non-valved tube graft in 3, and a bioprosthetic valve within a direct connection in 3. The median nominal diameter of the valve or conduit at the time of surgical repair was 26 mm (14-31 mm; unknown in 1), and the median duration from surgical conduit/valve implant to percutaneous intervention was 16 years (1-32 years). Eleven patients had previously undergone revision or replacement of the RA-RV pathway/conduit.

All patients had impaired functional status, with 2 patients in New York Heart Association (NYHA) class 2, 13 in class 3, and 1 in class 4. Most patients (n=12) had a history of or active atrial flutter. Other co-morbidities are summarized in Table 1. Poor surgical candidacy due to multiple previous operations and co-morbidities was the most common reason for attempting percutaneous valve intervention. One patient who was severely debilitated with atrial flutter, chronic renal insufficiency, anemia, hypothyroidism, lung disease, and type 2 diabetes was severely ill and hospitalized prior to the procedure.

Baseline hemodynamics:

Fourteen patients had some degree of mixed obstruction and regurgitation of the conduit/valve, and 1 each had isolated stenosis or regurgitation. Hemodynamic details from the pre-catheterization echocardiogram and the catheterization are summarized in Figure 2 and Table 2.

Procedure:

All procedures in this series were performed through femoral venous access, with 14 under general anesthesia and 2 with local anesthesia. Adjunctive intra-procedural imaging was used in 9 patients, including transesophageal echocardiography in 7 and intracardiac echocardiography in 2. Details of the intervention are summarized in Table 3. Rapid pacing was not utilized. Pre-stenting of the conduit with 1 or more bare metal stents was performed in 8 patients, including 7 of the 9 with unsupported conduits (i.e., homografts and non-valved synthetic tube grafts). Thirteen of the 15 Melody valves were deployed on a 22mm Ensemble delivery system (Medtronic Inc., Minneapolis, Minnesota), and 1 each was delivered on a 20mm delivery system or a 24mm balloon. The Sapien 3 valve was a 29mm device implanted within a bioprosthetic valve in a direct RA-RV pathway. The only concomitant procedure (other than pre-stenting) was stent implantation for left pulmonary artery stenosis in 1 patient, which was performed prior to Melody valve deployment. All valves were implanted successfully, without embolization or malposition (Figure 1, Video 1a & 1b).

Early outcomes:

Acute hemodynamic outcomes are summarized in Table 2 and depicted in Figure 2. Immediately post-implant, there was significant improvement in the mean RA-RV inflow gradient ($p < 0.001$) and the severity of RA-RV conduit regurgitation ($p = 0.002$). The highest post-implant mean RA-RV gradient was 3 mmHg by invasive pressure measurement (median 1.5 mmHg) and 4 mmHg by Doppler echocardiography (median 2 mmHg), and regurgitation was reduced to none ($n = 12$) or trivial ($n = 3$) in all but 1 patient, in whom it was reported as mild. Two patients had trivial ($n = 1$) or mild ($n = 1$) paravalvular regurgitation. Immediately post-intervention, the mean RA pressure remained unchanged, whereas RV systolic and end-diastolic pressures were higher than pre-procedure.

Three patients had pre-existing pacemakers, 1 of which was transvenous with a lead across the conduit into the RV that was entrapped between the Melody and the previously implanted bioprosthetic valve without any change in function. One patient had minor vascular complications without any sequelae, but no other procedural or hospital complications were noted. The median hospital stay was 2 days (1–16 days). At the time of discharge, all patients were on some form of anti-platelet and/or anti-coagulant

therapy: 8 on warfarin alone, 5 on anti-platelet therapy alone, and 3 on a combination of anti-platelet and warfarin therapy.

Follow-up:

Patients were followed for a median of 3.3 years (0.1-7.1 years); 5 patients were followed for 4 years or longer. Three patients died, including the only patient in NYHA class 4 pre-implant, 1, 11 and 35 months post-intervention. All of the deaths were from cardiovascular causes but unrelated to the procedure or valve: 1 arrhythmia, 1 progressive heart failure, and 1 patient (described above) who was acutely ill and hospitalized pre-procedure but never improved.

During follow-up, no patients underwent valve-related reinterventions. However, 1 patient underwent Fontan revision due to refractory atrial flutter and the RA-RV conduit was replaced at that procedure. Another patient underwent percutaneous atrial flutter ablation and 1 required ongoing renal replacement therapy for chronic insufficiency. NYHA status was reported at follow-up for 11 of the 13 surviving patients, 10 of whom had improved by 1 (n=7) or 2 (n=3) grades. The median follow-up NYHA class was 2 (1-3), with 4 patients in class 1 and only 1 patient in class 3 (Figure 2). No patients were diagnosed with suspected or confirmed infective endocarditis. One patient, who had a valve implanted within a heavily calcified homograft conduit with a single pre-stent, was diagnosed with a Melody valve stent fracture approximately 2 years after implant, and was observed to have progression in the number of fractured struts over the subsequent 5 years but no evidence of valve dysfunction (mean gradient 5 mmHg at most recent follow-up) (Figure 3) (14).

As summarized in Table 2, transcatheter valve function remained good in most patients, although new onset moderate TR was observed in 1 patient 4.4 years post-intervention. The mean Doppler gradient on the most recent echocardiogram was modestly but significantly higher than on the early post-implant study by paired t-test (3.8 ± 2.3 vs 2.3 ± 1.1 , $p=0.002$), but still substantially lower than pre-implant (7.1 ± 5.0 , $p=0.011$). Six patients underwent cardiac catheterization 2.3-4.3 years after implant (median 3.4 years), with mean and phasic RA pressures that were lower than pre-implant and RV pressures that were similar.

The patient who received a Sapien 3 valve was followed for only 2.3 months. Video 2 demonstrates intracardiac echocardiography of a well functioning Melody valve during catheterization 3.5 years after implant.

Discussion

Patients born with tricuspid atresia are usually palliated with a modified Fontan circulation. Prior to the advent of lateral tunnel and extracardiac conduit strategies for total cavopulmonary connection, patients with tricuspid atresia and normally related great arteries often had a Björk or modified Björk Fontan procedure, in which the subpulmonary RV was incorporated into the Fontan circuit, allowing injection of kinetic energy into the pulmonary circulation. Although several studies from the 1980s suggest that there are benefits to incorporation of the RV in patients with tricuspid atresia, it is unclear if and in which patients this circulatory arrangement conferred a long-term survival or functional advantage (19-21). The RA-RV connection in a modified Björk procedure can vary in size, type, and configuration, but studies found that reintervention on the conduit/anastomosis was among the most common sources of late morbidity regardless of conduit type(4). This is reflected in the current study cohort, two-thirds of whom had undergone surgical revision of the RA-RV connection prior to Melody valve implant. Although, studies have demonstrated that a direct RA appendage-RV connection is associated with significantly less need for reintervention than pathways incorporating an extra-anatomic RA-RV conduit, patients with a valveless direct connection are more prone to complications of a failing Fontan circulation (4,22). Although the Björk procedure is rarely employed in the current era, there remain numerous patients with this circulation who present with the various complicating factors of a Fontan circulation and require management.

In this multicenter study, transcatheter implantation of a Melody or Sapien 3 valve was effective at restoring good hemodynamic function of the extra-anatomic RA-RV connection in patients with a Björk or modified Björk Fontan connection, with few procedural or late complications. It was encouraging to note excellent valve function over a relatively long duration of follow-up and stable clinical improvement in this complex patient population. However, some patients remained symptomatic, mainly due to atrial flutter,

and thus it was difficult to assess the true impact of valve implantation in these patients. Also, the relatively high mortality (n=3) during follow-up, despite successful valve implant, highlights the limitations of this modest hemodynamic intervention on the background of an inherently inefficient modified Fontan circulation. Although RA-RV conduit dysfunction is a rare problem in the current era, it is important to recognize that transcatheter therapy can be utilized to help improve the hemodynamic status of this circulation but that it has limitations.

There are no recent series of reoperation in patients with obstruction of a RA-RV Fontan connection, but studies published 15-20 years ago reported substantial mortality(4,9). It is likely that percutaneous intervention for RA-RV conduit dysfunction offers a number of advantages over reoperation in patients who do not require other surgical interventions, including avoidance of cardiopulmonary bypass and the other morbidity associated with re-sternotomy, freedom from blood transfusion which may help reduce sensitization that can interfere with suitability for cardiac transplantation, and earlier mobilization and shorter hospital stay. Of course, these benefits must be weighed against risks. There were few complications in this series, but potential risks may be inferred from the literature on Melody valve implant in RV outflow tract conduits. In particular, recent articles raised concern about infective endocarditis after transcatheter valve replacement(23,24). No cases of endocarditis or systemic infection were reported during follow-up of up to 7 years in this small cohort, all of whom were maintained on anti-platelet and/or anti-coagulant therapy, but close follow-up and a low threshold for investigating signs or symptoms of infection are critical in this population, as in any patient with a prosthetic valve or conduit.

As the RA-RV pathway is prone to external compression, pre-stenting the conduit/graft prior to the Melody valve may play a critical role maintaining valve integrity during follow-up. In the early experience with the Melody valve in the RV outflow tract, stent fracture and consequent obstruction was a problem, but this has been largely overcome with the routine use of bare metal stents to pre-stent the conduit before valve implant. (25). The anterior position of the RA-RV conduit or pathway in an RA-RV Fontan may impart similar risk for Melody valve stent fracture risk. Accordingly, pre-stenting may be important in Björk patients undergoing Melody valve implant, particularly in those with an unsupported RA-RV

connection (e.g., a homograft conduit or non-valved tube graft). Most of the patients in this series with an unreinforced conduit had pre-stents placed before valve implant, and one of these patients was diagnosed with a fractured pre-stent several years after Melody valve placement, with no evidence of valve dysfunction. Otherwise, there were no Melody valve stent fractures. Although the issue of conduit compression was not specifically addressed in the current study, using a projection that looks down the barrel of the conduit can help demonstrate residual compression and pre-stent implantation and help guide decision-making about placement of additional stents, as depicted in Figure 3.

In patients with intractable atrial arrhythmias or severe hemodynamic derangement after a modified Fontan procedure, simply relieving RA-RV conduit obstruction or regurgitation by implanting a transcatheter valve is unlikely to make a major difference. In such cases, heart transplant or Fontan conversion with arrhythmia surgery are likely necessary (26,27). However, Fontan conversion can be associated relatively high mortality (27), particularly in sicker patients, and many patients are deemed unsuitable candidates. RA-RV valve implantation may be of palliative benefit in such patients. Similarly, valve implant within an RA-RV conduit will not mitigate the deleterious pathophysiology of a Fontan circulation altogether, and in the current study cohort, RA pressures remained elevated even after Melody valve placement, due at least in part to high RV end-diastolic pressures. And in the sickest patient in this series, who died 1 month after implant despite an uncomplicated procedure and good valve function, valve implant made no difference, illustrating the importance of intervening before it is too late. Even though valve implant may yield only modest hemodynamic benefit, reduction of regurgitant flow and elimination of obstruction should nevertheless improve the efficiency of this circulation, which may be sufficient to reduce symptoms in some patients, as demonstrated in this study. It is also possible that valve implant will allow sufficient clinical improvement in some patients with symptomatic atrial flutter that they will become more favorable surgical candidates.

Limitations:

This is a retrospective multi-center registry with inherent limitations, including a small number of patients, incomplete data, and potential reporting and selection biases. While operators from each participating

center submitted data on all patients who underwent catheterization for intended valve implant in this patient population, there were likely similar patients at other centers who were not included in the registry. Moreover, generalization of the findings may not be appropriate. While RA-RV conduit function clearly improved and patients reported an improvement in functional status, the physiologic and clinical implications of valve implantation were not evaluated, making it difficult to determine the impact of these interventions.

Conclusions:

Percutaneous Melody or a Sapien valve deployment to treat obstruction and/or regurgitation of the RA-RV connection after a modified Björk Fontan procedure is a viable alternative to surgery that appears to be safe and offers good early and intermediate-term results. Further long-term follow-up of these patients will be required to evaluate longevity of the Melody or the Sapien valve in this position.

Accepted Article

References:

1. Bjork VO, Olin CL, Bjarke BB, Thoren CA. Right atrial-right ventricular anastomosis for correction of tricuspid atresia. *The Journal of thoracic and cardiovascular surgery* 1979;77:452-8.
2. Huddleston CB. The failing Fontan: options for surgical therapy. *Pediatric cardiology* 2007;28:472-6.
3. Driscoll DJ, Offord KP, Feldt RH, Schaff HV, Puga FJ, Danielson GK. Five- to fifteen-year follow-up after Fontan operation. *Circulation* 1992;85:469-96.
4. Fernandez G, Costa F, Fontan F, Naftel DC, Blackstone EH, Kirklin JW. Prevalence of reoperation for pathway obstruction after Fontan operation. *The Annals of thoracic surgery* 1989;48:654-9.
5. Eicken A, Fratz S, Hager A, Vogt M, Balling G, Hess J. Transcatheter Melody valve implantation in "tricuspid position" after a Fontan Bjork (RA-RV homograft) operation results in biventricular circulation. *International journal of cardiology* 2010;142:e45-7.
6. Kiraly L, Dalrymple-Hay MJ, Salmon AP, Keeton BR, Monro JL. The fate of antibiotic sterilized aortic allografts in Fontan circulation: results of the long-term follow-up. *European journal of cardio-thoracic surgery : official journal of the European Association for Cardio-thoracic Surgery* 1999;16:660-2.
7. Kirshbom PM, Myung RJ, Simsic JM et al. One thousand repeat sternotomies for congenital cardiac surgery: risk factors for reentry injury. *The Annals of thoracic surgery* 2009;88:158-61.
8. Morales DL, Zafar F, Arrington KA et al. Repeat sternotomy in congenital heart surgery: no longer a risk factor. *The Annals of thoracic surgery* 2008;86:897-902; discussion 897-902.
9. Dore A, Somerville J. Right atrioventricular extracardiac conduit as a fontan modification: late results. *The Annals of thoracic surgery* 2000;69:181-5.
10. Hasan BS, McElhinney DB, Brown DW et al. Short-term performance of the transcatheter Melody valve in high-pressure hemodynamic environments in the pulmonary and systemic circulations. *Circulation Cardiovascular interventions* 2011;4:615-20.
11. Tanous D, Nadeem SN, Mason X, Colman JM, Benson LN, Horlick EM. Creation of a functional tricuspid valve: novel use of percutaneously implanted valve in right atrial to right ventricular conduit in a patient with tricuspid atresia. *International journal of cardiology* 2010;144:e8-10.
12. Roberts PA, Boudjemline Y, Cheatham JP et al. Percutaneous tricuspid valve replacement in congenital and acquired heart disease. *Journal of the American College of Cardiology* 2011;58:117-22.
13. Butcher CJ, Plymen CM, Walker F. A novel and unique treatment of right ventricular inflow obstruction in a patient with a Bjork modification of the Fontan palliation before pregnancy. *Cardiology in the young* 2010;20:337-8.
14. Eicken A, Schubert S, Hager A et al. Percutaneous tricuspid valve implantation: two-center experience with midterm results. *Circulation Cardiovascular interventions* 2015;8.
15. Godart F, Baruteau AE, Petit J et al. Transcatheter tricuspid valve implantation: a multicentre French study. *Archives of cardiovascular diseases* 2014;107:583-91.
16. Durand E, Borz B, Godin M et al. Transfemoral aortic valve replacement with the Edwards SAPIEN and Edwards SAPIEN XT prosthesis using exclusively local anesthesia and fluoroscopic guidance: feasibility and 30-day outcomes. *JACC Cardiovascular interventions* 2012;5:461-7.
17. Wilson WM, Benson LN, Osten MD, Shah A, Horlick EM. Transcatheter Pulmonary Valve Replacement With the Edwards Sapien System: The Toronto Experience. *JACC Cardiovascular interventions* 2015;8:1819-27.
18. Kappetein AP, Head SJ, Genereux P et al. Updated standardized endpoint definitions for transcatheter aortic valve implantation: the Valve Academic Research Consortium-2 consensus document. *The Journal of thoracic and cardiovascular surgery* 2013;145:6-23.
19. Bull C, de Leval MR, Stark J, Taylor JF, Macartney FJ. Use of a subpulmonary ventricular chamber in the Fontan circulation. *The Journal of thoracic and cardiovascular surgery* 1983;85:21-31.
20. Coles JG, Leung M, Kielmanowicz S et al. Repair of tricuspid atresia: utility of right ventricular incorporation. *The Annals of thoracic surgery* 1988;45:384-9.

1. Ilbawi MN, Idriss FS, DeLeon SY et al. When should the hypoplastic right ventricle be used in a Fontan operation? An experimental and clinical correlation. *The Annals of thoracic surgery* 1989;47:533-8.
2. Burkhart HM, Dearani JA, Mair DD et al. The modified Fontan procedure: early and late results in 132 adult patients. *The Journal of thoracic and cardiovascular surgery* 2003;125:1252-9.
3. McElhinney DB, Benson LN, Eicken A, Kreuzer J, Padera RF, Zahn EM. Infective endocarditis after transcatheter pulmonary valve replacement using the Melody valve: combined results of 3 prospective North American and European studies. *Circulation Cardiovascular interventions* 2013;6:292-300.
4. Buber J, Bergersen L, Lock JE et al. Bloodstream infections occurring in patients with percutaneously implanted bioprosthetic pulmonary valve: a single-center experience. *Circulation Cardiovascular interventions* 2013;6:301-10.
5. McElhinney DB, Cheatham JP, Jones TK et al. Stent fracture, valve dysfunction, and right ventricular outflow tract reintervention after transcatheter pulmonary valve implantation: patient-related and procedural risk factors in the US Melody Valve Trial. *Circulation Cardiovascular interventions* 2011;4:602-14.
6. Deal BJ, Costello JM, Webster G, Tsao S, Backer CL, Mavroudis C. Intermediate-Term Outcome of 140 Consecutive Fontan Conversions With Arrhythmia Operations. *The Annals of thoracic surgery* 2016;101:717-24.
7. Ono M, Cleuziou J, Kasnar-Samprec J et al. Conversion to Total Cavopulmonary Connection Improves Functional Status Even in Older Patients with Failing Fontan Circulation. *The Thoracic and cardiovascular surgeon* 2015;63:380-7.

Accepted

Figure Legends

Figure 1

Frontal (A and C) and lateral (B and D) projection angiograms before (A and B) and after (C and D) Melody valve (M) implantation in a patient with a stenotic and regurgitant bioprosthetic valve (black arrows) in the proximal portion of the right atrium (RA) to right ventricle (RV) connection. The black arrows indicate the radiopaque markers on the commissural posts of the surgical valve. The white arrows in B indicate the narrow orifice of the valve and regurgitation into the RA. After Melody valve implant, the caliber of the orifice is larger and there is no regurgitation.

Figure 2

Panels top) and middle) depict top) the mean Doppler RA-RV gradient and middle) RA-RV conduit regurgitation severity determined by echocardiography pre-intervention, early post-intervention, and at latest follow-up. The p values in top) reflect comparison with the pre-intervention time point (pre- vs early post-intervention & pre- vs follow-up) by paired t-test. The column chart in bottom) depicts the distribution of NYHA functional status classification before implant (n=16) and at most recent follow-up (n=13). Two of the deceased patients are included in the follow-up column, including the 1 in NYHA class 4 and 1 of the 2 in class 3, both of whom were unchanged from pre-implant.

Figure 3

Top) This lateral projection chest x-ray demonstrates a Melody valve implanted within a heavily calcified homograft RA-RV conduit (HC), with multiple minor stent fractures (arrows indicate 2 of these). There is a single pre-stent. A indicates the anterior chest wall. Bottom) These lateral projection fluoroscopic images show a stented RA-RV conduit prior to Melody valve implant (left) and following placement of an additional pre-stent and a Melody valve (right). Note the significant anteroposterior compression of the stented conduit on the left, and the enlargement and relief of compression after stent and Melody valve implant on the right.

Video 1a & 1b

These angiograms demonstrate A) obstruction and regurgitation of a homograft RA-RV conduit before intervention, and B) after Melody valve implantation.

Video 2

These 2D and Doppler color flow intracardiac echocardiogram images obtained during catheterization 3.5 years after placement of a Melody valve in an RA-RV conduit demonstrate unobstructed flow, good leaflet coaptation, and trivial regurgitation. There is a small area of thickening or possibly thrombus attached to one of the leaflets.

Accepted Article