

DR. MANUEL ARTETA (Orcid ID : 0000-0001-8496-3127)

Received Date : 17-Nov-2016

Revised Date : 27-Jan-2017

Accepted Date : 13-Feb-2017

Article type : Case Report

Interstitial lung disease of infancy caused by a new *NKX2-1* mutation

**Khalid H. Safi, John A Bernat, Catherine Keegan, Ayesha Ahmah, Marc B. Hershenson,
Manuel Arteta**

Department of Pediatrics and Communicable Diseases, University of Michigan Medical School,
Ann Arbor, Michigan, USA

Address for Correspondence and Reprint Requests: Manuel Arteta, M.D., University of
Michigan Medical School, Women's Hospital L2202, 1500 E. Medical Center Drive, Ann Arbor,
MI 48109-5212; Phone: (734) 764-4123, fax: (734) 763-9635; Email: marteta@umich.edu

Key words: Interstitial lung disease, hypothyroidism, thyroid transcription factor-1.

Running head: New *NKX2-1* mutation causing brain-thyroid-lung disease

Word Count: 1831

This is the author manuscript accepted for publication and has undergone full peer review but has not been through the copyediting, typesetting, pagination and proofreading process, which may lead to differences between this version and the [Version of Record](#). Please cite this article as [doi: 10.1002/ccr3.901](https://doi.org/10.1002/ccr3.901)

This article is protected by copyright. All rights reserved

Key clinical message: Patients with personal or family history of congenital hypothyroidism, and/or neurological findings that also have chronic respiratory symptoms may have a mutation in the *NKX2.1* gene as the unifying cause of their disease. Brain-lung-thyroid disease is the ensuing condition, which although rare, needs to be part of the differential diagnosis.

Summary

The *NKX2-1* gene encodes thyroid transcription factor 1, a transcription factor required for the expression of surfactant protein A, B, and C and other lung-specific proteins. *NKX2-1* also regulates the expression of pendrin and thyroglobulin. Thus, mutations in *NKX2-1* have been linked to the development of respiratory disease, neurological impairment and hypothyroidism, referred to as brain-lung-thyroid syndrome. In this report, we describe two siblings with interstitial lung disease associated with a single *NKX2-1* splice mutation (c.464-9C>A) which was not considered pathogenic at the time of initial testing. Maternal history is positive for severe childhood lung disease requiring extracorporeal membrane oxygenation as well as hypothyroidism, gait ataxia and tremors. Other family members also have thyroid disease but no neurological or lung disease. The proband's respiratory symptoms improved with a combined regimen of hydroxychloroquine, prednisolone and azithromycin. The *NKX2-1* mutation found in this family has not been previously reported as a cause of pulmonary disease, and our report demonstrates the phenotypic variability of mutations on this gene.

Introduction

The *NKX2-1* is a gene that encodes the thyroid transcription factor 1, a member of the homeodomain-containing family of transcription factors. During human development, *NKX2-1* is expressed early in fetal life in the thyroid bud and prosencephalon, and later in the lung epithelium^{1,2} *NKX2-1* is critical for the expression of surfactant proteins A, B, and C, as well as ABCA3³⁻⁵, a lipid transporter in pulmonary surfactant biogenesis. Haploinsufficiency for *NKX2-1* due to either complete gene deletions or loss-of-function mutations results in brain-thyroid-lung syndrome with affected individuals having variable degrees of pulmonary disease (neonatal respiratory distress syndrome or children's interstitial lung disease), hypothyroidism, and neurologic abnormalities (typically benign hereditary chorea)⁶⁻¹¹. However, the classical triad is not always present and severity of the thyroid, neurological and pulmonary disorders vary widely^{8,12}. In this report we describe a family of two siblings and their mother with a *NKX2-1* mutation that has not previously been associated with lung disease. The mother signed an informed consent for the publication of these cases.

Case presentations

The mother of the two siblings described in this report has congenital hypothyroidism (Figure 1, II-2). She required extracorporeal membrane oxygenation (ECMO) therapy in the neonatal period for respiratory failure due to meconium aspiration, she was discharged home without supplemental oxygen and has not had any significant respiratory illnesses since then. She also has gait ataxia and tremors which were attributed to brain injury following ECMO therapy. The maternal aunt (Figure 1, II-3) has hypothyroidism but no respiratory or neurologic disease. Both the mother and maternal aunt were found to carry the same *NKX2-1* gene variant as the proband case. The maternal grandparents have no history of thyroid, neurologic or respiratory disease, and they do not carry this gene variant.

Case one: Our first encounter with the family was with the oldest child (Figure 1, III-1). She was born full term without complications. Her newborn screen was positive for hypothyroidism and she was started on thyroid hormone replacement. At 4 months of age, she was admitted for management of preseptal cellulitis. During that admission she was found to have mild tachypnea, subcostal retractions, bilateral lung crackles and an oxyhemoglobin saturation ranging between 83 and 90% on room air. Initial radiograph of the chest was unremarkable. Further work up included high resolution computed tomography (HRCT) of the chest, bronchoscopy, echocardiogram, sleep study, video swallow study, and brain MRI. The HRCT of the chest showed only some dependent atelectasis, but normal lung parenchyma, the sleep study revealed mild obstructive hypopnea that improved with oxygen supplementation but no hypoventilation, and the video swallow study revealed aspiration of thin liquids. The child was discharged home on oxygen via nasal cannula (1.5 L/min), thickened formula, and thyroid hormone replacement. *NKX2-1* gene analysis was reported as heterozygous for an intronic variant, c.464-9C>A. This mutation was considered a variant of uncertain significance as it had not been previously reported in patients or unaffected individuals; however, splice site calculators indicated a potential reduction in correct splicing.

Over the next few months, her oxygen requirement increased to 2 L/min. At 12 months the age she was admitted with severe respiratory distress requiring endotracheal intubation and mechanical ventilation due to human metapneumovirus infection. She developed severe ARDS requiring two weeks of ECMO therapy. She recovered from this acute illness and was discharged home with supplemental oxygen at 2.5 L per min via nasal cannula and nasogastric tube feeding due to oral aversion.

She was admitted a third time at age of 20 months with Respiratory Syncytial Virus (RSV) bronchiolitis and severe respiratory distress requiring endotracheal intubation and high frequency mechanical ventilation. Three weeks later she was discharged with an increased oxygen requirement of 3 L per min. A repeat swallow study during this admission was normal. The child was seen in pulmonary clinic at 22 months of age. At that time, respiratory rate was 70/min on 2 L/min supplemental oxygen, oxyhemoglobin saturation on room air was 82%, and lung examination showed severe retractions, and diffuse crackles. A repeat HRCT of the chest showed diffuse mixed ground-glass and ill-defined nodular opacities scattered throughout both lungs. Treatment was begun with triple anti-inflammatory therapy consisting of prednisolone (2

mg/kg every other day), azithromycin 80 mg three times a week, and hydroxychloroquine (6 mg/kg/day). Two months later, the child showed significant improvements in growth, respiratory rate and lung exam. One year after initiating chronic anti-inflammatory therapy, prednisolone dose had been weaned to 0.7 mg/kg every other day, oxygen therapy remained at 2 L/min, her oxyhemoglobin saturation had improved to 90% on room air, respiratory rate was 42/min, there were no retractions, lung exam showed only sparse crackles at the bases, and she had not required hospitalizations .

Case 2. The younger sister (Figure 1, III-2) was born to the same parents at term without complications. She was also diagnosed with congenital hypothyroidism by newborn screening and was started on thyroid hormone replacement therapy soon after birth. She did not have any respiratory problem until 4 months of age when she developed RSV bronchiolitis. During that illness she was found to be hypoxemic and required oxygen therapy for a few days, but discharged home on room air and with a normal respiratory exam. Genetic testing for *NKX2-1* demonstrated the same variant as her older sister. She was admitted to a local hospital at the age of 7 months with pneumonia and was treated with antibiotics, during that admission she again required oxygen supplementation. Upon follow up in the pulmonary clinic at 8 months of age, she was started on maintenance prednisolone therapy of 2 mg/kg/day, which was weaned off slowly without development of respiratory symptoms.

Discussion

The individuals from the family described in this report possess a heterozygous *NKX2-1* gene variant (c.464-9C>A; p.Ile155Thrfs*286). Because the variant was located within an intron and had not been previously linked to brain-lung-thyroid syndrome, it was initially reported as a variant of uncertain significance. However, the same *NKX2-1* variant was subsequently reported to be linked to benign hereditary chorea in a Japanese family¹⁸. This family included six individuals in three generations presenting with choreic involuntary movements in childhood, without thyroid or respiratory problems. Further study of this variant found that it activates a cryptic splice acceptor site, resulting in the insertion of seven nucleotides in the transcript. This is predicted to cause a change in the reading frame resulting in an abnormal protein with amino acid substitutions beginning at amino acid 155. To our knowledge, this *NKX2-1* mutation has

not been reported in association with lung disease previously.

A molecular defect in the *NKX2-1* gene was first identified in 1998 in a patient with neonatal thyroid dysfunction and respiratory failure, who later developed hypotonia and truncal ataxia⁷. Subsequently other cases were described, and the term “Brain-Thyroid-Lung syndrome” was coined in 2005⁸⁻¹¹. Since then this term has become widely used to describe patients who have neurological, thyroid and/or lung disorders in association with *NKX2-1* gene mutations^{8,12}. The classical triad of this syndrome is not always present, as can be appreciated in the family described in this report; and the severity of neurological, thyroid and lung compromise is also variable¹⁰. The lung disease may present as respiratory distress syndrome, interstitial lung disease, pulmonary fibrosis, or recurrent respiratory tract infections^{11,13-17}.

In the family we describe in this report we have not only observed variation in the organ systems involved, but also a variable degree of lung disease, this is consistent with the findings of Hanvas et.al. in a case series of 21 patients with different *NKX2-1* mutations and variable degree of lung disease recently reported¹⁰. The same observation was noted with regard to thyroid and neurological involvement by Gras et al, who concluded that there were no genotype-phenotype correlations, and that there was phenotype variability in individuals with the same mutation¹³. Hanvas et.al. also reported that recurrent pulmonary infections were a prominent feature in patients with *NKX2-1* mutations¹⁰, this phenomenon can also be appreciated in the proband case of our report.

The patients’ maternal grandparents both tested negative for the familial *NKX2-1* variant, but had two children (the patients’ mother and maternal aunt) who tested positive for the variant. It is then likely that one of the grandparents is mosaic for the variant, which was not detectable in DNA extracted from a blood sample. However, the possibility of misattributed parentage was not specifically excluded.

Hydroxychloroquine has been successfully used in the treatment of both surfactant protein C and ABCA3 deficiencies^{19,20}. Since the transcription factor *NKX2-1* regulates the expression of both surfactant protein C and ABCA3, we reasoned that hydroxychloroquine would be useful in the treatment of brain-lung-thyroid disease associated with an *NKX2-1* mutation. Therapy with hydroxychloroquine, along with azithromycin and prednisolone, was associated with significant clinical improvement in the sibling with life-threatening lung disease. As far as we are aware, this is the first report of seemingly successful treatment of *NKX2-1*

associated lung disease with this combination therapy, but given the variable phenotypic manifestations of lung involvement in infants with this condition, and the fact that our patient was recovering from a severe pulmonary viral infections, our ability to state with a high degree of certainty that this drug therapy improved the underlying lung disease is limited. On the other hand her symptoms responded promptly and she has been doing well since then suggesting that this intervention has played a role.

Conclusion

Mutations in the *NKX2-1* gene result in variable disease phenotypes. The classical triad of brain thyroid-lung syndrome is not always present, and different presentations may result from same mutations. A high index of suspicion should be maintained in patients with lung disease of unknown cause, especially if there is associated neurological or thyroid disease or a family history of such disorders. In this report, we show that the c.464-9C>A variant in the *NKX2-1* gene can be associated with life-threatening infantile lung disease, and that treatment with hydroxychloroquine, azithromycin and prednisolone might be helpful in such cases.

References

1. Trueba SS, Augé J, Mattei G, Etchevers H, Martinovic J, Czernichow P, Vekemans M, Polak M, Attié-Bitach T. PAX8, TITF1, and FOXE1 Gene Expression Patterns during Human Development: New Insights into Human Thyroid Development and Thyroid Dysgenesis-Associated Malformations. *The Journal of Clinical Endocrinology & Metabolism* 2005;90(1):455-462.
2. Szinnai G, Lacroix L, Carré A, Guimiot F, Talbot M, Martinovic J, Delezoide A-L, Vekemans M, Michiels S, Caillou B, Schlumberger M, Bidart J-M, Polak M. Sodium/Iodide Symporter (NIS) Gene Expression Is the Limiting Step for the Onset of Thyroid Function in the Human Fetus. *The Journal of Clinical Endocrinology & Metabolism* 2007;92(1):70-76.
3. Bingle CD. Thyroid transcription factor-1. *The International Journal of Biochemistry & Cell Biology* 1997;29(12):1471-1473.

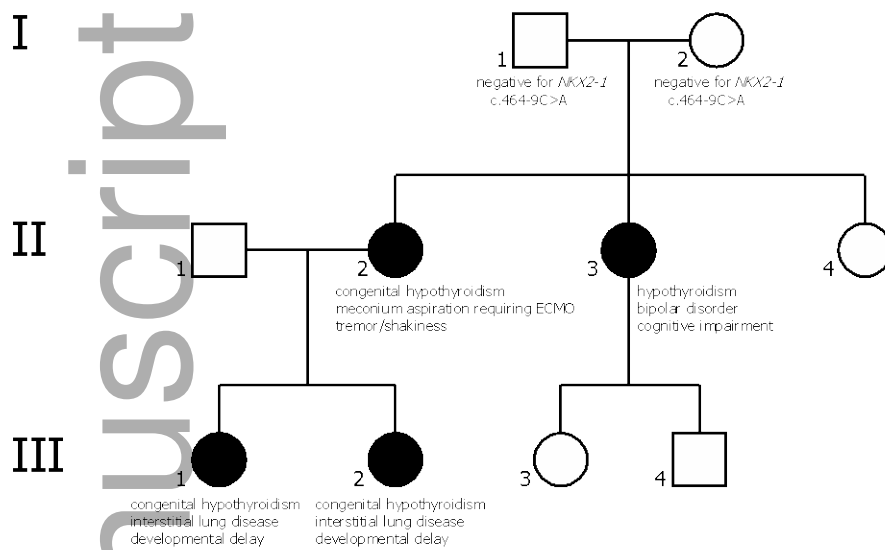
4. Bohinski RJ, Di Lauro R, Whitsett JA. The lung-specific surfactant protein B gene promoter is a target for thyroid transcription factor 1 and hepatocyte nuclear factor 3, indicating common factors for organ-specific gene expression along the foregut axis. *Molecular and Cellular Biology* 1994;14(9):5671-5681.
5. Besnard V, Xu Y, Whitsett JA. Sterol response element binding protein and thyroid transcription factor-1 (Nkx2.1) regulate Abca3 gene expression 2007. L1395-L1405 p.
6. Devriendt K, Vanhole C, Matthijs G, de Zegher F. Deletion of Thyroid Transcription Factor-1 Gene in an Infant with Neonatal Thyroid Dysfunction and Respiratory Failure. *New England Journal of Medicine* 1998;338(18):1317-1318.
7. Krude H, Sch, xFc, tz B, Biebermann H, von Moers A, Schnabel D, Neitzel H, xF, nnies H, Weise D, Lafferty A, Schwarz S, DeFelice M, von Deimling A, van Landeghem F, DiLauro R, Gr, ters A. Choreoathetosis, hypothyroidism, and pulmonary alterations due to human NKX2-1 haploinsufficiency. *The Journal of Clinical Investigation* 2002;109(4):475-480.
8. Pohlenz J, Dumitrescu A, Zundel D, Martin, xE, Ursula, Sch, xF, nberger W, Koo E, Weiss RE, Cohen RN, Kimura S, Refetoff S. Partial deficiency of Thyroid transcription factor 1 produces predominantly neurological defects in humans and mice. *The Journal of Clinical Investigation* 2002;109(4):469-473.
9. Doyle DA, Gonzalez I, Thomas B, Scavina M. Autosomal dominant transmission of congenital hypothyroidism, neonatal respiratory distress, and ataxia caused by a mutation of NKX2-1. *The Journal of Pediatrics* 2004;145(2):190-193.
10. Hamvas A, Deterding RR, Wert SE, White FV, Dishop MK, Alfano DN, Halbower AC, Planer B, Stephan MJ, Uchida DA, Williams LD, Rosenfeld JA, Lebel RR, Young LR, Cole FS, Noguee LM. Heterogeneous pulmonary phenotypes associated with mutations in the thyroid transcription factor gene nkx2-1. *Chest* 2013;144(3):794-804.
11. Willemsen MAP, Breedveld G, Wouda S, Otten B, Yntema J, Lammens M, de Vries BA. Brain-Thyroid-Lung syndrome: a patient with a severe multi-system disorder due to a de novo mutation in the thyroid transcription factor 1 gene. *Eur J Pediatr* 2005;164(1):28-30.
12. Carré A, Szinnai G, Castanet M, Sura-Trueba S, Tron E, Broutin-L'Hermite I, Barat P, Goizet C, Lacombe D, Moutard M-L, Raybaud C, Raynaud-Ravni C, Romana S, Ythier H, Léger J, Polak M. Five new TTF1/NKX2.1 mutations in brain-lung-thyroid

- syndrome: rescue by PAX8 synergism in one case. *Human Molecular Genetics* 2009;18(12):2266-2276.
13. Gras D, Jonard L, Roze E, Chantot-Bastaraud S, Koht J, Motte J, Rodriguez D, Louha M, Caubel I, Kemlin I, Lion-François L, Goizet C, Guillot L, Moutard M-L, Epaud R, Héron B, Charles P, Tallot M, Camuzat A, Durr A, Polak M, Devos D, Sanlaville D, Vuillaume I, Billette de Villemeur T, Vidailhet M, Doummar D. Benign hereditary chorea: phenotype, prognosis, therapeutic outcome and long term follow-up in a large series with new mutations in the TITF1/NKX2-1 gene. *Journal of Neurology, Neurosurgery & Psychiatry* 2012;83(10):956-962.
 14. Young LR, Deutsch GH, Bokulic RE, Brody AS, Noguee LM. A mutation in *ttf1/nkx2.1* is associated with familial neuroendocrine cell hyperplasia of infancy. *Chest* 2013;144(4):1199-1206.
 15. Maquet E, Costagliola S, Parma J, Christophe-Hobertus C, Oligny LL, Fournet J-C, Robitaille Y, Vuissoz J-M, Payot A, Laberge S, Vassart G, Vliet GV, Deladoëy J. Lethal Respiratory Failure and Mild Primary Hypothyroidism in a Term Girl with a de Novo Heterozygous Mutation in the TITF1/NKX2.1 Gene. *The Journal of Clinical Endocrinology & Metabolism* 2009;94(1):197-203.
 16. Kleinlein B, Griese M, Liebisch G, Krude H, Lohse P, Aslanidis C, Schmitz G, Peters J, Holzinger A. Fatal neonatal respiratory failure in an infant with congenital hypothyroidism due to haploinsufficiency of the NKX2-1 gene: alteration of pulmonary surfactant homeostasis. *Archives of Disease in Childhood - Fetal and Neonatal Edition* 2011;96(6):F453-F456.
 17. Gillett ES, Deutsch GH, Bamshad MJ, McAdams RM, Mann PC. Novel NKX2.1 mutation associated with hypothyroidism and lethal respiratory failure in a full-term neonate. *J Perinatol* 2013;33(2):157-160.
 18. Konishi T, Kono S, Fujimoto M, Terada T, Matsushita K, Ouchi Y, Miyajima H. Benign hereditary chorea: dopaminergic brain imaging in patients with a novel intronic NKX2.1 gene mutation. *J Neurol* 2013;260(1):207-213.

19. Hepping N, Griese M, Lohse P, Garbe W, Lange L. Successful treatment of neonatal respiratory failure caused by a novel surfactant protein C p.Cys121Gly mutation with hydroxychloroquine. *J Perinatol* 2013;33(6):492-494.
20. Williamson M, Wallis C. Ten-year follow up of hydroxychloroquine treatment for ABCA3 deficiency. *Pediatric Pulmonology* 2014;49(3):299-301.

Author Manuscript

Figure 1. Pedigree.



Filled symbols represent individuals testing positive for NKX2-1 c.464-9C>A