

# **Minimal invasive flapless or open flap approach for single implant placement: a 2-year randomized controlled clinical trial**

Feng Wang, M.D., D.D.S.<sup>‡</sup> Wei Huang, M.S., D.D.S.<sup>‡</sup> Zhiyong Zhang, D.D.S.

<sup>‡</sup>Haowei Wang, D.D.S.<sup>‡</sup> Alberto Monje, D.D.S.<sup>\*</sup> Yiqun Wu, M.D., D.D.S.<sup>‡</sup>

<sup>‡</sup> Department of Oral Implantology, Ninth People's Hospital, Shanghai Jiao Tong University, School of Medicine; Shanghai Key Laboratory of Stomatology, Shanghai, China

<sup>\*</sup> Department of Periodontics and Oral Medicine, University of Michigan, School of Dentistry, Ann Arbor, MI, USA

## **Corresponding authors:**

**Yiqun Wu, M.D, D.D.S.**

Department of Oral Implantology, Ninth People's Hospital, Shanghai Jiao Tong University, School of Medicine; Shanghai Key Laboratory of Stomatology

No. 500 Quxi Road, Shanghai, China 200011

Email: [yiqunwu@hotmail.com](mailto:yiqunwu@hotmail.com)

Tel: 86-21-53315299

Fax: 86-21-53073068

Word count: 4000

Tables and figures: 3 tables and 2 figures

Running title: Minimal invasive implant placement

Disclaimer: The authors do not have any financial interests, either directly or indirectly, in the products or information listed in the paper.

## **ACKNOWLEDGEMENTS**

This study was supported by the project from School of Medicine, Shanghai Jiao Tong

**This is the author manuscript accepted for publication and has undergone full peer review but has not been through the copyediting, typesetting, pagination and proofreading process, which may lead to differences between this version and the [Version of Record](#). Please cite this article as [doi: 10.1111/clr.12875](https://doi.org/10.1111/clr.12875)**

This article is protected by copyright. All rights reserved

University (14XJ10023), the Combined Engineering and Medical Project of Shanghai Jiao Tong University (YG2012MS32, YG2014QN01), and the grant from National Nature Science Foundation of China (81371190).

Authors' contribution:

Dr. Feng Wang: drafting article, concept/design, data collection, data analysis

Pro. Yiqun Wu: surgery performance, concept/design, funding secured, critical revision of article

Pro. Wei Huang: data collection, patient enrollment

Pro. Zhiyong Zhang: funding secured

Dr. Alberto Monje: concept/design, critical revision of article

Dr. Haowei Wang: data collection

---

Received Date : 06-Dec-2015

Revised Date : 21-Apr-2016

Accepted Date : 26-Apr-2016

Article type : Original Research

**Minimally invasive flapless versus flapped approach for single implant placement:  
a 2-year randomized controlled clinical trial**

**Abstract**

**Purpose:** The purpose of this 2-year randomized controlled clinical trial was to assess the differences in implant survival rates, soft tissue preservation, patient centered outcome and crestal bone changes applying the minimally invasive (MI) flapless approach for single implant placement compared to flapped implant surgery (FS).

**Materials and Methods:** Subjects eligible for this study were randomly assigned into two groups: MI or FS. Items of evaluation were the following: implant installation position, soft tissue healing, post-surgical pain, soft tissue outcome, marginal bone loss (MBL) and implant survival rate.

**Results:** Forty subjects (14 women and 26 men, 20 in MI group and 20 in FS group with a mean of  $39\pm 13.2$  years old) were included in the study. None of the implants demonstrated dehiscence or loss during the follow-up. Subjects in MI group showed significantly lower post-surgical pain and significantly less wound healing index scores at 1-week follow-up. The width of keratinized mucosa decreased from a mean of  $4.2\pm 1.6$ mm pre-surgically to  $3.7\pm 1.1$ mm at crown delivery but remained stable at 2-year follow-up in MI group. At every appointment in the study, no statistical significant difference of PD and MBL were found between the two groups.

**Conclusion:** Compared with FS, single implants placed applying the MI technique in selected subjects showed advantages in improving patient comfort and decreasing post-implant placement soft tissue reaction. Meanwhile, implants with MI approach have the same level of MBL and high success rates as FS procedure at 2-year follow-up. The deduction of keratinized mucosa is very limited and the width of KM remained stable with MI approach at 2-year follow-up.

This article is protected by copyright. All rights reserved

---

**KEY WORDS:** dental implant, flapless, single implant, minimally invasive, randomized clinical trials

## **Introduction**

Endosseous dental implants have become a dependable and predictable method of replacing missing teeth to enhance patients' quality of life. Clinicians are striving to further improve the patient implant treatment journey through minimizing the peri- and post-surgical discomfort, maximizing aesthetics, and improving the long-term success of the implants. Flapless implant surgery appears to be one way this can be aided (Brodala et al. 2009).

The flapless technique uses rotary burs or a tissue punch to gain access to the bone without flap elevation, so the vascular supply and surrounding soft tissue are well preserved. The advantages of this type of procedure include less surgical trauma, shorten operative time, rapid post-surgical healing, fewer post-surgical complications, and decreased patient discomfort (Casap et al. 2005; Oh et al. 2007; Komiyama et al. 2008).

Another advantage of flapless surgery as pointed by some authors was that when implants were placed without flap reflection, the length of the junctional epithelium extended more coronal than in flap surgery, which may provide an environment that is less prone to peri-implantitis (You et al. 2009; Lee et al. 2010).

Authors' though was that inflammation occurring during the first 3 weeks of healing played a crucial role in early peri-implant bone loss (You et al. 2009; Lee et al. 2010). As a matter of fact, early bone loss can be prevented or minimized if soft tissue wound around the dental implants heals quickly with little inflammation and scar tissue formation (You et al. 2009; Lee et al. 2010). Although the information of the influence of the incision design during implant placement on the formation of the implanto-epithelial junction was only limited in animal study (Berglundh et al. 1996; You et al. 2009; Lee et al. 2010).

Traditional flapless implant surgery using a soft tissue punch device requires a circumferential excision of keratinized tissue at the implant site, which averts the preservation of the peri-implant keratinized mucosa (KM). Although the importance of KM around implants is debated, reduced KM around implants appears to be associated with clinical parameters indicative of inflammation and poor oral hygiene. So in the clinical setting having approximately 2-3 mm of KM on the oral aspect of the emerging implant structures when placing a non-submerged implant or at abutment connection stage to a

This article is protected by copyright. All rights reserved

---

submerged implant is considered optimal to minimize future peri-implant diseases (Wennström et al. 1994; Lin et al. 2013; Gobbato et al. 2013).

Minimally invasive (MI) flapless implant placement was firstly reported by Campelo et al. in 2002 (Campelo et al. 2002). A drill was used to make the initial osteotomy, penetrating through the mucosa and into bone. In the following years, some case reports and studies have described various techniques for using MI approaches for implant placement (Rao et al. 2007; Rajut et al. 2013; Sunitha et al. 2013). Predictable results including short term implant success rate and soft tissue outcomes have been confirmed by some studies applying such technique (De Bruyn et al. 2001; Rao et al. 2007; Becker et al. 2009; Rajut et al. 2013; Sunitha et al. 2013). In the clinical setting, when the implant site with limited width of KM, MI surgery seems more useful for preserving adequate quantity of circumferential KM around the emerging implant than punch technique. However, to authors' best knowledge, no randomized clinical trial to evaluate soft tissue response, crestal bone changes and patient subjective assessment between MI surgery and traditional FS in selected and appropriately planned cases has been reported. Furthermore, it would be interesting to investigate the fate of KM applying MI versus FS for single implant placement.

Taking into account the previous results on the effect of flapless placement on peri-implant soft tissue consolidation, the present randomized clinical trial was conducted to test the null hypothesis of no differences in implant survival rates, accuracy of implant position including buccal and lingual bone perforation rates, and soft tissue preservation, but less soft tissue reaction, patient discomfort and crestal bone changes applying MI versus FS.

## **Materials and Methods**

### **Study design**

This study was randomized controlled clinical trial from Dec 2012 to May 2015. The study design and clinical procedures were performed in accordance with Helsinki Declaration, and were approved by the Ethics Committee of Shanghai 9th People's Hospital, China (Approval number: 01504). All patients signed the informed consent form before treatment.

### **Patient selection**

Subjects who lost mandibular first molar at least 3 months of post-extraction healing were selected to

---

participate in the study. CBCT were performed to each subject in order to evaluate bone quantity in implant site before surgery. Entry criteria included the following: absence of uncontrolled or poorly controlled diabetes; periodontal healthy subjects; non-smokers; age over 18 years; agreed to follow-up visits for 2 year; presence of a minimum of 3 mm of KM at the facial aspects in the implant zone; adequate amount of bone for implant placement: minimum crestal bone width of 6 mm and bone architecture without undercuts and, presence of 1 mm of bone bucco-lingual to the planned position in a favorable prosthetic situation from pre-operative CBCT; vertical bone height from bone crest to top of mandibular canal 12 mm or more; a mesio-distal width of 7-10 mm and a minimum vertical distance of 5mm from the crestal mucosa of the potential implant site to the opposing dentition; subjects signed surgical consent forms. Exclusion criteria included the following: subjects with systemic diseases affecting the healing process; radiation to the head and neck; subjects requiring guided bone regeneration; bruxism and/or parafunctional habits; previous implant installation or bone grafting at the surgical site.

#### **Allocation and concealment**

Subjects eligible for this study were assigned to two groups using the random numbers table by an assistant. Subjects were randomly assigned into the two groups: minimal invasive (MI) (20 subjects) or flapped surgery (FS) groups (20 subjects). One skilled and experienced surgeon performed implant placement surgery for all 40 cases. The outcome examiner was kept blinded to the assignment.

#### **Treatment Procedure**

- MI group

Subjects rinsed preoperatively for 60 s with a 0.12% chlorhexidine solution to reduce the total mouth bacterial load. A periodontal probe (Stoma, PCPN22, Tuttlingen, Germany) was used to measure the width of KM from the center of potential implant site to the mucogingival junction at the facial aspects before local anesthesia. Then the surgical field was anesthetized using 2% xylocaine hydrochloride with epinephrine (1:200,000).

Bone mapping was applied to explore and to measure the soft tissue thickness in the potential implant site with a periodontal probe (Stoma, PCPN22, Tuttlingen, Germany). This measurement was recorded and used to determine the appropriate osteotomy depth and implant length. If the planned implant depth as measured from the CBCT was 10 mm and the distance from the mucosal margin to the bone crest was 3

---

mm, the site would be prepared to 13 mm. Then a one point four millimeter round drill was used to make the initial osteotomy, penetrating through the mucosa and into the cortical layer of bone. Standard drilling procedures according to the manufacturer's guideline was followed. ITI dental implant (Institut Straumann AG, Waldenburg, Switzerland) was inserted in site according to bone quantity and quality available. Following one-stage approach, healing cap was inserted into the implant.

- FS group

Pre-operative preparation and the way of local anesthesia were the same as MI group. The width of KM was also measured before local anesthesia. At the implant recipient site of the FS group, a midcrestal incision was made and sulcular incisions were made on the mesial and distal aspects of the adjacent teeth with a No. 15 blade, and a full-thickness flap was elevated. Initial entry was gained with a round bur with 2.3mm diameter. The drills were then used to the required depth and all implants were placed according to the manufacture's instruction. ITI dental implant (Institut Straumann AG, Waldenburg, Switzerland) was inserted in site according to bone quantity and quality available. Healing cap was inserted at the end of the surgical procedure. The flap was interrupted sutured with 4/0 Vicryl (Ethicon Inc., Somerville, New Jersey, USA).

- Post-operative instructions and prosthetic phase

Oral hygiene instructions including 0.12% Chlorhexidine mouth rinses were applied to reduce risk of oral infection. Subjects were prescribed oral antibiotics, Amoxicillin 500mg every 8h for 3 days, an anti-inflammatory and pain reliever drug, Ibuprofen 600mg for 2 days. For FS group, suture removal was performed 2 weeks after implant installation.

After a healing period of 3 months, the implants of both groups were restored with single cemented crown according to manufacturer's instructions.

**Outcome measurements**

The clinical parameters that were evaluated in this study and the time points at which they were measured are shown in Figure 1.

Implant installation position

CBCT was taken at the day of implant installation and was used to identify the position of implants and any potential dehiscence.

---

### Soft tissue healing assessment

At 1, 2, and 4 weeks post-surgery, the implant sites were inspected and gently cleaned with saline-soaked gauze; oral hygiene instruction was repeated. Soft tissue healing was assessed with a wound healing index (WHI) according to the following scheme:

Score 1: uneventful wound healing with no gingival edema, erythema, suppuration, or discomfort;

Score 2: for uneventful wound healing with slight gingival edema, erythema, or discomfort but no suppuration;

Score 3: poor wound healing with significant gingival edema, erythema (Huang et al. 2005).

### Postsurgical visual analog scale (VAS)

At 2 weeks post-surgery, postsurgical pain was measured on a VAS by questioning the patient to evaluate their pain after surgery (Eli et al. 2000). Each subject was given a paper Case Report Form to mark their response on the VAS. The subject marked a 100mm scale with a vertical line directly on the Case Report Form. A measurement was made from the left of the scale to the point of the first marking from the subject.

### Soft tissue outcome

#### 1. Width of KM

The width of KM was measured between the soft tissue margin and the mucogingival junction at the facial aspects of the abutment, the nearest millimeter with a periodontal probe (Stoma, PCPN22, Tuttlingen, Germany) on the day of crown delivery and at 12, 24 months follow-up (Wennström et al. 1994).

#### 2. Modified plaque index (mPI)

Soft tissue parameters including mPI, mSBI were evaluated at 1, 2, and 4 weeks post-surgery and 3, 6, 12 and 24 months post-crown delivery.

MPI was measured at four points around the implants according to the following scale: 0, no plaque; 1, plaque on probing; 2, visible plaque; and 3, abundant plaque. For each implant, one MPI value was calculated based on the average of the four obtained values (Mombelli et al. 1994).

#### 3. Modified sulcus bleeding index (mSBI)

This article is protected by copyright. All rights reserved



---

MSBI was measured at four surfaces around implants. The mSBI was scored as follows: 0 = no bleeding when a periodontal probe was passed along the gingival margin adjacent to the implant, 1 = visible, isolated bleeding spots, 2 = blood formed a confluent red line on the margin, and 3 = heavy or profuse bleeding. For each implant, one mSBI value was calculated based on the average of the four obtained values (Mombelli et al. 1994).

#### 4. Probing depth (PD)

PD was assessed at six locations around the implant for each implant (mesial-buccal, buccal, disto-buccal, mesio-lingual, lingual, and distal-lingual) at 4 weeks post implant insertion surgery, on the day of crown delivery and at 3, 6, 12, and 24 months following intervention. One PD value was calculated based on the average of the six obtained values.

The width of KM, mPI, mSBI and PD were recorded by one experienced clinician using a periodontal probe with a standardized probing force of 0.2 N.

#### 5. Marginal bone loss (MBL)

Periapical radiographs were made on the day after implant insertion, crown delivery and at 3, 12 and 24 months recall. The seating of healing caps for both groups were checked with postoperative periapical radiographs. Interproximal marginal bone level was measured from standardized periapical radiographs that were obtained using a film holder. All of the images were scanned and transferred to a computer with an image analysis program (GE Healthcare Centricity@ v3.0, US). MBL was documented on the radiograph viewer with the aid of four-fold magnification. The radiographic linear distance from the implant shoulder to the first bone-to-implant contact was used to calculate the MBL. The location of the MBL in relation to the implant shoulder was assessed at the mesial and the distal aspects. Radiographic assessments were conducted by two assistants who were blinded to the group allocation.

#### 6. Implant survival

The implant prognostic criteria were previously described by Albrektsson and Zarb (Albrektsson et al. 1986). Briefly, implants were termed “successful” if the following criteria were met: absence of mobility, absence of paresthesia and/or pain, absence of peri-implant pathology or radiographic radiolucencies, and marginal bone loss <1 mm during the first year and <0.2 mm/year in the following years.

### **Data Collection and Statistical Analysis**

Descriptive statistics were applied for continuous data, and nonparametric methods were applied for

---

categorical data and non-normal distributions. Descriptive statistics for continuous data included the mean, standard deviation and the range of values. Descriptive statistics applied to nominal and ordinal variables included the medians and quartiles for each group. For continuous data, such as VAS, PD, MBL, and the width of KM, were analyzed using the t-test for comparison between the two treatment groups at each time point. For mPI and mSBI, the Wilcoxon signed-rank test was performed to compare a given time point with the baseline and the differences between groups at each time point. Analysis was done with PASW Statistics 18.0 (SPSS Inc, Chicago, IL, USA). In all tests, a significance level of 0.05 was chosen.

## Results

### Study data

Forty subjects (14 women and 26 men - 20 in MI and 20 in FS group with a mean of  $39 \pm 13.2$  years old) were included in the study. No subject dropped out during the follow-up period. The difference in age between two groups was not statistically significant. Forty implants were successfully placed in the study population. No statistical significances were found of implant diameter and length between two groups. Table 1 illustrates demographic characteristics.

### Implant installation position

From post-operative CBCT, no implants in neither groups demonstrated any dehiscence or fenestration of the buccal/lingual plate. Three implants in the MI group showed a close distance of one millimeter from implant tip to buccal/lingual plate of bone.

### VAS

The average VAS for the MI and FS groups were  $13.2 \pm 4.3$ mm and  $56.3 \pm 23.4$ mm, respectively indicating a significant difference in pain measurements between the two groups ( $p < 0.01$ ). The number and percentage of subjects who felt no pain (VAS = 0) was higher in MI group than in the FS group (7 subjects (35%) in MI group versus 2 subjects (10%) in FS group). With MI and FS procedure, 3 and 7 subjects took pain release tablets, respectively, 1 day post-surgery.

### Soft tissue outcome

This article is protected by copyright. All rights reserved

---

### 1. WHI

Table 2 depicts the WHI scores for both groups through the study. For MI group, similar WHI was found at each appointment, while for FS group, a trend for a decreased WHI was found at 1, 2 and 4 weeks post-surgery. One week after surgery, 18 subjects in MI group presented score 1 compared to 10 subjects in FS group. The difference of both groups was statistical significance at 1 week follow-up ( $p < .01$ ). Two and 4 weeks following surgery, both groups had similar WHI scores and no statistical significances were detected.

### 2. MPI and mSBI

Table 2 depicts changes in mPI and mSBI for both groups in the first 4 weeks post-surgery. At 2-week post-surgical appointment, there was a trend for a decrease mPI score in FS group, compared to 1-week post-surgery, which had statistical significant differences. By 3 month after crown delivery, FS group had statistically significantly better mPI and mSBI scores compared to 1 week post-surgery and were sustained stable through 24 months.

Meanwhile, for the MI group, there was a decreased mSBI score at 4 weeks appointment, however, no statistically significant differences were found of mPI and mSBI at 1, 2, 4 weeks and the following appointments ( $p > 0.05$ ).

For mPI and mSBI scores, statistically significant differences between two groups were found at 1 and 2 weeks post-surgery ( $p < 0.05$ ).

### 3. KM width

The average KM width of MI group and FS groups were  $4.2 \pm 1.6$ mm (ranging from 3.0mm to 6.2mm) and  $4.5 \pm 1.3$ mm (ranging from 3.2mm to 6.1mm), respectively before treatment (Table 3). At the day of crown delivery, the width of KM decreased to a mean of  $3.7 \pm 1.1$ mm (ranging from 2.7mm to 5.8mm) in MI group and  $4.0 \pm 1.3$ mm (ranging from 3.0mm to 5.8mm) in FS group. Negative values represent gain of KM width. The mean of KM remained stable at 24-month follow-up and no statistical significant difference was found at every follow-up visit in both groups ( $p > 0.05$ ).

### 4. PD

PD values changes for both groups listed in Table 3. PD values at 4 weeks post-surgery was set as baseline measurement. Negative values donate reduction of PD. For MI group, PD was stable, no statistical significant difference was found at every follow-up visit ( $p > 0.05$ ). For FS group, there was mild increased PD on the day of crown delivery compared to 4 weeks post-surgery, however, it

---

demonstrated stable in following visit and no difference was detected ( $p>0.05$ ).

At every follow-up appointment in the study, no statistical significant difference of PD value was found between the two groups ( $p>0.05$ ).

#### Marginal bone loss

The linear distance from the implant shoulder to the first radiographic bone-to-implant contact for MI and FS groups were  $1.2\pm 0.5$ mm and  $1.0\pm 0.6$ mm, respectively after implant placement. Changes of MBL in the subsequent follow-ups are displayed in Table 3. There was a trend for minor bone loss after an early healing and bone remodeling for both groups at the day of crown delivery ( $0.4\pm 0.2$ mm and  $0.3\pm 0.3$ mm for MI and FS groups, respectively). However, no statistically significant difference was found between the two treatment modalities at this time point ( $p>0.05$ ). For both groups, the mean of MBL remained stable at 24-month follow-up and no statistical significant difference was found at every follow-up visit ( $p>0.05$ ).

#### Implant survival rates

No implant was lost in the study. Forty subjects with forty implants fulfilled the success criteria, representing a 2-year cumulative success rate of 100% for both groups.

### **Discussion**

Minimally invasive implant surgery offers advantages over the traditional flap access approach (De Bruyn et al. 2001; Campelo et al. 2002; Rao et al. 2007; Becker et al. 2009; Rajut et al. 2013; Sunitha et al. 2013). For minimally invasive approach, different authors used different drill as the initial bur/drill to perforate the soft tissue. De Bruyn used the drill of diameter 2 mm (De Bruyn et al. 2001); Becker used Prototype precision drills (Nobel Biocare, Yorba Linda, CA, USA) (Becker et al. 2005); Sunitha used a No. 5 round bur and in Jeong et al's canine study, a new drill with a cutting surface on the tip and rounded surfaces on all other sides was used as first pilot drill (Jeong et al. 2012; Sunitha et al. 2013). In our study, a one point four millimeter round drill was used to make the initial osteotomy. It seems the selection of initially drill for dental implant placement in minimally invasive flapless surgery is depending on the implant system utilized and clinician's preference.

---

The subjects in the MI group experienced significantly less pain than the patients allocated in the FS group, which is in agreement with previous studies (Tsoukaki et al. 2003; Fortin et al. 2006; Nkenke et al. 2007; Parmigiani-Izquierdo et al. 2013). In such studies, patients centered outcome especial post-surgery pain was evaluated when multiple implants were placed in partially edentulous or fully edentulous patients. In the present study, only one single implant was placed for patient in both groups and significantly reduced VAS scores in MI procedure were found compared with an open approach. That is to say, even for single implant placement without any additional surgery, which seems little traumatic or even atraumatic from the point of clinician's view, MI technique still has advantage for reducing patient discomfort compared with conventional FS approach.

Animal studies revealed that dental implant placed with flapless approach could improve the formation of a sufficient implanto-epithelial junction and achieved more richly vascularized supracrestal connective tissue (You et al. 2009; Kim et al. 2009; Mueller et al. 2012). Greater mean osseointegration and peri-implant bone height could also be observed 3-month after surgery compared with flaps procedure (Tsoukaki et al. 2003; Jeong et al. 2007; Mueller et al. 2012). The amount of osseointegration and the bone height around the implants with MI and punch approach for implants placement were also compared by Jeong et al with an animal study. No significant differences were noted between the two groups in the vertical alveolar ridge height or in bone/implant contact (Jeong et al. 2012). However, there were limited clinical studies that compared the average MBL occurring with flapped versus flapless implant surgery with conventional loading. De Bruyn et al placed 53 TiUnite Brånemark implants in 59 patients with flap or flapless surgery. At first year follow-up, there was a significant difference in bone loss between flapped and flapless groups. The bone-to-implant contact level was further apical from the reference point in the flapless group (De Bruyn et al. 2001). It was considered that the results probably reflect the fact of overdoing the countersinking procedure. More extensive widening of the crestal bone was necessary to remove enough bone as to allow proper placement of the healing abutment. By countersinking wider and deeper, the coronal portion of the implant was not always in intimate contact with the bone. Then with an early healing period and the establishment of the biological width, more MBL occurred in flapless group. In the flapped sites on the other site, the countersinking procedure was more controlled according to the guidelines of the manufacturer because visual inspection in situ was possible. However, after 1 to 4 years observation, no statistically difference of MBL was demonstrated between both groups ((De Bruyn et al. 2001)).

This article is protected by copyright. All rights reserved

---

Another study conducted by Al-Juboori et al evaluated the effect of initial implant position on the crestal bone level in flap and flapless technique during healing period (Al-Juboori et al. 2013). Twenty-two nonsubmerged implants were placed with the flapless and flap technique with a follow-up of 12 weeks. A positive correlation was found between the initial implant position and the MBL for the flapped group but no correlation was found in flapless group. The authors attributed the results to the rich blood supply to the alveolar bone when the periosteum and blood vessels were preserved from cutting in the flapless group. This rich vascularity provided a good defense mechanism against bacterial invasion (Al-Juboori et al. 2013).

One of disadvantages of flapless surgery as mentioned by De Bruyn was inability to ideally visualize the vertical endpoint of the vertical implant placement (too shallow/too deep) (De Bruyn et al. 2001). In the present study, the linear distance from the implant shoulder to the first radiographic bone-to-implant contact was measured on the day after surgery, which indicated the vertical position of implant placement, and no statistical significant difference was found between the two groups. In other words, the bone-to-implant level was the same in two groups. Although countersinking procedure was performed for both groups in the study according to manufacturer's instruction. It seems for tissue level implant system, because of the wider polished collar design, the possibility of countersinking deeper become decreased. Meanwhile, not as much bone is needed to remove to allow the proper placement of healing abutment as bone level implant. The other consideration might be the appropriate and strict patient selection process. With the help of pre-operative CBCT scanning, patients with narrow alveolar ridge had been excluded from the study, which might make placing implants with flapless approach in an accurate vertical position possible.

The setting of baseline measurements for PD at 4 weeks after surgery was according to a previous study (Becker et al. 2005). In this study, baseline PD and gingival inflammation scores were registered at 4 weeks after implant placement following a similar minimally invasive protocol. They found changes in PD and BOP at baseline. One month after restoration delivery such changes were clinically insignificant. Due to the biological width, complete soft tissue healing and maturation around dental implants takes 6 to 8 weeks (Hämmerle et al 1996). It is speculated that since less trauma and no mucoperiosteal flap evaluation occurs in the MI flapless approach, there might be less soft tissue response and faster soft tissue healing. In the present study, PD was 2.7mm in average in FS group compared to 2.3mm in MI group 4 weeks after surgery, which might be

---

attributed to less swelling after surgery with MI approach. For MBL, no statistically significant difference was found between the two treatment modalities. That is to say, in the study, less soft tissue reaction and inflammation did not seem have positive influence on preservation marginal bone around implant with MI procedure compared to conventional open flap approach in early healing period.

Traditional flapless implant surgery using a soft tissue punch device requires a circumferential excision of KM at the implant site. Resective contouring (gingivectomy) is indicated when the apico-coronal dimension of KM remaining on the buccal flap adjacent to the implant site is 5 to 6 mm. On the contrary, when only 3 to 4 mm of KM width remains on the buccal flap, lateral flap advancement is the indicated surgical maneuver (Sclar 2007). In the present study, the mean KM of MI group was  $4.2 \pm 1.6$  mm in average, after implant placement surgery and prosthetic procedure the KM still remained in a stable width around 3.7 mm. For ITI system, the final drill of 3.5 mm in diameter is regularly used for 4.1 mm implant, that is to say, a soft tissue round hole was created after implant site preparation. Different from punch technique with excision of KM thoroughly, MI approach seemed to have the potential of soft tissue preservation. Therefore, for the patients with limited KM, it might be an alternative to access bone with MI approach. However, large sample size and histological analysis are required to confirm the findings.

A disadvantage of flapless surgery is that the true topography of the underlying available bone cannot be observed because the mucogingival tissues are not raised. This may increase the risk for perforations (i.e. dehiscence or fenestration), which in its turn could lead to complication even, implant failure. CBCT can be undertaken of the patient's jawbone, from which the anatomy can be clearly visualized. –The limitation of this study is that computer guided template was not performed for patients. Although no dehiscence was found in MI group, there were still 3 implants in critical position from postoperative CBCT images. The result can most likely be attributed to the unbalanced resorption of buccal and lingual bone wall after tooth extraction. So when clinician placed flapless implants using neighboring teeth for guiding, skilled and experienced surgeons are recommended and controlling the angulation in a very precisely way is very necessary (Jeong et al. 2011; Sunitha et al. 2013).

## **Conclusion**

With the limitation of this study, compared with FS approach, single implants placed applying the MI technique with preoperative CBCT guide in selected patients has advantages in improving patient

This article is protected by copyright. All rights reserved

---

comfort and decreasing detrimental soft tissue reaction post-implant placement. Implants placed with the MI approach with conventional loading presented similar MBL and high success rates compared to those placed under FS procedure in 2-year follow-up. No excess KM was excised with MI approach and the width of KM remained stable at 2-year follow-up. Large sample size and long term follow-up are required to confirm the findings of this study.

## **Acknowledgements**

This study was supported by the project from School of Medicine, Shanghai Jiao Tong University (14XJ10023), the Combined Engineering and Medical Project of Shanghai Jiao Tong University (YG2014QN01), and the grant from National Nature Science Foundation of China (81371190).

## **Reference**

- Albrektsson, T., Zarb, G., Worthington, P. & Eriksson, A.R. (1986) The long-term efficacy of currently used dental implants: a review and proposed criteria of success. *International Journal of Oral Maxillofacial Implants* **1**:11-25.
- Al-Juboori, M.J., Ab Rahman. S., Hassan, A., Bin Ismail, I.H. & Tawfiq, O.F. (2013) What is the effect of initial implant position on the crestal bone level in flap and flapless technique during healing period? *Jouranal of Periodontal and Implant Science* **43**:153-159.
- Becker, W., Goldstein, M., Becker, B.E. & Sennerby, L. (2005) Minimally invasive flapless implant surgery: a prospective multicenter study. *Clinical Implant Dentistry and Related Research* **7**:S21-S27.
- Becker, W., Goldstein, M., Becker, B.E., Sennerby, L., Kois, D. & Hujuel, P. (2009) Minimally invasive flapless implant placement: follow-up results from a multicenter study. *Journal of Periodontology* **80**:347-52.
- Berglundh, T. & Lindhe, J. (1996) Dimension of the peri-implant mucosa. Biological width revisited. *Journal of Clinical Periodontology* **23**:971-973.
- Brodala, N. (2009) Flapless surgery and its effect on dental implant outcomes. *International Journal of Oral Maxillofacial Implants* **24** Suppl:118-125.
- Campelo, L.D. & Camara, J.R. (2002) Flapless implant surgery: a 10-year clinical retrospective analysis. *International Journal of Oral Maxillofacial Implants* **17**:271-276.
- Casap, N., Tarazi, E., Wexler, A., Sonnenfeld, U. & Lustmann, J. (2005) Intraoperative computerized navigation for flapless implant surgery and immediate loading in the edentulous mandible. *International Journal of Oral Maxillofacial Implants* **20**:92-98.



---

De Bruyn, H., Atashkadeh, M., Cosyn, J. & van de Velde, T. (2011) Clinical Outcome and Bone Preservation of Single TiUnite™ Implants Installed with Flapless or Flap Surgery. *Clinical Implant Dentistry and Related Research* **13**:175-183.

Gobbato, L., Avila-Ortiz, G., Sohrabi, K., Wang, C.W. & Karimbux, N. (2013) The effect of keratinized mucosa width on peri-implant health: a systematic review. *International Journal of Oral Maxillofacial Implants* **28**:1536-1545.

Eli, I., Baht, R., Kozlovsky, A. & Simon, H. (2000) Effect of gender on acute pain prediction and memory in periodontal surgery. *Eureapon Journal of Oral Science* **108**:99–103.

Fortin, T., Bosson, J.L., Isidori, M. & Blanchet, E. (2006) Effect of flapless surgery on pain experienced in implant placement using an image-guided system. *International Journal of Oral Maxillofacial Implants* **21**:298-304.

Hämmerle, C.H., Brägger, U., Bürgin, W. & Lang, N.P. (1996) The effect of subcrestal placement of the polished surface of ITI implants on marginal soft and hard tissues. *Clinical Oral Implants Research* **7**(2): 111-119.

Huang, L.H., Neiva, R.E., Soehren, S.E., Giannobile, W.V. & Wang, H.L. (2005) The effect of platelet-rich plasma on the coronally advanced flap root coverage procedure: a pilot human trial. *Journal of Periodontology* **76**:1768-1777.

Jeong, S.M., Choi, B.H., Li, J., Kim, H.S., Ko, C.Y., Jung, J.H., Lee, H.J., Lee, S.H. & Engelke, W. (2007) Flapless implant surgery: an experimental study. *Oral Surgery Oral Medicine Oral Pathology Oral Radiology and Endodontics* **104**:24-28.

Jeong, S.M., Choi, B.H., Kim, J., Xuan, F., Lee, D.H., Mo, D.Y., & Lee, C.U. (2011) A 1-year prospective clinical study of soft tissue conditions and marginal bone changes around dental implants after flapless implant surgery. *Oral Surgery Oral Medicine Oral Pathology Oral Radiology and Endodontics* **111**:41-46.

Jeong, S.M., Choi, B.H., Xuan, F. & Kim, H.R. (2012) Flapless implant surgery using a mini-incision. *Clinical Implant Dentistry and Related Research* **14**:74-79.

Kim, J.I., Choi, B.H., Li, J., Xuan, F. & Jeong, S.M. (2009) Blood vessels of the peri-implant mucosa: a comparison between flap and flapless procedures. *Oral Surgery Oral Medicine Oral Pathology Oral Radiology and Endodontics* **107**:508-512.

Komiyama, A., Klinge, B. & Hultin, M. (2008) Treatment outcome of immediately loaded implants installed in edentulous jaws following computer-assisted virtual treatment planning and flapless surgery. *Clinical Oral Implants Research* **19**:677-685.

---

Lee, D.H., Choi, B.H., Jeong, S.M., Xuan, F., Kim, H.R. & Mo, D.Y. (2010) Effects of soft tissue punch size on the healing of peri-implant tissue in flapless implant surgery. *Oral Surgery Oral Medicine Oral Pathology Oral Radiology and Endodontics* **109**:525-530.

Lin, G.H., Chan, H.L. & Wang, H.L. (2013) The significance of keratinized mucosa on implant health: a systematic review. *Journal of Periodontology* **84**:1755-1767.

Mombelli, A. & Lang, N.P. (1994) Clinical parameters for the evaluation of dental implants. *Periodontology* 2000 **4**:81-86.

Mueller, C.K., Thorwarth, M., Chen, J. & Schultze-Mosgau, S. A laboratory study comparing the effect of ridge exposure using tissue punch versus mucoperiosteal flap on the formation of the implant-epithelial junction. (2012) *Oral Surgery Oral Medicine Oral Pathology Oral Radiology and Endodontics* **114**:S41-S45.

Nkenke, E., Eitner, S., Radespiel-Tröger, M., Vairaktaris, E., Neukam, F.W. & Fenner, M. (2007) Patient-centred outcomes comparing transmucosal implant placement with an open approach in the maxilla: a prospective, non-randomized pilot study. *Clinical Oral Implants Research* **18**:197-203.

Oh, T.J., Shotwell, J., Billy, E., Byun, H.Y. & Wang, H.L. (2007) Flapless implant surgery in the esthetic region: advantages and precautions. *International Journal of Periodontics Restorative Dentistry* **27**:27-33.

Parmigiani-Izquierdo, J.M., Sánchez-Pérez, A. & Cabaña-Muñoz, M.E. (2013) A pilot study of postoperative pain felt After Two Implant Surgery Techniques: A Randomized Blinded Prospective Clinical Study. *International Journal of Oral Maxillofacial Implants* **28**:1305–1310.

Rajput, N., K, P.S., G, R., S, C.C. & Mohammed, J. (2013) Minimally invasive transmucosal insertion and immediate provisionalization of one-piece implant in partially edentulous posterior mandible. *Journal of Clinical Diagnostic Research* **7**:2070-2073.

Rao, W. & Benzi, R. (2007) Single mandibular first molar implants with flapless guided surgery and immediate function: Preliminary clinical and radiographic results of a prospective study. *Journal of Prosthetic Dentistry* **97**: S3-S14.

Sclar, A.G. (2007) Guidelines for Flapless Surgery. *Journal of Oral Maxillofacial Surgery* **65**:20-32.

Sunitha, R.V. & Sapthagiri, E. (2013) Flapless implant surgery: a 2-year follow-up study of 40 implants. *Oral Surgery Oral Medicine Oral Pathology Oral Radiology and Endodontics* **116**:e237-e243.

You, T.M., Choi, B.H., Li, J., Xuan, F., Jeong, S.M. & Jang, S.O. (2009) Morphogenesis of the peri-implant mucosa: a comparison between flap and flapless procedures in the canine mandible. *Oral Surgery Oral Medicine Oral Pathology Oral Radiology and Endodontics* **107**:66-70.

---

Wennström, J.L., Bengazi, F. & Lekholm, U. (1994) The influence of the masticatory mucosa on the peri-implant soft tissue condition. *Clinical Oral Implants Research* **5**:1-8.

Tsoukaki, M., Kalpidis, C.D., Sakellari, D., Tsalikis, L., Mikrogiorgis, G. & Konstantinidis, A. (2013) Clinical, radiographic, microbiological and immunological outcomes of flapped vs. flapless dental implants: a prospective randomized controlled clinical trial. *Clinical Oral Implants Research* **24**:969–976.

Author Manuscript

Table 1. Patient characteristics in the study

	MI group	FS group
<b>Patient enrolled No.</b>	20	20
<b>Female</b>	6	8
<b>Mean age (range)</b>	40.6 <sup>#</sup> (19-45)	38.3 (20-42)
<b>No. of patient withdraw consent</b>	0	0
<b>Mean implant diameter (range) (mm)</b>	4.34 <sup>#</sup> (4.1-4.8)	4.42 (4.1-4.8)
<b>Mean implant length (range) (mm)</b>	9.2* (8-10)	10.8 (8-12)
<b>No. of implant loss</b>	0	0
<b>No. of patient lost in follow-up</b>	0	0
<b>No. of patient analyzed</b>	20	20

<sup>#</sup> ■ \*p>0.05

Table 2. Clinical soft tissue outcome including mPI, mSBI and WHI indeices in the first 4 weeks

		post-surgery								
Parameters	groups	1 week			2 weeks			4 weeks		
		Mean±SD	Median	Quartiles	Mean±SD	Median	Quartiles	Mean±SD	Median	Quartiles
mPI	MI	0.82±0.32	0.75 <sup>%</sup>	0.25, 1.0	0.74±0.26	0.75 <sup>@</sup>	0.25, 1.0	0.68±0.23	0.75	0.25, 1.0
	FS	1.10±0.53	1.0 <sup>%</sup>	0.5, 1,25	1.00±0.32	1.0 <sup>#@</sup>	0.75, 1,25	0.71±0.24	0.75 <sup>#</sup>	0.25, 1,25
mSBI	MI	1.24±0.43	1.25 <sup>&amp;</sup>	0.5, 1.5	1.08±0.33	1.0 <sup>§</sup>	0.75, 1,25	0.87±0.21	1.0	0.5, 1,25
	FS	1.53±0.48	1.5 <sup>&amp;</sup>	0.75, 2.0	1.23±0.18	1.25 <sup>§</sup>	1.0, 1.5	0.92±0.20	1.0	0.75, 1.5
WHI	MI	1.10±0.04	1.0 <sup>*</sup>	0.75, 1.25	1.05±0.03	1.0	0.75, 1.25	1.00±0.0	1.0	1.0
	FS	1.50±0.10	1.5 <sup>*</sup>	1.25, 1.75	1.15±0.06	1.0	0.75, 1.25	1.00±0.0	1.0	1.0

MI: minimally invasive group; FS: flapless surgery group, <sup>%,\*#@&§</sup> p<0.05

# Author Manuscript

Table 3. PD and MBL measurements at baseline and follow-up visit

		Surgery	4 weeks	Day of	3-month	6-month	12-month	24-month
		day	post-surgery	crown	follow-up	follow-up	follow-up	follow-up
				delivery	(changes)	(changes)	(changes)	(changes)
				(changes)				
<b>Width of KM (mm)</b>	<b>MI</b>	4.2±1.6	-	0.3±0.2	-	-	-0.2±0.06	0.1±0.07
	<b>FS</b>	4.5±1.3	-	0.2±0.1	-	-	0±0.08	0.1±0.05
	<b>p</b>	0.10	-	0.35	-	-	0.14	0.30
<b>PD (mm)</b>	<b>MI</b>	-	2.3±1.0	0.2±0.05	-0.1±0.05	-0.2±0.03	0±0.08	0.1±0.04
	<b>FS</b>	-	2.7±1.2	0.3±0.06	0±0.02	0.1±0.04	0.2±0.04	0.2±0.07
	<b>p</b>	-	0.12	0.23	0.45	0.34	0.53	0.21
<b>MBL (mm)</b>	<b>MI</b>	-	-	-	0.5±0.2	-	0.7±0.3	0.5±0.2
	<b>FS</b>	-	-	-	0.4±0.4	-	0.5±0.4	0.4±0.3

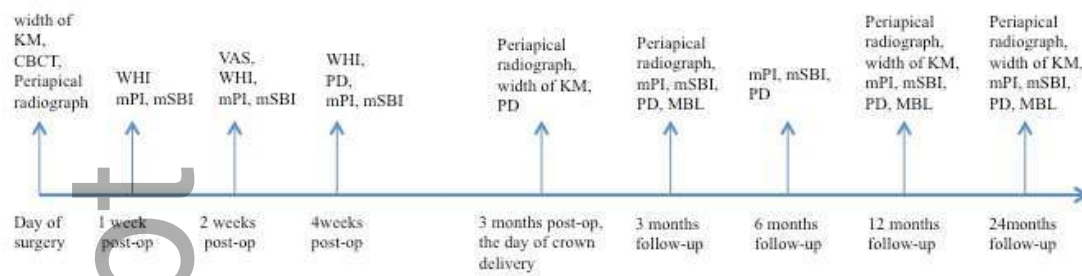


Figure 1. Clinical parameters evaluated and the time points at which they were measured in the study.

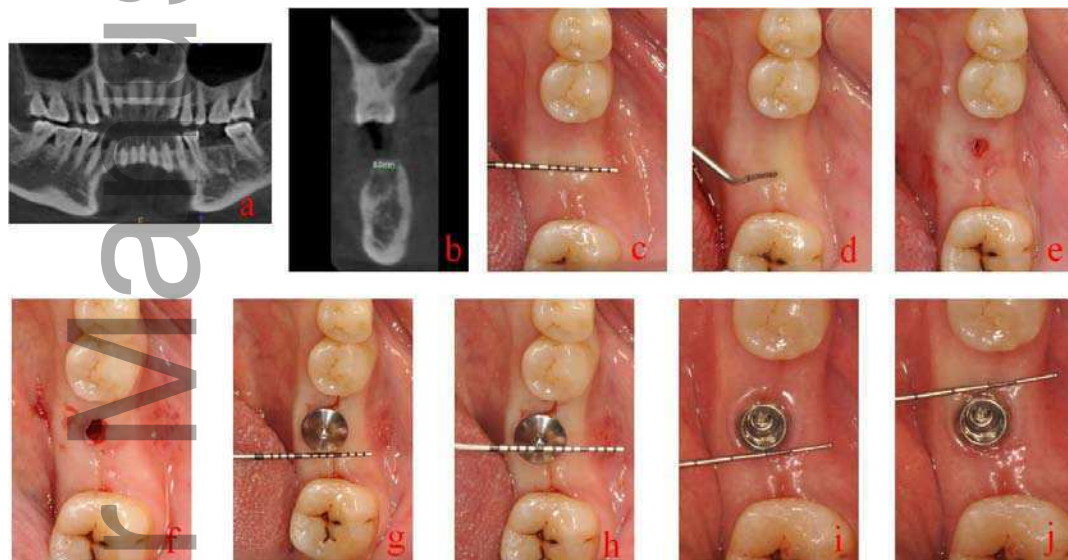


Figure 2. A typical case treated with minimal invasive flapless approach. a: A 35-year female patient with 36 lost for 5 months; b: Pre-operative CBCT determined the entry criteria for the study; c: A minimum of 3 mm of KM in the implant zone was presented; d: Bone mapping was applied to explore and to measure the soft tissue thickness in the potential implant site with a periodontal probe; e: One point four millimeter round drill was used to make the initial osteotomy, penetrating through the mucosa and into the cortical layer of bone; f: Standard drilling procedures according to the manufacturer's guideline was followed; g: Implant was inserted; h: The width of KM was measured after implant placement; i, j: The width of KM was measured between the soft tissue margin and the mucogingival junction at the facial aspects of implant with a periodontal probe on the day of crown delivery.