

## Management of Copper Deficiency in Cholestatic Infants: Review of the Literature and a Case Series

Allison Beck Blackmer, PharmD, BCPS<sup>1</sup>; and Elizabeth Bailey, RD<sup>2</sup>

Nutrition in Clinical Practice  
Volume 28 Number 1  
February 2013 75-86  
© 2012 American Society  
for Parenteral and Enteral Nutrition  
DOI: 10.1177/0884533612461531  
ncp.sagepub.com  
hosted at  
online.sagepub.com



### Abstract

Copper is an essential trace element, playing a critical role in multiple functions in the body. Despite the necessity of adequate copper provision and data supporting the safety of copper administration during cholestasis, it remains common practice to reduce or remove copper in parenteral nutrition (PN) solutions after the development of cholestasis due to historical recommendations supporting this practice. In neonates, specifically premature infants, less is known about required copper intakes to accumulate copper stores and meet increased demands during rapid growth. Pediatric surgical patients are at high risk for hepatic injury during long-term PN provision and a balance is needed between the potential for reduced biliary excretion of copper and adequate copper intakes to prevent deficiency. Copper deficiency has been documented in several pediatric patients with cholestasis when parenteral copper was reduced or removed. Few data guide the management of copper deficiency in the pediatric population. The following case series describes our experience with successfully managing copper deficiency in 3 cholestatic infants after copper had been reduced or removed from their PN. Classic signs of copper deficiency were present, including hypocupremia, anemia, neutropenia, thrombocytopenia, and osteopenia. Treatment included use of both parenteral and enteral copper supplementation. We suggest revision of current recommendations regarding decreasing copper in PN during cholestasis with a proposed algorithm for parenteral copper provision in the setting of cholestasis that is based on evaluation of measured serum copper concentrations. (*Nutr Clin Pract.* 2013;28:75-86)

### Keywords

trace elements; micronutrients; copper; cholestasis; infant; deficiency; parenteral nutrition

Copper is 1 of 10 essential trace elements, acting as a cofactor for several key physiologic enzymes, including lysyl oxidase and elastase (connective tissue synthesis), cytochrome oxidase (electron transport and energy metabolism), monoamine oxidase (oxidative deamination of monoamines), ceruloplasmin (iron metabolism and hemoglobin synthesis), superoxide dismutases (free radical scavenging), and dopamine  $\beta$ -hydroxylase (catalysis of dopamine to norepinephrine).<sup>1-3</sup> Thus, it is critical for several functions in the body, including hematopoiesis, incorporation of iron into hemoglobin, formation of melanin, synthesis of connective tissue, and bone mineralization, as well as immune and metabolic functions.<sup>1,4,5</sup>

During fetal development, copper accretion is approximately 50  $\mu\text{g}/\text{kg}/\text{d}$ , an amount believed to provide the appropriate copper reserve to term infants in the first stages of postnatal life.<sup>5</sup> Babies who are born prematurely will begin life with incomplete copper stores as the majority of copper is accumulated during the third trimester of pregnancy.<sup>6,7</sup> Adequate copper nutrition in the neonatal and early infancy periods, especially in premature, low birth weight infants, is crucial due to the increased demand for copper during the period of rapid growth observed within the first year of life, including skeletal growth and brain development.<sup>6,8</sup>

Published recommended daily requirements for copper are variable across the available literature.<sup>9-11</sup> The World Health Organization recommends a minimum of 60  $\mu\text{g}/\text{kg}/\text{d}$  enterally, with the current recommended daily allowance being 200  $\mu\text{g}/\text{d}$

for term infants.<sup>2</sup> For premature neonates and infants, the amount required to prevent the development of copper deficiency and provide stores equivalent to those accumulated by the term infant is largely unknown. Bioavailability may also be affected by the source of copper and type of salt, age, sex, physiologic effects of pH and digestion, overall composition of the diet, and concomitant administration of other elements, such as zinc and iron.<sup>12</sup> The capacity for absorption of enteral copper is thought to be equally distributed along the small intestine; therefore, individuals with disrupted integrity of the intestinal mucosa may have altered bioavailability of enterally ingested copper. Variations in enteral and parenteral recommended intakes are related to these differences in bioavailability. In those receiving parenteral nutrition (PN), the recommended copper intake is 20  $\mu\text{g}/\text{kg}/\text{d}$ .<sup>5,13,14</sup> However, for enterally fed neonates and infants, recommended daily copper intakes range from 100–150  $\mu\text{g}/\text{kg}/\text{d}$

From <sup>1</sup>Department of Pharmacy Services/College of Pharmacy and

<sup>2</sup>Patient Food and Nutrition Services, University of Michigan, Ann Arbor.

Financial disclosure: none declared.

This article originally appeared online on October 12, 2012.

### Corresponding Author:

Allison B. Blackmer, PharmD, BCPS, Department of Pharmacy Services/  
College of Pharmacy, University of Michigan, 1540 East Hospital Drive,  
Room 10-561B, Ann Arbor, MI 48109, USA.

Email: ablackm@umich.edu.

and 90–120 µg/100 kcal. Human milk contains approximately 0.4–0.6 mg/L of copper in early lactation, compared with 0.2–0.3 mg/L in mature milk.<sup>6,15</sup> Commercial premature formulas contain 120–250 µg/100 kcal; infant formulas contain a minimum of 75 µg/100 kcal.

## Copper Deficiency

Copper deficiency may be caused by prematurity, inadequate copper delivery, malnutrition, malabsorption, and diarrheal diseases.<sup>16</sup> The development of copper deficiency is well described in the literature and classically linked to hypochromic anemia, which is refractory to iron therapy, neutropenia, thrombocytopenia, bone marrow changes, decreased erythropoiesis, low serum ceruloplasmin and copper concentrations, growth retardation and poor weight gain, poor wound healing, the development of osteoporosis, and fractures of the long bones, as well as other vascular tissue anomalies.<sup>2,4,16–28</sup> Neutropenia may be the earliest manifestation of copper deficiency, whereas later effects may be seen in iron absorption and metabolism, resulting in iron deficiency and anemia with inadequate erythropoiesis.<sup>18</sup> Other manifestations of copper deficiency that have been described include loss of hair pigmentation, hypotonia, increased incidence of infection, abnormalities of glucose and cholesterol metabolism, and neurologic dysfunction.<sup>1,6,25</sup>

No single biomarker is sufficient for complete assessment of copper status. The clinical assessment of copper deficiency may include serum copper and ceruloplasmin concentrations, as well as evaluation of other hematologic and clinical parameters, such as complete blood counts (CBCs), bone radiographs, and markers of inflammation.<sup>2,6</sup> Other measures of copper deficiency may include serum concentrations of superoxide dismutase-1, cytochrome c oxidase, and diamine oxidase.<sup>6</sup> In older infants, serum copper concentrations <50 µg/dL or ceruloplasmin concentrations lower than 15 µg/100 mL are considered below normal. Normal values for premature infants are less well defined. It is important to note that institution-specific norms should be used when evaluating laboratory parameters.<sup>2</sup>

## PN, Cholestasis, and Copper Administration

The need for prolonged PN is prevalent among the neonatal and pediatric surgical populations. Although it is necessary for nutrition support, an unfortunate and often inevitable complication of prolonged PN is hepatobiliary dysfunction, leading to increased morbidity and mortality.<sup>29</sup> Approximately 40%–60% of children receiving long-term PN will develop hepatic dysfunction. Histopathological liver changes can be observed within 2 weeks of PN initiation. Cholestasis is typically the first finding and is seen with high frequency in patients with PN-induced liver pathology.

Cholestasis is the accumulation of biliary substances in the blood and tissues due to impaired bile flow.<sup>30</sup> Clinical manifestations in an infant with cholestasis include conjugated hyperbilirubinemia, jaundice, acholic stools, dark urine, and hepatomegaly. Conjugated hyperbilirubinemia can be defined as a direct bilirubin level >1 mg/dL when the total bilirubin is <5 mg/dL, or a direct bilirubin level that exceeds more than 20% of the total bilirubin when the total bilirubin is >5 mg/dL. A more commonly used definition of cholestasis is a direct bilirubin level of >2 mg/dL. Abnormalities in other indicators of liver function, such as serum transaminases, may also be present.<sup>31</sup> The development of cholestasis is multifactorial, with risk factors including prematurity, immaturity of the biliary tract, sepsis, early initiation and prolonged duration of PN, lack of enteral feeds, intestinal stasis, and the need for gastrointestinal surgery.<sup>30,31</sup>

Despite numerous documented cases of copper deficiency and hematologic dysfunction after removal of copper from PN, it remains common practice to reduce or eliminate copper in the PN solutions of patients with cholestasis. As copper is primarily excreted into the intestinal tract through bile, copper excretion is reduced in conditions that reduce bile flow, potentially leading to increased hepatic copper levels.<sup>32</sup> The concern for hepatocellular injury from abnormal accumulation of copper in the liver led to the practice of reducing parenteral copper intake in the setting of cholestasis. High hepatic copper concentrations have been documented in patients with intrahepatic cholestasis of childhood, with liver copper levels similar to that seen in Wilson disease, supporting the notion that impaired biliary excretion may be the most important factor in increased liver concentration in those patients.<sup>33</sup> A study performed by Blaszyk et al<sup>34</sup> also reported elevated hepatic copper levels (>35 µg/g) among 89% of adult patients receiving long-term PN with abnormal serum liver enzyme levels. Higher hepatic copper levels correlated with the degree of cholestasis. However, all control patients diagnosed with drug-induced cholestasis and never receiving PN also had elevated hepatic copper. The authors concluded that PN-induced chronic cholestatic liver disease can lead to elevated hepatic copper levels, but it appeared unlikely that direct copper overload via PN trace elements had occurred.

Although reduction of copper remains common practice, additional data seem to support the safety of copper administration in cholestatic infants. In contrast to the study by Blaszyk et al,<sup>34</sup> an inverse correlation between stainable copper detected in liver tissue and the degree of cholestasis has been described in neonates with a clinical history of receiving PN.<sup>29</sup> In 24 infants studied, no infants with severe cholestasis had stainable copper present, compared with 43% of noncholestatic infants with detectable copper. Analysis of liver histological sections showed that the intracellular copper deposition was lower among neonates with moderate to severe liver changes and longer duration of PN. Thus, these results did not

support the occurrence of copper accumulation in the hepatocytes of infants with severe liver abnormalities, while suggesting a possible protective effect of copper against PN-induced liver damage. A retrospective review of 28 cholestatic infants who received PN containing 20  $\mu\text{g}/\text{kg}/\text{d}$  of copper concluded that continuing the standard dose of copper despite cholestasis does not significantly increase serum copper levels or lead to worsening of liver disease.<sup>7</sup> Elevated serum copper levels only occurred in 2 infants (7%). Results also showed that initial higher copper values did not lead to worsening of liver disease. An additional retrospective review presented similar findings. In 28 cholestatic patients who were younger than 1 year and receiving more than half of their nutrition needs via PN, only 1 elevated serum copper level was found.<sup>35</sup> Thirteen low serum copper levels were found, despite the majority of patients receiving standard doses of copper in their PN, and with a small number of infants requiring higher than standard doses of parenteral copper. The conclusion that cholestasis cannot be used as a predictor of serum copper levels was also supported in an investigation of 54 pediatric patients receiving PN with standard doses of parenteral copper for weight.<sup>36</sup> Of the 20 patients with cholestasis, 7 had elevated copper levels, compared with 8 of 34 noncholestatic subjects ( $P = .9588$ ). However, only 1 subject younger than 6 months had a serum copper level above 100  $\mu\text{g}/\text{dL}$  (normal range cited as 20–70  $\mu\text{g}/\text{dL}$ ). This information seems to best support the practice of continuing the recommended daily dose of 20  $\mu\text{g}/\text{kg}/\text{d}$  of parenteral copper in cholestatic infants, while obtaining a baseline serum copper level and regularly monitoring serum levels before adjusting the copper dose, especially in infants receiving long-term PN. At our institution, we have adopted this practice, adjusting the dose as dictated by serum copper levels and clinical findings, rather than adjusting the dose empirically. This strategy has been successful in preventing the development of copper deficiency.

## Treatment of Copper Deficiency

The recent evidence, as discussed above, suggests continuing standard doses of copper in cholestatic infants on prolonged PN to prevent the development of copper deficiency. However, few data exist to guide the practitioner on the management of acquired copper deficiency, with or without the presence of cholestasis. Several case reports of copper deficiency in the pediatric population have been published, all with varying treatment approaches. Table 1 outlines the treatment methods documented in noncholestatic pediatric patients, highlighting differences in route of administration, copper salt, and dose. Documented cases of copper deficiency in the cholestatic pediatric population also show variable treatment regimens using intravenous (IV) copper. Reported doses range from 20  $\mu\text{g}/\text{kg}/\text{d}$  every other week to 200  $\mu\text{g}/\text{d}$ , as outlined in Table 2.

This paucity of data guiding the management of copper deficiency during infancy, specifically in the setting of PN dependence and significant cholestasis, makes determining a safe

and effective regimen to resolve hypocupremia and its associated clinical findings a difficult task. However, we have gained experience in the treatment of acquired copper deficiency. The following cases describe our experience with successfully managing copper deficiency in 3 cholestatic infants.

## Patient Cases

### Case 1

A 10-week-old male infant, born at 27 weeks' gestation, with a birth weight of 1070 g, was transferred to our institution on day of life (DOL) 72. The patient had a past medical history significant for necrotizing enterocolitis (NEC) requiring small bowel resection and creation of ileostomy and ascending colon mucous fistula. The resection resulted in short bowel syndrome (SBS), with 22 cm of small bowel remaining, and PN dependence with PN-associated cholestasis. Additional medical history included grade III–IV bilateral intraventricular hemorrhage with posthemorrhagic hydrocephalus, status post-placement of ventricular reservoir, chronic lung disease, anemia of prematurity and chronic disease, fungal infection, and intermittent thrombocytopenia. It was also noted that the patient required multiple transfusions of packed red blood cells and platelets.

The patient was started on PN on DOL 1, followed by initiation of small-volume enteral feeds on DOL 5. Enteral feeds were suspended intermittently due to multiple septic episodes and concerning abdominal findings consistent with NEC. Surgical resection was performed on DOL 23, as described above. Enteral feeds were resumed on DOL 42 with a maximum tolerated rate of 4 mL/h. Copper had been removed from his PN for direct hyperbilirubinemia. The date of removal was not documented; however, a direct bilirubin of 3.8 mg/dL was noted on DOL 23. A serum copper level of 55  $\mu\text{g}/\text{dL}$  (reference range, 38–104  $\mu\text{g}/\text{dL}$ ) was noted on DOL 49 at the outside institution.

PN was continued upon transfer, and enteral feeds were provided as protein hydrolysate formula with slow advancement. On DOL 85, enteral feeds were transitioned to free amino acid formula and maintained at approximately 80 mL/kg/d with supplemental PN until the patient underwent exploratory laparotomy, ostomy takedown with primary anastomosis from small bowel to transverse colon, and placement of a gastrostomy tube. Enteral feeds were resumed 18 days after surgery (DOL 111); however, his feeding course was complicated by 2 treatment courses for NEC, necessitating intermittent suspension of enteral feeds. Subsequently, the patient was able to resume enteral feeds and successfully advance to 26 mL/h with free amino acid formula (approximately 50% of daily caloric intake), discharging home on DOL 209 with a combination of enteral feeds and PN.

Upon admission to our institution, despite the known presence of cholestasis, copper was resumed in the PN at 20  $\mu\text{g}/\text{kg}/\text{d}$  due to concern for copper deficiency with prolonged removal from PN. A direct bilirubin level of 6.4 mg/dL (normal

**Table 1.** Copper Deficiency and Treatment in Pediatric Patients.<sup>11,18,20,22,24,26,27</sup>

Patient Description	Copper Provision	Time Until Documented Copper Deficiency (Serum Copper Concentration)	Treatment Dose of Copper	Time to Serum Copper Normalization After Treatment
Marasmic infant <sup>18</sup>	Not reported	Not reported (undetectable)	2.5 mg/d (528 µg/kg/d); route and salt not specified	5 d
10-y-old male patient with 44% third-degree burns and SBS <sup>20</sup>	Provided in PN at RDA for 6 wk, then transitioned to goal enteral feeds	11.5 wk (15 µg/dL; normal: 66 µg/dL)	0.05 mg/d as IV trace mineral supplementation	2 mo
18-y-old male with intestinal fistula <sup>22</sup>	85–113 µg copper/d in PN	27 wk (3 µg/dL)	0.3–1.8 mg/d as IV CuCl <sub>2</sub> -H <sub>2</sub> O	4–6 wk
9-mo-old female with megacystis microcolon, intestinal hypoperistalsis syndrome, and draining jejunostomy; PN dependent <sup>11</sup>	None	9 mo of age (24 µg/dL; normal: 70–130 µg/dL)	410 µg/d IV (50 µg/kg/d)	2–4 wk
6-mo-old former 30-wk gestational age infant <sup>27</sup>	Not reported, but received copper-deficient milk diet	8 mo of age (33 µg/dL; normal: 120–160 µg/dL)	1–3 mg/d as 1% oral copper sulfate solution	38 d
7.5-mo-old female with SBS; PN dependent <sup>24</sup>	None	236 d (9 µg/dL; normal: 85–163 µg/dL)	2.5 mg/d as 0.5% oral copper sulfate solution	Not documented; 77 µg/dL at 30 d
12-y-old female with extensive intestinal resection; PN dependent <sup>26</sup>	None in PN with intermittent oral intake	Approximately 6 mo (32 µg/dL)	5 mg oral copper sulfate (1.25 mg elemental copper) daily	18 d

IV, intravenous; PN, parenteral nutrition; RDA, Recommended Daily Allowances; SBS, short bowel syndrome.

range, 0–0.3 mg/dL) was noted 2 days after admission. An initial CBC showed thrombocytopenia with a platelet count of 103 k/mm<sup>3</sup> (normal range, 150–450 k/mm<sup>3</sup>) and a mildly low hemoglobin at 9.9 g/dL (normal range, 10–14 g/dL). Hematocrit and white blood cell (WBC) count were normal. However, anemia was noted on the fifth day of admission with a hemoglobin of 8.1 g/dL and hematocrit of 24.6% (normal range, 28%–42%), in conjunction with a downward trend in WBC count and platelet count. The patient received 3 blood transfusions and 1 platelet transfusion during his initial month at our facility. His WBC count was noted to be low at 3.4 k/mm<sup>3</sup> (normal range, 6–18 k/mm<sup>3</sup>) 9 days after admission, with a low absolute neutrophil count (ANC) of 0.8 k/mm<sup>3</sup> (normal range, 1.2–8.3 k/mm<sup>3</sup>) documented the following day. Radiographic evidence of diffuse osteopenia was also present.

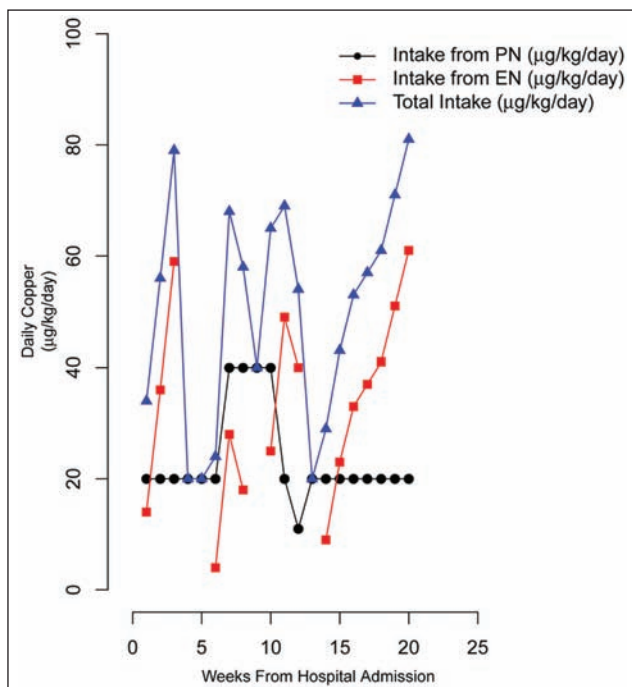
Further blood work confirmed hypocupremia, with a serum copper level of 20 µg/dL (reference range, 70–140 µg/dL) noted 2 weeks after admission (DOL 86). Copper provision was continued at the standard dose in his PN. A repeat serum copper level 1 month later showed a persistently low serum copper concentration of 20 µg/dL. Anemia and thrombocytopenia remained. However, his WBC count was maintained in normal range after receiving the standard dose of copper for 1

month, and no further blood or platelet transfusions were required. Generalized osteopenia was still present, with additional osseous changes noted in the bilateral humeral metaphyses. The parenteral copper dose was increased to 40 µg/kg/d at this time. His platelet count normalized 3 days after increased copper provision and was maintained in normal range until discharge, with the exception of 1 low value during his second bout of NEC. With increased copper provision in the setting of continued cholestasis, a serum copper level was repeated 2 weeks after increasing the copper dose, showing an improved level of 60 µg/dL. The parenteral copper dose was reduced to the standard dose of 20 µg/kg/d approximately 3 weeks later, after resolution of hypocupremia (80 µg/dL) on DOL 133. Only persistent anemia was noted at this time. A final serum copper level, checked 1 month after resuming the standard copper dose, showed maintenance of normal serum copper concentration at 80 µg/dL. Hematologic parameters normalized about 1 month prior to discharge and remained within normal limits at time of discharge. Osteopenia remained throughout admission. The patient was discharged home with 20 µg/kg/d copper in his PN. Figures 1 and 2 depict the copper provision and serum copper levels, as well as hematologic findings, throughout the hospital and treatment course.

**Table 2.** Copper Deficiency and Treatment in PN-Dependent Pediatric Patients With Cholestasis.<sup>4,25</sup>

Patient Description	Copper Withheld in PN	Time Until Documented Copper Deficiency (Serum Copper Level)	Treatment Dose of Parenteral Copper	Time to Serum Copper Normalization After Treatment (Serum Copper Level)
Former 27 <sup>4</sup> / <sub>7</sub> -wk infant with SBS <sup>4</sup>	Yes	7 mo (2 µg/dL)	200 µg/d	6 wk (not reported)
16-y-old male with microvillus inclusion disease <sup>25</sup>	Yes	3 mo (66 µg/dL)	20 µg/kg/d, administered every other week	3 wk (92 µg/dL)
37-wk infant with SBS <sup>25</sup>	Yes	1. 2 mo (12 µg/dL) 2. Not reported (35 µg/dL) Two occurrences of deficiency reported	1. 20 µg/kg/d 2. 10 µg/kg/d	1. 1 mo (99 µg/dL) 2. Resolution not reported
Former 28-wk infant with SBS <sup>25</sup>	No, provided at 10 µg/kg/d	6 wk (30 µg/dL)	20 µg/kg/d, decreased to 20 µg/kg twice weekly after serum copper normalized	Not reported
Former 35-wk infant with SBS <sup>25</sup>	Yes	7 mo (26 µg/dL)	20 µg/kg/d	2 mo (84 µg/dL)

PN, parenteral nutrition; SBS, short bowel syndrome.



**Figure 1.** Provision of daily copper intake: case 1. EN, enteral nutrition; PN, parenteral nutrition.

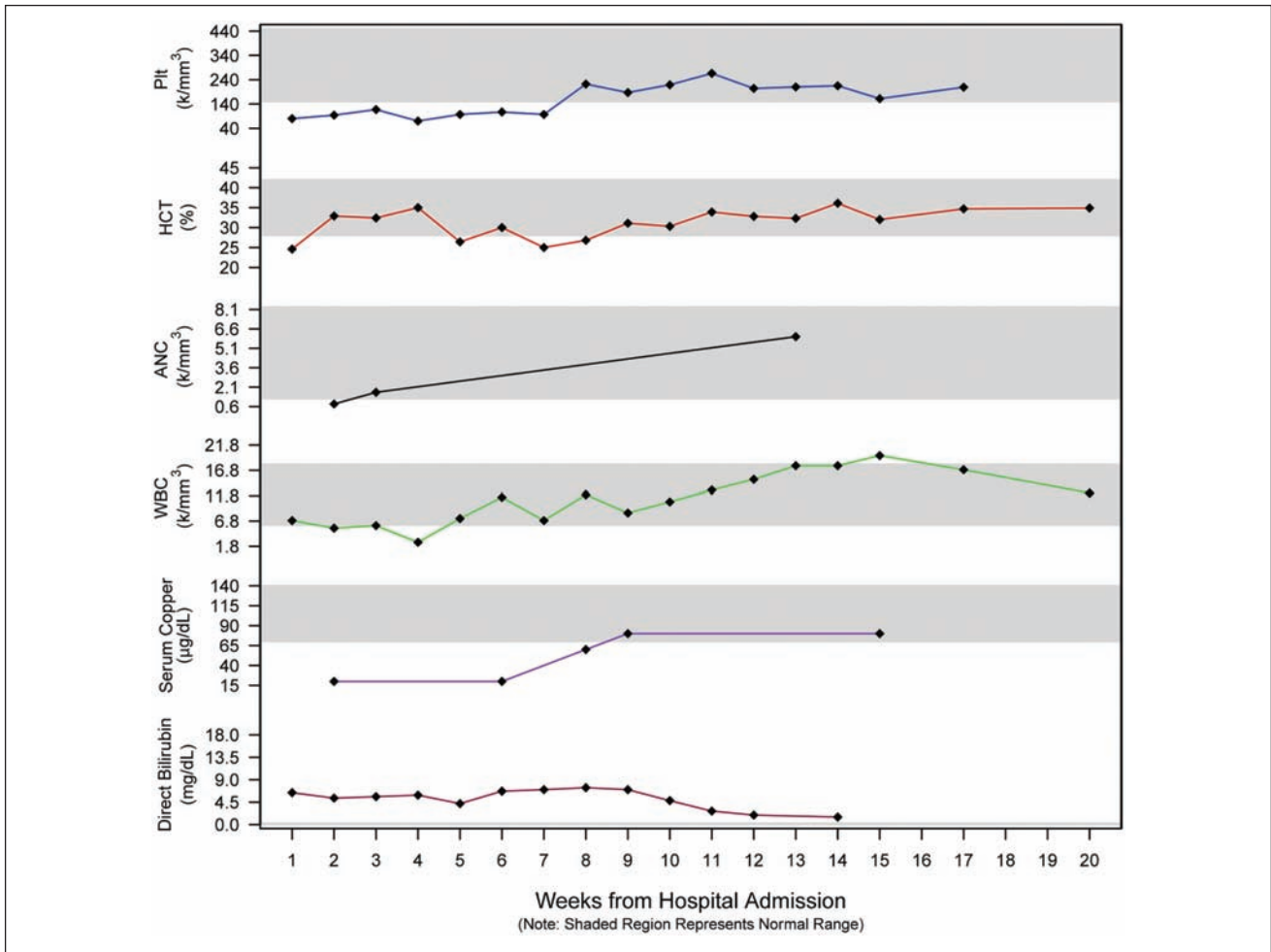
### Case 2

A female infant born at 25<sup>3</sup>/<sub>7</sub> weeks' gestation was transferred to our institution at 12 weeks of life. The patient had a past medical history significant for a surgically ligated

patent ductus arteriosus, chronic lung disease necessitating mechanical ventilation and resulting in ventilator-associated pneumonia, chronic thrombocytopenia, NEC, and PN-associated cholestasis. The baby stoolled spontaneously after medical management of NEC; however, this was followed by an inability to tolerate enteral nutrition (EN), abdominal distension, and worsening respiratory status. Upon transfer to our institution, the patient was receiving all nutrition via PN. At the outside hospital, because of the diagnosis of PN-induced cholestasis, the amount of copper provided in the PN was halved to 10 µg/kg/d at 1 month postnatal age.

Additional workup at our institution included a right upper quadrant ultrasound showing a mildly distended gallbladder, an abdominal radiograph displaying gaseous distension of the small and large bowel, no intraperitoneal gas, pneumatosis or portal venous gas, and a barium enema indicating an area of stricture proximal to the sigmoid colon. Furthermore, evidence of diffuse osteopenia was revealed radiographically. The patient underwent surgical management of the identified colonic stricture 3 days after admission to our institution, with resection of the strictured segment of bowel.

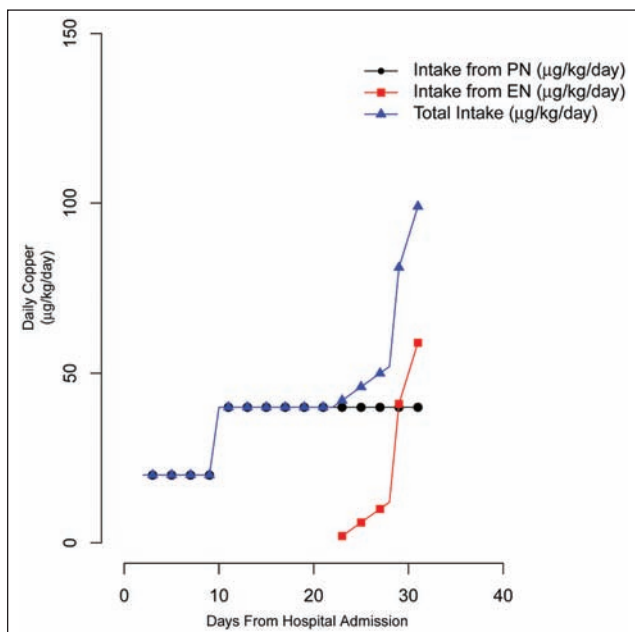
Upon transfer, a CBC revealed a WBC count of 4.8 k/mm<sup>3</sup> (normal range, 6–17 k/mm<sup>3</sup>), hematocrit of 28.2% (normal range, 34%–41%), and a platelet count of 101 k/mm<sup>3</sup> (normal range, 150–400 k/mm<sup>3</sup>). The direct bilirubin was found to be 8 mg/dL (normal range, 0–0.3 mg/dL). Further blood work revealed significant copper deficiency, complicated by persistent neutropenia, anemia, and thrombocytopenia



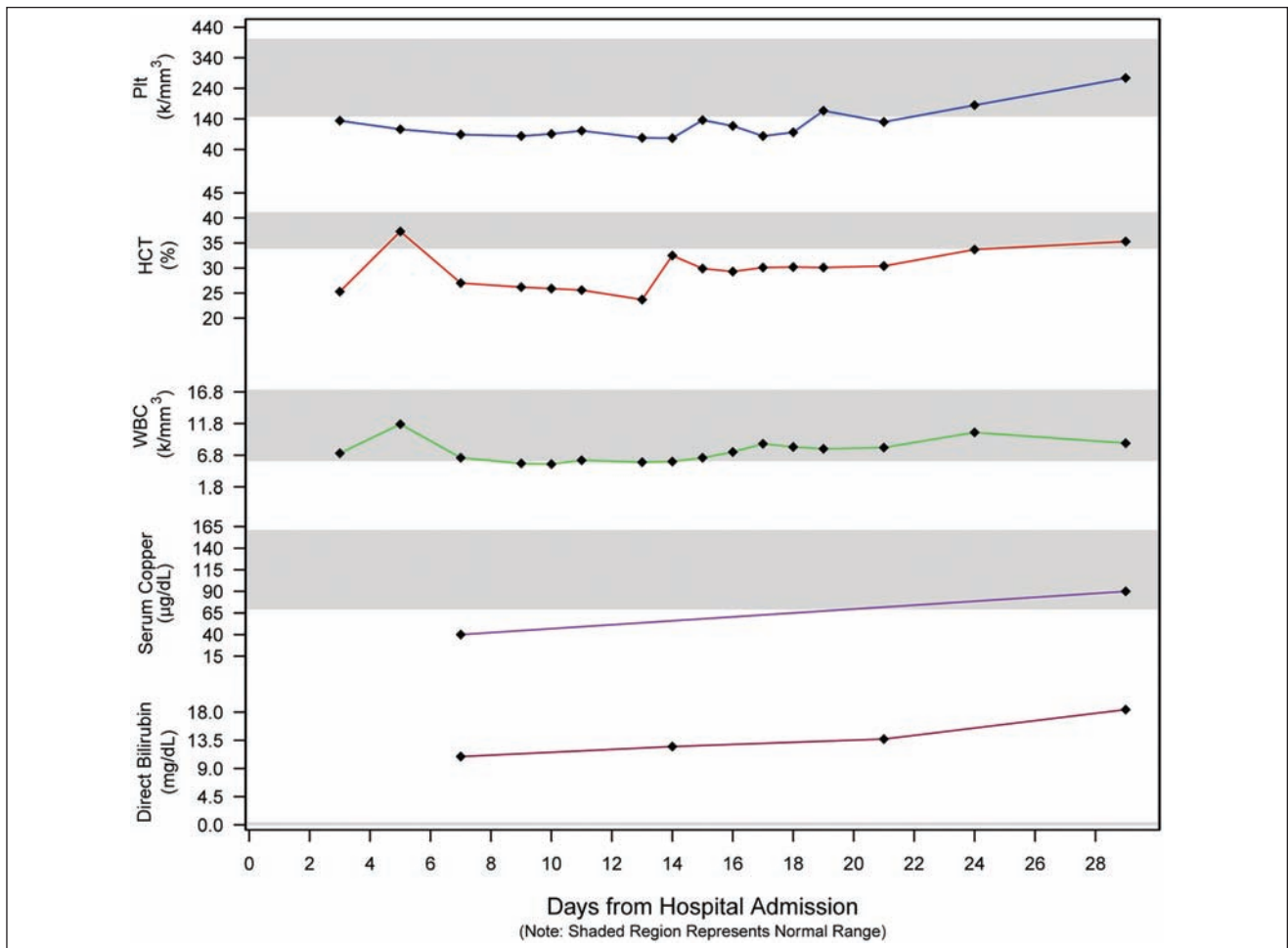
**Figure 2.** Serum direct bilirubin, copper concentrations, and white blood cell (WBC) count, absolute neutrophil count (ANC), hematocrit (HCT), and platelet (Plt) count: case 1.

(unresponsive to transfusions); direct hyperbilirubinemia; and abnormal liver function tests.

The most likely cause for her copper deficiency was deemed to be suboptimal provision of copper in the PN after diagnosis of PN-associated cholestasis. As such, upon admission to our institution, copper replacement was initiated by empirically increasing the copper in the PN to 20 µg/kg/d. After 7 days of therapy at this dose, the serum copper concentration was found to be 40 µg/dL (reference range, 70–160 µg/mL). At that time, the amount of copper in her PN was doubled to a dose of 40 µg/kg/d and continued for 21 days. After 14 days at this dose of 40 µg/kg/d (postoperative day 18), enteral feeds, given as expressed breast milk fortified with human milk fortifier, were initiated and slowly advanced, providing additional enteral copper. Within 9 days of initiation of feeds, the patient was receiving enteral feeds at 10 mL/h, providing approximately 59 µg/kg/d of copper in addition to PN for a total of approximately 100 µg/kg/d of copper. At this time, the serum copper concentration was found to be within the normal range at 90 µg/dL. Furthermore, her neutropenia, anemia, and thrombocytopenia had resolved. She was then transferred from our institution, with the recommendation to



**Figure 3.** Provision of daily copper intake: case 2. EN, enteral nutrition; PN, parenteral nutrition.



**Figure 4.** Serum direct bilirubin, copper concentrations, and white blood cell (WBC) count, absolute neutrophil count (ANC), hematocrit (HCT), and platelet (Pt) count: case 2.

return to the standard parenteral copper dose of 20 µg/kg/d in her PN and to continue to advance enteral feeds to goal. Figures 3 and 4 depict the copper provision and serum copper levels, as well as hematologic findings, throughout the hospital and treatment course.

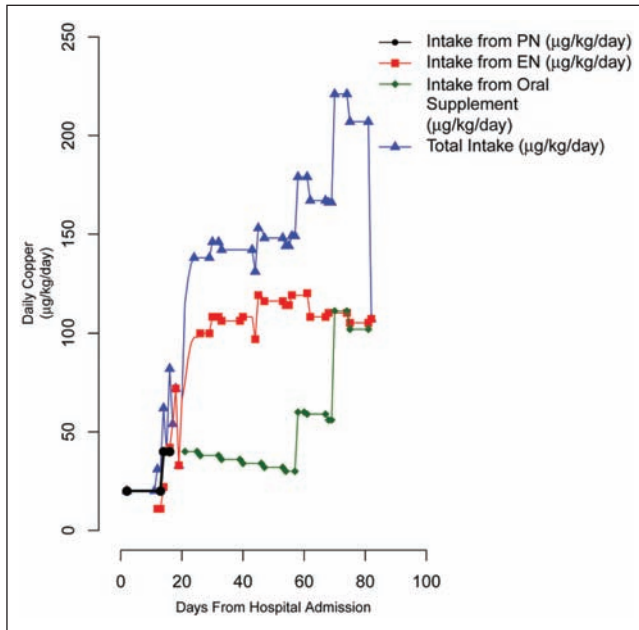
### Case 3

A male infant born at 27 weeks' gestation was transferred to our institution on DOL 55 for management of abdominal distension in the setting of feeding intolerance. The patient had a past medical history of intrauterine growth restriction (birth weight: 586 g), malrotation, microcolon, low ganglion cells and hypertrophic nerves at the splenic flexure, PN-associated cholestasis, and persistent thrombocytopenia. Past surgical history was significant for exploration for a bowel obstruction on DOL 18, which resulted in creation of an ileostomy and mucous fistula. Upon transfer to our institution, nutrition consisted of trophic nasogastric feedings of a protein hydrolysate formula at 2 mL/h with PN. Copper had been completely

removed from the PN because of the diagnosis of PN-induced cholestasis, although the exact date of removal was unknown.

Medical workup at our institution revealed radiographic evidence of bone abnormalities, metaphyseal flaring and ill-definition consistent with rickets and diffuse osteopenia, and bilateral proximal femur and rib fractures. A CBC showed a WBC count of 9.4 k/mm<sup>3</sup> (normal range, 6–17 k/mm<sup>3</sup>), hemoglobin of 10.3 g/dL (normal range, 10–13 g/dL), hematocrit of 30.3% (normal range, 34%–41%), and a platelet count of 48 k/mm<sup>3</sup> (normal range, 150–400 k/mm<sup>3</sup>). Further blood work revealed copper deficiency; persistent thrombocytopenia, anemia, and neutropenia; direct hyperbilirubinemia (19.7 mg/dL; normal range, 0–0.3 mg/dL); and abnormal liver function tests. Because of the severity of the direct hyperbilirubinemia, treatment included the placement of a transhepatic cholecystostomy tube designed to promote the drainage, as well as the flushing, of bile. The patient eventually underwent ostomy takedown and gastrostomy tube placement at 7 months postnatal age.

Persistent pancytopenia in the absence of copper supplementation raised concerns for copper deficiency upon admission



**Figure 5.** Provision of daily copper intake: case 3. EN, enteral nutrition; PN, parenteral nutrition.

to our facility. A copper replacement strategy was initiated by empirically adding back the standard 20 µg/kg/d to the patient's PN. Seven days after admission, a serum copper level was obtained. Five days later, when the result was received, copper deficiency was confirmed with a serum concentration found to be significantly decreased at 30 µg/dL (normal range, 70–160 µg/dL). At that time, the amount of copper in his PN was doubled to 40 µg/kg/d. Simultaneously, the patient was receiving enteral feeds at 2 mL/h, which provided an additional 11 µg/kg/d of copper. The dose of copper in the PN was kept at 40 µg/kg/d for 3 days until the PN was discontinued. Ten days after discontinuation of PN, the patient was found to be persistently hypocupremic (50 µg/dL). His enteral feeds at this point provided approximately 90–100 µg/kg/d of copper. Enteral copper had been initiated 5 days prior, when tolerance of feeds had been established, and was provided as oral copper gluconate at a dose of 0.1 mg elemental copper (40 µg/kg/d). This regimen was continued for 37 days, at which point the patient remained hypocupremic (60 µg/dL), and the dose was increased to 0.2 mg elemental copper (80 µg/kg/d). Twelve days later, the patient continued to be copper deficient, and the dose of oral copper was increased again to 0.4 mg elemental copper (111 µg/kg/d). This was continued for a total of 12 days, until the patient was found to have resolution of hypocupremia. Enteral feedings were slowly advanced to goal over the course of therapy, ultimately providing approximately 110–120 µg/kg/d of copper.

In addition to resolution of hypocupremia, neutropenia, anemia, and thrombocytopenia also resolved. One month after hospital discharge and normalization of serum copper levels,

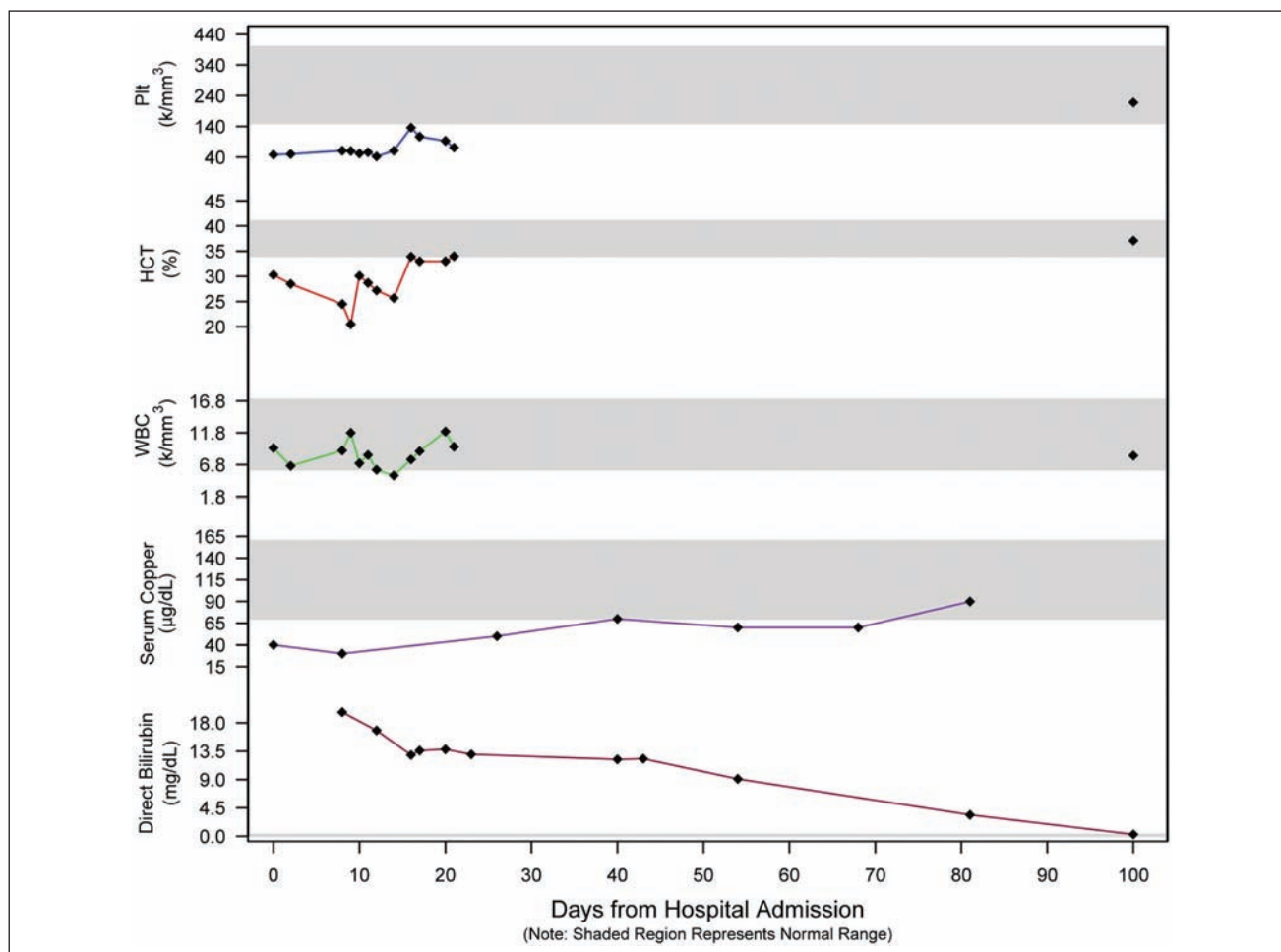
hematologic findings had normalized with a CBC showing a WBC count of 8.2 k/mm<sup>3</sup>, hemoglobin of 13.1 g/dL, hematocrit of 37.1%, and platelet count of 218 k/mm<sup>3</sup>. In addition, radiographs showed evidence of bony changes consistent with treated rickets and healing bilateral rib fractures with callus formation. Figures 5 and 6 depict the copper provision and serum copper levels, as well as hematologic findings, throughout the hospital and treatment course.

## Discussion

Cases of copper deficiency in the pediatric population have been well documented in the literature (Tables 1 and 2). Although copper deficiency is rare among people consuming regular diets and those with normal nutrient absorption, deficiency has been noted more frequently in PN-dependent patients, as first documented by Karpel and Peden in 1972.<sup>11,24</sup> Despite the potential for copper toxicity with reduced biliary excretion of copper, copper deficiency has been documented in patients with cholestasis and was further described in our 3 patient cases.<sup>4,25</sup> As the clinical ramifications of copper deficiency are significant, especially during infancy, it is crucial to understand its risk factors and manifestations to adequately prevent and treat this deficiency.

The development of copper deficiency is often influenced by several risk factors, as seen in the 3 presented cases. An initial risk factor was prematurity. With the majority of fetal copper stores accumulated during the third trimester, our patients were predisposed to copper deficiency as a result of reduced copper stores in the liver.<sup>6</sup> In addition, these premature infants would have had increased copper requirements during periods of rapid growth and for brain development.<sup>6,32</sup> A second risk factor was impaired copper absorption, with our patients at higher risk due to their prematurity and surgical histories. Utilization of copper may be limited in preterm infants; previous studies suggest that absorption and retention of copper can be ineffective in this population, resulting in negative copper balance for several months after birth.<sup>15</sup> Intestinal resection can also lead to varying degrees of malabsorption and feeding difficulties, which may have further predisposed these infants to the development of deficiency. Malabsorption and diarrhea were present in 2 of our infants (case 1 and case 3). A final risk factor was prolonged PN and the development of cholestasis. Several cases of copper deficiency have been noted when copper was not initially provided in PN or was removed after cholestasis developed.<sup>4,11,24-26</sup> Because of differing practices relating to copper provision during cholestasis, our infants were receiving copper-free or reduced copper PN for extended periods of time prior to admission to our institution. This combination of low copper stores at birth, increased copper needs, decreased enteral absorption, and inadequate parenteral copper provision led to persistent copper deficiency and associated clinical manifestations.





**Figure 6.** Serum direct bilirubin, copper concentrations, and white blood cell (WBC) count, absolute neutrophil count (ANC), hematocrit (HCT), and platelet (Plt) count: case 3.

Copper deficiency often leads to classic clinical findings, including abnormal hematologic markers or evidence of osteopenia.<sup>2,4,16-28</sup> These classic signs were demonstrated in our 3 patient cases. Neutropenia, anemia, and thrombocytopenia were noted upon or soon after admission to our institution. Evidence of bone abnormalities and osteopenia was also present in all 3 infants, with 1 infant experiencing multiple bone fractures. It is important to note that one cannot attribute the development of osteopenia in our patients solely to copper deficiency. Prematurity, long-term PN dependency, and, in cases 1 and 3, use of hydrolyzed or elemental enteral formulas that do not adequately meet the calcium and phosphorus needs of premature infants could also have contributed to its development. Nevertheless, the combination of clinical findings and history of reduced copper intakes prompted us to obtain copper levels, leading to documented hypocupremia and the diagnosis of copper deficiency.

Although serum copper and ceruloplasmin concentrations are limited in their use as markers of copper status, they are frequently used when evaluating copper status. Availability

and cost of these markers, as well as their sensitivity to moderate or severe copper deficiency, have led to their common use. Use of serum copper concentration as a marker of deficiency in our patients allowed for comparison to institutional norms, as well as comparison to copper levels in published cases of copper deficiency. However, data on normal ranges for serum copper and ceruloplasmin concentrations are variable, especially in preterm infants.<sup>37</sup> These markers are also not sensitive to marginal deficiency and may increase during periods of inflammation or infection.<sup>6,38</sup> Therefore, these limitations must be taken into account when evaluating the copper status of patients, specifically critically ill or postsurgical patients. Other indicators of copper deficiency have been proposed, but their use remains limited.<sup>6,38</sup> A decrease or change in a single biomarker seems to be inadequate in the assessment of copper status, supporting the use of concomitant clinical findings when evaluating patients for copper deficiency.<sup>38</sup> Thus, we evaluated our patients using serum copper concentrations in conjunction with clinical findings and observed response to therapeutic trials of copper supplementation. The difficulty in

assessing copper status highlights the need for further research to identify the most appropriate biomarker for evaluating copper status, as well as age-related norms.

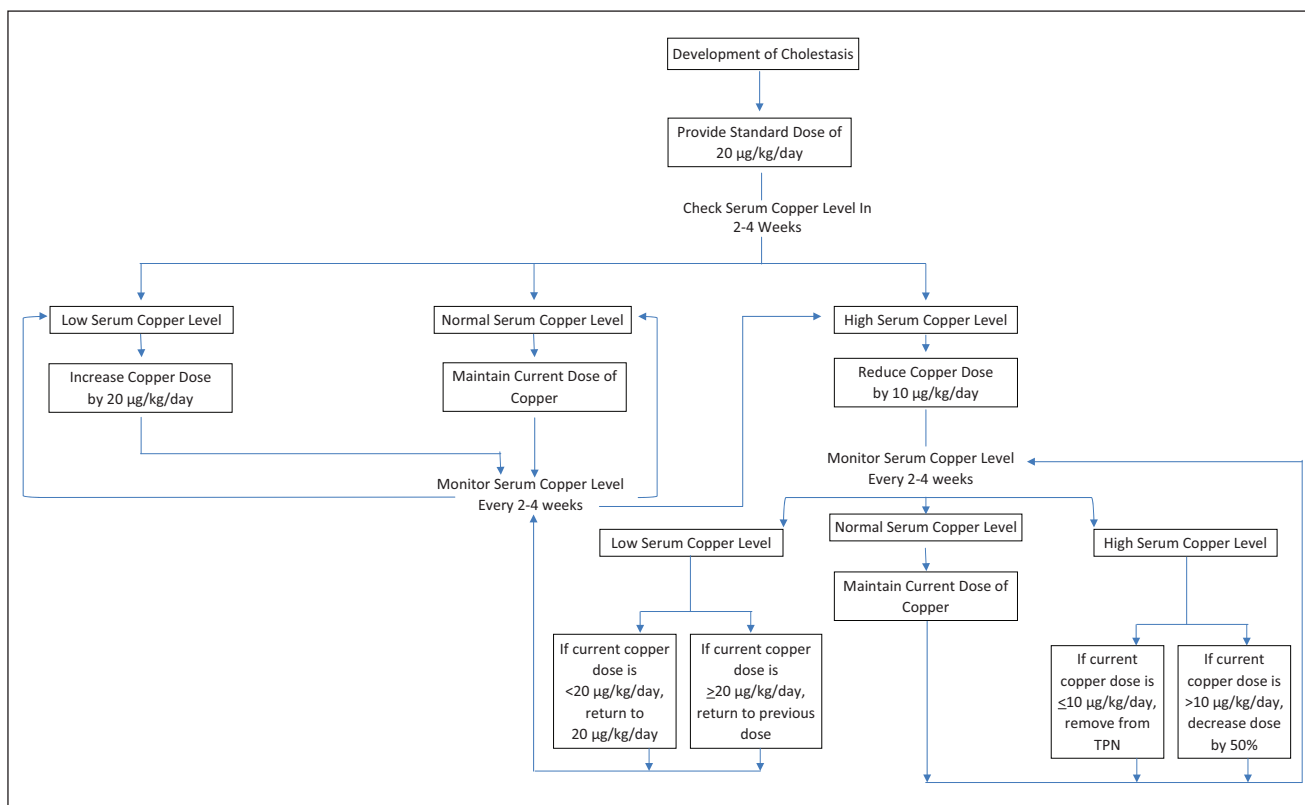
The time frame seen in development of copper deficiency and associated clinical findings is variable in neonates, infants, and children, with variations attributable to differences in enteral absorption, excretion, and total body stores, as well as clinical conditions and copper provision.<sup>19</sup> Cordano<sup>18</sup> reported a peak incidence at 7 to 9 months of age in severely malnourished infants undergoing nutrition rehabilitation. He also noted that additional cases of copper deficiency had been reported in very low birth weight infants, with two-thirds of cases diagnosed by 15 weeks of age, supporting the assessment of copper status early in life and ensuring adequate copper provision in premature infants. An 18-year-old male requiring PN due to an intestinal fistula developed hypocupremia and hematologic abnormalities within 27 weeks of receiving PN, despite provision of copper in PN.<sup>22</sup> Additional reports show deficiency developing at 3 and 6 months of age in infants fed low-copper diets and at 7½ months in an infant with SBS receiving copper-free PN.<sup>24,27</sup> More recent reports of cholestatic infants with copper withheld or provided at reduced doses in PN show a range of 6 weeks to 7 months until deficiency was documented.<sup>4,25</sup> In the cases of our patients, signs of deficiency were present upon admission to our institution, with hypocupremia confirmed within 1–2 weeks. The patients in our 3 cases were approximately 10, 12, and 8 weeks of age, respectively.

There is little published consensus in the literature guiding clinicians on the prevention and treatment of copper deficiency in pediatric patients. Data are even more limited in patients with cholestasis. However, we have reported on our successful experience with treating acquired copper deficiency. With our first case, we adopted a conservative management strategy with frequent monitoring of serum copper levels. Because of a lack of previous experience supplementing additional copper during acquired copper deficiency and concern for the development of toxicity in the setting of cholestasis, the parenteral dose of copper was kept at 20 µg/kg/d for a prolonged period. Despite documented deficiency shortly after admission to our facility, the decision was made to maintain the parenteral dose at 20 µg/kg/d due to the extended period of time that the patient had received copper-free PN. This more conservative approach resulted in an extended treatment course until serum copper normalization and clinical resolution were seen. In our second case, the dose of copper was increased more rapidly. We noted faster resolution of serum copper concentrations, as well as clinical parameters, supporting the safety of more aggressive copper supplementation, even in the setting of severe cholestasis. In addition, we monitored serum copper levels less frequently to avoid iatrogenic anemia and to allow time for serum concentrations to normalize. In our third case, we were able to gain experience using enteral copper. Due to the patient's severe PN-associated cholestasis, limiting PN was paramount, and we opted to advance enteral feeds more rapidly. Since the

period of time to supplement parenteral copper was subsequently diminished, we were more aggressive with our initial parenteral dosing. In transitioning to oral copper supplementation, we were faced with new challenges, specifically appropriate dosing and administration technique. Much like our experience in case 1 with parenteral copper supplementation, we were somewhat conservative in our initial enteral management approach and monitoring of serum copper concentrations. In addition, we encountered difficulties in administering oral copper gluconate. The contents of a 2-mg copper gluconate capsule were emptied and dissolved in 10 mL of sterile water to make a 0.2-mg/mL concentration. This was done at the patient's bedside. Using an oral syringe, the nurse measured the appropriate volume to provide the ordered dose of copper gluconate. The dissolution of copper gluconate may have been incomplete, leading to variability in dosing. Furthermore, oral copper supplements are not rigorously regulated. Therefore, the potential for variation within and between products exists. Finally, oral absorption of copper is variable and unpredictable, especially in the surgical population. In previously published studies, various copper salts were used, with the majority using copper sulfate. However, no standard exists. It appears that the supplemental dose of oral copper is 2.5 times the parenteral copper dose required to overcome deficiencies.

The resolution of copper deficiency, as demonstrated in our cases, appears to occur within 1–3 months, with variations relating to initial severity of copper deficiency, method of copper supplementation, and the dose of supplemental copper. This is consistent with what has previously been published in the literature for both noncholestatic and cholestatic infants.<sup>4,11,18,20,22,24-27</sup> The time to serum copper normalization in cholestatic infants has been reported to take between 3 weeks and 2 months. We believe, however, that resolution of acquired copper deficiency may be accelerated with more aggressive initial parenteral copper supplementation when copper deficiency is diagnosed, as observed in case 2. Once deficiency has resolved, standard doses of copper can be resumed to maintain normal serum concentrations and hematologic parameters.

With historical recommendations to remove copper from PN in patients with cholestasis, pediatric surgical patients represent a population that may be at high risk for copper deficiency due to the high incidence of hepatobiliary disease associated with long-term PN use. In addition, this vulnerable population may receive little or no EN for extended periods of time, limiting the ability to prevent deficits with enteral copper intake. Additional enteric losses can contribute to deficiency, as infants with increased losses may need 10–15 µg/kg/d of copper in addition to the parenteral maintenance dose of 20 µg/kg/d.<sup>11</sup> Other nutrient supplementation that is prevalent in this population, including high doses of zinc and iron, can also interfere with copper metabolism.<sup>12,32</sup> Therefore, if the historical recommendation to remove copper from PN is followed, it seems inevitable that copper deficiency will develop. In the 2004 Safe Practices for Parenteral Nutrition guidelines, the



**Figure 7.** Proposed algorithm for provision of copper in parenteral nutrition in the presence of cholestasis.

American Society for Parenteral and Enteral Nutrition recommends consideration of removing copper from PN in patients with hepatobiliary disease due to impaired clearance.<sup>13</sup> We believe that this recommendation deserves revising, especially in those patients at high risk, supported by the several published accounts of copper deficiency with copper removal during cholestasis, as well as the case series presented here.

Because of the logistical difficulties and the overall observed variability of oral supplementation, coupled with the success observed with parenteral supplementation, we believe that IV copper supplementation should be preferentially used when treating acquired copper deficiency, unless limited by parenteral copper product shortages. We recommend maintaining an initial dose of 20 µg/kg/d of copper in PN despite the development of cholestasis, with monitoring of serum copper levels on a biweekly or monthly basis in patients receiving long-term PN. A proposed algorithm for the provision of copper in PN is displayed in Figure 7. Dose adjustments should be driven by serum copper concentrations, leading to PN modifications that are individualized for each patient, rather than empiric changes. Although we have suggested one approach to maintaining copper homeostasis, further studies are warranted to elucidate the optimal strategy for copper supplementation in the setting of cholestasis.

## Acknowledgments

We are grateful to Daniel Teitelbaum, MD, and Sabina Siddiqui, MD, for their review and input and to Vince Marshall, MS, for his assistance with the design of the graphical display of data.

## References

1. Btaiche IF, Yeh AY, Wu IJ, Khalidi N. Neurologic dysfunction and pancytopenia secondary to acquired copper deficiency following duodenal switch: case report and review of the literature. *Nutr Clin Pract.* 2011;26:583-592.
2. Kleinman R. *Pediatric Nutrition Handbook*. 6th ed. Elk Grove Village, IL: American Academy of Pediatrics; 2009.
3. Shike M. Copper in parenteral nutrition. *Gastroenterology.* 2009;137:S13-S17.
4. Angotti LB, Post GR, Robinson NS, Lewis JA, Hudspeth MP, Lazarchick J. Pancytopenia with myelodysplasia due to copper deficiency. *Pediatr Blood Cancer.* 2008;51:693-695.
5. Zlotkin SH, Atkinson S, Lockitch G. Trace elements in nutrition for premature infants. *Clin Perinatol.* 1995;22:223-240.
6. Olivares M, Araya M, Uauy R. Copper homeostasis in infant nutrition: deficit and excess. *JPEN J Parenter Enteral Nutr.* 2000;31:102-111.
7. Frem J, Sarson Y, Sternberg T, Cole CR. Copper supplementation in parenteral nutrition of cholestatic infants. *JPEN J Parenter Enteral Nutr.* 2010;50:650-654.
8. Castillo-Duran C, Fisberg M, Valenzuela A, Uauy R. Controlled trial of copper supplementation during the recovery from marasmus. *Am J Clin Nutr.* 1983;37:898-903.

9. Araya M, Koletzko B, Uauy R. Copper deficiency and excess in infancy: developing a research agenda. *J Pediatr Gastroenterol Nutr.* 2003;37: 422-429.
10. Higuchi S, Higashi A, Nakamura T, Matsuda I. Nutritional copper deficiency in severely handicapped patients on low copper enteral diet for a prolonged period: estimation of the required dose of dietary copper. *JPEN J Parenter Enteral Nutr.* 1988;7:583-587.
11. Tokuda Y, Yokoyama S, Tsuji M, Sugita T, Tajima T, Mitomi T. Copper deficiency in an infant on prolonged total parenteral nutrition. *JPEN J Parenter Enteral Nutr.* 1986;10:242-244.
12. Wapnir RA. Copper absorption and bioavailability. *Am J Clin Nutr.* 1998;67(suppl):1054S-60S.
13. Mirtallo J, Canada T, Johnson D, et al; Task Force for the Revision of Safe Practices for Parenteral Nutrition. Safe practices for parenteral nutrition. *JPEN J Parenter Enteral Nutr.* 2004;28:S39-S70.
14. Agostoni C, Buonocore G, Carnielli VP, et al. Enteral nutrient supply for preterm infants: commentary from the European Society for Paediatric Gastroenterology, Hepatology, and Nutrition Committee on Nutrition. *J Pediatr Gastroenterol Nutr.* 2010;50:1-9.
15. Lonnerdal B. Copper nutrition during infancy and childhood. *Am J Clin Nutr.* 1998;67(suppl):1046S-1053S.
16. Castillo-Duran C, Cassorla F. Trace minerals in human growth and development. *J Pediatr Endocrinol Metab.* 1999;12:589-601.
17. Shah MD, Shah SR. Nutrient deficiencies in the premature infant. *Pediatr Clin North Am.* 2009;56:1069-1083.
18. Cordano A. Clinical manifestations of nutritional copper deficiency in infants and children. *Am J Clin Nutr.* 1998;67(suppl):1012S-1016S.
19. Fuhrman MP, Herrmann V, Masidonski P, Eby C. Pancytopenia after removal of copper from total parenteral nutrition. *JPEN J Parenter Enteral Nutr.* 2000;24:361-366.
20. Liusuwan RA, Palmieri T, Warden N, Greenhalgh DG. Impaired healing because of copper deficiency in a pediatric burn patient: a case report. *J Trauma.* 2008;65:464-466.
21. Castillo-Duran C, Uauy R. Copper deficiency impairs growth of infants recovering from malnutrition. *Am J Clin Nutr.* 1988;47:710-714.
22. Fujita M, Itakura T, Takagi Y, Okada A. Copper deficiency during total parenteral nutrition: clinical analysis of three cases. *JPEN J Parenter Enteral Nutr.* 1989;13:421-425.
23. Beck JA, Glick N. Copper deficiency anemia and neutropenia in a jejunostomy-fed patient. *PM R.* 2009;1:887-888.
24. Karpel JT, Peden VH. Copper deficiency in long-term parenteral nutrition. *J Pediatr.* 1972;80:32-36.
25. Hurwitz M, Garcia MG, Poole RL, Kerner JA. Copper deficiency during parenteral nutrition: a report of four pediatric cases. *Nutr Clin Pract.* 2004;19:305-308.
26. Dunlap WM, James GW, Hume D. Anemia and neutropenia caused by copper deficiency. *Ann Intern Med.* 1974;80:470-476.
27. Ashkenazi A, Levin S, Djaldetti M, Fishel E, Benvenisti D. The syndrome of neonatal copper deficiency. *Pediatrics.* 1973;52:525-533.
28. Ito Y, Ando T, Nabeshima T. Latent copper deficiency in patients receiving low-copper enteral nutrition for a prolonged period. *JPEN J Parenter Enteral Nutr.* 2005;29:360-366.
29. Zambrano E, El-Hennawy M, Ehrenkranz RA, Zelterman D, Reyes-Mugica M. Total parenteral nutrition induced liver pathology: an autopsy series of 24 newborn cases. *Pediatr Dev Pathol.* 2004;7:425-432.
30. Venigalla S, Gourley GR. Neonatal cholestasis. *Semin Perinatol.* 2004;28:348-355.
31. Guglielmi FW, Regano N, Mazzuoli S, et al. Cholestasis induced by total parenteral nutrition. *Clin Liver Dis.* 2008;12:97-110.
32. Beshgetoor D, Hambidge M. Clinical conditions altering copper metabolism in humans. *Am J Clin Nutr.* 1998;67(suppl):1017S-1021S.
33. Evans J, Newman S, Sherlock S. Liver copper levels in intrahepatic cholestasis of childhood. *Gastroenterology.* 1978;75:875-878.
34. Blaszyk H, Wild PJ, Oliveira A, Kelley DG, Burgart LJ. Hepatic copper in patients receiving long-term total parenteral nutrition. *J Clin Gastroenterol.* 2005;39:318-320.
35. Corkins MR, Martin VA, Szeszycki EE. Copper levels in cholestatic infants on parenteral nutrition. *JPEN J Parenter Enteral Nutr.* In press.
36. McMillan NB, Mulroy C, MacKay MW, McDonald CM, Jackson WD. Correlation of cholestasis with serum copper and whole-blood manganese levels in pediatric patients. *Nutr Clin Pract.* 2008;23:161-165.
37. Giles E, Doyle LW. Copper in extremely low-birthweight or very preterm infants. *NeoReviews.* 2007;8:e159-e164.
38. Milne DB. Copper intake and assessment of copper status. *Am J Clin Nutr.* 1998;67(suppl):1041S-1045S.