

Thromboembolic Prophylaxis Protocol with Warfarin after Radiofrequency

Catheter Ablation of Infarct-Related Ventricular Tachycardia

Konstantinos C. Siontis, MD; Sina Jamé MD; Ghaith Sharaf Dabbagh, MD; Rakesh Latchamsetty, MD; Krit Jongnarangsin, MD; Fred Morady, MD; Frank M. Bogun, MD

From the Division of Cardiovascular Medicine, University of Michigan, Ann Arbor, MI

Correspondence to: Dr. Bogun, Division of Cardiovascular Medicine, Cardiovascular Center, University of Michigan, 1500 East Medical Center Drive SPC 5853, Ann Arbor, Michigan 48109-5853. E-mail: fbogun@med.umich.edu

Disclosures: None

Abstract

Introduction: Ablation in the left ventricle (LV) is associated with a risk of thromboembolism. There are limited data on the use of specific thromboembolic prophylaxis strategies post-ablation. We aimed to evaluate a thromboembolic prophylaxis protocol after ventricular tachycardia (VT) ablation.

Methods and Results: The index procedures of 217 patients undergoing ablation for infarct-related VT with open irrigated-tip catheters were included. Patients with large LV endocardial ablation area (>3 cm between ablation lesions) were started on low-dose, slowly escalating unfractionated heparin (UFH) infusion 8 hours after access hemostasis, followed by 3 months of anticoagulation. Patients with less extensive ablation were treated only with antiplatelet agents post-ablation. Post-ablation bridging anticoagulation was used in 181 (83%) patients. Of them, 11 (6%) patients experienced bleeding events (1 required endovascular intervention) and 1 (0.6%) experienced lower extremity arterial embolism requiring vascular surgery. Systemic anticoagulation was prescribed in 190 (89%) of 214 patients discharged from the hospital (warfarin in 98%), while the rest received single or dual antiplatelet therapy alone. Patients treated with an anticoagulant had significantly longer

This is the author manuscript accepted for publication and has undergone full peer review but has not been through the copyediting, typesetting, pagination and proofreading process, which may lead to differences between this version and the [Version of Record](#). Please cite this article as [doi: 10.1111/jce.13418](https://doi.org/10.1111/jce.13418).

This article is protected by copyright. All rights reserved.

radiofrequency time compared to patients treated with antiplatelet agents only. One (0.5%) of the patients treated with oral anticoagulation experienced major bleeding 2 weeks post-ablation. No thromboembolic events were documented in either the anticoagulation or the “antiplatelet only” group post-discharge.

Conclusion: A slowly escalating bridging regimen of UFH, followed by 3 months of oral anticoagulation is associated with low thromboembolic and bleeding risks after infract-related VT ablation. In the absence of extensive ablation, antiplatelet therapy alone is reasonable.

Keywords: VT ablation; thromboembolic prophylaxis; anticoagulation; antiplatelet therapy; bleeding risk; stroke

Introduction

Catheter ablation of the left-sided cardiac chambers is associated with a risk of thromboembolism, and most of the current knowledge on the incidence, risk factors and prophylaxis strategies is derived from atrial fibrillation (AF) ablation procedures^{1, 2}. In left ventricular (LV) ablations, particularly for ventricular tachycardia (VT), the prolonged radiofrequency (RF) energy application over extensive endocardial areas contributes to an increased thromboembolic risk, which is mitigated by the use of high anticoagulant doses intra-procedurally; however, the thromboembolic risk may persist beyond the intraprocedural period. While clinically overt peri-procedural cerebrovascular events are uncommon, silent embolic events are frequent (more than 50% of patients) as shown by a recent study in which patients underwent brain magnetic resonance imaging (MRI) after LV-RF ablation for ventricular arrhythmias³.

There are very limited data regarding the effectiveness and safety of post-ablation anticoagulation strategies, including bridging and post-discharge anticoagulation. In the multicenter Thermocool VT study, a 3-month course of warfarin was used post-procedurally if ablation had been performed over an area with >3 cm distance between ablation sites, otherwise full-dose aspirin was used⁴. The benefits of anticoagulation, however, need to be weighed against the risks of bleeding in

the immediate post-procedural period and during follow-up. The current study aimed at assessing the feasibility, safety and effectiveness of a thromboembolic prophylaxis protocol in patients undergoing catheter ablation for infarct-related VT.

Methods

Patient population and pre-procedural testing

We included consecutive patients undergoing ablation for infarct-related VT with open irrigated-tip catheters between 2008 and 2015. Patients either had a clinical history of myocardial infarction or evidence of prior infarction on cardiac imaging. All patients had a transthoracic echocardiogram with or without echocardiographic contrast on the day before the procedure for assessment of LV thrombus. A pre-procedural transesophageal echocardiogram was performed in patients presenting with atrial fibrillation (AF) for assessment of left atrial (LA) thrombus and in patients with a history of unexplained stroke for assessment of atheromatous disease in the thoracic aorta. The presence of LA thrombus or mobile, pedunculated LV thrombus was considered a contraindication for the procedure, while chronic laminated LV thrombus was not a contraindication⁵. In cases of a laminated LV thrombus, the procedure was performed if deemed to be urgent and benefits outweighed the risk. The thrombus was identified with intracardiac echocardiography and marked on the electroanatomic map so that catheter manipulation could be avoided in that area. In non-urgent cases, the procedure was performed after 6-8 weeks of therapeutic anticoagulation. The first ablation performed at our institution was considered the index procedure. This retrospective study was approved by the Institutional Review Board of the University of Michigan.

Electrophysiology procedure

After informed consent, arterial and venous femoral access was obtained and multi-electrode catheters were positioned in the high right atrium, the His position and the right ventricular apex. Electroanatomical mapping was performed with open-irrigation ablation catheters (CARTO and Thermocool, Biosense Webster, Inc., Diamond Bar, CA). Multipolar mapping or contact force-

sensing catheters were not used in any of the patients, whereas intracardiac echocardiography was used in all patients. Electrograms were filtered at 50-500 Hz and stored on an optical disc (St Jude Medical, St Paul, MN). In patients that did not present spontaneously in VT, programmed ventricular stimulation was performed with up to 4 extrastimuli from multiple right ventricular locations with coupling intervals down to 200 ms or refractoriness, whichever occurred first. Entrainment mapping was performed for hemodynamically tolerated VT with ablation at sites of concealed entrainment. Ablation during sinus rhythm at sites with matching pace-maps or fragmented electrograms or low voltage electrograms was performed in hemodynamically unstable VT. Cardioversion was performed as needed for patients with hemodynamically unstable VTs that were not promptly pace terminable. At the conclusion of the procedure, programmed ventricular stimulation was repeated from 2 ventricular sites with up to 4 extrastimuli. Procedural success was classified as complete when no sustained monomorphic VT was inducible, partial when only non-clinical VTs were inducible, and failed when clinical VTs were inducible at the end of the procedure.

Anticoagulation protocol

Before the procedure, in patients taking warfarin the medication was discontinued 3-4 days in advance and the INR was allowed to decrease below 1.5 in anticipation of the need for arterial access. Patients with an indication for pre-procedural bridging (AF with recent stroke, recent venous thromboembolism, mechanical mitral or older generation mechanical aortic valve) were admitted before the procedure for bridging with intravenous unfractionated heparin (UFH). Direct oral anticoagulants (DOACs) were stopped 1-2 days before the procedure.

After vascular access, 3000 units of UFH were administered at the beginning of the procedure. If mapping in the LV was necessary, the patient received additional heparin according to a weight-based nomogram to achieve an activated clotting time (ACT) of 250-300 seconds. In cases requiring subxiphoid percutaneous epicardial access for mapping/ablation, anticoagulation was interrupted to allow for epicardial puncture with an ACT <140 sec and it was restarted if additional endocardial mapping/ablation was required. At the conclusion of the procedure, the arterial and

venous sheaths were removed manually when the ACT was <150 seconds. The use of protamine for anticoagulation reversal before sheath removal was at the discretion of the operator.

The protocol of post-ablation anticoagulation is outlined in *Figure 1*. In summary, patients with a large ablation area (>3 cm between ablation sites⁴) or with other indications for bridging anticoagulation were treated with a low-dose, slowly escalating bridging regimen of UFH while transitioned to oral anticoagulation. Warfarin (target INR 2-3) was the preferred oral anticoagulant for an intended course of 3 months. LMWH was avoided for 48 hours after sheath removal. In the absence of bleeding while on UFH, half-dose LMWH could be used after UFH discontinuation on the day of discharge until the INR was within target range in patients who were prescribed warfarin. If a patient was on a DOAC prior to the procedure, this medication was restarted as early as 48 hours after sheath removal provided there was no bleeding complication. In patients without extensive LV endocardial ablation, full-dose aspirin, or clopidogrel plus aspirin were used at the physician's discretion instead of therapeutic anticoagulation.

Data collection and definition of clinical events

Baseline demographics, clinical and procedural characteristics were collected, including the use of protamine at the end of the procedure, the use of bridging anticoagulation in the immediate post-procedural period and the use of post-hospitalization anticoagulation.

Patients were seen in routine clinical follow-up 2-3 months after the procedure, or sooner as indicated. Follow-up was obtained from clinic or emergency room visits, hospital admissions, or by contacting the referring physicians. The first incident thromboembolic (stroke, transient ischemic attack, peripheral arterial embolism) and bleeding events in the 3 months post-ablation were documented (in-hospital and post-discharge). Bleeding events were classified as major if blood transfusion, or endovascular or other surgical intervention was required. We used a 3-month cut-off for event definition because the duration of anticoagulation for the sole indication of VT ablation was a maximum of 3 months. Also, any events beyond 3 months after the procedure are most likely unrelated to the procedure.

Data analysis

Categorical variables are reported as frequencies and percentages, while continuous variables are reported as means \pm standard deviations, or medians and interquartile ranges (IQR) for normally and non-normally distributed variables, respectively. Normality of distribution was assessed by the Shapiro-Wilk test. Categorical baseline characteristics and procedural variables were compared by the Fisher's exact or chi-square testing, as appropriate, for the groups with versus without post-discharge anticoagulation. Group comparisons for continuous variables were performed with two-sided Student's t-test or Wilcoxon rank-sum test as appropriate. P-values are two-tailed and $P < 0.05$ was considered statistically significant. Analyses were performed in Stata 14.2 (StataCorp, College Station, TX).

Results

Baseline characteristics

The baseline characteristics of the study population are shown in *Table 1*. The index procedures of 217 patients were included. Sixty-four (29%) patients had a prior VT ablation procedure at other institutions prior to the index procedure. Twenty-five patients (12%) had a history of stroke or TIA, 91 (42%) had a history of AF and 19 (9%) had a history of LV thrombus. All patients were taking aspirin or other agents (clopidogrel, ticagrelor, or dipyridamole) as single or combination antiplatelet therapy at baseline.

Procedural characteristics

All procedures requiring LV mapping and ablation were performed via a retrograde aortic approach except for 2 procedures that were performed transseptally due to the presence of ascending aortic mural thrombus or large atheromatous plaques. Patients received intraprocedural UFH except for 2 patients with suspected or confirmed heparin-induced thrombocytopenia (HIT) who received argatroban during and after the procedure. All patients underwent endocardial mapping and ablation

(LV n=174, RV n=3, LV+RV n=40), while 4 patients also underwent epicardial mapping/ablation via a percutaneous subxiphoid approach.

The patients had a median of 1 (IQR 1-3) different documented clinical VTs and median of 7 (IQR 4-10) induced VTs. Median RF application time was 82.5 (IQR 42-126) minutes with median total procedure time of 452.5 (IQR 354-558) minutes. Post-ablation, 115 (53%) patients had completely successful procedures (no inducible VT), while 96 (44%) patients had a partially successful or failed procedure. In 3 patients the procedure was complicated by pericardial effusion, 2 of which required emergent pericardiocentesis. Both patients received protamine for reversal of the heparin effect before the pericardiocentesis. In both patients, the drain was removed within 48 hours. Neither of the 2 patients received bridging heparin or warfarin post-procedure. One patient was re-started on aspirin 81 mg daily (long-term medication) 3 days after the procedure and the other patient was re-started on clopidogrel 75 mg daily (long-term medication) 2 weeks after the procedure. Overall, protamine was administered in 18 (8%) cases for anticoagulation reversal prior to sheath removal at the end of the procedure.

Early post-procedural anticoagulation and clinical events

After initial access site hemostasis and before any anticoagulation was initiated, 17 (8%) patients had minor access site bleeding and 3 (1%) had a major access site complication (retroperitoneal bleeding requiring blood transfusion, n=1; femoral artery pseudoaneurysm requiring thrombin injection, n=1; and access site bleeding requiring vascular surgery, n=1). Overall, bridging anticoagulation was used in 181 (83%) patients [UFH in 126 (70%), LMWH in 11 (6%), UFH followed by LMWH in 42 (23%), and argatroban in 2 (1%)], while the remaining 36 (17%) patients did not receive bridging due to limited endocardial LV ablation (n=33) or major periprocedural access site complication (n=3). Among patients receiving bridging anticoagulation, in-hospital bleeding occurred in 11 (6%) patients after a mean of 1.8 days, including minor access site bleeding in 8 patients, major access site bleeding and pseudoaneurysm in 1 patient (requiring thrombin injection), and hematuria in 2 patients with indwelling urinary catheters (both treated conservatively).

One patient (0.6% of those receiving bridging anticoagulation) had a thromboembolic event in the early post-ablation period. This patient had a lower extremity arterial embolism presenting with pain and paresthesias 12 hours after the procedure and required surgical embolectomy and fasciotomies for compartment syndrome with complete clinical recovery. After the embolectomy, the patient remained on UFH infusion for 5 days (target PTT 60-70 seconds) and was then transitioned to warfarin long-term for secondary prevention of arterial thrombosis, along with aspirin 81 mg and clopidogrel 75 mg daily. In this patient, ablation was performed along the inferior and inferoseptal LV over a total area of 31 cm². All RF was performed in the LV endocardium with the exception of one RF application in the RV apex. The patient received protamine for anticoagulation reversal at the end of the procedure due to the presence of a small pericardial effusion. It is unknown if this patient had aortic atheromas as he did not have an indication for pre-ablation TEE and the transthoracic echocardiogram did not visualize the aorta adequately. No definite intracardiac source of embolism was identified by transthoracic echocardiography.

Post-discharge anticoagulation and clinical events

Three (1.4%) patients died during the index hospitalization due to septic shock (n=1) or cardiogenic shock (n=2) at a mean of 11 days post-ablation. Among the 214 patients who were discharged, systemic anticoagulation was prescribed in 190 (89%) patients. In 81 (43%) patients, post-ablation thromboembolic prophylaxis was the sole indication for anticoagulation, whereas 109 (57%) patients had concomitant indications for long-term anticoagulation, most commonly AF (Table 2).

The anticoagulation regimen consisted of warfarin (INR target 2-3) in most patients (n=186, 98%) and one patient was treated with enoxaparin for 2 months due to a history of warfarin intolerance (Figure 2). Among patients receiving warfarin, 53 patients were also prescribed LMWH for bridging anticoagulation at discharge until the INR was therapeutic. Three (1%) patients who were taking DOACs for AF prior to the VT ablation were restarted on the DOAC (dabigatran n=2, rivaroxaban n=1) upon discharge. Among patients on therapeutic anticoagulation, 181 (95%) were

also discharged on one (n=148) or two (n=33) antiplatelet agents. Twenty-four (11%) patients with less extensive LV ablation were treated only with antiplatelet agents, including low-dose aspirin (n=4), full-dose aspirin (n=9), clopidogrel (n=1) and combination of aspirin and clopidogrel (n=10).

Patients who were prescribed systemic anticoagulation had a lower LVEF, higher number of clinical and induced VTs, and longer RF and procedure time compared to patients who were treated only with antiplatelets (*Table 1*).

After hospital discharge, no definite or possible thromboembolic events (stroke, TIA, peripheral embolism) were documented within the first 3 months post-ablation. Within the same period, 1 of the 190 (0.5%) patients who were treated with systemic anticoagulation post-discharge experienced a major bleeding event 2 weeks after the procedure (thigh hematoma in the setting of supratherapeutic INR requiring blood transfusion and correction of the coagulopathy). No bleeding events were documented in the “antiplatelet only” group. Among patients in the anticoagulation group with available 3-month follow-up, there were no instances of premature anticoagulation discontinuation.

Discussion

Main findings

In this study, we report the safety and effectiveness of an anticoagulation protocol for thromboembolic prophylaxis after RF catheter ablation of infarct-related VT. Following standard intraprocedural anticoagulation, patients with a large area of endocardial LV ablation received a low-intensity and slowly escalating UFH infusion that was initiated after adequate vascular access hemostasis was achieved, followed by warfarin as the anticoagulant of choice for 3 months. Patients with limited endocardial ablation were treated only with antiplatelet agents during follow-up. With this approach, we observed a very low risk of post-ablation thromboembolic and bleeding events.

Pathogenesis of thromboembolism after VT ablation

A variety of mechanisms may be implicated in the pathogenesis of thromboembolism during or shortly after RF ablation⁶: pre-formed intracardiac thrombus mobilized by a catheter, de novo coagulum formation on a catheter and at the sites of endocardial tissue damage, heat-denatured albumin microparticle formation, and dislodgement of aortic atheromatous material when a retrograde aortic approach is used. Infarct-related VT ablation procedures are particularly relevant in the study of thromboembolism pathogenesis and prophylaxis. First, patients with a history of CAD and myocardial infarction are more likely to have regional myocardial dysfunction (including LV aneurysms) predisposing to blood stasis and thrombus formation. These patients also frequently have significant aortic atheromas, which can complicate LV access via a retrograde aortic approach, as well as peripheral arterial disease, which can increase the risk of access-related complications with post-procedure anticoagulation. Finally, thrombogenicity may be increased with prolonged, complex procedures and longer radiofrequency time, such as in scar-related VT ablation⁷.

Current approaches for thromboembolic prophylaxis post-ablation

Intraprocedural anticoagulation is universal in LV VT ablations, but there is no established approach for thromboembolic prophylaxis immediately after or in the first few weeks post-ablation and practices vary between centers. In the landmark Multicenter Thermocool VT Ablation Trial, warfarin was used for 3 months if ablation was performed over an area with >3 cm between ablation sites⁴. The subsequent EHRA/HRS Expert Consensus on Catheter Ablation of Ventricular Arrhythmias also recommended a 6-12 week course of warfarin after ablation over large endocardial areas (several square centimeters)⁵. The Consensus Statement also recommended bridging anticoagulation while therapeutic warfarin is being instituted. However, to date there are no comparative studies between different anticoagulation approaches. The study of periprocedural thromboembolic risk factors and prophylaxis strategies remains challenging partly due to the fact that thromboembolism is an infrequent complication of VT ablation. No thromboembolic events were documented in either the pre-approval or in the post-approval Thermocool VT study^{4, 8}. In two other studies of VT ablation in structural heart disease, the reported rates of thromboembolism were 0.8% and 0.5%^{9, 10}, similar to the rate of early post-ablation thromboembolism observed in our study. In an

earlier study of structural VT ablation utilizing an ablation catheter with closed-loop irrigation, the rate of periprocedural cerebrovascular events was higher (2.7%)¹¹, which may be attributable to the increased thrombogenicity of the closed-loop compared to the open irrigation configuration for catheter tip cooling¹². The use of post-procedural anticoagulation in these studies was not specified.

Asymptomatic cerebral embolism

Even though clinically overt thromboembolic events are infrequent after LV ablation, asymptomatic cerebral embolism may be much more common. This phenomenon has been well recognized in LA ablations for AF¹³ and may be associated with adverse neurocognitive effects¹⁴, which highlights the importance of meticulous anticoagulation in ablation procedures of the left-sided cardiac chambers. In a recent study of 18 patients who underwent brain MRI within 1 week after endocardial ablation for ventricular arrhythmias (predominantly premature ventricular complexes), 58% of the patients were found to have a subclinical embolic event after LV ablation. In comparison, no patients undergoing exclusively RV ablation had embolic events³. Similar to the current study, most procedures were done via a retrograde aortic approach. Patients were treated with 81 mg/day of aspirin if an embolic event was found on MRI, but otherwise no standardized approach to post-procedural anticoagulation was used. Whether routine post-procedure bridging anticoagulation can prevent such embolic events is unknown as the timing (intra- or post-procedural) and mechanism of these events are unclear. Also, in that study, contact force-sensing ablation catheters were used while in our cohort only non-contact-force-sensing catheters were used. AF ablation studies have demonstrated a difference in the risk of silent cerebral embolism with different types of catheters¹⁵. Whether such differences exist among the catheters that are currently utilized in LV ablation procedures requires further study.

Bleeding risk

The benefits of anticoagulation should be balanced against the risk of access and non-access site bleeding. The thrombogenic potential may be highest in the early post-ablation period (<48 hours)¹⁶. However, instituting early aggressive anticoagulation may expose the patient to an increased

access-related bleeding risk. Therefore, a low-dose, slowly escalating, no-bolus regimen of UFH starting a few hours after access hemostasis allows for the introduction of anticoagulation while monitoring for bleeding complications. A benefit of using UFH is the easy reversibility of its effect by discontinuing the infusion and by administration of protamine in case of bleeding. On the other hand, LMWH is an effective and convenient anticoagulant, but it has been avoided early post-procedure (<48 hours) at our institution due to the risk of access site bleeding from femoral arterial access with large bore sheaths. In some patients with low bleeding risk who tolerated the low-dose UFH infusion, LMWH was used as a bridge to therapeutic warfarin in order to expedite discharge from the hospital. Similarly, the rapid onset of action and limited reversal options of DOACs may limit their use after VT ablation with arterial access. However, DOACs may be a reasonable alternative for anticoagulation in patients with low bleeding risk, especially if only venous access is used. An ongoing study is currently investigating the use of apixaban after scar-related VT ablation (NCT02666742).

Limitations

In this study, the majority of patients underwent extensive LV ablation, thus the number of patients treated only with antiplatelet agents was small. In addition, thromboembolic and bleeding events were infrequent, thus the comparative effects of therapeutic anticoagulation versus only antiplatelet therapy cannot be addressed adequately. Larger sample sizes are required to achieve sufficient statistical power. We also did not have a control group in whom a different thromboembolic prophylaxis protocol was utilized.

Conclusion

After infarct-related VT ablation involving extended areas of the LV endocardium, a low-dose, slowly escalating regimen of UFH for bridging anticoagulation, followed by 3 months of therapeutic anticoagulation is associated with low thromboembolic and bleeding risks. In patients without extensive endocardial ablation, antiplatelet therapy alone appears reasonable. The comparative

effectiveness and safety of different thromboembolic prophylaxis approaches, as well as the role of direct oral anticoagulants after VT ablation require further investigation.

References

- [1] Oral H, Chugh A, Ozaydin M, Good E, Fortino J, Sankaran S, Reich S, Igie P, Elmouchi D, Tschopp D, Wimmer A, Dey S, Crawford T, Pelosi F, Jongnarangsin K, Bogun F, Morady F: Risk of thromboembolic events after percutaneous left atrial radiofrequency ablation of atrial fibrillation. *Circulation* 2006; 114:759-765.
- [2] Cappato R, Calkins H, Chen SA, Davies W, Iesaka Y, Kalman J, Kim YH, Klein G, Natale A, Packer D, Skanes A, Ambrogi F, Biganzoli E: Updated worldwide survey on the methods, efficacy, and safety of catheter ablation for human atrial fibrillation. *Circ Arrhythm Electrophysiol* 2010; 3:32-38.
- [3] Whitman IR, Gladstone RA, Badhwar N, Hsia HH, Lee BK, Josephson SA, Meisel KM, Dillon WP, Hess CP, Gerstenfeld EP, Marcus GM: Brain Emboli After Left Ventricular Endocardial Ablation. *Circulation* 2017; 135:867-877.
- [4] Stevenson WG, Wilber DJ, Natale A, Jackman WM, Marchlinski FE, Talbert T, Gonzalez MD, Worley SJ, Daoud EG, Hwang C, Schuger C, Bump TE, Jazayeri M, Tomassoni GF, Kopelman HA, Soejima K, Nakagawa H, Investigators MTVAT: Irrigated radiofrequency catheter ablation guided by electroanatomic mapping for recurrent ventricular tachycardia after myocardial infarction: the multicenter thermocool ventricular tachycardia ablation trial. *Circulation* 2008; 118:2773-2782.
- [5] Aliot EM, Stevenson WG, Almendral-Garrote JM, Bogun F, Calkins CH, Delacretaz E, Della Bella P, Hindricks G, Jaïs P, Josephson ME, Kautzner J, Kay GN, Kuck KH, Lerman BB, Marchlinski F, Reddy V, Schalij MJ, Schilling R, Soejima K, Wilber D, (EHRA) EHRA, (ESC) RBotESoC, (HRS) HRS, (ACC) ACoC, (AHA) AHA: EHRA/HRS Expert Consensus on Catheter Ablation of Ventricular Arrhythmias: developed in a partnership with the European Heart Rhythm Association (EHRA), a Registered Branch of the European Society of Cardiology (ESC), and the Heart Rhythm Society (HRS); in collaboration with the American College of Cardiology (ACC) and the American Heart Association (AHA). *Heart Rhythm* 2009; 6:886-933.
- [6] Haines DE, Stewart MT, Barka ND, Kirchhof N, Lenz LR, Reinking NM, Urban JF, Halimi F, Deneke T, Kanal E: Microembolism and catheter ablation II: effects of cerebral microemboli injection in a canine model. *Circ Arrhythm Electrophysiol* 2013; 6:23-30.
- [7] Lee DS, Dorian P, Downar E, Burns M, Yeo EL, Gold WL, Paquette M, Lau W, Newman DM: Thrombogenicity of radiofrequency ablation procedures: what factors influence thrombin generation? *Europace* 2001; 3:195-200.
- [8] Marchlinski FE, Haffajee CI, Beshai JF, Dickfeld TM, Gonzalez MD, Hsia HH, Schuger CD, Beckman KJ, Bogun FM, Pollak SJ, Bhandari AK: Long-Term Success of Irrigated Radiofrequency Catheter Ablation of Sustained Ventricular Tachycardia: Post-Approval THERMOCOOL VT Trial. *J Am Coll Cardiol* 2016; 67:674-683.
- [9] Bohnen M, Stevenson WG, Tedrow UB, Michaud GF, John RM, Epstein LM, Albert CM, Koplan BA: Incidence and predictors of major complications from contemporary catheter ablation to treat cardiac arrhythmias. *Heart Rhythm* 2011; 8:1661-1666.
- [10] Santangeli P, Frankel DS, Tung R, Vaseghi M, Sauer WH, Tzou WS, Mathuria N, Nakahara S, Dickfeldt TM, Lakkireddy D, Bunch TJ, Di Biase L, Natale A, Tholakanahalli V, Tedrow UB, Kumar S, Stevenson WG, Della Bella P, Shivkumar K, Marchlinski FE, Callans DJ, Group IVACC: Early Mortality After Catheter Ablation of Ventricular Tachycardia in Patients With Structural Heart Disease. *J Am Coll Cardiol* 2017; 69:2105-2115.
- [11] Calkins H, Epstein A, Packer D, Arria AM, Hummel J, Gilligan DM, Trusso J, Carlson M, Luceri R, Kopelman H, Wilber D, Wharton JM, Stevenson W: Catheter ablation of ventricular tachycardia in patients with structural heart disease using cooled radiofrequency energy: results of a prospective multicenter study. Cooled RF Multi Center Investigators Group. *J Am Coll Cardiol* 2000; 35:1905-1914.

- [12] Yokoyama K, Nakagawa H, Wittkampf FH, Pitha JV, Lazzara R, Jackman WM: Comparison of electrode cooling between internal and open irrigation in radiofrequency ablation lesion depth and incidence of thrombus and steam pop. *Circulation* 2006; 113:11-19.
- [13] Gaita F, Caponi D, Pianelli M, Scaglione M, Toso E, Cesarani F, Boffano C, Gandini G, Valentini MC, De Ponti R, Halimi F, Leclercq JF: Radiofrequency catheter ablation of atrial fibrillation: a cause of silent thromboembolism? Magnetic resonance imaging assessment of cerebral thromboembolism in patients undergoing ablation of atrial fibrillation. *Circulation* 2010; 122:1667-1673.
- [14] Medi C, Evered L, Silbert B, Teh A, Halloran K, Morton J, Kistler P, Kalman J: Subtle post-procedural cognitive dysfunction after atrial fibrillation ablation. *J Am Coll Cardiol* 2013; 62:531-539.
- [15] Herrera-Siklody C, Deneke T, Hocini M, Lehrmann H, Shin DI, Miyazaki S, Henschke S, Fluegel P, Schiebeling-Romer J, Bansmann PM, Bourdias T, Dousset V, Haissaguerre M, Arentz T: Incidence of asymptomatic intracranial embolic events after pulmonary vein isolation: comparison of different atrial fibrillation ablation technologies in a multicenter study. *J Am Coll Cardiol* 2011; 58:681-688.
- [16] Manolis AS, Melita-Manolis H, Vassilikos V, Maounis T, Chiladakis J, Christopoulou-Cokkinou V, Cokkinos DV: Thrombogenicity of radiofrequency lesions: results with serial D-dimer determinations. *J Am Coll Cardiol* 1996; 28:1257-1261.

Table 1. Clinical and Procedural Characteristics in the Overall Population and in Patients With and Without Systemic Anticoagulation at Discharge

Variable	Overall (n=217)	Anticoagulation (n=190)*	No anticoagulation (n=24)*	P- value
Age, yrs (mean±SD)	67.8 (9.1)	67.7 (8.9)	68.3 (10.9)	0.73
Male, n (%)	199 (92)	176 (93)	20 (83)	0.15
LVEF, median (IQR)	27 (20- 40)	25 (20-35)	40 (28-55)	<0.001
Hypertension, n (%)	167 (77)	146 (77)	18 (75)	0.88
Dyslipidemia, n (%)	178 (82)	157 (83)	18 (75)	0.36
Diabetes, n (%)	69 (32)	58 (31)	10 (42)	0.26
Atrial fibrillation, n (%)	91 (42)	80 (42)	9 (38)	0.68
Stroke or TIA, n (%)	25 (12)	22 (12)	3 (13)	0.89
Peripheral vascular disease, n (%)	33 (15)	33 (17)	0 (0)	0.03
Chronic renal failure, n (%)	42 (19)	38 (20)	3 (13)	0.39
Prior ablation, n (%)	64 (29)	58 (31)	6 (25)	0.59
ICD shock within prior 3 months, n (%)	185 (85)	165 (87)	17 (71)	0.04

Prior VT storm, n (%)	66 (30)	60 (32)	6 (25)	0.52
Number of clinical VTs, median (IQR)	1 (1-3)	1 (1-3)	1 (1-1)	0.03
Number of induced VTs, median (IQR)	7 (4-10)	7 (5-11)	3 (1.5-6)	<0.001
Procedure time (min), median (IQR)	452.5 (354- 558)	460 (380-566)	337 (222-414)	0.001
RF time (min), median (IQR)	82.5 (42- 126)	90.5 (52-140)	15 (7-35)	<0.001
Complete or partial success, n (%)	204 (94)	183 (96)	18 (75)	0.01
Protamine use, n (%)	18 (8)	13 (7)	4 (17)	0.12

*Among patients who were discharged alive (3 patients died in-hospital)

Abbreviations: LVEF, left ventricular ejection fraction; SD, standard deviation; IQR, interquartile range; TIA, transient ischemic attack; ICD, implantable cardioverter defibrillator; VT, ventricular tachycardia; RF, radiofrequency

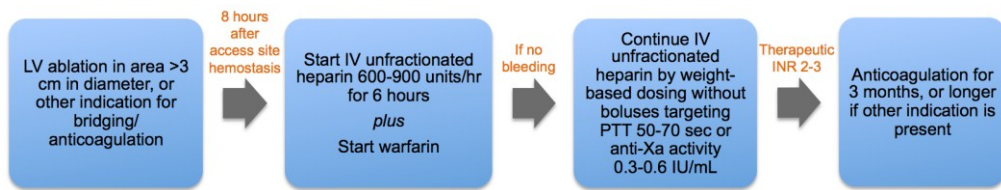
Table 2. Indications for Anticoagulation Post-ablation

Anticoagulation indication	N = 190 patients discharged on an anticoagulant
LV ablation (as the sole indication)	81 (43)
Atrial fibrillation	90 (47)
LV thrombus	12 (6)
LV aneurysm	2 (1)
Mechanical valve	2 (1)
LV assist device	2 (1)
DVT/PE	5 (3)

Abbreviations: LV, left ventricle; DVT, deep vein thrombosis; PE, pulmonary embolism

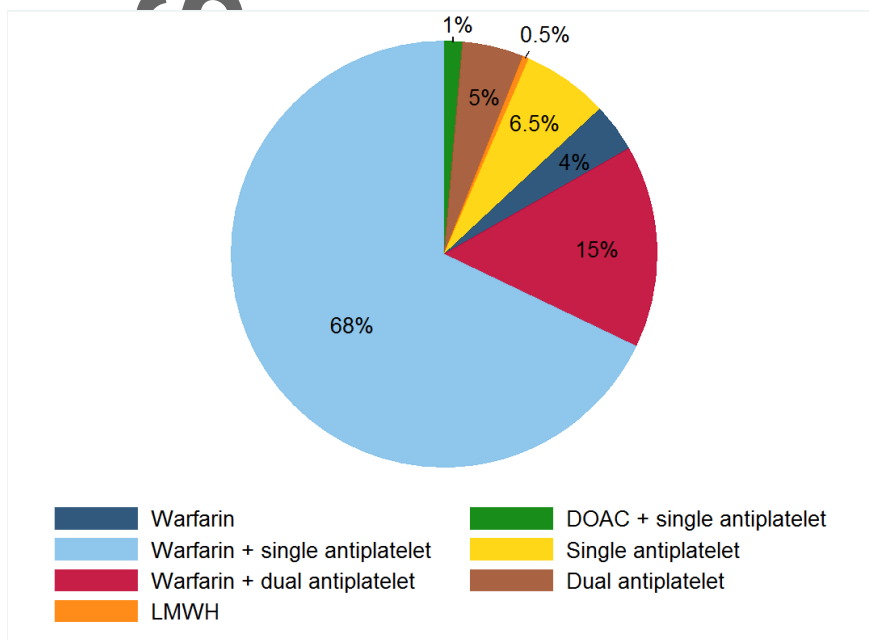
FIGURE LEGENDS

Figure 1. Post-Ablation Anticoagulation Protocol.



Abbreviations: LV, left ventricle; PTT, partial thromboplastin time; INR, international normalized ratio

Figure 2. Anticoagulant and Antiplatelet Agents Utilized Post-Discharge.



Note: Among patients receiving warfarin (n=186), 53 (28%) patients were also prescribed LMWH for bridging anticoagulation at discharge until the INR was therapeutic. These patients are not depicted separately in this figure.

Abbreviations: LMWH, low molecular weight heparin; DOAC, direct oral anticoagulant