

## Genotype-phenotype correlations in individuals with pathogenic *RERE* variants

Valerie K. Jordan,<sup>1</sup> Briana Fregeau,<sup>2</sup> Xiaoyan Ge,<sup>3,4</sup> Jessica Giordano,<sup>5</sup> Ronald J. Wapner,<sup>5</sup> Tugce B. Balci,<sup>6</sup> Melissa T. Carter,<sup>6</sup> John A. Bernat,<sup>7</sup> Amanda N. Moccia,<sup>8</sup> Anshika Srivastava,<sup>8</sup> Donna M. Martin,<sup>8,9</sup> Stephanie L. Bielas,<sup>8</sup> John Pappas,<sup>10</sup> Melissa D. Svoboda,<sup>11</sup> Marlène Rio,<sup>12,13</sup> Nathalie Boddaert,<sup>12,14</sup> Vincent Cantagrel,<sup>12,15</sup> Andrea M. Lewis,<sup>3,16</sup> Fernando Scaglia,<sup>3,16</sup> Undiagnosed Diseases Network, Jennefer N. Kohler,<sup>17</sup> Jonathan A. Bernstein,<sup>17</sup> Annika M. Dries,<sup>17</sup> Jill A. Rosenfeld,<sup>3</sup> Colette DeFilippo,<sup>18</sup> Willa Thorson,<sup>19</sup> Yaping Yang,<sup>3,4</sup> Elliott H. Sherr,<sup>2</sup> Weimin Bi,<sup>3,4</sup> Daryl A. Scott<sup>1,3,16\*</sup>

1) Department of Molecular Physiology and Biophysics, Baylor College of Medicine, Houston, TX, USA

2) Department of Neurology, University of California, San Francisco, San Francisco, CA, USA

3) Department of Molecular and Human Genetics, Baylor College of Medicine, Houston, TX, USA

4) Baylor Genetics, Houston, TX, USA

5) Institute of Genomic Medicine and Department of OB/GYN, Columbia University Medical Center, New York, NY, USA

6) Department of Genetics, Children's Hospital of Eastern Ontario, Ottawa, ON, Canada

7) Stead Family Department of Pediatrics, The University of Iowa, Iowa City, IA, USA

8) Department of Human Genetics, University of Michigan Medical School, Ann Arbor, MI, USA

This is the author manuscript accepted for publication and has undergone full peer review but has not been through the copyediting, typesetting, pagination and proofreading process, which may lead to differences between this version and the [Version of Record](#). Please cite this article as [doi: 10.1002/humu.23400](https://doi.org/10.1002/humu.23400).

This article is protected by copyright. All rights reserved.

- 9) Department of Pediatrics, University of Michigan Medical School, Ann Arbor, MI, USA
- 10) New York University School of Medicine, New York, NY USA
- 11) Department of Pediatrics, Children's Hospital of San Antonio/Baylor College of Medicine, San Antonio, TX, USA
- 12) Laboratory of Developmental Brain Disorders, INSERM UMR 1163, Paris, France
- 13) Service de Génétique, Necker Enfants Malades University Hospital, APHP, Paris, France
- 14) Pediatric Radiology, Necker Enfants Malades University Hospital, APHP, Paris, France
- 15) Paris Descartes - Sorbonne Paris Cité University, Imagine Institute, Paris, France
- 16) Texas Children's Hospital, Houston, TX, USA
- 17) Stanford University School of Medicine, Stanford, CA, USA
- 18) Stanford Children's Health/Lucile Packard Children's Hospital Stanford, Palo Alto, CA, USA
- 19) University of Miami, Miller School of Medicine, Miami, FL, USA

\* Correspondence:

Daryl A. Scott

R813, One Baylor Plaza, BCM225, Houston, TX 77030 USA

Email: [dscott@bcm.edu](mailto:dscott@bcm.edu)

Phone: +1 713-203-7242

This article is protected by copyright. All rights reserved.

Grant Sponsors: NIH Common Fund, Office of Strategic Coordination/Office of the NIH Director U01HG007708 and U01HG007942; NIH grant R01NS097862, NIH grant R01DC009410 and R01DC014456; the Donita B. Sullivan, MD Research Professorship in Pediatrics and Communicable Diseases; NIH Training Grant Michigan Predoctoral Training in Genetics T32GM007544; the Greek Orthodox Ladies Philoptochos Society, Inc. and Agence National pour la Recherche grant ANR-16-CE12-0005-01.

## ABSTRACT

Heterozygous variants in the arginine-glutamic acid dipeptide repeats gene (*RERE*) have been shown to cause neurodevelopmental disorder with or without anomalies of the brain, eye, or heart (NEDBEH). Here we report nine individuals with NEDBEH who carry partial deletions or deleterious sequence variants in *RERE*. These variants were found to be *de novo* in all cases in which parental samples were available. An analysis of data from individuals with NEDBEH suggests that point mutations affecting the Atrophin-1 domain of *RERE* are associated with an increased risk of structural eye defects, congenital heart defects, renal anomalies and sensorineural hearing loss when compared to loss-of-function variants that are likely to lead to haploinsufficiency. A high percentage of *RERE* pathogenic variants affect a histidine-rich region in the Atrophin-1 domain. We have also identified a recurrent two-amino-acid duplication in this region that is associated with the development of a CHARGE syndrome-like phenotype. We conclude that mutations affecting *RERE* result in a spectrum of clinical phenotypes. Genotype-phenotype correlations exist and can be used to guide medical decision making. Consideration should also be given to screening for *RERE* variants in individuals who fulfill diagnostic criteria for CHARGE syndrome but do not carry pathogenic variants in *CHD7*.

## KEY WORDS

RERE, NEDBEH, 1p36 deletion syndrome, CHARGE syndrome, CHD7, genotype-phenotype correlations

## INTRODUCTION

The arginine-glutamic acid dipeptide repeats gene (*RERE*; MIM# 605226) encodes a widely-expressed nuclear receptor coregulator (L. Wang, Rajan, Pitman, McKeown, & Tsai, 2006; Zoltewicz, Stewart, Leung, & Peterson, 2004). Acting in a complex with nuclear receptors and other transcription factors, RERE can function to inhibit or promote the expression of individual genes including *FGF8* and *RARB* (Kumar & Duester, 2014; Vilhais-Neto et al., 2010; L. Wang, Charroux, Kerridge, & Tsai, 2008; Zoltewicz et al., 2004). One of RERE's roles is to positively regulate retinoic acid signaling in multiple tissues during embryonic development (Kumar & Duester, 2014; Vilhais-Neto et al., 2010; Vilhais-Neto et al., 2017).

The importance of RERE during development was first demonstrated in animal models. Although no abnormal phenotypes have been described in mice that are haploinsufficient for RERE, Zoltewicz et al. demonstrated that mouse embryos which were homozygous for an *Rere* null allele (*om*, c.396+2T>A) died around E9.5 with open neural tube defects and signs suggestive of cardiac failure (Zoltewicz et al., 2004). A detailed analysis of *Rere*-null embryos revealed failure of ventralization of the anterior neural plate, fusion of the telencephalic and optic vesicle, failure of heart looping and irregular partitioning of somites. This provided evidence that RERE plays a critical role in brain, eye and heart development as well as embryonic patterning.

Schilling et al. and Plaster et al. reported that zebrafish carrying homozygous variants affecting *rerea*, the zebrafish homologue of *RERE*, had microphthalmia, inconsistent startle response and decreased microphonic potentials (Plaster, Sonntag, Schilling, & Hammerschmidt, 2007;

Schilling et al., 1996). This finding provided additional evidence for the role of RERE in eye development and also suggested that RERE may play a role in inner ear development and function.

To overcome the early lethality associated with complete loss of RERE function, Kim et al. generated an allelic series of mice bearing the *om* null allele and an *eyes3* (c.578T>C, p.(Val193Ala)) hypomorphic allele (Kim et al., 2013). *Rere*<sup>om/eyes3</sup> embryos and mice had a variety of abnormal phenotypes including postnatal growth deficiency, brain hypoplasia, decreased numbers of neuronal nuclear antigen (NeuN)-positive hippocampal neurons, abnormal cerebellar morphology, delayed maturation and migration of Purkinje cells, ventriculomegaly, microphthalmia, colobomata, hearing loss, conotruncal and septal congenital heart defects, spontaneous development of cardiac fibrosis and renal agenesis (Fregeau et al., 2016; Kim & Scott, 2014; Kim et al., 2013).

Many of the features seen in RERE-deficient mice overlap those associated with 1p36 deletion syndrome (MIM# 607872) in humans, which is characterized by developmental delay, intellectual disability, seizures, vision problems, hearing loss, short stature, distinctive facial features, brain anomalies, orofacial clefting, congenital heart defects, cardiomyopathy, and renal anomalies (Jordan, Zaveri, & Scott, 2015; Kang et al., 2007; Shapira et al., 1997). Since *RERE* is located within the proximal 1p36 deletion syndrome critical region, Kim et al. hypothesized that *RERE* haploinsufficiency in humans is likely to contribute to many of the phenotypes seen in individuals with terminal and interstitial 1p36 deletions that include *RERE* (Jordan et al., 2015; Kim et al., 2013).

This hypothesis was supported by Fregeau et al. who identified ten individuals with intellectual disability, developmental delay and/or autism spectrum disorder that carried rare, heterozygous putatively damaging sequence variants in *RERE* (Fregeau et al., 2016). These

variants were *de novo* in all cases in which parental DNA samples were available.

Neurocognitive deficits, hypotonia, seizures, behavioral problems, structural brain anomalies, ophthalmologic anomalies, congenital heart defects, and genitourinary abnormalities were recurrently documented within this cohort. The genetic syndrome found in these individuals was subsequently described as neurodevelopmental disorder with or without anomalies of the brain, eye, or heart (NEDBEH; MIM #616975).

Here we describe nine unrelated individuals with NEDBEH caused by partial deletions or putatively deleterious sequence variants in *REER*. An analysis of clinical and molecular data from individuals with NEDBEH suggests the existence of novel genotype-phenotype correlations and demonstrates that a high percentage of *REER* pathogenic variants affect a histidine-rich region in the Atrophin-1 domain. We document two individuals who carry a recurrent two-amino-acid duplication in this region who fulfill diagnostic criteria for CHARGE syndrome (MIM #214800) but do not carry pathogenic variants in *CHD7* (MIM # 608892).

## **MATERIALS AND METHODS**

### **Subject Accrual**

All subjects or their parents/guardians provided informed consent and were enrolled in institutional review board-approved research studies. In all cases, the procedures followed were in accordance with the ethical standards of the institution's committee on human research and were in keeping with international standards.

### **Copy Number Variant Analysis**

The *REER* deletion in Subject 1 was identified by array-based CNV analysis performed on a clinical basis at Baylor Genetics. This analysis was performed using a custom-designed

oligonucleotide-based array that included 400,000 probes for the detection of gains or losses of genomic material via array-based comparative genomic hybridization and 60,000 SNP probes for the detection of absence of heterozygosity (Wiszniewska et al., 2014).

### **Exome Sequencing**

Exome sequencing was performed for all subjects in CLIA or ISO15189 certified laboratories with the exception of Subject 2 whose exome sequencing was performed on a research basis. For Subject 2, trio exome sequencing was performed on a HiSeq2500 platform (Illumina, San Diego, CA). Library preparation was performed using a KAPA Biosystems (Wilmington, MA) library preparation kit followed by whole-exome capture using a Roche NimbleGen (Madison, WI) SeqCap EZ Exome Kit v3.0/v4.0. Bioinformatics processing was performed by Columbia University's Institute for Genomic Medicine using established bioinformatic and trio analysis platforms. All sequence variants described in this manuscript were confirmed by Sanger sequencing.

Throughout the text and tables, nucleotide (cDNA) numbering uses +1 as the A of the ATG translation initiation codon in the reference sequence, with the initiation codon as codon 1. All *RERE* variants mentioned in the text have been submitted to the ClinVar database (<https://www.ncbi.nlm.nih.gov/clinvar/>).

### ***In Silico* Prediction of the Effects of Sequence Variants**

The following programs were used to predict the effects of sequence variants on protein function: PolyPhen-2 [HumVar] (<http://genetics.bwh.harvard.edu/pph2/>), SIFT (<http://sift.jcvi.org/>) and MutationTaster (<http://www.mutationtaster.org/>).

## Statistical Analysis

A 2-tailed Fisher exact test (VassarStats statistical package, <http://vassarstats.net/tab2x2.html>) was used to compare the incidences of structural birth defects and sensorineural hearing loss between individuals who carried *RERE* putative loss-of-function variants and individuals who carried point mutation that affect the RERE Atrophin-1 domain.

## RESULTS

Here, we describe nine individuals who carry partial deletions or putatively deleterious sequence variants in *RERE* (Figure 1). These changes were shown to have arisen *de novo* in the eight individuals for whom parental samples could be obtained. As expected, these changes are rare in the general population with none being seen in individuals cataloged in the ExAC browser (<http://exac.broadinstitute.org/>) or gnomAD ([gnomad/broadinstitute.org](http://gnomad.broadinstitute.org)). Brief descriptions of their molecular findings and their clinical presentations are provided below and in Tables 1 and 2. Detailed clinical histories are available in the Supplementary Materials. All *RERE* sequence variants reported are based on *RERE* transcript variant 1 (NM\_012102.3). Throughout the text and tables, nucleotide (cDNA) numbering uses +1 as the A of the ATG translation initiation codon in the reference sequence, with the initiation codon as codon 1.

### Subject 1

Subject 1 is a 4-year, 3-month-old Hispanic male who carries an approximately 317 kb deletion (minimum deletion chr1:8,509,888-8,803,072; maximum deletion chr1:8,497,191-8,813,784; hg19) which includes coding exons 1-10 of the *RERE* gene. These exons encode the first 401 amino acids of RERE (Figure 1). No other genes were included in this deletion region. Parental samples were not available for analysis.



Pregnancy was uncomplicated, and he was delivered via repeat caesarian section without incident. At birth, he weighed 3.26 kg (43<sup>rd</sup> centile). His mother has mild cerebral palsy, speech problems and learning disabilities, but graduated from a technical college. His father and a paternal aunt have bipolar disorder, and a sister had developmental delay as an infant but is currently doing well in school. His clinical diagnoses include global developmental delay and mixed receptive-expressive language disorder. A hearing evaluation was normal. A brain MRI obtained at 3 years, 11 months of age was normal.

At 4 years 3 months of age, he weighed 16.3 kg (35<sup>th</sup> centile) and his height was 100 cm (13<sup>th</sup> centile). Physical exam findings included a triangular face, mild plagiocephaly, normal tone and a right ankle contracture.

## **Subject 2**

Subject 2 is an 8-month-old Hispanic male who carries a *de novo* c.248dupA, p.(Ser84Valfs\*4) variant in *RERE*. A nuchal translucency scan at 9 weeks and 6 days of gestation revealed a cystic hygroma. At 14 weeks of gestation the nuchal translucency was normal at 2.2 mm. Anatomy ultrasounds and fetal echocardiography did not identify any structural anomalies. He was born at 38 weeks of gestation via vaginal delivery. Birth weight was 2.955 kg (20<sup>th</sup> centile).

In the first months of life he had multiple urinary tract infections. Radiographic studies showed no evidence of hydronephrosis or vesicoureteral reflux. He was noted to be hypertonic, but his gross motor development has been normal: he rolled over at 3 months of age and started sitting on his own at 7 months of age.

At 8 months of age his length was at the 25<sup>th</sup> centile, his weight was at the 5<sup>th</sup> centile and his occipital frontal circumference (OFC) was at the 25<sup>th</sup> centile. On physical examination he was noted to have bifrontal narrowing, a low anterior hairline, mild hypertelorism, bilateral epicanthal folds,

downslanted palpebral fissures, synophrys, mild hypoplastic helices, redundant nuchal skin and spasticity of all four extremities with upper limbs being more affected than lower limbs.

### Subject 3

Subject 3 is a 21-year-old male of European descent who carries a *de novo* c.4300 T>C, p.(Ser1434Pro) missense variant in *RERE*. Pregnancy was complicated by twin gestation with loss of the second twin at 10 weeks of gestation. He was born via vaginal delivery. At birth he weighed 3.402 kg (54<sup>th</sup> centile) and was 53.3 cm (97<sup>th</sup> centile) in length. He rolled over at 6 months of age, sat at 9 months of age, crawled at 18 months of age and walked at 3 years of age. Parents indicate that he said his first words at approximately 9 months of age and that he put two words together between 2 and 3 years of age.

He had an atrial septal defect for which he underwent a transcatheter closure and is currently being treated with atenolol for aortic root dilatation. His clinical diagnoses include developmental delay, intellectual disability, hypotonia, ataxia, obsessive compulsive disorder, expressive language disorder, bilateral ptosis, esotropia, sleep apnea and scoliosis. A brain MRI obtained at 9 years of age revealed moderate global volume loss both supratentorially and infratentorially, a thin corpus callosum, flattening of the brain stem and a thin rim of sella. Hearing loss evaluations revealed chronic tympanic membrane perforation on the right and mild sensorineural hearing loss on the left.

At 19 years, 7 months of age his height was 163.3 cm (3<sup>rd</sup> centile) and his weight was 59.9 kg (14<sup>th</sup> centile). He was noted to have repetitive hand movements, an elongated and myopathic face with midfacial retraction, bilateral ptosis, deep-set eyes, a highly arched palate, spatulated thumbs and hyperconvexity of his fingernails and toenails. He currently speaks in up to 4 to 5 word sentences and also uses sign language to communicate.

#### Subject 4

Subject 4 is a 13-year-old female of European descent who carries a *de novo* c.4303C>T, p.(His1435Tyr) missense variant in *RERE*. Pregnancy was uneventful and she was born at 39 weeks of gestation by cesarean section for breech presentation. At birth she weighed 2.980 kg (29<sup>nd</sup> centile) and was 46 cm (5<sup>th</sup> centile) long with an OFC of 35 cm (83<sup>rd</sup> centile). She had hypotonia first noted in the neonatal period and was ultimately diagnosed with global developmental delay and severe intellectual disability. A brain MRI obtained at 5 years of age showed hemispheric cerebellar dysplasia with abnormal lobule and fissure orientation in the inferior hemispheres. Onset of puberty was noted between 6 and 7 years of age. Treatment for precocious puberty was initiated at 8 years of age and continued until she was 13 years old.

At 13 years of age her height was 148 cm (10<sup>th</sup> centile), her weight was 47 kg (55<sup>th</sup> centile), and her OFC was 54 cm (62<sup>nd</sup> centile). She had a vocabulary of less than 20 words and was not using two-word phrases. Hearing evaluation was normal. She has frequent temper tantrums.

#### Subject 5

Subject 5 is a 22-year-old female of Japanese and European ancestry who carries a *de novo* c.4304A>G, p.(His1435Arg) variant in *RERE*. She was born by induced delivery at 40 2/7 weeks of gestation following an uneventful pregnancy. At birth she weighed 3.6 kg (78<sup>th</sup> centile), her length was 53 cm (95<sup>th</sup> centile) and her OFC was 33 cm (23<sup>rd</sup> centile). Her Apgar scores were 8 and 9. Shortly after birth she was noted to have hypotonia and hypoxia. During her hospitalization she was diagnosed with an atrial septal defect and found to have 11 pairs of ribs. She was discharged home at 14 days of age with supplemental oxygen.

Global developmental delay was noted in infancy. At 1.5 years of age, acoustic emittance testing revealed normal (type A) tympanograms but behavioral audiometry was inconclusive due to cognitive

immaturity. Subsequent high frequency auditory brainstem response (ABR) evaluation was normal but middle and low frequencies were not tested. She walked and spoke her first word at 5 years of age. At 8 years of age she used approximately 25 words. A brain MRI was performed at 2 years of age and showed only mildly prominent CSF spaces.

At 21 years old, her height was 143 cm (<1<sup>st</sup> centile, -3.08 SD), her weight was 63.6 kg (73<sup>rd</sup> centile), her body mass index (BMI) was 31.1 (99<sup>th</sup> centile) and her OFC was 55.5 cm (73<sup>rd</sup> centile). She was noted to have upslanted palpebral fissures, large ears with overfolded helices, a right preauricular pit, small hands and feet, brachydactyly, and hyperconvex toenails.

### **Subject 6**

Subject 6 is an 8-year, 6-month-old male of Asian Indian descent who carries two *de novo* heterozygous missense variants in *RERE*, a c.3292C>G, p.(Leu1098Val) variant and c.4304A>T, p.(His1435Leu) variant. The phase of these variants is not known. He was also found to carry a *de novo* c.1147C>T, p.(Arg383Trp) variant in the protein phosphatase 2 regulatory subunit, alpha gene (*PPP2R2A*, MIM #604941, NM\_002717.3). This variant was predicted to be benign by PolyPhen-2, damaging by SIFT, and disease causing by MutationTaster, and has not been seen in control individuals in the ExAC Browser or in gnomAD. *PPP2R2A* is a member of a large family of heterotrimeric Ser/Thr phosphatases and plays a critical role in homologous recombination repair through modulation of ATM phosphorylation (Kalev et al., 2012). *PPP2R2A* has a probability of loss-of-function intolerance (pLI) score of 0.96 in the ExAC Browser but has not been associated with a specific genetic disorder in humans.

He was ultimately diagnosed with global developmental delay, intellectual disability, autism spectrum disorder, cerebral palsy, mild bilateral sensorineural hearing loss, bilateral myopia and exotropia for which he had surgery. A brain MRI performed at 2 years, 1 month of age was normal.

At 8 years, 6 months of age, his height was 116.4 cm (6<sup>th</sup> centile), his weight was 22.2 kg (26<sup>th</sup> centile) and his OFC was 50.5 cm (22<sup>nd</sup> centile). On physical exam he was noted to have prominent, cupped ears, a triangular-shaped face, mild fifth finger clinodactyly, 2<sup>nd</sup> toes that override his 1<sup>st</sup> toes bilaterally, and ankle valgus deformities of the feet resulting in pronation for which he wears braces.

### Subject 7

Subject 7 was a male of European descent who died at 33 days of age. He carried a *de novo* c.4313\_4318dupTCCACC, p.(Leu1438\_His1439dup) variant in *RERE*. This type of variant is not amenable to evaluation by PolyPhen-2 or SIFT, and MutationTaster predicts this variant to be a polymorphism. However, this duplication is located in the Atrophin-1 domain of *RERE* and affects a histidine-rich region whose amino acid sequence is 100% conserved down to *Xenopus* and zebrafish. We also note that the same variant was found to have arisen *de novo* in a previously reported individual with NEDBEH (Fregeau et al., Subject 2) and in Subject 8 (Fregeau et al., 2016).

Pregnancy was complicated by polyhydramnios and gestational diabetes mellitus. He was born prematurely at 36 4/7 weeks gestation via spontaneous vaginal delivery. At birth he was flaccid and required positive pressure ventilation for apnea and cyanosis. Apgar scores were 2, 4, 7 and 9. He was placed on continuous positive airway pressure (CPAP) and transferred to a neonatal intensive care unit where he was intubated due to low tone and increased work of breathing. His weight was 2.550 kg (24<sup>th</sup> centile), his length was 47 cm (37<sup>th</sup> centile) and his OFC was 33.5 cm (37<sup>th</sup> centile). Physical exam findings included a flat nasal bridge, a large prominent forehead, bilateral ptosis, left-sided iris coloboma and corneal clouding, small, low-set ears, excessive nuchal skin, bilateral contractures of the 2<sup>nd</sup> and 3<sup>rd</sup> digits, widely spaced nipples, hypospadias, and axial hypotonia with normal deep tendon reflexes.

He was subsequently found to have bilateral choanal atresia, an atrial septal defect, a ventricular septal defect, a small patent foramen ovale and a mildly dilated right ventricle. A head ultrasound performed on day 3 of life revealed diffuse white matter changes with increased echogenicity and concerns for simplified sulcation. A brain MRI performed on the seventh day of life revealed a simplified gyral pattern with unusually large ventricles suggestive of delayed brain maturation. Multiple punctate periventricular ischemic lesions were also detected along with restricted diffusion in the splenium of the corpus callosum. Audiometry was not performed, but MRI and CT scans revealed normal semicircular canals.

Over time, he developed heart failure with pulmonary edema and elevated right ventricle and diastolic pressures (>50% systemic) suggestive of persistent pulmonary hypertension. He remained intubated until his death at 33 days of age. An autopsy confirmed the simplified gyration of cerebral cortex and also showed atrophy of the frontal lobes, dysplasia of the inferior olivary and dentate nuclei, mild to moderate ventriculomegaly, multifocal neuroglial heterotopia and optic nerve hypoplasia. There was also evidence of hypoxic-ischemic damage.

### **Subject 8**

Subject 8 is an 8-year, 3-month-old female of European descent who carries a *de novo* c.4313\_4318dupTCCACC, p.(Leu1438\_His1439dup) variant in *RERE*. A truncus arteriosus type I defect was identified prenatally along with intrauterine growth retardation and fetal hand posturing. She was born at 39 1/7 weeks gestation by emergency cesarean section because of decreased fetal heart tones. Apgar scores were 1 and 6. Birth weight was 2.415 kg (3<sup>rd</sup> centile), length was 47 cm (13<sup>th</sup> centile) and OFC was 32 cm (6<sup>th</sup> centile).

She was subsequently diagnosed with bilateral choanal atresia, right-sided chorioretinal and iris coloboma and anisometropia. She underwent repair of her truncus arteriosus at 1 month of age.

Following surgery, she had neonatal supraventricular tachycardia (SVT) which resolved by 1 year of age.

She has progressive sensorineural hearing loss and wears a hearing aid in the left ear and has a cochlear implant on the right side. A temporal bone CT scan showed bilateral cochlear dysplasia. She has been diagnosed with developmental delay and intellectual disability. She has no speech and cannot stand or walk without assistance. She has short stature with advanced bone age and has been diagnosed with neuromuscular thoracolumbar scoliosis, bilateral hip dysplasia, and bilateral equinus contractures.

At 8 years, 3 months of age, her height was 114.3 cm (0.4<sup>th</sup> centile), her weight was 20.4 kg (4<sup>th</sup> centile) and her OFC was 47 cm (<1<sup>st</sup> centile). She had a flattened facial profile, hypertelorism, a right-sided iris coloboma, normally set ears with very small lobules and prominent antihelices, a broad nasal bridge, a III/VI systolic murmur and bilateral hockey stick palmar creases.

### **Subject 9**

Subject 9 is a 4-year-old female of European descent who carries a *de novo* c.4391A>G, p.(His1464Arg) variant in *REER*. She has a twin brother who is healthy and an older brother who was diagnosed with dyslexia but is otherwise healthy. She has been diagnosed with developmental delay, autism spectrum disorder and obsessive compulsive disorder. Her parents report erratic behavior, extreme separation anxiety and difficulty falling asleep and remaining asleep. At her most recent physical examination, her height and weight were at the 95<sup>th</sup> centile and her head circumference was at the 50<sup>th</sup> centile. She was found to have hirsutism affecting the back and arms, synophrys, hypertelorism, an upturned nose and a wide mouth.

## DISCUSSION

Here we report nine individuals with NEDBEH caused by partial deletions or putatively deleterious sequence variants in *RERE*. Functional analyses aimed at confirming the effect of these variants on *RERE* function were not performed. Consistent with previous reports of individuals with NEDBEH, intellectual disability, developmental delay and/or autism was diagnosed in all individuals except Subject 2, who is 8 months old and achieved his early motor milestones on time despite being hypertonic, and Subject 7 who died in infancy. Among the six individuals who had brain MRIs, three (50%) had structural defects, one (17%) had only mildly prominent CSF spaces, and two (33%) had MRIs that were reported as normal for age. Structural eye defects were seen in two individuals in our cohort (22%), both of whom had colobomata. Other eye/vision problems identified included myopia, anisometropia, astigmatism, exotropia, esotropia, ptosis and optic nerve hypoplasia. Congenital heart defects were seen in four individuals (44%) and included septal defects and truncus arteriosus.

Some of the medical problems identified in only one individual (1/10, 10%) in the NEDBEH cohort reported by Fregeau et al. were also identified in one or more individuals in our cohort (Fregeau et al., 2016). These include sensorineural hearing loss which was present in 3 subjects (33%), scoliosis which was identified in 2 subjects (22%) and congenital hip dysplasia, which was seen in one individual (11%). These medical problems have also been previously reported in individuals who carry 1p36 deletions that include *RERE* (Fregeau et al., 2016).

### **Pathogenic variants affecting a histidine rich region of the Atrophin-1 domain of *RERE***

Of the 19 individuals with NEDBEH described here and by Fregeau et al., nine (47%) carry sequence variants that affect a histidine-rich region of the Atrophin-1 domain that spans 21 amino acids (1425 to 1445) (Fregeau et al., 2016). The amino acid sequence in this region is 100%



conserved down to *Xenopus* and zebrafish, but the functional significance of this domain is currently unknown.

### Genotype-phenotype correlations

Fregeau et al. suggested that point mutations in the Atrophin-1 domain might be associated with a more severe clinical presentation (Fregeau et al., 2016). Our study provides additional evidence in support of this genotype-phenotype correlation. Among the 19 individuals with NEDBEH described here and by Fregeau et al., six (31%) carry putative loss-of-function variants—partial deletions, nonsense variants or frameshift variants—and 12 (63%) individuals carry point mutations in the Atrophin-1 domain. We evaluated the incidence of structural defects of the brain, eye, heart and kidney and sensorineural hearing loss between these two groups (Table 3, Supp. Table S1). The total number of structural defects and sensorineural hearing loss seen in individuals with point mutations in the Atrophin-1 domain is significantly higher than expected based on the number of structural defects seen in individuals with putative loss-of-function variants ( $p = 0.0004$ ).

The increase in severity seen with point mutations in the Atrophin-1 domain may be due to the generation of an abnormal protein product that functions in a dominant negative fashion by antagonizing the function of the wild-type gene product within the same cell. This hypothesis is supported by the fact that the phenotypes seen in individuals with point mutations overlap those of *Rere*<sup>om/eyes3</sup> mice who carry both a null and a hypomorphic allele of *Rere* (Fregeau et al., 2016; Kim et al., 2013).

Our ability to identify genotype-phenotype correlation is currently limited by the relatively small number of patients that have been described who carry pathogenic variants in *RERE*. As additional individuals with NEDBEH are identified, more detailed genotype-phenotype correlations may become apparent.

Studies of RERE-deficient mice on different genetic backgrounds have shown that the penetrance of some RERE-related phenotypes, such as congenital heart defects, are highly dependent on genetic factors that have yet to be identified (Kim et al., 2013). Variations in the phenotypes of individual RERE-deficient mice on the same genetic background suggest that epigenetic, environmental and/or stochastic factors also exist that can influence the penetrance and severity of individual phenotypes. These findings provide hope for the development of penetrative and therapeutic interventions, but also suggest the need for caution when providing individuals and families with prognostic information based largely on genotype-phenotype correlations.

### **An *RERE* variant in *CHD7*-negative CHARGE syndrome**

Two individuals within our cohort carry the same *de novo* c.4313\_4318dupTCCACC, p.(Leu1438\_His1439dup) variant in *RERE*. This same variant also arose *de novo* in a previously reported 15-month-old male (Fregeau et al., Subject 2) who had a unilateral iris coloboma, a ventricular septal defect, patent ductus arteriosus that was surgically closed, anomalous pulmonary venous return, choanal atresia, simple ears, cryptorchidism, a right-sided multicystic kidney, short stature, microcephaly, developmental delay and brain anomalies that included a thin corpus callosum, ventriculomegaly, incompletely folded hippocampi, and severely diminished white matter-volume (Fregeau et al., 2016).

Due to their clinical presentations, all three of these individuals were originally suspected to have CHARGE syndrome (Coloboma, Heart defects, choanal Atresia, Retarded growth and development, Genital abnormalities, and Ear anomalies) which is most commonly caused by heterozygous variants in *CHD7* (Hall, 1979; Hittner, Hirsch, Kreh, & Rudolph, 1979; Vissers et al., 2004). Indeed, all of these individuals fulfill the diagnostic criteria for CHARGE syndrome proposed by Hale et al. (Table 4) (Hale, Niederriter, Green, & Martin, 2016). In all cases, exome sequencing

was undertaken only after screening of the *CHD7* gene failed to reveal a causative variant. This suggests that consideration should be given to sequencing *RERE*, or testing for the c.4313\_4318dupTCCACC variant, in individuals who meet diagnostic criteria for CHARGE syndrome but do not have pathogenic variants in *CHD7*.

Although *RERE* and *CHD7* are not known to interact, both function to regulate the transcription of other genes and are widely expressed in the developing embryo (Bouazoune and Kingston, 2012; Lalani et al., 2006; Sanlaville et al., 2006; Zoltewicz et al., 2004). The overlapping phenotypes seen in individuals with deficiency of *RERE* and *CHD7* suggest that they may regulate the expression of a common set of genes in the developing embryo or that their gene targets may function in the same molecular pathways. In support of this hypothesis, we note that *RERE* has been shown to positively regulate retinoic acid signaling during embryonic development (Kumar & Duester, 2014; Vilhais-Neto et al., 2010; Vilhais-Neto et al., 2017). Although, *CHD7* has not been shown to regulate retinoic acid signaling, modulation of retinoic acid signaling has been shown to prevent *in vivo* inner ear and *in vitro* neural stem cell defects caused by *CHD7* deficiency (Micucci et al., 2014).

In addition, *RERE* has also been shown to stimulate Notch target gene expression, including the expression of *Hes* genes, by preventing degradation of the Notch intracellular domain (NICD) (H. Wang, Gui, Rallo, Xu, & Matise, 2017). Similarly, *CHD7* is required for the full induction of *Hes5* in quiescent neural stem/progenitor cells (NSCs) and loss of *CHD7* function lead to decreased expression of the Notch ligand *JAG1* in the developing inner ear (Hurd, Micucci, Reamer, & Martin, 2012; Jones et al., 2015).

### **Conclusions**

Individuals carrying pathogenic variants in *RERE* can present with a range of clinical phenotypes. Some individuals have isolated neurodevelopmental disorders—developmental delay, intellectual

disability, and autism—while others have a variety of structural birth defects involving the brain, eye, ear, craniofacial structures, heart, kidney and skeleton. Genotype-phenotype correlations exist and may help guide medical management and surveillance. Additionally, individuals who carry the c.4313\_4318dupTCCACC, p.(Leu1438\_His1439dup) variant in *RERE* share overlapping clinical features similar to that seen in CHARGE syndrome. Individuals who are suspected of having CHARGE syndrome but do not carry variants in *CHD7* should be evaluated for pathogenic variants in *RERE*.

## ACKNOWLEDGEMENTS

The authors thank family members for participating in this research.

## Consortia

Members of the Undiagnosed Diseases Network include David R. Adams, Mercedes E. Alejandro, Patrick Allard, Euan A. Ashley, Mahshid S. Azamian, Carlos A. Bacino, Ashok Balasubramanyam, Hayk Barseghyan, Gabriel F. Batzli, Alan H. Beggs, Hugo J. Bellen, Anna Bican, David P. Bick, Camille L. Birch, Devon Bonner, Braden E. Boone, Bret L. Bostwick, Lauren C. Briere, Donna M. Brown, Matthew Brush, Elizabeth A. Burke, Lindsay C. Burrage, Shan Chen, Gary D. Clark, Terra R. Coakley, Joy D. Cogan, Cynthia M. Cooper, Heidi Cope, William J. Craigen, Precilla D'Souza, Mariska Davids, Jean M. Davidson, Jyoti G. Dayal, Esteban C. Dell'Angelica, Shweta U. Dhar, Ani Dillon, Katrina M. Dipple, Laurel A. Donnell-Fink, Naghmeh Dorrani, Daniel C. Dorset, Emilie D. Douine, David D. Draper, David J. Eckstein, Lisa T. Emrick, Christine M. Eng, Gregory M. Enns, Ascia Eskin, Cecilia Esteves, Tyra Estwick, Liliana Fernandez, Paul G. Fisher, Brent L. Fogel, Noah D. Friedman, William A. Gahl, Emily Glanton, Rena A. Godfrey, David B. Goldstein, Sarah E. Gould, Jean-Philippe F. Gourdine, Catherine A. Groden, Andrea L. Gropman, Melissa Haendel, Rizwan Hamid, Neil A. Hanchard, Lori H. Handley, Matthew R. Herzog, Ingrid A. Holm, Jason Hom,

This article is protected by copyright. All rights reserved.

Ellen M. Howerton, Yong Huang, Howard J. Jacob, Mahim Jain, Yong-hui Jiang, Jean M. Johnston, Angela L. Jones, David M. Koeller, Isaac S. Kohane, Donna M. Krasnewich, Elizabeth L. Krieg, Joel B. Krier, Jennifer E. Kyle, Seema R. Lalani, C. Christopher Lau, Jozef Lazar, Brendan H. Lee, Hane Lee, Shawn E. Levy, Richard A. Lewis, Sharyn A. Lincoln, Allen Lipson, Sandra K. Loo, Joseph Loscalzo, Richard L. Maas, Ellen F. Macnamara, Calum A. MacRae, Valerie V. Maduro, Marta M. Majcherska, May Christine V. Malicdan, Laura A. Mamounas, Teri A. Manolio, Thomas C. Markello, Ronit Marom, Julian A. Martínez-Agosto, Shruti Marwaha, Thomas May, Allyn McConkie-Rosell, Colleen E. McCormack, Alexa T. McCray, Jason D. Merker, Thomas O. Metz, Matthew Might, Paolo M. Moretti, John J. Mulvihill, Jennifer L. Murphy, Donna M. Muzny, Michele E. Nehrebecky, Stan F. Nelson, J. Scott Newberry, John H. Newman, Sarah K. Nicholas, Donna Novacic, Jordan S. Orange, J. Carl Pallais, Christina GS. Palmer, Jeanette C. Papp, Neil H. Parker, Loren DM. Pena, John A. Phillips III, Jennifer E. Posey, John H. Postlethwait, Lorraine Potocki, Barbara N. Pusey, Chloe M. Reuter, Amy K. Robertson, Lance H. Rodan, Jacinda B. Sampson, Susan L. Samson, Kelly Schoch, Molly C. Schroeder, Daryl A. Scott, Prashant Sharma, Vandana Shashi, Edwin K. Silverman, Janet S. Sinsheimer, Kevin S. Smith, Ariane G. Soldatos, Rebecca C. Spillmann, Kimberly Splinter, Joan M. Stoler, Nicholas Stong, Jennifer A. Sullivan, David A. Sweetser, Cynthia J. Tifft, Camilo Toro, Alyssa A. Tran, Tiina K. Urv, Zaheer M. Valivullah, Eric Vilain, Tiphonie P. Vogel, Daryl M. Waggott, Colleen E. Wahl, Nicole M. Walley, Chris A. Walsh, Michael F. Wangler, Patricia A. Ward, Katrina M. Waters, Bobbie-Jo M. Webb-Robertson, Monte Westerfield, Matthew T. Wheeler, Anastasia L. Wise, Lynne A. Wolfe, Elizabeth A. Worthey, Shinya Yamamoto, Guoyun Yu, Diane B. Zastrow, Chunli Zhao, and Allison Zheng.

## **Funding**

Research reported in this manuscript was supported in part by the NIH Common Fund, through the Office of Strategic Coordination/Office of the NIH Director under Award Numbers

This article is protected by copyright. All rights reserved.

U01HG007708 and U01HG007942, NIH grant R01NS097862 (SLB), NIH grant R01DC009410 and R01DC014456 (DMM), the Donita B. Sullivan, MD Research Professorship in Pediatrics and Communicable Diseases (DMM), and NIH Training Grant Michigan Predoctoral Training in Genetics T32GM007544 (ANM). The content is solely the responsibility of the authors and does not necessarily represent the official views of the National Institutes of Health.

This work was also supported in part by a grant from the Greek Orthodox Ladies Philoptochos Society, Inc. and Agence National pour la Recherche grant ANR-16-CE12-0005-01.

### **Conflict of Interest Statement**

The Department of Molecular and Human Genetics at Baylor College of Medicine derives revenue from clinical laboratory testing conducted at Baylor Genetics. All other authors report no conflicts of interest.

### **REFERENCES**

- Bouazoune, K., & Kingston, R. E. (2012). Chromatin remodeling by the CHD7 protein is impaired by mutations that cause human developmental disorders. *Proc Natl Acad Sci U S A*, *109*(47), 19238-19243. doi:10.1073/pnas.1213825109
- Fregeau, B., Kim, B. J., Hernandez-Garcia, A., Jordan, V. K., Cho, M. T., Schnur, R. E., . . . Sherr, E. H. (2016). De Novo Mutations of RERE Cause a Genetic Syndrome with Features that Overlap Those Associated with Proximal 1p36 Deletions. *Am J Hum Genet*, *98*(5), 963-970. doi:10.1016/j.ajhg.2016.03.002
- Hale, C. L., Niederriter, A. N., Green, G. E., & Martin, D. M. (2016). Atypical phenotypes associated with pathogenic CHD7 variants and a proposal for broadening CHARGE syndrome clinical diagnostic criteria. *Am J Med Genet A*, *170A*(2), 344-354. doi:10.1002/ajmg.a.37435

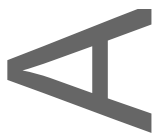This article is protected by copyright. All rights reserved.

- Hall, B. D. (1979). Choanal atresia and associated multiple anomalies. *J Pediatr*, 95(3), 395-398.
- Hittner, H. M., Hirsch, N. J., Kreh, G. M., & Rudolph, A. J. (1979). Colobomatous microphthalmia, heart disease, hearing loss, and mental retardation--a syndrome. *J Pediatr Ophthalmol Strabismus*, 16(2), 122-128.
- Hurd, E. A., Micucci, J. A., Reamer, E. N., & Martin, D. M. (2012). Delayed fusion and altered gene expression contribute to semicircular canal defects in Chd7 deficient mice. *Mech Dev*, 129(9-12), 308-323. doi:10.1016/j.mod.2012.06.002
- Jones, K. M., Saric, N., Russell, J. P., Andoniadou, C. L., Scambler, P. J., & Basson, M. A. (2015). CHD7 maintains neural stem cell quiescence and prevents premature stem cell depletion in the adult hippocampus. *Stem Cells*, 33(1), 196-210. doi:10.1002/stem.1822
- Jordan, V. K., Zaveri, H. P., & Scott, D. A. (2015). 1p36 deletion syndrome: an update. *Appl Clin Genet*, 8, 189-200. doi:10.2147/TACG.S65698
- Kaley, P., Simicek, M., Vazquez, I., Munck, S., Chen, L., Soin, T., . . . Sablina, A. (2012). Loss of PPP2R2A inhibits homologous recombination DNA repair and predicts tumor sensitivity to PARP inhibition. *Cancer Res*, 72(24), 6414-6424. doi:10.1158/0008-5472.CAN-12-1667
- Kang, S. H., Scheffer, A., Ou, Z., Li, J., Scaglia, F., Belmont, J., . . . Bacino, C. A. (2007). Identification of proximal 1p36 deletions using array-CGH: a possible new syndrome. *Clin Genet*, 72(4), 329-338. doi:10.1111/j.1399-0004.2007.00876.x
- Kim, B. J., & Scott, D. A. (2014). Mouse model reveals the role of RERE in cerebellar foliation and the migration and maturation of Purkinje cells. *PLoS One*, 9(1), e87518. doi:10.1371/journal.pone.0087518



This article is protected by copyright. All rights reserved.

- Kim, B. J., Zaveri, H. P., Shchelochkov, O. A., Yu, Z., Hernandez-Garcia, A., Seymour, M. L., . . . Scott, D. A. (2013). An Allelic Series of Mice Reveals a Role for RERE in the Development of Multiple Organs Affected in Chromosome 1p36 Deletions. *PLoS One*, *8*(2), e57460. doi:10.1371/journal.pone.0057460
- Kumar, S., & Duester, G. (2014). Retinoic acid controls body axis extension by directly repressing Fgf8 transcription. *Development*, *141*(15), 2972-2977. doi:10.1242/dev.112367
- Lalani, S. R., Safiullah, A. M., Fernbach, S. D., Harutyunyan, K. G., Thaller, C., Peterson, L. E., . . . Belmont, J. W. (2006). Spectrum of CHD7 mutations in 110 individuals with CHARGE syndrome and genotype-phenotype correlation. *Am J Hum Genet*, *78*(2), 303-314. doi:10.1086/500273
- Micucci, J. A., Layman, W. S., Hurd, E. A., Sperry, E. D., Frank, S. F., Durham, M. A., . . . Martin, D. M. (2014). CHD7 and retinoic acid signaling cooperate to regulate neural stem cell and inner ear development in mouse models of CHARGE syndrome. *Hum Mol Genet*, *23*(2), 434-448. doi:10.1093/hmg/ddt435
- Plaster, N., Sonntag, C., Schilling, T. F., & Hammerschmidt, M. (2007). REREa/Atrophin-2 interacts with histone deacetylase and Fgf8 signaling to regulate multiple processes of zebrafish development. *Dev Dyn*, *236*(7), 1891-1904. doi:10.1002/dvdy.21196
- Sanlaville, D., Etchevers, H. C., Gonzales, M., Martinovic, J., Clement-Ziza, M., Delezoide, A. L., . . . Attie-Bitach, T. (2006). Phenotypic spectrum of CHARGE syndrome in fetuses with CHD7 truncating mutations correlates with expression during human development. *J Med Genet*, *43*(3), 211-217. doi:10.1136/jmg.2005.036160



This article is protected by copyright. All rights reserved.



- Schilling, T. F., Piotrowski, T., Grandel, H., Brand, M., Heisenberg, C. P., Jiang, Y. J., . . . Nusslein-Volhard, C. (1996). Jaw and branchial arch mutants in zebrafish I: branchial arches. *Development*, *123*, 329-344.
- Shapira, S. K., McCaskill, C., Northrup, H., Spikes, A. S., Elder, F. F., Sutton, V. R., . . . Shaffer, L. G. (1997). Chromosome 1p36 deletions: the clinical phenotype and molecular characterization of a common newly delineated syndrome. *Am J Hum Genet*, *61*(3), 642-650. doi:10.1086/515520
- Vilhais-Neto, G. C., Fournier, M., Plassat, J. L., Sardi, M. E., Saraf, A., Garnier, J. M., . . . Pourquie, O. (2017). The WHHERE coactivator complex is required for retinoic acid-dependent regulation of embryonic symmetry. *Nat Commun*, *8*(1), 728. doi:10.1038/s41467-017-00593-6
- Vilhais-Neto, G. C., Maruhashi, M., Smith, K. T., Vasseur-Cognet, M., Peterson, A. S., Workman, J. L., & Pourquie, O. (2010). Rere controls retinoic acid signalling and somite bilateral symmetry. *Nature*, *463*(7283), 953-957. doi:10.1038/nature08763
- Vissers, L. E., van Ravenswaaij, C. M., Admiraal, R., Hurst, J. A., de Vries, B. B., Janssen, I. M., . . . van Kessel, A. G. (2004). Mutations in a new member of the chromodomain gene family cause CHARGE syndrome. *Nat Genet*, *36*(9), 955-957. doi:10.1038/ng1407
- Wang, H., Gui, H., Rallo, M. S., Xu, Z., & Matisse, M. P. (2017). Atrophin protein RERE positively regulates Notch targets in the developing vertebrate spinal cord. *J Neurochem*, *141*(3), 347-357. doi:10.1111/jnc.13969
- Wang, L., Charroux, B., Kerridge, S., & Tsai, C. C. (2008). Atrophin recruits HDAC1/2 and G9a to modify histone H3K9 and to determine cell fates. *EMBO Rep*, *9*(6), 555-562. doi:10.1038/embor.2008.67



This article is protected by copyright. All rights reserved.

Wang, L., Rajan, H., Pitman, J. L., McKeown, M., & Tsai, C. C. (2006). Histone deacetylase-associating Atrophin proteins are nuclear receptor corepressors. *Genes Dev*, 20(5), 525-530. doi:10.1101/gad.1393506

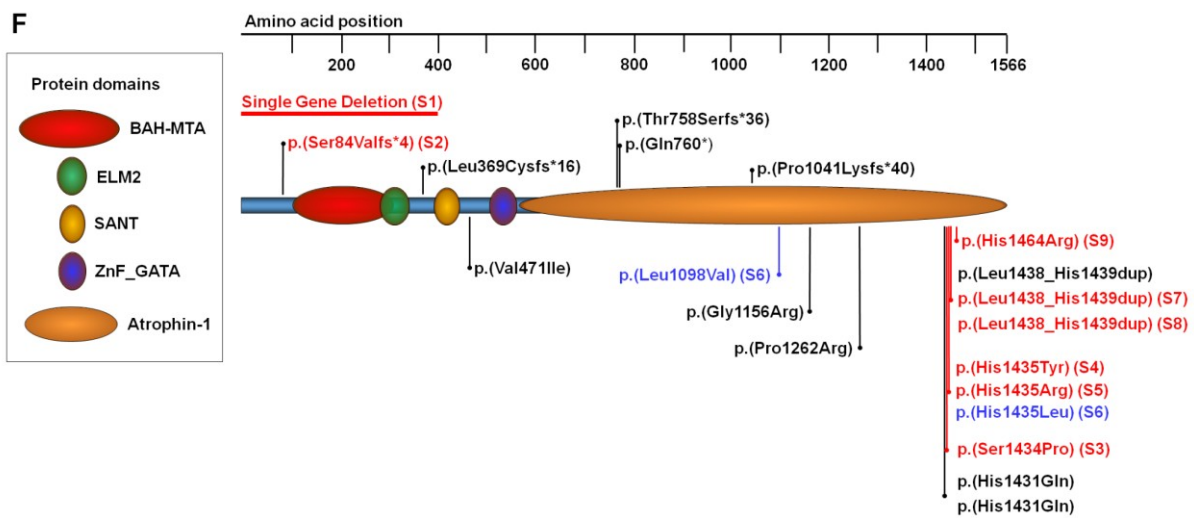
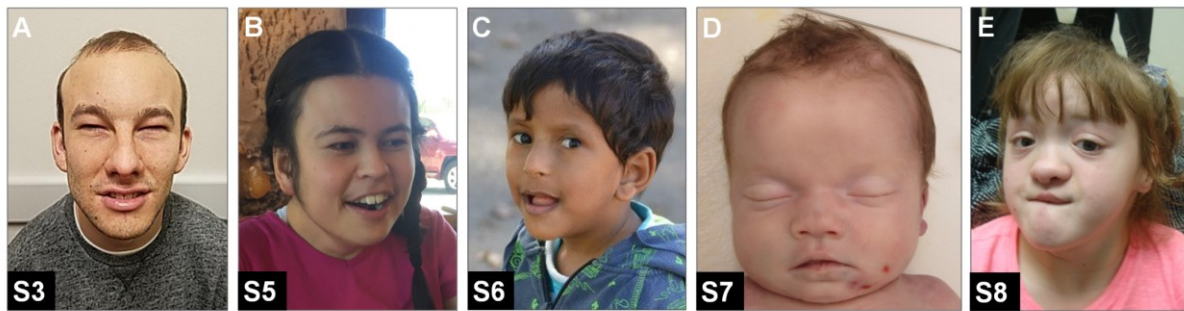
Wiszniewska, J., Bi, W., Shaw, C., Stankiewicz, P., Kang, S. H., Pursley, A. N., . . . Patel, A. (2014). Combined array CGH plus SNP genome analyses in a single assay for optimized clinical testing. *Eur J Hum Genet*, 22(1), 79-87. doi:10.1038/ejhg.2013.77

Zoltewicz, J. S., Stewart, N. J., Leung, R., & Peterson, A. S. (2004). Atrophin 2 recruits histone deacetylase and is required for the function of multiple signaling centers during mouse embryogenesis. *Development*, 131(1), 3-14. doi:10.1242/dev.00908

## FIGURE LEGENDS

**Figure 1** A-E) Photos of Subjects 3, 5, 6 (at six years of age), 7 (postmortem) and 8. As previously reported, a consistent pattern of dysmorphic features is not seen among individuals with NEDBEH (Fregeau et al., 2016). F) Deletions and sequence variants identified in Subjects 1-9 and previously published individuals with NEDBEH. The locations of the *RERE* deletions and sequence variants reported in individuals with NEDBEH are shown in relation to the protein domains of RERE.

Deletions and sequence variants found in Subjects 1-9 are shown in red if only a single variant was detected and blue if two variants were detected. Previously published sequence variants are shown in black. A high percentage of *RERE* pathogenic variants affect a 21 amino acid (amino acids 1425 to 1445), histidine-rich region of the Atrophin-1 domain. Nucleotide (cDNA) numbering uses +1 as the A of the ATG translation initiation codon in the reference sequence, with the initiation codon as codon 1.



**Table 1** *REER* deletions and sequence variants identified in Subjects 1-9

Subject	Deletions and sequence variants affecting <i>REER</i> <sup>a</sup>	Inheritance	PolyPhen-2 (HumVar)	SIFT	MutationTaster <sup>c</sup>	Allele present in the ExAC browser or gnomAD?
S1	Minimum deletion (hg19) chr1:8,509,888-8,803,072 Maximum deletion (hg19) chr1:8,497,191-8,813,784	N/D	N/A	N/A	N/A	N/A
S2	c.248dupA	<i>De novo</i>	N/A	N/A	Disease Causing	No

	p.(Ser84Valfs*4)					
S3	c.3146C>T p.(Pro1049Leu)	<i>De novo</i>	Benign	Tolerated	Disease Causing	No <sup>b</sup>
S4	c.4303C>T p.(His1435Tyr)	<i>De novo</i>	Possibly Damaging	Damaging	Disease Causing	No
S5	c.4304A>G p.(His1435Arg)	<i>De novo</i>	Probably Damaging	Damaging	Disease Causing	No
S6	c.3292C>G p.(Leu1098Val)	<i>De novo</i>	Possibly Damaging	Tolerated	Disease Causing	No
	c.4304A>T p.(His1435Leu)	<i>De novo</i>	Probably Damaging	Damaging	Disease Causing	No
S7	c.4313_4318dupTCCACC p.(Leu1438_His1439dup)	<i>De novo</i>	N/A	N/A	Polymorphism	No
S8	c.4313_4318dupTCCACC p.(Leu1438_His1439dup)	<i>De novo</i>	N/A	N/A	Polymorphism	No
S9	c.4391A>G p.(His1464Arg)	<i>De novo</i>	Benign	Tolerated	Disease Causing	No

a = Based on *RERE* transcript variant 1[NM\_012102.3]. Nucleotide (cDNA) numbering uses +1 as the A of the ATG translation initiation codon in the reference sequence, with the initiation codon as codon 1.

b = This amino acid is altered to a Ser (p.Pro1049Ser) in 10/113338 alleles in gnomAD.

c = MutationTaster classifies all variants as either “Disease Causing” or “Polymorphism”. These classifications do not indicate that the variant has been shown to cause disease or that the variant is found at a frequency  $\geq 1\%$ .

N/D = Not determined due to a lack of parental samples, N/A = Not applicable

**Table 2** Summary of clinical findings in subjects 1-9

	S1	S2	S3	S4	S5	S6	S7	S8	S9
Age/Sex	4y M	8m M	21y M	13y F	22y F	8y M	33d M	8y F	4y F
Developmental delay/intellectual disability/autism	+	-	+	+	+	+	N/A	+	+
Hypotonia	-	-	+	+	+	-	+	-	-
Abnormal brain MRI	-	N/D	+	+	-**	-	+	N/D	N/D
Structural eye anomalies	-	-	-	-	-	-	+	+	-
Sensorineural hearing loss	-	-	+	-	-	+	N/D	+	-
Choanal atresia	-	-	-	-	-	-	+	+	-
Congenital heart defects	-	-	+	-	+	-	+	+	-
Renal anomalies	-	-*	-	-	-	-	-	-	-
Scoliosis	-	-	+	-	-	-	-	+	-

F = Female, M = Male, - = Not reported, + = Reported, N/A = Not applicable, N/D = Not done

\* = subject had multiple urinary tract infections during the first few months of life but radiographic studies showed no evidence of hydronephrosis or vesicoureteral reflux

\*\* = mildly prominent CSF spaces

**Table 3** Statistical comparison of the incidence of structural birth defects and sensorineural hearing loss among genotypic groups

	Loss-of-function variants*	Point mutations in the Atrophin-1 domain	<i>p</i> value
Brain anomalies	1/3 (33%)	8/10 (80%)	0.20

Eye anomalies	0/6 (0%)	6/12 (50%)	0.11
Congenital heart defects	1/6 (17%)	7/12 (58%)	0.15
Renal anomalies	0/6 (0%)	2/12 (17%)	0.53
Sensorineural hearing loss	0/6 (0%)	4/11 (36%)	0.24
Number of defects per individual	0.33 (2/6)	2.25 (27/12)	0.0004**

\* = Partial deletions, stop-gains variants or frameshift variants

\*\* = Based on the total number of defects that could have been identified in each group

**Table 4** Individuals with the *RERE* c.4313\_4318dupTCCACC, p.L1438\_H1439dup variant meet diagnostic criteria for CHARGE syndrome\*

	CHARGE syndrome	Fregeau et al. Subject 2	Subject 7	Subject 8
Major criteria	Coloboma	Unilateral iris coloboma	Unilateral iris coloboma	Unilateral chorioretinal and iris colobomas
	Choanal atresia or cleft palate	Choanal atresia	Bilateral choanal atresia	Bilateral choanal atresia
	Abnormal external, middle or inner ears, including hypoplastic semicircular canals	Simple ears	Low set ears	Small lobules and prominent antihelices, cochlear dysplasia
	Pathogenic <i>CHD7</i> variants	-	-	-
Minor criteria	Cranial nerve dysfunction including hearing loss	-	-	Progressive sensorineural hearing loss
	Dysphagia/feeding	-	N/A	-

	difficulties			
	Structural brain anomalies	Thin corpus callosum, ventriculomegaly, incompletely folded hippocampi, severely diminished white matter volume	Simplified gyration of cerebral cortex, atrophy of the frontal lobes, dysplasia of the inferior olivary and dentate nuclei, ventriculomegaly, multifocal neuroglial heterotopia	
	Developmental delay/intellectual disability/autism	Developmental delay	N/A	Developmental delay, intellectual disability
	Hypothalamo-hypophyseal dysfunction and genital anomalies	Cryptorchidism	Hypospadias	-
	Heart or esophagus malformation	VSD, PDA, APVR	VSD, PFO	Truncus arteriosus
	Renal anomalies	Right-sided multicystic kidney	-	-
	Skeletal/limb anomalies	5th finger clinodactyly with nail hypoplasia	Contractures of the 2nd and 3rd digits	Neuromuscular thoracolumbar scoliosis, bilateral hip dysplasia, bilateral equinus contractures

\* The presence of two major and any number of minor criteria is required to fulfill diagnostic criteria for CHARGE syndrome as described by Hale, et al., 2016.

- = not documented, APVR = anomalous pulmonary venous return, N/A = Not applicable, PDA = patent ductus arteriosus, PFO = patent foramen ovale, VSD = ventricular septal defect.