



ORIGINAL ARTICLE

Estimation of the diagnostic accuracy of clinical parameters for monitoring peri-implantitis progression: An experimental canine study

Alberto Monje^{1,2} | Angel Insua³ | Mia Rakic⁴ | Jose Nart² | Jose Luis Moyano-Cuevas⁵ | Hom-Lay Wang⁶

¹Department of Oral Surgery and Stomatology, ZMK School of Dentistry, Bern, Switzerland

²Department of Periodontology, International University of Catalonia, Barcelona, Spain

³Department of Oral Surgery and Implantology, University of Santiago de Compostela, Santiago de Compostela, Spain

⁴INSERM UMR-1229 RMeS, Faculty of Dental Surgery, University of Nantes, Nantes, France. Institute for Biological Research "Sinisa Stankovic," University of Belgrade, Belgrade, Serbia

⁵Bioengineering and Health Technologies Unit, Jesús Uson Minimally Invasive Surgery Center, Cáceres, Spain

⁶Department of Periodontics and Oral Medicine, University of Michigan School of Dentistry, Ann Arbor, MI

Correspondence

Alberto Monje, DDS, MS,
Department of Oral Surgery, ZMK, School of Dentistry, University of Bern, Freiburgstrasse 7, 3010–Bern (Switzerland).
Email: amonjec@umich.edu

Abstract

Background: Lack of consensus on the clinical parameters of peri-implantitis may complicate accurate diagnosis of the disorder. Furthermore, the lack of reliable estimates of the diagnostic capacity of the clinical endpoints precludes the definition of an effective treatment protocol for peri-implantitis. The present canine study assesses the diagnostic accuracy of the clinical parameters for monitoring the peri-implant tissues in a controlled ligature-induced peri-implantitis model followed by a spontaneous progression phase.

Methods: Six beagle dogs were followed-up on during three episodes of ligature-induced peri-implantitis and a further episode of spontaneous progression. Probing depth (PD), bleeding on probing (BOP), mucosal recession (MR), and suppuration (SUP) were recorded at four sites per implant and at four study timepoints. Moreover, the implant mucosal index (IMI) was calculated at implant level. Marginal bone loss (MBL) was determined using computed tomography at four sites per implant. A linear regression model was used to estimate clinical and radiological parameters during peri-implantitis progression.

Results: Progressive peri-implant bone loss is characterized by an increase in PD, more profuse BOP, MR, and SUP in advanced cases ($p < 0.001$). However, even in the presence of severe bone loss, SUP was not a common finding, with an incidence of approximately 10% at the last timepoint. These clinical parameters were significantly correlated to MBL at most of the timepoints. The IMI, in turn, showed a positive correlation to MBL and the peri-implant inflammatory signs ($r = 0.39$; $p < 0.001$), with a tendency to exhibit higher scores during ligature-induced peri-implantitis, followed by a slight decrease during the spontaneous progression period.

Conclusion: The clinical features of peri-implantitis and spontaneous progression of the disorder may facilitate an accurate monitoring of peri-implant pathologic bone loss.

KEYWORDS

dental implants, diagnosis, implant stability, peri-implant mucositis, peri-implantitis



Over the last two decades there has been considerable controversy regarding the definition of peri-implant diseases, which were initially classified based on the classification of periodontal diseases. Accordingly, peri-implant mucositis was considered a precursor of peri-implantitis, characterized by reversible inflammation of the soft peri-implant tissues.¹ However, no treatment protocol capable of affording complete disease resolution has been established.^{2,3} In turn, as the inflammation spreads towards the bone tissue, peri-implant mucositis transforms into peri-implantitis, which represents a nonreversible condition with a nonlinear progression pattern.^{4,5} Currently, peri-implant diseases are considered to be important in view of their increasing prevalence and the lack of a standard treatment protocol.³ As a result of this situation, studies^{6,7} were conducted to thoroughly explore the causes of this increasing prevalence and to improve the treatment protocols. The primordial observation was a lack of consensus regarding case definition—this resulting in great heterogeneity in the reported prevalence rate of these disorders. In this regard, it was emphasized that the specificity of peri-implant bone remodeling, the lack of periodontal ligament, and implant-related factors contribute to make the diagnosis more complicated in the case of implants compared with the natural dentition.^{8,9} The need for standardization of the clinical diagnostic parameters in implants was therefore underscored as a pivotal precondition for prevention and monitoring, and for the development of novel treatment solutions.

Clinical parameters such as bleeding on probing (BOP), probing depth (PD), mucosal recession (MR), or suppuration (SUP) have been used to monitor peri-implant diseases.⁹ Nevertheless, as commented above, the diagnostic accuracy of peri-implant diseases is not as satisfactory as in the case of periodontal disease. For instance, in the evaluation of PD it seems that the implant design and implant-abutment connection (i.e., standard versus switched platform, one- versus two-piece implants), added to the not so uncommon difficulties in probing because of the prosthesis design and emergence profile, influence the outcome,^{10,11} as there is an increase in laxity of the collagen fibers around the collar of the implant restoration and the implant machined surface.¹² Likewise, a deeper apico-coronal position might be related to deeper PD owing to the greater extent of bone remodeling at least down to the implant-abutment interface.¹¹ On the other hand, greater peri-implant bone loss results from more apical migration of the long junctional epithelium and connective tissue, and probing therefore can be expected to be deeper.^{13,14} Likewise, BOP has been found to be highly specific and with moderate sensitivity, because bleeding was noticed in 67% of the individuals with healthy implants, whereas 91% presented BOP in the presence of peri-implantitis.¹⁴ Along these lines, Fransson et al. noticed BOP in over 90% of the individuals without progressive bone loss.¹⁵ Contrarily, SUP seems to

be a more accurate endpoint in the diagnosis of peri-implant bone loss,¹⁶ because it occurs as a consequence of the host reaction to persistent pathologic stimuli—in this case represented by the bacterial biofilm as the main etiologic factor underlying peri-implantitis. Nonetheless, again the absence of SUP does not necessarily indicate the absence of disease,¹⁷ because the acute phase of the inflammatory process is followed by new connective tissue formation that could mask the condition.¹⁸

Our group has recently published a clinical study on the diagnostic accuracy of clinical parameters for monitoring peri-implant conditions,¹⁹ where it was concluded that the diagnosis of peri-implant diseases does not rely solely on individual clinical parameters but rather on a combination of criteria. Moreover, it was seen that the specificity of the clinical parameters exceeded their sensitivity in detecting peri-implant diseases. The main advantage of animal experimental models in medical research is the ability to measure the parameters and different effects under strict and controlled conditions—this being particularly suitable for estimating the changes in diagnostic parameters and their respective accuracy.⁵ In turn, the measurement of clinical parameters provides information on the characteristics of the experimental model referred to the comparative accuracy and compatibility rates between experimental and naturally occurring conditions. This is of special importance in translational implant research, because the outcomes from preclinical studies in dogs are critical for transfer to humans. Precise knowledge of the accuracy of the model and related evaluation methods is therefore of crucial importance in relation to the safety, efficacy, and cost-effectiveness of the experimental procedures.

The aims of the present study were: 1) To estimate the diagnostic accuracy of the standard clinical parameters in all phases of the ligature-induced peri-implantitis model in the dog, from prodromal stage to progression and chronification; 2) To estimate the impact of implant design upon the measured clinical parameters; and 3) To investigate the influence of the reported site (buccal versus lingual) on progressive peri-implant bone loss.

1 | MATERIALS AND METHODS

The Local Ethical Committee (Government of Extremadura, Health and Social Policy Council, Extremadura, Spain [#2017209030001787]) approved the present study in abidance with the local and European regulations (REGA ES 100370001499). In addition, the research project was conducted following the ARRIVE (Animal Research: Reporting of *In Vivo* Experiments) guidelines developed as part of an NC3Rs initiative to improve the design, analysis, and reporting of research using animals.²¹



1.1 | Experimental design

A randomized, two-arm in vivo animal study involving healthy Beagle dogs ($n = 12$) of approximately 1 year of age was carried out. One-half of the animals were used in a ligature-induced peri-implantitis model ($n = 6$). The dogs were housed under laboratory conditions, with a room temperature of 18–24°C and a relative humidity of 30–70%. The animals were housed in pairs and were freed once daily outside. The light cycle was controlled using an automatic timer (12 hours light, 12 hours dark). The dogs were fed a daily pellet diet to supply all the required nutrients using a metal feeder. Two weeks after the surgical intervention (implant placement stage), food was provided with a certain degree of moisture to facilitate mastication and avoid damaging the edentulous mandibles. Water was supplied using electronic dispensers that were checked daily to ascertain proper function. All the specimens presented intact maxillae, with no general occlusal trauma, oral, viral, or fungal lesions, or periodontal disease.

1.2 | Teeth extraction

Mandibular premolar and molar extractions (PM3, PM4, M1) were performed in the hemiarches of each dog. On the buccal as well as on the lingual aspect of the ridge, minimal full-thickness flaps were raised to expose the marginal portion of the periodontal tissues. The teeth were sectioned in a bucco-lingual direction at the bifurcation using a tungsten carbide burr so that the roots could be individually extracted using a periosteal elevator and forceps, without damaging the bony walls. The wound margins were stabilized with continuous interlocking suture.

1.3 | Placement of implants and healing abutments

Eight weeks after tooth extraction, implant placement was performed randomly. A crestal incision and flattening of the edentulous ridge with a round bur was carried out. Implants were placed following the instructions of the manufacturer. Altogether, 6 implants were inserted per animal (3 on each side to maximize the mesiodistal space between the implants). All implants were placed according to the recommendations of the manufacturer, and were seated in an equi-crestal position, where the interface between the implant-abutment interface was used as landmark in all implants. One-half of the implants were randomly assigned to be placed <1.5 mm from the buccal ridge (thin buccal bone - tbb), and the other half were placed at ≥ 1.5 mm (thick buccal bone - TBB). Moreover, two different implant designs were placed according to their coronal design (rough up to the top | R (TiCare Inhex Mini 3.3 mm, MozoGrau, Valladolid, Spain) versus hybrid design with 1.5 mm of machined surface in the

coronal portion | H (TiCare Inhex Mini 3.3 mm, MozoGrau, Valladolid, Spain)) to study the influence of this variable during the course of peri-implantitis. The flaps were closed, achieving primary closure with interrupted sutures. Six dogs were sacrificed to study physiologic bone resorption of the implants placed at different bucco-lingual positions of the alveolar ridge (group A). No healing abutments were placed in group A. Straight platform healing abutments were positioned 8 weeks after implant placement, using a minimally invasive approach according to the needs to preserve ≥ 2 mm of keratinized mucosa around the implants in group B.

1.4 | Ligature-induced peri-implantitis

After 8 weeks of healing time, silk ligatures were placed around each healing abutment and pushed apically until stopped by the local tissues (group B). The dogs were then fed a soft diet to induce plaque accumulation and provoke peri-implant inflammation and loss of alveolar bone. Additional ligatures were placed and changed, spaced three weeks apart, for a total of three ligature additions (being recorded at timepoints T1, T2, and T3). Lastly, after three weeks, all ligatures were removed (T3, being recorded ligature-free at T4). Oral hygiene remained restricted during the following three weeks to favor the spontaneous progression/remission of peri-implantitis (Figure 1).

1.5 | Clinical assessment

The following clinical parameters were recorded at each timepoint at four sites per implant (mesiobuccal, buccal, distobuccal, and lingual): probing depth under approximately 17 g (PD) using a North Carolina Probe; bleeding on probing (BOP) measured on a scale from 0–3; suppuration (SUP) reported as a dichotomic variable; and mucosal recession (MR) using a North Carolina Probe. Based on these data, the mucosal gingival index (mGI)²² which matched the BOP scale and the implant mucosal index (IMI)²⁰ could be calculated at implant level. Briefly, the recordings were scored from 0–4, where 0 = no bleeding; 1 = minimal, single-point bleeding; 2 = moderate, multipoint bleeding; and 4 = suppuration.

1.6 | Radiographic assessment

All images were obtained using computed tomography (CT) (Phillips Medical System, Eindhoven, The Netherlands) under general anesthesia immediately after every clinical examination. The imaging parameters were set at 120 kV, with an increment of 0.5 mm, a slice thickness of 1 mm, a mAs/slice of 250, collimation 6×0.75 with a matrix of 512, and a field of view (FOV) sufficient to scan the mandibular body.

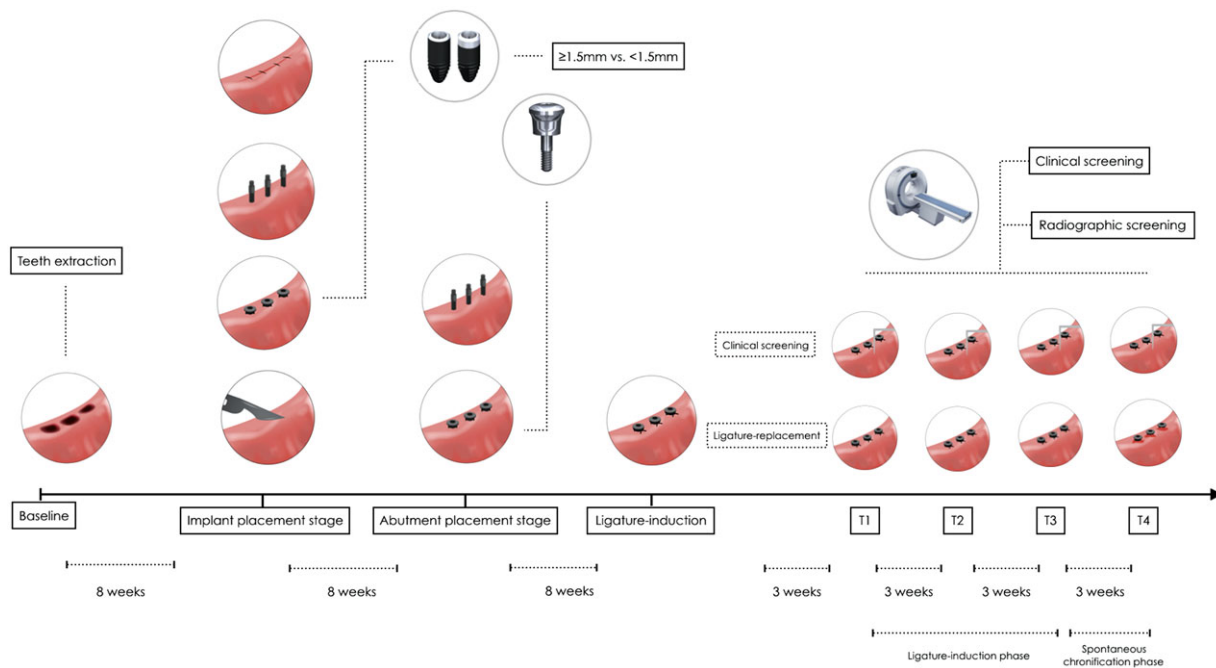


FIGURE 1 Flowchart of the experimental design (adapted from a concomitant submission – under review up to date May 24, 2018 to *Clinical Oral Implants Research* titled “Diagnostic Accuracy of the Implant Stability Quotient in Monitoring Progressive Peri-Implant Bone Loss: An Experimental Study in Dogs” authored by Monje A et al.)

The CT scans of each dog were transferred to a desktop computer with implant planning software. Data were saved in the Digital Imaging and Communications in Medicine (DICOM) format.

1.7 | Buccal/lingual alveolar bone thickness

The Aurora Tracking System (NDI, Waterloo, CA) was used to measure the linear distance between the implants and the buccal/lingual bony plates (supplementary Figure 1 in online *Journal of Periodontology*). Briefly, this system follows the tracking principle in an electromagnetic field, providing in real time the position in space of the sensor with respect to the magnetic field generator of the system. The sensor was placed at the tip of the probe. The precise buccal-most site of the implants (coinciding with the bucco-lingual mid-line) and the outside-most point of the alveolar bone (buccal and lingual bony flanges) were registered, reporting a position within space by applying repetitive measurements (40 \times /second) for 20 seconds. The linear distance between both points was calculated using the Euclidean distance formula.

1.8 | Statistical analysis

Nonlinear Spearman coefficients were applied to evaluate the correlations at implant or site level at a specific timepoint. The Kruskal-Wallis test was used to evaluate the homogeneity

of one of the variables in three or more independent samples defined by the levels of the other.

A linear regression model was generated by generalized estimation equations (GEE) to study marginal bone loss (MBL) and all the clinical parameters at each timepoint. The 95% confidence interval for the coefficients was obtained from Wald's χ^2 statistic. With this model, the correlations between the measurements of each parameter at the four different timepoints and the multiplicity of implants within the same animal could be controlled. The level of significance set in the analyses was 5% ($\alpha = 0.05$).

2 | RESULTS

Overall, 72 implants were inserted in 12 dogs (36 in each group). None of the implants were lost during follow-up. Six dogs (36 implants) underwent three episodes of ligature-induced peri-implantitis and a further episode of spontaneous progression. Data of this study were compiled from these 6 dogs (group B).

2.1 | Clinical parameters during induction and spontaneous progression of peri-implantitis

The progression of the clinical parameters is shown in Figure 2. Marginal bone loss progressed significantly faster buccal compared to lingual at each timepoint, reaching a

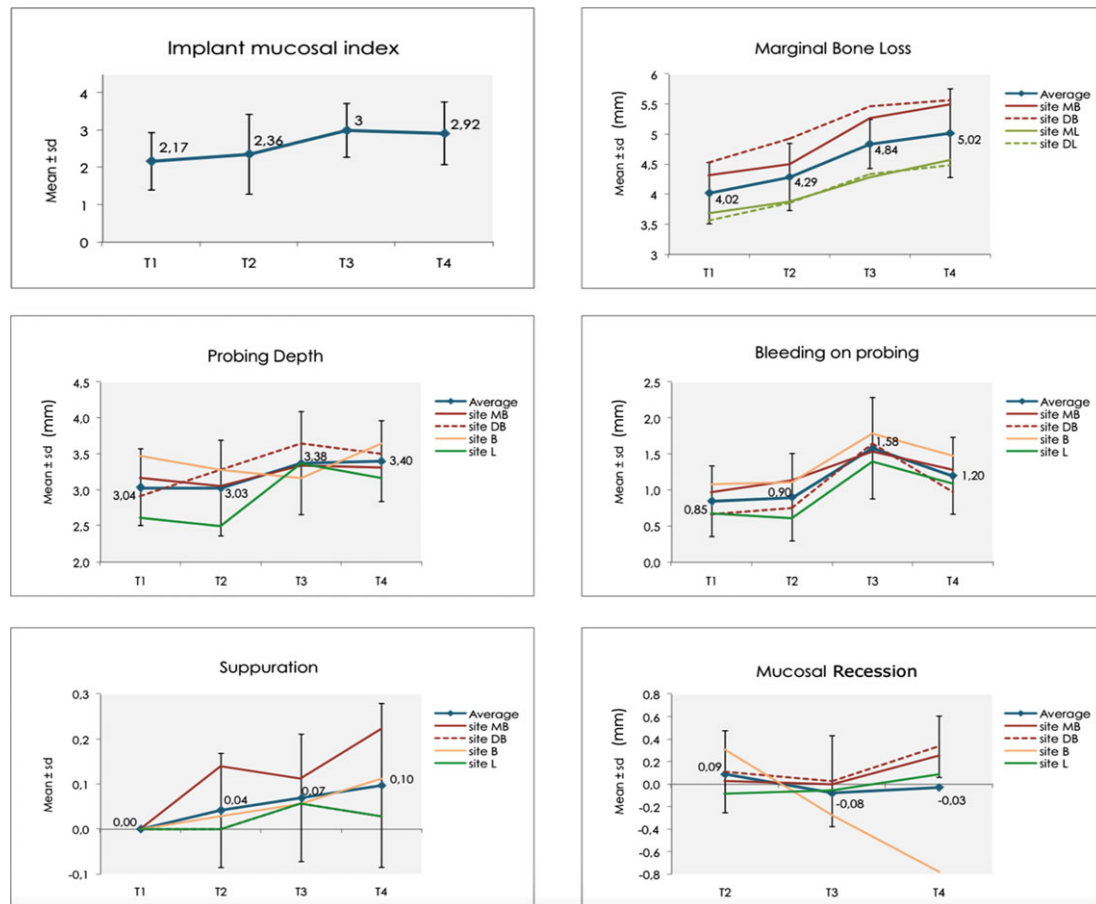


FIGURE 2 Clinical and radiological features of ligature-induced (T1–T3) and spontaneous progression (T4) of peri-implantitis

difference of 1 mm at T4 (5.52 ± 0.86 mm on the buccal side versus 4.52 ± 0.76 mm on the lingual side). The mean PD at T1 reached 3.04 ± 0.53 mm and increased to 3.40 ± 0.56 mm at the end of follow-up. Bleeding on probing (mGI) increased 41.2% from T1 (0.85 ± 0.49) to T4 (1.20 ± 0.53), with maximum BOP (mGI) at T3 (1.58 ± 0.70). Suppuration was not present at any site at T1, though it became more frequent in the later stages, reaching a maximum at T4 (0.10 ± 0.18). Marginal recession at T1 could not be accurately established due to excessive accumulation of plaque and debris. The MR values were 0.09 ± 0.36 mm, -0.08 ± 0.4 mm, and 0.03 ± 0.27 m at T2, T3, and T4, respectively. In turn, the mean IMI score at T1 was 2.17 ± 0.77 , while a significant 34.5% increase to 2.92 ± 0.84 was seen at T4. The maximum value was reached at T3 (3.0 ± 0.72).

2.2 | Correlation between IMI and MBL

The IMI and MBL values (Figure 3) were higher in later than early stages, with a moderate global correlation between both variables ($r = 0.39$; $p < 0.001$). According to timepoints, the strongest correlation was observed at T2 ($r = 0.40$; $p = 0.016$). By using a lineal Wald chi-square test, an MBL of 0.154 mm could be expected for each additional point in IMI score.

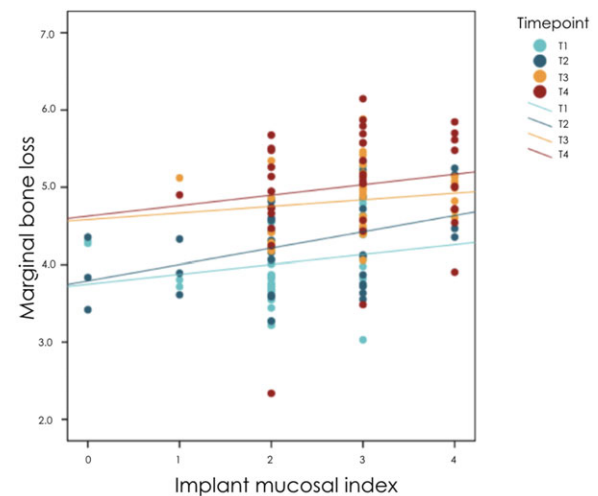


FIGURE 3 Correlation between the implant mucosal index (IMI) and marginal bone loss (MBL)

2.3 | Correlation between IMI and clinical parameters

A moderately significant correlation between IMI and BOP was found at all timepoints, being more intense at T1 ($r = 0.8$, $p < 0.001$). In contrast, the correlation between IMI and PD

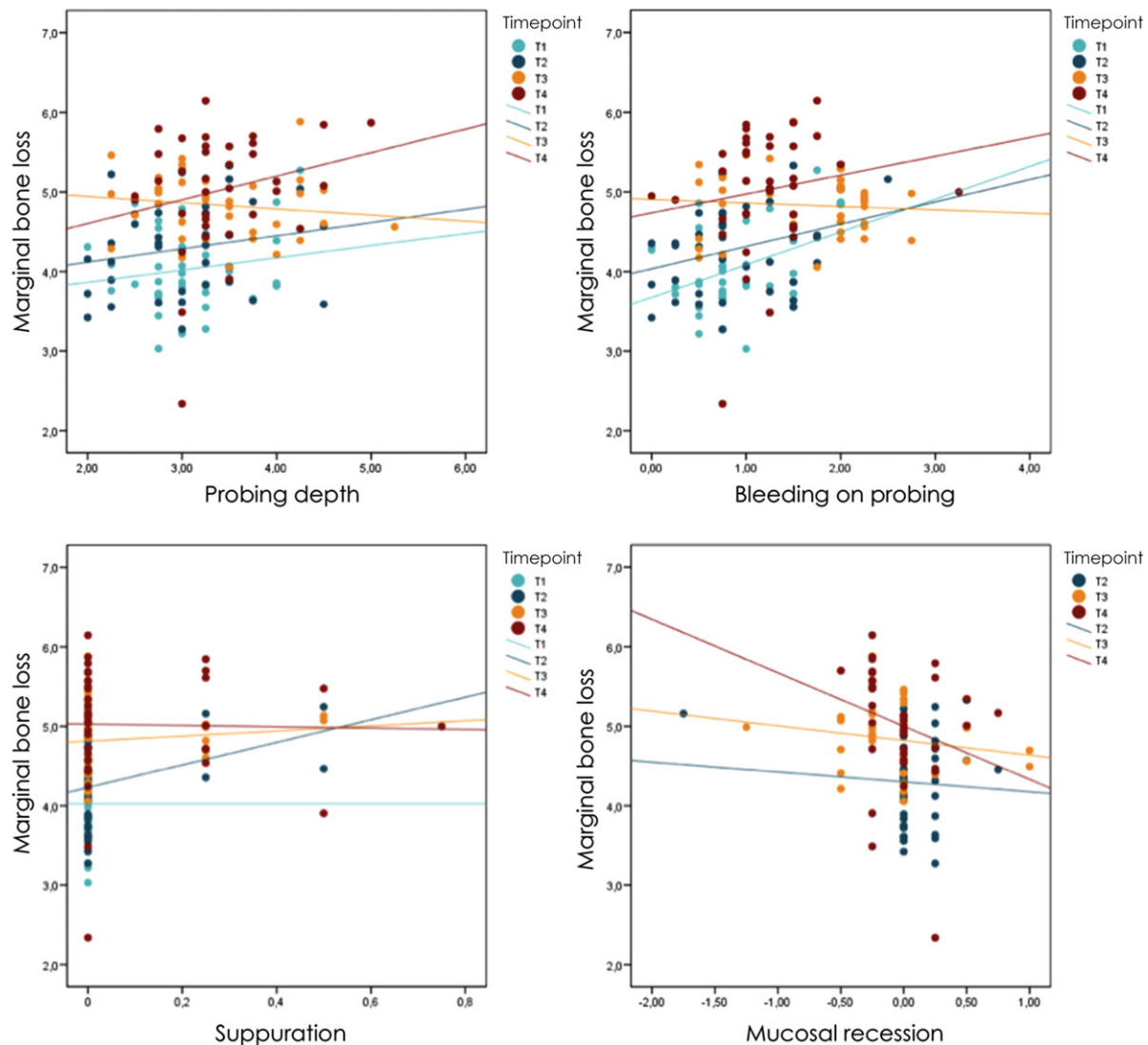


FIGURE 4 Correlation between marginal bone loss (MBL) expressed in mm and the clinical parameters

was stronger at later than at initial stages (T1: $r = 0.14$; T4: $r = 0.53$; $p = 0.001$). Higher IMI scores implied an increase in suppuration score from T2, and the correlation became stronger at both T3 and T4 ($r = 0.81$; $p = 0.001$). On the other hand, IMI and MR showed no clear correlation at any timepoint.

2.4 | Correlation between MBL and clinical parameters

MBL and PD showed a strong positive correlation ($p < 0.001$), though at T3 the correlation was seen to flatten out (Figure 4). This was dictated by the increase in MR at T4 compared to T3. In other words, PD was shallower in the presence of greater MR and vice versa. MBL and BOP (mGI) likewise showed a positive correlation ($p = 0.003$), though with differences depending on the timepoint ($p < 0.001$). A moderately significant association was found at T1 ($r = 0.4$; $p = 0.016$),

with a weaker association at the rest of the timepoints (Figure 4).

The increases in SUP values were associated to greater MBL ($p = 0.001$), though the degree of correlation differed according to the timepoint considered ($p < 0.001$) (Figure 4). The correlation was slightly greater at T2 ($r = 0.32$, $p = 0.059$) and weaker at the other timepoints. The correlation between MBL and MR proved negative, especially at T4 ($r = -0.38$; $p = 0.024$). Generally, positive MR values (as consequence of tumor) implied lower MBL values ($p = 0.001$) at any time during follow-up.

2.5 | Influence of implant design on clinical and radiographic parameters

Neither the clinical nor the radiographic parameters (i.e., MBL) reached significance at any timepoint (Figure 5). However, from T1 to T4 there appeared to be a tendency towards

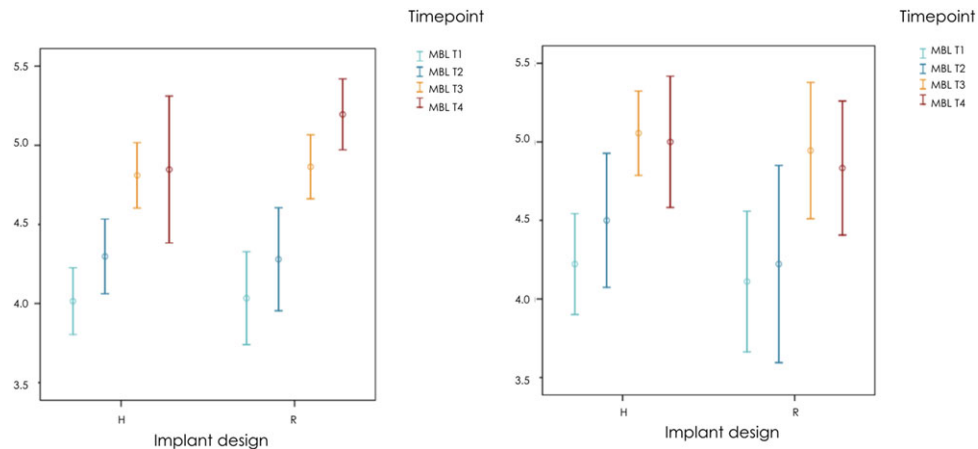


FIGURE 5 Effect of implant design (rough – R versus hybrid – H) upon marginal bone loss (MBL) expressed in mm and the implant mucosal index (IMI)

greater MBL in R compared to H implants. The IMI likewise failed to reach statistical significance ($p > 0.4$) (Figure 5).

3 | DISCUSSION

The present study shows that ligature-induced peri-implantitis and spontaneous progression are characterized by clinical characteristics that can lead to an accurate diagnosis of disease progression. Interestingly, implants placed in an incorrect bucco-lingual position (thin buccal bone) were more prone to be associated with more overt clinical signs and hence to a more definitive disease diagnosis. Moreover, the present study tested two indexes proposed in the classic and recent literature for assessing marginal mucosal conditions.^{20,22} Both indexes demonstrated to be reliable for monitoring peri-implant conditions, since both were strongly correlated to the progression of bone loss.

A recent clinical study evaluated interrater agreement in the diagnosis of peri-implant diseases.²³ Strikingly, only 52% of the examiners reached complete agreement, showing moderate to good agreement referred to PD, MR, and MBL, but poor agreement referred to the assessment of BOP. Indeed, the clinical parameters for diagnosing peri-implantitis have been the subject of discussion, and this may potentially influence the reported prevalence. For instance, Koldslund et al.²⁴ in a clinical study showed that although 74.8% of the individuals presented PD > 4 mm, the prevalence dropped to 43.9% when PD > 6 mm was taken to be the cut-off point for defining peri-implantitis. Likewise, these authors studied the impact of different thresholds for radiographic bone loss in discriminating between disease and health. The results of this study demonstrated that 25.3% of the individuals showed a bone loss of >2 mm. On the other hand, if >3 mm is set as the threshold, only 13.1% of the cases could be defined as corresponding to peri-implantitis.²⁴ In this regard, preclinical

studies have shown that BOP does not seem to offer high diagnostic accuracy, as it may be present under healthy conditions because of the nature of the peri-implant tissues.^{12,13} In 1987, Mombelli et al.²² proposed the mGI based on the profuseness of BOP. Posteriorly, Apse et al.²⁵ based the assessment of marginal mucosal condition on the presence and severity of edema, redness, glazing, ulceration, and bleeding with or without probing. More recently, French et al.²⁰ modified the original scale described by Mombelli et al.²² to overcome the drawback of the poor sensitivity of BOP as a diagnostic criterion of peri-implantitis. This novel scale is based on the presence and extensiveness of bleeding (single-point, moderate multipoint or profuse multipoint). Moreover, this index adds suppuration as the level of highest severity, owing to its strong correlation to more advanced bone loss, as corroborated in the present study ($p < 0.001$). French et al.²⁰ evidenced a statistically significant relationship between inflammation and MBL. In this regard, as the IMI scores became higher, MBL tended to occur more rapidly. Specifically, at 4 years, the IMI score was ≥ 2 , with a mean MBL of 0.33 mm, 0.71 mm, and 1.52 mm for IMI = 2, IMI = 3 and IMI = 4, respectively. The present canine study confirmed the existence of this correlation between IMI and MBL, which was moreover shown to be strong ($r = 0.39$; $p < 0.001$). Additionally, IMI was seen to be correlated to PD, and the strength of the correlation was greater at later than at initial stages (T1: $r = 0.14$; T4: $r = 0.53$; $p = 0.001$). Hence, this study supports the use of IMI for monitoring peri-implantitis, though further human *in vivo* studies are needed to confirm its diagnostic accuracy.

Suppuration is the most specific clinical parameter of peri-implantitis and an indicator of progressive forms of the disease.^{3,9,26,27} In the present study, suppuration was absented at T1 and tended to increase steadily towards T4, which perfectly matches the biological pattern. In this regard, T1 can be considered the phase of infective trauma followed by acute



inflammation, also known as the exudative stage, related to exudation and the migration of neutrophils to the experimental site through the dilated vessels.²⁷ This exudate rich in pro-inflammatory mediators is coordinated with the inflammatory response, initially directed to support neutrophil activity against bacteria and later toward disease chronification.²⁸ Hence, in the initial stages, the exudate remains transparent as manifested by a lack of pus, whereas over time it transforms into the purulent stage as a result of the increase in dead or living leukocytes and pyogenic bacteria, followed by an increased presence of tissue debris.²⁹ This clinically manifests as an increase in exudate turbidity and subsequent pus formation over time. This observation again confirms the specificity of this clinical parameter as well as its limited sensitivity. On the other hand, SUP was positively associated to IMI—the most reliable index in this study—and in the correlation was strongest at T4. Considering the high specificity of SUP, this finding may further support the diagnostic capacity of IMI. Finally, SUP was associated to increased MBL, thus confirming SUP as an indicator of progressive bone loss.

Peri-implant bone loss progressed steadily during the ligature-induced episodes and the spontaneous progression of peri-implantitis. At the end of follow-up (T4), the mean MBL was 5.02 ± 0.74 mm. Similar radiographic values have been previously reported (5.73 ± 0.55 mm and 5.54 ± 0.96 mm for moderately rough and polished implants, respectively).³⁰ In the mentioned study the radiologic measurements were based on periapical X-rays in which the buccal and lingual bony flanges were disregarded. In this regard, CT and CBCT are accurate diagnostic tools for measuring the histologic extent of peri-implantitis defects.³¹ Albouy et al.³² assessed the spontaneous progression of peri-implantitis in different types of implants. During the period of active breakdown, slightly lower MBL was found (ranging from 3.53 ± 1.04 mm to 4.69 ± 0.52 mm). Likewise, Carcuac et al.³³ recorded a mean MBL of 2.69 ± 0.57 mm and 3.14 ± 0.69 mm during the induction of peri-implantitis with two different types of implants. On the other hand, substantially greater values were reported after 60 days of induction using four different implant surfaces (6.00 ± 0.70 mm, 6.06 ± 0.27 mm, 6.22 ± 0.50 mm, and 6.32 ± 0.33 mm for pure titanium, titanium plasma sprayed, hydroxyapatite and acid-etched surfaces, respectively).³⁴ In partial accordance, the present study found that although statistical significance was not reached, peri-implantitis progresses to a greater extent in R implants (5.20 ± 0.45 mm) than in H implants (4.85 ± 0.93 mm).

As a consequence of the shorter spontaneous progression phase involved, we recorded less MBL (0.18 mm) compared with other studies.^{30,31} In this regard, Berglundh et al.³⁰ observed a mean MBL of 0.07 mm with polished implants and 1.12 mm with moderately rough surfaced implants during a 5-month period without ligatures. Significantly greater values up to 2.78 mm were reported in a four-month period

in another study by the same research group.³² Statistically significant differences were found between two implant surfaces in the spontaneous phase, with an additional bone loss of 0.02 ± 0.66 mm and 1.34 ± 1.19 mm, respectively.³³ Again, differences between surfaces, study periods, study design and cleaning protocols could account for the slightly different findings in the progression of peri-implantitis. Moreover, it must be highlighted that because of the primary objective of the present study, the implants were not placed within the ideal alveolar bucco-lingual position. This fact may explain the greater rapidness and aggressiveness of the peri-implantitis progression in the buccal versus the lingual sites.

There is controversy regarding the lack of tissue response related to different implant surfaces.^{35,36} In any case, as previously discussed,³⁷ the ligature-induced peri-implantitis model—like all experimental designs—does not fully simulate the naturally occurring condition, and therefore poses certain limitations. In this respect, the type and position of the ligature, the frequency of replacement, and the cleaning protocol used may result in different degrees of MBL and tissue reaction, as evidenced by the studies found in the literature. However, because translational studies referred to peri-implantitis treatment traditionally use dog models before application to humans, the present study offers the added value of defining exact clinical characteristics and diagnostic ranges of the clinical parameters in the canine model.

4 | CONCLUSION

Progressive peri-implantitis is characterized by clinical features that may facilitate accurate monitoring of peri-implant pathologic bone loss. Ligature-induced and spontaneous progressive bone loss evolve more rapidly and more aggressively at the buccal sites versus the lingual counterparts. Further, implant mucosal index appears to be a promising tool for the monitoring the peri-implant conditions.

ACKNOWLEDGMENTS

The authors thank TICARE Implants (Mozo Grau, Valladolid, Spain) for funding of the study. Furthermore, the FEDICOM foundation partially funded the study by providing surgical instruments, supplying accommodation and covering traveling expenses of the principal investigator (Dr. Alberto Monje). Thanks are also due to Francisco Javier Vela (Centro de Cirugía Mínimamente Invasiva Jesús Usón, Cáceres, Spain) for his professionalism and kindness in housing the dogs. In addition, the primary authors thank Dr. Alva Pérez (Center of Implantology CICOM, Badajoz, Spain) and Dr. Blanca Monje-Melero (Center of Implantology CICOM, Badajoz, Spain) for their assistance during surgery and data management.



DISCLAIMER

The authors do not have any direct financial interests with the products and instruments listed in the paper. Dr. A. Monje received lecture honorariums and research funding/grants from MozoGrau (Valladolid, Spain) to conduct the present study.

REFERENCES

- Salvi GE, Aglietta M, Eick S, Sculean A, Lang NP, Ramseier CA. Reversibility of experimental peri-implant mucositis compared with experimental gingivitis in humans. *Clin Oral Implants Res.* 2012;23:182–190.
- Schwarz F, Becker K, Sager M. Efficacy of professionally administered plaque removal with or without adjunctive measures for the treatment of peri-implant mucositis. A systematic review and meta-analysis. *J Clin Periodontol.* 2015;42(Suppl 16):S202–213.
- Figuerio E, Graziani F, Sanz I, Herrera D, Sanz M. Management of peri-implant mucositis and peri-implantitis. *Periodontology 2000.* 2014;66:255–273.
- Papantonopoulos G, Gogos C, Housos E, Bountis T, Loos BG. Peri-implantitis: a complex condition with non-linear characteristics. *J Clin Periodontol.* 2015;42:789–798.
- Sanz M, Chapple IL, Working Group 4 of the VEWoP. Clinical research on peri-implant diseases: consensus report of Working Group 4. *J Clin Periodontol.* 2012;39(Suppl 12):202–206.
- Derks J, Tomasi C. Peri-implant health and disease. A systematic review of current epidemiology. *J Clin Periodontol.* 2015;42(Suppl 16):S158–171.
- Atieh MA, Alsabeeha NH, Faggion CM, Jr, Duncan WJ. The frequency of peri-implant diseases: a systematic review and meta-analysis. *J Periodontol.* 2013;84:1586–1598.
- Lang NP, Berglundh T, Working Group 4 of Seventh European Workshop on P. Periimplant diseases: where are we now?—Consensus of the Seventh European Workshop on Periodontology. *J Clin Periodontol.* 2011;38(Suppl 11):178–181.
- Salvi GE, Lang NP. Diagnostic parameters for monitoring peri-implant conditions. *Int J Oral Maxillofac Implants.* 2004;19(Suppl):116–127.
- Caram SJ, Huynh-Ba G, Schoolfield JD, Jones AA, Cochran DL, Belser UC. Biologic width around different implant-abutment interface configurations. A radiographic evaluation of the effect of horizontal offset and concave abutment profile in the canine mandible. *Int J Oral Maxillofac Implants.* 2014;29:1114–1122.
- Hermann JS, Buser D, Schenk RK, Schoolfield JD, Cochran DL. Biologic width around one- and two-piece titanium implants. *Clin Oral Implants Res.* 2001;12:559–571.
- Ericsson I, Lindhe J. Probing depth at implants and teeth. An experimental study in the dog. *J Clin Periodontol.* 1993;20:623–627.
- Schou S, Holmstrup P, Stoltze K, Hjorting-Hansen E, Fiehn NE, Skovgaard LT. Probing around implants and teeth with healthy or inflamed peri-implant mucosa/gingiva. A histologic comparison in cynomolgus monkeys (*Macaca fascicularis*). *Clin Oral Implants Res.* 2002;13:113–126.
- Lang NP, Wetzel AC, Stich H, Caffesse RG. Histologic probe penetration in healthy and inflamed peri-implant tissues. *Clin Oral Implants Res.* 1994;5:191–201.
- Fransson C, Wennstrom J, Berglundh T. Clinical characteristics at implants with a history of progressive bone loss. *Clin Oral Implants Res.* 2008;19:142–147.
- Ostman PO, Hellman M, Sennerby L. Ten years later. Results from a prospective single-centre clinical study on 121 oxidized (TiUnite) Branemark implants in 46 patients. *Clin Implant Dent Relat Res.* 2012;14:852–860.
- Roos-Jansaker AM, Renvert H, Lindahl C, Renvert S. Nine- to fourteen-year follow-up of implant treatment. Part III: factors associated with peri-implant lesions. *J Clin Periodontol.* 2006;33:296–301.
- Lack CH. Some biological and biochemical consequences of inflammation in connective tissue. *Biochem Pharmacol.* 1968(Suppl):197–203.
- Monje A, Caballé-Serrano J, Nart J, Peñarrocha D, Wang H-L, Rakic M. Diagnostic accuracy of clinical parameters to monitor peri-implant conditions: a matched case-control study. *J Periodontol.* 2018;407–417.
- French D, Cochran DL, Ofec R. Retrospective cohort study of 4,591 Straumann implants placed in 2,060 patients in private practice with up to 10-year follow-up: the relationship between crestal bone level and soft tissue condition. *Int J Oral Maxillofac Implants.* 2016;31:e168–e178.
- Kilkenny C, Browne W, Cuthill IC, Emerson M, Altman DG, Group NCRGW. Animal research: reporting in vivo experiments: the ARRIVE guidelines. *J Gene Med.* 2010;12:561–563.
- Mombelli A, van Oosten MA, Schurch E, Jr, Land NP. The microbiota associated with successful or failing osseointegrated titanium implants. *Oral Microbiol Immunol.* 1987;2:145–151.
- Merli M, Bernardelli F, Giulianelli E, et al. Inter-rater agreement in the diagnosis of mucositis and peri-implantitis. *J Clin Periodontol.* 2014;41:927–933.
- Koldstad OC, Scheie AA, Aass AM. Prevalence of peri-implantitis related to severity of the disease with different degrees of bone loss. *J Periodontol.* 2010;81:231–238.
- Apse P, Zarb GA, Schmitt A, Lewis DW. The longitudinal effectiveness of osseointegrated dental implants. The Toronto Study: peri-implant mucosal response. *Int J Periodontics Restorative Dent.* 1991;11:94–111.
- Monje A, Wang HL, Nart J. Association of preventive maintenance therapy compliance and peri-implant diseases: a cross-sectional study. *J Periodontol.* 2017;88:1030–1041.
- Kumar R, Clermont G, Vodovotz Y, Chow CC. The dynamics of acute inflammation. *J Theor Biol.* 2004;230:145–155.
- Wright HL, Moots RJ, Bucknall RC, Edwards SW. Neutrophil function in inflammation and inflammatory diseases. *Rheumatology.* 2010;49:1618–1631.
- Muller WA. Getting leukocytes to the site of inflammation. *Vet Pathol.* 2013;50:7–22.
- Berglundh T, Gotfredsen K, Zitzmann NU, Lang NP, Lindhe J. Spontaneous progression of ligature induced peri-implantitis at



- implants with different surface roughness: an experimental study in dogs. *Clin Oral Implants Res.* 2007;18:655–661.
31. Golubovic V, Mihatovic I, Becker J, Schwarz F. Accuracy of cone-beam computed tomography to assess the configuration and extent of ligature-induced peri-implantitis defects. A pilot study. *Oral Maxillofac Surg.* 2012;16:349–354.
 32. Albouy JP, Abrahamsson I, Persson LG, Berglundh T. Spontaneous progression of peri-implantitis at different types of implants. An experimental study in dogs. I: clinical and radiographic observations. *Clin Oral Implants Res.* 2008;19:997–1002.
 33. Carcuac O, Abrahamsson I, Albouy JP, Linder E, Larsson L, Berglundh T. Experimental periodontitis and peri-implantitis in dogs. *Clin Oral Implants Res.* 2013;24:363–371.
 34. Martins MC, Shibli JA, Abi-Rached RS. Progression of experimental chronic peri-implantitis in dogs: clinical and radiographic evaluation. *J Periodontol.* 2005;76:1367–1373.
 35. Pongnarisorn NJ, Gemmell E, Tan AE, Henry PJ, Marshall RI, Seymour GJ. Inflammation associated with implants with different surface types. *Clin Oral Implants Res.* 2007;18:114–125.
 36. Battula S, Lee JW, Wen HB, Papanicolaou S, Collins M, Romanos GE. Evaluation of different implant designs in a ligature-induced peri-implantitis model: a canine study. *Int J Oral Maxillofac Implants.* 2015;30:534–545.
 37. Berglundh T, Zitzmann NU, Donati M. Are peri-implantitis lesions different from periodontitis lesions?. *J Clin Periodontol.* 2011;38(Suppl 11):188–202.

SUPPORTING INFORMATION

Additional supporting information may be found online in the Supporting Information section at the end of the article.

How to cite this article: Monje A, Insua A, Rakic M, Nart J, Moyano-Cuevas JL, Wang H-L. Estimation of the diagnostic accuracy of clinical parameters for monitoring peri-implantitis progression: An experimental canine study. *J Periodontol.* 2018;89:1442–1451. <https://doi.org/10.1002/JPER.18-0081>