

A Technique to Simultaneously Fabricate Multiple Custom Impression Posts for Implant-Supported Restorations in the Esthetic Zone

Running Title

A Technique to Fabricate Custom Implant Impression Posts

Authors (First[Given name] Middle Last[Family name])

Yuan-Lynn Hsieh, MS, DDS,¹ Sharon Aronovich, DMD, FRCD(C), FACS,² Stephanie Munz, DDS,³ & Fei Liu, DDS, PhD, FACP¹

Institutions

¹Department of Biologic & Materials Sciences and Prosthodontics, University of Michigan School of Dentistry, Ann Arbor, MI

²Department of Oral and Maxillofacial Surgery, University of Michigan School of Dentistry, Ann Arbor, MI

³Department of Oral and Maxillofacial Surgery/Hospital Dentistry, University of Michigan School of Dentistry, Ann Arbor, MI

Correspondence: Fei Liu, University of Michigan School of Dentistry – BMSP, 1011 N University Ave., Ann Arbor, MI 48109. E-mail: feiliu@umich.edu.

Accepted January 30, 2019

The authors deny any conflicts of interest related to this study.

ABSTRACT

Peri-implant transmucosal tissue, an essential element of peri-implant esthetics, is critical to the success of prostheses in the esthetic zone. The optimal transmucosal tissue profile can be transferred to the master cast with the aid of custom impression posts. In this clinical technique, the initial cast used to fabricate interim prostheses was conveniently used to aid in the time-efficient fabrication of multiple custom impression posts simultaneously using self-cured acrylic resin. This technique also applies to single restorations. In addition, the use of an initial cast as holder makes it easy to transfer custom impression posts to the mouth accurately and efficiently.

This is the author manuscript accepted for publication and has undergone full peer review but has not been through the copyediting, typesetting, pagination and proofreading process, which may lead to differences between this version and the [Version of Record](#). Please cite this article as [doi: 10.1111/jopr.13031](https://doi.org/10.1111/jopr.13031).

This article is protected by copyright. All rights reserved.

Keywords: Emergence profile; impression coping; peri-implant; soft tissue.

An implant-supported prosthesis has become the standard of care to restore missing tooth/teeth in the esthetic zone. In addition to proper 3D placement of the implant, the amount and quality of surrounding soft tissue also plays a critical role in the optimal esthetic outcomes.^{1,2} The peri-implant soft tissue is initially developed by surgical modalities such as tissue grafting and second-stage implant surgery; however, without the assistance of interim prostheses, it is difficult to form an optimally scalloped gingival contour, which is in harmony with tissues around natural teeth, around the implant.³ The interim prosthesis can guide soft-tissue healing if it is delivered at the same time as the surgical procedures such as implant placement or second-stage implant surgery.⁴⁻⁶ The adjustments of the emergence profile of an interim prosthesis would continuously optimize the shape and architecture of the surrounding tissue via the mechanism of dynamic compression³ or selective pressure.⁷

With the aid of implant provisional restorations, the architecture of transmucosal tissue around implants and interdental papilla could be optimally sculpted in 8 weeks.⁸ The result of implant restoration in the esthetic zone is greatly influenced by the quality of the master cast, which should accurately duplicate the position of implants and contour of both teeth and transmucosal soft tissue. A proper impression technique is critical for accurate transfer of the tissue architecture from mouth to cast. Nonetheless, the stock impression post is cylinder-shaped, and it cannot support the transmucosal soft tissue while making an impression. Several clinical techniques have been reported regarding the precise registration of peri-implant soft tissue.

First, a direct custom impression post technique using flowable composite resin to fill the peri-implant crevicular space intraorally was proposed⁹⁻¹⁰ This technique is simple and straightforward; however, tissue collapse and irritation are the most common clinical concerns. Second, an implant provisional crown can be used as the definitive impression post to record the emergence profile accurately.^{11,12} However, the clinician must keep the interim prosthesis while

pouring the master cast, which increases the patient's chair time and the risk of damaging the interim prosthesis.

Third, a custom impression post can be fabricated indirectly outside the mouth by registering the emergence profile of provisional crowns using a small container or analog holder.^{13,14} The shape of the emergence profile recorded by provisional crowns can be transferred to the impression post using acrylic resin. Using this technique it is difficult to determine the correct orientation of post in mouth, and a reference position must be marked. This technique also requires the repeated procedure to fabricate each individual custom post in the case of multiple single implant crowns or an implant-supported fixed partial denture (FPD), and can be very time-consuming.

Fourth, a provisional implant-supported FPD can be inserted onto the final cast using a stock impression post; the portion of the impression representing peri-implant soft tissue is replaced later using additional steps.¹⁵ This technique offers a novel approach to record the gingival configuration around a provisional implant-supported FPD; however, the prolonged treatment time and the need to keep the interim prosthesis in association with this method call for additional approaches to meet clinical needs.

To simplify the fabrication of custom impression posts, especially in the scenarios of multiple single implant crowns or an implant-supported FPD, an efficient, practical, and easy technique to register the transmucosal tissue using the initial cast as fabricating base is presented in this article. The advantages of the technique include one-time fabrication of multiple custom impression posts and straightforward transfer of impression posts to the mouth. The disadvantage of this technique is the necessity to keep the initial cast, which was used to fabricate the interim prosthesis.

TECHNIQUE

1. Keep the initial cast on which the interim prostheses were made.

2. After having achieved the desired esthetic result using the interim prostheses, disconnect the provisional implant restorations from the mouth and connect them to the implant analogs (conical connection implant analog, Nobel Biocare US, Raleigh, NC) on the initial cast after the removal of the artificial gingivae (Fig 1).
3. Apply addition reaction silicone elastomeric impression material (Reprosil Putty; Dentsply, York, PA) to fill the gap between the cast and the cervical third of the provisional implant prostheses (Fig 2).
4. Disconnect the provisional implant prostheses from the cast. The emergence profile of the provisional implant restoration will be accurately captured by the silicone impression material (Fig 3).
5. Connect stock impression transfer posts (Nobel Biocare US) to the cast (Fig 4).
6. Fill the space between the silicone material and impression post with autopolymerizing acrylic resin (Pattern Resin LS; GC America, Alsip, IL) to duplicate the emergence profile of all interim prostheses at the same time (Fig 5).
7. Disconnect the custom impression posts and smooth the surface (Fig 6).
8. Seat the custom impression posts back to the cast after adjustment and transfer them to the mouth one by one according to the corresponding implant position (Fig 7). Direct transfer of custom posts from cast to mouth facilitates the easy and accurate orientation of the custom impression posts in the mouth with less chance of misorientation.
9. After confirming the satisfactory seating of the custom impression posts by radiograph, the patient is ready for definitive impression. The vinylpolysiloxane impression material and the custom impression posts together register the teeth contour, soft tissue architecture, and the implant position. The master cast made from the definitive impression features the accurate

duplication of the transmucosal tissue contour around implants in the patient's mouth, providing excellent reference to the dental laboratory for the fabrication of the definitive prosthesis (Fig 8).

SUMMARY

This clinical technique describes a method to fabricate custom impression posts using the initial cast as fabricating base. Compared to other reported approaches, this technique offers a simple approach to simultaneously fabricate multiple custom impression posts in the treatment of patients requiring multiple single implant crowns or implant-supported FPDs. In addition, transferring the custom impression post directly from the initial cast to the mouth reduces the chance of misorientation. With this technique, the architecture of transmucosal tissue will be efficiently and accurately transferred to the master cast for the fabrication of the definitive prosthesis.

References

1. Grunder U, Gracis S, Capelli M: Influence of the 3-D bone-to-implant relationship on esthetics. *Int J Periodontics Restorative Dent* 2005;25:113-119
2. Levine RA, Ganeles J, Gonzaga L, et al: 10 keys for successful esthetic-zone single immediate implants. *Compend Contin Educ Dent* 2017;38:248-260
3. Wittneben JG, Buser D, Belser UC, et al: Peri-implant soft tissue conditioning with provisional restorations in the esthetic zone: the dynamic compression technique. *Int J Periodontics Restorative Dent* 2013;33:447-455
4. Jansen CE: Guided soft tissue healing in implant dentistry. *J Calif Dent Assoc* 1995;23:57-58, 60, 62 passim
5. Touati B: Custom-guided tissue healing for improved aesthetics in implant-supported restorations. *Int J Dent Symp* 1995;3:36-39
6. Hinds KF: Custom impression coping for an exact registration of the healed tissue in the esthetic implant restoration. *Int J Periodontics Restorative Dent* 1997;17:584-591
7. Nam J, Aranyarachkul P: Achieving the optimal peri-implant soft tissue profile by the selective pressure method via provisional restorations in the esthetic zone. *J Esthet Restor Dent* 2015;27:136-144

8. Alshiddi IF, Dent DC: Accurate registration of peri-implant soft tissues to create an optimal emergence profile. *Contemp Clin Dent* 2015;6:S122-125
9. Polack MA: Simple method of fabricating an impression coping to reproduce peri-implant gingiva on the master cast. *J Prosthet Dent* 2002;88:221-223
10. Schoenbaum TR, Han TJ: Direct custom implant impression copings for the preservation of the pontic receptor site architecture. *J Prosthet Dent* 2012;107:203-206
11. Attard N, Barzilay I: A modified impression technique for accurate registration of peri-implant soft tissues. *J Can Dent Assoc* 2003;69:80-83
12. Tsai BY: A method for obtaining peri-implant soft-tissue contours by using screw-retained provisional restorations as impression copings: a clinical report. *J Oral Implantol* 2011;37:605-609
13. Paranhos KS, Oliveira R: An impression technique to accurately transfer soft tissue contours for implant-supported restorations: three case reports. *J Oral Implantol* 2001;27:317-321
14. Patras M, Martin W: Simplified custom impression post for implant-supported restorations. *J Prosthet Dent* 2016;115:556-559
15. Yiqing H, Yuting H, Wang J: A technique to record the gingival configuration of an interim implant-supported fixed partial denture. *J Prosthet Dent* 2018;120:495-497

Figure 1. Interim prostheses secured on the initial cast after the removal of artificial gingivae.

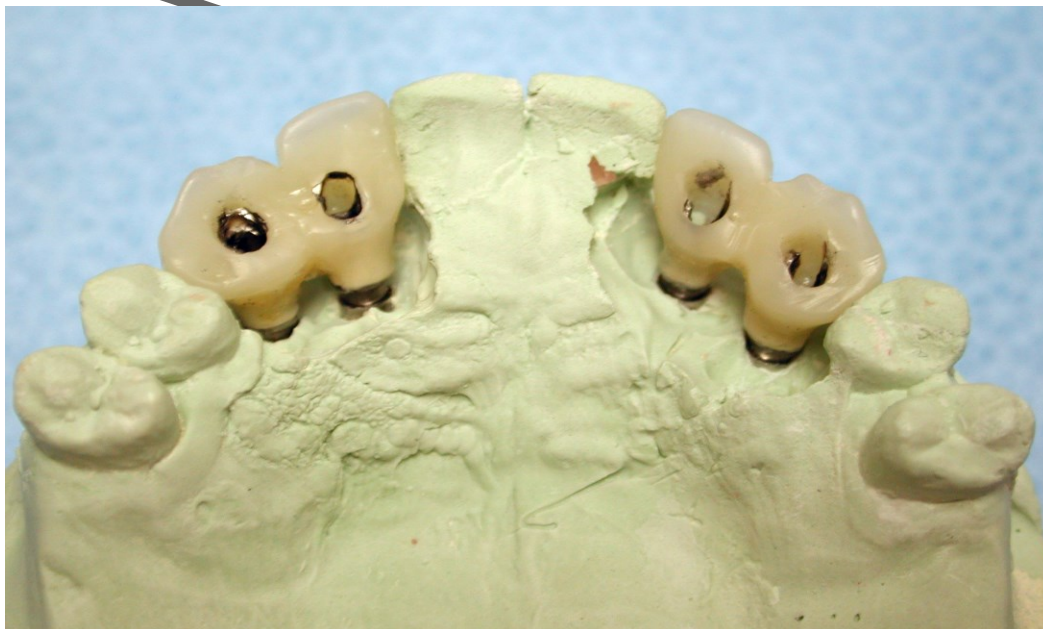

Figure 2. Silicone impression material is used to register the emergence profile of the interim prostheses.

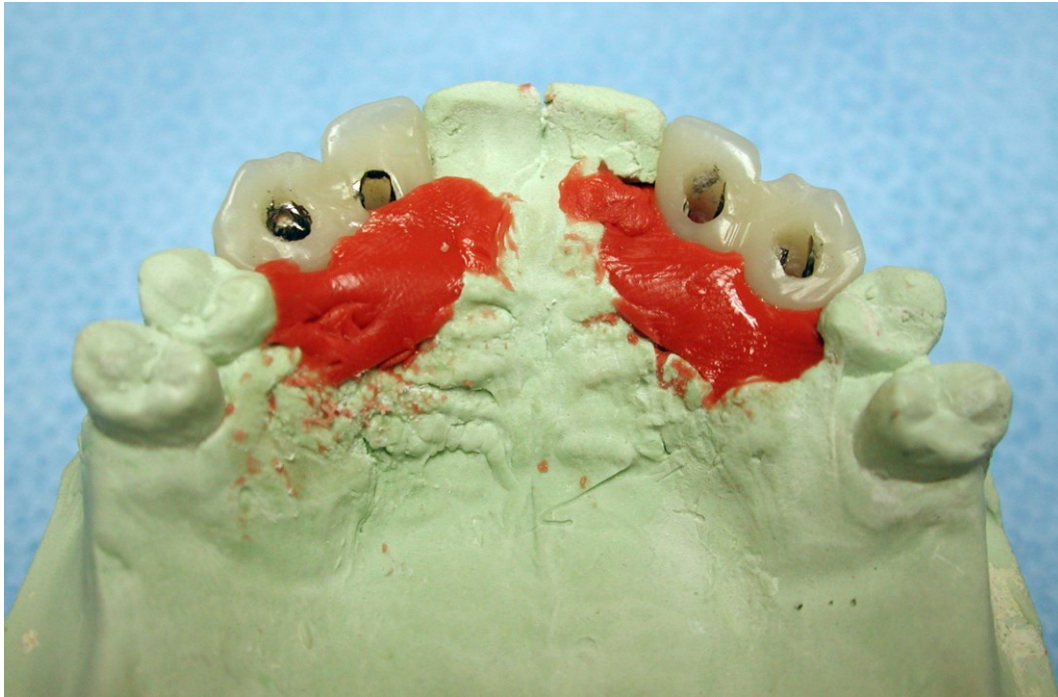

Figure 3. Space created after the removal of the provisional prostheses.

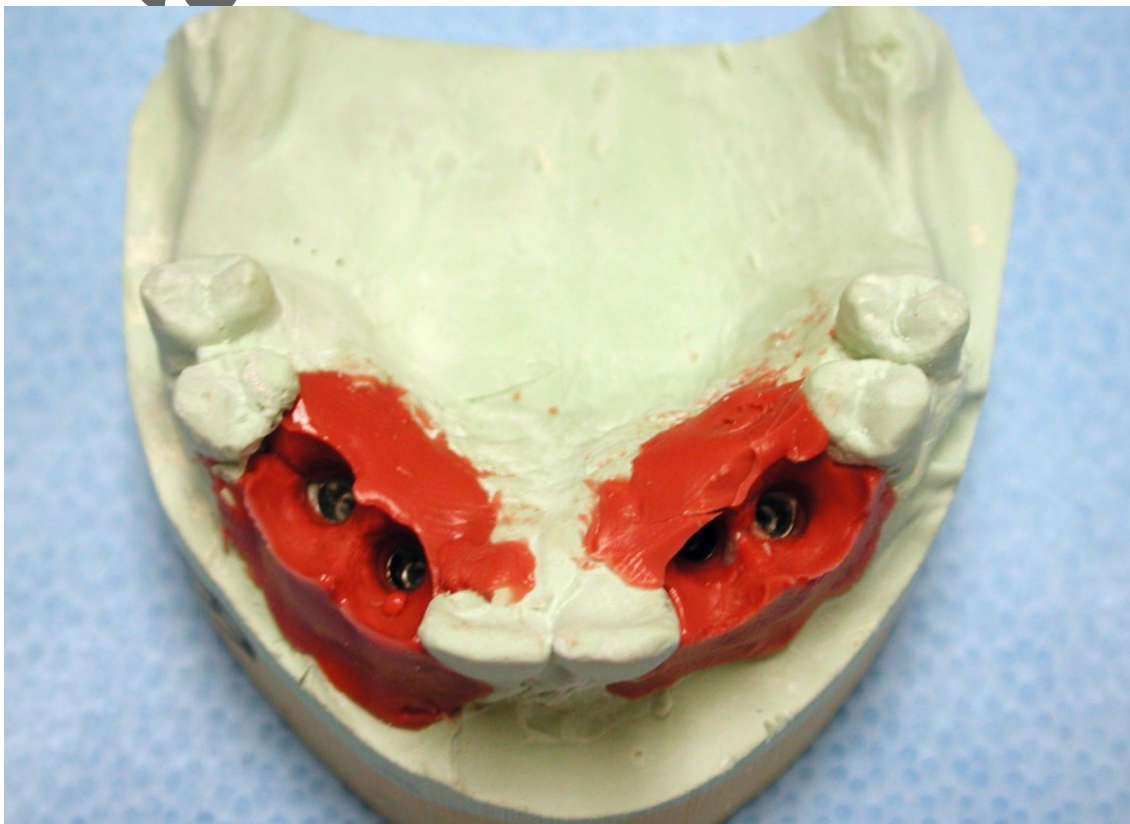

Figure 4. Connect stock impression posts to the initial cast.

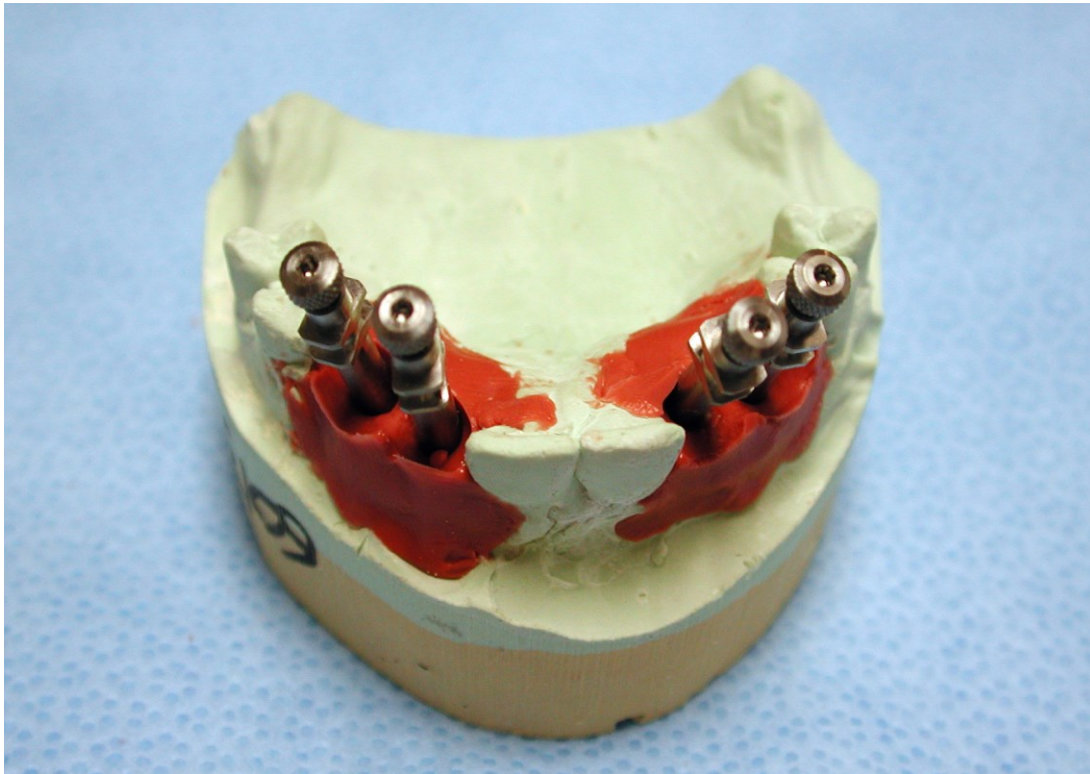


Figure 5. Fill the transmucosal gap with acrylic resin. All the custom impression posts are fabricated simultaneously.

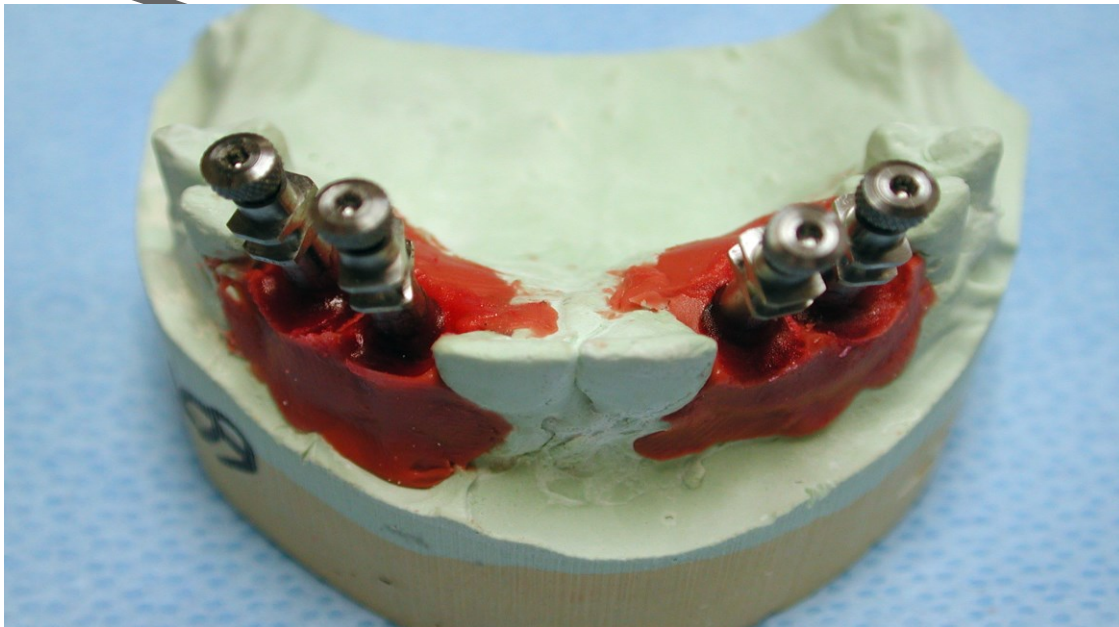


Figure 6. Impression posts removed and smoothed.



Figure 7. Custom impression posts are transferred directly from initial cast to mouth one by one using their positions on the cast as reference.

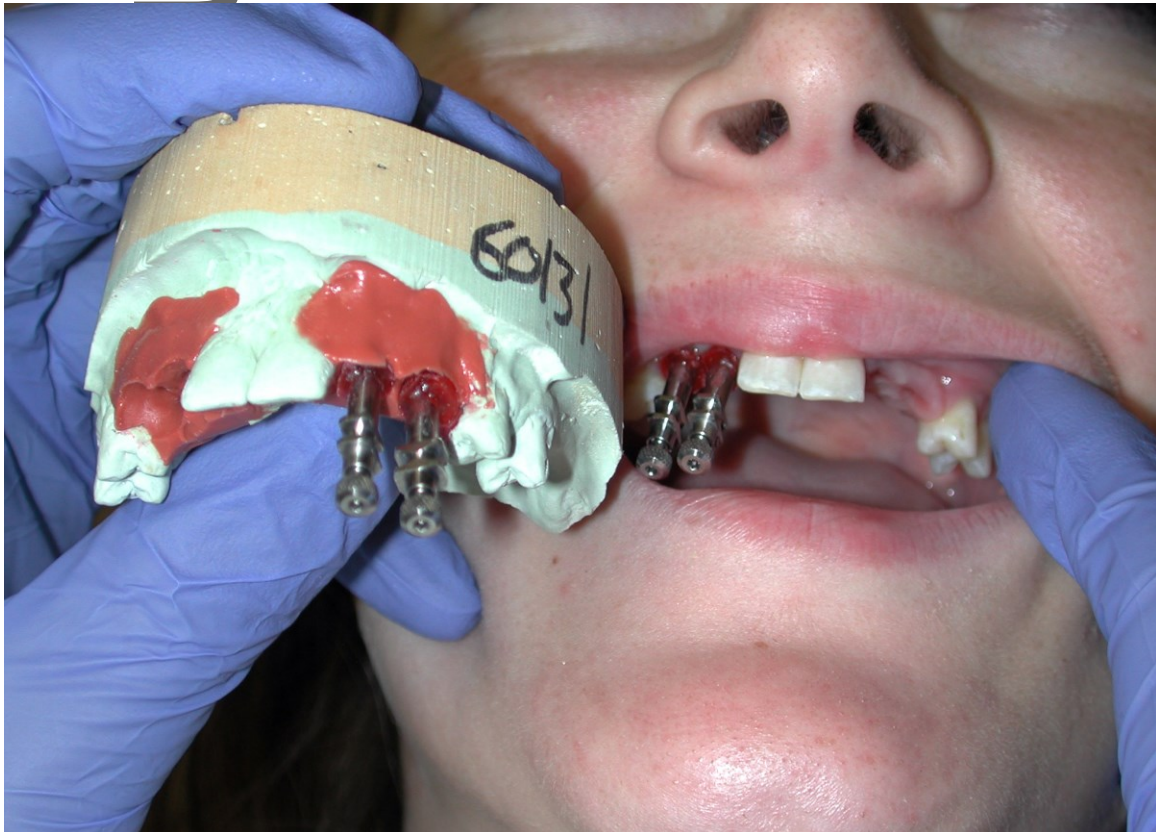
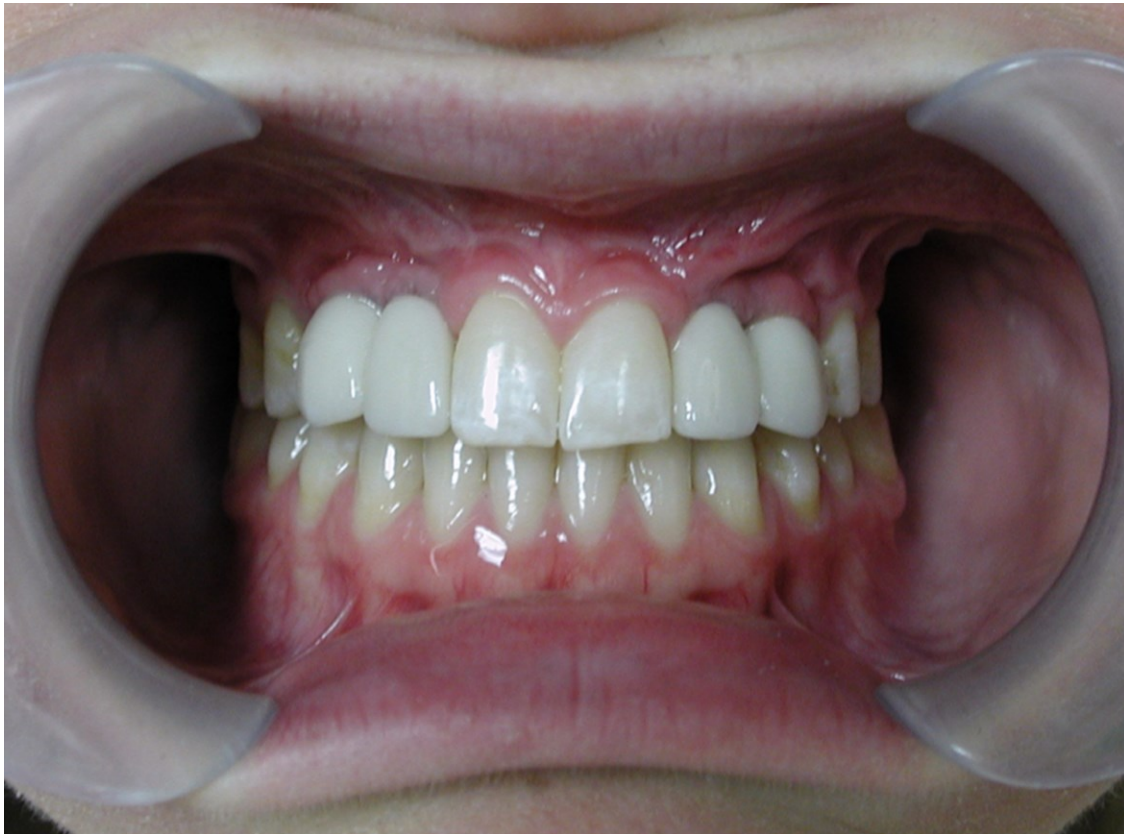
Figure 8. Frontal view of definitive restorations on left and right maxillary lateral incisors and canines.



Author M