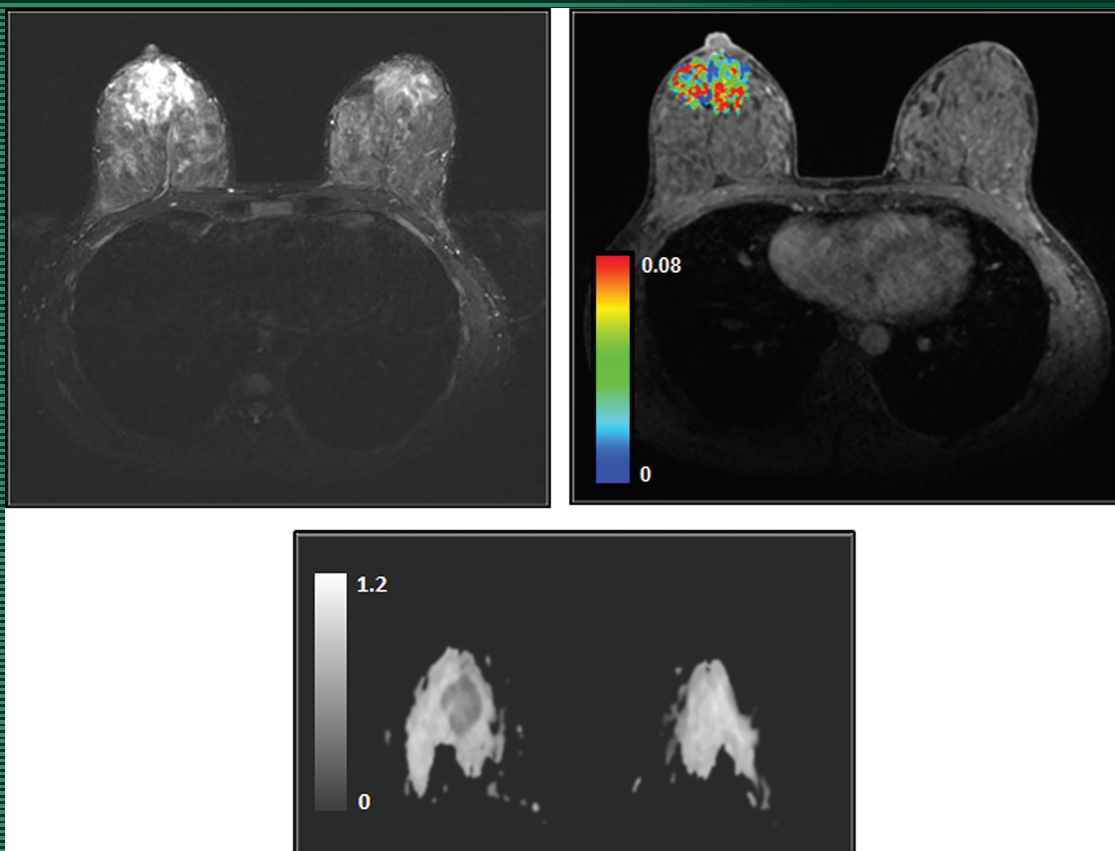


# JMIRI

Journal of Magnetic Resonance Imaging

AN OFFICIAL JOURNAL OF THE INTERNATIONAL SOCIETY FOR MAGNETIC RESONANCE IN MEDICINE

SPECIAL ISSUE ON THE VALUE OF MRI



REPRESENTATIVE MR IMAGES FROM A BREAST CANCER PATIENT (34 YEARS OLD, FEMALE) WITH GRADE II INVASIVE DUCTAL CARCINOMA (IDC) IN THE RIGHT BREAST BY SHUKLA-DAVE ET AL. (PP E101-E121)