









ORIGINAL ARTICLE

# Muir-Torre syndrome appropriate use criteria: Effect of patient age on appropriate use scores

## Task Force/Committee Members:

Claudia I. Vidal<sup>1,2</sup>  | Angela Sutton<sup>1,2\*</sup> | Eric A. Armbrecht<sup>3</sup> | Jason B. Lee<sup>4,5</sup>  |  
Brandon R. Litzner<sup>6,7,8</sup>  | M. Yadira Hurley<sup>1,2</sup>  |

## Rating Panel:

Murad Alam<sup>9,10,11</sup> | Lyn M. Duncan<sup>12</sup> | Dirk M. Elston<sup>13</sup> | Patrick O. Emanuel<sup>14</sup>  |  
Tammie Ferringer<sup>15,16</sup> | Maxwell A. Fung<sup>17,18</sup>  | Gregory A. Hosler<sup>19,20,21</sup>  |  
Alexander J. Lazar<sup>22,23,24</sup>  | Lori Lowe<sup>25,26</sup> | Jose A. Plaza<sup>27</sup> | June K. Robinson<sup>28</sup> |  
Andras Schaffer<sup>29</sup>

<sup>1</sup>Department of Dermatology, Saint Louis University School of Medicine, St. Louis, Missouri

<sup>2</sup>Department of Pathology, Saint Louis University School of Medicine, St. Louis, Missouri

<sup>3</sup>Center for Health Outcomes Research, Saint Louis University, St. Louis, Missouri

<sup>4</sup>Department of Dermatology, Sidney Kimmel Medical College at Thomas Jefferson University, Philadelphia, Pennsylvania

<sup>5</sup>Department of Cutaneous Biology, Sidney Kimmel Medical College at Thomas Jefferson University, Philadelphia, Pennsylvania

<sup>6</sup>Department of Dermatology, Via Christi Clinic, Ascension Medical Group, Wichita, Kansas

<sup>7</sup>Department of Pathology, Via Christi Clinic, Ascension Medical Group, Wichita, Kansas

<sup>8</sup>Department of Family Medicine, University of Kansas Medical Center-Wichita, Wichita, Kansas

<sup>9</sup>Department of Dermatology, Feinberg School of Medicine, Northwestern University, Chicago, Illinois

<sup>10</sup>Department of Otolaryngology, Feinberg School of Medicine, Northwestern University, Chicago, Illinois

<sup>11</sup>Department of Surgery, Feinberg School of Medicine, Northwestern University, Chicago, Illinois

<sup>12</sup>Pathology Service and Dermatopathology Unit, Massachusetts General Hospital and Harvard Medical School, Boston, Massachusetts

<sup>13</sup>Department of Dermatology, Dermatologic Surgery Medical University of SC, Charleston, South Carolina

<sup>14</sup>Departamento de Patología, Clínica Ricardo Palma, Lima, Peru

<sup>15</sup>Department of Dermatology, Geisinger Medical Center, Danville, Pennsylvania

<sup>16</sup>Department of Laboratory Medicine, Geisinger Medical Center, Danville, Pennsylvania

<sup>17</sup>Department of Dermatology, University of California, Davis School of Medicine, Sacramento, California

<sup>18</sup>Department of Pathology and Laboratory Medicine, University of California, Davis School of Medicine, Sacramento, California

<sup>19</sup>Division of Dermatopathology, ProPath, Dallas, Texas

<sup>20</sup>Department of Dermatology, University of Texas Southwestern Medical Center, Dallas, Texas

Claudia I. Vidal is the current Chair of the AUC Committee.

M. Yadira Hurley is the senior author and was the Chair of the AUC committee when the majority of the work was completed.

Lyn M. Duncan, Dirk M. Elston, Patrick O. Emanuel, Tammie Ferringer, Maxwell A. Fung, Gregory A. Hosler, Lori Lowe, and Jose A. Plaza are representatives of the American Society of Dermatopathology (ASDP).

Murad Alam and June K. Robinson are representatives of the American Academy of Dermatology (AAD).

Alexander J. Lazar and Andras Schaffer are representatives of the College of American Pathologist (CAP).

\*Angela Sutton is not a member of the AUC Task Force / Committee.

<sup>21</sup>Department of Pathology, University of Texas Southwestern Medical Center, Dallas, Texas

<sup>22</sup>Department of Pathology, The University of Texas MD Anderson Cancer Center, Houston, Texas

<sup>23</sup>Department of Dermatology, The University of Texas MD Anderson Cancer Center, Houston, Texas

<sup>24</sup>Department of Genomic Medicine, The University of Texas MD Anderson Cancer Center, Houston, Texas

<sup>25</sup>Department of Dermatology, University of Michigan Medical Center, Ann Arbor, Michigan

<sup>26</sup>Department of Pathology, University of Michigan Medical Center, Ann Arbor, Michigan

<sup>27</sup>Division of Dermatopathology, Miraca Life Sciences, Irving, Texas

<sup>28</sup>Department of Dermatology, Northwestern University, Chicago, Illinois

<sup>29</sup>Division of Dermatopathology, Bay Dermatology and Cosmetic Surgery, Spring Hill, Florida

#### Correspondence

Claudia I. Vidal, Saint Louis University School of Medicine, 1755 South Grand Boulevard, St. Louis, MO 63104.

Email: vidalcmd@gmail.com

**Background:** Muir-Torre syndrome (MTS) is a rare inherited syndrome, with an increased risk of sebaceous and visceral malignancy. Prior reports suggest screening for mismatch repair (MMR) deficiency may be warranted in patients <50 years and when sebaceous neoplasms are located on a non-head and neck location. Previously, appropriate use criteria (AUC) were developed for clinical scenarios in patients >60 years concerning the use of MMR protein immunohistochemistry (MMRP-IHC). This analysis explores the appropriateness of testing in patients ≤60 years.

**Methods:** Panel raters from the AUC Task Force rated the use of MMRP-IHC testing for MTS for previously rated scenarios with the only difference being age.

**Results:** Results verify the previously developed AUC for the use of MMRP-IHC in neoplasms associated with MTS in patients >60 years. Results also show that in patients ≤60 years with a single sebaceous tumor on a non-head and neck site, MMRP-IHC testing should be considered. Testing can also be considered with a 2-antibody panel on periocular sebaceous carcinoma in younger patients.

**Conclusions:** Our findings align with known evidence supporting the need to incorporate clinical parameters in identifying patients at risk for MTS, with age being a factor when considering MMRP-IHC testing.

#### KEYWORDS

anatomic location, appropriate use criteria, expert rating, immunohistochemistry, mismatch repair protein analysis, Muir-Torre syndrome, patient age, sebaceous neoplasms

## 1 | INTRODUCTION

Muir-Torre syndrome (MTS) is a rare inherited syndrome that was first described independently in 1967 and 1968 by Dr. E.G. Muir and Dr. Douglas Torre.<sup>1,2</sup> MTS was later shown to be a clinical variant of hereditary nonpolyposis colorectal cancer (HNPCC) and Lynch syndrome, the latter of which is caused by germline mutations in the DNA mismatch repair (MMR) genes.<sup>3</sup> MTS is characterized by the presence of one or more sebaceous neoplasms or keratoacanthomas and at least one HNPCC or Lynch syndrome-related internal malignancy. The sebaceous lesions that can be seen in MTS include sebaceous adenoma, sebaceoma, sebaceous epithelioma, and sebaceous carcinoma. The mean age of presentation of sebaceous lesions in MTS is 53 years. Because the sebaceous lesions may precede internal malignancy, it has been suggested that dermatopathologists have an opportunity to screen for MTS because microsatellite instability

secondary to germline mutations in the *MSH2*, *MLH1*, *MSH6*, and *PMS2* genes can be detected immunohistochemically by loss of MMR protein expression.<sup>4-7</sup> The most commonly used screening antibodies include MSH2, MLH1, MSH6, and PMS2. It is debated in the literature if MMR protein immunohistochemistry (MMRP-IHC) testing should be performed on all sebaceous neoplasms, but most studies suggest a targeted approach incorporating clinical parameters to help dictate those neoplasms that should be tested.<sup>7</sup> Recently, the American Society of Dermatopathology (ASDP) published appropriate use criteria (AUC) for the use of MMRP-IHC in neoplasms associated with MTS for patients more than 60 years old.<sup>8,9</sup> AUC combines scientific evidence with expert judgment to yield a statement of appropriateness of a test in a specific clinical scenario.<sup>10</sup> While age >60 years was explored in the initial AUC given the greater potential for misuse in this population, appropriateness ratings for the test are lacking in younger patients that are diagnosed with

**TABLE 1** MTS appropriate use scores with 16 vs 12 panel raters categorizing clinical scenarios for age >60 y

Clinical scenario	16 PR <sup>8,9</sup>	12 PR
<b>4 Antibody panel</b>		
1. Periocular sebaceous carcinoma	NC (3.5; 0/16 out)	NC (3.3; 0/12 out; SD = 2.9)
2. One sebaceous tumor; head and neck location	NC (5.1; 1/16 out)	NC (5.9; 1/12 out; SD = 2.1)
3. One sebaceous tumor; non head and neck location	NC (6.7; 1/16 out)	NC (6.7; 1/12 out; SD = 2.3)
4. Multiple sebaceous tumors	UA (7.2; 0/16 out)	UA (7.4; 0/12 out; SD = 2.2)
5. Basal cell carcinoma with sebaceous differentiation	U (5.0; 0/16 out)	U (5.3; 0/12 out; SD = 1.6)
6. Keratoacanthoma with sebaceous differentiation	UA (7.1; 0/16 out)	UA (7.3; 0/12 out; SD = 1.9)
7. Cystic sebaceous tumor	UA (7.3; 0/16 out)	UA (7.3; 0/12 out; SD = 2.0)
8. MTS associate neoplasm and/or visceral malignancy	UA (7.3; 1/16 out)	UA (7.1; 1/12 out; SD = 2.2)
<b>2 Antibody panel</b>		
1. Periocular sebaceous carcinoma	RA (3.0; 0/16 out)	RA (2.6; 0/12 out; SD = 1.8)
2. One sebaceous tumor; head and neck location	U (4.9; 0/16 out)	U (5.6; 1/12 out; SD = 1.8)
3. One sebaceous tumor; non head and neck location	UAU (6.9; 1/16 out)	NC (6.7; 1/12 out; SD = 2.0)*
4. Multiple sebaceous tumors	UA (7.2; 0/16 out)	UA (7.4; 0/12 out; SD = 1.9)
5. Basal cell carcinoma with sebaceous differentiation	U (4.6; 0/16 out)	U (4.9; 0/12 out; SD = 1.9)
6. Keratoacanthoma with sebaceous differentiation	UAU (6.6; 0/16 out)	UAU (6.6; 0/12 out; SD = 1.8)
7. Cystic sebaceous tumor	UAU (6.9; 0/16 out)	UAU (6.8; 0/12 out; SD = 1.8)
8. MTS associate neoplasm and/or visceral malignancy	UAU (6.9; 0/16 out)	NC (6.9; 1/12 out; SD = 2.1)*

Note. Usually, appropriate indications (UA; mean' scores of  $\geq 7.0$ ) are colored dark green; usually appropriate to uncertain ("majority usually appropriate") indications (UAU; mean' scores between 6.1 and 6.9 and SD <2.0) and colored light green; rarely appropriate indications (RA; mean' scores of  $\leq 3.0$ ) are colored dark red; rarely appropriate to uncertain (majority rarely appropriate) indications (RAU; mean' scores between 3.1 and 3.9 and SD <2.0); uncertain appropriateness indications (U; mean' scores of  $\geq 4.0$  and  $\leq 6.0$  with a SD <2.0) are colored blue; no consensus (NC; mean' scores between 3.1 and 6.9 that had a SD  $\geq 2.0$ ) are colored white.

Abbreviations: MTS, Muir-Torre syndrome; PR, panel rater.

\*Indicates difference noted between two groups.

neoplasms associated with MTS. This subsequent analysis explores expert consensus (AUC) regarding MMRP-IHC testing in patients aged  $\leq 60$  years.

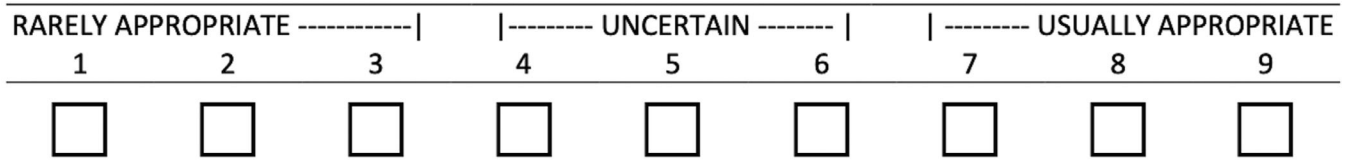
**TABLE 2** Definitions and clinical scenarios Muir-Torre syndrome

Definitions <sup>6,8,9,11</sup> :
<ul style="list-style-type: none"> <li>Age 60: There are some articles that suggest age 50 instead of 60 as a cut off, this may be because sebaceous neoplasms present at a mean age of 53</li> <li>MTS associated sebaceous neoplasm: sebaceous adenoma, sebaceoma, sebaceous epithelioma, sebaceous carcinoma</li> <li>MTS-associated neoplasm: MTS associated sebaceous neoplasms, cystic sebaceous neoplasm, basal cell carcinoma with sebaceous differentiation, keratoacanthoma with sebaceous differentiation</li> <li>MTS-associated visceral malignancy: colorectal adenocarcinoma (most common), genitourinary carcinoma (second most common), breast, hematologic, endometrial and gastric carcinoma (less common)</li> </ul>
Clinical scenarios:
<ol style="list-style-type: none"> <li>A patient with a periocular sebaceous carcinoma.</li> <li>A patient with a single sebaceous tumor on the head and neck.</li> <li>A patient with a single sebaceous tumor on a site other than the head and neck.</li> <li>A patient with multiple (greater than or equal to 2) sebaceous tumors.</li> <li>A patient with a basal cell carcinoma with sebaceous differentiation.</li> <li>A patient with a keratoacanthoma with sebaceous differentiation.</li> <li>A patient with a cystic sebaceous neoplasm.</li> <li>A patient with a MTS-associated neoplasm and/or a personal history of a MTS-associated visceral malignancy.</li> </ol>

Abbreviation: MTS, Muir-Torre syndrome.

## 2 | METHODS

Institutional review board approval was deemed unnecessary as the study does not involve human subjects or include any interaction or intervention with human subjects. Previously, the use of MMRP-IHC: 4-antibody panel (MSH2, MLH1, MSH6, and PMS2) and 2-antibody panel (MSH2 and MLH1), in the screening for MTS was explored in eight clinical scenarios (Table 1), which represent common situations encountered in clinical practice.<sup>8,9</sup> Each scenario was accompanied by a set of definitions<sup>6,8,9,11</sup> and independently reviewed for completeness by dermatopathologists with expertise in the area and modified accordingly (Table 2). Evidence on the use of MMRP-IHC was compiled (search years 2000 to 2016), provided to panel raters and is published in the *Journal of Cutaneous Pathology*.<sup>7</sup> In the current analysis, expert panel raters (PRs) from the AUC Task Force of the ASDP were surveyed and asked to independently rate the appropriateness of the use of MMRP-IHC testing as a screening tool for MTS for the previously rated eight clinical scenarios, with the only difference being age. As the ratings for the younger age group occurred almost immediately following the third round for the previously developed AUC, each PR was provided their score for the third rating round of the clinical scenarios for age >60 years. For each clinical scenario, PRs were asked if age less than or equal to 60 years would change their prior rating. PRs indicated "yes" or "no" to this question. If they answered "yes" to this question, they were then asked to rank the appropriateness of the



**FIGURE 1** Nine-point scale used in the ranking process for each clinical scenario. A score of 7 to 9 indicates the test is “usually appropriate” with higher scores indicating greater agreement within this category. A score of 1 to 3 indicates the test is “rarely appropriate” in that specific clinical scenario. A lower score within this range would indicate strength in conviction of the test being less appropriate. Scores in the range of 4 to 6 indicate “uncertain appropriateness” for ordering the test and generally indicate panel rater’s assessment that there is a lack of scientific evidence available to make a judgment either way

test for that specific clinical scenario on a 9-point scale (Figure 1) using their own best judgment and available literature. This was the same scale used previously in the development of AUC.<sup>8,9</sup> PRs did not repeat the analysis for patients over the age of 60. As with the prior study, PRs were instructed not to consider cost in their rating. In total, 12 of the prior 16 PRs completed the subsequent analysis.

The mean was calculated for both age groups (age >60 years and age ≤60 years) based on the categorical assessment made by each PR and then filtered by removing the highest and lowest scores to minimize impact of outlying raters (mean'). The SD was also calculated for each rating. Because not all the PRs completed the subsequent assessment, notation was made as to the individual PR completing the subsequent assessment. Only those PRs completing both assessments were included in the current analysis. As with the prior assessment scenarios with a mean' >7 were categorized as “usually appropriate”. Mean' values between 6.1 and 6.9 and with a SD <2 were categorized as majority usually appropriate (“usually appropriate to uncertain”). Clinical scenarios with a mean' ≤3 were categorized as “rarely appropriate”. Mean' scores between 3.1 and 6.9 that had a SD <2.0 were designated as majority rarely appropriate (“rarely appropriate to uncertain”). Uncertain categorization was used for those clinical scenarios with a mean' score of ≥4 and ≤6 with a SD of <2.0. Mean' scores between 3.1 and 6.9 and with a SD ≥2 were defined as not having reached consensus. Differences in appropriateness ratings, stratified by patient age (<60 vs ≥60), were examined. In general, the categories ranked “uncertain” and those that did not reach consensus represent areas where the literature may have been underdeveloped. Again, PRs had the option to utilize the “out” option, which is not an acronym and indicated that “assessment of appropriateness of test cannot be made without direct communication with the clinician and furthermore the appropriateness will change on a case by case basis depending on the clinical information provided.” The use of this “out” option was recorded and considered significant if used by greater than three PRs.

### 3 | RESULTS

Twelve PR responses were compared with prior published responses from successive rounds of rating with 16 PRs that have been previously published (Table 1). Validating the previously developed AUC, the rating categories did not change for the use of the 4-antibody panel in the age greater than 60 years group with 12 vs 16 PRs (Table 1). There were minor category changes in the 2-antibody panel

rating obtained with 12 vs 16 PRs (Table 1). One change was in clinical scenario #3, which referred to testing of a patient with a sebaceous tumor on a non-head and neck site and the second in clinical scenario #8, which refers to testing of a patient with a MTS associated neoplasm and / or visceral malignancy. In both instances, the ratings changed from “usually appropriate to uncertain” (majority usually appropriate) to “no consensus”. These changes relate to minor differences in the SD likely resulting from fewer PRs. Table 1 highlights the AUC scores obtained with 16 contrasted with 12 PRs.

In looking at the younger age group and use of the 4-antibody panel (Table 3), there was a notable difference in categorical AUC ranking for clinical scenario #3 - patient with a sebaceous tumor on a

**TABLE 3** MTS appropriate use scores for the 4-antibody panel grouped by patient age

Clinical scenario	Age >60 y	Age ≤60 y
1. Periocular sebaceous carcinoma	NC (3.3; 0/12 out; SD = 2.9)	NC (4.0; 0/12 out; SD = 3.0)
2. One sebaceous tumor; head and neck location	NC (5.9; 1/12 out; SD = 2.1)	NC (6.0; 0/12 out; SD = 2.2)
3. One sebaceous tumor; non head and neck location	NC (6.7; 1/12 out; SD = 2.3)	UA (7.1; 0/12 out; SD = 2.4)*
4. Multiple sebaceous tumors	UA (7.4; 0/12 out; SD = 2.2)	UA (7.6; 0/12 out; SD = 0)
5. Basal cell carcinoma with sebaceous differentiation	U (5.3; 0/12 out; SD = 1.6)	U (5.6; 0/12 out; SD = 1.8)
6. Keratoacanthoma with sebaceous differentiation	UA (7.3; 0/12 out; SD = 1.9)	UA (7.6; 0/12 out; SD = 0)
7. Cystic sebaceous tumor	UA (7.3; 0/12 out; SD = 2.0)	UA (7.7; 0/12 out; SD = 0)
8. MTS associate neoplasm and/or visceral malignancy	UA (7.1; 1/12 out; SD = 2.2)	UA (7.8; 0/12 out; SD = 2.1)

Usually appropriate indications (UA; mean' scores of ≥7.0) are colored dark green; usually appropriate to uncertain (“majority usually appropriate”) indications (UAU; mean' scores between 6.1 and 6.9 and SD <2.0) and colored light green; rarely appropriate indications (RA; mean' scores of ≤3.0) are colored dark red; rarely appropriate to uncertain (majority rarely appropriate) indications (RAU; mean' scores between 3.1 and 3.9 and SD <2.0); uncertain appropriateness indications (U; mean' scores of ≥4.0 and ≤ 6.0 with a SD <2.0) are colored blue; no consensus (NC; mean' scores between 3.1 and 6.9 that had a SD ≥2.0) are colored white.

Abbreviation: MTS, Muir-Torre syndrome; y, years.

\*Indicates difference noted between two groups.

**TABLE 4** MTS appropriate use scores for the 2-antibody panel grouped by patient age

Clinical scenario	Age >60 y	Age ≤60 y
1. Periocular sebaceous carcinoma	RA (2.6; 0/12 out; SD = 1.8)	NC (3.9; 0/12 out; SD = 2.1)*
2. One sebaceous tumor; head and neck location	U (5.6; 1/12 out; SD = 1.8)	NC (5.9; 1/12 out; SD = 2.4)*
3. One sebaceous tumor; non head and neck location	NC (6.7; 1/12 out; SD = 2.0)*	UA (7.1; 0/12 out; SD = 2.7)*
4. Multiple sebaceous tumors	UA (7.4; 0/12 out; SD = 1.9)	UA (7.2; 0/12 out; SD = 1.8)
5. Basal cell carcinoma with sebaceous differentiation	U (4.9; 0/12 out; SD = 1.9)	NC (4.9; 0/12 out; SD = 2.0)*
6. Keratoacanthoma with sebaceous differentiation	UAU (6.6; 0/12 out; SD = 1.8)	NC (6.6; 0/12 out; SD = 2.1)*
7. Cystic sebaceous tumor	UAU (6.8; 0/12 out; SD = 1.8)	UAU (6.8; 0/12 out; SD = 1.9)
8. MTS associate neoplasm and/or visceral malignancy	NC (6.9; 1/12 out; SD = 2.1)*	UA (7.0; 0/12 out; SD = 1.9)*

Usually appropriate indications (UA; mean' scores of  $\geq 7.0$ ) are colored dark green; usually appropriate to uncertain ("majority usually appropriate") indications (UAU; mean' scores between 6.1 and 6.9 and SD <2.0) and colored light green; rarely appropriate indications (RA; mean' scores of  $\leq 3.0$ ) are colored dark red; rarely appropriate to uncertain (majority rarely appropriate) indications (RAU; mean' scores between 3.1 and 3.9 and SD <2.0); uncertain appropriateness indications (U; mean' scores of  $\geq 4.0$  and  $\leq 6.0$  with a SD <2.0) are colored blue; no consensus (NC; mean' scores between 3.1 and 6.9 that had a SD  $\geq 2.0$ ) are colored white.

Abbreviation: MTS, Muir-Torre syndrome; y, years.

\*Indicates difference noted between two groups.

non-head and neck anatomic location. This scenario was deemed "no consensus" in a patient >60 years of age; however, in younger patients it was ranked by PRs as "usually appropriate". Table 4 highlights the ratings for the use of the 2-antibody panel in younger patients. Like the 4-antibody panel, clinical scenario #3 was ranked "usually appropriate" to perform the test in patients  $\leq 60$  years of age. Clinical scenario #1 was ranked as "no consensus" in patients  $\leq 60$  years of age. This is opposed to the ranking in older patients of "rarely appropriate" to performing the test. Differences in rating were also seen in clinical scenarios #2, #5, and #6, but these were secondary only to a slight increase in the SD. In addition, the calculated mean' in clinical scenarios #5 and #6 remained the same between both age groups. Only rare PRs utilized the "out" option in the ratings and did not reach significance, which was defined as >3 instances, for any clinical scenarios. These results are summarized in Tables 3 and 4.

## 4 | DISCUSSION

The appropriateness method developed in the 1980s by RAND/UCLA was established to explain the variation in utilization of medical

procedures and has a goal of improving the quality, efficiency, and cost-effectiveness of health care. AUC are meant to determine when, which, and how often a particular procedure or diagnostic test should be performed in the context of: available scientific evidence, patient characteristics, risk/benefit of treatment, and available health care resources. AUC have been shown to improve diagnostic yield, clinical outcomes, and reduce overall cost as well as resource utilization. AUC are patient-centered and provide physicians with guidance for the use of ancillary studies for a variety of patient scenarios that occur in clinical practice. In general, AUC facilitate this decision-making by deriving levels or categories of appropriateness based on examining the available clinical evidence and supplementing evidence with collective clinical expertise and review from an expert panel of physicians.<sup>10</sup>

MTS and Lynch syndrome are caused by mutations in DNA MMR genes.<sup>7</sup> Review of the literature shows that MMR deficiency in sebaceous neoplasms ranges from 25% to 66% with the sensitivity of MMRP-IHC testing being reported as high as 81%.<sup>7</sup> However, MMRP-IHC analysis is not without drawbacks. Studies with germline mutation analysis show a high false-positive rate of MMRP-IHC in the range of 56%<sup>12</sup> and a specificity of only 48%.<sup>13</sup> This high false-positive rate and low specificity have necessitated a more critical assessment of when to screen MTS associated lesions before testing is initiated.

This study examines the effect of patient age on appropriateness ratings with respect to MMRP-IHC analysis in clinical scenarios surrounding MTS. Our previously published results for the use of a 4-antibody and 2-antibody panel in the screening for MTS in patients over the age of 60 years emphasizes that dermatopathologists should utilize a targeted screening approach in situations when MMRP-IHC is being considered and take into account other strong clinical indicators of MTS.<sup>8,9</sup> The result of this analysis validates the previously published AUC, highlighting that even with fewer PRs AUC ratings for the use of MMRP-IHC in patients over the age of 60 remain essentially unchanged. Moreover, this study further supports the necessity of a tailored approach, which incorporates patient age, and strengthens the argument that clinical parameters are essential in selecting individuals that would benefit from testing. Previous studies have also suggested that age of presentation of sebaceous neoplasms is an important clinical parameter to consider in identifying those patients at risk for MTS.<sup>12</sup> Other studies investigating MMR deficiency in sebaceous neoplasms have reported more frequent deficiencies on non-head and neck sites.<sup>14,15</sup> Thus, it is not surprising that a significant categorical change occurred in the appropriateness ratings for younger patients ( $\leq 60$  years of age) in clinical scenario #3, which refers to a non-head and neck site. This holds true whether screening is performed with a 4-antibody panel or a 2-antibody panel. While all sebaceous tumors that have been associated with MTS were included in this category, recent genetic data on extraocular sebaceous carcinoma suggests that while microsatellite instability is not uncommon, many cases are secondary to somatic rather than germline mutations.<sup>16,17</sup> In addition, there was a categorical change with the use of a 2-antibody panel in clinical scenario #1, which explores the appropriate use of MMRP-IHC in periocular sebaceous carcinoma. Appropriate ratings moved from "rarely appropriate" to "no consensus". Ocular sebaceous carcinoma is classically considered a disease of the elderly with a median age of 73 years.<sup>18</sup>

Consequently, its occurrence in a patient  $\leq 60$  years of age may have been considered meaningful by some PRs. Recent sequencing data in sebaceous carcinoma has suggested that half of lesions tested harbor a somatic mutation in the PI3K signaling pathway and acquire recurrent truncating mutations in transcription factor *ZNF750*.<sup>16,17</sup> Still, many of the lesions studied by Tetzlaff et al<sup>16</sup> were older (median 63 years) and age range was not presented for the sebaceous carcinomas studied in North et al.<sup>17</sup> As the literature continues to emerge and more information is gained, these ratings may change. An update, which includes incorporation of recent literature, is already in progress.

Limitations of this study include that the UCLA/RAND methodology used to develop these AUC requires a focus on appropriateness without comparison. Accordingly, the results do not speak to which antibody panel is better. The PRs were also instructed not to consider cost in the analysis, which can be considered another limitation. Of note, the nomenclature selected for the rating categories emphasizes that the ultimate decision to perform the test should be made by the physician considering the specifics of the patient. In addition, while the PRs were provided specific instructions for rating there was likely an assumption by PRs of no prior diagnosis of MTS. Lastly, one must also recognize that AUC development is a lengthy process and in areas where the literature is rapidly evolving, it can be challenging to keep up to date.

In sum, this study helps to authenticate the previously developed AUC for the use of MMR protein immunohistochemistry in neoplasms associated with MTS in patients  $>60$  years. In particular, highlighting the importance of patient age and neoplasm location on appropriate use scores when testing is being considered for cutaneous lesions associated with MTS. Congruent with our prior study<sup>8,9</sup> and the works of Roberts et al<sup>12</sup> and Singh et al<sup>13</sup> these ratings lend further support to a directed approach in selecting those individuals that could benefit from MMRP-IHC testing and highlights the necessity of incorporating clinical parameters.

## ACKNOWLEDGEMENTS

The authors would like to acknowledge Dr. Dirk Elston for his efforts to create the AUC Task Force/Committee during his time as President of the American Society of Dermatopathology and guidance during the project. The authors would also like to thank Drs. Garrett Desman, Jane Messina, and Puja Puri for their work as reviewers of definitions and clinical scenarios. The authors would also like to thank Dr. Michael Hitchcock for his expertise.

## ORCID

Claudia I. Vidal  <https://orcid.org/0000-0003-2672-4974>

Jason B. Lee  <https://orcid.org/0000-0002-8154-4258>

Brandon R. Litzner  <https://orcid.org/0000-0001-9928-563X>

M. Yadira Hurley  <https://orcid.org/0000-0002-1162-7250>

Patrick O. Emanuel  <https://orcid.org/0000-0003-1068-6969>

Maxwell A. Fung  <https://orcid.org/0000-0003-1771-8257>

Gregory A. Hosler  <https://orcid.org/0000-0002-6281-0565>

Alexander J. Lazar  <https://orcid.org/0000-0002-6395-4499>

## REFERENCES

- Muir EG, Bell AJ, Barlow KA. Multiple primary carcinomata of the colon, duodenum, and larynx associated with kerato-acanthomata of the face. *Br J Surg*. 1967;54(3):191-195.
- Torre D. Multiple sebaceous tumors. *Arch Dermatol*. 1968;98(5):549-551.
- Lynch HT, Lynch PM, Pester J, Fusaro RM. The cancer family syndrome. Rare cutaneous phenotypic linkage of Torre's syndrome. *Arch Intern Med*. 1981;141(5):607-611.
- Machin P, Catusus L, Pons C. Microsatellite instability and immunostaining for MSH-2 and MLH-1 in cutaneous and internal tumors from patients with the Muir-Torre syndrome. *J Cutan Pathol*. 2002;29(7):415-420.
- Abbas O, Mahalingam M. Cutaneous sebaceous neoplasms as markers of Muir-Torre syndrome: a diagnostic algorithm. *J Cutan Pathol*. 2009;36(6):613-619.
- John AM, Schwartz RA. Muir-Torre syndrome (MTS): an update and approach to diagnosis and management. *J Am Acad Dermatol*. 2016;74(3):558-566.
- Lee JB, Litzner BR, Vidal CI. Review of the current medical literature and assessment of current utilization patterns regarding mismatch repair protein immunohistochemistry in cutaneous Muir-Torre syndrome-associated neoplasms. *J Cutan Pathol*. 2017;44(11):931-937.
- Vidal CI, Armbracket EA, Andea AA, et al. Appropriate use criteria in dermatopathology: initial recommendations from the American Society of Dermatopathology. *J Cutan Pathol*. 2018;45(8):563-580.
- Vidal CI, Armbracket EA, Andea AA, et al. Appropriate use criteria in dermatopathology: initial recommendations from the American Society of Dermatopathology. *J Am Acad Dermatol*. 2018;80(1):189-207.
- Fitch K, Bernstein S, Aguilar MS, et al. *The RAND/UCLA Appropriateness Method User's Manual 2001*. No. MR-1269-DG-XII/RE:126. Santa Monica, CA: RAND Corp.; 2001.
- Bhaijee F, Brown AS. Muir-Torre syndrome. *Arch Pathol Lab Med*. 2014;138(12):1685-1689.
- Roberts ME, Riegert-Johnson DL, Thomas BC, et al. A clinical scoring system to identify patients with sebaceous neoplasms at risk for the Muir-Torre variant of Lynch syndrome. *Genet Med*. 2014;16(9):711-716.
- Roberts ME, Riegert-Johnson DL, Thomas BC, et al. Screening for Muir-Torre syndrome using mismatch repair protein immunohistochemistry of sebaceous neoplasms. *J Genet Couns*. 2013;22(3):393-405.
- Singh RS, Grayson W, Redston M, et al. Site and tumor type predicts DNA mismatch repair status in cutaneous sebaceous neoplasia. *Am J Surg Pathol*. 2008;32(6):936-942.
- Jessup CJ, Redston M, Tilton E, Reimann JD. Importance of universal mismatch repair protein immunohistochemistry in patients with sebaceous neoplasia as an initial screening tool for Muir-Torre syndrome. *Hum Pathol*. 2016;49:1-9.
- Tetzlaff MT, Singh RR, Seviour EG, et al. Next-generation sequencing identifies high frequency of mutations in potentially clinically actionable genes in sebaceous carcinoma. *J Pathol*. 2016;240(1):84-95.
- North JP, Golovato J, Vaske CJ, et al. Cell of origin and mutation pattern define three clinically distinct classes of sebaceous carcinoma. *Nat Commun*. 2018;9(1):1894.
- Orr CK, Yazdanie F, Shinder R. Current review of sebaceous cell carcinoma. *Curr Opin Ophthalmol*. 2018;29(5):445-450.

**How to cite this article:** Vidal CI, Sutton A, Armbracket EA, et al. Muir-Torre syndrome appropriate use criteria: Effect of patient age on appropriate use scores. *J Cutan Pathol*. 2019; 46:484-489. <https://doi.org/10.1111/cup.13459>