

## Letter to the Editor

### CD20+ T Cells in Primary Mediastinal Large B Cell Lymphoma Microenvironment

We have read the article entitled “Evaluation of primary mediastinal large B cell lymphoma by flow cytometry” recently published in *Cytometry Part B* with great interest (1). In this article, Cherian and Fromm along with neoplastic clone evaluated the reactive infiltrate in primary mediastinal large B cell lymphoma (PMLBCL). The authors reported presence of CD3+CD4+CD7-bright/CD45-bright subpopulation in the reactive infiltrate in 41% of their cases, which appears to be a common finding in classical Hodgkin lymphoma tumor microenvironment.

We observed CD20+ T cells in the mediastinal mass tissue in two recent cases with histologically proven PMLBCL on flow cytometric analysis. CD20+ T cells were identified by CD3, CD7, and CD2 staining (Fig. 1). These two cases with prominent CD20+ T cell population (45.53% and 56.3% within the CD45-bright lymphocyte gate) showed decreased CD4/CD8 ratio (0.49 and 0.35, respectively) in contrast to the findings recently reported in PMLBCL reactive tissue (1). In Case 1, the CD20 expression on T cells was about the same intensity as that of mature B cells and about one logarithmic difference lower than that of the neoplastic cells, while in Case 2 the CD20 expression on T cells was broad compared to that of mature B cells within the reactive infiltrate (Fig. 1A, B). The specimen in Case 1 was run and analyzed on Beckman Coulter Epics XL flow cytometer (Brea, CA) on three color panel and on Beckman Coulter Gallios flow cytometer (Brea, CA) on 10 color panel in Case 2. For both panels, fluorescence minus one controls were run to account for any artifact or nonspecific fluorescence. Three different fluorochrome conjugates of CD20 monoclonal antibody, all with the same clone (Clone B9E9, Beckman Coulter, Brea, CA) were used

in the panels—APC and APC Alexa Fluor 750 in Case 1 and PE in Case 2.

Other B cell markers such as CD19 and CD22 were absent on these cells suggesting that these were CD20-expressing T cells and not B and T cell–cell or cell particle–cell conjugates (Fig. 1C). Ten-color flow cytometric analysis of CD20+ T cells showed that these were distributed among various T cell subsets, including CD4–CD8– (double-negative), CD4+CD8+ (double-positive), CD8+, and CD4+ cells, 42.86%, 5.08%, 39.85%, and 12.22%, respectively in Case 2. (Fig. 1D). Interestingly, in the second case, there was an increased double-negative T cell presence (25% of T cells) with positive TCR- $\gamma\delta$  staining pattern (90%) in the tumor microenvironment. To our knowledge these findings have not been reported in PMLBCL or any other type of lymphoma reactive tissue.

A small population (~3–5%) of CD3+CD20dim+ has been identified in peripheral blood of healthy individuals, cerebrospinal fluid, and primary and secondary lymphoid tissue, including thymus (2,3). It has been shown that, immunophenotypically these T cells are more common in CD8+, CD45RO+ memory, and in CCR7– subpopulations. Compared to CD3+CD20– T cells, they show increased frequency of IL-4, IL-17, IFN- $\gamma$ , and tumor necrosis factor (TNF)- $\alpha$  producing cells (3).

Origin of these cells is controversial. One study has suggested that these cells may arise from transfer of CD20 molecules to T cells upon close T cell–B cell interaction in the tissue by intercellular exchange of membrane components via a process known as trogocytosis (4). However, another study showed that peripheral blood CD3+CD20+ cells transcribe both CD3 and CD20 (3).

The function of CD20+ T cells is not yet clear. This subset has been found

to be in a higher state of activation in patients with autoimmune disorders such as psoriasis, rheumatoid arthritis, multiple sclerosis, and increased in ovarian cancer. Compared with healthy individuals, circulating CD20+ T cells have been shown to produce more cytokines, interleukin IL-17A, TNF- $\alpha$ , and IL-21 in patients with psoriasis. Additionally, higher levels of IL-17A, TNF- $\alpha$ , and IL-21 production by CD20+ T cells was observed in the affected areas and skin lesions with increased severity index scores in psoriasis (5). In multiple sclerosis, activated CD20+ T cells have been shown in chronic lesions of brain, secreting pro-inflammatory cytokines IFN- $\gamma$  and IL-17, possibly contributing to the disease pathogenesis (6). Eggleton and colleagues have reported that the proportion of IL-17-producing CD20+ T cells in the peripheral blood of rheumatoid arthritis patients increased by 240-fold as compared to healthy individuals (7). In ovarian cancer, while CD20+ T cells were 6% in peripheral blood, this population was found to be increased to 23% in ascites fluid (4).

Several cases of CD20+ T cell leukemia/lymphoma have been reported in the literature (8–13). Quintanilla-Martinez et al. speculated that CD20+ T cell lymphomas may arise from neoplastic transformation of normal CD20+ T cell subset (8). In PMLBCL, it is also possible that CD20+ T cells are highly activated Th17 cells and may be involved in antitumor immunity. Studies in larger number of cases analyzing the tumor tissue and the effect of CD20+ T cells in treatment outcome are warranted, which might help guide therapy including, the use of immunotherapy and immune checkpoint inhibitors, in particular (14).

#### CONFLICT OF INTEREST

Nothing to report.

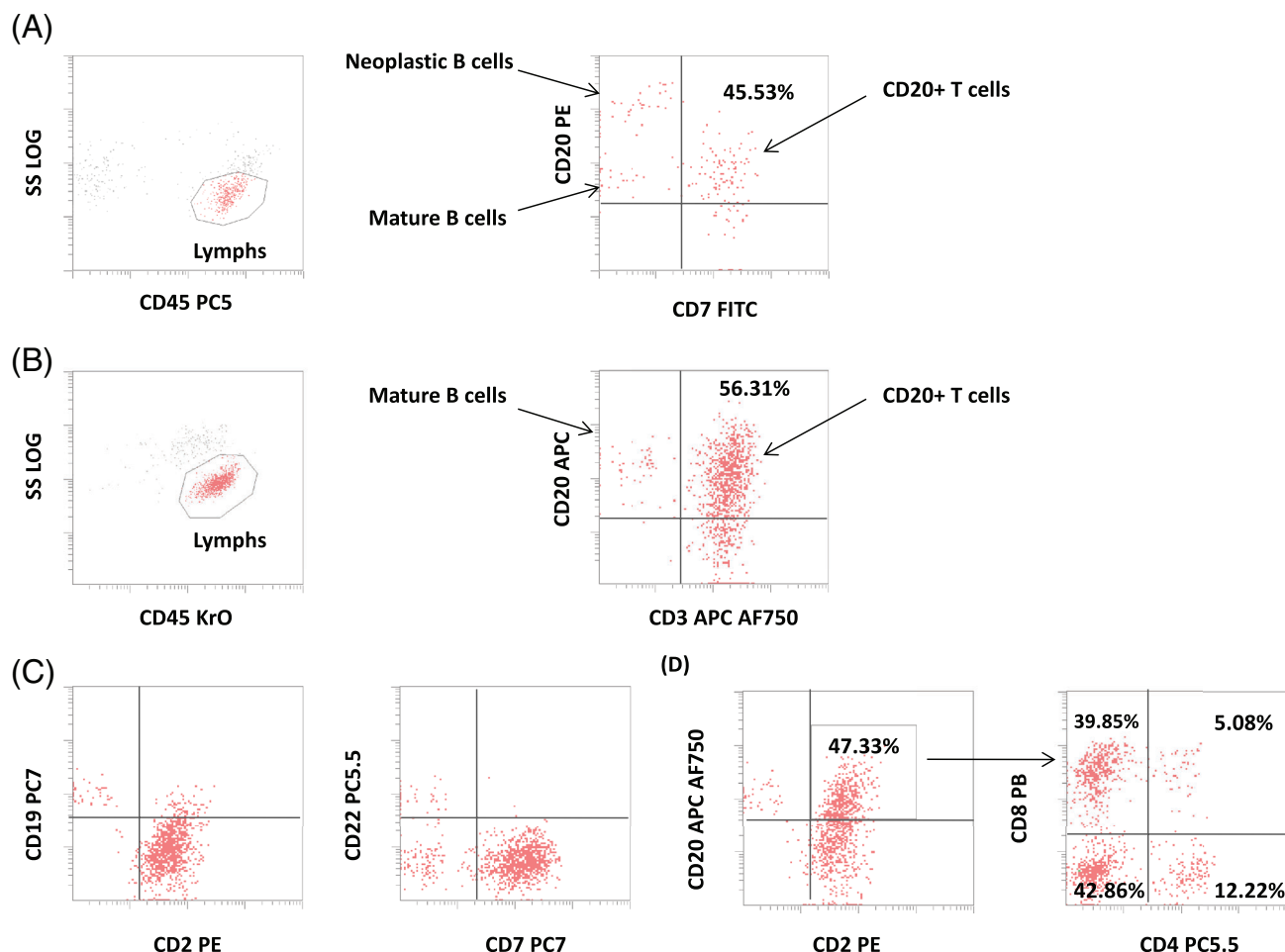



FIG. 1. Two cases of PMLBCL evaluated by flow cytometry. **(A)** Case 1 displaying CD20+ CD7+ T cells within the reactive infiltrate of the tumor tissue. The CD20+ T cells have about same intensity of CD20 expression as that of mature B cells within the reactive infiltrate, while one log difference lower CD20 intensity than that of neoplastic cells. **(B)** Case 2 displaying CD20+CD3+ T cells within the reactive infiltrate of the tumor tissue. The CD20+ T cells show broad CD20 expression. Tumor cells were not detected in the tumor tissue specimen on the flow cytometric analysis. **(C)** CD20+ T cells in Case 2 does not show any significant expression of other B cell markers such as CD19 and CD22. **(D)** CD20+ T cells in Case 2 showed that these cells were distributed among various subsets of T cells, including CD4+, CD8+, CD4+CD8+ (double positive), and CD4–CD8– (double negative) T cells. [Color figure can be viewed at [wileyonlinelibrary.com](http://wileyonlinelibrary.com)]

## LITERATURE CITED

- Cherian S, Fromm JR. Evaluation of primary mediastinal large B cell lymphoma by flow cytometry. *Cytometry Part B*. 2018;94B:459–467.
- Hultin LE, Hausner MA, Hultin PM, Giorgi JV. CD20 (pan-B cell) antigen is expressed at a low level on a subpopulation of human T lymphocytes. *Cytometry*. 1993;14:196–204. <https://doi.org/10.1002/cyto.990140212>.
- Schuh E, Berer K, Mulazzani M, Feil K, Meil I, Lahm H, Krane M, Lange R, Pfannes K, Subklewe M, et al. Features of human CD3<sup>+</sup> CD20<sup>+</sup> T cells. *J Immunol*. 2016;187:1111–1117.
- De Bruyn M, Wiersma VR, Wouters MC, Samplonius DF, Klip HG, Helfrich W, Nijman HW, Eggleton P, Bremer E. CD20<sup>+</sup> T cells have a predominantly Tc1 effector memory phenotype and are expanded in the ascites of patients with ovarian cancer. *Oncoimmunology*. 2015; Mar 19;4(4): e999536.
- Niu J, Zhai Z, Hao F, Zhang Y, Song Z, Zhong H. Dissection of a circulating CD3<sup>+</sup>CD20<sup>+</sup>T cell subpopulation in patients with psoriasis. *Clin Exp Immunol*. 2018; 192:206–212. <https://doi.org/10.1111/cei.13106>.
- Holley JE, Bremer E, Kendall AC, de Bruyn M, Helfrich W, Tarr JM, Newcombe J, Gutowski NJ, Eggleton P. CD20+ inflammatory T-cells are present in blood and brain of multiple sclerosis patients and can be selectively targeted for apoptotic elimination. *Mult Scler Relat Disord*. 2014;3:650–658.
- Eggleton P, Bremer E, Tarr JM, de Bruyn M, Helfrich W, Kendall A, Haigh RC, Viner NJ, Winyard PG. Frequency of Th17 CD20+ cells in the peripheral blood of rheumatoid arthritis patients is higher compared to healthy subjects. *Arthritis Res Ther*. 2011;13(6):R208.
- Quintanilla-Martinez L, Preffer F, Rubin D, Ferry J, Harris N. CD20+ T cell lymphoma, neoplastic transformation of a normal T cell subset. *Am J Clin Pathol*. 1994;102: 483–489.
- Warzynski MJ, Graham DM, Axtell RA, Zakem MH, Rotman RK. Low level CD20 expression on T cell malignancies. *Cytometry*. 1994;18:88–92. <https://doi.org/10.1002/cyto.990180206>.
- Takami A, Saito M, Nakao S, Asakura H, Nozue T, Onoe Y, Yachie A, Shiobara S, Matsuda T. CD20-positive T-cell chronic lymphocytic leukaemia. *Br J Haematol*. 1998;102:1327–1329. <https://doi.org/10.1046/j.1365-2141.1998.00884.x>.
- Mohrmann RL, Arber DA. CD20-positive peripheral T-cell lymphoma: Report of a case after nodular sclerosis Hodgkin's disease and review of the literature. *Mod Pathol*. 2000;13:1244–1252.
- Yao X, Teruya-Feldstein J, Raffeld M, Sorbara L, Jaffe ES. Peripheral T-cell

- lymphoma with aberrant expression of CD79a and CD20: A diagnostic pitfall. *Mod Pathol.* 2001;14:105–110.
13. Sun T, Akalin A, Rodacker M, Braun T. CD20 positive T cell lymphoma: Is it a real entity? *J Clin Pathol.* 2004;57(4):442–444. <https://doi.org/10.1136/jcp.2003.011734>.
  14. Wright Z, Brown A. High-grade neutropenia in a patient successfully treated with nivolumab for refractory primary mediastinal B-cell lymphoma. *Blood Adv.* 2017;1(17):1306–1308.

**Manisha Gadgeel,<sup>1</sup>**   
**Batool Al-Qanber,<sup>1</sup> Steven Buck<sup>1</sup>**  
**and Süreyya Savaşan<sup>1,2</sup>**  
<sup>1</sup>Hematology/Oncology Flow Cytometry  
Laboratory, Division of  
Hematology/Oncology, Children's  
Hospital of Michigan, and Carman and  
Ann Adams Department of Pediatrics,  
Wayne State University, Detroit, Michigan  
<sup>2</sup>Pediatric Bone Marrow Transplant  
Program, Division of

Hematology/Oncology, Children's  
Hospital of Michigan, and Barbara Ann  
Karmanos Cancer Center, Carman and  
Ann Adams Department of Pediatrics,  
Wayne State University, Detroit, Michigan

---

Published online 20 June 2019 in Wiley  
Online Library ([wileyonlinelibrary.com](http://wileyonlinelibrary.com)).  
DOI: 10.1002/cyto.b.21832