

10th Anniversary Celebration  
October 31 - November 2, 1999

## Classic Reviews

From Past  
Comprehensive Review Courses  
In Prosthodontics

Volume II



The University Of Michigan  
Ann Arbor, Michigan



## TABLE OF CONTENTS

### Section Five - Removable Prosthodontics

Dr. Brien R. Lang	"Removable Prosthodontic Occlusion"
Dr. Glen P. McGivney	"Removable Partial Dentures - Part 1"
Dr. Edward J. Billy	"Removable Partial Dentures - Part 2"
Dr. Kenneth D. Rudd	"Designing The Removable Partial Denture"
Dr. Krishan K. Kapur	"Review Of RPD Clinical Trials"

### Section Six - Dental Implants

Dr. Alan B. Carr	"Prosthetic Management Using Dental Implants"
Dr. Hans-Peter Weber	"Dental Implants And Their Biological Interfaces"
Dr. Merle J. Jaarda	"Biomechanics And Implant Design"
Dr. Charles E. English	"A Review Of Implant Systems"
Dr. Steven Lewis	"Dental Implant Therapy"
Dr. Robert J. Cronin Jr.	"Treatment Considerations For The Implant Assisted Restoration Of The Partially Edentulous Patient"
Dr. Michael E. Razzoog	"Designing Fixed Partial Denture Reconstruction And Implant Rehabilitation Using CAD/CAM"
Dr. Stephen J. Riedy	"Accuracy And Precision In Dental Implants"
Dr. Brien R. Lang	"Implant Complications"
Dr. Brien R. Lang	"Occlusal Rehabilitation Of The Edentulous Patient With Or Without Implants"

### Section Seven - Oral Pathology, Drug Therapies, Basic Dental Materials, And Bonding And Luting Agents

Dr. Richard M. Courtney	"Oral Pathology And Prosthodontics"
Dr. Patrick M. Lloyd	"Drug Therapies In Prosthodontics"
Dr. John C. Wataha	"Review of Basic Materials In Prosthodontics"
Dr. Stephen Bayne	"Bonding And Luting Agents"

### Section Eight - Maxillofacial Prosthetics

Dr. Arthur O. Rahn	"Prosthodontic Principles In The Construction Of Intra-oral Maxillofacial Restorations"
--------------------	--

## **Section Five - Removable Prosthodontics**

Section Five contains information related to removable prosthodontics. The examination of the edentulous patient provides information that is essential for sequencing the plan of treatment. Developing an occlusal concept and scheme for the edentulous patient is based in part on science and in part on clinical experience. Where science is lacking, experience has been invaluable, however, a great deal of information contained in the literature is empirical. Literature dealing with the treatment of the partially edentulous patient is more exacting, however, it is sparse. Clinical trials have been completed and articles dealing with their findings are included in this section. Designing the removable partial denture and the mechanics of design are detail. The authors and the titles of their presentations related to removable prosthodontics follow:

**Dr. Brien R. Lang**

“Removable Prosthodontic Occlusion”

**Dr. Glen P. McGivney**

“Removable Partial Dentures - Part 1”

**Dr. Edward J. Billy**

“Removable Partial Dentures - Part 2”

**Dr. Kenneth D. Rudd**

“Designing The Removable Partial Denture”

**Dr. Krishan K. Kapur**

“Review Of RPD Clinical Trials”

# **Removable Prosthodontic Occlusion**

**Dr. Brien R. Lang**



# REMOVABLE PROSTHODONTIC OCCLUSION

## Background

The search for the ideal occlusal form and tooth arrangement for removable prosthodontics has been going on for almost two centuries. During this time authors have devoted considerable time and effort writing about the advantages of one occlusion over another. Up to and including most of the 1970's, these reports have centered on: 1) comparing anatomic to nonanatomic teeth, or 2) comparing a balanced occlusal concept versus a nonbalanced arrangement from three perspectives, namely:

1. The effects on denture base stability.
2. The functional stresses produced by the various tooth forms during chewing and mandibular movements.
3. The effects on tissue preservation.

The subject of complete denture occlusion was the basis for the International Prosthodontic Workshop in Ann Arbor in 1972. Approximately 100 individuals address this topic from seven different perspectives.

Section I	ALVEOLAR BONE
Section II	THE PHYSIOLOGY OF JAW MOVEMENTS
Section III	ARTICULATORS AND ARTICULATION
Section IV	OCCLUSAL PATTERNS AND TOOTH ARRANGEMENTS
Section V	DENTAL MATERIALS
Section VI	POST-INSERTION CHANGES
Section VII	HUMAN FACTORS

Perhaps, the single most important finding from the Section on Occlusal Patterns and Tooth Arrangements was the statement clearly summarized in their report, "At the present, the choice of a posterior tooth form or arrangement for complete dentures is an empirical procedure. Little or no supporting research is available to the profession relative to the overall effect on esthetics, function, and the long-term maintenance of the supporting tissues. All the occlusal forms may be arranged with or without bilateral balance. Many claims and counterclaims appear in the literature extolling the merits of a given concept or pointing out the deficiencies of another. Scores of clinically competent and intellectually honest professionals document clinical experiences in a very subjective manner. Since their experiences differ and their conclusions conflict, the practitioner is left to make his or her own choice. The available research fails to identify a superior tooth form or arrangement; therefore, it appears logical to use the least complicated approach that fulfills the *requirements of the patient.*"

Has the body of knowledge changed and is additional scientific information available today that will provide some of the answers that were lacking in 1972? Regarding tooth form and occlusal schemes, the answer is no! What has emerged however, are technological advances and improved methodologies which demonstrate that potential

does exist to develop research protocols to discover the answers to these plaguing questions.

## NOMENCLATURE AND TERMINOLOGY

Any discussion in prosthodontics would be incomplete without a review of nomenclature and terminology. We cannot communicate effectively unless we are speaking the same language. The fifth edition of the Glossary of Prosthodontic Terms published in the *Journal of Prosthetic Dentistry* in December 1987 should be the reference source for all scientific writings or discussions. With this edition, numerous changes for better clarity were introduced. For example:

1. In the past, we generally used the term "occlusion" in discussions, however, the more appropriate term is "articulation, dental".
2. "Centric occlusion" is another term used in the past that should be replaced with "intercuspatation, maximum".
3. "Centric relation" is a term in transition to obsolescence, however, it is most difficult to discuss dental articulation in the absence of this term.

Recognizing that articulation is a dynamic state and occlusion represents a static tooth relationship, one must further define the types of static tooth contacts that can be observed. For example:

Anatomic occlusion  
Monoplane occlusion  
Linear occlusion

All three types of occlusions have been described in the literature based on tooth contact relationships and their definitions must be clearly understood.

Articulation, on the other hand, is the dynamic state of tooth contact relationships and has several types. For example:

Balanced articulation  
Monoplane articulation  
Lingualized articulation

"Balanced occlusion" is a term that is considered objectionable and should be avoided if possible.

Just as we defined "articulation, dental," we must also recognize that there is a functional articulation.

On the other hand, "balanced articulation" can be further defined as:

Cross-arch balanced articulation



It would be difficult to discuss dental articulation without reference to teeth. Therefore, we should be familiar with the terms:

Teeth, anatomic teeth  
Non anatomic teeth  
Zero-degree teeth  
Cuspless teeth.

No discussion of terminology and nomenclature as related to occlusion would be complete without the terms:

Cusp height and cusp angle  
Working and nonworking side

## REVIEW OF OCCLUSAL FORMS AND OCCLUSAL SCHEMES

### Occlusal Form

Most of the artificial teeth that are available to the profession today were developed by the manufacturers in response to the development of the dental articulator in the early 1900's. These early designs, most of which are still in use today, employ geometrical principles and are considered "engineered" artificial teeth, or they are conceived designs by the master carver that would hopefully fulfill the requirements of function and stability for the patient. The concept of an engineered tooth was the direct result of the application of geometrical concepts into articulator design as described in the early work of Bonwill and Gysi. Basically, the articulator became the kinematic instrument that directed the carving tools which cut the primordial forms that were eventually carved into the anatomic tooth forms. The classical article describing the carving of denture teeth was that of Gysi in 1929. Gysi used four strips of metal to cut forms that he considered to be similar to "sharks' teeth" which he mounted on a dental articulator. A block of plaster was attached to the opposite member of the articulator and the various movements of the articulator were made to define the primordial forms of the masticatory surfaces of the maxillary premolars and molars. Gysi later replaced this rather crude method of tooth carving with geometric concepts whereby, "given the rotation points for the right and left lateral bites and the protrusive movement, one can determine by purely scientific methods, and without the shark's teeth, the size and inclination of each facet of each tooth."

Examination of these early applications of geometric form and motion and the resulting primordial forms that are then carved into teeth, clearly demonstrated that the artificial tooth is a dynamic three-dimensional body possessing many inclinations and angles that are significant in articulation that cannot be defined by the current definition as cusp angles. By definition, cusp angle is the slope of a cusp with a perpendicular line bisecting the cusp, measured mesiodistally or buccolingually. Such cusp angles have little bearing on the design of the tooth. In fact, the designation of cusp angle associated with some of the currently supplied artificial teeth are misnomers. A study by Thompson and

Lang (to be discussed later) clearly points out the differences in cusp angles as defined and cusp angles of significance in articulation.

The earliest posterior tooth designed by Gysi using this method was the Trubyte 33-degree posterior. These teeth were carved with a 33 degree condylar inclination and a similar incisal guidance. These mechanical equivalents and controlling factors were selected for two reasons: 1) the average condylar slope for adult patients as determined experimentally by Gysi was approximately 33 degrees and 2) Gysi had observed as early as 1911 that a reduction in the incisal guidance from an average of 60 to 80 degrees for natural teeth to 30 to 35 degrees for the edentulous patient, would effectively reduce lateral forces and increase the denture stability. Scientific data to support the lateral force reduction and the increase in denture base stability by present day standards, however, was not published. A careful study of the occlusal surface of the 30-degree teeth created by these end-controlling factors supports the premise that very few if any cusps on the occlusal surface of this tooth would be 30-degrees.

During the 1920's considerable bone loss under dentures was associated clinically with the higher cusp teeth (45 degrees) and thus, the introduction of "all sort of mechanical posteriors." The emphasis on cusp reduction resulted in Gysi and W.C. Whitmore developing the 20-degree porcelain posteriors in 1930. The 20-degree teeth were carved as a working unit accurately to the mathematical plan for its design. The condylar guidance for the cutting instrument was set at 30 degrees to the horizontal and the sagittal incisal guidance was 10 degrees. Historically, the Trubyte 20-degree posterior teeth were followed by a 30-degree posterior tooth designed and formulated by Drs. Pilkington and Turner. The 30-degree posterior teeth were mathematically designed and cut to a horizontal condylar angle and the sagittal incisal angle of 30 degrees. Many other anatomic and nonanatomic posterior tooth forms have been developed since Gysi introduced the engineered tooth concept. In most instances, their occlusal morphology has been based on engineering principles and articulation. Harold R. Ortman presents an excellent historical overview of these many different posterior tooth molds in Chapter 13 - Complete Denture Occlusion in the text *Essentials of Complete Denture Prosthodontics*, 2nd edition by Sheldon Winkler, 1988.

In 1925, Rudolph L. Hanau presented the profession with a discussion paper entitled, "Articulation, Defined, Analyzed and Formulated." His theories were formulated without experimental evidence, yet accepted by the profession with only slight modification of his original concepts. What evolved was an interpretation of the laws of articulation into an interrelationship; which Hanau called "factors governing articulation." Hanau stated, "balanced articulation is the change from one balanced occlusion to another while the masticatory surfaces remain in balanced contact." His concepts were limited to mechanical balanced articulation thereby distinguishing them from physiologic balanced articulation. Mechanical involves as Hanau stated, "precise laws of articulation based on geometry, an occlusion constructed on an articulator completely controlled by mechanics." Hanau further stated that, "of the five factors governing articulation it is 'relative cusp height' that unites the manufacturers tooth form to the concept of mechanical balanced articulation." Hanau defines "relative cusp height" as the projection on the cusp base of the movement of a point directed along the incline from the base to the cusp summit. The magnitude of this guiding path is related to its projection onto an accepted coordinate

system. Cusp angle is the conventional term and being described in degrees, was adhered to in expressing the laws of articulation." This definition is probably more significant in relating articulator end-controlling factors and the angular inclines developed mathematically during articulation to what will be required on the occlusal surface of a supplied tooth to achieve occlusal balanced articulation as a maxillary tooth passes over the surface of its mandibular antagonist.

Cusp angulations and their effect on balanced articulation, are discussed in Sharry's text, the second edition, chapter 15, pages 235 to 259. Sharry states that the inclination of the teeth and the compensating curves are of more importance to balanced articulation than is the inclination of the occlusal plane. The inclination of a particular tooth is of little value unless the tooth is placed vertically and thereby re-establishing the compensating curves produced in its occlusal design. In fact, if one refers back to the tooth carving process, we soon realize that the compensating curves, both anteroposteriorly and mediolaterally, are cut into the tooth during carving as a function of the cutting tools' position within the cutting instrument. To introduce further compensation during the arrangement of teeth, defeats the engineering principles developed in carving the tooth.

For example, regarding protrusive balance, if the horizontal condylar guidances were 30 degrees and the horizontal incisal guidance was also 30 degrees, teeth with 30 degree cusps would balance perfectly if all contacted a 0 degree plane of occlusion. Sharry further states, "if the condylar guidances were 45 degrees and the incisal guidance 30 degrees, teeth with 30-degree cusps, if all contacted a 0 plane of occlusion, would not balance, but instead would separate posteriorly." Indeed, Sharry was right; however, most clinicians would suggest increasing the compensating curve during tooth arrangement to achieve balance in this example. Doing so, however, would destroy the relationship of the engineered guidance pathways to the opposing dentition. The better choice would be to select a tooth with steeper cusp angulations.

Recognizing the relationship of the influence of the end-controlling factors on articulation, and the methods used to create the "engineered" posterior artificial teeth, one soon realizes that a 30-degree tooth with its complex occlusal surface must be arranged in the articulator in the same relationship to the end-controlling factors as it was in the carving instrument when its primordial form was created, if one wishes to achieve a balanced articulation. Any deviation from this position will alter the relationship of the guidance pathways created in carving the tooth to the guidance pathways established by the end-controlling factors during movements of the articulator. Manipulation, rotation, raising, lowering, or repositioning of the teeth to a different position to gain a balanced articulation defies the existence of solid geometry as a science and produces occlusal contact relationships in either the static positions or during articulation that are not within the design concepts of the teeth. More strongly stated, one cannot create an exact balanced articulation by merely moving the teeth around. Balanced articulation is created through arrangement in the best possible maximum intercuspal position, in a slightly open occlusal vertical dimension, followed by selective occlusal equilibration to create the exact primordial forms needed that can be formed into the cuspal inclinations required to achieve mechanical balanced articulation as influenced by the several guidances established in programming the dental articulator.

To further emphasize this discussion, read the article by Thompson and Lang in which 23 different posterior teeth were measured for the cusp angulations from the cusp base along the guidance pathways in various movements. Very few, if any, posterior teeth can be arranged to a balanced articulation while maintaining the engineering designs, without extensive occlusal modification. Again, altering the position of the tooth to gain contact in one movement of balanced articulation destroys the contacts in the other movements.

## Occlusal Schemes

It may well have been this difficulty in achieving balanced articulation that led to the development of a great number of occlusal schemes. Ten contemporary occlusal schemes were reviewed by Beck in 1972 and summarized into five that demonstrated the balanced occlusion and articulation concept and five in the nonbalanced category in eccentric maximal intercuspal positions.

### Balanced Occlusion and Articulation.

The classical example of bilateral balanced articulation dates back to 1914 when Gysi introduced the 33-degree cusp form arranged according to the movements of the articulator. This scheme was meant to enhance stability and direct the contact forces towards the ridges.

Reduction of the occlusal table of the lower posterior teeth to increase the stability of the dentures was advocated by French in 1954. The upper posterior teeth have slight lingual occlusal inclines of 5 degrees for the first premolars, 10 degrees for the second premolars, and 15 degrees for the first and second molars, so that a balanced articulation could be developed laterally as well as anteroposteriorly by the arrangements of the teeth on a curved occlusal plane.

Sears was one of the greatest exponents of nonanatomic tooth forms. He introduced his chewing members in 1922 and his channel type posterior teeth in 1927. These teeth had a restricted acceptance by the profession. The modified nonanatomic tooth patterns from the early types are more extensively used today. A balanced articulation can be developed by a curved occlusal plane anteroposteriorly and laterally or with the use of the second molar ramp.

Pleasure rationalized that the occlusion should be of special design due to the instability of the lower denture. Resultant forces should be directed vertically and/or lingually. His scheme employed a posterior reverse lateral curvature except for the second molar which is set with the customary lateral curvature to provide a balanced articulation.

The last balanced scheme employs an arbitrary articulator balance, followed by intraoral corrections to obtain balance, and it illustrates a linear occlusion which is intended to give a one-dimensional contact between the opposing posterior teeth as advocated by Frush. A blade on the lower posterior teeth contacts essentially flat surfaces of the upper teeth set at a slight angle to the horizontal. The intent in this scheme is to eliminate occlusal deflective contacts and provide greater stabilization of the dentures.

## Nonbalanced Schemes

A nonbalanced scheme that stresses the position of the anterior teeth to preserve the phonetic values of the patient in harmony with increased denture stability and efficiency with the chewing cycle was advocated by Pound. The scheme incorporated a sharp upper lingual cusp in opposition with the widened fossae of the lower teeth in centric occlusion. The buccal cusps of the lower posterior teeth were reduced thereby eliminating any deflective contacts on the completed dentures. In effect, the occlusion is lingualized by the elimination of contacts on the buccal cusps and by the anteroposterior arrangements of the lower posterior teeth so that their lingual surfaces are on or within the lingual side of a triangle from the mesial area of the lower cuspid to the sides of the retromolar pad.

Another scheme described by Beck, by way of a personnel communication with Arthur Aull, used the 33-degree cusp form with full occlusal gold surfaces. The anterior teeth are set to the requirements of phonetic values. Extreme vertical overlaps producing cuspid guidance are frequently used, resulting in disocclusion of the posterior teeth away from the maximum intercuspal position.

A contemporary occlusal design using nonanatomic teeth in a straight horizontal occlusal plane was introduced by Hardy. Porcelain, plastic or metal shearing blades, placed in a block of upper posterior teeth occluding against lower porcelain teeth, were also considered with this scheme.

The occlusal pivot introduced by Sears was another nonbalanced scheme. The pivots were proposed to place the mandible in equilibrium by maintaining the load in the molar regions, and thereby protecting the temporomandibular joints against injury. Stress was also reduced in the anterior regions of the ridges in anticipation of tissue maintenance using this scheme.

A nonbalanced articulation in eccentric positions using a horizontal occlusal plane without a posterior ramp was advocated by Kurth. The posterior teeth were arranged in a block with a flat anteroposterior occlusal plane and reverse lateral curve.

Many of these schemes are in use today, however, long-term scientific investigations to support any claims of tissue maintenance, denture stability, or increased masticatory efficiencies are lacking in the literature.

We would be remiss if we didn't mention the monoplane occlusal concept as defined by Philip M. Jones in 1972. In this concept, a nonanatomic occlusal scheme is used with a few specific modifications. The first departure is the articulator used. It should accommodate large casts, it should not show lost motion, and it should possess an incisal guide pin. As Jones states, a barn door hinge fits these requirements. Another departure is that the maxillary and mandibular teeth are arranged without any vertical overlap. The amount of horizontal overlap is determined by the jaw relationships. The maxillary posterior teeth are set first, and the occlusal plane must fulfill certain requirements. First, it should result in an occlusal plane that evenly divides the space between the upper and lower ridges. Second, it should provide an occlusal plane that parallels the mean denture base foundation. Finally, the plane should fall at the junction of the upper and middle

thirds of the retromolar pads. In the final arrangement of the teeth the maxillary and mandibular teeth contact from anterior to posterior in maximum intercuspation with the exception of the second molars. The occlusal surface of the upper second molar should be set parallel to the occlusal surface of the lower second molar; but 2 mm above the occlusal plane, thus well out of occlusion. This condition is established because the first and second premolars and the first molars masticate the food. The second molars are space fillers and do not function. This occlusal scheme has received a great deal of attention over the past years, however in most instances when monoplane occlusion has been discussed, these previously described modifications are not strictly followed.

## REMOVABLE OCCLUSION - CURRENT KNOWLEDGE

Removable occlusion research during the past twenty years has been rather sparse and centered around three areas: a) theoretical or specific clinical models, b) chewing efficiency and chewing ability, and c) biting forces and/or chewing forces. Research aimed specifically at tooth forms and occlusal schemes have not been a high priority during this period, probably because of the difficulty to isolate the variables involved, and the reliability of the scientific methods available. However, recent studies involving patients with dentures in combination with osseointegrated implants are demonstrating methodologies that may help to determine if there is a tooth form or occlusal scheme that is better for the overall health and welfare of the patient.

### Theoretical Or Specific Clinical Models

Colaizzi et al. in a specific clinical model studied border movements at the incisor point in denture wearers with two interchangeable occlusal schemes of posterior teeth to determine if differences occurred as a function of tooth form, and to compare the movement patterns to those of patients with natural dentitions. The authors concluded that the denture patient populations produced a rounded, poorly defined intercuspal-like position in contrast to a well-defined sharp intercuspal position in the natural dentition subjects. This poorly defined position in the denture wearers occurred with both the nonanatomic or anatomic posterior tooth forms in place. However, the lack of a sharply defined intercuspal-like position would seem to support the hypothesis that research on tooth forms and border movements was influenced more by the denture base instability than the tooth forms themselves. This study would seem to further support the premise that the absence of differences may be the result of the lack of a reliable method not necessarily the absence of a difference in response to tooth form.

The finite element experimental model was used by Maeda and Wood to study bone resorption beneath a maxillary complete denture as influenced by occlusal forces. In their study, the authors assumed that a threshold of compressive strain existed in the alveolar bone above which resorption occurred. The pattern of predicted resorption was observed when 100 newtons of force was applied to three positions occlusally, and 20 N was applied facially. The pattern of simulated bone resorption was similar to that reported from clinical observations, which suggested that the restoration may be associated with compressive strains developed in the alveolar bone. The resorptive pattern developed by this mathematical model argues for the importance of occlusal adjustment of dentures to move the occlusal load point palatally and the possible significance of tooth contacts

and/or tooth forms used in producing a balanced occlusion in protrusive and lateral excursions.

### **Chewing Efficiency And Chewing Ability**

Clough et al., examined chewing efficiency and chewing ability using 30 patients treated with duplicate sets of dentures. One set had monoplane occlusion using 0-degree teeth in both arches, while the other was arranged to the lingualized concept using maxillary 30-degree teeth opposing the mandibular 0-degree tooth. The patients wore one set for three weeks and then the other set for a second three week test period. The chewing ability of each patient was recorded along with their preference for a given set of dentures. There was a preference for the lingualized occlusion by sixty-seven percent of the patients interviewed and this preference was statistically significant according to a chi-square analysis. The reason given by patients who preferred the lingualized occlusion seemed to support the contention that lingualized occlusion improves their masticatory abilities as compared to a cusplless scheme, while also providing a noninterfering freedom and bilaterally balanced articulation. It must be remembered, however, that the data collected in this study were responses to a questionnaire and thus nonparametric in nature.

### **Biting Force And/or Chewing Forces**

A number of studies have been conducted over the past several years on biting force and/or chewing forces. Michael, Javid, Colaizzi, and Gibbs compared the biting force of the denture wearer to patients with natural teeth. The maximum biting force of the denture wearer averages 35 lbs or 16 kg. The bite strength of natural dentition subjects was 162 lbs or 74 kg, or 4.5 times greater than that of the denture wearers. It should be noted that the range of bite strength varied for both the natural dentitions (55 to 280 lbs) and the denture wearers (22 to 47 lbs). Similar ranges and bite forces have been found in other studies by Gibbs et al.

Bite forces were studied in selected groupings of patients with different prosthetic rehabilitation conditions by Lassila et al. Three groups were examined: a) patient with maxillary and mandibular complete dentures, b) patients with maxillary complete dentures opposing a mandibular removable partial denture, and c) patients with natural teeth or removable partial dentures in the maxillary arch opposing a mandibular removable partial denture. Patients were asked to bite on a special bite fork that recorded maximum force in newtons. Seven regions were measured around the dental arch. The authors concluded that instability and interferences in the occlusion created a significant decrease in bite force in groups (a) the totally edentulous group, and group (b) the combination syndrome patient ( $p < .001$ ). The bite force was clearly greater with the natural teeth versus the RPD in group (c). In both the edentulous group (a) and the RPD/denture group (b), the greater bite force was in the molar and premolar regions. The contralateral stabilization of occlusion during the recording had a considerable effect on the bite force. Values that were reached were clearly greater than without stabilization and the measurement was more reliable. The importance of a stable occlusion increased as the number of natural teeth decreased. The positive effect of a stable occlusion on the bite force was evident in this study. This study is extremely important in that it supports the hypothesis that a lack of stability can influence the magnitude, the validity and reliability

of the measurements being made. Considering these findings, few if any previous studies trying to measure the effect of either tooth forms or balanced versus a nonbalanced relationship using the edentulous population, had any chance of providing data to prove statistically significant differences. This does not mean that differences do exist, however, it clearly supports the hypothesis that the previous studies had little if any chance to prove the same.

One of the few studies conducted recently that dealt with occlusal forms and chewing ability was by Michael et al. In this investigation denture wearers were studied using dentures with interchangeable posterior occlusal schemes involving zero degree and 30 degree posterior teeth. These examiners studied bite strength and chewing forces and found no statistical differences in chewing forces between the two posterior tooth forms studied. Again, one might question denture base instability and the scientific method.

Lundquist, Carlsson, and Hedegard studied masticatory function by means of a chewing efficiency test and bite force measurements in a group of patients who were seeking rehabilitation with osseointegrated implants. The patient population consisted of individuals with dentures who had experienced great difficulty adapting to dentures. The patients chewing efficiency and bite forces were measured before and after new dentures were constructed. They found no significant correlations between the quality of the dentures and the measurements of bite force and chewing efficiency.

Forces required by complete dentures for penetrating some commonly used food items were measured experimentally by Eerikainen and Kononen under simulated conditions. These forces were compared with the maximal bite forces of twenty-seven complete denture wearers as measured clinically. Simulated laterotrusion aided most in the penetration of ray bread and boiled meat. The penetration forces in simulated conditions were high compared with the maximal bite forces of the complete denture wearers clinically. It is reasonable to assume that perhaps the major cause for the rejection of particular food items from the diet by patients may be due to high bite force needed to chew these foods. Food pulverization experiments have shown that complete denture wearer's ability to penetrate food is much lower (one-third to one-sixth) that of persons with natural dentitions.

In a study by Lindquist, 64 edentulous patients were evaluated prior to and following new denture construction for bite force, chewing efficiency and chewing ability. The patients were then treated with osseointegrated implants in the mandible and retested for the previously listed variables. In summary the function tests showed small changes after denture treatment. Improvement was greater, however, in those subjects with the poorest pretreatment values.

Following treatment with implants, the means in newtons of bite force measurements increased in 24 edentulous subjects at three force levels on four occasions I = old dentures, II = after denture treatment, III = 2 months following treatment, and IV = 3 years after implant placement in the mandible.

The patient's own evaluation of their ability to chew different foods changed only slightly after denture treatment, whereas a dramatic improvement was reported after



insertion of the implants. This improvement was maintained during the observation period.

One of the few negative consequences of the improved masticatory function in the rehabilitated patients was a high rate of midline fractures of the maxillary denture. The maximal bite force has been shown to become two or three times as high after insertion of a fixed TIP in the mandible of complete denture wearers.

Jemt and Carlsson conducted a similar study on 16 edentulous patients wearing complete dentures who were subsequently treated with implant placement in the mandible. These investigators measured bite force, chewing efficiency, and chewing ability. Their findings verified that the rehabilitation of complete denture wearers with fixed bridges on OI fixtures in the mandible on average gave a substantial improvement to masticatory function.

In a study by Haraldson et al., nine subjects were treated with OI implants in the mandible, followed by an overdenture. These subjects were also evaluated for bite force, chewing efficiency and ability. Chewing function seemed to improve; however, it was less obvious than their findings in earlier studies where the mandibular restorations were fixed by the osseointegrated implants.

Haraldson and Zarb evaluated 21 patients ten years following treatment with implants and dentures. These investigators measured the anamnestic and clinical examination and registration of bite force. The bite force ranged from 118 N (gentle biting) to 250 N (as chewing) to maximum bite at 495.5 N. On average, the bite force improved significantly at all bite force levels compared to 10 years earlier. It was concluded that oral functions in patients with OI implants are very favorably improved.

In yet another study, Lundgren et al. evaluated eight patients with maxillary complete dentures and fixed restorations in the mandibular arch supported by 5-6 OI fixtures. Cantilever segments 16 mm in length extended beyond the last fixture on each side. Chewing, swallowing, and closing forces were measured. In the maxillary dentures, four strain gauges were placed in anterior and posterior regions. The patients chewed peanuts, roast beef, and potato salad. The occlusal force pattern during chewing and biting was comparable to patients with complete dentitions. Comparisons were made with data for tooth-supported, cross-arch unilateral posterior two unit cantilever fixed partial dentures, occluding with natural teeth. The posterior cantilever segments in the OI cantilever prosthesis occluding with complete dentures regularly exhibited the largest local forces.

The comparisons as described in these last few studies are both interesting and informative. However, their greatest significance may be in the fact that they clearly demonstrate that in the presence of implants and increased denture base stability, bite force transmission during chewing, swallowing and particularly clenching, gnashing and bruxing appear to be significantly greater than with conventional dentures. In these circumstances, we must ask if these forces may also be influenced by the occlusal form used in either the maxillary denture or the OI mandibular prosthesis. Of equal importance may be the influence of a cross-arch balanced or nonbalanced articulation. The article by Brewer in 1963 and his studies on functional and nonfunctional tooth contacts in denture patients

adds additional impetus to the importance of studying these variables especially regarding the implant patient. Functional and nonfunctional contacts were recorded over a 24-hour test period by Brewer. Although this study was limited to only two patients, the length of contact ranged from 10 minutes for chewing, to 2 to 4 hours for nonfunctional activity. The tooth form used in prosthodontic reconstruction, or the occlusal concept employed may be an extremely important influence on the health of various oral structures during these occlusal contact periods. That such differences have not demonstrated devastating effects in the edentulous population is probably due to the fact that the conventional denture bases move. The increasing numbers of patients receiving implant therapy make it imperative that sound scientific data be obtained to either support or refute the significance of tooth forms or occlusal schemes on the supporting tissues.

It is safe to say that little ground has been gained during the past twenty years in determining the influence, if any, of the tooth form or the occlusal scheme used on the overall welfare or oral health of the patient. However, this population of patients rehabilitated with OI prosthesis may well prove to be the experimental populations that will provide the answers to these long unanswered questions about tooth forms and a balanced versus a nonbalanced articulation.

## REFERENCES

- Beck, HO. Occlusion as related to complete removable prosthodontics. J Prosthet Dent 1972;27:246-256.
- Bonwill WGA. Geometrical and mechanical laws of articulation. Anatomical articulation. Odont Soc Pa Tr 1885;nv:119-33.
- Bonwill WGA. Scientific articulation of the human teeth as founded on geometrical, mathematical and mechanical laws. Dent Items Interest 1899;21:617-36, 873-80.
- \* Brewer, AA. Prosthodontic research in progress at the School of Aerospace Medicine. J Prosthet Dent, 1963;13:49-69.
- \* Clough et al. A comparison of lingualized occlusion and monoplane occlusion in complete dentures. J Prosthetic Dent 1983;50:176-9.
- Colaizzi FA, Michael CG, Javid NS, and Gibbs CH. Condylar and incisal border movements: A comparative study of complete denture wearers and natural dentition subjects. J Prosthet Dent 1988;59:453-
- Eerikäinen, E and Kononen, M. Forces required by complete dentures for penetrating food in simulated function. J Oral Rehabil 1987;14:607-613.
- French, FA. The problem of building satisfactory dentures. J Prosthet Dent 1954;4:769-81.
- Frush, JP. Linear occlusion. Ill Dent J 1966;35:788-94.
- Glossary of prosthodontic terms, 5th edition. J Prosthet Dent 1978;58:717-762.
- Gysi, Alfred and Wayne, OT (translator). The problem of articulation Dent Cosmo 1910;52:403-18
- Gysi Alfred. Masticating efficiency in natural and artificial teeth, III. The bites in natural and porcelain teeth. Dent Digest 1915;21:139-45.
- Gysi, Alfred. Practical application of research results in denture construction. Am Dent A J 1929;16:199-223.
- Gysi, Alfred. Evolution of the prosthetic incisor overbite and the prosthetic cusp angulation of the posteriors to what is called "functional norm". Dentists' Supply Company of New York. York, PA, 1935, p.38, duplicated.
- \* Hanau, RL. Articulation defined, analyzed and formulated. Am Dent A J 1926;8:1694-1709.
- Haraldson T, Jemt T, Stålblad P-Å, and Lekholm U. Oral function in subjects with overdentures supported by osseointegrated implants. Scand J Dent Res 1988;96:235-42.

- Haraldson, T and Zarb, G. A 10-year follow-up study of the masticatory system after treatment with osseointegrated implant bridges. *Scand J Dent Res* 1988;96:243-52.
- Hardy, IR. Developments in the occlusal patterns of artificial teeth. *J Prosthet Dent* 1951;1:14-32.
- International Prosthodontic Workshop on Complete Denture Occlusion.* Lang BR, Kelsey CC (eds), The University of Michigan, School of Dentistry, 1973, xxvi+338 p.
- Jemt, T and Carlsson, GE. Aspects of mastication with bridges on osseointegrated implants. *Scand J Dent Res* 1986;94:66-71.
- Jones, PM. The monoplane occlusion for complete dentures. *J Prosthet Dent*, 1972;85:94-100. *Classic*
- Kelsey CC, Reid FD, and Coplowitz JA. A method of measuring pressures against tissues supporting functioning complete dentures. *J Prosthet Dent* 1976;354:376-383.
- Kurth, LE. Balanced occlusion. *J Prosthet Dent* 1954;4:150-67. *Classic*
- Lassila V, Holmlund I and Koivumaa KK. Bite force and its correlations in different denture types. *Acta Odontol Scand* 1985;43:127-132.
- Levin, B. Monoplane teeth. *J Am Dent Assoc* 1972;85:781. *Classic*
- Lindquist, LW. Prosthetic rehabilitation of the edentulous mandible. *Swed Dent; J Suppl* 1987;48:1-39
- Lundgren D, Laurell L, Falk H and Bergendal T. Occlusal force pattern during mastication in dentitions with mandibular fixed partial dentures supported on osseointegrated implants. *J Prosthet Dent* 1987;58:197-203.
- Lundquist LW, Carlsson GE, and Hedegard B. Changes in bite force and chewing efficiency after denture treatment in edentulous patients with denture adaptation difficulties. *J Oral Rehabil*;1986;13:21-29.
- Maeda Y and Wood WW. Finite element method simulation of bone resorption beneath a complete denture. *J Dent Res* 1989;68:1370-1373.
- Michael CG, Javid NS, Colaizzi FA and Gibbs CH. Biting strength and chewing forces in complete denture wearers. *J Prosthet Dent* 1990;63:549-553.
- New Trubyte posteriors functional 20 degree shallow bites. Dentists' Supply Company of New York. York, PA, 1935, p.12, duplicated.
- Ortman, HR. Complete denture occlusion, in Winkler, Sheldon (ed): *Essentials of Complete Denture Prosthodontics*. 2nd edition. PSG Publishing Co., Inc., 1988, p.217-249

Pleasure, MA. Anatomic versus nonanatomic teeth. *J Prosthet Dent* 1953;7:47-54.

Pound, Earl. Utilizing speech to simplify a personalized denture service. *J Prosthet Dent* 1971;24:586-600.

Sears, VH. Thirty years of nonanatomic teeth. *J Prosthet Dent* 1953;3:596-617.

Sears, VH. Occlusal pivots. *J Prosthet Dent* 1956;6:332-8.

- Sharry, JJ. Arrangement and occlusion of teeth, in Sharry, JJ (ed): *Complete Denture Prosthodontics*. McGraw-Hill, Book Co., Inc., 1962, p. 235-259.

Suggestions for the arrangement and articulation of Pilkington-Turner 30 degree posteriors by Trubyte. Dentists' Supply Company of New York. York, PA, 1966, p.27.

The new Pilkington-Turner vacuum fired 30 degree posteriors. Dentists' Supply Company of New York. York, PA, 1953, p.48.

Lang, B.R. and Thompson, R.M. The Cusp Angles of Artificial Mandibular First Molars. *J Prosthet Dent* 1972;28:26-35.

Woelfel et al. Effect of posterior tooth form on jaw and denture movement. *J Prosthet Dent* 1962;12:922-39.

*October, 1993*



# **Removable Partial Dentures - Part 1**

**Dr. Glen P. McGivney**





## REMOVABLE PARTIAL DENTURE

### BOARD REVIEW

#### I Scientific basis for RPD design

##### A Longitudinal studies

1. Longitudinal studies of up to eight years in length indicate that in partially edentulous arches restored with removable partial dentures, few undesirable changes can be attributed to the wearing of the removable partial denture. There is little or no difference in caries, change in sulcus depth, tooth mobility, or bone loss in wearers vs. nonwearers. Few teeth were lost.

There was generally some increased gingival inflammation in regions covered by the RPD. Oral hygiene in these studies was less than ideal. There was little evidence in these studies that the presence of RPD's was causing dental or periodontal breakdown.

Schwalm, C.A., Smith, D.E., and Erickson, J.D.: Clinical study of patients one to two years after placement of removable partial dentures. *J. Prosthet Dent* 38:380-91, 1977.

Benson, D. and Spolsky, V.W.: A clinical evaluation of removable partial dentures with I-bar retainers. Part I. *J Prosthet Dent* 41:246, 1979.

Kratochvil, F.J., Davidson, P.N. and Tandarts, J.G.: Five year study of treatment with removable partial dentures. Part I. *J Prosthet Dent* 48:237, 1982.

Chandler, J.A. and Brudvik, J.S.: Clinical evaluation of patients eight to nine years after placement of removable partial dentures. *J Prosthet Dent* 51:736, 1984.

2. A longitudinal study of removable partial denture patients 13 years after placement indicated a correlation between good oral hygiene and good results of treatment of 68 partial dentures in 58 patients. Twenty-three were still being worn, 14 had new partial dentures, and 21 were not being used and not replaced. The periodontal problems were rarely serious.

Carlsson, G.E., Hedegard, B., and Koivumaa, K.K.: Late results of treatment with partial dentures. An investigation by questionnaire and clinical examination 13 years after treatment. *J Oral Rehabil* 3:267, 1976.

3. The effect of extension base removable partial dentures on oral function, esthetics, comfort and periodontal support was studied in a three part investigation comparing subjects with shortened dental arches (SDA) and subjects with SDA restored with removable partial dentures (RPDs). Significant

differences were noted in subjects restored with RPDs. They reported: limited mobility of the mandibles; impaired chewing capacity; and chewing with the anterior teeth. They also reported more esthetic complaints - RPDs did not significantly improve oral comfort. The differences with regard to periodontal support were small. However, the combination of pre-existing and existing periodontal disease involvement and SDA is considered to be an unfavorable situation.

Winter, D.J.: The effect of removable partial dentures on oral function in shortened dental arches. *J. Oral Rehabil* 16:27-33, 1989.

- Oral comfort in shortened dental arches. *J. Oral Rehabil* 17:137-43, 1990

- Shortened dental arches and periodontal support. *J. Oral Rehabil* 18:203-12, 1991.

## **B. Tissue response to removable partial dentures**

1. The amount of bone resorption beneath removable partial denture bases is related to the type of teeth in the opposing arch.

Plotnick, E.I., Beresin, V.E. and Simkins, A.B.: The effects of variations in the opposing dentition on changes in the partially edentulous mandible. Part I. Bone changes in serial radiographs. *J Prosthet Dent* 33:278, 1975.

2. Periodontal disease variables were shown to be more severe in individuals wearing removable partial dentures in a cross sectional study. Age did not have a significant effect on these variables.

Rissin, L., House, J.E., Conway, C., Loftus, E.R. and Chauncey, H.H.: Effect of age and removable partial dentures on gingivitis and periodontal disease. *J Prosthet Dent* 42:217, 1979.

3. The use of the Peritron to follow changes in gingival health has been investigated, and its feasibility established. This instrument measures the flow of gingival crevicular fluid which is related to changes in gingival health. The method could give a rapid indication of the effect removable partial denture designs have on gingival health.

Spielberger, M.C., Lubow, R.M., Bange, A.A. and Mayhew, R.B.: Effect of retentive clasp design on gingival health: a feasibility study. *J Prosthet Dent* 52:397, 1984.

4. If good plaque control and good oral hygiene are established, and if the removable partial denture is properly maintained, the forces transmitted to the abutment teeth do not seem to induce periodontal breakdown.

Bergman, B.: Periodontal reactions related to removable partial dentures: A literature review. *J Prosthet Dent* 58:454, 1987.

5. A longitudinal study (10 years) confirmed results of initial study. Patients who demonstrated good oral hygiene and maintenance of their removable partial dentures, had better results from a periodontal point of view.

Bergman, B. and Ericson, G.: Cross-sectional study of the periodontal status of removable partial denture patients. *J Prosthet Dent* 61:208, 1989.

6. Partial denture, irrespective of professional problems, appears to affect coronal and root caries of abutments. Partial dentures requiring maintenance were related to periodontal status. Good oral hygiene and maintenance are directly related to partial denture success.

Drake, C.W. and Peck, J.O.: The oral status of elderly removable partial denture wearers. *J. Oral Rehabil* 20:53, 1993.

## II. Treatment Planning and Design

### A. Biomechanics and Design Considerations

#### 1. Possible movements of extension base RPDs

- a. Concepts of the movements of the extension base removable partial dentures suggest that there are at least three possible rotational movements:

- 1) *rotation about an axis through the most posterior abutments*
- 2) *rotation about a longitudinal axis as the distal extension base moves in a rotary direction about the residual ridge*
- 3) *rotation about an imaginary vertical axis located near the center of the dental arch.*

McGivney, G.P., and Castleberry, D.J.: McCracken's Removable Partial Prosthodontics, 8th Edition, St. Louis, C.V. Mosby Co., 1989.

- b. **These axes of rotation may be through occlusal rests or any other rigid portion of a direct retainer assembly located occlusally or incisally to the height of contour of the abutments.**

McGivney, G.P., and Castleberry, D.J.: McCracken's Removable Partial Prosthodontics, 8th Edition, St. Louis, C.V. Mosby Co., 1989.

Renner, R.P. and Boucher, L.J.: Treatment of Partially Edentulous Patients. Chicago. Quintessence Publishing Co., 1987.

Krol, A.J., et al: Removable Partial Denture Design. U of Pacific School of Dentistry bookstore, San Francisco, CA. 1990.

Kratochvil, F.J.: Partial Removable Prosthodontics, Philadelphia, W.B. Sanders 1988.

*Stewart, K.L., Rudd, K.D., and Kuebker, W.A.: Clinical Removable Partial Prosthodontics, Ishiyaku EuroAmerican Inc., St. Louis - Tokyo, 1992.*

- c. An axis of rotation is created through the most distally placed occlusal rests when a distal-extension removable partial denture is loaded. If the residual ridges are of unequal lengths, this axis of rotation may not be perpendicular to the residual ridges. The resultant movement of asymmetric denture bases and their effect on the tissues are discussed. Movement of I-bar retainers located on the mesiobuccal aspect of asymmetrical abutment teeth may torque the abutment teeth as the denture base moves tissueward. Use of L-shaped direct retainers on the distobuccal surveyed undercut will create a more favorable class II lever effect on the abutment tooth.

*Aviv, I., Ben-Ur, Z., Cardash, H.S.: An analysis of rotational movement of asymmetrical distal-extension removable partial dentures. J Prosthet Dent. 61(2):211-4. 1989.*

2. Type / direction of stress that activate movements of the extension base partial denture.

- a. Magnitude and direction of these rotational movements are dependent upon Tooth and Tissue support, design characteristics and the fit of the RPD, masticatory stresses, and patient habits.

*McGiuney, G.P., and Castleberry, D.J.: McCracken's Removable Partial Prosthodontics, 8th Edition, St. Louis, C.V. Mosby Co., 1989.*

*Renner, R.P. and Boucher, L.J.: Treatment of Partially Edentulous Patients, Chicago, Quintessence Publishing Co., 1987.*

*Krol, A.J., et al: Removable Partial Denture Design. U of Pacific School of Dentistry bookstore, San Francisco, CA. 1990.*

*Kratochvil, F.J.: Partial Removable Prosthodontics, Philadelphia, 1988, W.B. Sanders.*

*Stewart, K.L., Rudd, K.D., and Kuebker, W.A.: Clinical Removable Partial Prosthodontics, Ishiyaku EuroAmerican Inc., St. Louis - Tokyo, 1992.*

b. Force analysis

- 1) Several investigators have studied the stresses produced by various clasping systems. Photoelastic studies have indicated that the RPI design or the mesial rest with a wrought retentive arm produce the best stress distribution (Kratochvil 1975, 1977, 1981; Thompson 1977). The periodontometer has been used to study stresses on abutment teeth. There was no difference in rest and clasp design (McCartney 1980). Strain gauges have been used to measure stresses on abutment teeth. There were variations between patients

# **Removable Partial Dentures - Part 2**

**Dr. Edward J. Billy**



# REMOVABLE PARTIAL DENTURE

## BOARD REVIEW

### III. Mouth Preparations -

All the information cited is mostly empirically based. None of these investigations will withstand critical analysis for scientific validity.

#### A. Surveying

1. A survey of specialists and graduate students or residents attending the American College of Prosthodontists was conducted at their annual meeting in 1987. The survey was designed to determine the philosophies and techniques used by prosthodontic specialists in treatment involving the removable partial denture. There were 195 questionnaires completed and used in determining the results. The results indicated areas of general agreement. Comparison with other data shows areas of controversy, but prosthodontists tend to follow techniques and philosophies similar to what is taught in most U.S. dental schools and what is recommended by the Academy of Denture Prosthetics (Academy of Prosthodontics)

Burns DR, Ward JE and Nance GL. Removable partial denture design and fabrication survey of the prosthodontic specialist. J Prosthet Dent 62[3]:303-7, 1989 Sept.

According to Krol, whenever possible, cast should be surveyed with the occlusal plane parallel to the base of the surveyor so that its path of placement is perpendicular to the occlusal plane. This position usually demonstrates favorable tooth contours, which permits the development of an acceptable design. This neutral or zero degree tilt facilitates the development of a path of placement, which may be easily managed by the patient.

Krol AJ, Jacobson TE and Finzen FC. Removable Partial Denture Design - Outline Syllabus, 4th Ed., Pg 25. Univ. of Pacific School of Dentistry Bookstore, San Francisco, CA 1990.

2. Recording the relation of a cast to the surveyor is mandatory for accurate fabrication of the partial denture framework. Prosthodontic residents were only able to reproduce the tripod orientation at  $\pm 0.2$  mm at each of three reference points an average of 0.3 degree of cast angulation error.

Bowley JF. Accuracy of cast reorientation to a surveyor. J Prosthet Dent. 1992; 68:294-8.

Others have described method of accurately orienting the cast during surveying. Davenport described a bubble gauge for recording the path of placement.

Davenport JC. Bubble gauge for recording path of placement. J Dent. 18(4):198-202, 1990 Aug.

Recently, Johnson described the need to identify both occlusogingival and mesiodistal undercuts when the path of random dislodging forces are not definitely controlled. He has devised a method to identify these undercuts by modifying the Ney surveyor. This aid will help in preventing the creep of the retentive clasp from undercuts in any direction.

Johnson DL. Retention for a removable partial denture. J Prosthodont 1992; 1:11-17.

Johnson DL. Adapting a dental surveyor to function in Two Planes. J Prosthodont 1993;2:206-210.

3. The use of a surveyor to determine the overall design of the removable partial denture has been generally accepted by prosthodontic specialists. Decisions on the augmentation of bony and soft tissue undercuts, recontouring of teeth to facilitate the path of insertion, and the alteration to the abutment tooth to best satisfy the chosen clasp assembly can only be accomplished in a systematic way by the use of a surveyor. Therefore, one of the main users of this instrument is to determine mouth preparation.

McGivney GP and Castleberry DJ. McCrachen's Removable Partial Prosthodontics, 8th Ed., St. Louis, C.V. Mosby Co., 1989.

#### B. Sequence of abutment preparations.

1. The accept sequence of mouth preparation is to prepare the guiding plane first so that the dimensions of the rest can be properly executed. According to Krol, guiding planes are not required for rotational path removable partial dentures and may be of questionable value for tooth supported removable partial dentures. Krol also recommends in extension base RPD's, the occlusogingival form to be flat, confined to the occlusal one third, and 2-3 mm in length. The faciolingual dimensions are confined to the proximal surface, rounded faciolingually in harmony with the existing tooth contour and 3-4 mm in width. Stern associated the guiding plane with the retention of the clasp. He recommended action distance = reciprocative distance = length of guiding plane. While Krotovichil advocates a longer guiding plane to eliminate the food impaction distal to the terminal abutment. He allows freedom of movement of the framework assembly by "physiologically relieving the casting. Demer points out the problems of a distal guide plane if left above the height of contour or a mesially tipped tooth whose distal guide plane is less than 90° to the occlusal plane.

McGivney GP and Castleberry DJ. McCrachen's Removable Partial Prosthodontics, 8th Ed., St. Louis, CV Mosby Co., 1989.

Krol AJ, Jacobson TE and Finzen FC. Removable Partial Denture Design - Outline Syllabus, 4th Ed., Pg 25, Univ. of Pacific School of Dentistry Bookstore, San Francisco, CA 1990.

Stern WJ. Guiding planes in clasp reciprocation and retention. J Prosthet Dent 34:408-414, 1975.

Kratochivil FJ. Partial Removable Prosthodontics. Philadelphia, W. B. Saunders Co., 1988.



Demer WJ. An analysis of mesial rest-I-bar clasp designs. J Prosthet Dent. 36:243-253, 1976.

2. The preparation of the occlusal rest has been outlined in several text books and articles. The general consensus is that it is spoon shaped, one third the faciolingual width of the tooth, one half the width between the facial and lingual cusp tip, approximately 1 mm in thickness, the seat should be lower in the middle of the tooth than at the marginal ridge, and the junction with the minor connector is rounded to avoid a fracture point. Variations in anterior design such as V-shaped, C-shaped, or ledge have been advocated. However, caution of dentin exposure was noted in an average of 55% of the preparations. In the molar tooth, Kratochivil recommends carrying the rest into the distal fossae to better direct the occlusal forces.

Krol AJ, Jacobson TE and Finzen FC. Removable Partial Denture Design - Outline Syllabus. 4th Ed., Pg. 142, Univ. of Pacific School of Dentistry Bookstore, San Francisco, CA 1990.

McGivney GP and Castleberry DJ. McCracken's Removable Partial Prosthodontics, 8th Edition, St. Louis, CV Mosby Co., 1989.

Jones RM. Dentin exposure and decay incidence in removable partial denture rest seats. Int J Prosthodont 5:227-36, 1992.

Kratochivil FJ. Partial Removable Prosthodontics, Philadelphia, WB Saunders Co., 1988.

3. The treatment of the abutment teeth for clasp placement has gone from unaltering the form of the tooth (Roach) to total alteration of the tooth (McCracken) and variation in-between with the use of veneers (Dixon).

Roach FE. Principles and essentials of bar clasp partial dentures. JADA. Jan 1930, pp. 124-138.

McGivney GP and Castleberry DJ. McCracken's Removable Partial Prosthodontics. 8th Ed., St. Louis, CV Mosby Co., 1989.

Dixon DL, et al. Use of a partial-coverage porcelain laminate to enhance clasp retention. J Prosthet Dent. 63:55-58, 1992.

- a. Axin described a method of recontouring abutment to establish a retentive area. He cautions that if the tooth diverges from the parallel more than a few degrees, a retentive undercut would not be possible without taking away an excessive amount of tooth structure.

Axin S. Preparation of retentive areas for clasps in enamel. J Prosthet Dent. 34:405-407, 1975.

- b. Smith describes the use of crowns to modify abutment tooth contours to better accommodate the clasp assembly.

Smith BJ and Turner CH. The use of crowns to modify abutment teeth of removable partial dentures. J Dent. 7:52-56, 1979.

- c. Dixon used a porcelain laminate restoration to enhance the retention of a wrought wire clasp. She later tested the wear on porcelain using a wear machine. The results showed no debonding with equivalent wear up to five years. The combined wear of a clasp and porcelain showed no significant difference from the combined wear of a clasp and human enamel. A similar study on composite resin by Tiege demonstrated that the resin clasp combination wear can be as much as five times that of the human tooth and clasp.

Dixon DL, et al. Wear of I-bar clasps and porcelain laminate restorations. *Int J Prosthodont* 5:28-33, 1992.

Tiege JD, et al. In vitro investigation of the wear of resin composite materials and cost direct retainers during removable partial denture placement and removal. *Int J of Prosthodont*. 5:145-153, 1992.

### C. Use of isolated abutments

Goodkind studied the effects of a lone standing premolar tooth during removable partial denture function. He concluded that more mobility was noticed when the occlusal rest was moved anteriorly or mesially. The use of wrought wire allowed for more movement buccally. The wear on the distolingual aspect of the tooth suggested relief of that portion of the proximal plate. He recommended splinting lone standing teeth to increase their longevity.

Goodkind RT. The effects of removable partial dentures on abutment tooth mobility: A clinical study. *J Prosthet Dent*. 30:139-46, 1973.

### D. Splinting

#### 1. Periodontal effect

Waerhaug reported that splinting did not significantly help reduce the mobility of teeth. He stated that the periodontal fibers are very capable of supporting the teeth even when damaged by periodontal disease. He stated that clinical trials and experimental data did not support splinting to reduce mobility. Good periodontal therapy will reduce mobility in itself. Mobility does not cause bone loss.

Waerhaug J. Justification for splinting in periodontal therapy. *J Prosthet Dent*. 22:201-207, 1969.

Selipsky discussed the indications and contraindications for splinting. Based on the data he collected, he feels splinting should be avoided if possible, but not evaded if necessary. He states such indications as replacement of missing teeth, patient discomfort from loose teeth, retention of teeth in new positions often orthodontic movement, prevention of extrusion of unopposed teeth, and extreme residual mobility after therapy, usually related to severe and continued parafunctional habits would constitute splinting.

Selipsky H. Osseous surgery - How much need we compromise? *DCNA* 20:1, 79-106, 1976.

Franzetti recognizes the need for splinting when a removable partial may increase the torquing on the abutment teeth. The stability should be determined in provisional splints. If provisional splints fail to stabilize the teeth, then additional teeth should be included in the splinting. In any case, a sufficient number of nonmobile and/or mobile teeth must be included in planning for the splinted segment to achieve adequate long-term stabilization.

Franzetti JJ. Periodontal considerations and guidelines for therapy. DCNA 29:1, 17-38, 1985.

2. Stewart evaluated the mobility of teeth before and after treatment with removable partial denture that stabilized weakened teeth. He showed that carefully planned and constructed partial dentures with guiding planes appear to be effective in stabilizing weakened teeth.

Stewart KL and Rudd KD. Stabilizing periodontally weakened teeth with removable partial dentures. J Prosthet Dent 19:475, 1968.

Becker discussed the theoretical and practical considerations in treating secondary occlusal traumatism with removable prostheses. Long-term success depends on a continued control of periodontal inflammation and occlusal traumatism. A recommended cause of treatment was divided into three equally important segments of (1) periodontal therapy, (2) the removable prosthesis, and (3) close maintenance.

Becker CM and Kaldahl WB. Using removable partial dentures to stabilize teeth with secondary occlusal traumatism. J Prosthet Dent. 47:587-594, 1982.

Kratochvil studied the effect of splinting on abutment teeth with attachments using photoelastics. His results showed more favorable force concentration on those abutments that were splinted. Attachment abutments that were not splinted showed a more induced distal force, which resulted in unfavorable horizontal bone forces.

Kratochvil FJ, et al. Photoelastic analysis of stress patterns on teeth and bone with attachment retainers for removable partial dentures. J Prosthet Dent. 46:21-28, 1981.

Fisher in a longitudinal study reported on the influence of base stability on abutment teeth. He reported in those patients with poor base stability, the abutments with negative mobility in splinted teeth had a slightly high percentage ratio than those restored or unrestored. However, there was no significant difference between the groups.

Fisher RL. Factors that influence the base stability of mandibular distal extension removable partial dentures: A longitudinal study. J Prosthet Dent. 50:167-171, 1983.

## E. Materials

### 1. Framework

Cunningham discussed the advantages and disadvantages of Type IV gold alloys and base metal alloys. He concludes that the decision is up to the dentist. However, he states some factors that may influence the selection are (1) the availability of space for the major connectors, (2) the amount and location of undercut on the proposed abutment for retention, (3) the complexity of the framework design, (4) the question of whether intracoronal attachments are used, (5) the availability of competent technical assistance, and (6) cost.

Cunningham DM. Comparison of base metal alloys and Type IV gold alloys for removable partial denture frameworks. *DCNA* 17:4, 719-722, 1973.

Stevenson reported the favorable properties of titanium used as a maxillary overdenture. He states the titanium base weights substantially less than conventional resin dentures. It requires an adhesive resin to increase the bond to the resin. The biocompatibility of titanium is well documented. He feels it represents the state of the art in denture base materials.

Stevenson GC and Connelly ME. Titanium palate maxillary overdenture: A clinical report. *J Prosthodontics* 1:1, pp 57-60, 1992.

### 2. Resins

Conventional denture base resins have been used to replace the extension base of a removable partial denture. The introduction of bonding resins to improve the attachment of the metal/resin interface have been introduced. These include fused silane (silicoater), chemically bonded (4 Meta), and Tribocarbonate (Roca Tec) which improves resin adhesion and reduces microleakage.

Bahammon SA, et al. Application of silica coating technique for removable prosthodontics. A clinical report. *J Prosthet Dent*. 65:1-3, 1991.

Tiller HJ. The Kulzer silicoater method. Evaluation from the scientific-material science viewpoint. *Zahntechnik* 44:48-49, 1986.

Nord RS. Krelzer's silicoater. A new technique for bonding methacrylates to metal *Trend Tech Contemp Dent Lab*. 3:32-38, 1986.

Tiller HJ, et al. Sandblasting process and its use in surface conditioning of dental alloys. *I Quintessence* 36:1927-1934, 1985.

Tiller HJ, et al. Sandblasting procedures and its effect on the surface properties of dental alloys. *I Quintessence*. 36:2151-58, 1985.

Jacobson TE. The significance of adhesive denture base resin. *Int J Prosthodont*. 2:163-172, 1989.

Jacobson TE, et al. Bond strength of 4-META acrylic resin denture base to cobalt chromium alloy. *J Prosthet Dent*. 60:570-576, 1988.

#### IV. Impressions for Removable partial dentures.

##### A. Anatomy

The anatomy of the denture bearing area has been well documented. A review of any removable partial denture text will illustrate this.

McGivney GP and Castleberry DJ. McCracken's Removable Partial Prosthodontics. 8th Ed., St. Louis, C.V. Mosby Co., 1989.

Krol AJ, et al. Removable Partial Denture Design. Univ. of Pacific School of Dentistry Bookstore, San Francisco, CA 1990.

Kratochvil FJ. Partial Removable Prosthodontists, Philadelphia, 1988, W. B. Saunders.

Stewart KL, Rudd KD, and Dieblser WA. Clinical Removable Partial Prosthodontics. Ishiyaku Euro American Inc., St. Louis-Tokyo, 1992.

Monteith described a method to classify the total resistance potential of the supporting structures of a distal extension jaw. This is achieved first by identifying the ridge resistance and abutment resistance of the jaw and then by awarding each of these either a positive or negative score. Thus, the jaw is classified as falling into one of four possible categories. It is hoped that such a classification will increase practitioners' awareness that the supporting structures should dictate the choice of treatment modality.

Monteith BD. Management of loading forces on mandibular distal-extension prostheses. Part II: Classification for matching modalities to clinical situations. *J Prosthet Dent*. 52:832-835, 1984.

##### B. Tissue Conditioning

Lytle studied the displacement of soft tissues beneath the denture base of complete and partial dentures. He concluded (1) dentures that cause only minimal displacement are more ideal than those that cause excessive displacement, (2) denture bases should cover the maximum area of denture bearing area, (3) denture bases should not extend into unhealed sockets, (4) interceptive occlusal contacts should be eliminated prior to the time the patient wears a new denture, (5) removable partial dentures should be designed strategically placing rests on remaining natural teeth, (6) soft tissues that have been displaced by ill-fitting dentures should be returned to normal form before impressions are made for new dentures, and (7) future denture service should include conditioning of soft tissues of the denture foundation.

Lytle RB. Soft tissue displacement beneath removable partial and complete dentures. *J Prosthet Dent* 12:34-43, 1962.

Manderson studied the behavior of biologic tissues under a load and states the value of these results in understanding how to assess and treat these tissues prior to making an impression. When the support for a prosthesis is derived from different sources, e.g., teeth, mucosa, teeth and mucosa, or implant, the displacement of the supporting tissues will vary in magnitude and character and may justify special impression techniques or stress relieving designs.

Tissues that have been subjected to sustained or intermittent loads require treatment by tissue conditioners and/or complete resting for several hours before recording impressions if a distorted record of the tissues is to be avoided.

Manderson RD, et al. Biomechanics of denture-supporting tissues: Proceedings of the Second International Prosthodontic Congress. pp. 98-101, St. Louis, C.V. Mosby Co., 1979.

McCarthy discusses the composition of the different conditioning and soft lining denture base materials. He reviews the application of these materials as to their intended use. He concludes that there should be some controlled clinical research to develop guidelines that will enable the manufacturer to develop materials designed to fulfill specific clinical requirements regarding plastic and elastic phase properties.

McCarthy JA and Moser JB. Tissue conditioning and functional impression materials and techniques. DCNA 28:2, 239-251, 1984.

### C. Methods of impression making

#### 1. Influencing factors

Stewart and Rudd's text defines three basic philosophies that influence the method in which impressions for removable partial dentures are made.

Stewart KL. Clinical Removable Partial Prosthodontics. Ishiyaku Euro American Inc., St. Louis Chapter 12, 13, and 14, 1988.

- a. Stress equalization registers the tissues in their anatomical position (Mucostatics). Page first presented mucostatics to the profession in 1937. The principle demands an impression and a denture base that are accurate negatives of ridge tissues in their passive form. Clayton uses this method to make impressions for the Stable Base Precision Attachment Removable Partial Denture.

Clayton JA. A stable base precision attachment removable partial denture (PARPD): Theories and principles. DCNA 24:1:3-29, 1980.

Lee RE. Mucostatics, DCNA 24:1:81-96, 1980.

- b. Physiological basing or (functional) is a method that records the supporting tissues under an applied load. The theory suggests displacement of tissue under a functional load. This theory is supported by Hindels, Preiskel, and Blatterfein.

Hindels GW. Load distribution in extension saddle partial dentures. J Prosthet Dent 2:92-100, 1952.

Preiskel HW. Impression techniques for attachment retained distal-extension removable partial dentures. J Prosthet Dent 25:620-627, 1971.

Blatterfein L, et al. A loading impression technique for semiprecision and precision removable partial dentures. J Prosthet Dent. 43:9-14, 1980.

- c. Broad stress distribution or (selective pressure) describes a method that selectively places tissues to support a functional load. It differs from the functional theory in that no load is applied during making the impression. This theory is supported by Applegate, Holmes, Leupold, and Krotchvil.

Applegate OC. Essentials of Removable Partial Denture Prosthesis. Saunders, Co., 3rd Ed., Pp. 253-274, 1965.

Holmes JB. Influences of impression procedures and occlusal loading on partial denture movement. J. Prosthet. Dent 15:474-481, 1965.

Leupold RJ. A comparative study of impression procedures for distal extension removable partial dentures. J Prosthet Dent 16:708-720, 1966.

Krotchvil FJ. Partial Removable Prosthodontics, Philadelphia, W. B. Saunder Co., 1988.

## 2. Material Selection

Christensen and Koran discuss impression materials; their uses and their contraindications. Impression material should be compatible with the impression philosophy used.

Christensen GJ. Impression materials for complete and partial denture prosthodontics. DCNA 28:2:223-238, 1984.

Koran A. Impression materials for recording denture bearing mucosa. DCNA 24:1:27-111, 1980.

3. Technique - refer to part one on influencing factors. All the techniques are described in these articles.

## D. Cast formation

### 1. Pouring the master cast

Young studied the cast surface when the impressions were inverted and allowed to set vice non-inverted impression. Sixty-four samples were evaluated. The inverted samples showed a rougher cast surface.

Rudd compared the surface of casts soaked in slurry and casts soaked in tap water. After six hours, no difference was noticed between the casts soaked in slurry and the control. However, the casts soaked in tap water showed a difference from the control in only 15 minutes.

Young JM. Surface characteristics of dental stone: Impression orientation. J. Prosthet Dent. 33:336-341, 1975.

Rudd KD, et al. Comparison of effects of tap water and sherry water on gypsum casts. J Prosthet Dent. 24:563-570, 1970.

## 2. Altered casts

Pouring the corrected ridge impression requires attention to detail if distortion and/or misorientation will not result. Rudd describes several methods to accurately pour the corrected cast impression.

Rudd KD, Morrow RM and Eissmann HF. Dental Laboratory Procedures - Removable Partial Dentures. pp 30-57, St. Louis, C.V. Mosby Co., 1981.

## V. Occlusal Relationships for Removable Partial Dentures

### A. Interocclusal Records

Whitbeck describes how the methods in recording the occlusal relationship depends on the number of remaining teeth and the opposing dentition. Several text books on removable partial dentures also address the methods for recording jaw relations. A major consideration would be the position of the mandible when recording these jaw relations. Should maximum intercuspation (centric occlusion) be recorded or the centric relation position?

Whitbeck BS and Ivanhoe JR. Occlusal relationships. DCNA 29:1:149-162, 1985.

McGivney GP and Castleberry DJ. McCracken's Removable Partial Prosthodontics. 8th Ed., Chapter 16. St. Louis, C.V. Mosby Co., 1989.

Renner RP and Boucher LJ. Treatment of Partially Edentulous Patients. Chicago, Quintessence Publishing Co., 1987.

Stewart KL, Rudd KD and Kuebker WA. Clinical Removable Partial Prosthodontics. Ishiyaku EuroAmerican Inc., St. Louis-Tokyo, 1992.

### B. Occlusal Schemes

The selection of the occlusal scheme is empirically based. A general consensus is that when a bilateral extension based removable partial denture opposes another bilateral extension based removable partial denture or complete denture, bilateral balanced occlusion is indicated. In all other situations, no balance is indicated. Browning investigated the directional loading on an extension base removable partial denture and concluded that central loading produced the least movement to the primary abutments. Henderson stated that if most posterior natural teeth remain and there is no evidence of temporomandibular joint disorder, neuromuscular disturbances, or periodontal pathosis due to occlusal trauma, the restoration may be made with centric occlusion. When most natural centric stops are missing, the restoration should be constructed so that centric relation and centric occlusion coincide. Whitbeck stated the occlusal relationships of teeth, both functionally and esthetically, are of the utmost importance to the clinician in the fabrication of a successful fixed or removable prosthodontic restoration. He suggests a list of occlusal schemes to fit a variety of occlusal relationships treated with a removable partial denture prosthesis.

Browning J, et al. Effect of positional loading of three removable partial denture clasp assemblies on movement of abutment teeth. J Prosthet Dent 55:347-351, 1986.



Henderson D. Occlusion in removable partial prosthodontics. *J Prosthet Dent* 27:151, 1972.

Whitbeck BS and Ivanhoe JR. Occlusal relationships. *DCNA*, 29:1:149-161, 1985.

## VI. Insertion/Follow-up/Maintenance

### A. Insertion

#### 1. Framework Fit.

Eick found that the amount of abutment tooth and clasp assembly movement was significantly reduced after framework adjustment. When compared to no adjustment, the magnitude of the clasp assembly movement was reduced by more than half with the adjustment using a 10X stereomicroscope. After final adjustment with 10X magnification, the abutment tooth and clasp assembly moved together.

Brudvik discovered that the fitting and finishing of a removable partial denture framework can result in measurable loss of metal and affects its fit and function. Under ideal controls, electropolishing, stoning and polishing with rubber wheels can result in a loss of 0.127 mm of metal. Uncontrolled loss can be significantly higher 0.41 mm.

Eick JD, et al. Abutment tooth movement related to fit of a removable partial denture. *J Prosthet Dent* 75:66-72, 1987.

Brudvik J. The tooth removable partial denture interface. *J Prosthet Dent*. 68:924-927, 1992.

#### 2. Base Fit.

Several investigators suggested that the better the base fit, the less movement on the abutment teeth of a removable partial denture. Tebrock suggested that stable denture bases and good harmony in occlusion are more important than the clasp design. Cecconi demonstrated a decrease in abutment tooth movement when the ridge was fitted to the extension base. Holmes use of the corrected ridge impression (altered cast technique) to demonstrate a decrease in denture base movement.

Tebrock OC, et al. The effect of various clasping systems on the mobility of abutment teeth for distal extension removable partial dentures. *J Prosthet Dent*. 41:511-516, 1979.

Cecconi BT, et al. Fit of the removable partial denture and its effect on the abutment tooth movement. *J Prosthet Dent*. 25:515-519, 1971.

Holmes JB. Influence of impression procedures and occlusal loading on partial denture movement. *J Prosthet Dent*. 15:474, 1965.

#### 3. Occlusal Stability

Several investigators identified the need for good occlusal stability. The longitudinal study by Fisher indicated that one of the factors in poor mandibular extension base stability was the occlusal instability of complete dentures.

Appelbaum stated that occlusal schemes that fail to harmonize with the residual ridge morphology may lead to unnecessary post-insertion appointments and ultimately to failure of the prosthesis. Colman stressed the need to keep the occlusal work load transmitted to the alveolar bone within minimal limits so that it does not exceed the tissue tolerance. He regards the occlusion as one of the most important factors in this issue.

Steward in his text describes the methods of remounting removable partial dentures to effect better occlusion prior to insertion.

Billy and Shotwell describe a quick and accurate procedure for making a combination remount cast of stone and elastomeric material for removable partial dentures. This method does not require the blocking out of the partial denture prior to making the remount cast.

Fisher RC. Factors that influence the base stability of mandibular distal-extension removable partial dentures. *J Prosthet Dent.* 50:167-171, 1983.

Appelbaum M. Pans of Occlusion. *DCNA.* 28:2:273-285, 1984.

Colman AJ. Occlusal requirements for removable partial dentures. *J. Prosthet Dent.* 17:155, 1967.

Stewart KL, Rudd KD and Kuebker WA. Clinical Removable Partial Prosthodontics. Ishiyaku EuroAmerican Inc., St. Louis-Tokyo, 1992.

Billy EJ and Shotwell J. Combination stone and resilient material for removable partial denture remount cast described and compared with two other remount cast procedures. *J Prosthet Dent.* 71:417-9, 1994.

#### 4. Nutritional Counseling

Even though the placement of a prosthesis has been shown to improve the masticatory efficiency of an individual by giving them the ability to eat a variety of foods, it appears that in a study by Sandstrom and Linquist that when 23 edentulous patients were observed in dietary intake before and after treatment with an implant prosthesis, no patient changed their dietary intake. Gunne also reported the need for dietary counseling.

Sandstrom B and Linquist LW. The effect of different prosthetic restorations on the dietary selection in edentulous patients. *Acta Odontol Scand.* 45:423-428, 1987.

Gunne HJ. The effect of removable partial dentures on mastication and dietary intake. *Acta Odontol Scand.* 43:269-278, 1985.

#### 5. Oral hygiene instructions and caring for the prosthesis.

Wagner suggests early education to help patients prepare for their new prosthesis and understand the responsibility for its care and maintenance. This will build confidence within the patient lead to a better prognosis. He also suggests that the education program be tailored to fit each patient's dental, prosthodontic and emotional situation.

Wagner AG. Maintenance of the partially edentulous mouth and care of the denture. DCNA. 17:4:755-768, 1973.

Abere reviews the current concepts of post-placement care. He discussed the various methods of cleaning dentures, such as brushing, soaking, and ultrasonic cleaning. In addition, he looks closely at denture cleaners themselves, their efficiency, value, advantage and disadvantages.

Abere DJ. Post-placement care of complete and removable partial dentures. DCNA 23:1:143-151, 1979.

Tinanoff in a six-month double blind trial of 61 adults with fixed and removable partial dentures, comparing the clinical and microbial effects of brushing twice daily with either 0.22% NaF or 0.4% SnF<sub>2</sub>. The results demonstrated that those using SnF<sub>2</sub> had less gingivitis and fewer bleeding sites for both total teeth and abutment teeth. Plaque scores between groups were only statistically different for abutment teeth.

Tinanoff N, et al. Clinical and microbiological effects of daily brushing with either NaF or SnF<sub>2</sub> gels in subjects with fixed and removable dental prostheses. J Clin Periodontol. 16:284-290, 1989.

A study by Kostner studied the effect of cleansers on removable partial dentures. He indicated that Calgon Clorox changes the flexibility of base metal clasps. Tested commercial cleaners had no effect. Another study by Blackenstose showed that Polident and Efferdent had no effect. However, Mersene had some effect and Clorox showed pitting of the metal in eight hours.

Kastner C, et al. Effects of chemical cleansers on the flexibility of cast clasps. J Prosthet Dent. 50:473, 1983.

Blackenstose WM and Wells JG. Side effects of immersion type cleansers on the metal components of dentures. J Prosthet Dent 37:615, 1977.

## **B. Follow-up**

### **1. Short-Term**

Schwalen conducted a two year study on 93 patients. No oral hygiene instructions were given during the recall visits. The results showed that 93% of the patients in this study wore their partial dentures satisfactorily. There was an increase in recall plaque indices. It is believed that this was the result of patient neglect and not from the removable partial dentures. The teeth supporting the removable partial dentures did not show any clinically significant increase in mobility or sulcular depth after the two-year period.

Schwalen CA, et al. A clinical study of patients one to two years after placement of removable partial dentures. J Prosthet Dent. 38:380-391, 1977.

Kapur conducted a random clinical trial to compare the effectiveness of two partial denture designs, one with I bar retainers and one with circumferential retainers. One hundred thirty-four (134) patients with Kennedy Class I and II edentulous conditions. Thirty patients were considered failure, five because of abutment factors and 25 because of the lack of RPD use for eating. Five year success rates of 71.3% for

circumferential design did not differ significantly from the 76.6% for the I bar design ( $p > .05$ ).

There were no discernible changes in the nine periodontal health components of the abutment teeth with either of the two designs after 60 months. The results indicate that the two designs do not differ significantly in terms of success rates, maintenance care, and effects on abutment teeth. A well-constructed RPD of either design, supported by favorable abutments and accompanied by a regular recall program, offers a satisfactory treatment modality.

Kapur K, et al. A randomized clinical trial of two basic removable partial dentures. Part I: Comparison of five-year success rates and periodontal health. *J Prosthet Dent.* 72: 268-82, 1994.

Other short term studies related to this subject were conducted by Bergman and associates and also by Carlson and co-workers.

Bergman B, et al. Periodontal and prosthetic conditions in patients treated with removable partial dentures and artificial crowns. A longitudinal two year study. *Acta Odontol Scand* 29:621-638, 1971.

Carlson GE, et al. Studies in partial denture prosthesis II. An investigation of mandibular partial dentures with double extension saddles. *Acta Odontol Scand.* 19:215-237, 1961.

## 2. Long-Term

Fisher conducted an eight-year longitudinal study that evaluated 2,084 patient visits. Oral hygiene instructions were initiated during the patient's total treatment program. Prosthodontic treatment was not started until good gingival health existed. This study shows that poor mandibular distal extension removable partial denture base stability is significantly related to age of the patient, the fit of the framework, whether the patient wore a previous removable partial denture, and the opposing dentition. It is not necessarily related to the patient's sex, the classification of the prosthesis (Class I or II), the type or mobility of the abutments, and the materials used to make the impression of the edentulous ridge.

Fisher RL. Factors that influence the base stability of mandibular distal-extension removable partial dentures: A longitudinal Study. *J Prosthet Dent.* 50:167-171, 1983.

Bergman conducted a ten year study on 17 men and 13 women with a mean age of 52 years and a range of 24 to 80 years. Oral hygiene was part of their program. The teeth were sealed and polished with a rubber cup and pumice at the recall appointment. The patients were examined at yearly intervals at which time re motivation and reconstruction regarding oral hygiene was given. Patient cooperation was excellent and no significant deterioration of the periodontal status of the remaining teeth was found. In addition, there was a low increase in the frequency of decayed and filled tooth surfaces during the decade. The dentures showed damage and several changes during the follow-up period, conditions that necessitated various corrective prosthetic procedures.

Bergman B, et al. Caries, periodontal and prosthetic findings in patients with removable partial dentures: A ten year longitudinal study. J Prosthet Dent. 48:506-513, 1982.

**C. Maintenance**

The need for maintenance in servicing a removable partial denture patient is mandatory as stated in the Bergman study that various corrective prosthetic procedures were conducted during his ten year study. The repair and reline procedures are very adequately covered in several removable partial denture texts.

McGivney GP and Castleberry DJ. McCracken's Removable Partial Prosthodontics, 8th Ed., St. Louis. C.V. Mosby Co. 1989.

Stewart KL, Rudd KD and Kubker WA. Clinical Removable Partial Prosthodontics. Ishiyaku EuroAmerican Inc. St. Louis-Tokyo, 1992.

Renner RP and Baucher LJ. Treatment of Partially Edentulous Patients. Chicago. Quintessence Publishing Co., 1987.



# **Designing The Removable Partial Denture**

**Dr. Kenneth D. Rudd**





The essential elements in successful removable partial denture treatment are good plaque control, a healthy oral environment which has been prepared to receive a removable partial denture, and a design which is systematically developed from an evaluation of the diagnostic data. The tools commonly used to gather information are the health history, clinical examination, radiographs, mounted diagnostic casts, dental surveyor, and consultations as needed. The process of evaluating diagnostic information and converting the data into a recommendation for treatment requires deductive and reasoning skill which is based on the dentist's education, professional experience, creativity and judgment. An accurate master cast is essential because in prosthodontics everything is made to fit a cast not the mouth. When the cast is not an accurate duplication of the mouth or the restoration does not fit an accurate cast, it will not fit the mouth.

INTRODUCTION: The Dentist who initiates removable partial denture prosthesis is responsible for the design of the restoration. This is not and should not be the responsibility of the dental laboratory. This procedure is presented as a guide for the dentist who initiates these restorations. It advocates the use of diagnostic casts as an aid and guide in diagnosis and treatment planning as well as the actual mouth preparation. Completely designed casts represent probably the best prescription to the dental technician. The dental laboratory is responsible for the technical fabrication of the restoration as prescribed by the dentist. The laboratory's responsibility ends when they make a framework that fits the cast. They cannot be responsible for making it fit the mouth.

ARMAMENTARIUM:

1. Health history and clinical examination information.
2. Diagnostic radiographs.
3. Diagnostic casts.
4. Dental surveyor with cast holder, styli, and carbon marker.
5. Red, blue, brown and black pencils.  
Berol double color (red and blue) verithin 748  
Eagle verithin (dark brown) 756  
Venus drawing pencil (black lead) 4H
6. Work authorization form.

## COLOR CODE:

Recommended by:

Rudd, Morrow, Rhoads, 1986, and Stewart, Rudd, and Kuebker, 1992.

Red - Portions of teeth to be ground, prepared or re-contoured.

Blue - acrylic resin denture base outline

Brown - metal (framework or denture base).

Black - survey line and hard and soft tissue undercuts.

Recommended by:

Henderson and Steffel, 1981, and Johnson and Stratton, 1980

Red - solid red denotes any tooth alteration needed

Blue - outline denotes the form of the framework

Black - survey line on teeth and soft tissue contours

Red - outline denotes the extent of the plastic

## WHY SURVEY?

A cast is surveyed to:

1. Select abutments.
2. Locate rests.
3. Locate and mark desirable and undesirable hard tissue undercuts.
4. Locate and mark soft tissue undercuts.
5. Decide whether or not to recontour or restore teeth.
6. Mark survey lines.
7. Determine the path of insertion and removal.

## PRELIMINARY PROCEDURES:

Think about what you are going to do about the following features of the partial denture:

## Major Connectors

Major connectors must be rigid to distribute functional stresses throughout the mouth. They should be located so as to take advantage of multiple curvatures and convolutions of the surface to promote strength in less bulky forms. Gingival borders of major connectors laying solely on palatal mucosa should not be scalloped. Ordinarily the gingival border of a maxillary major connector will be placed 6 mm., and the mandibular major connector 4 mm., away from the gingival crest. Draw the major connector by outlining its form in brown.

## Minor Connectors

Minor connectors should be located in interproximal recesses if possible, so they can be made rigid. Strive to avoid covering naturally prominent surfaces with additional metal. Draw the minor connectors from the rests to the major connector by outlining them in brown.

## Reciprocation

Reciprocation may be achieved with guide plates, minor connectors, rigid clasp arms, plating and as a part of the denture base. If true reciprocation is to occur, the reciprocator must be placed on the opposite side of the abutment tooth so it will contact the abutment during the time that the retentive tip of the clasp passes over the height of contour. Sometimes, effective reciprocation is difficult to achieve.

## Bracing

Bracing elements of a removable partial denture are used to resist horizontal movement of the denture. They may also be used to produce bilateral stabilization for periodontally weakened teeth and, as such, will provide the most conservative, economical and hygienic stabilization available. Bracing is especially effective in removable partial dentures that are completely tooth supported. Draw the bracing elements by outlining them in brown.

## Denture Base Retention and Single Tooth Replacements

Large soft tissue defects can be restored with better esthetic results when denture teeth and a denture base are used. Also, plastic denture bases permit the clinician to reline the base overlying healing ridges (which may be re-contouring rapidly). The weakness

in fractures of many maxillary anterior denture bases comes from inadequate mass of plastic beneath, and communicating through the metal retention network. According to Dunny and King, the plastic tears from itself, but the metal seldom breaks. Single tooth replacements must be supported on all sides lest functional stresses overwhelm the retentive quality causing the facing to come loose. Whenever tube-teeth or custom-ground facings are employed, the shade and mold must be supplied on the work authorization form for the framework.

### Retention

Retention is an extremely complex and little understood quality of a denture to resist dislodging forces. It is achieved by placing retentive clasp arms in measured undercuts. When a removable partial denture is completely seated, all retainers must be passive. They should activate only when resisting dislodging forces.

### Orientation of the Cast

On the surveying table, the distal portion of the cast should be next to you so as you view the cast you are looking toward the lingual surface of the anterior teeth.

In the laboratory, all casts should be considered as being mandibular casts. This simplifies discussing the cast, the design, the tilt and the anatomy, i.e., when one says keep the clasp as low on the tooth as possible, whether it is a maxillary or mandibular cast, it will mean next to the gingival tissue of the tooth, or when we talk about a right or left tilt, it will mean that whether it is a maxillary cast or mandibular cast, a right lateral tilt will be to the right hand side of the person viewing the cast from the posterior position and vice versa for a left lateral tilt. It should be a cast orientation, not a mouth orientation.

## Before fastening cast to the surveying table:

1. Place a mark at the center of the cast.
2. Positioned above the cast, look down at the cast from a right angle vantage point.
3. Evaluate the inclinations of the proximal walls.
4. Evaluate the interferences, such as tori, exostoses, tipped teeth, bulbous crowns, high frenal attachments and shallow vestibules.
5. Evaluate natural undercuts on crowns of teeth that have the potential to receive retentive clasps.
6. Insure that esthetic values for anterior replacements are enhanced by tipping the cast in order to fill the edentulous space as much as possible.
7. Mount casts on a plasterless articulator or hand articulate them. Determine if there is enough space for rests, framework and teeth.
8. Before using the surveyor, place a pinch of non-fibered acrylic resin powder, on the surveyor platform (base).

## Surveying the Diagnostic Cast

In most cases, a compromise among the esthetic requirements, guideplanes, interferences, and potential retention produces a tilt that is not ideal for any individual determinant, but is optimal for the combination of the determinants. The process involves a continuous series of evaluations among all the proximal walls, undercuts, interferences and esthetic needs. The tilt of the cast may be adjusted many times as you check and recheck individual aspects of each undercut, etc. Ordinarily, the plane of occlusion should be parallel to the table top to start with. This orientation aligns the majority of the guideplanes so that subsequent adjustments to the tilt will probably produce a path of insertion/removal which varies less the 5° from the starting point. Remember that the path must be reproduced in the mouth if the denture is to function as planned. One should strive to develop a path of insertion/removal which will require the least amount of tooth alterations.

## PROCEDURE

1. Carefully examine the occluded diagnostic casts.
  - a. Examine the facial aspect of the occluded casts and locate the rest spaces to be prepared. Indicate these by a mark on the base or capital portion of the diagnostic casts and not on the cast teeth. Be assured of adequate rest spaces, at least 1 mm clearance for each rest. Indicate in red crayon any cuspal relief required to give additional rest clearance.
  - b. Examine the lingual aspect of the occluded casts to assure there is adequate space for proposed lingual rests, indirect retainers, etc. Draw a pencil line on the lingual surface of the upper anterior teeth, using the occluded lower anteriors as a guide, to determine the gingival and occlusal limits of any proposed rests or indirect retainers.
  - c. If tube teeth, reinforced acrylic resin teeth (RAP), or metal pontics are required, indicate with a pencil using the following symbols:
    - (1) T - Tube teeth
    - (2) RAP - Reinforced acrylic resin tooth
    - (3) M/ac - Metal Pontic with an acrylic resin window
    - (4) M - Metal pontic

Draw each symbol on the soft tissue or anatomical portion of the diagnostic cast below the crest of the ridge on the facial surface.

2. Place cast on the surveyor cast holder at a level or horizontal tilt. Examine teeth to be clasped with analyzing tool of the surveyor to determine location of usable undercuts, as well as the shape and contour of the proposed abutment teeth. If the shape and contour of these teeth require re-contouring, indicate the location and extent of the proposed alternation by outlining the area with a red crayon pencil. Examine the proposed sites for the minor connectors and struts at this time. Determine the most favorable tilt (if required) that will permit convenient and proper placement of clasps, minor connectors, anterior teeth, and denture bases. This will be the path of insertion and removal.

3. Tripod the diagnostic cast.
4. Clamp the analyzing rod or the carbon marker in the vertical arm of the surveyor and use the tip to place three widely separated marks on the lingual aspect of the cast. These marks will locate the horizontal plane of the cast as it sits on the tilt-top table. Make certain the vertical arm of the surveyor is locked in position and that only the tip of the marker is used to mark the cast. Circle the tripod marks in red crayon pencil (optional, after the cast is tripoded, it may be removed from the cast holder to draw this portion of the design on the cast).
5. Mark all contour changes which were noted during the development of the path of insertion/removal by circling them with red color. These will denote preparations for guideplanes, reduction of interferences, improvement of the occlusal forms, and other alterations that will enhance the position and/or quality of retention.
6. With a red crayon pencil, draw the exact extent of the rest seats to be prepared in the mouth. The entire rest seat portion of the cast should be solid red.
7. Outline all of the denture base sites with a crayon pencil. Blue crayon pencil indicates acrylic resin denture bases. Brown crayon pencil indicates metal denture bases. Do not draw the clasps at this time.
8. If the cast was removed from the cast holder in step 4, remount the cast on the cast holder and realign the tripod marks to reposition the cast in the same relation it was in before it was removed. Proceed to draw the survey line on the abutment teeth as well as other teeth that will be involved in the design of the partial denture.
  - A. Replace the carbon marker in the surveyor with the .010, .020, or .030 undercut gauge as the undercut condition, length, and size of the clasp arm indicate. (As a general rule, using chrome cobalt alloy castings, the .010 inch gauge will suffice for short clasp arms, the .020 inch gauge will suffice long clasp arms, and the .030 inch gauge will rarely be used for extremely long flexible clasp arms fabricated of wrought wire. Gold alloy castings will accommodate slightly more undercut than the chrome cobalt alloy castings.) Place the gauge on the

desired retentive undercut of the tooth so that the head and shank of the undercut gauge touch the tooth simultaneously. Mark this spot with a red crayon pencil. Verify the accuracy of this mark with the head of the undercut gauge. This red mark will position the gingival edge of the clasp tip that will engage the undercut.

- B. With the brown crayon pencil, draw the clasp arms with a double line so that the occlusal and gingival portions of the clasp arms will be indicated to the laboratory. (As a general rule, keep the clasp arms gingivally as far as possible on the clinical crown in harmony with the position and location of the survey line, and the depth of the undercut to be engaged by the clasp tip.)
- C With a black pencil, indicate the position and extent of undesirable soft tissue undercuts that may interfere with the insertion of the removable partial denture so that they will be blocked out by the technician.

9. Your design should now be completed.

#### ALTERNATE PROCEDURE

After preparations, re-contouring, etc., have been accomplished in the mouth, the master impression is made and poured with artificial stone, use the master cast as a reference, grind or scrape the diagnostic cast to approximate the alterations that appear on the master cast if the teeth were recontoured. After this is accomplished, make the necessary correction of the design on the diagnostic cast to conform to the preparations that have been made in the mouth. No markings, oil or grease, powder or design should be made on the master cast.



## REFERENCES AND BIBLIOGRAPHY

VandenBrink, JP; Wolfaardt, JF; Faulkner, MG: A Comparison of Various Removable Partial Denture Clasp Materials and Fabrication Procedures for Placing Clasps on Canine and Pre-molar Teeth, J. Prosthet. Dent., 1993; 70: 180-8.

Curtis, DA; Curtis, TA; Wagnild, GW: Incidence of Various Classes of Removable Partial Dentures, J. Prosthet. Dent., 1992; 67: 664-7.

Asher, ML: Application of the Rotational Path Design Concept to a Removable Partial Denture with a Distal-Extension Base, J. Prosthet. Dent., 1992; 68: 641-3.

Brudvik, JS; Reimers, D; The Tooth-Removable Partial Denture Interface, J. Prosthet. Dent., 1992; 68: 924-7.

Ahmad, I; Sherriff, M; Waters, NE: The Effect of Reducing the Number of Clasps on Removable Partial Denture Retention, J. Prosthet. Dent., 1992; 68: 928-33

Stewart, KL; Rudd, KD; Kuebker WA: Clinical Removable Partial Prosthodontics, ed 2, 1992, Chicago; Iskiyaku EuroAmerica, Inc.

Components of a Removable Partial Denture, pp. 19-96

Principles of Removable Partial Dentures, pp. 97-115

Survey and Design, pp. 221-266

I-Bar Removable Partial Dentures, pp. 267-275

McGivney, BP; Castleberry, DJ: McCracken's Removable Partial Prosthodontics, ed 8, 1989, St. Louis, Mosby.

Major & minor connectors, pp. 22-58

Rests & rest seats, pp. 59-77

Direct retainers, pp. 78-124

Indirect retainers, pp. 125-134

Denture base considerations, pp. 135-156

Principles of Removable Partial Denture Design, pp. 157-184

Surveying, pp. 185-208

Rudd, KD; Morrow, RM; Rhoads, JE: Dental Laboratory Procedures-Removable Partial Dentures, Volume Three, ed 2 1986, St. Louis, Mosby.

Wrought wire clasps, pp. 273-298  
Frictional wall precision attachment partial prosthesis, pp. 458-500  
Swing-lock, pp. 501-534  
Reinforced Facings (RAP) and metal backings, pp. 535-561  
Special purpose partial dentures, pp. 562-576

Henderson and Steffel:, McCracken's, Removable Partial Dentures, 6th ed, 1981, St. Louis, Mosby.

Major and minor connectors, pp. 18-43  
Direct retainers, pp. 62-96  
Indirect retainers, pp. 97-104  
Denture bases and stressbreakers (stress equalizers), pp. 105-119  
Principles of removable partial design, pp. 120-142  
Surveying, pp. 143-167

Johnson, DL; Stratton, RJ: Fundamentals of Removable Prosthodontics, 1980, Chicago, Quintessence.

Removable partial denture elements and their function, pp. 125-145  
Removable partial denture design based on an evaluation of diagnostic data, pp. 195-224

Zarb, GA., et al.: Prosthodontic Treatment for Partially Edentulous Patients, 1978, St. Louis, Mosby.

Removable partial Prosthodontics: clinical and laboratory protocol, pp. 409-521  
Alternative clinical techniques for the partially edentulous patient, pp. 525-563

King, GE; Dunny JH: Minor Connector Designs for Anterior Acrylic Resin Bases: A Preliminary Study; J. Prosthet, Dent., 1975; 34:496-592.

Kroll, AJ: RPI (rest, proximal plate, I bar) Clasp Retainer and It's Modifications; Dent. Clin. of North America, 1973; 17: 631-649.

Kratochvil, FJ: Influences of Occlusal Rest Position and Clasp Design on Movement of Abutment Teeth, J. Prosthet. Dent., 1963; 13:114-124.

# General Principles for Removable Partial Denture Design

## Kenneth D. Rudd, D.D.S.

(These are some but by no means all of the principles and they are not listed in the order of their importance)

1. Minimize the lateral movement of teeth.
2. Use an altered cast procedure, especially when tooth support is weak or soft tissues are compromised.
3. When using a clasp on a tooth next to the edentulous ridge on a distal extension removable partial denture, the clasp should be designed so it will not torque the tooth distally when masticating force is applied.
4. The reciprocal portion (arm) of a clasp on a tooth should be designed to support (immobilize) the tooth while the retentive arm is springing over the survey line (greatest diameter) and into or out of the retentive undercut.
5. All major connectors must be stiff enough to transfer an equal portion of the masticatory forces applied to one side of the arch to the opposite side.
6. When lingual plating is used, the entire superior edge (the edge towards the occlusal surface of the teeth) must be scalloped and must be occlusal to the survey line and each interproximal point must extend to the contact point on the teeth.
7. The approach arm of a bar type clasp must be kept close to the soft tissue.
8. When guiding planes are used, the laboratory must be instructed to use a zero degree blockout.
9. To stabilize a tooth, it must be supported on the mesial, distal, facial, lingual, and occlusal surfaces with clasps, minor connectors, rests, part of the denture base or reciprocation.
10. Rests must not be placed on an inclined plane.
11. Do not increase the vertical dimension of occlusion with a conventional removable partial denture.
12. A single tooth or small space replacement on a removable partial denture should be made with a tube tooth, reinforced acrylic resin pontic (RAP), solid metal, or metal with an acrylic resin window.
13. Denture base retention should be designed to support the acrylic resin not just hold it in place.
14. Finish lines should be undercut (V shaped) unless a special bonding process is used.
15. Denture teeth on a removable partial denture should be made of plastic when they are opposed by natural teeth, silver amalgam, gold, composite or other plastic denture teeth.
16. All partial denture frameworks must be fitted to the patients mouth.

## FUNDAMENTALS OF DESIGN

Factors of Design. Ideally every partial denture would have optimum appearance and the precise amount of retention needed to retain it. These attributes would be coupled with the required support and distribution of stresses to reduce to a minimum the strains on the abutment teeth. Such a partial would function indefinitely. The ideal patient would, of course, have excellent oral health, strong well-shaped abutments, and assume meticulous and continuing care of the partial and the mouth. Such ideal conditions are seldom, if ever, encountered. The usual partial denture patient will present a set of conditions which are far less than ideal. Each patient will offer his own peculiar problems. Success in this critically important phase of prosthodontics will depend to a large degree on a mutual understanding between the dentist and the laboratory technician concerning areas of responsibility each must assume. The knowledge and skill of each member of the doctor-technician team must be combined with a common goal if the patient is to receive the best that modern prosthetic dentistry has to offer.

### Planning the Design

Clinical Phase. There are two phases in the planning of the design for a cast partial denture. The first is the clinical phase. During this stage, the mouth is carefully examined and evaluated with the aid of diagnostic casts, radiographs and other diagnostic aids. Several decisions are called for at this time. For example, the question of whether a partial will be tooth borne, or borne by a combination of tooth and soft tissue, may hinge on whether or not a third molar is retained or extracted. Under certain conditions the tooth may be retained for the express purpose of providing needed support for a rest. A decision is sometimes necessary as to whether a prominent ridge of alveolar bone will be removed in the anterior region to make possible the insertion of a labial flange on the denture. On this decision may hinge the choice of anterior tooth to be used. A decision may be necessary as whether to remove surgically a torus, a tuberosity, or pendulous soft tissue. Occasionally a badly rotated or tipped tooth might be removed for esthetic or mechanical reasons.

Factors to be considered by the dentist during the clinical phase:

1. What type of prosthesis will the patient best tolerate? Age, sex, health and emotional makeup of the patient are important considerations.
2. What is the general condition of the mouth--the extent of dental decay? Will the patient maintain the mouth and the prosthesis with good oral hygiene?
3. What is the probable life of the abutment teeth? Is the bone support good?
4. How much support will the soft tissues provide? Is the tissue firm, soft or flabby? Would surgery improve it?

5. What esthetic problems might be encountered? Is the appearance apt to influence the patient's desire to wear the partial? Can the esthetic consideration be compromised for mechanical excellence?
6. What is the nature of the occlusion? Is the bite strong, medium or light? Do the remaining natural teeth require balancing?
7. Is the distribution of the remaining teeth favorable? Will any of the teeth interfere with good design? Do badly tipped or rotated teeth require disking to improve parallelism?
8. Is the intermaxillary space adequate? Could it be improved by surgery? Is there room in the anterior region for the tooth of choice?
9. Are the abutment teeth well shaped for clasping? Would disking of restorations improve the contour? Is the enamel thick enough for good rest seats, or should inlays or crowns be constructed and the rest seats prepared in the metal?

These decisions are the responsibility of the dentist and must be resolved before the final impressions are made.

Laboratory Phase. When the final impressions have been made and the master casts are complete, the second phase of planning begins. Some of the factors which now bear on the final design of the partial denture are:

1. The number and distribution of the remaining teeth-- are the abutments favorable for clasping?
2. The form of the ridges--are undercuts, tori or bulbous tuberosities present? What type of base is indicated?
3. The relationship of the maxillary and mandibular arch--will the occlusion be difficult to restore? What type of tooth will best suit the needs of the patient?
4. The type of opposing occlusion--will the partial function against natural teeth, another partial, or a complete denture?
5. The long axis inclination of the abutment teeth relative to each other--can the retention be equally distributed?
6. The amount of intermaxillary space--will there be adequate clearance for the connectors of choice? For the replacement of teeth?
7. The phonetics--can the connector and base be designed so that there is a minimum of interference with the speech mechanism?

8. The leverage factor--how long are the edentulous areas on either side of the fulcrum line? Can indirect retention be used to advantage?
9. The type of material--are the materials of choice available, and within a satisfactory financial range?

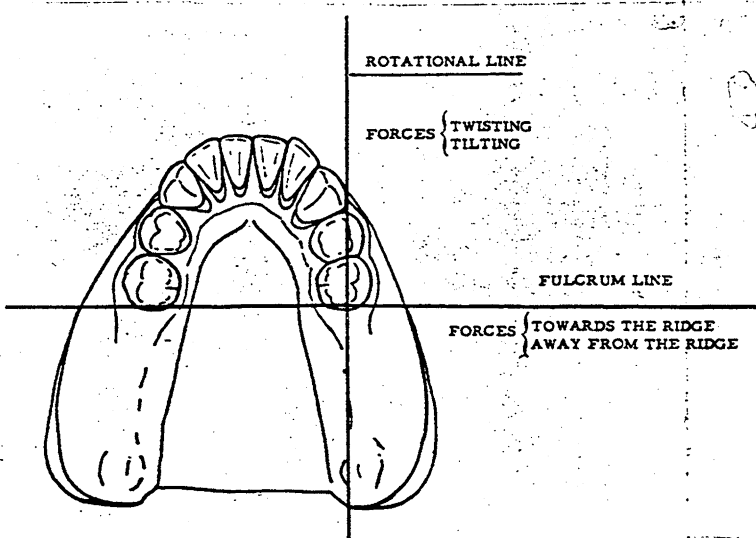
The Objective. The prime objective in cast partial denture design should be preserving the health of the remaining oral tissues. Firm retention should never be thought of as a final goal. The end to be sought is efficient masticatory function, equal distribution of stresses, and comfort and appearance as the patient perceives it.

Forces Acting on the Partial Denture. It is helpful in a study of partial denture design to approach the subject from this standpoint: What are the different forces which will act on the partial denture and how can they best be counteracted to reach the above objective?

When these forces have been analyzed, and are understood, they can be controlled by intelligent design.

All forces directed on a partial denture act on and around (1) the fulcrum line, and (2) the rotational line. Forces acting on the fulcrum line are either (1) towards the ridge, or (2) away from the ridge. Forces acting on the rotational line are either (1) twisting, or (2) tilting.

ROTATIONAL LINE - FULCRUM LINE



*Forces acting on the fulcrum line*

Force activated by	Resultant force	Counteracted by
Sticky foods Tongue and muscle pull Gravity (upper only)	Vertical lift	(1) Retentive clasps (2) Indirect retainers (3) Adequate base coverage (4) Correct placement of artificial teeth.
Occlusal load		

*Forces acting on the rotational line*

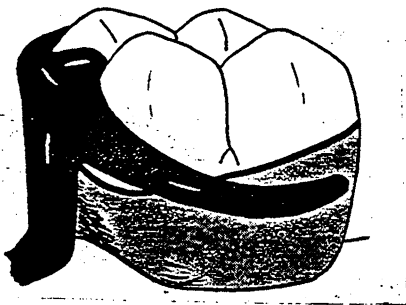
Masticatory stress (inter cusping teeth)	Twisting Tilting	(1) Balanced occlusion. (2) Adequate base coverage (3) Adequate Bracing. a. Rigid connectors b. Connector choice and design. c. Clasp design.
Lifting forces on opposite side of mouth	Twisting Tilting	

## FUNDAMENTALS OF CLASP DESIGN


All cast clasps can be divided into two groups based on the direction from which the retentive arm approaches the survey line.

Suprabulge Clasps. The clasps whose retentive arm approaches the undercut from the occlusal are known as "pull" type or suprabulge clasps. They are also known by a variety of other general names such as circlet, circumferential or Akers. In addition, each clasp has a specific name.

Infrabulge Clasps. Clasps whose retentive arm approaches the survey line from the gingival are known as "push" type or infrabulge clasps. As a group these are also known as bar, vertical projection or Roach clasps. Each have specific names depending on which letter of the alphabet they resemble.



Suprabulge Clasp



Infrabulge Clasp

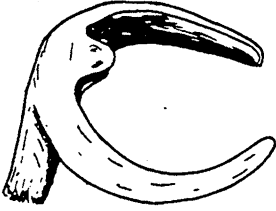
### SUPRABULGE CLASPS

Advantages of the Suprabulge Clasp. (1) Excellent bracing qualities; (2) Usually easier to design and construct; (3) Require less metal to construct, and usually less metal is lost in finishing; (4) More easily repaired if broken. Easier to straighten if bent; (5) Less possibility of food collection under the clasp; (6) The clasp body and shoulders help the occlusal rest to provide support; (7) Can be used conveniently with either a metal or an acrylic resin base.

Disadvantages of the Suprabulge Clasp. (1) More conducive to caries because of greater tooth coverage; (2) It may be less esthetic in some cases; (3) The "pull" type retention is less effective than the "push" type of bar clasp; (4) Possibilities of variation in design are limited; (5) It increases the circumference of the abutment tooth which in effect adds to the load to be borne by the tooth.

## Types of Suprabulge Clasps

### Simple Circlet (Akers Clasp cast)

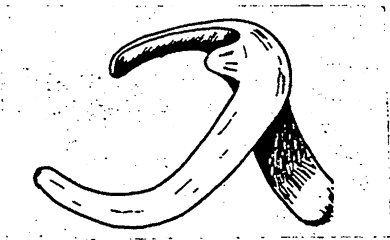


Simple Circlet

Indications: (1) The most versatile of all clasps and the most universally used; (2) When there is a choice between this clasp and another of equal capability the circlet should be the clasp of choice; (3) Should not be used in a mesial undercut on a distal extension partial.

Structural Details: Correct taper is essential. It should taper uniformly from body to tip. The rest must be heavy enough to withstand normal masticatory stress. Common error is to wax the rest thin over the marginal ridge. There should be very little flexibility in the shoulder of the clasp. The shoulder must always be designed on or above the survey line.

### Reverse Approach Circlet



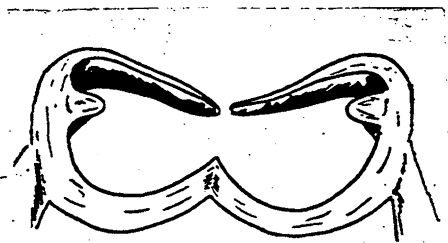
Reverse Approach Circlet

Indications: (1) Used on bicuspid and cuspid when the usable undercut is on the distal surface and there is adequate space on the mesial for the body and connector; (2) Used in cases where a bar type clasp is undesirable or contraindicated, and esthetics is not a prime requirement.

Structural Details: Correct taper is essential. The arms should taper uniformly from the body to tip. The rest must be heavy enough to withstand normal masticatory stress.

There should be very little flexibility in the shoulders. Never design this part of the clasp below the survey line. This clasp can be designed with a distal rest NOT connected directly to the clasp.

### Multiple Circlet



Multiple Circlet

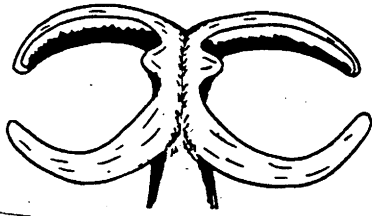
Indications: (1) When it is desirable to reinforce a weak abutment by distributing part of the stress to an adjoining tooth or teeth. It is most frequently used on bicuspid; (2) When the retention provided by the most distal abutment is not considered adequate and the tooth next to the abutment offers a means for increasing it.



Structural Details: Adequate rest seats are essential. The lingual clasp arms are usually united and not tapered. Both minor connectors must connect to a strong rigid major connector.

### Embrasure

Indications: (1) When a clasp must be used in a quadrant of the mouth where there is no edentulous space; (2) When a space too small for a tooth is present between two natural teeth, an embrasure clasp can be used to retain the partial and also fill the space to restore the occlusion.



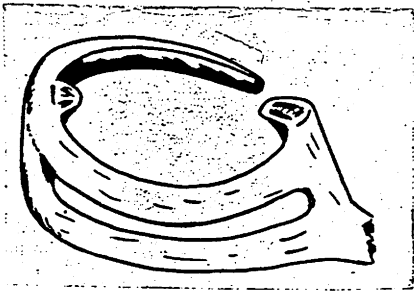
Embrasure

Structural Details: Taper the same as for a simple circlet clasp. Must be thick enough through the embrasure to withstand occlusal stress.

Must adequately clear the opposing occlusion. Avoid over thickening the clasp at the junction of the body and the minor connector. Retain normal clasp contour.

### Ring

Indications: (1) On mandibular molars which are tipped mesially and lingually with the usable undercut on the mesio-lingual surface of the tooth; (2) On maxillary molars which are tipped mesially and buccally with the usable undercut on the mesio-buccal surface; (3) It is contraindicated if there is a distal buccal undercut on a maxillary molar, unless it is very low or very slight; (4) This is a very difficult clasp to adjust if it becomes distorted.



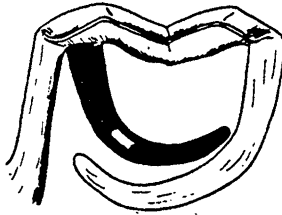
Ring

Structural Details: Tapers from the distal rest to the clasp tip. The extra bracing arm is usually thick throughout with no taper.

The only undercut engaged by the clasp is at the tip.

The bracing arm of the clasp is not tapered and should be thick throughout.

### Onlay

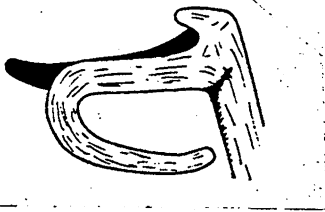


Onlay

Indications: (1) To extend from an onlay, or extended occlusal rest to engage an undercut; (2) The retentive arm may be designed to extend from any point along the buccal or lingual margin of the onlay where the occlusion permits, and it may engage a retentive area in either a mesial or distal direction.

Structural Details: Taper should be the same as for a simple circllet clasp. The clasp arm should form an abrupt angle where it joins the onlay.

### Circllet "C" (Fish Hook)



Circllet "C"

Indications: (1) Where a springy retentive clasp arm is needed and the undercut is under the occlusal rest; (2) Where a tissue undercut precludes the use of a bar type clasp; (3) The crown of the tooth must be longer than average to provide room for the clasp loop; (4) The retentive arm may extend from an onlay or from a conventional occlusal rest; (5) The retentive arm must clear the opposing occlusion.

Structural Details: The retentive arm must taper uniformly throughout its length.

## INFRABULGE CLASPS

Advantages of the Infrabulge Clasp. (1) Less conducive to caries, since there is less tooth contact; (2) More flexible because of its longer length, hence there is less strain on the abutment tooth; (The shorter type "I", "C", and double "I" are exceptions.) (3) Often more esthetic because of its approach; (4) Has a wider range of adaptability than the circllet type clasp; (5) The "push" type retention is said to be more effective than the "pull" type which is characteristic of the circllet clasp. For this reason a partial constructed with bar clasps may be easier to insert and more difficult to remove.

Disadvantages of the Infrabulge Clasp. (1) It provides less bracing than the cast circllet clasp; (2) There is danger of tissue impingement under a bar clasp as a result of faulty technique or settling of the restoration; (3) There is a possibility of food lodging under the approach arm as it crosses a blocked out area; (4) It usually requires more metal to construct and more metal is lost in finishing; (5) The bar clasp is more difficult to repair or replace if broken.

Clasp Construction. The following rules apply in the construction of all bar type clasps:

The approach arm of a bar clasp must never impinge on soft tissue. The area which the approach arm covers need not be relieved on the master cast, but the tissue side of the metal should be rounded, smooth and highly polished.

The minor connector which attaches the occlusal rest to the frame should be strong and rigid to contribute some bracing to the partial.

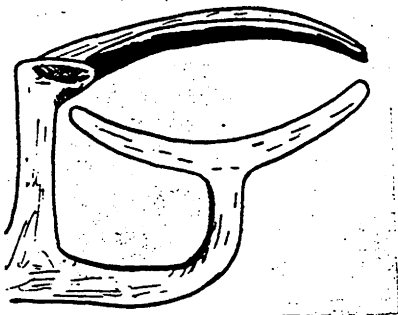
The approach arm must always be tapered uniformly from its attachment at the frame to the clasp tip.

The occlusal rest must be strong to provide positive support. Failure to provide positive support may allow the approach arm to settle and impinge on the soft tissue.

The approach arm must never be designed to bridge over a soft tissue undercut because of the food trap which will result.

#### Types of Infrabulge Clasps

"T"



"T"

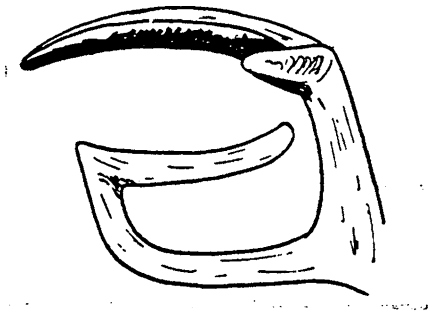
Indications: (1) The most commonly used bar type clasp because of its versatility; (2) Used most often in combination with a circlet type bracing arm; (3) Like most bar type clasps, it provides little bracing; (4) Used most often where the undercut is under the occlusal rest of the abutment tooth; (5) It is often used to stabilize a free end denture base when the retentive area is on the disto-buccal surface of a terminal abutment.

Structural Details: The approach arm should be tapered gradually and uniformly from the major connector.

The cross bar of the "T" must be tapered. The junction of the cross bar and the upright of the "T" should form a definite angle.

The portion of the cross bar away from the rest must cross the survey line onto the suprabulge area so the tooth will be released when pressure is applied to the free end denture base.

### Modified "T"

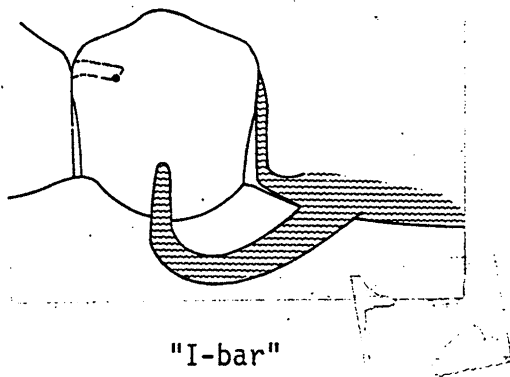


Modified "T"

Indications: (1) Has the same indications as the "T" clasp and is somewhat better esthetically; (2) It is most often used on maxillary first and second bicuspids to provide maximum esthetics; (3) Like many of the bar type clasps, it is contra-indicated on teeth with high survey lines because a space is created under the approach arm.

Structural Details: The approach arm should taper gradually and uniformly from the major connector. The junction of the cross bar and the upright of the "T" should form a right angle and this junction must be across the survey line onto the supra-bulge area of the tooth.

### "I-bar" (Kratovichil and Krol)



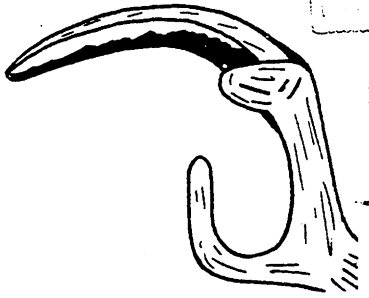
"I-bar"

Indications: (1) Clasp approaches the undercut from a gingival direction and does not cross the survey line once the removable partial denture is in position; (2) Favorable stress distribution to the abutment during functional movement of the denture base; (3) Minimal coverage of tooth and gingiva; (4) Less interruption of natural tooth contours; (5) Somewhat more difficult to adjust and may not have as effective bracing action as other infrabulge clasps.

This clasp should be used as a complete system, not as an individual clasp with another technique.

Structural Details: In this system the rest is on the mesial and not on the distal. The approach arm tapers from its source at the denture base retention to the tip. The distal strut is not in an undercut and contacts the tooth only at the guiding plane in the area of the survey line.

"I"



"I"

Indications: (1) Has limited use: (2) Because of its short length it must be designed with judgement, and care must be taken to provide encirclement of the tooth; (3) For mouths with rampant caries, since it will cover a minimum of enamel; (4) When a stiff clasp is needed and there is only a slight undercut next to the gingivae; (5) In situations where esthetics is a prime consideration.

Structural Details: Should be designed short, stubby and stiff. The approach arm should come directly off a major or a minor connector in the shortest possible distance.

Must be uniformly tapered from connector to tip.

### MAJOR CONNECTORS

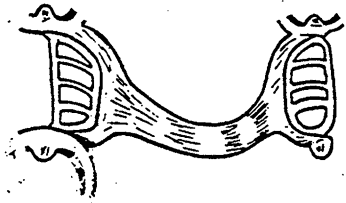
The function of a major connector is:

1. To join the parts of one side of the partial with those of the other side.
2. To distribute stresses to different parts of the partial and to the underlying tissue. (Stabilization or bracing)
3. To function as an indirect retainer in some cases.

### MAXILLARY MAJOR CONNECTORS

#### Special Structural Requirement: Beading

- (1) A maxillary major connector should have a specially prepared seal along the border of the connector. This prepared seal forms a beading at the border which will slightly displace the soft tissues;
- (2) The beading should be scribed to a depth and width of approximately 0.5 to 1 mm. at all border areas. The beading should fade out approximately 6 mm. from the free gingival margin to avoid displacement of this tissue and in areas of thin tissue coverage such as tori or the median suture line.



Palatal Bar

### Palatal Bar

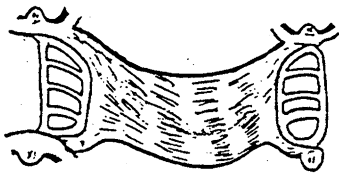
Indications: In unilateral situations where only one or two teeth are missing.

Objectionable Qualities: (1) Usually too flexible; (2) Too bulky if an attempt is made to make it sufficiently rigid; (3) Provides poor support.

Contraindications: (1) Any distal extension partial denture; (2) When anterior teeth are also missing; (3) When patient comfort and rigidity of the connector are important.

Structural Details: (1) Place in the vicinity of the first molar; (2) Bar is narrow and thick with its central portion thicker than the edges, (Half oval); (3) Bar is gently curved with no point in the midline; (4) Bar should not form sharp angle at the junction with the denture base.

### Palatal Strap



Palatal Strap

It is a most versatile maxillary connector and because of the large amount of palatal support that can be utilized with this design, it is considered a very excellent connector.

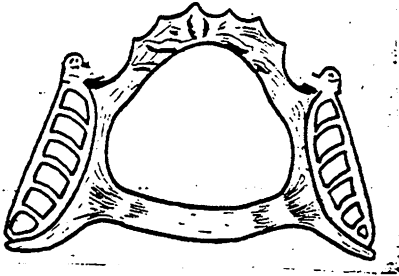
Indications: (1) Can be made fairly narrow for a tooth supported denture where the edentulous spaces are small; (2) Can be made wide when edentulous spaces are longer and when more support from the palate is desirable.

Advantages: (1) Provides excellent support and rigidity; (2) Provides good patient comfort because the connector can be made very thin; (3) Distributes occlusal stresses over a wide area; (4) Enhances retention of the denture through the forces of adhesion and cohesion; (5) Contributes toward indirect retention, since firm palatal tissues may be intimately contacted on several different planes.

Disadvantages: Patient may complain of extensive palatal coverage, however, this is usually less objectionable than a narrow but thicker connector.

Structural Details: (1) Must be made wide (minimum of 8 mm.) and thin; (2) Must be rigid.

Double Palatal Bar (Anteroposterior Palatal Bar)  
and  
Modified Double Palatal Bar



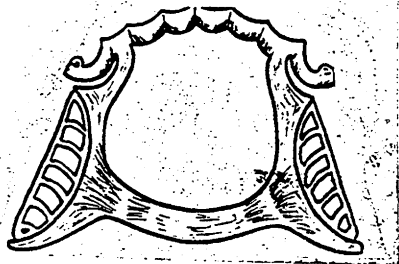
Double Palatal Bar

Indications: (1) Used in designs where support is not a major consideration and the anterior and posterior abutments are widely separated; (2) Occasionally indicated when the patient strongly objects to a large amount of palatal coverage; (3) Where the maxillae present a large torus palatinus; (4) Where some anterior teeth are weak or missing.

Contraindications: (1) In most maxillary designs because of the narrow bars; (2) When a high narrow vault is present as the anterior bar will interfere with proper phonetics.

Advantages: Structurally it is a very rigid major connector.

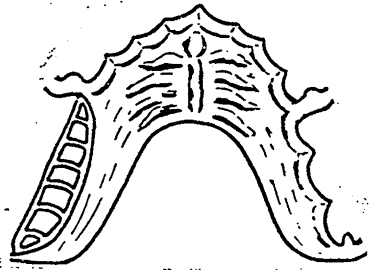
Disadvantages: (1) Provides very little support from the palate; (2) Uncomfortable for the patient, because the bars are narrow and must be bulky for rigidity; (3) Tongue tends to investigate and play with the long border areas of the two bars.



Modified Double Palatal Bar

Structural Details: (1) Borders of the anterior bar are placed in the depressions or valleys between the rugae, never on the rugae crests; (2) Anterior bar is made flat and the posterior bar should have a half oval contour. Bars are joined together by longitudinal elements of the connector on each side. This gives the effect of a circle and is considerably more rigid than either bar would be individually. The two bars lie in different planes, creating a structurally strong "L" beam effect; (3) Both bars should cross the midline at a right angle rather than on a diagonal; (4) Other structural details are the same as for the single palatal bar.

## Horseshoe



Horseshoe

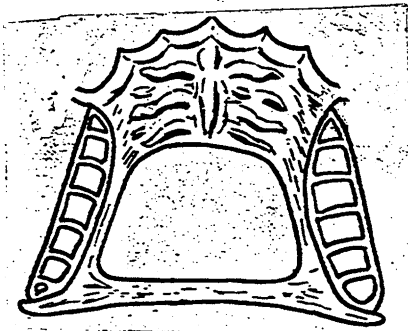
Indications: (1) Where several anterior teeth are to be replaced; (2) Where periodontally weakened teeth require stabilization; (3) Where a hard medial suture line or an inoperable torus is present.

Contraindications: (1) Distal extension removable partial dentures; (2) When the presence of long edentulous spaces or weakened teeth require good cross-arch stabilization.

Disadvantages: (1) Poor connector because it is flexible and movement can occur at the open ends. Provides poor cross-arch stabilization in the posterior areas; (2) Metal must be thick in the rugae area in order to achieve any degree of rigidity. Interferes with phonetics and patient discomfort can result.

Structural Details: (1) Borders must be placed 6 mm. from the free gingival margin or onto the lingual surfaces of the teeth; (2) Connector should have uniform thickness; (3) Borders should be placed in valleys between the rugae; (4) Palatal borders are placed at the junction of the horizontal and vertical surfaces of the palate. Rigidity can be increased by extending onto the horizontal palatal surfaces; (5) Connector should be symmetrical with its palatal borders the same height on both sides.

## Closed Horseshoe



Closed Horseshoe

Indications: (1) May be used in most maxillary partial denture designs and is particularly indicated when a torus palatinus is present.

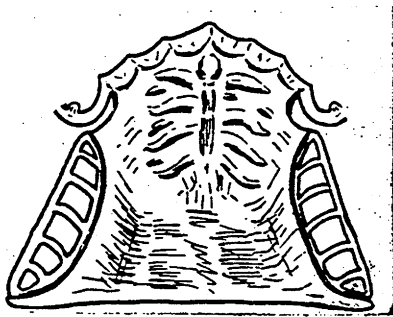
Advantages: (1) Very rigid connector and provides good support from the palate; (2) Corrugations formed by the rugae allow the connector to be made thinner as the corrugated contour adds strength; (3) Shape provides a definite "L" beam effect; i.e. metal lies in two different planes, also increasing rigidity.



Disadvantages: (1) May interfere with phonetics and patient comfort; (2) Has extensive length of borders for the tongue to investigate.

Structural Details: (1) Metal should be of uniform thickness; (2) Borders should end at least 6 mm. from the free gingival margin or extend onto the teeth; (3) Place anterior component as far posteriorly in the rugae area as possible to minimize the interference with phonetics; (4) Place palatal border at the junction of the vertical and horizontal surfaces of the palate.

### Full Palate



Full Palate

Indications: (1) Long span bilateral distal extension removable partial dentures; (2) Bilateral distal extension partial dentures when anterior replacements are also needed; (3) When very heavy occlusion is anticipated; (4) Where flat or flabby ridges or a shallow vault is present; (5) Whenever maximum support from the palate is desired; (6) In cleft palate patients; (7) When acrylic resin is used as a major connector; (8) When the partial denture is considered a transitional prosthesis with complete denture treatment anticipated in the near future; (9) When only anterior teeth are present or when the remaining teeth have extensive loss of periodontal support.

Advantages: (1) Can be made into a uniformly thin metal plate that faithfully reproduces anatomic contours of the palate. Surface irregularities that are present feel natural to the patient; (2) Very rigid major connector; (3) Retention is enhanced because of the large area of intimate contact between the connector and the tissue. (4) Utilizes the maximum amount of support from the palatal tissues.

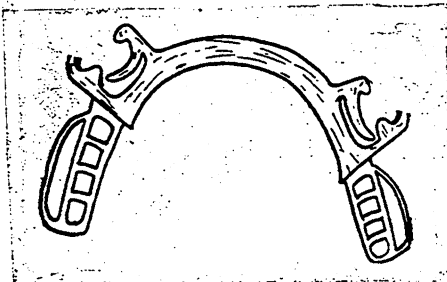
Structural Details: (1) Posterior border should be short of the vibrating line; (2) Anterior border must be 7 mm. away from marginal gingivae or cover the cingula of the anterior teeth; (3) Beading should be employed along the posterior border (A full postdam (posterior palatal) seal such as used for a complete denture should not be used.)

## MANDIBULAR MAJOR CONNECTORS

### Special Structural Requirements:

Beading: Never bead mandibular major connectors

Relief: Adequate relief must be developed under all types of lingual bars: (1) Where lingual soft tissues do not slope toward the floor of the mouth, minimum relief (28 gauge) is necessary; (2) Where lingual tissues do slope toward the floor of the mouth, more than normal relief is required; (3) Less relief is required for an all tooth borne partial denture than for distal extension dentures; (4) Lingual tori should be generously relieved when surgery is contraindicated; (5) Where the lingual soft tissue is undercut, the undercut area should be blocked out, however, additional relief of the undercut area is not necessary.



Lingual Bar

### Lingual Bar

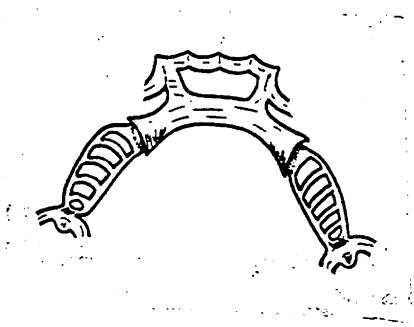
Indications: (1) Used whenever possible unless one of the other types of connectors would have definite advantages; (2) For most Kennedy Class III situations.

Advantages: (1) Covers a minimum of the tissues; (2) Does not contact teeth or tissues; (3) Does not collect food against teeth.

Disadvantages: May be flexible if poorly constructed.

Structural Details: (1) Must be rigid; (2) Should be half pear in cross sectional shape with the thick portion in an inferior position; (3) Should be at least 5 mm. in superior-inferior width; (4) Superior border should be at least 3 mm. below and parallel to an imaginary line passing through the lowest level of the gingival margins of the teeth; (5) Lower border should be as low as the tissues of the floor of the mouth will permit when they are in function.

### Double Lingual Bar (Kennedy Bar)



Double Lingual Bar

Indications: Primarily indicated in those mouths in which indirect retention must be supplemented by the major connector, and in which periodontal disease and its treatment have created large interproximal embrasures between the lower anterior teeth.

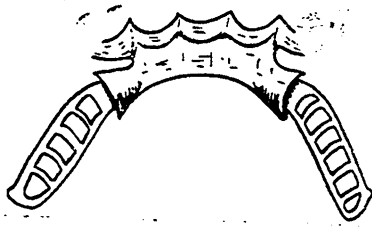
Contraindications: Where the lower anterior teeth show marked crowding.

Advantages: (1) It effectively extends the indirect retention farther anteriorly provided it has adequate occlusal, incisal or lingual rests at each end of the bar; (2) It makes a contribution to the horizontal stability of the prosthesis as it distributes the stress to all of the teeth which it contacts, thereby reducing the stress borne by any individual tooth; (3) It makes a minor contribution to the support of the partial denture; (4) It permits a free flow of saliva through the interproximal embrasures and since the gingival tissues are not covered by the connector, it allows natural stimulation of the marginal gingiva.

Disadvantages: (1) Frequently more objectionable to the patients' tongue than is a contoured lingual plate; (2) Although more rigid than a lingual bar, it is not as rigid a connector as a lingual plate; (3) The open space between the two bars may collect food and produce irritation; (4) Numerous undercuts created by the overlapping anterior teeth make it difficult to fit the bar closely to the lingual surface of each tooth.

Structural Details: (1) Lower border of the upper bar should rest on the top edge of the cingula; (2) Bars should be attached to each other by means of rigid minor connectors at each end of the continuous bar. The minor connectors should be positioned opposite the gingival embrasures so as to be less noticeable to the tongue; (3) Positive rests must be placed at each end of the continuous bar for support. (No farther distal than the mesial of the first premolar.) Omission of these rests could result in settling of the connector and/or orthodontic movement of the anterior teeth; (4) The lower bar should have the same design as a single lingual bar. (Pear-shaped in cross section); (5) If a diastema is present between the anterior teeth, a "step back" design of the upper bar may be necessary so as to avoid producing an unesthetic result.

## Lingual Plate



Lingual Plate

Indications: (1) Where most posterior teeth have been lost and the major connector must be used for indirect retention; (2) Where all remaining teeth have weakened periodontal support. (3) When a high lingual frenum, and/or, a high floor of the mouth, are present; (4) Where lingual tori are present and are inoperable; (5) Where future replacement of anterior teeth is expected; (6) When a patient objects to a lingual bar; (7) To help stabilize weakened anterior teeth; (8) If the patient is prone to heavy calculus formation; (9) To help prevent further eruption of extruded anterior teeth.

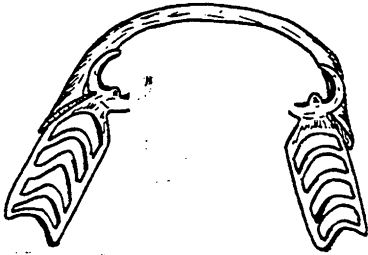
Advantages: (1) More rigid than a lingual bar or double lingual bar; (2) When properly contoured, it will not cause interference with the tongue; (3) Aids in stabilizing periodontally weakened teeth if it is properly designed and constructed.

Disadvantages: (1) Extensive coverage of tooth structure may contribute to caries activity if oral hygiene is inadequate; (2) May contribute to gingival irritation and periodontal disease if not properly relieved and the patient does not practice good oral hygiene.

Structural Requirements: (1) Must be rigid; (2) A pear shaped lingual bar is used on the lower border and positioned as low as possible without interfering with the functional activity of the floor of the mouth; (3) Plating onto the lingual surfaces of the teeth is merely a thin plate extending from an already rigid lingual bar; (4) Adequate blackout and relief is necessary; (5) All lingual soft tissue and tooth undercuts should be surveyed and blocked out; (6) Free gingival margin and sulcus areas must be relieved; (7) Upper border of the lingual plating must intimately contact the lingual surfaces of the teeth above the survey line to avoid food entrapment; (8) Should have scalloped appearance, covering the cingula with projections extending incisally to the contact points. Areas between the sharply pointed projections should be knife edged and placed no higher than the middle third of the teeth; (9) Plating should be made as thin as possible.

### Labial Bar

Indications: (1) Where the lower anterior teeth and premolars are so severely inclined lingually so as to prevent the use of a conventional lingual major connector. Every attempt should be made to recontour the teeth or orthodontically move them to avoid using a labial bar; (2) A swinglock type removable partial denture employs a labial bar in conjunction with a lingual major connector.



Labial Bar

Disadvantages: (1) Esthetics are poor unless the lower lip is relatively immobile. Even then, the bulk of the connector can contribute to a poor esthetic result; (2) Patient discomfort due to the bulk of metal between the gingiva and the lip; (3) The depth of labial vestibule is not usually great enough to allow a connector of sufficient rigidity without approaching the free gingival margin too closely.

Kenneth D. Rudd, D.D.S.  
The University of Texas Health Science  
Center at San Antonio, Dental School  
Offices of the Dean  
7703 Floyd Curl Drive  
San Antonio, Texas 78284

## CONDITIONS WHICH AFFECT THE CHOICE OF CONNECTORS

UPPER	STRESS BEARING TISSUE			TYPE OF BITE			OPPOSING OCCLUSION		TYPE OF RIDGE		TYPE OF BRACING NEEDED		CASE PECULIARITIES	
	FIRM	MED.	SOFT	WEAK	MEDIUM	HEAVY	ARTIFICIAL TEETH	NATURAL TEETH	WELL FORMED	FLAT	AVERAGE	MORE THAN AVERAGE	PALATAL TORUS	LINGUAL TORI
FULL PALATE	⊙	⊙	X	⊙	⊙	X	⊙	X	⊙	X	⊙	X	usually not indicated	
HORSE-SHOE	⊙	X		⊙	X		⊙	X	X		X		X	
CLOSED TYPE HORSE-SHOE	⊙	⊙	X	⊙	⊙	X	⊙	X	⊙	X	⊙	X	X	
DOUBLE PALATAL BAR	⊙	X		⊙	X		X		X		X		X	
SINGLE PALATAL BAR	X			X			X		X		X			
<b>LOWER</b>														
LINGUAL BAR	⊙	X		⊙	X		X		X		X			
DOUBLE LINGUAL BAR	⊙	⊙	X	⊙	⊙	X	⊙	X	⊙	X	⊙	X		
LINGUAL PLATE	⊙	⊙	X	⊙	⊙	X	⊙	X	⊙	X	⊙	X		X

**NOTE:**

IN USING THE CHART THE DESIGNER SHOULD ASK HIMSELF THE QUESTION: "IF THE CASE TO BE DESIGNED HAS THESE CHARACTERISTICS, WHICH CONNECTOR IS INDICATED?" THE X, INDICATES THE TYPE OF CONNECTOR WHICH WILL MOST IDEALLY DO THE JOB REQUIRED. THE CIRCLED X'S (⊙) ARE SECONDARY CHOICES AND ARE ENTIRELY SATISFACTORY.

*Factors which affect the choice of major connectors*

		Full palate	Horseshoe	Closed type horseshoe	Double palatal bar	Single palatal bar	Lingual bar	Double lingual bar	Lingual plate
Stress-bearing tissue.....	Soft	First choice	-----	Second choice	-----	-----	-----	Choice	Choice
	Med.	Acceptable	Usually acceptable	Acceptable	Acceptable	Sometimes acceptable	Acceptable	Acceptable	Acceptable
	Firm	Acceptable	Acceptable	Acceptable	Acceptable	Usually acceptable	Acceptable	Acceptable	Acceptable
Bite.....	Weak	Acceptable	Acceptable	Acceptable	Acceptable	Acceptable	Acceptable	Acceptable	Acceptable
	Med.	Acceptable	Acceptable	Acceptable	Acceptable	-----	Acceptable	Acceptable	Acceptable
	Heavy	First choice	-----	Usually acceptable	-----	-----	-----	Acceptable	Acceptable
Opposing occlusion.....	Artificial teeth	Acceptable	Acceptable	Acceptable	Acceptable	Acceptable	Acceptable	Good	Good
	Natural teeth	First choice	-----	Acceptable	Sometimes acceptable	Often not acceptable	Often not acceptable	Good	Good
Type of ridge.....	Well formed	Acceptable	Acceptable	Acceptable	Acceptable	Acceptable	Acceptable	Acceptable	Acceptable
	Poorly formed	First choice	-----	Second choice	-----	-----	-----	Good	Good
Type of bracing needed.....	Average	Acceptable	Acceptable	Acceptable	Acceptable	Acceptable	Acceptable	Acceptable	Acceptable
	More than average	First choice	-----	Second choice	Sometimes acceptable	-----	-----	Second choice	First choice
Case peculiarities: Palatal torus.....		Usually not indicated	Acceptable	Acceptable	Acceptable	Usually not indicated	-----	-----	-----
Lingual tori.....		-----	-----	-----	-----	-----	Sometimes acceptable	Second choice	First choice

## Removable Partial Dentures

1. Removable partial dentures may be made with
  - A. extracoronal attachments.
  - B. intracoronal attachments.
  - C. stress breakers (stress equalizers).
  - D. frictional wall precision attachments.
    1. A & C
    2. C & D
    3. B & A
    4. A, B & C

\* → 5. all of the above
2. Factors that influence the flexibility of a clasp are:
  - A. Shape
  - B. Taper
  - C. Kind of metal
  - D. Amount of undercut
    1. A & B
    2. B & C
    3. C & D

\* 4. A, B & C

5. A, B & D
3. All of the dentists listed below were contemporaries of Applegate except,
  - A. Henderson.
  - B. Steffel.
  - C. Beck.
  - D. Hindels.

\* E. Akers.
4. Denture teeth with a flange on the a removable partial denture may be indicated in the incisor region of the arch when there is a
  - A. slight amount of ridge loss.
  - B. great amount of ridge loss.
  - C. no ridge or bone loss.
    1. A only
    2. B only
    3. C only
    4. A & B
    5. A & C

\* 2. B only

5. Which of the following is an intracoronal attachment?
- A. Ceka (rigid)
  - B. Gerber 686C
  - \* C. Sterns G/L
  - D. Dalbo 604
  - E. Rothermann 746
6. Which of the following is a resilient attachment?
- A. Stern's No. 7
  - B. Ney No.9
  - \* C. Crismani 689
  - D. Stern G/L
  - E. Baker premolar
7. Which of the following is not a semi - adjustable articulator?
- \* A. Hagman Balancer
  - B. Hanau H2
  - C. Whip Mix
  - D. Dentatus
  - E. Kinescope
8. Which of the following clasps are known as suprabuldge clasps.
- A. Roach, T, I-Bar
  - B. Akers, ring
  - C. Circumferential, simple circlet
  - 1. A only
  - 2. B only
  - \* 3. B & C
  - 4. A & C
  - 5. all of the above
9. An alginate impression is more noticeably distorted by
- A. hydration.
  - \* B. dehydration.
  - C. pressure.
  - D. release of strains.
  - E. all of the above.
10. Dental wax may contain any of the ingredients listed below except
- A. paraffin
  - B. gum dammar
  - \* C. gum tragacanth
  - D. candelilla
  - E. ceresin



11. In determining the type of maxillary major connector to use, one must consider
- A. the location of other components.
  - B. the number and location of missing teeth.
  - C. the palatal anatomy.
  - D. the amount of support available from the remaining teeth.
  - E. the type of mandibular major connector which will be used.
    - 1. A, B & E
    - 2. B, C & D
    - 3. A & E
    - \* 4. A, B, C & D
    - 5. B, C, D & E
12. Containdications for use of a bar-type clasp include:
- A. A deep cervical undercut (high survey line).
  - B. A severe soft tissue undercut 1 mm from gingival margin.
  - C. Only disto-buccal undercuts on the two terminal abutments when working with a Kennedy Class I R.P.D.
  - D. Only mesio-buccal undercuts on the terminal abutments when working with a Kennedy Class I R.P.D.
    - 1. A & B.
    - 2. C & D
    - \* 3. A, B & D
    - 4. B, C & D
    - 5. A, B & C
13. Possible limitations to the use of internal attachments for removable partial dentures would include:
- A. Large pulpals in abutment teeth.
  - B. Short clinical crown on abutment teeth
  - C. Additional cost to the patient.
  - D. Poor esthetic possibilities.
  - E. Lack of stability
    - 1. A, B & E
    - 2. C, D, & E
    - 3. A & B
    - 4. C & D
    - \* 5. A, B & C
14. Dangers in the corrected cast procedure for removable partial dentures include:
- A. Movement of framework during the pouring of the cast.
  - B. Overextension of the denture base area.
  - C. Improper placement of the framework during impression making.
  - D. Framework not reseated on the cast accurately after impression is made.
  - E. Less accurate impression of the denture base area.
    - 1. C, D, & E
    - 2. A, B, C, D & E
    - 3. A, C, D & E
    - \* 4. A, B, C & D
    - 5. B, D & E

15. Which method will most likely produce the most accurate cast when dental stone is poured into a hydrocolloid impression?
- A. Double pour - impression boxed
  - B. Single pour - impression boxed
  - \* C. Double pour - without boxing
  - D. Single pour - without boxing
  - E. Single pour - after soaking impression in 2% potassium sulfate.

# **Review Of RPD Clinical Trials**

**Dr. Krishan K. Kapur**



Review of Clinical Trials (Krishan K. Kapur, D.M.D., M.S.)

Suggested References:

Carlsson GE, Hedegard B, Koivumma KK. Studies in partial dental prosthesis II. An investigation of mandibular partial dentures with double extension saddles. Acta Odontol Scand. 1961;19:215-37.

Carlsson GE, Hedegard B, Koivumma KK. Studies in partial dental prosthesis III. A longitudinal study of mandibular partial dentures with double extension saddles. Acta Odontol Scand. 1962;20:95-119.

Carlsson GE, Hedegard B, Koivumma KK. Studies in partial dental prosthesis. Acta Odontol Scand. 1965;23:443-472.

Bergman B, Hugoson A, Olsson C-O. Caries and periodontal status in patients fitted with removable partial dentures. J Clin Periodont. 1977;4:134-46.

Derry A, Bertram U. A clinical survey of removable partial dentures after two years usage. Acta Odontol Scand. 1970;28:581-98.

Schwalm CA, Smith DE, Ercickson JD. A clinical study of patients 1 to 2 years after placement of removable partial dentures. J Prosthet Dent. 1977;38:380-91.

Benson D, Spolsky VW. A clinical evaluation of removable partial dentures with I-bar retainers. Part I. J Prosthet Dent. 1979;41:246-54.

Wetherell JD, Smales RJ. Partial denture failures: A long-term clinical survey. J Dent. 1980;8:333-40

Kratochvil JE, Davidson PN, Guijt J. Five-year survey of treatment with removable partial dentures Part I. J Prosthet Dent. 1982;48:237-44.

Bergman B, Hogoson A, Olsson C-O. Caries, periodontal and prosthetic findings in patients with removable partial dentures: A ten-year longitudinal study. J Prosthet Dent. 1982;48:506-14.

Chandler JA, Brudvick JS. Clinical evaluation of patients eight to nine years after placement of removable dentures. J Prosthet Dent. 1984;51:736-43.

## **Section Six - Implants**

Section Six contains information related to implants and prosthetic therapy. The use of implants in oral rehabilitations, the biological response of the tissues in contact with the devices, biomechanics, a review of the different implant systems available to the clinician, and treatment considerations are among the topics reviewed. The role of the precision of fit of the implant components, and the occlusal forces are reported as significant contributors to success or failure. Implant therapy has been used in single tooth replacements, restoration of the partially edentulous condition or management of the totally edentulous ridge. The authors and the titles of their presentations related to implant therapy follow:

**Dr. Alan B. Carr**

“Prosthetic Management Using Dental Implants”

**Dr. Hans-Peter Weber**

“Dental Implants And Their Biological Interfaces”

**Dr. Merle J. Jaarda**

“Biomechanics And Implant Design”

**Dr. Charles E. English**

“A Review Of Implant Systems”

**Dr. Steven Lewis**

“Dental Implant Therapy”

**Dr. Robert J. Cronin Jr**

“Treatment Considerations For The Implant Assisted Restoration Of The Partially Edentulous Patient

**Dr. Michael E. Razzoog**

“Designing Fixed Partial Denture Reconstruction And Implant Rehabilitation Using CAD/CAM”

**Dr. Stephen J. Riedy**

“Accuracy And Precision In Dental Implants”

**Dr. Brien R. Lang**

“Implant Complications”

**Dr. Brien R. Lang**

“Occlusal Rehabilitation Of The Edentulous Patient With  
Or Without Implants”





# **Prosthetic Management Using Dental Implants**

**Dr. Alan B. Carr**



# Prosthodontic use of dental implants

## Recommendations for use based on an evaluation of the strength of evidence

### I. *While implants can be used for many conditions, when should they be used?*

Implants are currently used for all varieties of edentulous conditions [single teeth, limited spans, and edentulous arches] which also have conventional prosthodontic treatment options. The fact that something new, such as dental implants, can be used is not sufficient justification that it should be used unless additional evidence reveals measurable benefits compared to other treatments. Deciding on the best treatment option for a given oral condition of tooth loss can be helped by evaluating reports of treatment outcomes of all various treatment options. The current status of the dental literature may not provide clear evidence for decision-making *between* prosthodontic options, consequently the clinician should understand the strength of research regarding implant outcomes to enable the best informed decisions for their use .

*The objectives of this presentation are to describe outcomes considered important for making clinical decisions in dentistry, to describe a process of determining the strength of clinical research reports based on an understanding of important limitations to common study designs, and to review the literature pertaining to use of dental implants to gain insight into the strength of the evidence that influences our clinical decisions.*

### II. *What outcomes are important in dentistry?*

Typical criteria for prosthodontic success stress prosthesis characteristics of support, stability, and retention provided in a manner that is esthetically pleasing, functional and comfortable to the patient while also preserving the status of the oral condition. Though valuable outcomes, clinical measures used to monitor them have not consistently been shown to be valid or reproducible, and the scope of the outcomes may have limitations. An understanding of important outcomes for dentistry and prosthodontics can be found in a recent publication by Bader and Shugars,<sup>1</sup> in which they initially describe general medical outcomes organized into dimensions (or groups of measures) to include: survival & life expectancy, symptom states, physiological states, physical functional states, emotional & cognitive states, perceptions about present & future health, and satisfaction with health care.

Within the above dimensions, various outcomes are possible, and several aspects of an outcome can be measured. Using this as a framework for development, Bader and Shugars introduced a classification of treatment outcomes for dentistry which included:

Physical/Physiological dimension	Economic dimension
presence of pathology	direct costs
presence of pain	indirect costs
assessment of function	
Psychological dimension	Longevity/Survival dimension
perceived esthetics	pulp death
perceived level of oral health	tooth loss
satisfaction with oral health status	treatment-related morbidity/mortality
self-concept & interpersonal relations	time until re-treatment for same condition
	time until treatment for new condition

For every treatment (or choice of no treatment) there are a variety of outcomes, each of which should be considered from several perspectives important to one or more of the participants. It has been common in dentistry to focus on the Physical/Physiological and Longevity/Survival dimensions which may have been more appropriate during a time when patients considered the provider's opinion regarding the best treatment to be unquestionable. There is sufficient evidence today to suggest a lack of concordance of opinion concerning treatment needs and satisfactory treatment between patients and providers<sup>2</sup> to emphasize the need to know more about the patient-based outcomes, Psychological and Economic dimensions. Each of the outcomes mentioned above can have more than one measure, and, as stated above, each outcome may have to be assessed in consideration of the appropriateness of care.

***How can the various outcomes mentioned be used?***

How we use the information on treatment outcomes is also variable. Since the ultimate purpose of applied health research is to improve health care, the clinician desiring to use the best available information will apply it to patient care decisions. More formal published statements regarding use of such outcome information mention that application can be to promote or discourage a new intervention, to help with cost-related and policy-oriented analysis, to enable development of decision analyses (modeling a treatment decision analysis), and formulation of practice guidelines. *The intent of this report is to emphasize outcome evaluation and use for patient care decisions.*

In a summary of the current status of dental outcomes relative to the condition of tooth loss, it has recently been reported that few evaluations of the comparative effectiveness of alternative treatments (fixed and removable partial dentures, and implants) were noted, and comparisons of outcomes of replacement teeth made against no such replacement have not been reported at all in the literature.<sup>1</sup> The author goes on to say that the typical study designs used in dentistry most often are efficacy type studies (dental specialists in institutions) which may lack generalizability or application to the typical dentist in the typical setting. Also, the validity of studies that are most often retrospective analyses or long-term prospective case studies may be weakened due to problems related to; baseline comparability of patients and conditions, standardization of measures between studies, and investigator bias. These are very important points to consider when evaluating the dental implant literature and will be addressed below.

*If the limitations to our literature are as described, how should clinicians proceed in applying the reports from the literature to their patient care efforts?*

III. ***Why is strength of evidence an important consideration?***

When making judgements from clinical reports or investigations, it is important to realize that information from such sources may have strengths and/or weaknesses when you apply the findings to your patients. When drawing conclusions from the report (data) and applying the findings to the larger population of similar patients, which includes yours under consideration, the value of the results to your patient is dependent on the strength of the evidence. This strength of the evidence is dependent on the validity of the report procedures, the significance (statistical & clinical) of the findings, and the extent to which the patients in the report are representative of your patient(s).

For many clinical questions a great deal of evidence is available from a variety of studies. Due to this study variability, it is important to consider a *hierarchy of evidence*. Given that the studies are appropriately carried out within the limitations inherent in their design, the usefulness of the information can be ranked according to the following<sup>3</sup>:

1. Randomized control trials
2. Cohort and case-control studies
3. Other comparative studies
4. Case series, descriptive studies, clinical experience, etc.

Evidence from RCT should be given the greatest weight because of the unique advantages of these studies in overcoming the problems of bias and confounding. The next two levels have increasing amounts of bias and confounding when compared to the RCT, but are comparative in nature. Cohort studies should reveal less observation bias, give clearer evidence of time relationships of association, and have a comparison group whose results are more easily determined. The last level of evidence is largely anecdotal and provides a significantly limited foundation to support clinical decision-making.

The systematic use of a modification of the above ranking scheme has been employed for important clinical medicine conditions. For certain medical interventions, guidelines have been proposed to assess the value of clinical research. This value, or strength of evidence, is typically determined by reviewing overviews, which are highly structured literature reviews, of specific clinical conditions or questions. Cook et al<sup>4</sup>, graded overview reports from level I (strongest evidence) to level V (weakest evidence) based on the following design features;

- Level I - Randomized Control Trial with low alpha and beta errors
- Level II - Randomized Control Trial with high alpha and beta error
- Level III- Nonrandomized concurrent cohort studies
- Level IV- Nonrandomized historical cohort studies
- Level V - Case series

Recommendations for treatment are based on the collective strength inherent in the studies reviewed in the overview and are classified as; Grade A recommendation supported by level I evidence, Grade B recommendation by Level II evidence, and Grade C recommendation by Levels II, IV or V evidence. It is important to note that no difference was assigned for evidence from cohort or case series types of studies which collectively received the lowest grade of recommendation (see Addendum 1).

The above format for assessing the value of clinical research underwent modification, and later Guyatt et al<sup>5</sup> formulated recommendations based on the strength and heterogeneity of primary studies in the overview, the magnitude and precision of the treatment effect, and the benefit/risk considerations. The grades of recommendations are for a specified level of baseline medical risk and are summarized in Addendum 2. As with Cook et al, it is obvious that greater emphasis is placed on the more rigorous study designs and the lowest level of recommendation is assigned to the observational studies. Because the potential for bias is much greater in cohort and case-control studies (observational studies) than in RCTs, recommendations from overviews combining observational studies will be much weaker. This is because such studies have been shown to overestimate efficacy. Even expert consensus approaches

to treatment recommendations, when based on uncontrolled clinical experience, risk precipitating widespread application of treatments that may be no more beneficial to our patients than other treatments. The reasons for this are numerous, but some insight into issues related to clinical research design methods helps our understanding of these limitations, and has direct application to our use of results from dental implant research in our patients.

Before moving to a discussion of other study designs, it is also important to realize that some controversy exists regarding the actual benefit of RCT findings to the clinical practice setting. While it has been shown that RCTs in dentistry (periodontics) are not necessarily without important biases,<sup>6</sup> the controversy exists over an efficacy (ideal treatment conditions - RCT) versus effectiveness (typical practice conditions) issue.<sup>7</sup> This may be quite important in dentistry where it has been shown that practice variation is great (arguing for effectiveness data more applicable to less structured delivery of care). However, from a specialist standpoint, (comparative) efficacy information could be quite useful for demonstrating advantages for certain treatments in the more controlled environment of a specialty practice (though this has not been validated), especially when high initial treatment costs greatly impact decisions. Since RCTs are not common in prosthodontics, it is best to emphasize the limitations with the less rigorous study designs to assure that the clinician understands if the evidence is strong or weak for supporting clinical decisions regarding treatment selection.

#### IV. *Study designs in dentistry - Case reports*

Developing expertise in evaluating the literature is necessary to enable today's practitioner to provide the best treatment for his/her patients. It compliments another form of outcome information, the careful and objective evaluation of our patients' conditions and response(s) to everyday treatments, which over the course of a career are the data processed by the clinician to develop what is commonly described as clinical experience or intuition. Much of the literature in both medicine and dentistry is devoted to such case study, whether narrative descriptions of a single or a handful of cases (case reports), quantitative analysis of larger groups of patients (case series), or comparisons of groups of cases with non-cases (case control studies). These observational types of studies, as well as the individual clinician experience gained from everyday treatment decisions (without control treatments) must be understood for their strengths and weaknesses.

##### *Case Series (Clinical Series)*

A case series (also called clinical series) is a study of a group (usually 10 or more) of patients with a similar condition or disease. The larger number of cases, compared to a case report, allows statistical summaries to be determined which is a common way of delineating the clinical picture of a condition/disease and its treatment feasibility or safety, in a specified manner. The intent is not to compare treatments, but to follow the clinical course of a specific condition or treatment. Because it is not comparative in nature, to base treatment decisions solely on this type of study may be inappropriate, as feasibility and safety of a specific treatment are separate outcomes from comparative treatment outcomes which might provide justification for one treatment over another based on the evidence of the comparisons. From the standpoint of providing support for treatment selections, such case series studies suffer from significant limitations because of an absence of controls (they are not comparative), they are typically conducted under ideal conditions, and, as is the case for most implant

reports, they are conducted on a self-selected population of patients (see Addendum 3).

### ***Controls and Comparison Groups***

Often new treatments are applied to patients and compared with the clinicians knowledge of other patient responses to alternative treatments, or data from previous studies of other treatments for the same condition (see Addendum 4). The use of historical controls, either implied or not, are thought to potentially influence the findings by some and was the focus of a paper by Sacks<sup>8</sup>. They investigated the use of historical control trials (HCT) and randomized control trials (RCT) when both had been used for the same treatments, to determine if the results differed based on the control group. Interestingly, when using the HCT, 79% of the studies found the new treatment effective while only 20% of the RCT of the same treatments agreed. Because use of HCT is easier than setting up a randomized study, they have been used frequently to "screen" for effective new treatments. The Sacks study revealed that HCT rarely conclude that a therapy is ineffective when it is in fact effective (good sensitivity), however they frequently conclude that a therapy is effective when it is ineffective (poor specificity). Such a research design characteristic promotes overtreatment (defined here as use of an alternate treatment that is more costly, creates greater treatment burden, and has no more tangible patient benefit than conventional treatments). For treatments where the costs and burdens of the treatment are significant compared to conventional treatments, caution should be exercised in proceeding with the new treatment until clear evidence reveals a measurable and tangible patient benefit over conventional treatments.

### ***Efficacy vs Effectiveness***

For dental research, an over-riding consideration for understanding study results is the extent to which dental implant research outcomes are based on assessments of effectiveness as opposed to efficacy. This can be answered by determining if the treatments were rendered in a common environment, by the usual providers, to the typical patients, and under the typical circumstances. This does not characterize most dental research which is usually conducted in institutions by faculty (usually specialists) and consequently cannot be considered germane to the populations (patients and providers) at large. This type of research is considered reflective of treatment under ideal circumstances (i.e., efficacy).

Also important to consider is whether the outcomes can be applied with any expectations of validity given study designs typical for dentistry. Some important points related to this include the fact that *comparative assessments of the outcomes of alternate treatments are infrequent*, as most studies are single treatments conducted either retrospective in nature or long-term prospective case studies, both often without control groups. For such study designs, validity related to *baseline comparability of patients and conditions (see Sacks and Chalmers), standardization of outcome measures, and investigator bias(es)* are important to assess when determining the application of research findings to patient treatment decisions.

### ***Patient Assignment to Groups***

When research trials have controls, there are important influences on the study results dependent on how the patients were assigned to the treatment or control groups (see Addendum 5). The design principle at issue here is the comparability issue: groups of patients used for comparing treatments (care) should be comparable so that the results are not dependent on patient factors (prognostic variables) but on treatment differences. Chalmers<sup>9</sup> reports that there are many possible reasons for differences in

outcomes between studies in which the controls are assigned at random and those in which they are selected by some other process (such as historical controls, nonblinded assignment, etc). He studied the effect of random/blinded (RB), random/nonblinded (RNB), and nonrandom (NR) assignment of patients in studies investigating treatment of acute MI. He determined that important prognostic variables were maldistributed between groups in all the studies, but to a varying degree based on randomness and blindness [14% RB, 26.7% RNB, and 58.1% NR]. The variable maldistribution would be suspected to alter the results which in fact demonstrated a significant relationship between aberrant distributions of prognostic variables based on patient assignment and blindness. The data suggest that treatments were judged to be effective more frequently in the studies where assignment of controls was either not blinded or less blinded, and this finding is solely due to bias in the selection or rejection of patients when the treatment to be given is known or suspected at the time of assignment. The authors state that in such research designs, bias in the assignment could be a more important determinant of outcome than the treatment under investigation.

### ***Potential for bias even with RCTs***

Even with seemingly appropriate designs, careful evaluation of the study can reveal important problems as illustrated by a recent meta-analysis of surgical versus non-surgical methods of periodontal disease treatment.<sup>1</sup> In this report of a structured analysis of selected articles meeting the criteria of RCT of surgical and non-surgical treatment comparisons, the authors stated that the results were limited by the low quality scores of the evaluated studies, the potential for bias due to a lack of blindness (difficult in dentistry), a small mean treatment difference, and the measurement variability.

*Given the above typical examples of dental research design, what important questions can we use to screen the literature for the best evidence regarding implant use?*



#### IV. ***Suggested Critical Appraisal Format For Implant Literature***

A sound foundation for evaluating the dental literature relative to implant use can be established by critical appraisal of specific reports regarding basic research design features. A *suggested* format for use is summarized below and addresses the concerns regarding: use of controls or comparison groups, baseline comparability of patients, standardization of a variety of measures, and investigator bias in measurement.

1. Was there a comparison or control group?
  - a. No - limited strength/weaknesses of case series
  - b. Yes- If a historical control, strong bias for false (+)<sup>5</sup>  
If concurrent control, how comparable are groups? (#2)
2. Patient assignment by:
  - a. Random process - comparable groups (#3)
  - b. Nonrandom process- bias due to confounding maldistributions<sup>6,10</sup>
3. Were multiple outcomes measured blindly and in a standardized manner?
  - a. No multiple outcomes - (limited in broad tangible benefit)  
No blindness - (see Addendum 6)
  - b. No standardization - (does not allow consolidation of studies)
  - c. Yes - when combined with strengths from above questions, the study has the best chance for unbiased results which may influence treatment selection decisions.

Using the above format as a guide, a critical appraisal of relevant literature for conditions of complete edentulism, partial edentulism, and single tooth loss all of which have been managed using implants will reveal the level of evidence driving the treatment decisions for implants.

**Search strategy:** to ensure that the most useful research is obtained, a search strategy that combines the important aspect(s) of the question of interest (type of treatment, diagnostic category, risk factor, etc.) with important research design features (methodology) enables discovery of better evidence.

MESH terms: *Dental implants, dental implantation-endosseous, dental prostheses-implant supported*

- 1) Combined with *RCT* provided no references in Medline for databases 1983 - current.
- 2) Combined with *Cohort studies* yielded 2 references.
- 3) A broad search under headings of *dental implants* plus *edentulous, partially edentulous, and single missing teeth*, yielded a list which served as a starting point (a list which actually included articles with MESH terms *RCT* and *Cohort*).

A hand search of bibliographies and reference lists completed the list. Because of the manner with which the list was assembled, it should not be regarded as an exhaustive list of the available literature. It should, however, serve the purpose of representing the state of the evidence for implant use in the varying conditions.

## Completely Edentulous

### **Osseointegrated implants in the treatment of the edentulous jaw. Experience from a 10-year period. Branemark P-I, et al; Scand J Plast Reconstr Surg 1977;11:(supplement 1).**

The purpose of this report was to provide results obtained during 10 years of clinical reconstruction work using the osseointegration technique of implantation in the treatment of the edentulous jaw. This extensive report presents follow-up data on continuous bridge stability taking into account implant performance (anchorage function) and soft tissue health (barrier function). The total number of patients is difficult to determine, however, continuous bridge stability was achieved in 86% of the patients. Within this 86% category, 66% required only the initial surgery, 14% required an additional surgery, and 6% required numerous surgeries to achieve this level of success. The bridges that were in function for 3 years showed 85% continuous stability in the maxilla and 96% for the mandible. There were no significant differences due to gender for comparable age groups. Results of an external examination of the clinical material by an independent Board of Health and Welfare is provided and concludes that the osseointegration procedures can and should be used as a complement to conventional prosthetics. Additional discussion of related reports pertaining to psychiatric and functional outcomes were presented in the discussion.

*An excellent example of a prospective study of a consecutive series of patients managed with a novel procedure for a similar condition- a clinical series (see above discussion, page 4).*

*An excellent method to establish safety and efficacy, and this is an example of an efficacy study (as opposed to an effectiveness study).*

*Although Albrektsson et al (J Period 1988;59:287, see below) referred to this as a controlled trial, the term controlled trial refers to a trial where a control group was part of the study and this report does not provide evidence of such use of a control group (see Addendum 5). The term was most likely used to emphasize the adherence to protocol for both the treatment and the follow-up which in prior dental implant reports was considered suspect.*

### **A 15-year study of osseointegrated implants in the treatment of the edentulous jaw.**

#### **Adell R, et al; Int J Oral Surg 1981;10:387.**

The purpose of this paper was to summarize 15 years of clinical use of osseointegrated implants in the treatment of the edentulous jaw. In 371 patients (average age 53), 2768 implants were placed in 191 maxillary and 219 mandibular jaws. Of the original 410 jaws, 405 were restored with prostheses as the other 5 were lost to death or psychiatric reasons. Patients were closely monitored every 3 months for the first year, then at least annually; radiographs were obtained 1 week post abutment connection and at 6 and 12 months; "periodontal" parameters were monitored; and adverse biological and mechanical reactions were recorded. The results are presented by categories of procedure evolution and the initial developmental group data are not discussed at length. Implant "anchorage function" is provided as the ratio of implants supporting a prosthesis to implants placed, and was from 81-88% for maxillary and 91-97% for mandibular implants. Bridge stability was 89-96% for maxillary and 100% for mandibular prostheses. Numerous conclusions are provided, not all relate directly to the data presented.

*No controls or comparison as presented, efficacy study.*

**Osseointegration and its experimental background. Branemark P-I; Jour Prosthet Dent 1983; 50:399.**

The purpose of this article is to provide a description of the various investigations that have led up to the clinical application of osseointegration. Presents the conceptual development, experimental investigation, and clinical application (intraoral and extraoral) of osseointegration.

*A descriptive report of the research and development of a procedure.*

**Psychological reactions to edentulousness and treatment with jawbone-anchored bridges. Blomberg S, Lindquist LW; Acta Psychiatr Scand 1983; 68:251.**

The purpose of this study was to follow two groups of edentulous patients who were either treated with conventional prostheses or implant-supported mandibular prostheses and determine any psychiatric response differences. A total of 26 patients were randomly selected from a group of referred patients (professional referrals or self-referrals responding to a media release regarding a new dental procedure called osseointegration), and following examination and psychiatric evaluation had either new dentures fabricated or their existing dentures optimized. After 2 months the psychiatric evaluations were repeated, the treatment group had implants placed and psychiatric evaluations were repeated after 3 months and 2 years. The two groups were different in psychiatric characteristics possibly related to the outcomes; the control group reported more occupational problems due to dentures and twice as many were under treatment for nervous disorders. Patient responses about fit, adaptation, and social confidence improved significantly with implant treatment.

*Though a control group was assembled data collection for the control group was not as complete as for the treatment group (see Addendum 3 regarding Hawthorne effect), nonrandom patient assignment no statement made about psychometric instrument validity or reliability (see Addendum 7)*

**The longitudinal clinical efficacy of osseointegrated dental implants: A 3-year report. Cox JF, Zarb GA; Int J Oral Maxillofac Implants 1987; 2:91.**

The purpose of this prospective study was to attempt to replicate the clinical results of the Swedish dental team in the application of dental implants for the treatment of mandibular edentulousness. A total of 26 patients (5 men and 21 women) of the average age 52 who had been edentulous for at least 5 years were included in this report. The patient sample were those individuals who had experienced significant difficulties with conventional complete mandibular dentures. Typical "periodontal" parameters were monitored, as well as implant and prosthesis survival. Of the original 151 implants placed, 18 did not osseointegrate (87.5% success). This implant loss impacted only 1 patient's ability to continuously wear the mandibular prosthesis. These results are comparable to the earlier Swedish results, and replication of the clinical course with this new treatment is an endorsement of its clinical usefulness.

*No control, efficacy study (stated purpose was replication).*

**Osseointegrated oral implants: A Swedish multicenter study of 8139 consecutively inserted Nobelpharma implants. Albrektsson T, et al; J Periodontol 1988; 59:287.**

The purpose of this retrospective, multicenter study was to give a complete follow-up of all consecutively inserted implants by all Swedish teams outside the University of Gothenburg with an experience of at least three years. Five-, three-, and one-year follow-up data are given (to assure inclusion of all failures) from an original sample of 8139 implants which included 4907 mandibular implants in 918 patients, and 3089 maxillary implants in 723 patients [additional implants were placed

in grafted and irradiated jaws]. The prostheses were mainly fixed bridges with some overdentures. Success rates for implants at each time interval (1, 3, 5 years) reveal implant success for the mandible to be over 98% and the maxilla to be over 84%. The results replicate earlier results of Adell et al, and respond to criticism of previous data analysis which suggested more stringent analysis by *life-table* methods (considers cumulative probabilities of survival) be accomplished. No prosthesis results provided.

*Multicenter study (see Addendum 8), retrospective with no controls, limited outcomes measured.*

**A long-term follow-up study of osseointegrated implants in the treatment of totally edentulous jaws. Adell R et al; Int J Oral Maxillofac Implants 1990; 5:347.**

The purpose of this report is to present the outcomes of prostheses and implants in 759 totally edentulous jaws in 700 patients. A total of 4636 implants were placed and followed for a maximum of 24 years by the original team at Göteborg. Life table analysis revealed >95% of the maxillae had continuous prosthesis stability at 5 and 10 years, and at least 92% at 15 years. The mandible exhibited 99% prosthesis stability at all time intervals. Individual implant survival rates were; maxillary 78-92%, and mandibular 86-99%, ranges expressed for the various time intervals followed. The authors conclude that given the magnitude of the clinical material, the length of follow-up, and the positive outcomes relative to survival and other parameters (measured elsewhere), routine treatment of edentulism using the osseointegration method appears to be a highly efficient method of treatment.

*No controls, efficacy study, main outcomes are implant and prosthesis survival (other outcomes reported elsewhere).*

**Oral function in patients wearing fixed prosthesis on osseointegrated implants in the maxilla: 3-year follow-up study. Lundqvist S, Haraldson T; Scand Jour Dent Res 1992; 100:279.**

Seventeen consecutive patients provided with fixed prostheses on maxillary implants were evaluated over a 3-year period. Subjective and objective (occlusal functional measures) evaluation was made before, immediately after, 3-6 months after, and 3 years after treatment. Chewing force increased with time, clinical dysfunction index did not change during the observation period, and all patients expressed subjective improvement in jaw function.

*No control group (neither satisfied nor dissatisfied maxillary complete denture patients), efficacy study.*

**A 3-year clinical study of Astra dental implants in the treatment of edentulous mandibles. Aridson K et al; Int J Oral Maxillofac Implants 1992; 7:321.**

A prospective study of 54 edentulous patients treated with 310 Astra implants placed in the mandible and monitored for 3 years. Prosthesis stability was 100% and implant survival was 98.1% (7 failures). No significant adverse reactions were reported.

*No controls, limited outcomes measured.*

**A multicenter study of overdentures supported by Branemark implants. Johns RB et al; Int J Oral Maxillofac Implants 1992; 7:513.**

The purpose of this nine center prospective study was to follow 133 patients treated with overdentures and determine the feasibility and success rate. For 117 maxillary and 393 mandibular implants, these preliminary results indicate a success rate in the mandible comparable to the fixed implant prosthesis. Maxillary overdenture treatment was less favorable than previous fixed restoration reports. The

differences between previous fixed treatments (historical controls) and the present maxillary overdentures was thought to be based on differences in patient selection and bone quality. A total of 32 mobile implants were removed and 29 were lost to follow-up. A higher implant failure rate occurred in the maxilla, and mucosal reactions were unfavorable around implants in the maxilla.

*Historical controls (strong tendency to over-estimate treatment effect), a stated lack of comparable patients (patient selection for the two treatments would be expected to be based on different physical characteristics), efficacy study, limited length of follow-up .*

**A comparative prospective study of splinted and unsplinted Branemark implants in mandibular overdenture therapy: a preliminary report. Naert I, et al; Jour Prosthet Dent 1994; 71:486.**

The purpose of this study was to determine the effect of splinted vs unsplinted conditions for two-implant mandibular overdentures as measured by objective tissue responses and subjective patient evaluations. Thirty-six patients were selected and randomly divided into three experimental groups: magnet, ball, or straight bar with clip attachments (the latter served as the control). Mean loading time was 12.4 months (range 3 - 24 mos) after which results indicated no differences between groups for implant failures (none recorded) or "periodontal" parameters. While patient subjective response did not reveal a difference, splinted bar-retained overdentures scored better on an objective evaluation. Based on this short-term follow-up, the manner of connection for the mandibular overdenture did not alter the clinical response.

*Control within selected treatment not across treatments, random assignment to overdenture connection groups, limited sample size with a negative trial (see Addendum 9), stated limited follow-up.*

**Ten-year longitudinal study of masticatory function in edentulous patients treated with fixed complete dentures on osseointegrated implants. Carlsson GE, Lindquist LW; Int J Pros 1994; 7:448.**

The purpose of this study was to follow edentulous patients provided with mandibular implant-supported prostheses and monitor their oral function over a 10-year period. In an original group of 23 patients, 9 also received maxillary implants after mandibular treatment. Measures of maximum occlusal force (called mastication efficiency index) revealed no difference between groups. At the 3-year examination, lower values were recorded for the self-rated masticatory ability but these ratings increased at the 10-year evaluation. The authors concluded that mandibular implant-supported prostheses provided to dissatisfied complete dentures patients led to an acceptable and dramatic improvement, while some patients demanded additional treatment to reach their level of satisfaction.

*No controls, two groups which self-selected treatment and therefore were not comparable (selection based on patient differences, therefore subjective responses would be expected to differ), good length of follow-up.*

**The mandibular subperiosteal implant denture: a prospective survival study. Yanase R, et al; Jour Prosthet Dent 1994; 71:369.**

The purpose of this study was to follow patients treated with subperiosteal implants monitoring clinical course which included maintenance requirements and complications. Over a 21 year period, 81 implants were placed in edentulous patients in a Graduate Prosthodontic clinic. Few patients were lost to follow-up but a significant number died before termination of the study. At 10 years, the survival rate was 79% for 63 patients, at 15 years 60% for 34 patients, and this trend led the authors to conclude that use of the subperiosteal implant comes with a low long-term survival which continues to decline over time

without reaching a steady state.

*No controls as presented, censored data handling would be a concern if a positive trial, excellent long-term follow-up.*

**Problems with prostheses on implants: a retrospective study. Walton JN, MacEntee MI; Jour Prosthet Dent 1994; 71:283.**

The purpose of this study was to determine prosthesis maintenance differences for fixed and removable implant prostheses. A retrospective evaluation of 156 patients was conducted and revealed removable prostheses adjustments to be almost 3 times that for fixed, and repairs were more than 2 times as frequent in the removable group. Contour adjustments for both prostheses, clip replacements for the removable prostheses, and gold screw adjustments for the fixed prostheses were the most common problems. Despite the high maintenance needed, patients were satisfied with both types of prostheses and the fixed prosthesis group exhibited limited satisfaction with cleansability. It was concluded that maintenance considerations should be made when deciding between prostheses.

*Retrospective study (see Addendums 4 & 5), large sample size, useful outcome measure which is not frequently considered.*

**Peri-implant mucosal aspects of III implants supporting overdentures. A five-year longitudinal study. Mericske-Stern R et al; Clin Oral Impl Res 1994; 5:9.**

The purpose of this longitudinal study was to follow 33 elderly patients (mean age 69 years) provided with mandibular implants and overdenture prostheses connected by bar or spherical attachments for 5 years. "Periodontal" parameters were monitored and it was noted that about 50% of the implants were placed in lining mucosa. The results revealed that 2 implants failed (1 due to fracture and 1 due to a peri-implant lesion), the average probing depths were 3mm, small local angular defects were noted on 16 implants in 12 patients (22%) which also exhibited slightly increased probing depths, and loss of attachment was less frequent when implants were placed following a prolonged period of edentulousness (>5 years). The authors conclude that reduced dexterity of elderly patients and the environmental conditions of the overdentures did not represent an increased risk of the development of peri-implant lesions.

*Assumed control (spherical attachment group?), no assurance of comparability of groups, negative trial with limited sample size (requires discussion and potentially a power analysis - see Addendum 9), adequate follow-up given population age.*

**Comminution of food with mandibular implant-retained overdentures. Geertman ME et al; Jour Dent Res 1994; 73:1858.**

The purpose of this study was to test the hypothesis that masticatory performance is dependent on the degree of support for mandibular prostheses provided by implants and/or alveolar mucosa. In a randomized clinical trial, measures of artificial food comminution were made in three edentulous patient treatment groups: conventional complete dentures (n=28), mandibular overdenture attached to 2 implants by a single bar-clip (n=29), and mandibular overdenture attached to a transmandibular implant by a 5 clip/three bar with cantilever extensions arrangement (n=27). Patients were allocated to treatment groups using a balanced method for six patient characteristics. The conventional denture group required 1.5 to 3.6 more chewing strokes to achieve comparable comminution. No difference was measured between the implant groups, and the authors concluded that retention and stability of the

prostheses rather than implant support provided the greatest impact on patient ability to comminute food during mastication.

*Treatment control group, randomized assignment, time for prosthesis accommodation was assured, outcomes not measured by blinded individuals*

**Within-subject comparisons of implant-supported mandibular prostheses: choice of prosthesis. Feine JS et al; Jour Dent Res 1994; 73:1105.**

The purpose of this study was to compare different types of implant-supported prostheses. A total of 15 patients were included in this cross-over clinical trial evaluating fixed and long-bar removable implant-supported mandibular prostheses. After random assignment, the groups functioned with their respective prostheses for 2 months and psychometric and physiological evaluations were made. The prostheses were then changed and the procedures repeated. Patients were asked to choose the prosthesis most satisfactory to them, and 8 chose the fixed prosthesis, 7 the removable prosthesis. Both groups rated the fixed prosthesis as best relative to stability and ability to chew; while the patients who chose the removable prosthesis rated ease of cleaning as the most important parameter in influencing their decision. There was a tendency for the removable prosthesis to be chosen by older patients (>50 years). The authors conclude patient attitudes should be considered prior to making treatment decisions.

*Treatment group as a control, cross-over design concerns relative to washout period (see Addendum 10).*

**Within-subject comparisons of implant-supported mandibular prostheses: evaluation of masticatory function. Feine JS et al; Jour Dent Res 1994; 73:1646.**

From the same study as above, the chewing movements and EMG activity were recorded for 5 test foods to test the hypothesis of whether fixed prostheses are more efficient in masticatory performance tests. Three test sessions per prosthesis with 5 trials per food each session revealed chewing stroke vertical amplitude was less (for all foods but one) and cycle duration was longer for 2 foods in the overdenture group compared to the fixed group, however, contrary to expectations, the long-bar overdenture was no less efficient than the fixed prosthesis. The data suggest that patients are capable of adapting their masticatory movements to the characteristics of the two prostheses.

*As above, with repeated measures it is important to have measurement reliability information regarding issues of clinical measurement variation to assure the method can distinguish some important difference, the repeated measures with rigorous analyses (including multilevel analyses exploring numerous sources of variation) required for this design attempted to do that, censoring of masticatory movement data may be of concern for some readers.*

**Prospective clinical evaluation of mandibular implant overdentures: Part I- Retention, stability, and tissue response. Burns DR et al; Jour Prosthet Dent 1995; 73:354.**

The purpose of this study was to determine the response (stability, retention, and tissue) of changing from a conventional complete denture to an O-ring or magnet-retained implant-overdenture. A total of 17 patients were enrolled in the study, their pre-existing dentures were modified prior to baseline data collection, and following this the patients were randomly assigned to the two experimental groups. Data collection was by force gauge for retention/stability and by 3 prosthodontists for retention/stability and tissue response. The results revealed statistical superiority of the implant groups compared to the conventional group. The O-ring group was statistically better than the magnet group for retention and stability, and the tissue response favored the implant groups.

*Control data preceded two experimental groups (patients considered implant treatment due to conventional problems, therefore subjective data would be expected to favor implant groups), blind assessment of outcomes is difficult for clinical evaluative component, interexaminer reliability not reported for any of the clinical examination parameters (stated that interexaminer studies performed but no report of reliability given).*

**Prospective clinical evaluation of mandibular implant overdentures: Part II- Patient satisfaction and preference. Burns DR et al; Jour Prosthet Dent 1995; 73:364.**

From the same study above, data were collected following modification of the conventional dentures and following use of the implant prostheses for 6 months. The subjects were satisfied with both attachment overdentures (over the conventional dentures), but showed a strong preference for the O-ring.

*As above, psychometric instrument used was a modification of a previous questionnaire (which was a modification of a previous questionnaire) and no documentation for proven validity and reliability is provided (see Addendum 6).*

**Osseointegration of Branemark fixtures using a single-step operating technique. A preliminary prospective one-year study in the edentulous mandible. Bernard JP et al; Clin Oral Impl Res 1995; 6:122.**

The purpose of this feasibility study was to apply the Branemark implant to a one-stage surgical procedure where the implants provide immediate stabilization to mandibular overdentures. Five volunteers (mean age 60 years) were provided with implants in the mandibular canine regions, three months after placement clinical and radiographic examination was conducted prior to changing the healing abutments for spherical attachments. At 9 months, clinical and radiographic measures revealed all implants to be stable and exhibiting favorable peri-implant health. All 5 patients considered the result to be adequate.

*No controls, limited sample size, stated limited follow-up, concern for volunteer effect on subjective outcomes (see Addendum 4).*

**Laser-welded titanium frameworks for fixed prostheses supported by osseointegrated implants: a 2-year multicenter study report. Bergendal B, Palmqvist S; Int J Oral Maxillofac Surg 1995; 10:199.**

The purpose of this study was to follow a group of patients (n=93) using 100 titanium laser-welded frameworks for 2 years and compare outcomes to a retrospective patient group (n=91) using 96 conventional frameworks. The results were good for both groups; 1.2% of the loaded implants were lost (1.6% in the titanium group, and 0.7% in the conventional group), 1 framework in each group fractured, and in the maxillary group there were significantly more implant failures and a tendency for more fractures of teeth and resin in the titanium group. Though the results are promising, the follow-up is too limited.

*Treatment control (conventional group) was retrospective (see Addendum 4), no randomization possible, good sample size (large enough to detect a clinically significant difference in outcomes?)*

**Factors related to success and failure rates at 3-year follow-up in a multicenter study of overdentures supported by Branemark implants. Hutton JE et al; Int J Oral Maxillofac Implants 1995; 10:33.**

The purpose of this international multicenter prospective study was to follow maxillary (117) and mandibular (393) overdentures supported by 510 implants. At 3 years 120 implants were supported by 44 implants; 150 were submerged and 66 implants had been withdrawn because of discontinued



participation; and 11 mandibular and 29 maxillary implants had failed and been removed from 21 patients. Eleven overdentures were considered failures (9.2% with a maxillary rate of 27.6% and a mandibular rate of 3.3%). Mandibular success was comparable to that reported for fixed prostheses. At highest risk for implant failure were patients who had poor bone characteristics (quantity E, quality 4), and patients who had 1 failure were more likely to have > 1 failure.

*Experimental comparison (or control) within implant treatment patient group (maxillary vs mandibular), also historical control for mandibular comparison to fixed prostheses, large sample size, rigorous analysis.*

**Nutritional adequacy of reported intake of edentulous subjects treated with new conventional or implant-supported mandibular dentures. Sebring NG et al; Jour Prosthet Dent 1995; 74:358.**

The purpose of this study was to compare baseline records of the nutritional dietary content to records kept semiannually for 3 years after treatment to ascertain whether nutrient intake of edentulous patients (convenience sample of the Washington, DC area) changed after receiving new implant-supported prostheses (n=41) or new conventional prostheses (n=30). The results revealed no significant difference between the groups for intake of calories or 27 nutrients ( $p > 0.01$ ). Trends noted in the groups reflected national trends, and more than 40% of the patients in both groups were found to have inadequate intake of dietary fiber, calcium, or both, and 25-50% had low intakes of vitamins A, E, D, B6 and/or magnesium; intakes that are similar to two age-matched populations.

*Age-matched historical controls (because data from the control group used has been repeatedly reported the validity may be less questionable), computer analysis of data allowed blind assessment, rigorous analysis including methods to analyze changes between groups over time where missing data could confound results and establishing an 0.01 significance level to compensate for the inflated type 1 error resulting from multiple comparisons.*

**Patient satisfaction and chewing ability with implant-retained mandibular overdentures: a comparison with new complete dentures with or without preprosthetic surgery. Boerrigter EM et al; Jour Oral Maxillofac Surg 1995; 53:1167.**

The purpose of this study was to compare denture satisfaction and chewing ability of edentulous patients treated with dental implant-retained overdentures or with conventional dentures with or without preprosthetic surgery. A total of 90 patients, 38 men and 52 women, with a mean anterior mandibular height of 21mm were assigned to the 3 treatment groups by a balancing allocation method. Satisfaction questionnaires related to denture complaints and chewing ability, and an overall satisfaction rating were used to measure prosthesis outcomes. At the 1-year evaluation, the majority of questionnaire factors showed significantly better scores for the two surgical groups compared to the conventional denture (without surgery) control. For the scale "functional complaints lower denture" the overdenture group scored significantly better than the preprosthetic group.

*Controlled trial, follow-up of 1 year though important to know may be too soon to distinguish time-dependent changes that could impact outcomes, validity/reliability of psychometric instrument very good (chose a previously validated instrument for this specific application, and established the reliability of its use for their patients by calculating Cronbach's coefficient  $\alpha$ )*

**Patient satisfaction with implant-retained mandibular overdentures. A comparison with new complete dentures not retained by implants - a multicenter randomized clinical trial. Boerrigter EM et al; Brit Jour Oral Maxillofac Surg 1995; 33:282.**

The purpose of this study was to determine the subjective patient evaluation difference for edentulous patients treated with conventional complete dentures or implant-retained mandibular overdentures. A total of 150 patients, 32 men and 118 women, the mean age of 56 years (range 35-84), exhibiting a mean anterior mandibular height of 13mm, were randomly assigned to the two treatment groups. Questionnaires focusing on denture-related complaints and general satisfaction revealed at 1 year the majority of factors scored significantly better for the overdenture group, and the authors concluded that for patients with severely resorbed mandibles, overdentures retained by implants can provide a more satisfactory solution to their denture-related complaints than new conventional dentures.

*Randomized control trial, unbalanced gender grouping but otherwise group comparability assured, measures applied and collected in a blind manner, limited follow-up though short-term differences were observed.*

**The edentulous predicament. I: A prospective study of the effectiveness of implant-supported fixed prostheses. Zarb GA, Schmitt A; JADA 1996; 127:59.**

This prospective study follows the clinical course of 50 patients who had experienced an unsuccessful conventional denture course and following a period of optimized conventional denture use, 45 were provided with implant-supported mandibular prostheses and 1 was provided with an overdenture. Eventually, 3 of the remaining 4 patients were provided with implant-supported overdentures. The results after a period of 11 to 15.5 years reveals: two patients (16 implants) did not return for follow-up evaluation, two patients died (8 or 10 placed implants still in function), one patient lost 5 mandibular implants after 3-6 years of function, and forty patients with 38 implant-supported prostheses were functioning well. Of the original 259 implants placed, 32 failed to osseointegrate (21 by Stage 2 surgery and 11 after varying periods of loading).

*Prospective study, no controls, selective sample (authors discuss this weakness), efficacy study.*

**The edentulous predicament. II: The longitudinal effectiveness of implant-supported overdentures. Zarb GA, Schmitt A; JADA 1996; 127:66.**

This prospective study follows 50 consecutive patients, who were unable to wear their conventional complete dentures, after optimizing their prostheses and assigning implant-retained overdenture therapy for 45 of the original 50 patients. The results after from 3 to 13 years reveals: two patients were unaccounted for (in function for 2 and 6 years), six patients died (14 implants), and thirty-seven patients with 39 prostheses were functioning successfully. Out of the original 132 implants placed, 5 failed to osseointegrate (three by Stage 2 and two after 2-3 years of function).

*Prospective study, no controls, [as in the preceding study, the authors discuss the outcomes in light of the stability requirement of prostheses which is the major prosthetic benefit with implant use and offer a clinical decision-making "model" for distinguishing between the need for totally implant-supported or implant/tissue-supported prostheses]*

## **Partially Edentulous - Fixed Partial Dentures**

**A clinical evaluation of fixed-bridge restorations supported by the combination of teeth and osseointegrated titanium implants. Ericsson I, et al; J Clin Perio 1986;13:307-12.**

The purpose was to determine whether implant and natural tooth support could be combined for fixed partial dentures. Ten patients were provided with a variable number of implants (2 to 6) in variable distributions relative to natural teeth, and splinted rigidly (n=6) or non-rigidly (n=4, Boos attachment) and followed for periods ranging from 6 to 30 months during which strict oral hygiene practices were monitored. Clinical outcomes included; oral hygiene status, gingival conditions, probing depths, marginal bone levels, and prosthetic quality using CDA-system criteria. Concluded that for short time frame, results are satisfactory given no adverse findings of significance but recommendations are premature due to limited time of follow-up.

*No control group, extreme variability in clinical use for such a small sample size.*

**Veterans Administration Cooperative Dental Implant Study- comparisons between fixed partial dentures supported by blade-vent implants and removable partial dentures. Part II: Comparisons of success rates and periodontal health between two treatment modalities. Kapur K; Jour Prosthet Dent 1989;62:685.**

The purpose of this RCT was to determine whether FPDs supported by blade-vent implants offer an acceptable substitute for mandibular unilateral or bilateral distal-base extension RPDs. Among 232 patients entered into this trial, 118 received RPDs and 114 received FPDs. During the 60 month treatment period, failures occurred in 19 FPD patients and 30 RPD patients. Ten FPD failures occurred prior to FPD insertion and 25 RPDs were considered failures due to lack of using the prostheses during eating. Life table analysis showed 5 year success to be 84.2% for the FPD group, and 74% for the RPD group. A statistically and clinically significant higher success rate was achieved for the FPD in patients with a Kennedy Class II edentulous condition, but the RPD fared better for those patients with a Kennedy Class I condition.

*RCT (stratified random assignment from a selective patient population), comparative assessment of prosthodontic options for similar categories of missing teeth distribution, multiple outcome analysis with predetermined treatment difference magnitudes (for 2 outcomes) to predict sample size needs, data reviewed after collection by study chairman before submitting to biostatistician - no mention of blind collection/assessment, psychometric instrument validity/reliability not addressed, multiple site allows replicability and technique sensitivity to be determined, patient population generalizability questions.*

**Osseointegrated implants in the treatment of partially edentulous patients: A preliminary study on 876 consecutively placed fixtures. Jemt T, Lekholm U, Adell R; Int J Oral Maxillofac Implants 1989; 4:211.**

The purpose of this prospective study was to follow the use of dental implants in 244 partially edentulous patients in an effort to determine safety and efficacy for use in this patient population. A total of 876 implants placed in 268 jaws of 244 patients were monitored for implant and prosthesis survival from 1 to 20 years. The results are subdivided into three time periods and reveal: only 712 implants were uncovered, of these 24 were lost; continuous prosthesis stability was evident for 98.7% of the prostheses.

*Prospective study, no controls, efficacy study, data stratification and presentation considered a form of censoring by some, limited outcomes.*

**The applicability of osseointegrated oral implants in the rehabilitation of partial edentulism: A prospective multicenter study on 558 fixtures. van Steenberghe et al; Int J Oral Maxillfac Implants 1990; 5:272.**

The purpose of this study was to prospectively follow 159 partially edentulous patients at 9 clinical centers treated with dental implant-supported prostheses. Clinical "periodontal" and functional parameters were monitored to assess safety and efficacy for this application. Of the original 558 implants placed, 521 remained to provide support to 199 prostheses in 154 patients. Thirty-seven implants were lost or unaccounted for, and after the first year of a 5 year study, 189 of the original 199 prostheses remained in function. Most failures occurred in patients with less-favorable bone quality.

*Prospective multicenter study, no controls, efficacy study.*

**The applicability of osseointegrated implants in the treatment of partially edentulous patients: three-year results of a prospective multicenter study. Henry PJ, Tolman DE, Bolender D; Quint Int 1993; 24:123.**

The purpose of this study was to prospectively follow at 9 clinical centers partially edentulous patients treated with dental implants. Clinical parameters were measured for "periodontal" status, prosthesis stability, and stomatognathic function in 159 patients ranging in age from 18 to 70 years. After 3 years, 460 loaded implants supporting 174 prostheses in 139 patients remained and were stated to have achieved a success rate comparable to edentulous patients.

*Prospective multicenter study, no controls, efficacy study.*

**The longitudinal clinical effectiveness of osseointegrated dental implants in anterior partially edentulous patients. Zarb GA, Schmitt A; Int Jour Pros 1993; 6:180.**

The purpose of this prospective study was to adapt the implant technique used for edentulous patients to the patients with anterior partially edentulous condition. In 30 patients with 34 partially edentulous areas, 94 implants were placed and followed. After periods of loading from 2-8 years [mean of 4.7], 94% [47 of 50] maxillary implants and 88.6% [39 of 44] mandibular implants remain in function. This average success rate of 91.5% was sufficient to resolve 100% of these selective maladaptive prosthetic experiences, and this suggests that implant use in the anterior region of the partially edentulous mouth can be as successful as in the edentulous experience.

*Prospective multicenter study, no controls (though assigned to patients with a poor conventional prosthetic experience), efficacy study, limited population, limited time followed (less than 5 years) and limited outcomes measured. By most dental standards and given the limitations with no controls (see Addendum 5), a well done study.*

**The longitudinal clinical effectiveness of osseointegrated dental implants in posterior partially edentulous patients. Zarb G, Schmitt A; Int Jour Pros 1993; 6:189.**

The purpose of this study was as the previous study except for the posterior jaws of partially edentulous patients. In 35 patients with 46 edentulous areas, 105 implants were placed. After loading for 2.6 to 7.4 years [mean 5.2], 97.6% [40 of 41] maxillary implants and 92.2% [59 of 64] mandibular implants remained in function. The overall average success rate of 94.3% suggests that dental implant use in the posterior jaws is a predictable treatment.

*As previous, efficacy study without controls.*

**Implant treatment in partially edentulous patients: a report on prostheses after 3 years. Gunne J, Jemt T, Linden B; Int Jour Pros 1994; 7:143.**

The purpose of this prospective multicenter study was to follow implant use in partially edentulous patients. In 154 patients provided with 521 implants to support 197 free-standing prostheses, 94.8% of the prostheses and 93.9% of the implants were in function at 3 years (cumulative success rates). Most of the lost prostheses were two-implant prostheses, which also was the group which experienced the greatest number of technical and mechanical complications.

*Prospective multicenter study, no controls, efficacy study.*

**Implant survival rates in partially edentulous patients: a 3-year prospective multicenter study. Higuchi KW, Polmer T, Kultje O; Jour Oral Maxillofac Surg 1995; 53:264.**

The purpose of this report was to provide 3 year data for a 5 year prospective study following the use of dental implants in partially edentulous jaws. Cumulative success rates for 139 patients with 460 implants were 92.5% for maxillary and 94.8% for mandibular implants. The failures noted were associated with poor bone quality, smaller implant sites, and higher plaque index, and were more than likely to occur before loading.

*Prospective multicenter study, no controls, efficacy study.*

**Bridges supported by free-standing implants versus bridges supported by tooth and implant. A five-year prospective study. Olsson M, Gunne J, Astrand P, Borg K; Clin Oral Impl Res 1995; 6:114.**

The purpose of this study was to address whether it is possible to combine teeth and implants for FPD support. In 23 patients who exhibited Kennedy Class I partially edentulous mandibular arches and completely edentulous maxillary arches, the two types of FPDs [2-implant only and tooth-implant] were randomized to side such that each patient had one of each FPD. The implant survival rate was 88% there was no significant difference in survival between the sides, FPD stability was 89% for the implant FPDs and 91% for the tooth-implant FPDs. No difference was noted in marginal bone changes between the groups. No increased risk of failure was seen for implants connected to teeth with FPDs compared to free-standing implant FPDs [when opposed by a complete denture].

*Treatment control, randomized assignment to side in a split-mouth design (see Addendum 11), small sample size, efficacy study.*

**Prospective investigation of the single-crystal sapphire endosteal dental implant in humans: ten-year results. Steflik DE, et al; Jour Oral Implantol 1995; 21:8.**

The purpose of this longitudinal prospective study was to evaluate the use of single-crystal sapphire screw-shaped implants, and attempt to establish clinical parameters for success and failure. In 17 patients, 28 mandibular implants were placed and after 6 weeks, 23 implants in 15 patients served as distal support for FPDs. Patient comfort, radiographic and "periodontal" parameters were monitored, and any implant failing in any three categories or requiring removal were deemed failures. At 10 years, 17 implants were available to recall and functioning (2 lost to recall, others failed) for a stated 81% success rate. Authors state that qualitative and quantitative parameters are useful for evaluation.

*No control, though multiple outcomes were measured three parameter cutoff for failure requires justification, censored data handling is misleading (see Addendum 12).*

**Delayed implants in the anterior maxilla with the IMZ-implant system. De Wijs PL, Cone MS, De Putter C; Jour Oral Rehab 1995; 22:319.**

The purpose of this report was to provide follow-up data on patients with anterior maxillary partially edentulous areas managed with dental implants. In 81 patients, 173 HA-coated implants were placed 3 or more months after tooth loss, and restored with fixed or removable partial dentures and single crowns. At 5 years the cumulative implant survival rate was 96.1%, and though esthetic compromise was common, the prostheses were stated to be highly satisfactory to both provider and patient.

*No controls, outcomes limited in scope.*

## **Partially edentulous - Single Teeth**

**Modified single and short-span restorations supported by osseointegrated fixtures in the partially edentulous jaw.**

**Jemt T; Jour Prosthet Dent 1986;55:243.**

The purpose of this article was to describe a clinical (technical) protocol for short-span restorations supported by implants and modified abutment components. The author concluded that short-term experience indicates the possibility of restoring single tooth and short edentulous spaces using dental implants.

*Technical information (with emphasis on technical and esthetic problems) regarding how to modify implant use from previous completely edentulous applications to the applications mentioned.*

**Single-tooth rehabilitation using osseointegration. A modified surgical and prosthodontic approach.**

**Ohrnell L-O, et al; Quint Int 1988; 19:871.**

The purpose of this report was to describe a modified surgical and prosthetic procedure is presented to improve the esthetic possibilities, shorten the treatment period, and simplify the single tooth implant procedure. Component modification introduced included an extended hex and a conical head on the implant, a counter-torque device, and cementing the crown as opposed to screw fastening.

*Technical information only, no data.*

**A new self-tapping Branemark implant: clinical and radiographic evaluation.**

**Friberg B, Grondahl K, Lekholm U; Int J Oral Maxillofac Implants 1992;7:80.**

The purpose of this report was to follow application of a new self-tapping implant, designed for denser bone qualities, and monitor insertion technique, complications, marginal bone remodeling, and survival rate. Thirty patients had 88 self-tapping and 91 standard implants placed in the mandible and maxilla. Insertion problems were seen for 13 self-tapping mandibular implants only; one implant from each group failed to integrate; radiolucencies were seen around apices of one implant from each group; and the mean marginal bone resorption at 1 year was 0.5 to 0.6mm for the two implants.

*Comparison at the implant level only, no prosthesis comparison, limited time for follow-up.*

**The longitudinal clinical effectiveness of osseointegrated dental implants for single-tooth replacement.**

**Schmitt A, Zarb G; Int J Pros 1993;6:197.**

The purpose of this study was to test the versatility of the osseointegration technique by testing its efficacy for single-implant support of crowns. Thirty-two patients were provided with 40 implants, 28 in the maxilla and 12 in the mandible, and loaded for 1.4 to 6.6 years. All implants at the time of evaluation (mean 2.9 yrs) were functional, and the results suggest the osseointegration technique can be adapted for use in patients with single missing teeth with predictably good success.

*No controls, short time period, limited outcomes (due to noncomparative nature), efficacy study by report.*

**Osseointegrated implants for single-tooth replacement: progress report from a multicenter prospective study after 3 years. Laney WR, et al; Int J Oral Maxillofac Implants 1994;9:49.**

The purpose of this study was to report 3 year data ("periodontal"/mechanical) for 82 of the original 92 patients. Since the first year report, 6 more patients have been lost to follow-up, but no additional implants in the *available* population have failed. The 3 year cumulative success rate was 97.2%, and no changes from the first year were noted in any of the "periodontal" outcomes measured. Abutment screw loosening continued but at a significantly reduced rate compared to that reported at the first year, and gold screws out-performed titanium screws in fastening security.

*Prospective multicenter study, no control/comparisons, whether lost patients counted as failures unsure.*

**Implants for single-tooth replacement. A clinical and experimental study on the Branemark CeraOne system.**

**Andersson B; Swed Dent J 1995; 108:1-41 (supplement).**

The purpose of this report was to present prosthodontic procedures and early clinical experience of the CeraOne system, with some outcomes from an on-going prospective trial. Survival rates for 57 patients after 2 years (65 implants) and 34 patients after 3 years (37 implants) revealed survival rates comparable to other reports (above 95%), however, conical implants showed a higher degree of bone loss in comparison to other implants.

*No controls, a variety of oral locations for a limited sample size.*

**Osseointegrated implants for single tooth replacements in general practice: a 1-year report from a multicenter prospective study. Henry PJ, et al; Austr Dent J 1995; 40:173.**

The purpose of this report is to describe 1 year results of single implant application by general practitioners who prior to the study had received no formal implant training, and provided treatment following intense training. The group placed and restored the implants, and at 1 year the results compared favorably with the reported results of previous centers. The authors suggest this is proof that general practitioners should be trained in the use of dental implants so that improved delivery of care can be provided at a more economic level.

*No controls, general practitioner component addresses issue of efficacy vs effectiveness from a provider standpoint- but extent to which care was provided as in the community is not easily determined, this directly relates to the conclusions which assumes because general practitioners in this setting achieved 1 year results comparable to others they will provide a better service to their patients (better than what is not stated, it is assumed the authors mean single tooth implants are better than any other option) in a more economical manner, though no direct/indirect cost comparisons were provided.*

**Single-tooth restorations supported by osseointegrated implants: results and experiences from a prospective study after 2 to 3 years. Andersson B et al; Int J Oral Maxillofac Implants 1995; 10:702.**

The purpose of this report is to provide follow-up data on 57 patients at 2 years, and 34 patients at 3 years, who have had the CeraOne system applied to single missing teeth conditions. The cumulative success rate at 3 years was 97.3%, and the only crown fractures that occurred were the result of trauma not occlusal forces. The conclusions were that the system achieves good esthetic results, and avoids both screw loosening and fistula formation complications.

*No controls, limited time for follow-up.*



## Summary

It is evident from the review of this selected literature that the application of dental implants to the edentulous conditions ranging from single missing teeth to complete edentulism can be safely and efficaciously accomplished. Whether the results reported are representative of outcomes expected in the private offices of the majority of providers is not known. What is also evident is that comparative outcomes for the use of osseointegrated dental implants are only available for the completely edentulous patient.

It was not intended for this review to detract from the research effort put forth in any of the reviewed studies. Clinical research is a very difficult and time-demanding endeavor. Progress in such efforts, however, demands critical appraisal to assure professional accountability and maximum yield of future efforts.

In practice, when patients are seeking dental care, they may have a particular treatment in mind and selection becomes a mute point. However, for those patients who are seeking the best treatment for their oral condition, the lack of comparative data for certain prosthetic options places a greater responsibility on the practitioner to inform the patient regarding this situation, especially when the cost component of the cost/benefit consideration is a major factor.

The best solution to this dilemma is to conduct comparative research for the prosthetic options and better understand cost/benefit as well as benefit/risk for these treatments. Such information will strengthen providers in their position to defend appropriate dental implant use for patients who are self-paying and for patients who benefit from third-party paying resources. Such research evidence will help individual practitioners as well as managed care policy-makers understand the most appropriate use of dental implants.



# **A Review Of Implant Systems**

**Dr. Charles E. English**



## Trends With Endosseous Implants

Charles E. English, DDS  
Augusta, Georgia  
FAX: 706.738.5359

### Part I

1. External Hex Implants	Ref: 1
2. Macrogeometries	1, 2
3. Immediate Transfers	3, 4
4. Immediate Loading	5, 6
5. Implant Choices	7
6. Emergence Profile	8
7. Site Development	9, 10, 11
8. IADR	12, 13
9. Staging	14
10. Single Tooth	15, 16, 17, 18, 19, 20,
11. Provisionals	21, 22, 23
12. Cement Usage	24, 25
13. Coating Technologies	26
14. Selective Extractions	27
15. Increased Osseous Needs	28, 29
16. Removable Prosthesis	30, 31, 32, 33
17. Improved Technologies	
18. Simplification and Cost Containment	
19. Team Concept Frustrations	
20. More to Come	

### Part II

#### Abutment Connection Mechanisms (8):

A. External Hex	E. Internal Octagon
B. Internal Hex	F. Polymer Butt
C. Internal Bevel	G. Internal Spline or Post
D. Butt Joint	H. External Spline

### Bibliography

1. English, C. E.: Externally hexed implants, abutments, and transfer devices: A comprehensive overview. *Implant Dent* 1992;1:273-282.
2. English, C. E.: An overview of implant hardware. *JADA* 1990;121:360-8.
3. Reiser, G. M., Dombush, J. R., Cohen, R.: Initiating restorative procedures at the first stage implant surgery with a positional index: A case report. *Int J Periodont Rest Dent* 1992;12:279-293.
4. Prestipino, V., Ingber, A.: Implant fixture position registration at the time of fixture placement surgery. *Prac Perio & Aesthet Dent* 1992; Nov-Dec. *The Implant Report* 1992.
5. Schnitman, P. A., Wohrle, P. S., Rubenstein, J. E.: Immediate fixed interim prostheses supported by two-stage threaded implants: Methodology and results. *J Oral Implantol* 1990;16:96-105.
6. Salama, H., Rose, L F. Salama, M., Betts, N. J.: Immediate loading of bilaterally splinted titanium root-form implants in fixed prosthodontics - A technique reexamined: Two case reports. *Int J Periodont Rest Dent* 1995;15:345-361.

## **Addendum 1 Observational studies**

Clinical studies in which the researcher gathers data by simply observing events as they happen, without playing an active part in what takes place, are called *observational studies*. Cohort and case control studies are common examples; in a cohort study, a group of people (a cohort) is assembled, none of whom has experienced the outcome of interest but all of whom could experience it, they are classified according to important characteristics related to the outcome of interest and followed over time to see which experience the outcome. Other names for cohort studies include longitudinal, prospective, and incidence.

Case-control studies start with people who have the outcome of interest (cases) and another group which does not (controls), who otherwise are as similar as possible, and looks backwards in time to determine the frequency of exposure in the two groups to some factor deemed important to developing the outcome of interest. Another name for a case-control study is retrospective.

The most important scientific disadvantage of observational studies is that they are subject to great many more potential biases than are experiments, especially related to sampling, selection and measurement.

Fletcher, RH. *Clinical epidemiology: The essentials*/ RH Fletcher, SW Fletcher, EH Wagner. 3rd ed. Williams & Wilkins, Baltimore, 1996, Chapters 5 & 10.

## **Addendum 2 Hierarchy of Evidence**

From Guyatt et al, the grades of recommendations are for a specified level of baseline medical risk:

A1 - RCTs, no heterogeneity, CIs on one side of threshold NNT

A2 - RCTs, no heterogeneity, CIs overlap threshold NNT

B1 - RCTs, heterogeneity, CIs on one side of threshold NNT

B2 - RCTs, heterogeneity, CIs overlap threshold NNT

C1 - Observational studies, CIs on one side of threshold NNT

C2 - Observational studies, CIs overlap threshold NNT

[RCT= randomized control trial, CI= confidence interval, NNT= number needed to treat; see reference for details].

The lowest level of recommendation is for study designs that have the greatest potential for bias.

Guyatt GH et al; User's guide to the Medical literature, IX. A method for grading health care recommendations. JAMA 1995; 274:1800.

### **Addendum 3 Sampling**

Populations are large groups of people in a defined setting or with a certain characteristic. A sample is a subset of a population and is selected from the population (a process referred to as sampling). Clinical research is ordinarily carried out on samples, and the population characteristic of interest is for practical purposes estimated from use of a *representative sample* of the population. Bias in sampling is an important consideration. The kinds of patients that are used in a trial determine the extent to which conclusions can be generalized to other patients, or the population at large.

Patients in clinical trials are often a highly selected, biased sample of all patients with the condition of interest. This is due to three main reasons:

- 1) Inclusion/exclusion criteria which are used to restrict heterogeneity of patients and to improve the chances of patients completing the assigned treatment. As heterogeneity is restricted in this way, the internal validity of the study is improved as there is less opportunity for variation in outcome that is not related to the treatment. Exclusions come at the price of diminished generalizability because characteristics that exclude patients will occur commonly among patients ordinarily seen in clinical practice.
- 2) Patients can refuse to participate because they may not want a particular type of treatment or to have medical care decided by someone unfamiliar to them. These patients are likely to be systematically different from those who agree to participate relative to socioeconomic class, severity of disease or condition, or some other health-related problem.
- 3) Patients thought to be unreliable or thought to not follow trial ground rules are usually not enrolled. This avoids wasted effort and the reduction in internal validity that would occur if patients moved in and out of treatment groups or out of the trial altogether.

Related to the above are sampling approaches used for questionnaires that share procedural concerns relative to bias for general sampling methods.

- 1) Sample of convenience - works well as long as the sample is large and includes a high percentage of the study population; one of the most commonly-used approaches that lends itself to much bias and is criticized by behavioral science researchers.
- 2) Random sample - valid as long as the sample is quite large and the selection process uses a true random approach; this emphasizes random assignment as well as random selection dimensions.
- 3) Self-selection/volunteers - since the types of persons who choose to participate have been shown to differ from others this process is prone to more bias; these individuals are more educated, have a higher occupational status, a high need for approval, high IQ, and are low in authoritarianism.
- 4) Density sampling - conducts samples from incident cases over a specific period of time where sampling and assessment of controls is done through the entire study to reduce bias by constant sampling of both subject and controls instead of using a cross-sectional approach.
- 5) Miscellaneous other approaches; blanket survey, stratified sample, and quota sample.

Timmreck TC, *An introduction to Epidemiology*, Jones & Bartlett Publishers, Boston, 1994, pages 238-241.

## Addendum 4 Comparisons

The value of a treatment can only be judged by comparing its results to those of some alternative course of action. The question is not whether a point of comparison is used, but how appropriate it is. Results among patients receiving an experimental (new) treatment can be measured against one or more of several kinds of comparison groups:

- 1) No intervention - Comparing treatment with no treatment measures the total effects of health care, both specific and nonspecific.
- 2) Observation - Do treated patients do better than patients who are simply observed? People have a tendency to change their behavior because they are the target of special interest and attention in a study, regardless of the specific nature of the intervention they might be receiving. This phenomenon is called the *Hawthorne effect*. Thus comparison of treatment with simple observation measures treatment effect over and above the Hawthorne effect.
- 3) Placebo - Do treated patients do better than patients given a *placebo*, an intervention indistinguishable from the active treatment but without any known mechanism of action? It has been demonstrated that placebos can be effective for about 1/3 of patients.<sup>11</sup> The value of the placebo effect may differ for researcher or clinician, however many clinical interventions have both specific (true treatment) and nonspecific (Hawthorne, placebo, and other) effects.
- 4) Usual treatment - Do patients given the experimental treatment do better than those receiving usual treatment? This is the only meaningful (and ethical) question if the usual treatment is already known to be efficacious.

Fletcher RH, Fletcher SW, Wagner EH: Clinical Epidemiology, The essentials. Williams and Wilkins, Baltimore, 1996, Chapter 7.



## Addendum 5 Controls

Trials are called uncontrolled if they specifically describe the course of disease (or condition) only in a single group of patients who have been exposed to a particular intervention of interest. What is wrong with assessing the effects of treatment by comparing clinical courses in patients before and after treatment? The results can be misleading for several reasons.

- 1) Unpredictable outcomes - In situations where the clinical course is extremely variable for a given patient and from one patient to another, assessing treatment effects by observing changes in the course of disease after treatment is unrealistic.
- 2) Nonspecific effects - As mentioned above, patients may respond to the special attention they receive as part of a study and there is no way of separating out this (Hawthorne) effect from treatment effects in uncontrolled trials. Also, as shown by placebo use, there can be other non-treatment specific effects at play in patient response. If there are control patients who receive the same attention as the treated ones, then these nonspecific effects cancel out in the comparison.
- 3) Regression to the mean - Patients selected for treatments because they represent an extreme value in a distribution are likely, on the average, to have lower values for later measurements. If the normal course of response for a disease or condition is to regress toward more normal values (the mean), then treatment provided may mistakenly be considered effective when the true effect is due to this regression. Regression is another reason why using patients as their own controls can be misleading for some outcomes.
- 4) Predictable outcome - (Related to the above, but more directed to disease course improvement instead of a laboratory or prognostic test value regressing to more normal levels) If the usual course of a disease is to improve, then therapeutic efforts may coincide with improvement but not cause it.

Controls, therefore, have an important role in establishing whether treatment effects are due to treatment-specific effects or nonspecific effects. The extent to which controls are used can vary. For many clinical questions, it is not possible nor practical to rely on a RCT. Compromises with this ideal include making comparisons to experience with past patients, to past experience with the same patients, or to a concurrent group of patients who are not randomly allocated. When these compromises are done, the internal validity of the study is weakened.

Fletcher RH, Fletcher SW, Wagner EH; as above, Chapter 7.

## Addendum 6 Blinding

Participants in a trial may change their behavior in a systematic way (i.e., be biased) if they are aware of which patients receive which treatment. One way to minimize this effect is by *blinding*, an attempt to make various participants in a study unaware of which treatment patients have been offered, so that the knowledge does not cause them to act differently. This protects the internal validity of the study.

Blinding can occur at 4 levels; at the time of treatment allocation the individual should not know which treatment will be assigned next, the patient should not have knowledge of which treatment was administered, providers should not know which treatment was offered, and those assessing the outcomes should not be aware of which treatment was offered. For many important clinical questions, such as comparative assessments of prosthodontic options, blinding of patients and providers is not easily accomplished.

Fletcher RH, Fletcher SW, Wagner EH; as above, Chapter 7.

## **Addendum 7 Questionnaires**

Questionnaires are frequently used to determine patient-based outcomes. The development of such measurement "instruments" is a structured process to assure that it is measuring what it intends to measure, termed validity, and that it can accomplish the measure in repeated applications, termed reliability. Such instruments used in clinical practice and research have three basic purposes: to discriminate among individuals along a continuum of health, illness, or disability; to predict outcome or prognosis; and to evaluate within-person change over time. Patient satisfaction, quality-of-life, or patient preference type of data are examples of outcomes that must be shown to have undergone validity and reliability testing before the results can be accepted. If such an instrument is to be used longitudinally it also needs to have the characteristic termed responsiveness, which means that it is responsive to change over time which is determined to be clinically significant in its extent. A suggested format for constructing an index or questionnaire to evaluate quality of life includes: selection of the item pool, reducing the number of items, choosing the response options, and determining reproducibility (reliability), validity, and responsiveness. If scientifically rigorous approaches to questionnaire development, selection, and administration are used, the results will be valid and credible to the scientific community.

Jaeschke R, and Guyatt GH: How to develop and validate a new quality of life instrument. *in*, Quality of Life Assessment in Clinical Trials, ed. B. Spiker, Raven Press, Ltd. New York, 1990, Chapter 5.

## **Addendum 8 Multicenter Trials**

When a novel treatment or procedure is introduced to the medical community, results from a single source provides a measure of success limited to the number of providers and sampled patients. To strengthen the results from the standpoint of universal application and benefit (i.e., usefulness), combining the efforts of multiple providers at different locations serving geographically and culturally diverse populations adds to the strength of the study results. Along with the advantage of efficiently increasing the sample size, this is the strategy for multicenter trials.

## **Addendum 9 Negative trial concerns for sample size**

Negative trials- when a trial comes to the conclusion that neither treatment is better than the other, the question should be asked if the results are due to chance alone? Is it likely that the result of no difference is in fact untrue, and the treatments actually differ? When this is the case, it is referred to as a false negative finding, also called a  $\beta$  (beta) or type II error. The risk of false-negative results is particularly large in studies with relatively few patients. Beta error has received less attention than false positive error due to numerous reasons. However, regardless of the reason for not considering the probability for false negative error, it is the main question that should be asked when the results of a study indicate no difference.

When such a study result is seen, the likelihood that a  $\beta$  error exists depends on four characteristics:

- 1) the magnitude of the difference in outcome between treatment groups,
- 2) the nature of the study's data,
- 3 & 4) the probabilities for both  $\alpha$  (false positive) and  $\beta$  errors.

Effect size is important in that large numbers of patients are needed to detect small differences in treatments. For outcomes expressed as continuous variables, power is affected by the degree to which patients vary among themselves (the larger the variation among patients, the lower the statistical power). The customary manner to protect against saying a treatment is effective when it is not ( $\alpha$  error) is to establish an acceptable level of risk (customarily 1:20 or 0.05) for making this type of error. The chosen risk for  $\beta$  error is another determinant of sample size. Conventional  $\beta$  errors are much larger (0.20) than  $\alpha$  errors, reflecting the higher value usually placed on being sure an effect is really present when we say it is present.

When a study has reached the conclusion of no difference (a negative trial) and discussion is directed to an analysis of the sample size which reveals that the sample had sufficient power to detect a difference, then the reader should be less concerned about false negative error.

Fletcher RH, Fletcher SW, Wagner EH; as above; Chapter 9.

### **Addendum 10 Cross-over designs**

Cross-over designs in clinical trials have their genesis in pharmacological studies. The universal appeal for such a design includes the reduced costs due to the need for fewer patients and the decreased statistical variance because of the seemingly identical groups. Concern exists for carry-over effects from one treatment to the other on physiological, pharmacological, or psychological outcomes being measured. A washout period is required to remove the potential for such carry-over effects and has as the objective to return the patients to a baseline parameter level. This design is generally used with great caution in medicine.

Feinstein, AR. *Clinical Epidemiology, The Architect of Clinical Research*, WB Saunders, Philadelphia, 1985, pg 695.

### **Addendum 11 Split-mouth designs**

The split-mouth design used in dentistry subdivides the mouth into experimental units that are considered comparable as independent baseline units. As comparisons are made within the same patient, it is anticipated that variability would be less than that for studies where the patient is basic unit of comparison. A potential disadvantage is that treatment performed in one part of the mouth can affect treatment in other parts of the mouth, a phenomenon referred to as carry-across effect and similar in principle to the cross-over design concern for carry-over effect.<sup>12</sup> Unless disease (or condition) characteristics that are important to the outcomes are symmetric in subdivided unit distribution, whole-mouth clinical trials may be preferable.<sup>13</sup>

Brunette DM, ed *Critical thinking, Understanding and evaluating dental research*. Quintessence, Chicago, 1996, Chapter 15.

### **Addendum 12 Censored data**

Data lost to follow-up is termed censored data. Censoring is an important consideration because it is not known whether censored patients experienced continued good outcomes or developed adverse outcomes (and decided not to come for evaluation). Therefore, the true effect they would have had on the study outcome is not known. Examination of data for censoring is often done by life table analysis. Another simpler method is to determine worse/best case impact on the existing data. For the data in the Steflik study, the 2 lost implants can be considered successes or failures, and a range of success rates from  $19/23 = 83\%$  (best case) to  $17/23 = 74\%$  (worse case) can be computed to provide the reader with a more complete understanding of possible outcomes.

## References

(suggested reading #s 1,5,6,12,13)

1. Bader JD, Shugars DA: Variation, treatment outcomes, and practice guidelines in dental practice. *J Dent Ed* 1995; 59:61-95.
2. Barenthin I. Dental health status and dental satisfaction. *Int J Epidemiol* 1977; 6:73.
3. Elwood JM, in *Causal relationships in medicine, A practical system for critical appraisal*. Oxford University Press, Oxford, 1988, pp 174-175.
4. Cook DJ, Guyatt GH, Laupacis A, Sackett DL: Rules of evidence and clinical recommendations on the use of antithrombotic agents. *Chest* 102;4:305S-311S,1992.
5. Guyatt GH, et al: User's Guide to the Medical Literature, IX. A method for grading health care recommendations. *JAMA* 1995; 274:1800.
6. Antczak-Bouckoms A, Joshipura K, Burdick E, Tulloch JFC: Meta-analysis of surgical versus non-surgical methods of treatment for periodontal disease. *J Clin Perio* 1993, 20;:259-268.
7. Bader JD, Shugars DA: Variation, treatment outcomes, and practice guidelines in dental practice. *Jour Dent Educ* 1995, 59;1:61-95 [see pg 72].
8. Sacks HS, Chalmers TC, Smith H: Sensitivity and specificity of clinical trials. *Arch Intern Med* 1983;143:753-755.
9. Chalmers TC, Celano P, Sacks HS, Smith H: Bias in treatment assignment in controlled clinical trials. *New Engl J Med* 1983;309:1358-61.
10. Fletcher RH, Fletcher SW, Wagner EH; *Clinical epidemiology, the essentials*. Baltimore, Williams & Wilkins, 1996, pg 145.
11. Fischer RW: Comparison of antipruritic drugs administered orally. *JAMA* 1968; 203:418-419.
12. Hujoel PP, De Rouen TA; Validity issues in split-mouth trials. *J Clin Periodontol* 1992; 19:625.
13. Hujoel PP, Loesche WJ; Efficiency in split-mouth designs. *J Clin Periodontol* 1990; 17:722.



# **Dental Implants And Their Biological Interfaces**

**Dr. Hans-Peter Weber**





# DENTAL IMPLANTS AND THEIR BIOLOGICAL INTERFACES

## THE SOFT TISSUE-IMPLANT INTERFACE

### Overview

The predominant biological considerations in endosseous implant dentistry have focused on the bone-to-implant interface, since predictable implant anchorage requires the implant to directly contact the bone tissue.

Through initial studies in dogs, Branemark (4,53) et al. recommended the following as prerequisites to achieve osseointegration predictably: 1) biocompatible material; 2) low-trauma surgery with low-temperature drilling; 3) primary implant stability; 4) non-loaded healing phase; and 5) submerged (submucosal) placement of implants, thus excluding soft tissue contact with the implant. After an initial healing period, a second stage surgery was performed to insert another implant component. The significance of the resulting connection gap between implant and abutment at or below the alveolar crest is presently not well understood, but is an area of current research interest.

Schroeder et al. (54) described a non-submerged technique of placing endosseous implants, i.e. the implant extended above the bone and through the soft tissues at the time of initial placement. It is clear today that both submerged and non-submerged approaches can be successful, as many papers have now been published which document long-term success.

Transmucosal structures in the oral cavity, such as teeth and implants, must penetrate the soft tissues, comprised of gingival connective tissue and gingival epithelium. This ensures the integrity of the integument by forming a seal between the inside of the body and the outside environment. Thus, the implantogingival tissues, by definition, serve a similar barrier function as dentogingival tissues, and the integration of the implant necessitates the integration of all three types of tissues - bone, soft connective tissue, and epithelium. When seen as a barrier, it is important to consider the soft tissues surrounding implants in two aspects: (1) the morphology (structure) and, (2) the physiological function of the implantogingival junction. Most studies to date have examined the morphology of the soft tissues around the implant.

An early study in monkeys described the soft tissue contact with various implant surfaces around 30 non-submerged implants (54). Implants placed in attached keratinized mucosa with minimal inflammation had connective tissue located between the bone and epithelium. The connective tissue contained many fibers with few inflammatory cells. Collagen fibers were in intimate contact with the implant post and ran between the implant and mucosa at the LM level. Evidence was described for a "... true adhesion of the epithelium to the implant ..", i.e. no space or gap was seen between the epithelium and the implant. Scanning electron microscope (SEM) analysis indicated that the connective tissue contact with the titanium plasma-sprayed surfaced implant was composed of a fibrous layer of interwoven fiber bundles firmly adherent to the surface of the implant. At this level, and against the rough surface, the fibers appeared to be functionally (more perpendicularly) oriented. SEMs also revealed epithelium with intercellular junctions and desmosomes. Hemidesmosomes were not observed in the sections of the rough surface, but the investigator acknowledged the technical difficulties in visualizing the titanium plasma-sprayed-epithelium interface. A basal lamina was observed between the epithelium and the titanium plasma-sprayed particles with microvilli from the epithelial cells extending into the layers of the basal lamina. A conclusion of this study was that the fine ultrastructure of the epithelial cells adjacent to the implant was not significantly different from that of other epithelial cells, and suggested that the cells were not influenced by the titanium.

In a review article that compared periodontal tissues to peri-implant tissues, periodontal ligament tissues were discussed, as was the question of why periodontal ligament was usually not found around endosseous implants (61). It was suggested that the lack of cementum was not due to an inability of cementum to form on titanium, but that it was due to a lack of cementum progenitor cells in the implant site. Cementum progenitor cells appeared to be derived from periodontal ligament, so without this source of cells, a ligament could not form around an implant. In interesting examples that reinforced this concept, three publications demonstrated that if an implant was placed adjacent to a root tip, an attachment apparatus similar to that around teeth was found (62-64). This was attributed to the fact that progenitor cells from the periodontal ligament were present, became stimulated, and formed cementum and periodontal ligament proper on the titanium surface. This was a particularly intriguing finding in

Periodontology, as it suggested that the substrate, i.e. the surface, was not the critical factor for the formation of periodontal ligament. At present, the desirability of an endosseous implant with a periodontal ligament is unknown. Experiences with fibrous encapsulation should not, however, be used as an analogy, since periodontal ligament with Sharpey's fibers is a functional structure and fibrous encapsulation is not.

Other studies confirmed the findings above (65,66). For instance, an examination was made of the mucosa in dogs around submerged Astra implants that had abutments placed four months after implant placement (67). The investigators found that the surrounding mucosa was similar to that around teeth. The soft tissues consisted of a collagenous stroma below a stratified squamous epithelium. Apical epithelial migration was not observed. The epithelium was arranged as a collar and consisted of multiple layers of flattened cells joined by desmosomes parallel to the implant surface with a relatively straight basement membrane. At the electron microscope (EM) level, there were typical cellular features including mitochondria, rough endoplasmic reticula, Golgi complexes, and tonofilaments. The outer implant epithelium was a keratinized, stratified squamous epithelium resembling masticatory oral mucosa. Rete pegs and an undulating interface with connective tissue papillae interdigitated with the epithelial ridges. All basal epithelial cells were connected to the basement membrane with hemidesmosomes. Dense bundles of collagen ran in different directions in the connective tissue. Inflammatory cells, such as polymorphonuclear leukocytes and plasma cells, were observed in addition to the connective tissue fibroblasts. The authors stated that the technical difficulties in preparing the specimens prevented more detailed information in this paper regarding the soft tissue-implant interface. This was due to their need to dissect the soft tissues from the implant interface in order to prepare the tissue for examination by electron microscopy.

The vascular topography of the soft tissues around teeth and implants was compared in two beagle dogs (68). Around teeth, the vascular supply was derived from supraperiosteal vessels lateral to the alveolar process and from vessels within the periodontal ligament. Implant soft tissue blood supply was derived from terminal branches of larger vessels from the bone periosteum at the implant site. Blood vessels adjacent to junctional epithelium around both teeth and implants revealed a characteristic "crevicular plexus". Furthermore, while peri-implant soft tissues lateral to the implant had sparse blood vessels, soft tissue lateral to root cementum was highly vascularized. The authors concluded that these latter findings confirmed the work of Buser et al. (69), in which a connective tissue zone lacking blood vessels was found directly adjacent to the implant surface.

A more recent paper using immunohistochemistry has confirmed structural differences in healthy human periodontal and peri-implant (ITI) keratinized gingival tissues (70). Collagen types I, III, IV and VII and fibronectin had similar distribution patterns between teeth and implants. Collagen types V and VI had different distributions between teeth and implants. The authors suggested that the greater amounts of type V collagen around implants was significant due to its greater collagenase resistance.

## **Epithelium**

Supracrestal tissues appear to be similar to gingiva around teeth in many ways. This tissue has a dense, collagenous lamina propria and is covered with stratified squamous, attached oral epithelium (61). The epithelium of the attached gingiva is envisioned to most closely resemble tissues around teeth having a keratinized oral epithelium continuous with a non-keratinized sulcular epithelium lining the gingival sulcus. The apical part of the gingival sulcus is lined by a junctional epithelium of typical tooth morphology. Thus, the sulcular epithelium appears to be a non-keratinized extension of the oral epithelium and is continuous with the junctional epithelium. The junctional epithelium is also non-keratinized, provides an epithelial union between the implant and surrounding gingiva, and does not apically proliferate to the bone.

Using a freeze-fracturing technique, an early study showed that in a manner similar to that of teeth, the junctional epithelium was attached to the implant surface by a basal lamina and hemidesmosomes (71). These findings were confirmed at the EM level using epoxy resin replicas of extracted teeth in monkeys (72). This study also demonstrated intact epithelium at the implant surface. A similar relationship of epithelium to titanium or titanium alloys using evaporated layers of metal over plastic implants, has also been shown (73). A similar finding was noted in a dog study which used freeze-fractured specimens from aluminum oxide ceramic implants (74).

## Epithelial Ultrastructure and Immunological Findings

Ultrastructurally, the mucosa around implants has been shown to be similar to the mucosa around teeth (75). In a beagle dog study of crystal sapphire implants which were placed in a non-submerged, or one-stage procedure, the marginal soft tissues had a collagenous stroma covered with an oral keratinized epithelium. The outer epithelial cells were joined by desmosomal contact. A junctional epithelium arranged as a collar was composed of flattened, non-keratinized squamous cells. Apical epithelial migration was not observed. At the EM level, mitochondria, rough endoplasmic reticula, Golgi complexes, and tonofilaments were observed. Hemidesmosomes were found at the basal lamina, which was smooth at the inner implant epithelium. An undulating basal lamina was found at the outermost epithelium, with connective tissue papillae interdigitated with the epithelial ridges. Collagen fibers ran in distinctively different directions and were embedded in ground substance. Biopsies from healthy implants contained few inflammatory cells.

The epithelial and connective tissue attachments to titanium micromachined grooved and smooth implant surfaces has been examined at the LM and EM levels (76). Using grooves of different sizes, this study indicated that epithelial cells closely attached to 3  $\mu\text{m}$  and 10  $\mu\text{m}$  grooves but not 22  $\mu\text{m}$  grooves. The cells attached to the titanium with basa-lamina-like structures approximately 30 nm thick. Tonofilaments (containing cytokeratins and characteristic of epithelial cells) were oriented parallel to the implant surface and the cells contained numerous ribosomes, some rough endoplasmic reticula, and mitochondria, in addition to many tonofilaments. Fibroblasts were oriented parallel to the long axis of the implants in the two smaller grooved surfaces, but were obliquely inserted into the 22  $\mu\text{m}$  grooved surface. These cells had structures which indicated highly synthetic cells, including abundant rough endoplasmic reticula, golgi apparatus, ribosomes, and mitochondria. The fibroblast attachment involved an approximately 20 nm amorphous, electron-dense zone adjacent to the titanium and a fibrillar zone running from the amorphous layer to the cell membrane.

Another study analyzed the distribution of interstitial collagenous and non-collagenous glycoproteins of keratinized tissue (77). Gingival biopsies from healthy tissues around successful IMZ implants in five partially edentulous patients were compared to similar biopsies from healthy human teeth. Immunofluorescence techniques were used to identify types I, III, and IV collagen, laminin, and fibronectin. A stratified squamous keratinized oral epithelium, continuous with a non-keratinized sulcular epithelium, was observed. The sulcular epithelium overlapped the outer coronal surface of the junctional epithelium and was separated from the underlying connective tissue by a basement membrane rich in type IV collagen and laminin. Dense connective tissue was observed under the oral epithelium. No significant difference was found in the distribution of collagenous components compared to the gingiva from teeth, however, the fibers in the connective tissue ran parallel to the long axis of the implant. Fibronectin, the major structural non-collagenous gingival glycoprotein, had the same distribution in tissues from both implants and teeth. Approximately half of the biopsies had inflammatory cells and decreased collagen content below the junctional epithelium. In these areas, increased staining of type III collagen and fibronectin was observed. The authors concluded that the distribution of interstitial collagenous and non-collagenous glycoproteins of keratinized tissue around successful implants was similar to that of normal gingiva around teeth.

One study used monoclonal antibodies to specific cytokeratins and ICAM-1 to compare staining in gingival biopsies around teeth to gingival biopsies around implants (78). These staining patterns allowed an evaluation of the differentiation pattern of the epithelium. The results indicated that the formations of oral, oral sulcular, and junctional epithelium were phenotypically similar between teeth and implant gingiva. The implications of this work, as outlined by these investigators, are interesting: (1) the presence of junctional epithelium around implants indicates that its formation is not dependent on odontogenic epithelium. This contrasts junctional epithelium formation around erupting teeth where reduced enamel epithelial cells likely play a role. This is additionally supported by the formation of junctional epithelium after various periodontal surgical procedures; (2) junctional epithelium and oral sulcular epithelium are not necessarily "dental" structures, as they are found around implants, implying that neither tooth structure nor periodontal ligament are required for their formation; and (3) the formation of epithelial structures around implants involves normal patterns of epithelial macromolecular synthesis, indicating a basic host response to oral transmucosal structures. This study confirmed an earlier immunohistochemical study which used staining of keratins and desmoplakins in a total of six biopsies to show that gingiva and implant mucosa had similar staining patterns (79).

## **Connective Tissue**

In one paper, a direct contact of connective tissue with the implant surface in the supracrestal area of non-submerged implants in beagle dogs was described (69). It appeared, as was noted above in the study of Schroeder et al. (54), that the implant surface characteristics influenced the orientation of the collagen fibers. In addition, the orientation of the fibers may have been affected by the relative mobility of the tissues surrounding the implant. In a review paper (61) the authors reported a difference in orientation between gingival fibers of attached mucosa versus alveolar mucosa. The attached mucosa showed fibers arranged in both parallel and perpendicular directions, while the implants surrounded by alveolar mucosa had only parallel fibers. Rough surfaces in this study demonstrated connective tissue attachments with better-developed, perpendicularly-oriented dense fibers compared to the smoother surfaces. Another study confirmed that the fiber orientation, in this case around a machined titanium surface, was parallel to the abutment surface (80).

One study evaluated the soft tissue healing around 24 implants with different surface characteristics in a range from a very smooth surface to a rough surface (69). This study utilized non-submerged implants in beagle dogs which were examined by LM three months after placement. A peri-implant sulcus was demonstrated which consisted of a non-keratinized sulcular epithelium and a junctional epithelium. No epithelial proliferation to the alveolar crest was found. A direct connective tissue contact was observed that was 50 to 100 um wide and contained dense circular fibers without blood vessels. Outside this area was a less dense connective tissue with horizontal and vertical collagen fibers and numerous blood vessels. No differences were found in the connective tissues between the rough sandblasted, fine sandblasted, and polished surfaces. There was, however, more coronal bone for the rougher surfaces than for the smoother surfaces. The authors concluded that the epithelial structures around non-submerged titanium implants were similar to teeth. In addition, the different surface textures did not affect soft tissue healing, but did influence the location of the most coronal bone-to-implant contact.

These findings were confirmed in two studies that demonstrated a "circular ligament" of densely packed collagen fibers free of inflammatory cells running parallel around non-submerged titanium screws in maxillary bone of monkeys (81,82). The characteristics of the implant surface used in these studies were not given in these articles. The authors concluded, however, that keeping the implant non-submerged did not influence its survival, and that the smooth neck of the implant was surrounded by a narrow sulcus with junctional-like epithelium and few inflammatory cells (82). The collagen fibers originated from the bone crest, adjacent teeth, and epithelial papillae, and converged on the implant to form the circular fibers around the implant. Histochemical analysis revealed the presence of highly sulfated proteoglycans around the connective tissue fibrils. From this and previous studies, these investigators also suggested that rougher implant surfaces (using titanium plasma-sprayed implants) resulted in a more perpendicular alignment of the fibers than did the smoother surfaces, which resulted in a parallel arrangement.

## **Types of Soft Tissue**

One repeatedly discussed question in regards to the soft tissues around implants has been whether the presence of keratinized mucosa is required for implant success (83). Meffert et al. (84) provided an excellent review of the literature that was available on this topic prior to the early 1990's. Several more recent papers have addressed this issue. One study described the placement of 69 ITI implants in 33 elderly patients and followed them for five years (85). Each patient received two implants in the mandible to support overdentures. Approximately half of the implants were in mucosa and therefore had no keratinized tissue around the implant. This tissue was maintained in a healthy condition over the five years with minimal or no attachment loss and with an average pocket depth of approximately 3 mm. There was a tendency (which was statistically significant for certain areas) for the width of the keratinized mucosa to increase over time. Interestingly, these authors divided their patients between those who had been edentulous for a shorter period (implants placed within two years after the last tooth was lost) versus those who had been edentulous for longer periods (at least five years since last tooth loss). Patients who had been edentulous for longer periods of time had a significantly smaller zone of keratinized mucosa. This work in older overdenture patients supported the results of studies in partially edentulous patients who had implants placed in non-keratinized mucosa (86-89). Taken together, these studies suggested

that there was a similar prognosis for implants regardless of whether keratinized or non-keratinized mucosa was present. In a later paper by this same group of investigators, 30 patients with 60 ITI implants and overdentures were evaluated at three and twelve months post-implant-placement (90). Approximately 60% of the implants had 1 mm or less of keratinized mucosa on the buccal and lingual aspects of the implant. The results demonstrated that no significant change in width of the keratinized mucosa occurred over the year of follow up.

Another study compared implants placed in varying amounts of masticatory mucosa (91). One hundred seventy-one Branemark implants were examined in areas where 24% lacked masticatory mucosa, 13% had a width of < 2mm, and mobility of the tissue (i.e. non-attached mucosa) was found in 61% of the implant sites. Multiple regression analysis indicated that neither the width of the masticatory mucosa nor the mobility of the mucosa had a significant effect on the plaque control level or the health of the soft tissues as determined by bleeding on probing. The authors concluded that the lack of attached masticatory mucosa around an implant did not jeopardize the maintenance of soft tissue health.

In a study of peri-implant health in dogs, implants were analyzed with and without buccal attached gingiva and with and without plaque (92). Keratinized tissue was eliminated by excision and in some cases was replaced by a free graft around the implant. The study found that there were no significant differences between implants with or without buccal attached gingiva and that the presence or absence of plaque control made no difference. Also, the height of the supporting attachment apparatus had no effect. The placement of a gingival graft increased the width of the attached keratinized tissue. The authors suggested that since this study was performed in dogs, and only three dogs were analyzed, these results should be cautiously interpreted for humans.

Another study in animals focused on plaque-induced peri-implantitis in monkeys (93). This study showed that ligated implants resulted in significantly more recession and slightly more attachment loss when there was no keratinized tissue around the implants. The authors concluded that implants placed in non-keratinized mucosa have a greater susceptibility to tissue breakdown as a result of plaque accumulation than do implants placed in keratinized mucosa.

Reports exist in the literature that have described altered gingival responses when implants and abutments penetrate intra-oral skin grafts. For example, persistent proliferation of epithelial tissue was discovered in two out of five patients who received split-thickness skin grafts for mandibular vestibuloplasty (94). Traditional surgical and oral hygiene techniques did not prevent further proliferation of the tissues. Following removal of titanium abutments and replacement with custom gold abutments, the epithelial proliferation diminished.

### **Clinical Aspects of Soft Tissues**

Investigators have also focused on the traditional periodontal parameters describing the clinical condition of the soft tissues around implants. One paper described the soft tissues around healthy and infected Branemark implants (95). Biopsies were obtained from six patients who had implants with pocket depths > 3mm and bleeding on probing, but minimal bone loss and no mobility. Biopsies from another six patients came from implants that were not significantly infected, had < 3 mm of pocket depth and no bleeding on probing, but had > 3mm bone loss and implant mobility. Light microscopic analysis revealed features in the infected specimens that were consistent with a diagnosis of advanced gingivitis, while the specimens from mobile, but non-infected, groups lacked signs of inflammation. Inflammatory signs included more transmigration of inflammatory cells, a higher percentage of inflammatory infiltrate, proliferation of blood vessels with engorgement and dilatation, and significantly higher numbers of plasma cells and mononuclear cells. Furthermore, there were proliferation of the sulcular epithelium, akantosis, and papilomatosis. Electron microscopy of the infected specimens revealed features consistent with those of plaque-induced periodontitis, while the non-infected but mobile implant specimens included healthy connective tissue and vacuolae formation in the epithelium. The authors concluded that the soft tissues around "osseointegrated" implants reacted similarly to plaque as do the periodontal tissues. The fact that there was mobility (Periotest value>+10) in half of the implants, but no significant infection, suggested that these implants were not the same as non-mobile implants without infection (healthy controls) which were not examined in this study. Also, tissue specimens from infected and mobile implants were not examined. These are parameters that normally define failing implants and their inclusion would have helped with the interpretation of the findings of this study.

One prospective study that involved several centers evaluated the periodontal indices of 174 bridges on 460 Branemark implants (96). After three years, the cumulative implant success rate was 93.9%, and failures appeared to be concentrated in patients who had a high plaque index. Only slight bone loss was found in the second and third years of the study, and the plaque and gingivitis indices were similar between implants and abutments and teeth. Pocket depths (accessible in only one-third of the sites) were found to decrease over time. This descriptive study also found that the sum of the pocket depth and recession around the implant correlated with the radiographic level of marginal bone. However, conflicting information has been published for Branemark implants (97). These investigators concluded that "The absence of any statistically significant correlations between marginal alveolar bone level change and plaque index, and amount of keratinized mucosa, suggest an independence of this implant system from the expected relationship of these factors to the natural dentition." The authors summarized: "The weak correlations between the bone level changes and the various periodontal indices suggest that these traditional measures of periodontal health should not be relied upon to infer the state of bone-supporting implants."

A study in beagle dogs compared the soft tissue reaction to plaque formation around implants with abutments versus teeth (98). Teeth and implants were cleaned for four months and a biopsy was taken. After three additional weeks with no oral hygiene, specimens were again taken, including block biopsies. Specimens of healthy tissues around implants with abutments, as well as around teeth, revealed features in common, including a keratinized oral epithelium, an approximately 2 mm long junctional epithelium, and an underlying connective tissue devoid of inflammatory cells. The differences between the implants with abutments and the teeth were predominantly in the direction and density of the collagen bundles. Specimens from implants with abutments and teeth that had no oral hygiene for three weeks both revealed subgingival plaque (similar amounts) and an inflammatory infiltrate. Both lesions were characterized by decreased collagen content and a dense accumulation of inflammatory cells. The density of fibroblasts was the main difference between the inflamed dentogingival and implantogingival tissues, with the density around the implants the same as that found around healthy implant tissues, while the density of the dentogingival tissues in inflamed conditions was significantly decreased. In spite of these differences, the authors concluded that both implantogingival and dentogingival tissues had a similar reaction to plaque formation, both qualitatively and quantitatively, suggesting that the barrier function of both types of tissues was the same. This was confirmed in a later study in monkeys in which peri-implant infections were induced by ligature placement (99).

In partially edentulous patients, evidence suggested that no significant differences existed in the distribution of bacterial morphotypes around implants and teeth (100). Significant differences were found in plaque composition between samples taken from fully edentulous patients and plaque from teeth or implants of partially edentulous patients. The authors suggested that the results indicated that "...teeth may serve as a reservoir for the bacterial colonization of titanium implants in the same mouth.". These findings confirmed an earlier study which examined crevicular fluid and plaque composition and which also found similarities between teeth and implants in partially edentulous patients, but differences from implants in edentulous patients (101).

Another report explored microbial differences between successful and failing implants and between the flora in partially edentulous patients and fully edentulous patients. Facultative anaerobic cocci predominated low bacterial counts from healthy implant samples. Spirochetes and gram-negative anaerobic rods in high numbers are found in samples from failing implants. Fully edentulous implant patients contained fewer periodontal-associated pathogens than did implant samples from partially edentulous patients. The authors concluded that their work confirmed "that spirochetes are not commonly associated with successful implants" (102,103).

Another study examined 18 gingival specimens from around clinically healthy implants and nine similar specimens from implants which clinically had overt signs of inflammation (104). Histologically, all the specimens had some amount of inflammation, but the clinically inflamed sites had a much greater inflammatory infiltrate. Immunohistological analysis included the proportion of T (50-60%) and B (40-50%) lymphocytes, the CD4:CD8 ratio (1.6:1 and 2 for healthy and inflamed sites, respectively), the number of Langerhans cells (no significant differences between groups), and the HLA class II positive cells (healthy and inflamed specimens were significantly different). Biopsies were also taken from tissues between the implants. Again, no differences were found in the infiltrates from clinically healthy implants compared to inflamed implants. The authors suggested, from their immunohistologic analysis, that the gingival lesion

around clinically healthy and inflamed implants was stable and well-controlled. The inflammatory lesion consisted of a lymphocyte/macrophage infiltrate with only a few plasma cells. The authors speculated that as the lesions increased to where they became clinically significant, the proportion of T and B cells and T cell subsets remained relatively constant. Although T cells dominated the inflamed lesions, the substantial number of B cells with a lack of plasma cells suggested that activation of the B cell population was controlled. This was in addition to the finding of consistent CD4:CD8 ratios of between 1.5 and 2.0:1, a ratio found in delayed-type hypersensitivity reactions in the skin, peripheral blood and regional lymphatic tissue, putative stable periodontal lesions, gingivitis in children, and experimental gingivitis lesions. From this, the authors suggested that gingivitis associated with osseointegrated implants was well-controlled immunologically and represented a stable condition.

## Summary

A review of the literature on the supracrestal soft tissues around endosseous dental implants revealed that many structures and features of non-inflamed soft tissues are analogous to non-inflamed gingiva around teeth. These include:

### **Structures.**

- (1) oral stratified squamous epithelium
- (2) sulcular non-keratinized epithelium
- (3) non-keratinized junctional epithelium
- (4) soft connective tissue contact
- (5) vascular components

### **Features.**

- (1) basement membrane
- (2) rete pegs
- (3) connective tissue papillae
- (4) collagenous stroma
- (5) collagen and non-collagen glycoproteins
- (6) desmosomes and hemidesmosomes
- (7) structural and non-structural proteins
- (8) immune cells

Thus titanium, or more properly, titanium oxide, does not appear to significantly effect epithelial cell structures or the formation of epithelial structures around transmucosal materials. This suggests that the location of the epithelium (in this case, oral gingival epithelium) is more influential in determining the morphology of the epithelial components than is the substrate (implant versus tooth). Evidence also exists that around titanium abutments, the major connective tissue fibers run parallel to the long axis of the implant. Around non-submerged one-part implants, the connective tissue forms a non-vascularized circular scar-type structure surrounded by a less dense vascularized connective tissue. Thus, the epithelial components around implants appear to be consistent with epithelial components around teeth, while the connective tissue, although having a similar composition, has a dramatically different spacial orientation.

## THE HARD TISSUE-IMPLANT INTERFACE

### Introduction

Endosseous implant therapy is dependent on direct contact of the implant with bone. Much of the implant literature examined the parameters of achieving direct bone contact on a predictable basis and under varying anatomical and prosthetic conditions. Many other studies examined the consequences of direct contact of bone with the implant. One difficulty in this area was the absence of information to allow a determination of how much bone-to-implant contact is clinically necessary or is, in fact, ideal. Histometric studies have determined the amount (usually expressed as a percentage of a defined surface area of the implant) of bone-to-implant contact, while other studies have determined the amount of torque required to remove an implant, or the amount of force required to pull or push the implant out of bone. In addition, many of the studies have examined ways to increase these parameters. These approaches primarily involve altering the surface and/or shape of the implant. A general perception exists that more bone-to-implant contact is better than less contact, although no data supports this. It is likely that the required (as well as the optimum) amount of contact varies depending on quality and quantity of bone, type of prosthesis, and amount and direction of occlusal forces. It is even possible that, under certain conditions, one may not want the maximum possible bone-to-implant contact. A question that can be raised is whether, in edentulous cases where mandibles have fractured after implant placement, or in cases of fractured implants, would the fracture have occurred if there was less bone-to-implant contact, implying more flexure between the bone and implant? Another question in this area is whether two implants with



30% bone-to-implant contact, for example, provide the same functional support as one implant with 60% bone-to-implant contact?

A further complicating factor in studying bone-to-implant contact is that the quality and quantity of oral bone greatly varies within patients as well as between patients. Superimposed on this complexity is the fact that most of the animal models used to study bone-to-implant contact have qualities and quantities of bone that are different than those of humans. For these reasons, experiments that have described bone-to-implant contact in the oral cavity of animals are more relevant than studies in long bones or other extra-oral sites. However, the extra-oral bone does allow for comparisons to be made between implants.

### **Direct Contact of the Implant to Bone**

Branemark et al. (53) described the conditions necessary for direct contact of the implant to bone. Light microscopy of dog hard tissues after the implant was removed from the specimens revealed bone adjacent to the impressions left by the surface of the removed implant. No connective tissue was found between the bone and the implant. A compact bone capsule around the implant was described with lamellae near the implant threads. Marrow space was often observed at the implant surface, but no inflammatory cells or other tissue reaction was noted. This was also true for bone in the maxilla, which was noted to be of lower density. Traumatic placement of the implants resulted in histological tissue damage and defects, while loading the implants resulted in remodeling of bone. In a review article, considerations for achieving integration of titanium implants in bone were described (111). This review was based upon results obtained from an optical titanium chamber placed in rabbit tibia where bone-to-implant contact can be transilluminated, i.e. vital microscopy. These studies led to the observation that the titanium chamber became integrated with the bone. Immediately after the chamber was placed in bone, vascular activity was increased and bone turnover was induced at the interface of the chamber. Prior to bony ingrowth, angiogenesis occurred. Capillary loops were first formed and, after approximately three weeks, a well-developed vascular network was found. Bone healing began during the first week after implant placement in this model, peaked at three to four weeks, and minor remodeling occurred at six to eight weeks, which was maintained for a year or more. If surgical trauma at time of implant placement occurred, the vascular healing, and subsequently the osseous healing, were incomplete and connective tissue proliferation was found. The concept was reviewed that osseointegration (4) was defined as direct contact of Haversian systems in bone with the implant surface at the light microscopic level. Other articles by this same group of investigators elaborated on the bone-to-implant interface and the effect of healing time on this junction (112-114).

Scanning and transmission electron microscopy (TEM) of a removed human implant (after 7.5 years) revealed a direct bone-to-implant interface (115). Collagen fibers that had the appearance of Sharpey's fibers were described in contact with the titanium surface. Auger electron spectroscopy revealed a thickened oxide layer (from 50 Å to 2,000 Å) on the implant surface. The biocompatibility of titanium, due to its oxide formation, was reviewed in comparison to other metals and the preparation of the surgical bed was emphasized. The critical temperature for bony necrosis, based upon rabbit tibial bone, was 47°C after heating for one minute (116,117). Heating bone to 50° for 1 min or 47° for 5 min caused bone resorption and replacement with fat cells. Heating bone to 47° C for 1 min caused fat cell injury, but resulted in an inconsistent bone injury. The authors concluded that "It seems likely that 47° C is the border temperature for the occurrence of morphologically evident bone tissue damage." These experiments provided the basis for cooling the osseous preparation and using slow speed drills during implant placement surgery. It must be remembered, however, that (1) these experiments were performed in rabbit tibia; and (2) the bone was heated in these experiments and may not be similar to what occurs when an implant drill is responsible for generating heat in oral bone. The prevention of premature loading was also discussed in relation to an allowance for differentiation of mesenchymal cells and osseous precursor cells, callus formation and creeping substitution (i.e., all cellular and tissue processes required to achieve direct bone contact).

In a review paper on the implant-to-bone contact, an earlier paper referred to the intimate contact of bone with the implant surface as 'functional ankylosis', while a later publication was quoted as defining, 'osseointegration' as "...a direct structural and functional connection between ordered, living bone and the surface of a load-bearing implant..." (61). By EM measurement, the bone was observed to be approximately 20 nm from the surface of the implant and oxide layer. Consistent with all bone extracellular matrices, this layer was thought to contain chondroitin sulfate glycosaminoglycans. It was further pointed

out that studies have indicated that the implant surface had a profound effect on bone apposition, both chemically and physically. For instance, bone formation in rats adjacent to the implant surface was three times faster around a plasma-sprayed titanium surface than against a smoother machined titanium surface. In addition, other studies indicated that the amount of bone contact to the implant surface was greater around rougher implant surfaces than around smoother implant surfaces, and that the strength of the bone-to-implant bond was greater in the rougher-surfaced implants (69,118).

### **Light Microscopy - Titanium**

Submerged, commercially pure, machined screw (Astra) implants in dogs that had abutments placed four months after implant placement were examined histologically after six months (67). Following fixation and demineralization, the implants were removed and the specimens prepared for embedding and cutting. All implants were stable and, based on the four most central threads, had an average of 61.3% of bone contact with the surface at the LM level. The implants at the coronal margin were in contact with compact bone while the more apical implant areas were in contact with spongy bone. In the spongy areas, the implant surface was found to contact both bone and bone marrow. Both compact and spongy bone appeared normally vascularized with uniformly-spaced lacunae. No osteoclasts or signs of an inflammatory reaction were observed in the sections and higher magnifications of the bone contact area revealed condensed small cellular fragments adjacent to the bone surface.

Machined experimental titanium screw implants have been examined in rabbit bone histologically and biomechanically after six weeks, three and six months (119). Implants were placed in rabbit tibia (metaphysis) and knee joint femoral intra-articular heads. These sites were chosen to compare more cortical bone sites with more cancellous bone sites, respectively. Many of the intra-articular implants were covered with cartilage at six weeks and the cartilage remained at the three and six month time periods. The effect of the cartilage on the healing and on the removal torque is unknown and makes interpretation for oral implants questionable. The authors stated that synovial fluid may have been in contact with the implant surface and may have altered healing around the implants placed in the joints. Statistical analysis was performed using Student's t-test, in spite of having data from three time points. An ANOVA is usually indicated under these conditions so that the effect of time can be calculated for the comparison data. In this study, bone area in all threads was measured. Torque removal forces increased with time in implants placed in the more cancellous sites, whereas no increase was found over time for removal torque with the implants that were placed in more cortical sites. Additionally, more bone was observed in the threads of the implants placed in more cortical sites (tibia) versus the more cancellous sites (subchondral) and the increased amount of bone corresponded to higher removal torque values.

A significant difference in removal torque between tibial and articular sites was found after six weeks of healing. The authors concluded that torque removal forces for titanium implants were dependent on the amount of compact bone surrounding the implant. These results were supported by findings in rabbit tibia and femur that demonstrated increased removal torque values for implants with greater bone-to-implant contact (achieved as a function of time) (114). In this study, a time-dependent increase of removal torque was demonstrated. The authors suggested that the observed time-dependent increase in removal torque was due to increasing amounts of bone-to-implant contact and to an increased bone quality (i.e. more mature) at the bone-to-implant interface. In the Sennerby study,<sup>118</sup> a time-dependent increase in removal torque was not observed with the implants placed in tibial sites in spite of a progressive increase in bone contact in the threads. Also in the Sennerby study, the authors speculated (119) that early bone maturation had already occurred in their study at their first examination (six week time point) compared to the latter study (114), in which the time points examined included three weeks, one, three, six, and twelve months of healing. Only a small change in removal torque was noted in the Sennerby study between three and twelve months (119). More comprehensive statistical analysis that included the effect of time in both studies would have helped to clarify the results.

Implants with a titanium plasma-sprayed surface (IMZ) were examined in rabbit femurs (120). Histological and biomechanical testing were performed two months after implant placement and the results were compared to implants placed in artificial bone defects and bone defects with a bone graft. The mean shear strength of the bone-to-implant contact in the control group was  $2.61 \pm 0.68$  MPa, with approximately 55% of the implant surface in contact with bone and the remainder in contact with bone marrow. Histologically, bone formation was the most advanced in the cortical areas at the coronal aspect of the implant compared to the bone interface in the more apical medullary bone.

A recent study evaluated titanium oxide-blasted implants with and without hydroxyapatite (HA) coating to machined control implants in rabbit tibia after three and twelve weeks of healing (121). Both screw and cylindrical implants were examined. The titanium oxide-blasted implants had both significantly higher bone-to-implant contact and significantly greater removal torque values than did machined implants. The differences were more pronounced at the early (three week) time point relative to the later (twelve week) time point. The HA-coated implants had a crystallinity of 88.1% and the results indicated that no HA-coated implant had a uniform appearance. In some of the more apical areas of the screw-shaped implants, no HA was found. The authors concluded that "...it was possible to influence the anchorage of implants by altering the surface structure morphology."

The effect of tapping the osseous implant site prior to placement of the implant has been compared to no tapping prior to placement of a screw-shaped implant (122). This is important, since clinicians often place screw-shaped implants in more cancellous bone without first tapping the site. This study involved only two monkeys and HA-coated implants. Histologic analysis (after three months unloaded) revealed that all implants had healed with direct bone-to-implant contact. No differences were observed histologically or histometrically between implants placed with or without prior tapping of the bone. The HA coating was uniform and showed no signs of resorption. These results were in contrast to a previous investigation by the same group (123), which showed that by not tapping prior to the placement of titanium oxide-coated and non-coated titanium alloy implants, fibrous connective tissue formed between the bone and the implant. If the site was tapped prior to implant placement, direct bone apposition to the implant occurred. Interpretation of the earlier study must be viewed with caution, in that the non-tapped osseous preparations appeared to result in a farther distance from the bone to the implant surface than did the sites that were tapped. This type of experiment may more likely indicate bone healing over specific distances rather than the result of tapping. Based on both studies, the authors concluded that the determining factors were the surface characteristics of the implant.

#### **Light Microscopy - Hydroxyapatite (HA)**

Four HA-coated unloaded titanium implants (Calcitek) were histologically examined in pig tibiae after four months of healing (124). The implants were placed so that one-half of the implant was in cortical bone and the remainder was in medullary space. Light and confocal laser scanning microscopy revealed that HA resorption on the implant surface was minimal in areas embedded in cortical bone, whereas greater resorption and dissolution were observed in medullary spaces. The implant surface in the medullary space was lined by a fibrous tissue capsule, and in some areas a thin basophilic material was observed next to the HA surface. In some sites, the HA coating was absent or detached from the metal surface, dispersed in extracellular fluids, or covered by soft tissue with mononucleated or polynucleated macrophages. The authors concluded that "...a high rate of deterioration in the HA was present in the investigation..." (which also included an analysis of HA blocks in rabbit tibiae after two months) and that the rate of resorption may be dependent on the bone biologic environment.

In a later study by the same investigators (125), 20 HA-coated (Sustain) implants were placed in rabbit femurs and examined after six months of unloaded healing by light and laser scanning microscopy. A tight (70%) contact of bone to the HA surface was observed in all specimens. In some specimens, the bone was in direct apposition with the HA, while in others a basophilic unmineralized material was observed between the bone and the HA. The staining characteristics of this material were similar to material around osteocyte lacunae. Laser scanning microscopy revealed fluorescence in many areas of the interface, inside the HA coating, and in osteocyte lacunae. The authors reported that their findings were similar to an earlier study (126), which observed a thin electron-dense layer of organic material at the bone-HA interface using TEM of HA-coated implants. This same material was also observed at the lining of the osteocyte lacunae and periphery of the bone resembling the lamina limitans (consisting of non-collagenous matrix proteins without bone) between mineralized and unmineralized bone matrix. The authors suggested (without quantification) that the unmineralized layer at the bone-HA interface was thicker in areas of bone deposition and speculated that this "...could be the result of biodegradation of HA in the body..." or the formation of the last layer of osteoid by the osteoblasts. The authors stated that they had never observed cells between the bone and the HA surface, and had only seen osteocytes in lacunae very near the interface.

The implant-to-bone interface around three commercially available implants (IMZ, Integral and Branemark) was evaluated in dog mandibles after 12 weeks of unloaded healing (127). Each implant had a

different surface: IMZ had a titanium plasma-sprayed surface, Integral had an HA surface, and Branemark had a machined titanium surface. No acute inflammatory reaction was observed around any of the implants and foreign-body giant cells were found in bone marrow close to the implant surface. On occasion, these cells around the HA-coated implants contained HA particles. In addition, a 0.5 to 2.0  $\mu\text{m}$  dark staining amorphous zone was observed on the surface of the HA-coated implants. The authors speculated that this material was similar to the resting lines between layers of bone. The HA-coated implant had significantly more bone contact with the implant surface (71.35%) than did the titanium plasma-sprayed surface (54.96%). Both of these surfaces had greater bone contact than the smoother, machined titanium screw surface (45.66%). Histologically, the machined screw surface had extensions of trabeculae into the threads of the screw, while the titanium plasma-sprayed cylinder demonstrated some trabeculae extensions as well as bone in a lamellar pattern with parallel dense layers along the implant surface. In bone 2 mm from the implant surface, small differences were found between the three implant surfaces, with the machined screw having the least and the HA surface having the greatest amount of bone. The authors stated that their results were consistent with an earlier study (128), which found that loaded HA implants had 66.3% bone contact to the surface while unloaded HA implants had 82.6% bone contact. Grit-blasted implants had 50.2% contact whether unloaded or loaded. These results were also consistent with the results of a study in dog femurs that showed that HA-coated screws had large areas of bone contact along the surface compared to titanium screws, which revealed only sparse areas of bone contact (129). The investigators concluded that the bone was more dense around the HA-surfaced implants and that due to the more lamellar bone along the HA and titanium plasma-sprayed surfaces, "...bone growth around these implants is different and apparently more lamellar than that seen with the screw-type design..." (127).

Cylindrical HA-coated and titanium plasma-sprayed implants (commercially available IMZ implants) were compared in a study in rabbit femurs after six months of healing (130). Histometric analysis of bone-to-implant contact demonstrated significantly greater bone around the HA-coated implants than around the titanium implants. Clinically, all the implants appeared healthy and stable. The results indicated that the HA coating was not uniform and that the titanium plasma-sprayed implant surface was irregular. Both implants had areas of direct bone-to-implant contact, with osteocytes close to the implant surface, and both implants had areas of soft tissue contact. All HA-coated implants had areas where no HA was found. The percentage of bone contact along the entire surface on HA-coated implants was 75.9% and 59.9% for the titanium plasma-sprayed implants, and this difference was significant. There was also a significant difference between the HA-coated and titanium plasma-sprayed implants (80.2% and 69.4%, respectively) when a 1,000  $\mu\text{m}$  section of the implant surface corresponding to that part of the implant in the cortical coronal bone was examined. The authors concluded that the "...study demonstrates that hydroxyapatite has a beneficial effect on interfacial bone formation adjacent to unthreaded, cylindrical implants, at least after 6 months of follow-up."

An earlier study by the same investigators compared threaded HA-coated and uncoated commercially-pure implants in rabbit tibial metaphysis (131). These implants did not have restorations placed, as this was a study in long bones. However, the authors described these implants as "semiloaded", since after surgery the animals were not restricted and could place weight on the legs. Histometric analysis at six weeks of healing indicated no significant difference between bone contact at the implant surface (65% for HA-coated implants, 53% for uncoated titanium). At one year, significantly more bone-to-implant contact was found around the uncoated implants (59% HA-coated versus 74% for uncoated titanium). No standard deviations were reported for the data and a Student's t-test for paired samples was performed rather than an ANOVA, which would have accounted for the time factor and could have influenced the findings. Areas of soft tissue were observed between the bone contacting the implant surface. The investigators stated that although the bone-to-implant contact was calculated for the entire implant, the three best consecutive threads of each implant "...were then selected for statistical calculations.". These threads were reported as representing the condition at the cortical passage. The authors stated that the implants in this study were "...mainly subjected to compressive loads.". The relevance and bone remodeling under these anatomical and study conditions in relation to oral bone is not known.

Loaded HA-coated and grit-blasted (with aluminum-oxide) titanium alloy implants have been compared in dog mandibles after one and ten months (128). The HA coating was 75  $\mu\text{m}$  thick and the grit-blasted surface had 25 to 50  $\mu\text{m}$  irregularities. Implants in the mandible were 13 mm in length and

radiographically appeared to penetrate the mandibular canal. Implants were exposed after two months and abutments and crowns were placed. No oral hygiene was performed. Two dogs were sacrificed at each time point. Three prostheses were lost in the one-month dogs, so the restorative procedures were changed for the ten-month animals. Crestal bone loss and pocket depths were not significantly different between the two types of implants, however, the HA-coated implants had significantly greater amounts of bone in contact with the implant surface (66.3%) than did the grit-blasted titanium alloy implants (50.2%). Interestingly, although "...the implants were all countersunk 1 mm beneath the alveolar crest...", crestal bone morphology was 0.5 to 1mm apical to the top of the implant, which demonstrated a large amount of remodeling. Fluorescent labeling of bone was similar around both types of implants, which revealed labeling of Haversian systems away from the implant-bone interface and no labeling at the interface. The findings in this study extended earlier findings on unloaded implants by the same investigators (132).

Histologic evaluation of HA-coated and non-HA-coated implants in dogs confirmed the above findings (133). The HA coating resulted in significantly greater bone height formation and maintenance than in the non-coated implants of similar design. In addition, after over a year and a half of loading, significant resorption of the HA coating was found. Similar findings occurred in a study in rats (134). HA-coated implants had more bone-to-implant contact than did uncoated implants, and in some bone-free areas the HA was missing from the surface and macrophages were seen along the implant surface. A study in the tibia of rabbits also demonstrated that HA-coated implants induced more bone in the medullary cavity than did titanium screws, but loss of coating was found after three months of healing (135). Another report in rabbit tibial metaphysis found no difference between the bone-to-implant contact of HA-coated and uncoated titanium screws after six months of healing (136). These investigators stated that while there was abundant documentation of the advantage of HA coatings for bone contact for cylindrical implants, their data suggested that this was not as certain for screw-shaped implants.

Titanium and aluminum-oxide ceramic implants have been examined in dog mandibles (137,138). After one year of loading, titanium implants (root-form and blades) had significantly more bone apposition (between 50-65% of the surface) than did the ceramic implants (approximately 42% surface contact). Many variables and configurations were present, so interpretation of the results was complicated and quantitative analysis was limited by the small numbers. The failure rate was high compared to other dog studies, in that eight implants were mobile (mobile ceramic implants comprised 25% of the implants at the three evaluation periods) and one out of 72 implants fractured. Some of the data analysis included mobile implants, which are normally considered failures in other studies. The authors pointed out that in their study the values for the percentage of bone contact were less than the very high percentages (81-84% contact) reported in a 1992 study (139), and suggested that this was possibly due to the fact that the earlier study only analyzed certain portions of the implant. It is likely that the porous aluminum-oxide ceramic implants in this study and the HA ceramic implants in other studies cannot be compared. A published review of HA-coated implants suggested that all commercially available HA coatings on implants differed in biochemical composition. In addition, correlations were found between biochemical composition and dissolution profiles for the HA coatings (140).

### **Electron Microscopy**

Epoxy-resin replicas of cylindrical titanium implants have been examined by both light microscopy (LM) and transmission electron microscopy (TEM) (141). The implants had a titanium plasma-sprayed apical portion and a smooth coronal collar and were placed as non-submerged implants in dogs for three months. Gingival fibers ran parallel to the implant surface with no insertions into the smooth or rough implant surface. The inner-most connective tissues had no blood vessels, with vascularity increasing in the outer connective tissue zone. Undemineralized and demineralized sections revealed that the bone was intimately adapted to the implant surface, with no intervening space. Occasionally, thinner and less densely packed collagen fibers were observed adjacent to the implant surface, but no fibril-free space could be detected. The authors concluded that "...no evidence was found for the presence of a presumptive proteoglycan layer separating the bone from the implant."

Using EM, one study examined the bone-to-titanium interface using a technique that embedded the bone and implant specimen in a low-viscosity resin prior to removal of the specimen for sectioning (as contrasted to removing the implant prior to embedding) (142). Three types of material were observed. One was a thin, compact, amorphous, electron-dense layer; the second was a broad layer of dense, amorphous granules; and the third was a combination of the first two. Utilizing two other EM techniques

(scanning-transmission electron microscopy-energy-dispersive x-ray analysis (EDX) and field emission scanning electron microscopy-EDX dot-mapping), titanium, phosphorus, and calcium were detected at the bone-to-implant boundary. The surface characteristics of the commercially pure implants were not described in this study and the implants were placed in calvarial bone.

Another study examined the bone-to-implant contact around unloaded implants placed in the mandibles of dogs after five months of healing (143). Steri-Oss implants were placed with an etched, commercially pure titanium surface in the apical portion of the submerged implant and a smooth polished coronal portion. Some implants were placed with the abutment connected at the time of implant placement (a two-part non-submerged approach). Four dogs had eight implants and undecalcified specimens were examined by LM and transmission and high-voltage TEM. An electron-dense material was observed between the bone and the implant surface that was approximately 50 nm (range 10 to 100) thick. Similar electron-dense material was found on the outer aspects of the lacunae supporting osteocytes and within canaliculi. Osteocytes in lacuna with cellular processes often reaching the implant surface through canaliculi were observed, as was a parallel-oriented (100 to 200 nm from the implant interface), densely mineralized collagen fiber matrix. Both approaches to implant placement resulted in close apposition of bone to the implant surface, with the morphology of the interface being similar on histological examination. Sample preparation for EM analysis involved removal (by cryofracture) of the implant from the cut block sections. Although the impression of the implant surface was revealed by this technique, it was not certain whether the interface material was altered or partially removed by the technical preparation. In addition, although the authors stated that the results "...demonstrated a dynamic bone interface to the implants...", one must remember that histological specimens are a two-dimensional picture of one point in time, and that on-going processes or tissue turnover (all dynamic or changing events) can only be hypothesized by what can be observed on the static pictures of tissue specimens.

These same investigators made many reports on the bone-to-implant contact of various endosseous implants placed in a variety of clinical situations (137,138,143-148). Most of these reports involved the dog model and some form of microscopy, including Nomarski differential interference microscopy, transmission and high voltage TEM, and scanning electron microscopy (SEM). In one of the more recent papers from this group (138), 72 implants were placed in 18 dogs and loaded for up to one year. Forty-eight implants were used as anterior bridge abutments. The authors discussed the bone-to-implant contact as a dynamic interface with a variety of interactions. Some investigators have described the bone-to-implant interface as (1) consisting of a mineralized collagen fiber matrix directly contacting the implant (141), or, as this group of investigators (as well as others) has shown, (2) an electron-dense thin (20 to 50 nm) coating separating the bone from the implant, or (3) a finely fibrillar mineralized matrix (100 nm) separating the bone from the implant. Because the interface is dynamic, the authors speculated that any of these types of interactions may be observed. Unmineralized areas also existed around the implant and this paper demonstrated that osteoblasts were routinely found at the implant interface. This zone varied in dimension from only an osteoid appearing zone to a four cell-layer-thick area. Also observed were unmineralized collagen, other proteins, and a finely fibrillar matrix. The osteoblasts were parallel to the collagen fibers and extended cell processes through the unmineralized connective tissue matrix to the mineralized collagen matrix of the supporting bone. This same group also described osteocytes in lacunae that have numerous cell processes that extended into the mineralized bone matrix through interdigitating canaliculi and also extended directly to the implant surface (147). These osteocyte processes terminated at the implant surface in a "funnel-like" morphology.

### **Surface Characterization**

A number of studies compared implants with different surfaces as regards the hard tissue-to-implant interface. For example, removal torques and bone-to-implant contact were histometrically compared around polished and rough commercially-pure titanium implant screws after six weeks in rabbit knee joints (118). The data demonstrated that the rough-surfaced implants had significantly higher removal torque (26.4 Ncm versus 17.2 Ncm, respectively) than did the smooth-surfaced implants. The authors stated that "...several investigations indicate that a rough-surfaced implant may be a better candidate for implant integration than a smooth implant.". The authors also quoted earlier studies which showed that rough-surfaced titanium implants developed bone contact earlier than smooth implants (115), and that smooth implants exhibited more fibrous tissue encasement, while similarly-shaped, rough-surfaced implants had more direct bone-to-implant contact (149-152). The smooth-surfaced implants in

this study were electropolished and had surface irregularities of approximately 10 nm compared to implants without electropolishing, which had irregularities of approximately 1,000 nm. Drill speeds "...greater than 2,000 rpm were avoided..." in this study and the implants were countersunk below the cartilage. All implants were stable at sacrifice and no macroscopic adverse tissue reactions were observed. Light microscopic analysis indicated "no clear differences" in the bone-to-implant contact (approximately 60%) between implant types with fibrous tissue at the apical ends of the screws, which the authors speculated was due to overdrilling. The authors concluded "...the present study has demonstrated the importance of the surface roughness for a proper bone interlock."

In a direct comparison of surface characteristics of similarly-shaped implants, rougher implant surfaces had greater bone-to-implant contact than smooth-surfaced implants (153). Seventy-two cylindrical implants with six different surfaces were compared in the metaphyses of the tibia and femur of six miniature pigs at three and six weeks of healing. Electropolished and medium grit-blasted implant surfaces had the lowest percentage of bone contact, in the range between 20% to 25% in the more cancellous pig bone. Large-grit sandblasted and titanium plasma-sprayed implants had 30% to 40% mean bone contact, while large-grit sandblasted and acid attacked (mean 50% to 60%) and HA-coated (mean 60% to 70%) had the greatest bone-to-implant contact. However, the HA-coated implants consistently revealed signs of resorption of the surface. The authors concluded that "...the extent of bone-implant interface is positively correlated with an increasing roughness of the implant surface."

These studies confirmed earlier, pivotal work on osseous integration of endosseous implants (149). These investigators systematically studied mechanical and histological factors affecting bone apposition to implants. Twelve types of implants were examined after 32 weeks of healing in dogs. Mechanical testing by push-out tests revealed that interface shear strength and stiffness were not significantly affected by implant surface composition. Implant surface texture was the only parameter studied that affected bone apposition. For each elastic modulus group, the rough-surfaced implants had greater strengths than the corresponding smooth-surfaced implants. Histologic evaluation revealed "...the roughened implants exhibited direct bone apposition, whereas the smooth implants exhibited various degrees of fibrous tissue encasement."

Another study compared machined, grit-blasted and HA-coated cylindrical implants in dogs after one, four, and ten months of healing (154). Histologic results indicated that the machined implants had a 200 to 400  $\mu\text{m}$  thick fibrous tissue encapsulation, while the grit-blasted implants had a 100 to 200  $\mu\text{m}$  fibrous interface at one month which decreased to 15 to 30  $\mu\text{m}$  at ten months. The HA-coated implants demonstrated direct contact of the surface with bone as early as one month, with 70% contact at four months and 90% contact at ten months. Lamellar bone contacted the HA-coated implant, while the uncoated implants had only 50% of their surface contacting bone. No evidence of HA resorption was found in the histological sections. The authors suggested that 'osseointegration' might be better defined as two terms: 'adaptive osseointegration', referring to osseous tissue approximating the implant surface without soft tissue in between at the light microscopic level; and 'biointegration', defined as a direct biochemical bond of the bone to the implant surface at the electron microscopic level.

A more recent paper confirmed the advantage of an implant with a rougher surface compared to an implant with a smoother surface (155). This study, also in rabbit bone, demonstrated that after 12 weeks of healing, a statistically higher removal torque was required to unscrew titanium screw-shaped implants with either a 25  $\mu\text{m}$  (20 implants) or 75  $\mu\text{m}$  (10 implants) aluminum oxide particle-blasted surface compared to a titanium screw (30 implants) with a turned (i.e., machined) surface. In femoral implants, 75  $\mu\text{m}$  particle-blasted surfaces required 32.7 Ncm compared to 28.6 Ncm for machined-surface implants. With implants placed in the tibia, 35.4 Ncm was required for 25  $\mu\text{m}$  particle-blasted surfaces compared to 29.2 Ncm for machined implants. Histometric analysis over all threads, i.e. the surface of the implant, revealed that greater bone-to-implant contact for the 25  $\mu\text{m}$  particle-blasted implant surface was found than for the machined surface. If only the three best consecutive threads were examined, no difference was found between the implants, indicating that this measurement may be misleading if it is the only one taken. If the bone was measured within the threads only, the implants with a turned surface had more bone contact than did the 25  $\mu\text{m}$  particle-blasted implants. Considering that the removal torques were significantly less in the implants with the turned surface, this finding indicated that measuring bone within the threads was not relevant to biomechanical strength of implants as determined by removal torque values. It is possible that an alteration of the pitch height could result in a higher correlation between removal torque forces and the measurement of bone between the threads.

Another recent study demonstrated that surface roughness and local peak spacing were two important surface parameters for achieving mechanically stable implant fixation (156). Three commercially used implant materials were examined, including blasting, high temperature acid etching, and HA coating. Miniature pigs with trabecular knee bone sites had cylindrical implants placed for 12 weeks. An excellent correlation was found ( $r^2=0.90$ ) between the average roughness of the implant surface and the push-out failure load.

In a paper that histometrically compared the removal torque and bone-to-implant contact of commercially pure smooth (machined) titanium and niobium implants, it was shown that no significant differences were found between the implants as regards the amount of bone-to-implant contact, but that a significantly higher removal torque was required to unscrew the niobium implants (157). This study was performed in rabbit long bones. The titanium implants had a smoother surface than the niobium implants, as determined by SEM. The force required to remove the implant was significantly greater for the niobium implant than for the smoother titanium implant (32.9 versus 25.3 Ncm). Histologically, both implants appeared similar, with mature bone in the cortical region and areas containing macrophages and multinucleated giant cells in areas where no bone was found adjacent to the implant. Bone-to-implant contact of the three best consecutive threads was not significantly different between the implants (41.1% niobium, 37.2% titanium) after three months of unloaded healing. This was usually in the cortical region and skewed the data to the greatest percentage of contact. Again, the significant difference in removal torques without a difference in bone-to-implant contact in the three 'best' consecutive threads indicated that the analysis of only three threads could be misleading, since studies indicated that removal torques were related to bone-to-implant contact. The authors suggested to the authors that the significant difference in removal torques could be due to metal biocompatibility or surface topography. However, many other studies (118,132,141,149,153,154,158-160) have clearly indicated that rougher implant surfaces have more bone-to-implant contact and/or require greater forces to be removed from the bone than do implants with smoother surfaces.

A more recent study also found more bone-to-implant contact around rough-surfaced implants. Standard machined (smooth) screw implant surfaces were compared to titanium oxide-blasted (rough) screw implant surfaces in the maxilla of dogs (Tioblast, Astra Tech) after two and four months of healing (161). The roughened surface resulted in "...surface irregularities smaller than 100  $\mu\text{m}$ ". The implants were placed with drill speeds up to 2,000 rpm and the implants were all submerged. Bone-to-implant contact was measured as the percentage of contact in the three best consecutive threads. The bone-to-implant contact around the rougher-surfaced implants went from 40.5% at two months to 65.1% at four months of healing. The smoother-surfaced machined implants had 39.4% contact at two months and was not changed at four months (42.9%). The difference between implant types was significant after four months of healing. Qualitatively, bone around both implants appeared histologically similar, with areas of both bone formation and resorption. The authors stated that their results confirmed the findings of others (131,153,162) that implants with a rougher surface have more bone contact than do implants with a smoother surface. Additionally, the authors pointed out that other studies have indicated that rougher implant surfaces have greater removal torques than do more smooth implant surfaces (162-165).

High-velocity flame-sprayed HA-coated titanium implants have been histologically and histometrically compared to non-coated titanium alloy implants in beagle dogs after two weeks, one, three, and six months of healing (166). The HA coating was 50  $\mu\text{m}$  and the titanium was a smooth, machined surface. Bone levels were maintained at higher levels around the HA-coated implants than around the non-coated implants, and at every time point examined more bone-to-implant contact occurred around the coated implant. In the medullary areas, where no direct bone contact was found, some resorption of the surface HA was observed. High-velocity flame-sprayed HA has been reported to result in a well-maintained HA crystalline structure. In spite of the better crystalline structure, these investigators still found resorption of the HA coating in the medullary areas where the implant surface was in contact with bone marrow. At two weeks the HA-surfaced implants had woven bone attached directly to the surface, although in bone-free areas, detachment of HA grains and phagocytosis of crystalline granules by multinuclear or mononuclear cells was observed. The titanium implants were surrounded by immature soft tissue with new bone projected toward the implant surface. At one month, more prominent bone contact was observed around the HA-coated implants, but free HA grains and cells with HA granules were observed. Limited direct contact of new bone to the titanium surface was observed. Instead, a thin layer of soft tissue infiltrated by multinuclear or mononuclear cells remained. At three months, secondary



osteons were observed around the HA-coated implants. Cells containing HA were still observed in the bone-free surfaces in the remodeling areas. The extent of bone on the titanium surfaces had increased relative to the one month specimens. Some areas demonstrated bone modeling, while the soft tissue areas were covered with more dense fibrous tissues. At six months, more bone was observed around each implant than was observed at three months. The HA-coated implants also showed phagocytosis of HA particles in the cancellous bone areas not in direct contact with bone.

The percent of bone contact of the HA-coated implant surface was high between two weeks and one month and was approximately 90% at one month, with little change after that. The authors stated that in contrast to the findings in an earlier study (126), where the resorption rate of HA was higher in medullary spaces and almost absent in cortical areas, the results of their study showed HA resorption in both cancellous and cortical areas. Around titanium implants there was a gradual increase in bone-to-implant contact from one to six months with a 40% contact at six months. Thus, bone contact occurred earlier around the HA-coated implant and at every time point, more bone contact was observed around the HA-coated implant than around the titanium implant. Additionally, no crestal bone loss occurred around the HA-coated implants even three months after abutment connection, while the titanium implants at the same time period had crestal bone loss between one and five months, with soft tissue around the neck of the implant between the implant surface and bone.

### **Submerged versus Non-submerged Placement**

Histological evaluations of tissue reactions to 24 submerged and non-submerged titanium plasma-sprayed unloaded implants in six monkeys were made after 22 weeks of healing. No differences were found in the bone-to-implant contact between the submerged and non-submerged implants. Standardized radiographic data was obtained and, interestingly, a significantly high correlation was found between the histologic and radiographic data. However, when compared to the histology, the radiographs appeared to underestimate the depth of the infrabony defects. Histologically, both mineralized and non-mineralized areas were observed along the implant surface. On implant surfaces that were surrounded with high percentages of bone, the bone was deposited in layers with the lamellae parallel to the implant surface. In surface areas without bone, collagen fibers were also oriented parallel to the implant surface. SEMs revealed an intimate contact of bone to the implant surface, with cellular-rich bony ingrowth into the porosities of the titanium plasma-sprayed surface. Frequently, marginal bone was found up to the coronal extent of the sprayed surface. Histometric analysis indicated that an average of 48% of the implant surface was in contact with bone, whereas 52% was in contact with bone marrow. The authors cautioned against comparing the percentage of bone-to-implant contact between published studies due to many factors, including great differences between animals, anatomic sites, regions and loading conditions, trabecular pattern, and ratio of cortical to cancellous bone. This paper concluded that no significant difference occurred between submerged and non-submerged implants placed in similar sites in the same animal as regards bone-to-implant contact, suggesting that "osseointegration" could be established in one-stage as well as two-stage procedures.

In another study (75), single-crystal aluminum-oxide (sapphire) implants placed non-submerged in two beagle dogs were examined with LM, SEM, and TEM after six months of unloaded healing. These investigators found direct contact of most of the implant with bone in the coronal cortical areas, with more bone marrow and cancellous bone contact in the more apical portion of the implants. The average bone-to-implant contact was 61.8% of the surface. No osteoclasts or signs of inflammation were observed in the sections. Mandibular sections revealed Haversian systems and interstitial bone. The authors concluded that "...comparison between one-stage and two-stage dental implants shows no obvious differences in the 'direct' bone-implant contact area."

A pilot study in monkeys on unloaded and loaded non-submerged implants confirmed the findings above (167). These investigators used histological techniques and concluded: "This study confirms recent clinical and experimental research and further suggests that implants do not have to be left submerged for a given period in order to achieve direct bone apposition with no intervening connective tissue."

An ultrastructural study of ceramic and titanium screw-shaped implants also confirmed the similarity of bone-to-implant contact of one- and two-stage implants (144). Dogs were utilized and half of the 32 implants were loaded with fixed bridge work. Radiographic and histologic analysis did not reveal significant differences between the implants in the study. The authors concluded that "...one-stage endosteal

implants are capable of maintaining a proportional bone-to-implant interface at the apical support region, similar to that suggested for two-stage implant systems."

## Summary

The direct contact of bone to an implant surface describes a morphological condition (159). This situation is described as 'osseointegration' or 'functional ankylosis'. Both of these terms are often used incorrectly to clinically describe an implant. It must be remembered that these terms refer to a histological phenomenon and that clinically the implants are not mobile and have no continuous periapical radiolucency, both of which are appropriate clinical and radiographic descriptions, respectively. The placement of an implant in oral bone almost always involves contact with both cortical and cancellous bone. Subjective clinical assessment of bone quality has never been subjected to calibration and the sensitivity and specificity of the assessment is not known. In addition, intra-examiner and inter-examiner variability is unknown as regards a determination of bone quality. Because both cortical and cancellous bone are encountered, there is often great variability in the amount of bone-to-implant contact along the implant. It must be remembered that bone never completely surrounds the implant surface, resulting in varying amounts of bone marrow and soft tissue contact of the implant surface. Because no implant has 100% surface contact with bone, the effect of where the bone does contact the implant and its effect on implant stability under various clinical conditions are unknown. This also relates to the question of how much bone-to-implant contact is required for an implant to be clinically successful. It is clear that in addition to questioning how much of each cortical and cancellous bone must be in contact with the implant surface, it must also be asked where along the surface of the implant each type of bone must be located. For example, it would appear that an implant that has firm cortical support in the coronal and apical portions of the implant would require much less cancellous bone contact than an implant in a site which has limited cortical bone in the coronal area of the implant and no cortical bone in the apical area. Another question is what amount of contact is required for a given amount of force applied and what amount of bone-to-implant contact is required as varying forces are applied at different angles off the long axis of the implant.

A number of experiments have been performed to increase the anchorage of implants in bone tissue by modifying the surface characteristics of the fixture. Rougher implant surfaces have almost universally been shown to have more bone contact and require greater forces to be displaced than smoother surfaces, with the following results: HA > rough titanium > smooth titanium for bone-to-implant contact. These results may vary somewhat over different time periods and clinical conditions, but the results to date are generally consistent and are supported by the studies on retrieved human implants. Another very consistent finding is that HA is found to come off the implant surface. The use of implants with an unstable surface is of concern, especially considering the fact that HA is often resorbed very slowly. However, it must be noted that no problems have been reported as a consequence of HA that has come from endosseous implants.

The data reviewed above also demonstrated that both submerged and non-submerged implants can achieve osseous integration. Because bone is a dynamic, well-vascularized tissue, no implant achieves 100% contact with bone, and vascular elements and soft tissue are in contact within the bone tissue. It appears that almost all endosseous implants that are used clinically can achieve bone contact at the LM level, given ideal bone, surgical, and clinical conditions. In some cases there is a non-mineralized zone at the EM level. This material is probably extracellular bone cell matrix.

The findings and discussion above permit a more enlightened view of implant integration in bone. It is now obvious that both the quality and the location, in addition to quantity, of 'osseointegration' on an implant surface is of critical importance in determining the biomechanics of implant integration. Analysis of biomechanical strength includes resistance to forces such as removal torques, push and pull out strengths, etc. For these reasons, it is proposed that the term 'osseointegration' be restricted to use as it was defined, i.e. to histologically describe direct bone-to-implant contact at the LM level. Thus, clinical integration of an implant is dependent on more than direct bone-to-implant contact ('osseointegration') and other factors must be taken into consideration, such as the amount and direction of lamellar bone, where cortical and cancellous bone are located along the implant surface (e.g. apically and coronary (bicortical) versus only cortical bone coronally), etc. A more appropriate clinical term for successfully integrated endosseous implants would be 'stably integrated' implants. Because the implant is endosseous by definition, use of the term 'osseo' is redundant. Furthermore, integration involves three tissues: epithelium, soft connective tissue, and bone, and the use of a term that refers to only one

component does not adequately describe integration of the implant. In addition, studies have indicated that radiographically-measured bone loss was not necessarily an indicator of the clinical success or failure of an implant, but that mobility of the implant was a more appropriate criterium. Therefore, clinical reports should refer to 'stably integrated' endosseous implants and not 'osseointegrated' implants. The clinical success of implants relates to their functional use, so a 'stably integrated' implant is the goal of implant therapy, as is a functional prosthesis for the patient. Covered or 'sleeping' implants do not benefit the patient and the risk/benefit ratio from the placement of such implants must be carefully evaluated, especially in light of the high success rates for endosseous implants.

**Note: The here documented review on implants and their biological interfaces represents an excerpt from what can be considered the most comprehensive and up-to-date review currently available. Its reading is strongly recommended and can be found under the following reference:**

**Cochran D, Implant Therapy 1, Ann Periodontol 1996; 1: 707-790**

9/23/97 HPW

## REFERENCES

4. Branemark P-I, Hansson B, Adell R, et al. Osseointegrated implants in the treatment of the edentulous jaw: Experience from a 10-year period. *Scand J Plast Reconstr Surg* 1977;11(Suppl. 16):1-132.
53. Branemark P-I, Breine U, Adell R, Hansson O, Lindstrom J, Ohlsson A. Intraosseous anchorage of dental prostheses. *Scand J Plast Reconstr Surg* 1969;3:81-100.
54. Schroeder A, Zypen E, Stich H, Sutter F. The reactions of bone, connective tissue, and epithelium to endosteal implants with titanium-sprayed surfaces. *J Maxillofac Surg* 1981;9:15-25.
61. Listgarten MA, Lang NP, Schroeder HE, Schroeder A. Periodontal tissues and their counterparts around endosseous implants. *Clin Oral Impl Res* 1991;2:1-19.
62. Buser D, Warrer K, Karring T. Formation of a periodontal ligament around titanium implants. *J Periodontol* 1990;61:597-601.
63. Buser D, Warrer K, Karring T, Stich H. Titanium implants with a true periodontal ligament: An alternative to osseointegrated implants? *Int J Oral Maxillofac Implants* 1990;5:113-116.
64. Warrer K, Karring T. Periodontal ligament formation around different types of dental titanium implants. I. The self-tapping screw type implant system. *J Periodontol* 1993;64:29-34.
65. McKinney R, Steflik D, Koth D. The epithelium dental implant interface. *J Oral Implantol* 1988;8:622-637.
66. Steflik D, Sisk A, Parr G, Lake F, Hanes P. Experimental studies of the implant-tissue interface. *J Oral Implants* 1993;19:90-94.
67. Arvidson K, Bystedt H, Ericsson I. Histometric and ultrastructural studies of tissues surrounding Astra dental implants in dogs. *Int J Oral Maxillofac Surg* 1990;5:127-134.
68. Berglundh T, Lindhe J, Johnson K, Ericsson I. The topography of the vascular systems in the periodontal and peri-implant tissues in the dog. *J Clin Periodontol* 1994;21:189-193.
69. Buser D, Weber H-P, Donath K, Fiorellini J, Paquette D, Williams R. Soft tissue reactions to nonsubmerged unloaded titanium implants in beagle dogs. *J Periodontol* 1992;63:226-236.
70. Romanos G, Schroter-Kermani C, Weingart D, Strub J. Healthy human periodontal versus peri-implant gingival tissues: An immunohistochemical differentiation of the extracellular matrix. *Int J Oral Maxillofac Implants* 1995;10:750-758.
71. James RA, Schultz RL. Hemidesmosomes and the adhesion of junctional epithelial cells to metal implants. A preliminary report. *J Oral Implant* 1973;4:294-230.
72. Listgarten MA, Lai C. Ultrastructure of intact interface between an endosseous epoxy-resin dental implant and host tissues. *J Biologie Buccale* 1975;3(1):13-28.
73. Gould T, Westbury L, Brunette D. Ultrastructural study of the attachment of human gingiva to titanium in vivo. *J Prosthet Dent* 1984;52:418-420.
74. McKinney R, Steflik D, Koth D. Evidence for a junctional epithelial attachment to ceramic dental implants. A transmission electron microscopic study. *J Periodontol* 1985;56:579-591.
75. Fartash B, Arvidson K, Ericsson I. Histology of tissues surrounding single crystal sapphire endosseous dental implants. *Clin Oral Impl Res* 1990;1:13-21.

76. Chehroudi B, Gould T, Brunette D. A light and electron microscopic study of the effects of surface topography on the behavior of cells attached to titanium-coated percutaneous implants. *J Biomed Mat Res* 1991;25:387-405.
77. Chavrier C, Couble ML, Hartmann DJ. Qualitative study of collagenous and noncollagenous glycoproteins of the human healthy keratinized mucosa surrounding implants. *Clin Oral Impl Res* 1994;5:117-124.
78. Mackenzie I, Tonetti M. Formation of normal gingival epithelial phenotypes around osseointegrated oral implants in humans. *J Periodontol* 1995;66:933-943.
79. Carmichael RP, McCulloch CAG, Zarb GA. Quantitative immunohistochemical analysis of keratins and desmoplakins in human gingiva and peri-implant mucosa. *J Dent Res* 1991;70:899-905.
80. Berglundh T, Lindhe J, Ericsson I, Marinello C, Liljenberg B, Thomsen P. The soft tissue barrier at implants and teeth. *Clin Oral Impl Res* 1991;2:81-90.
81. Ruggeri A, Franchi M, Marini N, Trisi P, Piatelli A. Supracrestal circular collagen fiber network around osseointegrated nonsubmerged titanium implants. *Clin Oral Impl Res* 1992;3:169-175.
82. Ruggeri A, Franchi M, Trisi P, Piatelli A. Histologic and ultrastructural findings of gingival circular ligament surrounding osseointegrated nonsubmerged loaded titanium implants. *Int J Oral Maxillofac Implants* 1994;9:636-643.
83. Krekeler G, Schilli W, Diemer J. Should the exit of the artificial abutment tooth be positioned in the region of the attached gingiva? *Int J Oral Surg* 1985;14:504-508.
84. Meffert R, Langer B, Fritz M. Dental implants: A review. *J Periodontol* 1992;63:859-870.
85. Mericske-Stern R, Schaffner TS, Marti P, Geering AH. Peri-implant mucosal aspects of ITI implants supporting overdentures: A five-year longitudinal study. *Clin Oral Imp Res* 1994;5:9-18.
86. Cox JF, Zarb GA. The longitudinal clinical efficacy of osseointegrated dental implants: A 3-year report. *Int J Oral Maxillofac Implants* 1987;2:91-100.
87. Zarb GA, Schmitt A. The longitudinal clinical effectiveness of osseointegrated dental implants: The Toronto Study. Part I: Surgical results. *J Prosthet Dent* 1990;63:451-457.
88. Zarb GA, Schmitt A. The longitudinal clinical effectiveness of osseointegrated dental implants: The Toronto Study. Part II: The prosthetic results. *J Prosthet Dent* 1990;64:53-61.
89. Zarb GA, Schmitt A. The longitudinal clinical effectiveness of osseointegrated dental implants: The Toronto Study. Part III: Problems and complications encountered. *J Prosthet Dent* 1990;64:185-194.
90. Mericske-Stern R, Milani D, Mericske E, Olah A. Periotest® measurements and osseointegration of mandibular ITI implants supporting overdentures. *Clin Oral Impl Res* 1995;6:73-82.
91. Wennstrom JL, Bengazi F, Lekholm U. The influence of the masticatory mucosa on the peri-implant soft tissue condition. *Clin Oral Impl Res* 1994;5:1-8.
92. Strub J, Gaberthuel T, Grunder U. The role of attached gingiva in the health of peri-implant tissue in dogs. Part I. Clinical findings. *Int J Periodontics Restorative Dent* 1991;11:317-333.
93. Warrer K, Buser D, Lang NP, Karring T. Plaque-induced peri-implantitis in the presence or absence of keratinized mucosa. An experimental study in monkeys. *Clin Oral Impl Res* 1995;6:131-138.

94. Mitchell D, Synnott S, VanDercreek J. Tissue reaction involving an intraoral skin graft and CP titanium abutments: A clinical report. *Int J Oral Maxillofac Implants* 1990;5:79-84.
95. Sanz M, Alandex J, Lazaro P, Calvo JL, Quirynen M, van Steenberghe D. Histopathologic characteristics of peri-implant soft tissues in Branemark implants with 2 distinct clinical and radiological patterns. *Clin Oral Impl Res* 1991;2:128-134.
96. van Steenberghe D, Klinge B, Linden U, Quirynen M, Herrman I, Garpland C. Peridontal indices around natural and titanium abutments: A longitudinal multi-center study. *J Periodontol* 1993;64:538-541.
97. Chaytor D, Zarb G, Schmitt A, Lewis D. The longitudinal effectiveness of osseointegrated dental implants. The Toronto Study: Bone level changes. *Int J Periodontics Restorative Dent* 1991;11:113-125.
98. Berglundh T, Lindhe J, Marinello C, Ericsson I, Liljenberg B. Soft tissue reaction to de novo plaque formation on implants and teeth: An experimental study in the dog. *Clin Oral Impl Res* 1992;3:1-8.
99. Lang NP, Bragger U, Walther D, Beamer B, Kornman K. Ligature-induced peri-implant infection in cynomolgus monkeys. I. Clinical and radiographic findings. *Clin Oral Impl Res* 1993;4:2-11.
100. Quirynen M, Listgarten MA. The distribution of bacterial morphotypes around natural teeth and titanium implants ad modum Branemark. *Clin Oral Impl Res* 1990;1:8-12.
101. Apse P, Ellen RP, Overall CM, Zarb GA. Microbiota and crevicular fluid collagenase activity in the osseointegrated dental implant sulcus: A comparison of sites in edentulous and partially edentulous patients. *J Periodont Res* 1989;24:96-105.
102. Mombelli A, VanOosten MAC, Schurch E, Lang NP. The microbiota associated with successful or failing osseointegrated titanium implants. *Oral Microbiol Immunol* 1987;2:145-151.
103. Mombelli A, Mericske-Stern R. Microbiological features of stable osseointegrated implants used as abutments for overdentures. *Clin Oral Impl Res* 1990;1:1-7.
104. Seymour GJ, Gemmell E, Lenz LJ, Henry P, Bower R, Yamazaki K. Immunohistologic analysis of the inflammatory infiltrates associated with osseointegrated implants. *Int J Oral Maxillofac Implants* 1989;4:191-198.
111. Albrektsson T. Direct bone anchorage of dental implants. *J Prosthet Dent* 1983;50:255-261.
112. Hansson H-A, Albrektsson T, Branemark P-I. Structural aspects of the interface between tissue and titanium implants. *J Prosthet Dent* 1983;50:108-113.
113. Albrektsson T, Hansson H-A, Ivarsson B. Interface analysis of titanium and zirconium bone implants. *Biomaterials* 1985;6:97-101.
114. Johansson C, Albrektsson T. Integration of screw implants in the rabbit: A 1-year follow-up of removal torque of titanium implants. *Int J Oral Maxillofac Implants* 1987;2:69-75.
115. Albrektsson T, Branemark P-I, Hansson H-A, Lindstrom J. Osseointegrated titanium implants. *Acta Orthop Scand* 1981;52:155-170.
116. Eriksson A, Albrektsson T. Temperature threshold levels for heat-induced bone tissue injury: A vital-microscopic study in the rabbit. *J Prosthet Dent* 1983;50:101-107.
117. Eriksson A, Albrektsson T, Grane B, McQueen D. Thermal injury to bone. A vital-microscopic description of heat effects. *Int J Oral Surg* 1982;11:115-121.

118. Carlsson LV, Rostlund T, Albrektsson B, Albrektsson T. Removal torques for polished and rough titanium implants. *Int J Oral Maxillofac Implants* 1988;3:21-24.
119. Sennerby L, Thomsen P, Ericson L. A morphometric and biomechanic comparison of titanium implants inserted in rabbit cortical and cancellous bone. *Int J Oral Maxillofac Implants* 1992;7:62-71.
120. Han C-H, Han D-H. A study on shear-bond strength on the interface between bone and titanium plasma-sprayed IMZ implants in rabbits. *Int J Oral Maxillofac Implants* 1994;9:698-709.
121. Gotfredson K, Wennerberg A, Johansson C, Skovgaard LT, Hjorting-Hansen E. Anchorage of TiO<sub>2</sub>-blasted, HA-coated, and machined implants: An experimental study with rabbits. *J Biomed Mat Res* 1995;29:1223-1231.
122. Akagawa Y, Satomi K, Nikai H, Tsuru H. Initial interface between submerged hydroxyapatite-coated titanium alloy implant and mandibular bone after nontapping and tapping insertions in monkeys. *J Prosthet Dent* 1990;63:559-564.
123. Satomi K, Akagawa Y, Nikai H, Tsuru H. Bone-implant interface structures after nontapping and tapping insertion of screw-type titanium alloy endosseous implants. *J Prosthet Dent* 1988;59:339-342.
124. Piatteli A, Cordioli GP, Trisi P, Passi P, Favero GA, Meffert R. Light and confocal laser scanning microscopic evaluation of hydroxyapatite resorption patterns in medullary and cortical bone. *Int J Oral Maxillofac Implants* 1993;8:309-315.
125. Piattelli A, Trisi P. A light and laser scanning microscopy study of bone/hydroxyapatite-coated titanium implants interface: Histochemical evidence of unmineralized material in humans. *J Biomed Mat Res* 1994;28:529-536.
126. de Lange G, De Putter C, De Wijs F. Histological and ultrastructural appearance of the hydroxyapatite-bone interface. *J Biomed Mat Res* 1990;28:829-845.
127. Weinlaender M, Kenney E, Lekhovic V, Beumer J, Moy P, Lewis S. Histomorphometry of bone apposition around three types of endosseous dental implants. *Int J Oral Maxillofac Implants* 1992;7:491-496.
128. Block M, Finger I, Fontenot M, Kent J. Loaded hydroxylapatite-coated and grit-blasted titanium implants in dogs. *Int J Oral Maxillofac Implants* 1989;4:219-225.
129. Thomas K, Kay J, Cook S, Jarcho M. The effect of surface macrotecture and hydroxylapatite-coating on the mechanical strengths and histologic profiles of titanium implant materials. *J Biomed Mat Res* 1987;21:1395-1414.
130. Gottlander M, Albrektsson T, Carlsson L. A histomorphometric study of unthreaded hydroxyapatite-coated and titanium-coated implants in rabbit bone. *Int J Oral Maxillofac Implants* 1992;7:485-490.
131. Gottlander M, Albrektsson T. Histomorphometric studies of hydroxylapatite-coated and uncoated CP titanium threaded implants in bone. *Int J Oral Maxillofac Implants* 1991;6:399-404.
132. Block M, Kent J, Kay J. Evaluation of hydroxylapatite-coated titanium dental implants in dogs. *J Oral Maxillofac Surg* 1987;45:601-607.
133. Pilliar RM, Deporter DA, Watson PA, et al. The effect of partial coating with hydroxyapatite on bone remodeling in relation to porous-coated titanium alloy dental implants in the dog. *J Dent Res* 1991;70:1338-1345.
134. Shirota T, Donath K, Matsui Y, Ohno K, Michi K. Reactions of bone tissue in old rats to three different implant materials. *J Oral Implants* 1994;20:307-314.

135. Jansen JA, van de Waerden J, Wolke J, de Groot K. Histologic evaluation of the osseous adaptation to titanium and hydroxyapatite-coated titanium implants. *J Biomed Mat Res* 1991;25:973-989.
136. Gottlander M, Albrektsson T. Histomorphometric analyses of hydroxylapatite-coated and uncoated titanium implants. The importance of implant design. *Clin Oral Impl Res* 1992;3:71-76.
137. Stefflik D, Sisk A, Parr G, et al. Osteogenesis at the dental implant interface: High voltage electron microscopic and conventional transmission electron microscopic observations. *J Biomed Mat Res* 1993;27:791-800.
138. Stefflik D, Parr G, Sisk A, Lake F, Hanes P. Histomorphometry of the dental implant-bone interface: One-year results of a comparative investigation in dogs. *Int J Oral Maxillofac Implants* 1994;9:501-512.
139. Albrektsson T, Eriksson AR, Friberg BMP, Lekholm U, Lindahl L, Nevine M. Histologic investigations on 33 retrieved Nobelpharma implants. *Clin Mater* 1992;12:1-9.
140. Biesbrock A, Edgerton M. Evaluation of the clinical predictability of hydroxyapatite-coated endosseous dental implants: A review of the literature. *Int J Oral Maxillofac Implants* 1995;10:712-720.
141. Listgarten MA, Buser D, Steinemann D, Donath K, Lang NP, Weber H-P. Light and transmission electron microscopy of the intact interfaces between nonsubmerged titanium-coated epoxy resin implants and bone or gingiva. *J Dent Res* 1992;71:364-371.
142. Budd T, Nagahara K, Bielat K, Meenaghan M, Schaaf N. Visualization and initial characterization of the titanium boundary of the bone-implant interface of osseointegrated implants. *Int J Oral Maxillofac Implants* 1992;7:151-160.
143. Stefflik D, Hanes P, Sisk A, et al. Transmission electron microscopic and high voltage electron microscopic observations of the bone and osteocyte activity adjacent to unloaded dental implants placed in dogs. *J Periodontol* 1992;63:443-452.
144. Stefflik D, McKinney R. Ultrasound comparisons of ceramic and titanium dental implants in vivo: A scanning electron microscopic study. *J Biomed Mat Res* 1989;23:895-909.
145. Stefflik D, Parr G, Sisk A, Hanes P, Lake F. Electron microscopy of bone response to titanium cylindrical screw-type endosseous dental implants. *Int J Oral Maxillofac Implants* 1992;7:497-507.
146. Stefflik D, Lacefield W, Sisk A, Parr G, Lake F, Patterson J. Hydroxylapatite-coated dental implants: Descriptive histology and quantitative histomorphometry. *J Oral Implants* 1994;20:201-213.
147. Stefflik D, Sisk A, Parr G, et al. Transmission electron and high-voltage electron microscopy of osteocyte cellular processes extending to the dental implant surface. *J Biomed Mat Res* 1994;28:1095-1107.
148. Stefflik D, Koth D, Robinson F, et al. Prospective investigation of the single-crystal sapphire endosteal dental implant in humans: Ten-year results. *J Oral Implants* 1995;21:8-18.
149. Thomas K, Cook S. An evaluation of variables influencing implant fixation by direct bone apposition. *J Biomed Mat Res* 1985;19:875-901.
150. Cook S, Kay J, Thomas K, Jarcho M. Interface mechanics and histology of titanium and hydroxylapatite-coated titanium for dental implant applications. *Int J Oral Maxillofac Implants* 1987;2:15-22.



151. Cook S, Baffes G, Palafox A, Wolfe M, Burgess A. Torsional stability of HA-coated and grit-blasted titanium dental implants. *J Oral Implants* 1992;18:354-358.
152. Cook S, Salkeid S, Gaisser D, Wagner W. The effect of surface macrotexture on the mechanical and histologic characteristics of hydroxylapatite-coated dental implants. *J Oral Implants* 1993;14:288-294.
153. Buser D, Schenk RK, Steinmenn S, Fiorellini J, Fox CH, Stich H. Influence of surface characteristics on bone integration of titanium implants. A histomorphometric study in miniature pigs. *J Biomed Mat Res* 1991;25:889-902.
154. Meffert R, Block M, Kent J. What is osseointegration? *Int J Periodontics Restorative Dent* 1987;7(4):9-21.
155. Wennerberg A, Albrektsson T, Andersson B, Krol J. A histomorphometric and removal torque study of screw-shaped titanium implants with three different surface topographies. *Clin Oral Impl Res* 1995;6:24-30.
156. Wong M, Eulenberger J, Schenk R, Hunziker E. Effect of surface topology on the osseointegration of implant materials in trabecular bone. *J Biomed Mat Res* 1995;29:1567-1575.
157. Johansson C, Albrektsson T. A removal torque and histomorphometric study of commercially pure niobium and titanium implants in rabbit bone. *Clin Oral Impl Res* 1991;2:24-29.
158. Wilke HJ, Claes L, Steinemann S. The influence of various titanium surfaces on the interface shear strength between implants and bone. *Adv Biomaterials* 1990;9:309-314.
159. Gotfredson K, Rostrup E, Hjorting-Hansen E, Stoltze K, Budtz-Jorgensen E. Histological and histomorphometric evaluation of tissue reactions adjacent to endosteal implants in monkeys. *Clin Oral Impl Res* 1991;2:30-37.
160. Steinemann SG, Eulenberger J, Mausli P, Schroeder A. Adhesion of bone to titanium. *Biolog Biomechanical Performances Biomat* 1986;6:404-414.
161. Ericsson I, Johansson CB, Bystedty H, Norton MR. A histomorphometric evaluation of bone-to-bone implant contact on machine-prepared and roughened titanium dental implants: A pilot study in the dog. *Clin Oral Impl Res* 1994;5:202-206.
162. Gotfredson K, Nimb L, Hjorting-Hansen E, Jensen JS, Holmen A. Histomorphometric and removal torque analysis for TiO<sub>2</sub>-blasted titanium implants. An experimental study in dogs. *Clin Oral Impl Res* 1992;3:77-84.
163. Carlsson LV. On the development of a new concept for orthopaedic implant fixation (Thesis). University of Gothenburg, Sweden. 1989.
164. Johansson C. On tissue reactions to metal implants (Thesis). University of Gothenburg, Sweden. 1991.
165. Carlson B, Carlsson GE. Prosthodontia complications in osseointegrated dental implant treatment. *Int J Oral Maxillofac Implants* 1994;9:90-94.
166. Matsui Y, Ohno K, Michi K, Yamagata K. Experimental study of high velocity flame-sprayed hydroxyapatite coated and noncoated. *Int J Oral Maxillofac Implants* 1994;9:397-404.
167. Piatelli A, Ruggeri A, Franchi M, Romasco N, Trisi P. An histologic and histomorphometric study of bone reactions to unloaded and loaded non-submerged single implants in monkeys: A pilot study. *J Oral Implants* 1993;19:314-319.



# **Biomechanics And Implant Design**

**Dr. Merle J. Jaarda**



# **Biomechanics and Implant Design**

Merle J. Jaarda DDS, MS  
University of Michigan

## **Biomechanical Considerations in Osseointegrated Prostheses. Skalak R., J Prosthet Dent 1983;49:843-848.**

- Analysis of macroscopic stress distribution and load transfer mechanism of osseointegrated prostheses.
- Titanium is stronger and stiffer than bone.
- Screw implant vs. smooth implant.
- Load distribution to multiple implants.
- Unified structural behavior of fixed osseointegrated partial denture.
- Shock resistance of acrylic teeth.

## **Biomechanical Factors Affecting the Bone-Dental Implant Interface. Brunski JB. Clin Mater. 1992;10:153-201.**

Review Paper

- 176 articles reviewed.
- 1913-1992.

## **Theoretical Analysis of the Fatigue Life of Fixture Screws in Osseointegrated Dental Implant. Patterson EA, Eng B, Eng C, Mech MI, Johns RB, Int J Oral Maxillofac Implants 1992;7:26-34.**

- Two main locations of stress concentration in screws:
  1. The change of section between the shank and the screw head.
  2. The highest concentration is in the root of the first completely loaded thread.
- Estimation of fatigue life of retaining screw is twenty years.
- If the fit of prosthesis is poor, the retaining screws will experience full loading and the fatigue life will be in the order of weeks instead of years.
- Applying correct torque is necessary to achieve a long fatigue life.

**Mechanical Aspects of a Branemark Implant Connected to a Natural Tooth: An In Vitro Study.** Rangert B, Gunne J, Sullivan DY, Int J Oral Maxillofac Implants 1991;6:177-186.

- Screw joint between prosthetic cylinder and abutment is a flexible system and the most flexible seems to be within the screw itself.
- Screw loosening has been observed more often when implant fixture has been interlocked with natural teeth.
- Laboratory tests by Nobelpharma show a 10 Ncm torque to correspond to a screw tension of 250-300 N which is just below yield strength.

**Forces and Moments on Branemark Implants.** Rangert B, Jemt T, Jorneus L, Int J Oral Maxillofac Implants 1989;4:241-7.

- **Two main types of loading:**
  - Axial force
  - Bending moment
- Optimal preload must be maintained so that the screw joint does not open
- Gold screw is designed to be the weak link in the system
- Screw loosening causes gold screw fracture
- **Maximum load:**
  - Ultimate tensile strength of the Branemark gold screws is 600N
  - Maximal occlusal force in incisor region is 150N
- **Design rules:**
  - Distribute forces along curvature of occlusal line
  - Ensure good fit between abutments and prosthesis
  - 15-20 mm extension in mandible
  - do not exceed 10 mm in softer, more porous maxilla
  - Shorter cantilever must be used when implants are in a straight line
  - Anterior-posterior interfixture distance of at least 10 mm
  - In situation where bending moments occur:
    - Maximize implant offset to one abutment diameter in the molar region and two abutment diameters in the incisor region

**Implant Superstructures: A Comparison of Ultimate Failure Force: McGlumphy EA, Robinson DM, Mendal DA; Int J Oral Maxillofac Implants 1992;7:35-39.**

- tested nine implant/abutment combinations using an 18 mm cantilever prosthesis loaded with compressive load on cantilever.
- Conclusions:
  - There is a large variability in the properties of implant components.
  - Larger diameter and those constructed from titanium alloy provide the most resistance to failure.

**On Clinical Loading of Osseointegrated Implants: A methodological and clinical study: Glantz P-O, Rangert RB, Svensson A, Stafford GD, Arvidarson B, Randow K, Linden U, Hulten J. Clin Oral Impl Res 1993;4:99-105.**

- In vivo and in vitro experiment using 4 strain gauges each on five implant abutments.
- Conclusions:
  - fundamental differences occurred between in vitro and in vivo testing conditions.
  - unexpectedly high bending of the implants was recorded in many in vivo loading conditions.
  - Multiple strain gauges must be used.
  - The biomechanical complexity of the masticatory system and the structural and compositional heterogeneity's of bone are contribute factors to the in vitro/in vivo differences.
  - considerable preload was shown in the abutments during tightening in spite of a "satisfactory fit"

**Tightening Characteristics for Screwed Joints in Osseointegrated Dental Implants. Burquete RL, Johns RB, King T, Patterson EA, J Prosthet Dent 1194;71:592-9.**

- Without preload, all external load is experienced by screw resulting in decreased fatigue life of the screw.
- With preload, the screw experiences only the external load which is greater than the preload, thereby increasing the fatigue life.
- Increasing preload is beneficial to the fatigue performance until total load is equal to the yield of the screw
- applied torque and preload are only indirectly proportional because of the influence of friction forces under the head of the screw
- Preload is a function of:
  - coefficient of friction
  - geometry
  - Material properties
- Coefficient of friction is dependent on:
  - Hardness of threads: increased hardness > increased coefficient
  - surface finish: increased roughness . increased coefficient
  - quantity and properties of lubricants
  - speed of tightening
- \*therefore, every screw design will have a different preload/torque relationship

**JOMI Current Issues Forum - What scientific proof does the restorative clinician have that intersystem implant hardware components are interchangeable without potential harm to long-term implant survival, Int J Oral Implants 1993;8:105-9.**

- The current literature does not sufficient support or oppose the interchangeability of implant components parts
- The key words in the question...are "scientific proof." And the answer is "none".
- "look-alike" components do not necessarily maintain the mechanical principles of the original. And if the mechanics are different, one can only assume that the biology will be affected.



**The Role of Screws in Implant Systems: Osseointegration Ten Years in Private Practice Conference. Int J Oral Maxillofac Impl. 1994;9: Suppl. 48-63.**

- minor changes in the threads of gold screws can change the ultimate torque value from 18 Ncm to 29.5 Ncm.
  
- **Why do prosthetic screws loosen?**
  - Inadequate tightening
  - Inadequate prosthesis fit
  - Poor machined components
  - Excessive loading
  - Screw design
  - Elasticity of bone
  
- **Inadequate tightening**
  - Low preload; inadequate clamping force
  - Failure to retighten after initial insertion and settling
  - Operator variability in torque application
  - Difficult access to properly tighten
  - Variation of torque output with mechanical drivers
  
- **Inadequate prosthesis fit**
  - Nonpassive fit; incomplete seating
  - Use of nonmachined components
  - Overpolished or overinstrumentation of mating surfaces
  - Abutments not fully seated
  - Incorrect or mismatched components
  
- **Poorly machined components**
  - Poor quality control by manufacturers
  - Too large machining tolerances to prevent movement and rotation
  - Inadequate mating surfaces
  - Inadequate crossover compatibility
  
- **Screw design**
  - Low tensile strength and yield strength . limits amount of preload
  - Slotted vs internal hex: hex permits more positive engagement and a greater preload
  - Inadequate screw length, diameter, thread, neck design for applied load
  
- **Elasticity of bone**
  - greater screw joint instability in maxilla related to functional deformation of cancellous bone
  - more implants required in maxilla
  - Incremental and progressive loading encourages increased cortication of receptor sites.

## Dimensional Analysis of Five Interchangeable Implant Prosthetic Retaining Screws. Jaarda MJ, Razzoog ME, Gratton DG (In Preparation)

### Method:

- SEM measurement of nine geometric parameters
- n = 5

### Materials:

- |  |          |
|--|----------|
| - 3i Implant Innovations, Inc.<br>West Palm Beach, Fl. | gold     |
| - Impl-Med, Inc.<br>Sunrise, Fl.                       | gold     |
| - Nobelpharma USA, Inc.<br>Chicago, Il.                | gold*    |
| - 3i Implant Innovations, Inc.<br>West Palm Beach, Fl. | titanium |
| - Implant Support Systems, Inc.<br>Irvine, Ca          | titanium |

\*control

### Statistical Analysis:

- ANOVA  $P < .05$ .
- Duncan Multiple Range, sig. level = .05.

### Results:

- Only significant differences presented.
- Difference of means.

Parameter A: The diameter of the head of the retaining screw.

- |                |                          |
|----------------|--------------------------|
| - 3I gold      | 40 $\mu\text{m}$ larger  |
| - ISS titanium | 136 $\mu\text{m}$ larger |

Parameter B:	The screw length	
-	3I gold	.08 $\mu\text{m}$ shorter
-	3I titanium	194 $\mu\text{m}$ shorter
-	Impla-med gold	174 $\mu\text{m}$ longer
-	ISS titanium	72 $\mu\text{m}$ longer
Parameter C:	The thread pitch	
-	No significant differences in comparing the "look-alike" screws to the Nobelpharma gold screws.	
Parameter D:	The major diameter	
-	Impla-Med gold	32 $\mu\text{m}$ smaller
Parameter E:	Diameter at the tip	
-	3I gold	21 $\mu\text{m}$ larger
-	3I titanium	64 $\mu\text{m}$
-	ISS titanium	82 $\mu\text{m}$
-	Impla-Med gold	38 $\mu\text{m}$ smaller
Parameter F:	The neck diameter	
-	Impla-Med gold	272 $\mu\text{m}$ larger
-	ISS titanium	156 $\mu\text{m}$ larger
-	3I gold	92 $\mu\text{m}$ smaller
-	3I titanium	108 $\mu\text{m}$ smaller
Parameter G:	The length of the neck	
-	3I gold	174 $\mu\text{m}$ longer
-	3I titanium	134 $\mu\text{m}$ longer
-	Impla-med gold	64 $\mu\text{m}$ shorter
-	ISS titanium	218 $\mu\text{m}$ shorter
Parameter H:	The crest width	
-	There were no significant differences.	
Parameter I:	The root width	
-	The 3I gold	29.2 $\mu\text{m}$ smaller
-	The 3I titanium	21.2 $\mu\text{m}$ smaller
-	The Impl-Med gold	5.0 $\mu\text{m}$ smaller

**Ultimate Torque/Tensile Preload Analysis of Five Interchangeable Implant Prosthetic Retaining Screws, MJ, Razzoog ME, Gratton DG (In Preparation) Jaarda**

**Method:**

- Tohnichi BTG-6 torque gauge
- n = 5

**Materials:**

- 3i Implant Innovations, Inc. gold  
West Palm Beach, Fl.
- Impla-Med, Inc. gold  
Sunrise, Fl.
- Nobelpharma USA, Inc. gold\*  
Chicago, Il.
- 3i Implant Innovations, Inc. titanium  
West Palm Beach, Fl.
- Implant Support Systems, Inc. titanium  
Irvine, Ca

**\*control**

**Results:**

- Manufacturer alloy /	Mean Ultimate Torque	Std. Dev.
- Nobelpharma gold*	24.5,	1.66
- 3I gold	24.41,	3.42
- Impla-Med gold	20.7**	1.72
- 3I titanium gold	20.1**	1.34
- ISS titanium	35.2**	3.42

- \* control

- \*\*Significant at .05 level, Duncan Multiple Range Test

**Ultimate Tensile Strength Analysis of Five Interchangeable Implant Prosthetic Retaining Screws, Jaarda MJ, Razzoog ME, Gratton DG (In Preparation).**

**Method:**

- Instron Universal Testing Machine
- n = 5
- Preloaded to 10 Ncm

**Materials:**

- 3i Implant Innovations, Inc.            gold  
  West Palm Beach, Fl.
- Impla-Med, Inc.                        gold  
  Sunrise, Fl.
- Nobelpharma USA, Inc.                gold\*  
  Chicago, Il.
- 3i Implant Innovations, Inc.        titanium  
  West Palm Beach, Fl.
- Implant Support Systems, Inc.        titanium  
  Irvine, Ca

\*control

**Results:**

- Manufacturer alloy / Mean UTS-kg	Std. Dev.	
- Nobelpharma gold*	84.540	0.921
- 3I gold	75.400**	4.197
- Impla-Med gold	76.060**	3.444
- 3I titanium	41.300**	2.466
- ISS titanium	108.080**	4.932

\* control

\*\* Significant at .05 level, Tukey HSD test

**Craig, RG (ed.), Restorative Dental Materials, 6th ed., C.V. Mosby, St. Louis, MO, 1980, pp. 60-1.**

**Functional Loads:**

- Vertical component of biting force with natural dentition
  - Molars = 390-880N
  - Bicuspids = 453N
  - Incisors = 222N

**Carlsson GE, Haraldsson T., Functional Response. In Tissue Integrated Protheses. ed P-I Branemark, G. Zarb and T. Albrektsson. Quintessence, Chicago, 1985, pp. 155-63.**

**Functional Loads:**

- Vertical component of biting force with dentures supported by implants
  - 42 - 412N

**Biomechanical Considerations in Osseointegrated Protheses. Skalak R., J Prosthet Dent 1983;49:843-848.**

**Functional Loads:**

- Maximum tensile load per screw may reach 1-1/2 - 2 times the applied compressive load in case of cantilever protheses.

**Elongation Analysis of Five Interchangeable Implant Prosthetic Retaining Screws. Jaarda MJ, Razzoog ME, Gratton DG (In Preparation).**

**Method:**

- Instron Universal Testing Machine
- n = 5
- Preloaded to 10 Ncm

**Materials:**

- 3i Implant Innovations, Inc. gold  
West Palm Beach, Fl.
- Impla-Med, Inc. gold  
Sunrise, Fl.
- Nobelpharma USA, Inc. gold\*  
Chicago, Il.
- 3i Implant Innovations, Inc. titanium  
West Palm Beach, Fl.
- Implant Support Systems, Inc. titanium  
Irvine, Ca

\*control

**Results:**

Elongation at 40 kg (392N) load

Mean ( $\mu\text{m}$ )

- Manufacturer alloy / Mean $\mu\text{m}$	Std. Dev.	
- Nobelpharma gold*	268	26
- 3I gold	308	81
- Impla-Med gold	277	34
- 3I titanium	fractured	
- ISS titanium	218	20

Elongation at 80 kg

Mean ( $\mu\text{m}$ )

- Manufacturer alloy / Mean $\mu\text{m}$	Std. Dev.	
- Nobelpharma gold*	506	27
- 3I gold	fractured	
- Impla-Med gold	fractured	
- 3I titanium	fractured	
- ISS titanium	420	19

**Elemental Analysis of Five Interchangeable Implant Prosthetic Retaining Screws. Jaarda MJ, Razzoog ME, Gratton DG (In Preparation).**

**Method:**

- Energy Dispersive Spectroscopy (EDS)
- n = 4

**Materials:**

- 3i Implant Innovations, Inc. gold  
West Palm Beach, Fl.
- Impl-Med, Inc. gold  
Sunrise, Fl.
- Nobelpharma USA, Inc. gold\*  
Chicago, Il.
- 3i Implant Innovations, Inc. titanium  
West Palm Beach, Fl.
- Implant Support Systems, Inc. titanium  
Irvine, Ca

**\*control**

**Results:**

- element percent

**Materials:**

	Au	Ag	Cu	Ga	Pd	Zn
3i gold		3.0	8.4	10.8	77.6	
Impla-Med gold	56.4	18.5	22.8			2.1
Nobelpharma gold	58.8	23.8	18.1			
	Ti	Al				
3i titanium	99.5	0.4				
ISS titanium	87.5	12.4				



**Effect of Preload Torque on the Ultimate Tensile Strength of Implant Prosthetic Retaining Screws. Jaarda MJ, Razzoog ME, Gratton DG. Implant Dent 1994;3:17-21.**

**Method:**

- 0, 6, 10, 15, 20N preloads
- n = 5

**Materials:**

- 3i Implant Innovations, Inc. gold  
West Palm Beach, Fl.
- Impla-Med, Inc. gold  
Sunrise, Fl.
- Nobelpharma USA, Inc. gold\*  
Chicago, Il.
- 3i Implant Innovations, Inc. titanium  
West Palm Beach, Fl.
- Implant Support Systems, Inc. titanium  
Irvine, Ca

\*control

**Results:**

- Lot #	Preload (Ncm)	Mean	UTS	Std. Dev.
- 2075/75	6	67.1	2.20	
- /10	67.9	5.59		
- /15	65.9	9.57		
- 6861 /0	83.0	6.11		
- /10	84.4	0.71		
- /20	81.0	7.76		

**Conclusion:**

- Altering preload torque does not affect the ultimate tensile strength of gold retaining screws.

7. Lazzara, R. J.: Criteria for implant selection: Surgical and prosthetic considerations. *Prac Perio & Aesthet Dent* 1994;9(6). *The Implant Report* 1994.
8. Pissis, P.: Emergence profile considerations of implant abutments. *Prac Perio & Aesthet Dent* 1994;7(6):69-78.
9. Tolman, D. E.: Reconstructive procedures with endosseous implants in grafted bone: A review of the literature. *Int J Oral Maxillofac Implants* 1995; 10:275-294.
10. Rose, L. F., Salama, H., Bahat, O., Minsk, L.: Treatment planning and site development for the implant-assisted periodontal reconstruction. *Compend Contin Educ Dent* 1995; 16(8):726-741.
11. Garber, D. A., Belser, U. S.: Restoration-driven implant placement with restoration-generated site development. *Compend Contin Educ Dent* 1995;16(8):796-804.
12. Langer, B., Sullivan, D. Y.: Osseointegration: Its impact on the interrelationship of periodontics and restorative dentistry. Part III Periodontal prosthesis redefined. In *J Periodont Rest Dent* 1989;9(4):241-261.
13. Sullivan, D. Y.: Optimal esthetic treatment: Transition from advanced periodontal disease to implant prosthesis. From: *Proceedings of the Fourth International Symposium on Implant Dentistry: Focus on Esthetics*. A. A. Siddiqui, Caudill, R. (eds.). *J Prosthet Dent* 1994;72:623-34.
14. Starr, N. L., Weisgold, A. S.: Implant prosthodontics - An adjunct in periodontal prosthesis. Part I and II: Diagnosis, treatment planning, sequencing of therapy. *Alpha Omega*, Vol. 85, Scientific Issue, 1992.
15. Lewis, S.: Anterior single-tooth implant restorations. *Int J Oral Maxillofac Implants* 1995;15:31-41.
16. Balshi, T. J.: Candidates and requirements for single tooth implant restorations. *Int J Perio Rest Dent* 1994;14:317-331.
17. Sherwood, R. L., Sullivan, D. Y.: Concepts and techniques of single tooth implant restorations. *Esthet Dent Update* 1991;2(1):16-22.
18. Holloway, J. A., McGlumphy, E. A.: Soft tissue contouring for esthetic single-tooth implant restorations. *Prac Perio & Aesthet Dent* 1993(5):41-48.
19. Hurzeler, M. B., Quinones, C. R., Strub, J. R.: Advanced surgical and prosthetic management of the anterior single tooth osseointegrated implant: A case presentation. *Prac Perio & Aesthet Dent* 1994;1(6):13-21.
20. Spiekermann, H.: Implantology Thieme, New York, 1995.
21. Binon, P. P.: Paramount role of transitional prosthesis within implant prosthodontics. *Dent Implantol Update* 1995;6(7):49-53.
22. Binon, P. P.: Provisionalization in implant prosthodontics for partially edentulous arch. *Dent Implantol Update* 1995;6(8):57-61.
23. Lewis, S., Parel, S., Faulkner, R.: Provisional implant-supported fixed restorations. *Int J Oral Maxillofac Implants* 1995;10:319-325.
24. Personal communication. Dan Root, 1995.
25. Guichet, D. L.: Load transfer in screw- and cement-retained implant fixed partial denture designs. In: *Proceedings of the Fourth International Symposium on Implant Dentistry: Focus on Esthetics*. 1994, San Diego. Eds.: Siddiqui, A., A., Caudill, R. *J Prosthet Dent* 1994;(6)72:623-634.
26. Steffik, D. (ed.): Hydroxyapatite coatings on dental implants: benefits and risks. *J Oral Implantol* 1994;(3)20. IADR Symposium, Seattle.
27. Reitzik, M.: Periodontal disease and implants: When implants are better than ailing teeth. Presentation, *Steri-Oss International Conference*, Newport, 1995.
28. Kopp, C. D.: Branemark osseointegration-prognosis and treatment rationale. *Dent Clin North Am.* 1989;33(4):701-731.
29. English, C. E.: Current treatment trends, restorative options, and guidelines with cylindrical endosseous implant. In: Linkow, L., Volume 4, Puccin Press, Padua. In press.
30. Kopp, C. D.: Overdentures and osseointegration-case studies in treatment planning. *Dent Clin North Am.* 1990;34(4):729-739.

31. English, C. E.: Removable prosthodontics as first-line treatment. *Prac Perio & Aesthet Dent* 1992; Winter: 26-29.
32. English, C. E.: Bar patterns in implant prosthodontics. *Implant Dent* 1994;3:217-229.
33. Keltjens, H. M., Kayser, A., Hertel, R., Pasquale, B: Distal extension removable partial dentures supported by implants and residual teeth: Considerations and case reports. *Int J Oral Maxillofac Implants* 1993;8:208-213.

h

## Restorative Guidelines:

### Mandibular Fixed (Partially Edentulous)

1. Anterior (symphysis) 1 imp/4 units
  - a. Use narrow platform (3.25mm) for centrals and laterals. Use 4.1 platform for canines. Watch lingual trajectory.
2. Posterior (bicuspid posterior) 1 imp/tooth
  - a. Use 4.1 platform for premolars and molars for 5-6mm widths for molars. (4.5-5.0 mm. most pr)
  - b. Determine occlusion: bicuspid only, or bicuspids and molars.
  - c. Avoid cantilevers when possible, avoid pier abutments, caution with non-rigid connectors, minimize span length, optimize support, optimize occlusal accuracy and protect with hard/soft laminated nightguard.
  - d. 3-4 unit fixed-implant supported: Use preable and cement-to abutments. Provisional cement is acceptable.
  - e. 3-4 unit fixed-implant to tooth supported: Used 2° gold copings on the natural teeth and provisionally cement or hard set cement with no copings if tooth reduction and clearance is a problem.
  - f. Use UCLA or coronal screw retention for fixed cases with 3-5mm of interarch clearance.
  - g. Strongly consider overpartial with implants not being in optimum position or length for classic fixed. This is effectively an implant supported, but removable fixed case similar to a Kennedy Class III RPD. Esthetics and function can be far better.
  - h. Horizontal bruxers can create havoc on posterior restorations. Therefore, be very cautious with short implants (8,10mm) and fixed with these patients.
  - i. Buccalized occlusion is an esthetic, non-interfering occlusal scheme for posterior fixed. Mandibular buccal cusp occludes in to a shallow maxillary fossa. One contact per tooth is adequate; tripodized is not practical or easily achievable.

### Maxillary Fixed (Partially Edentulous)

1. Anterior (premaxilla) 1 imp/3 units
  - a. Use 5mm or 6mm for centrals.
  - b. Use 4.1mm platform for canines and 3.5mm for laterals.
  - c. Watch trajectory and mesial-distal positioning.
  - d. Observe smile line and height, alveolar ridge contours, and tissue support needs.
2. Posterior (bicuspid Posterior) 1 imp/tooth
  - a. May need sinus graft; graft heals 1mm/month and vertically. Need to provisionalize and progressively load until bone matures.
  - b. Get implants splinted and stabilized as soon as uncovering due to bone density.
  - c. Pulp test adjacent teeth to implant sites prior to surgery.
3. Occlusion
  - a. Allow implants to provide vertical stops and natural teeth to provide disclusion. Remember: anterior natural teeth move facially 60-100 microns on protrusive and laterally protrusive movements. Allow for the natural tooth movement when adjusting occlusion on fixed cases and single tooth restorations.
  - b. Splinting implants to teeth may have advantages in the PDL neurophysiologic feedback mechanism. In these cases, distribute the occlusal contacts as evenly as possible on all abutments and teeth. Be sure optimum anterior disclusion is developed for the Class I. Optimum group function (canine, bi, bi) is developed for the Class II. Optimum edge to edge contacts for the Class III.
  - c. Watch the horizontal bruxer, develop minimum vertical overlap incisors (1mm).
  - d. Watch the vertical bruxers, develop cingulum incisor rests after opening the VDO. Use phonetics, lip posture,
  - e. Vertical bruxers can be restored fixed, but horizontal bruxers may need to be restored with removable overpartials. Consider a resilient overlay prosthesis.

## IMPLANT RESTORATIVE OPTIONS

The restoration would be called a ...partial or ...denture depending upon whether one is restoring an edentulous arch or partially dentate arch.

### I. Overpartial

Def.: 1-3 or more implants are used to support and retain a traditional partial denture prosthesis. O-rings, ERA's, or ball/cap retention devices are used with the retentive housing incorporated into the acrylic resin of the prosthesis.

### II. Bar/Overpartial

Def.: Same as above except that the implants are splinted together with a cast metal bar of a Hader, Dolder, or 2-4° milled configuration. This is an acrylic to metal bar contact concept.

### III. Double Bar Concepts:

Three variations: these are all metal to metal contact concepts

- A. Cast substructure milled with 2° walls and with a cast mating suprastructure that fits intimately over the substructure.  
This is a metal to metal contact concept that also uses retention devices such as Revax "Ceka", ERA, Ipsoclip, Minipressomatic, Lew Passive devices, or Bredent ball attachments.
- B. Alabama or Andrews Bar restorations which use Carpenter stainless steel parallel walled bars and riders of varying radii. They are cast-to the abutments after they have been paralleled with mandrels. The rider or clip is incorporated into the overlay prosthesis. They are very stable and are known as "the poor mans spark erosion".
- C. "Spark Erosion" or EDM technology produces very intimately fitting double bars or frames to tapered copings. The suprastructure is retained to the substructure with a swivel latch device

### IV. Fixed Detachable

Def.: A screw retained, dentist removable fixed partial prosthesis ad modum Branemark. May be porcelain fused to metal or denture teeth processed to a metal frame.

### V. Fixed (cemented)

Def.: Any fixed partial prosthesis that is luted to the abutments either one piece (bypassing the hex) or two piece (engaging the hex) with hard set (permanent), soft set (provisional), or non-setting cements. Author's opinion that one piece screw-on or screw-in abutments that bypass the hex, are torqued to place, and impressed like standard crown & bridge work best. A buccal groove or facet is important for mechanical stability of the abutment and bridge.

VI. Fixed (telescopic)  
Two variations:

A. Koerber technique from Germany

Total convergence angle of any abutment is a total of 12°. Ex.: 6° & 6° , 9° & 3°, 8° & 4°, etc. The higher convergence angles are on the distal of the distal abutments in order to accomodate the anterior trajectore of the anterior teeth or implant abutments. Prosthesis is retained by static friction only due to the intimate mating fit of the bridge to the custom milled copings.

B. Yalisove/Dietz technique from the United States

Involves varying the taper from 2° to 16° dependent upon the periodontal stability of the periodontally involved teeth. For implants this technique has been modified to mill all abutments 2 or 3° degrees.

Note: Minipressomatic or Ipsoclip pawl connectors may be used for retention with telescopic prostheses.

VII. Single tooth

An arch or quadrant can be restored with single tooth implants as well. The surgical challenge would be alignment and the technical challenge would be to create passive fit for all crowns without interproximal jamming with the porcelain to porcelain proximal contacts. Implants don't yield like the periodontal membrane. This is an unusual approach but has been published upon by Manfred Bender of Germany in Oral Implantology in 1995.

EXTERNAL HEX ABUTMENTS OPTIONS

(for a 4.1mm. platform)

I. Fixed-detachable, bar/overdenture, screw retained fixed

- |                                  |               |
|----------------------------------|---------------|
| A. PME (flat top)                | Steri-OSS     |
| B. One Piece Abutment (flat top) | Impla Med     |
| C. Conical (tapered)             | 3-I           |
| D. GUCA or GUCH (metal UCLA's)   | 3-I           |
| E. Gold cylinder                 | Steri-OSS     |
| F. UMA (hex taper)               | Attach. Intl. |
| G. Shouldered abutment           | Calcitek      |

II. Single Tooth

- |                             |                    |
|-----------------------------|--------------------|
| A. STR                      | 3-I or Nobelpharma |
| B. GUCA or GUCH             | 3-I                |
| C. CeraOne                  | Nobelpharma        |
| D. Conical                  | 3-I                |
| E. DIA Anatomic             | Steri-OSS          |
| F. Hexed Direct Gold coping | Calcitek           |

III. Provisional Abutment

- |                                   |                  |
|-----------------------------------|------------------|
| A. Provisional abutment (knurled) | Lifecore/Restore |
| B. UCLA (microgrooved)            | Impla Med        |
| C. HL 0° or 15° shouldered        | Steri-OSS        |
| D. AHP series                     | 3-I              |
| E. DIA Anatomic                   | Steri-OSS        |

IV. Fixed (cemented)

- |                             |            |
|-----------------------------|------------|
| A. DIA Anatomic             | Steri-OSS  |
| B. EP Abutment              | 3-I        |
| C. Fixed abutment           | Swede-Vent |
| D. AHP series               | 3-I        |
| E. Natural Profile abutment | Impla Med  |

V. Overdenture

- |                           |                         |
|---------------------------|-------------------------|
| A. O-ring stud            | Steri-OSS HL or Restore |
| B. THRC series            | 3-I                     |
| C. ERA series             | Impla Med               |
| D. Shiner magnet & keeper | Preat                   |

VI. Pre-angled

- |   |           |
|---|-----------|
| A. DIA Anatomic or HL series (15° or 25°) | Steri-OSS |
| B. Pre-angled (ovoid shape)               | 3-I       |

Many other excellent choices from:

Intec Inc.

Osteo-Implant Inc.

Universal Implant Systems

INTERNAL HEX/BEVEL & HEX ABUTMENT OPTIONS

DENTSPLY SPECTRA

- I. Fixed-detachable, bar/overdenture, screw retained fixed
  - A. Titanium straight insert (TSI3, et.al.) flat top
  - B. Titanium tapered insert (TSI1, et. al.) tapered shoulder
  
- II. Single Tooth
  - A. Hex-Lock abutment(friction-fit) (HLA3F)
  - B. Plastic castable abutment (PCT3)
  - C. Pre-angled base and angled head (HOBF, AH15, AH30)
  
- III. Provisional abutment
  - A. Hex-Lock abutment (HLA3F)
  
- IV. Fixed (cemented)
  - A. Hex-Lock abutment (HLA3F)
  - B. Titanium coping insert (TCT)
  
- V. Overdenture
  - A. Titanium straight ball insert (TSIB2)
  
- VI. Pre-angled (15° & 30°)
  - A. base (HOBF) for 3.5mm diameter
  - B. 15° angled head (AH15)
  - C. 30% angled head (AH30)
  
- VII. Cast-to screw housings & bases
  - A. Base (TSIR)
  - B. Flat top housing (RSH)
  - C. Tapered shoulder housing (RTH)
  
- VIII. Ball attachment to retrofit for overdenture
  - A. Titanium ball screw (TSB) which screws into (TSI3 or TSIW3)



IMPLANT(FIXTURE)-ABUTMENT CONNECTIONS

- I. EXTERNAL HEX/BUTT Joint: .7mm(h)X2.7mm(w) Platform:4.1mm m
1. Branemark by Nobelpharma
  2. 3-I by Implant Innovations
  3. Steri-OSS HL series by Steri-OSS
  4. Swede Vent by Dentsply
  5. ThreadLoc by Calcitek
  6. Impla Med by Sterngold Impla Med
  7. Imtec line by Imtec
  8. Restore by Lifecore
  9. Interpore Hex by Interpore Intl.
  10. Crossmark by Osteo Implant
  11. Bud by Great Lakes Orthodontics
  12. Minimatics by Minimatics
- II. EXTERNAL HEX/BUTT joint: 1mm(h)X2.3mm(w) Platform 3.25mm
1. Steri-OSS HL 3.25 by Steri-OSS
- III. INTERNAL HEX/BEVEL joint: 1.7mm X 2.4mm
- Spectra System by Dentsply: various platform widths from
1. Screw Vent 3.25-4.5mm
  2. Micro Vent
  3. Bio Vent
  4. Core Vent
- IV. BUTT joint: (3.25mm & 4.0mm diameters)
1. Integral by Calcitek
  2. Steri-OSS std. by Steri-OSS
  3. O-butment by "O" Company
- Note: Steri-OSS 3.8mm, Integral 4.0mm, and O-butment 4.0mm are interchangeable; however, 3.25mm Integral has a different thread tract than the other 3.25'
4. Miter by Miter Inc.
  5. ImplanTatum by Omni Intl.
- V. INTERNAL HEX joint:
1. HA-Ti by Mathys AG
  2. Mini by 3-I Platform: 3.25mm
- VI. INTERNAL OCTAGON joint:
1. Omnilock by Calcitek Platform: 4.0mm
- VII. INTERNAL BEVEL joint:
1. ITI by Straumann (8° bevel) Platform: 4.9mm
  2. Astra by AstraTech (11° bevel) Platform: 4.0mm
  3. Sustain by Lifecore Platform: 4.0mm
  4. Bicon system
- VIII. POLYMER BUTT joint: Platform: 3.3mm or 4.0mm
1. IMZ by Interpore Intl. (IME & IMC)

IX. UNIVERSAL ADAPTIVE SYSTEMS

1. UMA (Universal Modification Abutment) Attachments Intl.
2. Octa-Hex abutment system Universal Implant Systems
3. Custom abutments Impac/Vident
4. Sendax abutments Preat, Inc.
5. One system ISS/Lifecore

X. BUTT INT. SPLINE OR INT. POST

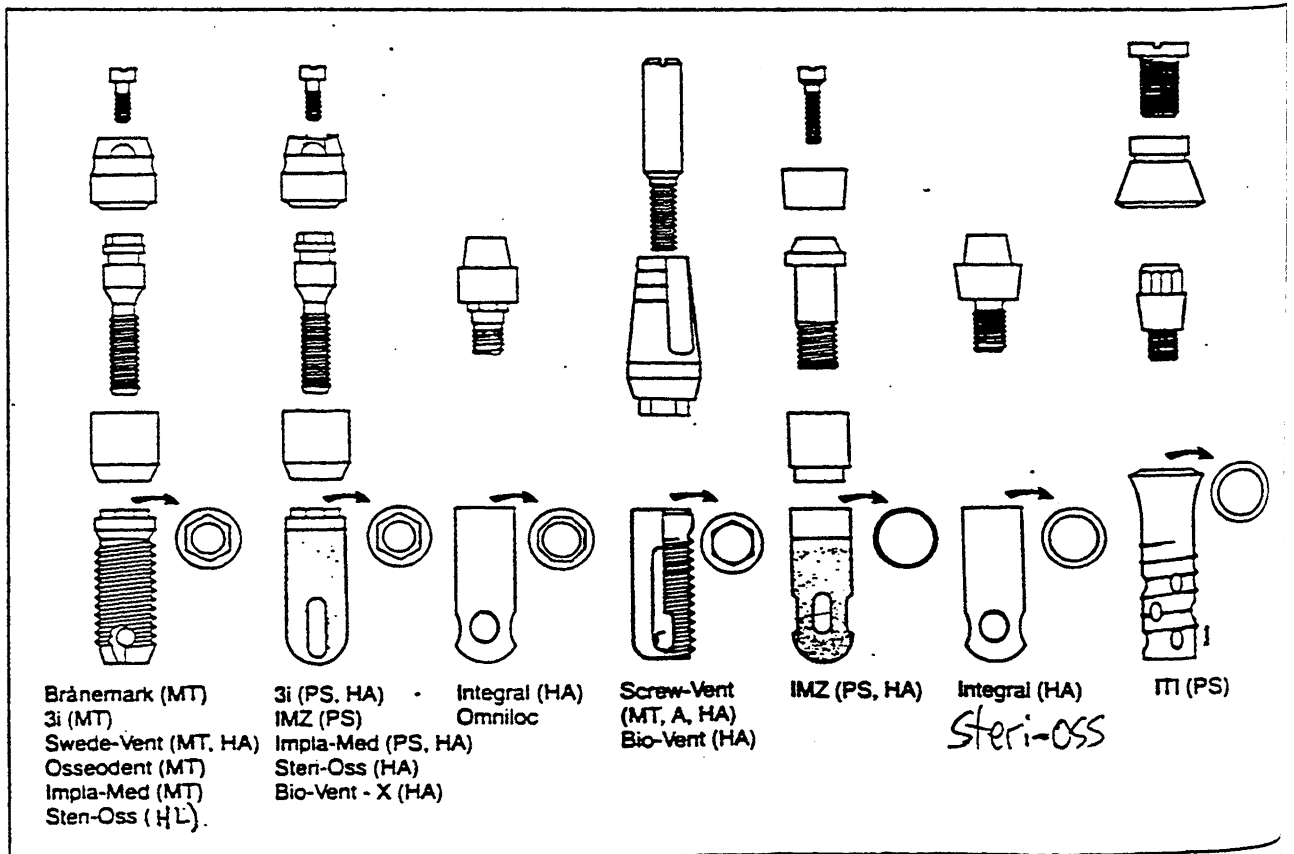
1. "O"butment ES
2. Star-Vent by Park Dental

XI. TAPERED HEAD (one stage) similar to TPS screw

1. Startanius by Park Dental

XII. TRANSITIONAL SYSTEMS:

1. MTI (Mini transitional implant)



English CE. Externally hexed implants, abutments, and transfer devices: A comprehensive overview. *Implant Dent* 1992;1:273-282.

This manuscript provides an overview of dental implant abutments for coronally hexed implants. Indications and contraindications for abutments are discussed. Implant designs from 16 different implant manufacturers with 64 abutment variations are illustrated.

English CE. Mechanical tooth concepts in implant dentistry. *Implant Dent* 1993;2:3-9.

This manuscript provides a history of mechanical tooth concepts with a brief discussion of the three basic categories of designs. .

English CE. Root intrusion in tooth-implant combination cases. *Implant Dent* 1993;2:79-85.

Etiologies for root intrusion in tooth-implant combination cases are suggested in this manuscript. Examples of root intrusion are illustrated. Advantages and disadvantages of nonrigid connector and coping/suprastructure techniques are presented.

English CE. Biomechanical concerns with fixed partial dentures involving implants. *Implant Dent* 1993;2:221-242.

Nine biomechanical factors in the design and fabrication of fixed partial dentures that use implants for support are discussed. Areas of concern are: cantilevers, pier abutments, long spans, nonrigid connectors, off-axis loading, occlusal plane to implant height ratio, and mandibular flexion and torsion.

Wiskott HWA, Belser UC. A rationale for a simplified occlusal design in restorative dentistry: Historical review and clinical guidelines. *J Prosthet Dent* 1995;73:169-83.

Traditional occlusal schemes are compared with occlusal contact patterns in which the number of contacts have been reduced.



# Dental Implant Therapy

Dr. Steven Lewis



# DENTAL IMPLANT THERAPY

Dr. Steven Lewis

## ANTERIOR ESTHETICS

Early implant restorations restored the edentulous patient. Due to resorption patterns, appearance of the restoration at the gingival margin was not critical. Without the need for esthetics, straight cylindrical titanium abutments allowed for the easy fabrication of supragingival restoration.

Partially edentulous patients brought about the demand for esthetics. Restorations had to appear as natural teeth emerging through the mucosa for acceptable results. Ridge laps provided esthetics but compromised hygiene. To generate a natural and gradual emergence through the soft tissue resulting in an esthetic and hygienic restoration, the restoration must begin beneath the mucosa.

### "UCLA" Abutment

The initial technique allowed for the restoration to begin directly to the top of the implant fixture. This procedure is commonly referred to as the "UCLA" Abutment. Impression copings fit directly to the implant fixtures and master soft tissue casts contain implant fixture analogs.

Plastic burn out patterns or machined gold alloy cylinders are designed to fit directly to the implant fixture. Thus, a casting can be made to connect directly to the fixture. The final porcelain fused-to-metal restoration is retained to the implant fixtures with titanium alloy abutment screws. By beginning at the level of the fixtures, the restoration can develop a natural and gradual emergency profile providing esthetics and hygiene.

Potential compromises of this technique include lack of a titanium to titanium interface at the level of the implant fixture. Potential for galvanism and corrosion at this interface is a concern. Also lacking is a titanium-to-soft-tissue interface. The hemidesmosomal connection of this interface may control and limit pocket depth around an implant interface. By bringing the restoration all the way to the implant fixture, significant deep soft tissue pocketing may be present when thick mucosa is above the implant. Soft tissue maintenance may be difficult in these situations.

Also, by going directly to the implant fixture with the restoration, it is difficult to evaluate the fit of the implant restoration. Delivering an implant restoration with a poor fit will introduce significant forces to the system. Ultimately, these forces could destroy the integration. In order to maximize the chance of delivering an adequately fitting restoration, the framework is made in segments. One segment for each fixture is made. In the laboratory, the individual segments are evaluated for fit onto a fixture. If all are acceptable, an intraoral solder index is made. Once soldered, the framework is re-evaluated on a verification index.

The mechanical compromise of the "UCLA" Abutment system is that, if for some reason a poorly fitting restoration is delivered, the adverse forces will be introduced but the "UCLA" Abutment technique does not contain a "weak link" to alleviate the stress. Bone loss and even loss of integration may occur.

### "EsthetiCone" Abutment

The EsthetiCone is a titanium abutment designed for esthetic implant restorations. It is a pure titanium abutment which is retained to the implant with a titanium abutment screw. The titanium-to-titanium interface eliminates the concern over galvanism.

The EsthetiCone abutments have three different size collars (1 mm, 2 mm, 3 mm). The titanium collar provides a titanium-to-soft-tissue interface. In order to develop an esthetic restoration, it is best to begin the restoration approximately 2-3 mms beneath the mucosa. In this space, the technician can create a natural and gradual emergence profile with the appearance of a natural tooth at the gingival margin. A collar height is selected which allows for the 2 - 3 mm distance. If the selected collar is too tall, inadequate space exists for a proper emergence profile. If the collar is too short, the resultant pocket depth may be too great and soft tissue health could be a concern. An advantage of the EsthetiCone abutment versus the UCLA technique is that by selecting collar height, one can control the level of the restorative/abutment interface, thus controlling pocket depth.

Tapered impression copings and square impression coping provide impression techniques similar to the standard abutments. Square impression copings are recommended for final impressions since they are never separated from the impression until after the cast is poured. Laboratory analogs



represent the abutments in the cast and, as with any subgingival implant restoration, soft tissue casts are preferred.

The gold alloy cylinder fits over the abutment or laboratory analog. It becomes part of the wax pattern and ultimately part of the final casting. In this way, the final restoration fits intraorally over the abutments and is retained with small gold alloy screws. The gold cylinders do not contact the lateral walls of the abutments. The contact of these gold cylinders, and hence the final restoration, is only at the base of the gold cylinder. With this design, if adverse forces are introduced to the system such as by delivering a poorly fitting restoration, it is the small gold retention screw which bears the stress. These screws are weak and will most likely loosen or break under this type of load. The gold screws thus act as "weak links" indicating overload before the bone-implant interface is adversely affected. If these screws do loosen, they are very easily retrievable by simply removing the abutment screw which acts as a housing for the gold screw. The gold screw comes out with the abutment screw. It should be noted that proper tightening of the screw joints is always recommended to provide the most stable support system. Titanium abutment screws are tightened to 20 Ncm while the gold retention screws are tightened to 10 Ncm.

Since the EsthetiCone does provide esthetic implant restorations by beginning 2-3 mm beneath the gingival margin, the same difficulty in evaluating fit of the framework exists as it does with the "UCLA" technique. For this reason, it may be beneficial to fabricate the framework in segments similar to the "UCLA" technique. A solder index is made and the soldered framework is checked on the verification cast. The advantage of the EsthetiCone is that while both techniques provide esthetic restorations, they also make it difficult to evaluate the final fit because of the subgingival base. At least the "EsthetiCone" contains a mechanical weak link in case a poorly fitting restoration is delivered.

### Implant Positioning

Implant positioning is far more critical when treating the partially edentulous patient than when treating the edentulous patient. Limited resorption and the design of restorations to emerge directly through the mucosa make positioning a key to success. The restorations are much more directly affected by the implant positioning in the partially edentulous patient than in the edentulous patient.

Interproximal positioning leads to poor esthetics and often compromised hygiene.

Buccal positioning leads to poor esthetics. Angulated abutments or custom-made abutments may overcome the buccal compromise but the techniques are time consuming and costly. Often the biomechanical principles are compromised with these solutions as well.

Lingual positions leads to ridge laps and poor hygiene access.

Inadequate apical positioning leaving little room to develop an acceptable emergence profile can also lead to poor esthetics and hygiene.

As a general rule for anterior esthetic implant restorations, the fixtures should be:

1. As close to the facial as possible without interfering with the facial. Therefore, the restoration will have normal buccal/lingual contours. Ridge lapping will not be necessary. By being just lingual to the incisal edge, the facial contours will not be infringed upon.
2. Centered mesial/distally.
3. Apically positioned 3-4 mm beneath the gingival margin.

It is important to note that the restoration must dictate implant placement. If the anatomy does not allow for ideal implant placement, the anatomy must be altered surgically.

In order to design the implant restoration prior to surgery, diagnostic casts must be articulated. A diagnostic wax-up is performed to design the final restoration. At this time, hard and soft tissue defects may be noted. If this is true, surgical correction of the defect must be planned prior to implant placement or simultaneous to implant placement. Only very minor soft tissue defects can be adequately addressed after the fixtures are placed. It is important to remember that hard and soft tissue defects are best restored with hard and soft tissue rather than restorative materials.

The need for orthodontics may be evaluated at the diagnostic wax-up stage. If orthodontic therapy is necessary, it must be completed prior to implant placement.

The diagnostic wax-up is converted into a surgical template. If the wax-up designs the final restoration, it is the template which conveys this information to the surgeon at the time of surgery. With this template, the restorative design can truly dictate the placement of the implant fixtures. The template can also be very useful at the time of surgery to visualize hard and soft tissue defects. Remember, it is at this time that these defects must be addressed.

Once integrated and uncovered, fixed provisional restorations should be fabricated on the implants. The fixed provisional should be used to reconfirm the restorative design prior to fabrication of the definitive restoration. Minor compromises may exist even with the use of diagnostic wax-ups and surgical templates, and the implant provisional is useful in determining the best design for the final restoration.

#### RECOMMENDED READING

Lewis S, Beumer J, Hornburg W, et al. The "UCLA" abutment. *Int J Oral Maxillofac Implants* 3:183-189, 1988.

Lewis S. An esthetic titanium abutment report of a technique. *Int J Oral Maxillofac Implants* 6:195-201, 1991.

Parel S, Lewis S. The EsthetiCone: an abutment alternative for esthetic implant restorations. *Esthetic Dent Update* 2;2:29-31.

Lewis S, Beumer J. Aesthetic considerations in implant reconstruction. *Oral and Maxillofac Clinics of North America* 3;4:965-978, 1991.

Parel S, Lewis S. The SmiLine System. Taylor Publishing. Dallas, TX, 1991.

## ESTHETIC IMPLANT RESTORATIONS

Adell R, Lekholm U, Rockler B, et al: A 15 year study of osseointegrated implants in the treatment of the edentulous jaw. *Int J Oral Surg* 6:387-416, 1981.

This article was one of the first to introduce the concept and treatment results of osseointegration. Edentulous patients treated by P-I Branemark and his colleagues were evaluated over a fifteen year period. During this period (1965-1980), 2768 fixtures were installed in 410 edentulous jaws of 371 consecutive patients. These edentulous patients were restored with fixed bone anchored bridges.

From this population a pilot group with observations from 5-9 years was selected to reflect the potential of the treatment methods. In this group 130 jaws were provided with 895 fixtures, and of these 81% of the maxillary and 91% of the mandibular fixtures were considered successful. This patient population also exhibited a restoration success rate of 89% in the maxilla and 100% in the mandible.

While adapting this technology in order to provide partially edentulous patients with esthetic restorations has involved modification of components and techniques, this report by Adell et al remains the standard to which we compare success.

Lewis S, Beumer J, Hornburg W, et al: The "UCLA" abutment. *Int J Oral Maxillofac Implants* 3:183-189, 1988.

The restorations achieved by Branemark and his colleagues revolutionized dentistry by providing edentulous patients with long-term successful results. The improvement in comfort and function for this patients was extraordinary. When the components and techniques developed by this group were applied to the partially edentulous patient population certain compromises resulted. A very significant concern was that of esthetics. The components designed for edentulous fixed bone anchored bridges did not provide esthetic

results. Rather than have a titanium cylinder emerge through the support tissue to support the restoration, it was desirable to begin the restoration beneath the mucosa and allow it to emerge with a natural and gradual appearance. By beginning the restoration directly to the implant fixture utilizing a "UCLA" abutment, it was possible to develop a natural and gradual emergence profile resulting in the appearance of a natural tooth at the level of the gingival margin.

Besides the improved esthetics of the multiple implant restoration using this technique of connecting directly to the implant fixture, the "UCLA" abutment also provided esthetic and functional single tooth implant restorations (Lewis S, Beumer J, Perri G, et al: Single tooth implant supported restorations. *Int J Oral Maxillofac Implants* 3:25-30, 1988).

Lewis S: An esthetic titanium abutment: report of a technique. *Int J Oral Maxillofac Implants* 6:195-201, 1991.

Parel S, Lewis S: The EsthetiCone: an abutment alternative for esthetic implant restorations. *Esthet Dent Update* 2:29-31, 1991.

While the "UCLA" abutment solved the demand of improved esthetics for partially edentulous implant supported restorations, it altered some of the basic principles of the implant restorations as developed by Branemark and his colleagues. There no longer was a titanium to titanium interface at the level of the implant fixture. This could potentially lead to concerns of galvanism and corrosion (Engelman M, Avera S: Effect of various alloys on corrosion resistance of osseointegrated implants. Presented at the UCLA Implant Symposium. Palm Springs, California, April 1990). The lack of a titanium to soft-tissue interface and the potential loss of a hemidesmosomal attachment may also be a concern to those who advocate a need for this so called "biologic seal."

The development of a titanium abutment designed for esthetic implant restorations was achieved in order to provide similar esthetic results as the "UCLA" abutment while maintaining many of the biomechanical principles of the components developed and utilized by Branemark and his colleagues. The "EsthetiCone" abutment (Nobelpharma AB, Gothenburg Sweden) is one of several titanium abutments which allows for the implant restoration to begin subgingivally resulting in a natural and gradual emergence profile and an esthetic result. The use of this type of abutment also maintains a titanium to titanium junction at the implant fixture level as well as a titanium to soft tissue interface.

Lewis S, Beumer J: Aesthetic Consideration in Implant Reconstruction. Oral and Maxillofac Surg Clinics of North America 3:965-978, 1991.

The "UCLA" abutment and EsthetiCone abutment are compared. While both abutments may provide equal esthetic results, the biomechanical principles of the EsthetiCone are more similar to those components utilized by Branemark and his colleagues and evaluated for long term results by Adell et al.

It is stressed that no matter which abutment technique is utilized, implant placement remains the key to achieving successful results. Mesial/distal, buccal/lingual, and apical positioning are all critical to achieve a satisfactory result and no abutment can adequately overcome poor implant positioning.

Parcel S, Sullivan D: ESTHETICS AND OSSEOINTEGRATION. Osseointegration Seminars Incorporated, San Antonio, TX, 1989.

Hard and soft tissue contours are critical for optimal esthetics. Deficiencies in either or both of these will result in compromised restorations and must be addressed prior to implant therapy.

Guidelines for proper implant positioning include: 1) as close to the facial as possible without interfering with the facial aspect of the restoration, 2) mesial/distal centering avoiding the interproximal, and 3) adequate apical positioning to that the implant fixture is approximately 3-4 mms beneath the intended emergence of the restoration through the mucosa. With these critical demands, the importance of surgical guide splints is stressed. These devices allow the surgeon to visualize the projected final restoration during implant placement. It must be remembered that the final restoration must dictate the implant positioning, not the anatomy. The surgical splint transfers the design of the final restoration to the surgical site.

Esthetic implant provisional restorations are often useful to confirm the final restorative design prior to fabricating the definitive prosthesis. Several techniques are reviewed in chapter five.

## Articles Dealing with Implant Complications

- Bidez MW, Chen Y, McLoughlin SW, and English CE. Finite element analysis of four-abutment hader bar designs. *Implant Dent* 1993; 2:171-176.
- English CE. Restoration of the maxillary arch with a precision-milled double-bar prosthesis. *Int J of Dent Symposia*. 2:16-19.
- English CE. Implant-supported versus implant-natural-tooth-supported fixed partial dentures. *J of Dent Symposia* August 1993; 10-15.
- English CE. Critical A-P spread. 1992; 3:14-15.
- The mandibular overdenture supported by implants in the anterior symphysis: A prescription for implant placement and bar-prosthesis design. *Dent Imp Update*. 1993; 4:9-14.
- Naert I, De Clercq M, Theuniers G, and Schepers E. Overdentures supported by osseointegrated fixtures for the edentulous mandible: A 2.5 year report. *Int J Oral Maxillofac Implants* 1988; 3:191-196.
- Ibbott CG. In vivo fracture of a basket-type osseointegrating dental implant: A case report. *Int J Oral Maxillofac Implant* 1989; 4:255-256.
- Sones AD. Complications with osseointegrated implants. *J Prosthet Dent* 1989; 62:581-585.
- Zarb GA and Schmitt A. The longitudinal clinical effectiveness of osseointegrated dental implants: The Toronto study. Part II: The prosthetic results. *J Prosthet Dent* 1989; 64:53-61.
- Zarb GA and Schmitt A. The longitudinal clinical effectiveness of osseointegrated dental implants: The Toronto study. Part III: Problems and complications encountered. *J Prosthet Dent* 1990; 64:185-194.
- Jemt T, Laney WR, Harris D, Henry PJ, Krogh PHJ, Polizzi G, Zarb GA, and Herrmann I. Osseointegrated implants for single tooth replacement: A 1-year report from a multicenter prospective study. *Int J Oral Maxillofac Implants* 1991; 6:29-36.
- Jemt T. Failures and complications in 391 consecutively inserted fixed prostheses supported by Branemark implants in edentulous jaws: A study of treatment from the time of prosthesis placement to the first annual checkup. *Int J Oral Maxillofac Implants* 1991; 6:270-276.
- Tolman DE and Keller EE. Management of mandibular fractures in patients with endosseous implants. *Int J Oral Maxillofac Implants* 1991; 6:427-436.
- Naert I, Quirynen M, Theuniers G, and vanSteenberghe D. Prosthetic aspects of osseointegrated fixtures supporting overdentures. A 4-year report. *J Prosthet Dent* 1991; 65:671-680.
- Jemt T, Linden B, and Lekholm U. Failures and complications in 127 consecutively placed fixed partial prostheses supported by Branemark implants: From prosthetic treatment to first annual checkup. *Int J Oral Maxillofac Implants* 1992; 7:40-44.
- Jemt T, Book K, Linden B, and Urde G. Failures and complications in 92 consecutively inserted overdentures supported by Branemark implants in severely resorbed edentulous maxillae: A study from prosthetic treatment to first annual check-up. *Int J Oral Maxillofac Implants* 1992; 7:162-167.



- Shonberg DC, Stith HD, Jameson LM, and Chai JY. Mandibular fracture through an endosseous implant. *Int J Oral Maxillofac Implants* 1992; 7:401-404.
- Tolman DE and Laney WR. Tissue-integrated prosthesis complications. *Int J Oral Maxillofac Implants* 1992; 7:477-484.
- Naert I, Quirynen M, van Steenberghe D, and Darius P. A six-year prosthodontic study of 509 consecutively inserted implants for the treatment of partial edentulism. *J Prosthet Dent* 1992; 67:236-45.
- Karr RA, Kramer DC, and Toth BB. Dental implants and chemotherapy complications. *J Prosthet Dent* 1992; 67:683-7.
- Naert I, Quirynen M, van Steenberghe D, and Darius P. A study of 589 consecutive implants supporting complete fixed prostheses. Part II: Prosthetic aspects. *J Prosthet Dent* 1992; 68:949-56.
- Beumer J, Hamada MO, and Lewis S. A prosthodontic overview. *Int J Prosthodont* 1993; 6:126-130.
- Carlson B and Carlsson GE. Prosthodontic complications in osseointegrated dental implant treatment. *Int J Oral Maxillofac Implants* 1994; 9:90-94.
- Hemmings KW, Schmitt A, and Zarb GA. Complications and maintenance requirements for fixed prostheses and overdentures in the edentulous mandible: A 5-year report. *Int J Oral Maxillofac Implants* 1994; 9:191-196.
- Walton JN and MacEntee MI. Problems with prostheses on implants: A retrospective study. *J Prosthet Dent* 1994; 71:283-8.
- Proceedings of a conference held October 9 and 10, 1992, at the Lansdowne Convention Center, Leesburg, Virginia. *Int J Oral & Maxillofac Implants. Special Supplement Volume 9, 1994.*
- Gunne J, Jemt T, and Linden B. Implant treatment in partially edentulous patients: A report on prostheses after 3 years. *Int J Prosthodont* 1994; 7:143-148.



**Treatment Considerations For The  
Implant Assisted Restoration Of The  
Partially Edentulous Patient**

**Dr. Robert J. Cronin Jr**



**TREATMENT CONSIDERATIONS FOR THE IMPLANT ASSISTED  
RESTORATION OF THE PARTIALLY EDENTULOUS PATIENT**

Robert J. Cronin, Jr., DDS, MS  
Associate Professor  
Division of Graduate Prosthodontics  
Department of Prosthodontics  
University of Texas Health Science Center at San Antonio

**Scientific Basis for Implant Use in Partially Edentulous Patients:**

1. Nevins M. and Langer B.: The successful application of osseointegrated implants to the posterior jaw: A long-term retrospective study. *Int J Oral Maxillofac Implants* 8:428-432,1993.

This long-term study has demonstrated the successful use of osseointegrated implants to replace posterior teeth in the partially dentate patient. A total of 1,203 Nobelpharma implants placed by two periodontists practicing in traditional office settings were included in the survey. Of the 551 implants placed in the mandible, 25 failed, for a success rate of 95.5%. Of the 247 mandibular prostheses fabricated for 200 mandibles, 8 failed, for a prosthesis stability rate exceeding 97%. Of the 652 implants placed in the maxilla, 31 failed, for a success rate of 95.2%. Of the 2150 maxillary prostheses fabricated for 193 maxillae, 2 failed, for a success rate exceeding 99%. The results compare favorably to previous reports in terms of implant survival and stability.

2. Schumann, D.: FDA and ADA evaluation of dental implants. *Journal of Public Health Dentistry* 52(6):373-4,1992.

The FDA classification of endosseous dental implants (EDI) is reviewed. Factors impacting the long-term efficacy of dental implants and the guidelines for development of EDI are enumerated. The role of the ADA in evaluation of EDIs is also discussed. Recommendations for development of performance criteria and reporting format are made.

3. Gunne, J., Astrand P., Ahlen K., Borg K., and Olsson M.: Implants in partially edentulous patients. A longitudinal study of bridges supported by both implants and natural teeth. *Clin Oral Impl Res* 3:49-56,1992.

The aim of the study was to compare the outcome of bridges supported by implants with bridges supported by a combination of implants and natural teeth abutments. The study comprised 23 patients with Applegate Kennedy Class I dentition in the mandible and a full upper denture. Implants ad modum Branemark were inserted in the posterior areas of both mandibular quadrants. On one side, a bridge supported by 2 implants was constructed (Type I) and on the other side, a bridge supported by 1 tooth (mostly the canine or first premolar) and 1 implant was made (Type III). A total of 46 bridges were made and during the 3-year follow-up period, 4 Type I and 2 Type II bridges were lost. Eight out of 69 implants were lost during the 3-year follow-up, resulting in an implant survival rate of 88.4%. Marginal bone loss, one of several parameters, was evaluated on standardized intraoral radiographs. This was performed during the 1st and 2nd year of function and the total mean bone loss from loading was 0.46mm and 0.56mm, respectively. The bone loss during the 2nd year of function was significantly less, adjacent to implants supporting Type II bridges, than adjacent to implants supporting Type I bridges. Summarily, no disadvantages of combining of teeth and implants in the same bridge were found in this study. On the contrary, the slightly lower marginal bone loss adjacent to implants in Type II bridges may indicate that the bone reactions could be more favorable when bridges are connected to both implants and teeth.

4. Friberg B., Jemt T., and Lekholm U.: Early failures in 4,641 consecutively placed Branemark Dental Implants: a study from stage 1 surgery to the connection of completed prostheses. *Int J Oral Maxillofacial Implants* 6:142-146,1991.

This study comprised 4,641 Branemark dental implants, which were retrospectively followed from stage 1 surgery to completion of the prosthetic restorations. The implants were placed during a 3-year period (1986 to 1988) in 943 jaws, representing 889 patients with complete and partial edentulism. The jaw and sex distribution revealed a predominance of mandibles (564/943) and females (534/943). The mean age of the patients was 57.7 years (range 13 to 88 years) at implant placement. Only 69 (1.5%) fixtures failed to integrate, and most losses were seen in completely edentulous maxillae (46/69), in which the jaw bone exhibited soft quality and severe resorption. A preponderance of failures could also be seen among the shortest fixtures (7 mm). A majority of the mobile implants were recorded at the abutment connection (stage 2) operation (48/69).

5. Smith, DE.: Review of endosseous implants for partially edentulous patients. *Int J of Prosthodont* 3(11):12-9, Jan-Feb 1990.

The scientific documentation of the biological acceptability of the Branemark osseointegrated implant has increased the interest in implants. This documentation was done on completely edentulous patients and therefore is not necessarily transferable to partially edentulous patients. Demographic studies indicate an increased need for implant restoration, yet clinical documentation of the effectiveness of implants in the partially edentulous is not nearly as strong as for the completely edentulous patient. There is a great need for well-designed research to compare prosthodontic materials and techniques. This review summarizes the literature on implants in the partially dentate mouth.

6. van Steenberghe D., et al: The applicability of osseointegrated oral implants in the rehabilitation of partial edentulism: a prospective multicenter study on 558 fixtures. *Int J Oral Maxillofac Implants* 5:272-281,1990.

Nine clinical centers using the Branemark System participated in a prospective study of 159 partially edentulous patients between 18 and 70 years of age. Clinical parameters evaluated were plaque index, gingivitis, pocket depth, bleeding index, tooth mobility, and stomatognathic function. Initially, 558 fixtures were placed and 521 remained in the study following prosthesis placement (199 prostheses in 154 patients). Fixtures were lost or unaccounted for because of nonintegration prior to prosthesis fabrication (19), patient withdrawal (11), prosthodontic reasons (6), and failure during prosthetic procedures (1). Failure was primarily attributable to unfavorable bone quality, sex (more in males), and smaller fixture size. Complications and failure related to other patient characteristics are presented. After 1 year of a 5-year study, preliminary results suggest that a success rate equal to or better than that obtained with edentulous patients may be expected.

7. van Steenberghe D.: A retrospective multicenter evaluation of the survival rate of osseointegrated fixtures supporting fixed partial prostheses in the treatment of partial edentulism. *J Prosthet Dent* 61 (2):21 7-23, February 1989.

Whether the excellent prognosis of the osseointegration technique also applies for the rehabilitation of partially edentulous jaws was investigated through a multicenter retrospective study. Six centers from three continents participated in the study, which included 133 fixtures in 38 patients. Forty fixtures were installed in the upper jaw and 93 in the lower jaw. The observation time varied between 6 and 36 months after prosthetic reconstruction. Clinical evaluation included mobility measurement of the restorations and control of infectious or neurologic complication. Radiologically the absence of radiolucency around the fixtures was checked by a single observer who also calculated the distance between the marginal bone and the top of the fixture. Fifty-eight percent of the prostheses were connected to natural teeth. The success rate for the individual fixtures in the upper and lower jaws was 87% and 92%, respectively. The most failures occurred before the prosthetic rehabilitation. The mean maximum distance between the margin of the bone and the fixture-abutment junction was 2.5 mm. Since only two of the 53 fixed prostheses were lost during the observation period, and since most fixture losses occurred before the prosthetic phase of the treatment, this study supports the concept that osseointegrated prostheses can also be applied to the rehabilitation of partial edentulism.

8. Jemt T., Lekholm U., and Adell, R.: Osseointegrated implants in the treatment of partially edentulous patients: a preliminary study on 876 consecutively placed fixtures. *Int J Oral Maxillofac Implants* 4:211-217,1989.

A total of 876 consecutively placed fixtures ad modum Branemark was followed in 268 partially edentulous jaws of 244 patients treated between April 1968 and the end of December 1988. A total of 24 of 712 fixtures exposed at the abutment connection was lost (3%); the continuous prosthesis stability rate was 98.7%, as only four of 293 prostheses were removed. The results of the study indicate the possibility for the Branemark osseointegration technique to be used in the treatment of partial edentulism.

9. Schmitman, et al: Implants for partial edentulism. *J Dent Educ* 52(12):725-736,1988.

Implant design is determined by bone morphology. There is little agreement on which prosthetic abutment configurations are most effective. There does, however, appear to be agreement that a variety of implant designs are necessary if we are to treat the myriad of anatomic conditions we are confronted with in the partially edentulous patient. This article presents a good literature review and the first study defining implant survival rates as a function of implantation site.

10. Zarb GA., Zarb FL., and Schmitt A.: Osseointegrated implants for partially edentulous patients. Interim considerations. *Dent Clin North Am* 31(3):457-72, July 1987.

Osseointegration is a clinical application of a biologically investigated host bone response to the placement of threaded unalloyed titanium implants using a meticulous surgical procedure. Its documented successful use as an analogue for the periodontal ligament in edentulous patients has already profoundly altered the predicament of being edentulous. Its application as a treatment modality for partial edentulism offers exciting challenges for the dentist. This article reviewed preliminary experiences from the University of Toronto's Clinical Osseointegration Unit in this area. Although it is tempting to extrapolate the successful longitudinal clinical applications with edentulous patients to partially edentulous ones, discretion and prudence demand that dentists remember that osseointegration for routine treatment of partially edentulous patients is still in its infancy. Until the results from long-term clinical trials in different centres are published, the dental profession cannot yet subsume the versatility and routine application of this exciting technique.

11. Ericsson L., et al: A clinical evaluation of fixed-bridge restorations supported by the combination of teeth and osseointegrated titanium implants. *J Clin Periodontol* 13:307-312,1986.

The present paper reports on the result of the use of osseointegrated titanium fixtures and teeth as combined abutments for fixed-bridge restorations in 10 partially dentate patients. In these patients, the remaining teeth were too few or too unfavorably distributed in the jaws to serve as sole abutments for fixed bridgework. Titanium fixtures ad modum Branemark were therefore implanted in suitable positions and used as abutments in combination with the remaining teeth. Evaluations at periods of 6 to 30 months postoperatively revealed good clinical results. Some tissue reactions, however, were also observed, indicating the presence of certain clinically significant differences in

the functional behavior of tooth abutments and titanium fixture abutments. These reactions and differences are discussed.

#### Diagnosis and Treatment Planning:

1. Arzouman, MJ., Otis L., Kipnis V., and Levine D.: Observations of the anterior loop of the inferior alveolar canal. *Int J Oral Maxillofac Implants* 8:295-300, 1993.

The inferior alveolar nerve may extend beyond the mental foramen as an intraosseous anterior loop. The purpose of this study was to determine if panoramic radiography accurately identifies the anterior loop of the inferior alveolar canal. Adult skulls (n=25) were radiographed using two panoramic machines both with and without radiopaque markers placed into the inferior alveolar canal and anterior loop. The anterior loop was also measured directly using flexible tubing (2 mm in diameter). Significantly fewer loops were detected in radiographs as compared with anatomic assessment ( $P < .001$ ). A significant loop ( $> 2$  mm) was identified in 92% to 96% of the direct measurements, whereas radiographs identified only 56% (Panelpipe) and 76% (Orthoralix). Analysis of variance demonstrated that the skeletal length of the anterior loop was significantly greater than that measured radiographically ( $P < .0001$ ). The average length of the anterior loop based on direct measurements was 6.95 mm, whereas radiographic measurements were 3.18 mm (Panelpipe) and 3.45 mm (Orthoralix). The difference in detection of anterior loops among the radiographic procedures studied was not significant ( $P > .05$ ).

2. Oesterle LJ., Cronin, RJ., and Ranly DM.: Maxillary Implants and the Growing Patient. *Int J Oral Maxillofac Implants* 8:377-387, 1993.

Maxillary skeletal and dental growth results in dramatic changes in all three dimensions during active growth. Experimental evidence and the behavior of ankylosed teeth suggest that an osseointegrated object remains stationary in the bone surrounding it and does not move or adapt to bone remodeling. Growth changes may result in the burying or loss of implants depending on the placement site. Hence, implants placed in the early mixed dentition have a poor prognosis of continued usefulness through puberty. When placed early, implants may disturb growth or have to be replaced. Implants placed during late puberty or early adulthood have the best chance for long-term usefulness.

3. Baxter JC. and Fattore, L.D.: Osteoporosis and Osseointegration of Implants. *J Prosthodont* 2:120-125, 1993.

According to medical literature, osteoporosis and related bone pathologies are increasing in epidemic proportions. The exact etiology of the disease is unknown, but hormonal, dietary, and genetic factors all contribute to the related loss of bone density. In the disease process, bone loss occurs throughout the body. Research indicates that the mandible and maxilla are affected, and show oral manifestations. There is no scientific data to contraindicate the use of two-step osseointegrated implants in osteoporotic individuals. The purpose of this article is to review the literature regarding osteoporosis and its relationship to oral bone loss.

4. Lemons JE., Lucas LC., and Johnansson BI.: Intraoral corrosion resulting from coupling dental implants and restorative metallic systems. *Implant Dentistry* 1(2):107-12, Summer 1992.

Materials used for the construction of dental restorations and implants include a wide range of metals and alloys, ceramics and carbons, and polymers. When metals and alloys are placed in direct contact in the oral cavity, a galvanic cell can be formed that may compromise the longevity of one or more of the materials in the couple. In vitro electrochemical corrosion analyses have proven to be a valuable tool for providing guidance on the selection of metallic materials. These analyses can provide basic data on electrochemical potentials, current rates, and the evaluation of galvanic corrosion conditions. This article seeks to provide the clinician with information that can be valuable in the selection of metallic materials that may be placed in direct contact with one another in the oral cavity.

5. Williams MY., Mealey BL., Hallmon WW.: The role of computerized tomography in dental implantology. *International Journal of Oral & Maxillofacial Implants* 7(3):373-80, Fall 1992.

Dental implant therapy has dramatically expanded the treatment options available for both the partially and completely edentulous patient. Advances in the use of dental implants have necessitated the inclusion of additional diagnostic procedures in the treatment planning process to optimize the site and angulation of fixtures and, consequently, the success of prosthetic restorations. One of these procedures is computerized tomography. Originally introduced as a medical diagnostic technique, it has been adapted for many uses in dentistry. This article reviews the role of computerized tomography in dental implantology. Its advantages, disadvantages, and indications are presented.

6. Bidez MW. and Misch CE.: Force transfer in implant dentistry: basic concepts and principles. *Journal of Oral Implantology* 18(3):264-74, 1992.

The mechanism and efficiency of force transfer by dental implants to contiguous biological tissues are clearly important determinants in the development of the implant-to-tissue interface and, indeed, implant longevity. Whether a clinician seeks to gain a better understanding of implant design rationale and/or to implement biomechanics concepts in patient care, a fundamental, yet clinically relevant, understanding of biomechanics is required. A primer in force transfer is thus presented, with particular attention focused on implications for the long-term success of dental implants and restorative procedures. Forces and their components, moments, force transfer mechanisms, impact, and

stress-strain relationships all influence clinical decisions and treatment plans.

7. Taylor TD and Worthington P.: Osseointegrated implant rehabilitation of the previously irradiated mandible; results of a limited trial at 3 to 7 years. *Journal of Prosthetic Dentistry* 69(1):60-9, January 1993.

The use of osseointegrated dental implants in patients with defects of the head and neck acquired as a result of ablative surgery for malignancy is an accepted and valuable extension of the well-documented use of these implants for the treatment of edentulism. In patients who have received ionizing radiation as part of tumor therapy, the use of dental implants is poorly documented. A limited trial of 21 Branemark implants placed in the previously irradiated mandibles of four patients is reported here. The implants have been in place and functioning for periods of 3 to 7 years. No implants have been lost. Patient selection, treatment, and complications encountered are discussed. Guidelines for further use of osseointegrated implants in patients with previously irradiated mandibles are suggested.

8. Meffert RM., Langer B., and Fritz ME.: Dental Implants: a review. *Journal of Periodontology* 63(11):859-70, November 1992.

The present article is a review presenting an update on the field of dental implants since the World Workshop in Clinical Periodontics in July 1989. Areas that are discussed include following: 1. Biomaterials and the implant interface, and the interaction of these with the environment. 2. Periodontal considerations including data supporting a perimucosal seal of implant to soft tissue and discussion of the endosseous interface between the bone and the implant. 3. Newer techniques of diagnostic imaging and their determination of bone types are related to the future practice of dental implants. 4. Implant selection and the surgical techniques involved in implant placement. 5. Current ideas of implant prosthodontics, implant maintenance, and the treatment of implant failures. 6. Finally, the use of dental implants in the United States and Sweden.

9. Tal H., and Moses O.: A comparison of panoramic radiography with computed tomography in the planning of implant surgery. *Dento-Maxillo-Facial Radiology* 20(1):40-2, February 1991.

The accuracy of panoramic radiography and computed tomography (CT) in the evaluation of depth of the mandible at recipient implant sites was compared by measuring the distance between the edentulous bony crest and the superior border of the inferior alveolar canal in a group of ten patients. Distortion was calculated using the metal ball technique for the panoramic radiographs and the computer scale for the CT scans. The precise distance between the bony crest and inferior alveolar canal was determined from postoperative radiographs from the known length of the implants. It was found that although CT scans are more precise, panoramic radiography is sufficiently accurate for routine clinical purposes. CT scans have, however, an additional advantage in presurgical planning, since they reveal the horizontal dimension and shape of the mandible, and the topography and buccolingual location of the inferior alveolar canal.

10. Odman J., Grondahl K., Lekholm U., and Thilander B.: The effect of osseointegrated implants on the dento-alveolar development. A clinical and radiographic study in growing pigs. *European Journal of Orthodontics* 13(4):279-86, August 1991.

In an attempt to study the effect of osseointegrated implants on vertical dento-alveolar development, six growing pigs of the Pigham strain were used, one of them randomly selected as a control. The test pigs received four fixtures each, three in the lower jaw and one in the upper. The fixtures were placed in areas where different patterns of the dento-alveolar development were expected. The clinical and radiographic findings have clearly shown that the implants do not behave like normal erupting teeth during the development of the dentition. Neither do the fixtures move together with the adjacent teeth, but behave more like ankylosed teeth.

11. Quirynen M., et al: CT scan standard reconstruction techniques for reliable jaw bone volume determination. *Int J Oral Maxillofac Implants* 5(4):384-9, 1990.

Computed tomography can assist the surgeon in planning the exact three-dimensional positioning of endosseous implants in the jaw bone. This study examined the reliability of three CT techniques: direct imaging (normal coronal and sagittal slices), standard reconstruction (based on axial slices), and multiplanar reconstruction and display (also based on axial slices). The three imaging techniques were used to estimate the bone height, bone width, and maximal implant length in six dissected human jaw bones. These jaws were then sawed perpendicular to their axis to enable measurement of real values for comparison. The sagittal and coronal slices frequently were overestimated, especially in the canine and premolar regions. The mean absolute deviation was 1.4 mm. Standard reconstruction offered the most reliable cross-sectional images, with a mean absolute deviation of 0.5 mm. The multiplanar reconstruction and display was 2.3 mm). The standard reconstruction technique seems to be the method of choice in preoperative radiographic examination of patients before implant placement.

12. Paterson DJ., Foster FL., and Smith PF.: Clinical applications of osseointegrated implants. *Canadian Dental Association Journal* 56(5):411-6, May 1990.

In the described seven case reports, the authors have demonstrated a number of varied applications of osseointegrated implant techniques including both removable and fixed prostheses. All patients had expressed dissatisfaction with previous prosthetic efforts to restore a satisfactory level of mastication or a desire to do away with removable oral prostheses. A high level of patient satisfaction was achieved through the application of implant techniques in these patients. Proper treatment planning must now include a consideration of implant



dentistry as well as the previously available conventional alternatives for our edentulous and partially edentulous patients.

13. Kassebaum DK., et. al.: Cross-sectional radiography for implant site assessment. *Oral Surgery, Oral Medicine, Oral Pathology* 70(5):674-8, Nov 1990.

An accurate tomographic technique is described for acquisition of optimal cross-sectional images of implant sites before implant surgery. The described technique is applicable to tomographic systems equipped with a cephalometric head positioner. This cross-sectional tomographic technique was performed on a series of patients and the images of the first 20 patients subsequently evaluated. The cross-sectional images allowed for the characterization of the alveolar crest and visualization of anatomic structures in a buccolingual dimension while providing an accurate estimation of available vertical space from the crest.

14. Jackson TR.: Removable partial overdentures with natural root structure and osseointegrated fixtures. *Dent Clin North Am* 34(4):711-28, October 1990.

The development and refinement of osseointegrated fixtures have had primary impetus in treatment of the totally edentulous patient. The same principles, however, may be applied to the partially edentulous patient. Osseointegrated fixtures used in conjunction with mechanical or magnetic attachments may be used to construct partial or full overdentures. This allows treatment with removable prosthodontics in many cases in which it is not practical to achieve anchorage for a fixed prosthesis.

15. Schwartz MS., et. al.: Computed tomography in dental implantation surgery. *Den Clin North Am* 33(4):555-97, October 1989.

High-resolution thin section CT with cross-sectional oblique and panoramic CT reconstruction has been shown to be an excellent tool for the preoperative evaluation of the mandible and maxilla for dental implant surgery. Oblique cross-sections throughout the entire surgical field allow visualization of osseous topography as well as related internal anatomic structures such as the inferior alveolar canal, the mental foramina, the incisive canal, and the maxillary sinuses. Armed with this knowledge, the surgeon-restorative dentist team can plan fixture positioning more effectively, thereby minimizing surprises in the operating room. Cases with inadequate buccolingual bone dimension are not attempted, whereas many other cases that do not appear to have adequate bone, as seen on conventional x-ray films, can be successfully implanted. The ultimate prosthesis is optimized because the surgeon can take full advantage of the available bone to achieve proper fixture alignment. It is quite likely that as future experience is obtained with maxillofacial CT, it may also be useful in diagnosis and treatment for a wide variety of other disorders of the jaw.

16. Rothman SL., et. al.: CT in the preoperative assessment of the mandible and maxilla for endosseous implant surgery. *Radiology* 168(1):171-5, July 1988.

A new computer software program that generates panoramic and oblique computed tomography scans was used to examine 205 patients who were being considered for endosseous dental implants in the mandibular or maxillary arches. This technique allowed recognition of the course of the inferior alveolar nerve canal and measurement of the alveolar ridge, which facilitated the design and placement of an optimal dental prosthesis.

#### **Prosthodontic Treatment:**

1. Carr AB.: Comparison of impression techniques for a two-implant 15-degree divergent model. *International Journal of Oral and Maxillofacial Implants* 7(4):468-75, Winter 1992.

To consistently provide passively fitting implant superstructures, an understanding of the accuracy and precision of all phases of fabrication and connection is required. The initial phase of fabrication, ie, impression making and cast forming, was investigated in an earlier report for a mandibular five-implant model. The current study evaluates the accuracy of working casts produced from impressions using two different transfer copings in a 15-degree divergent two-implant posterior mandibular model. While the indirect method is less cumbersome to use, it was found to be less accurate in the prior study. The purpose of this study was to see if the direct method is more precise for this clinical situation. A transfer was deemed effective in producing experimental casts if distances between specified points on the cast agreed with the corresponding distances on the master cast. The absolute value of the difference in distances between experimental and master casts was compared for the two techniques (two-sample t tests). No significant differences were noted (P: .05), and the power of the tests ranged from 0.70 to 0.96 against the one-sided hypothesis that the direct method had a smaller mean absolute difference in distance than the indirect method. This suggests no clear advantage in using the direct method in similar clinical situations. Comparison of these findings to other impression accuracy studies is made.

2. Jorneus L., Jemt T., and Carlsson L.: Loads and designs of screw joints for single crowns supported by osseointegrated implants. *International J of Oral & Maxillofacial Implants* 7(3):353-9, Fall 1992.

The problem of screw stability was approached in this study by calculating the maximum occlusal forces in vivo for patients with single

implant restorations (which use only one screw to secure the prosthetic reconstruction to the implant). The measurements of occlusal forces together with geometric parameters for the individual patients were used to determine the necessary holding capabilities of the screw joint. Different screw designs were tried in bench test situations and the results were compared with clinical situations. A gold alloy screw with a flat head and high tightening torque (35 Ncm) produced the best results.

3. Carr AB., and Brantley WA.: Titanium alloy cylinders in implant framework fabrication: a study of the cylinder-alloy interface. *Journal of Prosthetic Dentistry* 69(4):391-7, April 1993.

Titanium alloy has been proposed as a suitable alternative to noble metal alloys in premanufactured metal cylinders for fabricating implant prosthesis frameworks. The interfaces produced by standard lost wax procedures that use titanium and conventional noble metal implant cylinders with both high-fusing (high-palladium) and low-fusing (high-gold) noble metal casting alloys were compared. Elemental analysis by scanning electron microscopy and energy-dispersive spectroscopy (SEM/EDS) of the two titanium cylinders revealed that one commercial product had a composition similar to that for commercially pure titanium and the other had a composition consistent with that for Ti-6Al-4V alloy. The SEM observations and complementary elemental line scans indicated that the interfaces between the titanium cylinders and the two noble metal casting alloys did not meet proposed criteria for acceptable metal-to-metal unions. The interfaces between the noble metal cylinders and noble metal casting alloys did exhibit acceptable unions. The SEM observations and elemental analyses were supported by push-shear test results that showed that the resistance to failure was appreciably greater for interface specimens produced with alloy cast to noble metal cylinders compared with titanium cylinders.

4. Assif D., Fenton A., Zarb G., and Schmitt A.: Comparative accuracy of implant impression procedures. *International J of Periodontics & Restorative Dentistry* 12(2):112-21, 1992.

In this study, four impression procedures were assessed for accuracy in a laboratory model that simulated clinical practice. The accuracy of stone casts with brass implant analogs was measured against a standard framework. The fit of the framework on the casts was tested by manual and visual judgment and by microscopic measurement. The measurements supported the clinical judgments. When acrylic resin was used to splint transfer copings in an impression, all casts were acceptable and were more accurate than the best of the two other procedures, which did not use an acrylic resin splint. When an impression material was used to orient the transfer copings, the accuracy was better if undercut copings remained in the impression. When impressions were made by removing an impression from smooth transfer copings and replacing the copings in the impression, the majority of casts were unacceptable.

5. Rigdon TF.: Retrievable/fixed prosthetics for implant and natural dentitions. *Int J of Oral Implantology* 8(1):59-62, 1991.

Even though restorative procedures employed in oral implantology vary from traditional restorative techniques, meticulous attention to the sound, time-tested prosthetic principles of traditional restorative procedures are the basis on which the foundation of implant prosthodontics is based. In addition, the retrieval of a portion of/or the entire implant prosthesis to facilitate serviceability and/or oral hygiene maintenance is often desirable. To this end, the Castable-Telescopic Screw is unique in that it allows retrievability of implant prosthetics without compromise to sound prosthetic principles. In addition to retrievability, the Castable-Telescopic Screw offers flexibility of prosthetic design, maximum strength, a perfected occlusal scheme, life-like esthetic results, and is applicable with natural abutments as well as implant abutments. This paper outlines the potential, the indication, and advantages of the attachment. A case study is presented to demonstrate one of the many applications of the Castable Telescopic Screw.

6. Gracis SE., Nicholls JL., Chalupnik JD., and Yuodelis RA.: Shock-absorbing behavior of five restorative materials used on implants. *Int J Prosthodont* 4(3):282-91, May-June 1991.

The damping effect of five restorative materials used to veneer test crowns rigidly connected to a Branemark implant and subjected to an impact force was measured. These materials included a gold alloy; a noble metal ceramic alloy; porcelain; a laboratory-processed, light-activated microfilled resin; and a heat- and pressure-polymerized poly(methyl methacrylate) resin. The two resins were found to reduce the impact force by about 50% when compared to porcelain or the alloys. The clinical significance of the results is discussed.

7. Chiche GJ., and Pinault A.: Considerations for fabrication of implant-supported posterior restorations. *Int J Prosthodont* 4(1):37-44, January-February 1991.

Implant-supported posterior restorations must be fabricated following established prosthodontic principles. The need for screw-retained abutments and the narrow diameter of root-form implants dictate additional treatment protocols that fall beyond the scope of conventional prosthodontics. Cemented restorations offer simplicity and good control of morphology, but can only be considered if removal or no reserving of the restoration is anticipated. Screw-retained restorations allow for reserving or remediation but necessitate centering of the retaining screw within the occlusal anatomy. When the implant is misaligned, axis problems are solved with preangled copings, custom copings, or double frameworks. The diameter of root-form implants is significantly smaller than posterior natural teeth, and the emergence of the restorations must be progressively flared to achieve proper morphology. Limited interocclusal space and implant placement may dictate restoring posterior teeth as premolars, selecting a short abutment or a nonsegmented ("UCLA") abutment, or overlapping the crowns over the soft tissues. The final abutment selection is best assisted with a diagnostic waxing and with provisional restorations anticipating the completing treatment.

8. Hobo, S.: Occlusion for the osseointegrated prosthesis. *The Journal of Gnathology* 10(1):9-17, 1991.

The osseointegrated implant does not have periodontal tolerance like the natural teeth, nor does it have specific defense mechanisms against occlusal forces. Osseointegrated implants have shown high standards of success, but these success rates depend not only on meticulous surgical protocol but also on understanding the concepts of occlusion. With the osseointegrated implant, the prosthesis is connected firmly to fixtures so that any occlusal stresses generated are transmitted directly to the surrounding bone. Therefore, the prosthesis must be fabricated as accurately as possible in order to achieve long-term success. Occlusion should be a key factor to the overall success rate.

9. Hobkirk JA., and Schwab J.: Mandibular deformation in subjects with osseointegrated implants. *Int J Oral Maxillofacial Implants* 6:319-328, 1991.

Relative movement and force transmission between osseointegrated (OI) implants in the premolar regions of the edentulous mandible have been measured using intraoral transducers linked to OI implants. These have shown deformations of up to 420  $\mu$ m and force transmission of up to 16 N as a result of jaw movement from the rest position. Greater displacements and forces were observed in active opening and protrusion than in lateral excursions. There were wide variations from subject to subject, and while the effects of these phenomena are not known, they may be potentially harmful to the interfaces between the implants and bone and the various components of the implant superstructure.

10. Jemt T., et. al.: Osseointegrated implants for single tooth replacement: a 1-year report from a multicenter prospective study. *Int J Oral Maxillofacial Implants* 6:29-36, 1991.

One hundred seven dental implants were inserted to support single tooth restorations in 92 patients participating in a prospective multicenter investigation. Only three implants (2.8%) were lost after 1 year of clinical function. Most of the remaining restorations were esthetically successful by using modified components. The gingival condition was healthy around the single crowns and coincided well with the clinical situation around the permanent teeth. The most obvious problem experienced during the first year was related to loose abutment screws. Twenty-six percent of the screws retaining crowns were retightened during the observation period, but the frequency of loose screws had a tendency to decrease as the study progressed.

11. Lewis S.: An esthetic titanium abutment: report of a technique. *Int J Oral Maxillofacial Implants* 6:195-201, 1991.

New esthetic two-piece titanium abutment cylinders have recently been introduced for the Branemark implant system. The conical design allows for the fabrication of fixed partial dentures with improved esthetics compared to the conventional abutment design. The improved feature provides for the ability to begin the restoration closer to the implant while still maintaining a titanium/soft tissue interface. Two designs, one short and one long, are currently being produced. The components, techniques, and clinical advantages of the short two-piece esthetic abutments are reviewed.

12. Humphries RM., Yaman P., and Bloem TJ.: The accuracy of implant master casts constructed from transfer impressions. *Int J Oral Maxillofac Implants* 5(4):331-6, 1990.

The accuracy of master casts fabricated from three impression techniques commonly used with the Branemark System was measured. Points placed in a metal surrogate model and onto master abutments were compared after abutments were transferred to stone casts using splinted and unsplinted impression coping techniques. The mean values and standard deviations of each of the reference points on 12 total casts were compared with the values for each point from the surrogate model. Values from techniques using splinted and unsplinted squared polymer copings as well as unsplinted tapered hydrocolloid copings were not significantly different from values recorded from the master surrogate model. Tapered hydrocolloid copings yielded a higher correlation to coordinate values on the master than unsplinted squared polymer copings or splinted squared copings.

13. Spector MR., Donovan TE., and Nicholls JL: An evaluation of impression techniques for osseointegrated implants. *J Prosthet Dent* 63(4):444-7, April 1990.

A passive fit between osseointegrated implants and the prosthesis they will support has been advocated. An experimental model was developed to test the accuracy of three impression techniques and the components used to make the transfer records. Statistically, no significant difference was found between the three methods tested. From this initial study, it appears that further work is needed to isolate techniques that will predictably provide accurate registration of the position of endosseous implants.

14. Fischman B.: The rotational aspect of mandibular flexure. *J Prosthet Dent* 64:483-5, 1990.

A rotational aspect to mandibular flexure has been demonstrated by means of photographic comparisons. The importance of this movement in relation to anatomic considerations, periodontal therapy, restorative dentistry, and implant supported prosthesis, is discussed.

15. Kallas T., et. al.: Clinical evaluation of angulated abutments for the Branemark system: a pilot study. *Int J Oral Maxillofac Implants* 5(1):39-45, Spring 1990.

Where fixture placement and inclination had not been optimal from a restorative perspective, angulated abutments were used to overcome compromised esthetic and functional results in situations of complicated anatomy. The angulated abutment is a treatment adjunct that provides flexibility for ensuring successful treatment when a variety of reconstruction problems are confronted.

16. Eckert SE., and Laney WR.: Patient evaluation and prosthodontic treatment planning for osseointegrated implants. *Dent Clin North Am* 33(4):599-618, October 1989.

This article describes the pertinent medical and dental indications and contraindications for implant-supported prostheses. The importance of a thorough clinical investigation as well as the evaluation of appropriate radiographs and diagnostic casts prior to surgical intervention is emphasized. The cooperation of the surgeon and prosthodontist is essential for implant success; their appropriate roles are discussed. The various prosthetic options are evaluated with emphasis on the advantages and disadvantages of each. Those factors that create the ideal implant candidate are reviewed along with corrective measures that would be required to improve the condition of those patients who are not ideal candidates for implants.

17. Henry, P.J.: Treatment planning for tissue integrated prosthesis. *Int Dent J* 39(3):171-82, September 1989.

The concept of osseointegration and its clinical application in tissue integrated prosthesis has opened up many new avenues in treatment planning for missing teeth. A protocol for controlling the sequencing of diagnostic steps in the formulation of a treatment plan has been presented. The protocol is applicable to the completely edentulous mouth, the partially edentulous jaw, the missing single tooth and the extra-oral maxillofacial prosthetic case. Use of the protocol will ensure predictable treatment results and minimize the risk of complication and failure.

18. Langer E., and Sullivan DY.: Osseointegration: Its impact on the interrelationship of Periodontics and Restorative Dentistry. Part I. - *Int J Periodontics Restorative Dent* 9(2):85-105, 1989. Part II. - *Int J Periodontics Restorative Dent* 9(3):165-183, 1989. Part III - *Int J Periodontics Restorative Dent* 9(4):241-261, 1989.

The concept of osseointegration has been reviewed along with the appropriate diagnostic criteria for successful surgical placement techniques and soft tissue management. It appears that a broad spectrum of restorative applications are possible with predictable fixture survival. Once a viable scientifically valid and predictable implant procedure was developed, it was a natural progression to incorporate the concept into periodontal-prosthetic treatment. Conventional periodontal prosthetics has been replaced by Fixture Assisted Dental Reconstruction. Careful attention to detail, both surgical and prosthodontic, is required, as in the need to maintain precision in both mechanical components and the organic occlusions.

19. Hobo S., Ichida E., and Garcia LT.: Osseointegration and occlusal rehabilitation-Quintessence Publishing Co., Ltd., Tokyo, Japan, 1989.

20. Parel SM, and Sullivan DY.: Esthetics and Osseointegration. Taylor Publishing Company, Dallas, TX, 1989.

21. Lewis SG., et al: Single tooth implant supported restorations. *Int J Oral Maxillofac Implants* 3:25-30, 1988.

When used appropriately, this technique can provide an extremely esthetic restoration with less opportunity for rotation and loosening when compared to the conventional method of connecting the restoration to the abutment cylinder.

22. Ohnell L-O., et. al.: Single-tooth rehabilitation using osseointegration. A modified surgical and prosthodontic approach. *Quintessence Int* 19(12):871-876, 1988.

This paper described (1) a modified surgical procedure which is performed immediately following extraction of a tooth and (2) a simplified prosthetic procedure for replacing a single missing tooth according to the Branemark technique. These procedures will reduce the length of the treatment period and improve esthetics.

23. Jones SD., and Jones FR.: Tissue-integrated implants for the partially edentulous patient. *J Prosthet Dent* 60(3):349-54, 1988.

This article recommends procedures for patient evaluation, diagnosis, and treatment planning for partially edentulous patients requiring restorative treatment that includes tissue-integrated implant fixtures. Successful prognosis is directly related to proper diagnosis and treatment planning. Too few remaining teeth or teeth too sparsely positioned to serve as single or distal abutments for fixed partial dentures may indicate the use of implants.

24. Lewis S.. et al: The "UCLA" Abutment. *Int J Oral Maxillofac Implants* 3:183-189, 1988.

A technique has been developed to fabricate implant-supported restorations directly to Branemark implant fixtures, bypassing the traditional transmucosal abutment cylinders. This method provides for improved esthetics and soft-tissue health, and also solves the frequent problem of limited interocclusal space.

#### The Tooth/Implant Connection - A Restorative Controversary:

1. Weinberg LA.: The biomechanics of force distribution in implant-supported prostheses. *International Journal of Oral and Maxillofacial Implants* 8(1):19-31,1993.

Force distribution with natural teeth depends on micromovement induced by the periodontal ligament. The location and cusp inclination of the tooth qualitatively alter the force pattern. Osseointegrated implants do not have micromovement associated with force distribution. Force distribution to the osseointegrated implant interface is completely different than with natural teeth. Alterations in tooth location and cusp inclination are suggested to limit implant overload. Force distribution in splinted natural teeth and osseointegrated prostheses are compared. The mechanism of interface force distribution and the consequences of poor interface fit are interrelated. The differential mobility of splinted natural teeth affects diagnosis and treatment. However, combining natural teeth with an osseointegrated prosthesis requires new design principles.

2. Jacobs R., and van Steeberghe D.: Comparative evaluation of the oral tactile function by means of teeth or implant-supported prostheses. *Clin Oral Implants research* 2(2):75-80, April - June 1991.

To clarify more of the tactile function of oral implants, both an interocclusal thickness detection and discrimination task were carried out in 4 different test conditions on 37 patients: 5(tooth)/t, i(implant)/t, i/i and d(denture)/o(overdenture supported by implants). For the interocclusal detection of steel foils, the 50% detection threshold level (RL) in the 4 conditions was 20,48,64 and 108 microns, respectively, which indicates significant differences. The ability to discriminate interdental thickness was tested with a 0.2 and 1.0mm standard. It was evaluated as the 75% discrimination level (DL). In the 0.2mm discrimination task, corresponding DL-values for the t/t, i/t, i/i, and d/o condition were 25, 55, 66 and 134 microns, whereas the 1.0mm standard gave values of 193,293,336, and 348 microns, respectively. All results differed significantly from each other (p less than 0.05) except for the i/i-d/o comparison of the 1.0mm discrimination task where the difference was negligible. The present findings indicate that the tactile sensibility of implants is reduced with regard to natural teeth. Remaining receptors of the peri-implant tissues might play a compensatory role in the decreased exteroceptive function.

3. Lundgren D.: Prosthetic reconstruction of dentitions seriously compromised by periodontal disease. *J Clin Periodontol* 18:390-395,1991.

Dentitions seriously compromised by periodontal disease are often in need not only of cause-related periodontal therapy of high quality but also of relevant prosthetic rehabilitation. The free-standing, implant-supported bridge has recently become an important treatment modality for rehabilitation of the partially edentulous jaw, and follow-up studies demonstrate a high success rate. Prosthetic connections between natural teeth and implants have also been reported to have a good prognosis without incorporation of elastic elements in the constructions, provided that factors such as occlusal force pattern, tooth mobility and beam dimensioning are taken into consideration. Other factors influencing the force distribution in such constructions are size, type and number of implants as well as the jaw bone quality.

4. Klinge B.: Implants in relation to natural teeth. *J Clin Periodontol* 18:482-487,1991.

Osseointegrated implants are now an accepted part of the prosthetic treatment of edentulous patients. More recently, osseointegrated implants have been advocated in the treatment of partially dentate patients. The implants can be used in conjunction with natural teeth for the support of rigid prostheses. The natural tooth is supported in bone by a periodontal ligament, whereas the implant may be described as having a more intimate or ankylotic connection with the supporting bone. Different attachment mechanisms may lead to differential rates of destruction in both situations, particularly if teeth and implants are splinted together by a rigid prosthetic appliance. Also noteworthy are the possible differential rates of marginal tissue breakdown as a result of the influence of bacteria. Results of a pilot study in which marginal breakdown was induced around implants and natural teeth in beagle dogs suggest that the process of destruction proceeds more slowly in the case of implants. However, the disease process around implants may be more difficult to arrest due to conjectural problems in treating the surface of the implant using conventional techniques of periodontal treatment. From the limited data available so far, it would appear that osseointegrated implants can be used as predictably in partially dentate as in totally edentulous mouths. More research should be initiated on the potential for tissue-breakdown, and long-term maintenance of the marginal tissues around implants.

5. Astrand P., et al: Combination of natural teeth and osseointegrated implants as prosthesis abutments: a 2-year longitudinal study. *Int J Oral Maxillofac Implants* 6:305-312, 1991.

Twenty-three patients with Kennedy Class I mandibular dentition were supplied with prostheses in the posterior parts of the mandible. On one side they were given a prosthesis supported by two implants (prosthesis Type I) and on the other side they received a prosthesis supported by one implant and one natural tooth (prosthesis Type II). Sixty-nine fixtures were inserted and 46 prostheses constructed. Eight of the fixtures were lost during the observation period. The failure rate of the implants was about the same in the two types of prostheses five fixtures belonged to prostheses Type I (10.9%) and two fixtures belonged to prostheses Type II (8.7%), while one fixture was lost prior to loading. From a theoretical point of view, the combination of a tooth and an osseointegrated implant should encounter problems with regard to the difference in bone anchorage and there should be a risk of biomechanical complications. However, the results of this study did not indicate any disadvantages in connecting teeth and implants in the same restoration.

6. Rangert IS., Gunne J., and Sullivan DY.: Mechanical aspects of a Branemark implant connected to a natural tooth: an in vitro study. *Int J Oral Maxillofac Implants* 6:177-186, 1991.

Mechanical in vitro tests of the Branemark implant disclose that the screw joint which attaches the prosthetic gold cylinder and the transmucosal abutment to the fixture forms a flexible system. This inherent flexibility seems to match well the vertical mobility of a supporting tooth connected to the implant. Calculations of vertical load distribution based on measured flexibility data demonstrate that the forces are shared almost equally between tooth and implant even without taking the flexibility of the surrounding bone or the prosthesis into account. The therapy of a single Branemark implant connected to a natural tooth should be considered without any additional element of a flexible nature. Mechanical tests and theoretical considerations, however, indicate that the transverse mobility of the connected tooth should be limited and that the attachment of the prosthesis to the tooth should be of a rigid design to avoid gold-screw loosening.

7. Chapman RJ. and Hirsch A.: Variations in occlusal forces with a resilient internal implant shock absorber. *Int J Oral Maxillofac Implants* 5(4):369-74, 1990.

The importance of an internal shock absorber for implant prostheses has concerned many, primarily because the efficacy of a shock absorber to reduce stress has not been demonstrated in vivo. This study examined 15 subjects with unilateral distal extension single implant abutments attached to a single tooth abutment to assess the effect of a shock-absorbing element within the implant on occlusal force levels. Occlusal forces and bilateral occlusal similarity were examined using specially adapted research software for the T-Scan occlusal analysis system. The results indicate that there is a significant difference ( $P$  less than 0.01) between occlusal forces using an internal shock absorber (18 N) and a titanium internal element (130 N).

8. el Charkawi HG., el Wakad MT., and Naser ME.: Modification of osseointegrated implants for distal-extension prostheses. *J Prosthet Dent* 64(4):469-72, Oct 1990.

The use of a distal implant abutment splinted to a natural tooth by a fixed partial denture has been employed for distal-extension prostheses. There is a differential difference between the viscoelastic deflection of a natural tooth by its periodontal ligament, and the almost negligible elastic deformation of an osseointegrated implant. This difference may induce a fulcrum-like effect and overstress the implant. In this study a new modification of osseointegrated implants was proposed to counteract this problem. This modification was achieved by using a resilient layer material under the superstructure of the implant. Finite element modeling (FEM) was used to examine stresses and displacement distribution around a commercially available implant and one experimental implant with a resilient layer material. The results of this study showed that the new modification is a simple and efficient way to mimic the structural natural tooth unit. It also showed that it allowed movement of the superstructure without movement of the implant three times that of the nonresilient model.

9. van Rossen IP., et al: Stress-absorbing elements in dental implants. *J Prosthet Dent* 64(2):198-205, Aug 1990.

By means of finite element analysis, calculations, were made of the stress-distribution in bone around implants with and without stress-absorbing elements. It was concluded the variation in the E-modulus of the stress-absorbing element had no effect on the stresses in bone. Changing the shape of the stress-absorbing element had little effect on the stresses in cortical bone. For the implant connected with a natural tooth, it was concluded that a more uniform stress was obtained around the implant with a low E-modulus of the stress-absorbing element. It was also concluded that the bone surrounding the natural tooth showed a decrease in the height of the peak stresses.

10. Richter EJ., Orschall IS., and Jovanovic SA.: Dental implant abutment resembling the two-phase tooth mobility. *J Biomech* 23(4):297-306, 1990.

Natural teeth and dental implants have differing degrees of mobility thus causing a potential biomechanical problem when connected by fixed bridgework. The clinical follow-up often discloses marginal bone loss around an implant neck probably due to high stress factors. An implant with a built-in compliance resembling the tooth mobility could be advantageous for stress distribution. With axial loading the proposed 'elastic-test model' accomplishes this demand. By means of theoretical and experimental studies this 'elastic-test model' is

optimized and compared with a stiff implant-model. The results show a 20 times reduction of stress accumulation in bone with the 'elastic'-test model.

11. McGlumphy EA., Campagni WV., and Peterson LJ.: A comparison of the stress transfer characteristics of a dental implant with a rigid or a resilient internal element. *J Prosthet Dent* 62(5):586-93, November 1989.

This study compared the difference in the stress patterns generated in photoelastic plastic by an IMZ implant with a resilient or a rigid internal element. Under a standardized cantilever load, the stress patterns were photographed in the field of a circular polariscope. The total stress areas were calculated and a statistical comparison performed. The static load conditions of the model demonstrated no statistical difference between the area of stress pattern generated by an IMZ implant with or without a resilient internal element. Moreover, a single load produced the same deflection of the cantilever beam regardless of which element was interposed.

#### **Maintenance and Complications:**

1. Speelman JA., Collaert B., and Klinge B.: Evaluation of different methods to clean titanium abutments. A scanning electron microscopic study. *Clinical Oral Implants Research* 3(3):120-7, Sept. 1992.

The cleaning effectiveness of different treatment methods for titanium abutments was evaluated using scanning electron microscopy (SEM). In the mandible of 4 beagle dogs, 25 titanium abutments were installed (modum Branemark). After 16 weeks of plaque accumulation, mineralized deposits had formed on 23 abutments. Each of these abutments was subjected to one of the following treatment methods: scaling with (1) metal, (2) plastic, or (3) ultrasonic instruments; (4) air-polishing, (5) weekly rubber cup polishing or (6) daily brushing with a conventional toothbrush. Fourteen abutments were removed immediately after treatment. On 9 abutments, the scaling procedures and air-polishing were repeated after another 16 weeks of plaque accumulation. The abutments were prepared for SEM, and each of them was viewed and photographed at 3 different magnifications. The photomicrographs were evaluated by 3 examiners who, guided by reference pictures, gave each abutment a "cleanliness" score, ranking from 0 to 5. Regular rubber cup polishing and regular brushing resulted in the highest surface cleanliness, while the air-polishing procedure showed the lowest cleanliness score. None of the 3 scaling methods created a cleanliness score better than 3. The 3 scaling methods were considered equal in their cleaning effectiveness. No differences could be observed between surfaces treated 1 x or 2 x. Taken the present findings and those of other studies concerning the effects of scaling on the surface roughness and biocompatibility into consideration, it was concluded that plastic scalers may be the instruments of choice for debridement of titanium implant surfaces.

2. Meffert RM.: How to treat ailing and failing implants. *Implant Dentistry* (1):25-33, Spring 1992.

This article describes treatment of the ailing implant (bone loss with pocketing but static at the maintenance checks) and the failing implant (bone loss with pocketing, bleeding upon probing, purulence, and evidence of continuing bone loss irrespective of therapy). Because the surface of the implant is contaminated with endotoxin, it must be detoxified before any regenerative therapy. Studies have shown that citric acid is effective in detoxifying the hydroxyapatite-coated surfaces while tetracycline is more effective in sterilizing the metallic substrate fixtures. Guided tissue regeneration is useful as a "barrier" to prevent exfoliation of the grafted material. Both nonresorbable and resorbable materials have been used with great success. Allografts (freeze-dried bone) and alloplasts (synthetic materials) may be used to achieve a sulcus of decreased depth and possibly some type of osseous regeneration. The author recommends the use of the allograft if the surface is completely detoxified and the alloplast if it is not certain that the surface is sterilized and free of endotoxin. The allograft, being resorbable, will not effect biologic healing against a contaminated surface; hence, the use of the alloplast to "fill" the defect and prevent epithelial invagination.

3. Bauman GR., Mills R., Rapley JW., and Hallmon WW.: Implant maintenance: debridement and peri-implant home care. *Compendium* 12(9):644, 646, 748 passim, September 1991.

Although implant maintenance is one of the most frequently overlooked areas in implantology, the success of an implant can hinge on maintenance performed at regular intervals. Prevention of peri-implant disease should be a prime motivating factor for patient and therapist involvement in a regular maintenance program.

4. Bragger U., Burgin W., Lang NP., and Buser D.: Digital subtraction radiography for the assessment of changes in peri-implant bone density. *Int J Oral & Maxillofacial Implants* 6(2):160-6, Summer 1991.

Digital subtraction radiography is proposed as a potential diagnostic tool for implant research and patient monitoring. Examples of the application of this technique are given observing peri-implant density changes during the early healing phase and during ligature-induced peri-implants in an animal model. Additional cases document the loss of peri-implant bone density associated with a single crown. Digital subtraction radiography might be one of the most sensitive noninvasive methods for assessing subtle density changes in peri-implant tissues, providing additional diagnostic information on implant tissue integration and maintenance.

5. Langer IS.: Dental implants used for periodontal patients. *J Am Dent Assoc* 121 (4): 505-8, October 1990.

For those performing implant treatment, continued research and reports of long-term successful results are essential to evaluating the validity of implants, especially when variables such as design and surface treatment are introduced. The dental profession has enthusiastically embraced the clinical results of implant treatment and its benefits to the patient. However, just as patients who undergo periodontal and restorative treatment must continue a regular long-term routine of maintenance therapy to ensure their dental health, so must those patients who receive dental implants. Both the periodontist who places the implants and the dentist who fabricates the prosthetic replacement must work cooperatively to deliver a healthy restoration that will function for many years.

6. Johansson G., and Palmqvist S.: Complications, supplementary treatment, and maintenance in edentulous arches with implant-supported fixed prostheses. *Int J Prosthodont* 3(1):89-92, Jan-Feb 1990.

The first 50 edentulous arches treated with osseointegrated fixed partial dentures at the Postgraduate Dental Education Center, Orebro, Sweden, were studied retrospectively with concern for complications and time used for supplementary treatment and maintenance. The longest observation period was 9 years, the shortest 3 years, and the mean 5.2 years. Twenty-two percent of the patients experienced fractures of artificial teeth and/or the acrylic resin superstructure. The most severe technical complications were fractured or bent abutment screws (three) and fracture of the framework (one). The average time for supplementary treatment and maintenance was as follows: for surgery, 0.16 hours per prosthesis and year; for prosthodontics, 0.64 hours per prosthesis and year; and for dental laboratory procedures, 1.0 hour per prosthesis and year.

7. Apse R., et al: Microbiota and crevicular fluid collagenase activity in the osseointegrated dental implant sulcus: a comparison of sites in edentulous and partially edentulous patients. *J Periodont Res* 24(21):96-105, March 1989.

The soft tissues adjacent to osseointegrated dental implants (011) were investigated using clinical, biochemical and microbiological methods. Differences in clinical parameters were noted in that implants had significantly less keratinized gingiva and deeper probing depths. Crevicular fluid was present in the 011 sulcus but the crevicular fluid flow did not differ from that observed from tooth sites either in the partially edentulous or edentulous patients. Few differences were observed between implants and teeth in partially edentulous patients, indicating that crevices around teeth may act as reservoirs of bacteria which can colonize implant sites.

8. Bergman, CL.: Osseointegration. Complications. Prevention, recognition, treatment. *Dent Clin North Am* 33(4):635-63, October 1989.

Practitioners often have delayed responses to the problems involved with complications. This was especially true in the first years of endosseous implantology. Eventually hindsight becomes insight. This maturation is a necessary and normal process. It can be enhanced by careful documentation of the procedures and process of care such as numerous clinical photographs during treatment, and treating patients with several members of the team present (example: the prosthodontist scrubbing with the surgeon on very early or complex cases.) It is possible to improve the quality of care. Postsurgical case management conferences are invaluable. It is also important that each team member not only see his or her own role, but also the responsibility to see that the entire treatment is adequately done. Each individual must have a sense of responsibility for the management of the entire case. It is important that the practitioner not take a defensive posture regarding his or her own treatment. Reformatted computerized tomography (CT) including radiographic bone density measurement (Hounsfield units) can be very valuable in determining bone quality and anatomy and will provide insight into where and where not to place fixtures. In the event of a complication, it is important that it be recognized early that it is not be "covered up" and that the damage be contained and prevented from causing a secondary complication and further morbidity to the patient.

9. Jaffin RA.: Biologic and clinical rationale for second-stage surgery and maintenance. *Dent Clin North Am* 33(4):683-99, October 1989.

It is evident that control of the microbial flora around abutments is vital in maintaining peri-implant health. It has also been shown that a potential pathogenic flora is more likely to occur in the partially edentulous patient. More predictable indicators of peri-implant disease must be established, as classic periodontal measurements do not correspond to the active disease state around implants. Second-stage surgery must create a peri-implant environment in which functional and biologic needs are met. The patient's esthetic and phonetic requirements must be fulfilled. Using procedures described in this article these standards can be achieved.

10. Balshi TJ.: Preventing and resolving complications with osseointegrated implants. *Dent Clin North Am* 33(4):821-867, 1989.

A variety of potential complications, using osseointegrated implants, have been discussed. The objectives of this discussion is the development of concepts to prevent complications through careful treatment planning and meticulous execution of surgical and prosthetic treatment techniques. The six major categories of potential complications include: (1) esthetic, (2) phonetic, (3) functional, (4) biologic, (5) mechanical, and (6) ergonomic. The most frequently observed difficulty with any implant prosthesis relates to esthetics in the maxillary anterior and is followed then equally by phonetic, functional, biologic, and mechanical.



**Designing Fixed Partial Denture Reconstruction  
And Implant Rehabilitation Using CAD/CAM**

**Dr. Michael E. Razzoog**



Andersson M Carlsson L Persson M Bergman B  
Accuracy of machine milling and spark erosion with a CAD/CAM system.  
J Prosthet Dent 1996; 76(2):187-93

A method for manufacturing crowns and fixed partial dentures based on CAD/CAM has been developed as an alternative to the lost wax technique and the casting of an alloy. In this process two steps are included: milling and spark erosion. The computer-assisted design (CAD) relies heavily on the accuracy of the milling and spark erosion processes to achieve a clinically acceptable restoration. These two processes must be able to produce the crown data generated in the CAD files. This study evaluated the accuracy of the Procera CAD/CAM system in creating specific geometric bodies that were compared with the known dimensions in the CAD files for these bodies. The manufacturing errors of milling (ellipse +/- 6.5 microm, square +/- 3.4 microm, and cylinder +/- 5.8 microm) and spark erosion (ellipse +/- 8.6 microm and square +/- 10.4 microm) were determined. The accuracy of this manufacturing process demonstrated that this system was capable of producing a crown with a clinically accepted range for marginal opening gap dimension of less than 100 microm.

Russell MM Andersson M Dahlmo K Razzoog ME Lang BR  
A new computer-assisted method for fabrication of crowns and fixed partial dentures.  
Quintessence Int 1995; 26(11):757-63

The availability of high-technology systems that use computer-aided design and computer-aided machining is on the increase. One such system is the Procera system, which is currently providing cost-effective, high-quality dental restorative services to dental laboratories and to dentists. A reduction in cost to the dentist, and ultimately to the patient, is a major advantage of the Procera system. Cost benefits combined with its continued success in producing crowns and fixed partial dentures that meet professional standards of care should enhance the acceptance of this new technology.

Giordano R Cima M Pober R  
Effect of surface finish on the flexural strength of feldspathic and aluminous dental ceramics.  
Int J Prosthodont 1995; 8(4):311-9

The effects of surface finish on flexural strength of a feldspathic porcelain, aluminous porcelain, and a computer aided design-computer aided machining porcelain (Vitabloc MKI) were examined. A total of 105 bars of the feldspathic ceramic were made, randomly divided into seven groups, and sintered according to manufacturer's recommendations. The groups consisted of as-fired, self-glazed, overglazed, ground, polished, ground/annealed, and polished/annealed. A total of 45 bars of the aluminous ceramic and Vitabloc MKI were made and randomly divided into three groups: as-fired, ground, and polished. Overglazing, grinding, and polishing all significantly increased ( $P < .05$ ) the flexural strength (four-point-bend test) of the tested materials (15% to 30%).

Persson M Andersson M Bergman B  
The accuracy of a high-precision digitizer for CAD/CAM of crowns.  
J Prosthet Dent 1995; 74(3):223-9

An alternative method for manufacturing fixed prostheses that uses machine digitalization and a combination of milling and spark erosion has been developed. The digitizer used has a contact probe with a ball-shaped tip. This study evaluated the accuracy of the device and the transfer of data from the individual die to the computer. The dimensions of a square gauge as read by the machine were compared with the known dimensions of the object with a computer, which allowed determination of the accuracy of the digitalization. Procera machining and the implications for reliable prosthodontic treatment are discussed.

Samet N Resheff B Gelbard S Stern N  
A CAD/CAM system for the production of metal copings for porcelain-fused-to-metal restorations.  
J Prosthet Dent 1995; 73(5):457-63

A computer-aided design and manufacture system for the production of metal copings for porcelain-fused-to-metal restorations is described and evaluated. The three stages of production: digitizing, mathematical processing, and milling are described, with emphasis on the system's ability to produce metal copings for both single-unit and multiple-unit restorations. Evaluation of the marginal fit of the produced copings demonstrates the potential for clinically acceptable results.

White SN, Caputo A, Chun Z, Zhao XY. Modulus of rupture of the Procera all ceramic system. J Esthet Dent 1996;8:120-6.

Calamia JR  
Advances in computer-aided design and computer-aided manufacture technology.  
Curr Opin Cosmet Dent 1994 :67-73

Sjogren G  
Dental ceramics and ceramic restorations. An in vitro and in vivo study.  
Swed Dent J Suppl 1996; 111:3-50

Rommerdale EH  
CAD/CAM and its effect on the future of dental laboratory technology.  
Trends Tech Contemp Dent Lab 1993; 10(6):21-6

Monteith BD

Minimizing biomechanical overload in implant prostheses: a computerized aid to design. *J Prosthet Dent* 1993 ; 69(5):495-502

Implant-supported prostheses must be able to withstand the load capabilities of individual patients to overload them. The gold alloy screw in the Brånemark system is by intention the weakest component. Therefore, if cantilever lengths can be designed so that occlusal forces distributed to individual fixtures are limited to the gold screws' ability to accept them, breakage-free performance may be assured. Models, such as that of Skalak, are capable of developing the required analytical processes to provide the information necessary to achieve this design. Unfortunately, the overt mathematical complexity of the Skalak model has militated against its routine use in the operatory. Its computational aspects are, however, eminently suited to computerization and indeed provide the basis for the computer program that is described in this article. This program is simple to apply clinically and, when used in conjunction with available load parameters of gold screw performance, can provide the clinician with a routine and scientific basis for rational implant prosthesis design.

Schmitt SM Chance DA

Fabrication of titanium implant-retained restorations with nontraditional machining techniques.

*Int J Prosthodont* 1995; 8(4):332-6

Traditional laboratory techniques are being supplemented by modern precision technologies to solve complex restorative problems. Electrical discharge machining combined with laser scanning and computer aided design-computer aided manufacturing can create very precise restorations without the lost wax method. A laser scanner is used to create a three-dimensional polyline data model that can then be converted into a stereolithography file format for output to a stereolithography apparatus or other rapid prototyping device. A stereolithography-generated model is used to create an electric discharge machining electrode via copper electroforming. This electrode is used to machine dental restorations from an ingot of titanium, bypassing the conventional lost wax casting process. Retaining screw access holes are machined using conventional drilling procedures, but could be accomplished with electric discharge machining if desired. Other rapid prototyping technologies are briefly discussed.

Daftary F. The Bio-Esthetic abutment system; an evolution in implant prosthesis. *Int J Dent Sympos* 1996;3:10-15.

Binon PP. Evaluation of machining accuracy and consistency of selected implants, standard abutments, and laboratory analogs. *Int J Prosthodont* 1995;8:162-78.

Sorensen JA, Avera SP, Thomas C. Comparison of the interface fidelity of implants systems. [abstract]. *J Dent Res* 1991;70:540.

Marchack CB. A custom titanium abutment for the anterior single tooth implant. *J Prosthet Dent* 1996;76:288-91.

Jansen CE. Guided soft tissue healing in implant dentistry. *J Calif Dent Assoc* 1995;23:57-64.

Dowling EA, Maze GI, Kaldahl WB. Postsurgical timing of restorative therapy a review. *J Prosthodont* 1994;3:172-7.

Marchack CB, Yamashita T. A procedure for a modified cylindrical titanium abutment. *J Prosthet Dent* 1997;77:546-9.

This article describes a procedure to modify the CeraOne abutment, a cylindrical titanium abutment, into an anatomically shaped titanium ceramic transmucosal element. This modified abutment provides esthetics, retrievability, and support of the gingival tissue. This procedure can also be applied to other implant systems.

Binder WJ, Kaye A. Reconstruction of posttraumatic and congenital facial deformities with three-dimensional computer-assisted custom-designed implants. *Plastic and Reconstructive Surgery* 1994;94:775-85.

This process implements strict sets of manufacturing guidelines for the production of a solid silicone elastomer that is purer, harder, and tougher than RTV silicone and meets FDA certification for general use and distribution. The custom implants are produced by means of the three-dimensional imaging-CAD/CAM process; they are FDA -approved and commercially available.

Eufinger H, Wehmoller M, Machtens E, Heuser L, Harders A, Kruse D. Reconstruction of craniofacial bone defects with individual alloplastic implants based on CAD/CAM-manipulated CT-data. *Journal of Cranio Maxillo-Facial Surgery* 1995;23:175-81.

Golec TS. CAD/CAM multiplanar diagnostic imaging for subperiosteal implants. *Dental Clinics of North America* 1986;30:85-95.

Benjamin LS. Long-term retrospective studies on the CT-scan, CAD/CAM, one-stage surgery hydroxyapatite-coated subperiosteal implants, including human functional retrievals. *Dental Clinics of North America* 1992;36:77-95.

Fischer JE. CAD/CAM subperiosteal implants in Australia. Case report. *Australian Dental Journal* 1993;38:261-4.

# **Accuracy And Precision In Dental Implants**

**Dr. Stephen J. Riedy**





**Carr AB, Stewart RB. Full-arch implant casting accuracy: preliminary in vitro observation for in vivo testing. J Prosthodont 1993;2:2-8.**

The purpose of this study is to determine the accuracy of torch casting full arch frameworks using a high palladium alloy and a ringless phosphate-bonded investment technique. Three different variables were evaluated relative to the casting accuracy effect. The first variable, completeness of mold-fill, compared mold specimens where the entire spruce system was filled as part of the casting and cast specimens without the spruce system filled. The second variable studied phosphate-bonded investment special liquid concentrations. The third variable compared castings produced from a conventional ringless mold shape with a modified mold shape where the investment in the same horizontal plane as the pattern was equal in thickness at the internal and external surfaces. Horizontal and vertical distances on the wax pattern and resulting framework were measured using a machinist's microscope to determine casting error.

No significant differences existed among the three groups compared. The mean error of all groups exceeded the recommended level of fit needed to satisfy the passive fit requirement by more than ten fold.

This study concludes by suggesting that the use of a conventional lost wax casting technique to cast one-piece full arch implant frameworks in both imprecise and inaccurate as judged against the passive fit requirement.

**Jemt T, Linden B, Lekholm U. Failures and complications in 127 consecutively placed fixed partial prostheses supported by Branemark implants: from prosthetic treatment to first annual checkup.**

Ninety-six partially edentulous mandibles and maxillae were consecutively treated with 127 free standing fixed prostheses supported by 354 implants. The overall success rate was 98.6% for the examined implants in these patients who were followed for one year. None of the inserted prostheses was lost during the observation period. The most commonly reported problems during the first year of function were related to loose gold screws and esthetic complaints. These complications were low and less than has been reported for routine full arch fixed prostheses.

Patterson EA, Johns RB. Theoretical analysis of the fatigue life of fixture screws in osseointegrated dental implants. Int J Oral Maxillofac Implants 1992;7:26-34.

Metal fatigue failure of the gold screw used to retain a fixed prosthesis to Branemark osseointegrated fixtures/abutments had been analyzed theoretically. Mechanical engineering principles show the importance of appropriate preload being applied through the gold screw to the gold cylinder and abutment. The significance of the screw design and necessary of applying the correct torque achieve a long fatigue life for the screw are described. The consequence of misalignment of a gold cylinder to and abutment is discussed. A procedure for calculating the fatigue life of threaded parts in fixed prosthesis systems has been developed. When a system is accurately constructed with sufficient, equidistant implants, the fatigue of the fixture screws is of the order of 20 years. This life is drastically reduced when the prescribed conditions are not satisfied.

Jemt T, Linden B. Fixed implant-supported prostheses with welded titanium frameworks. Int J Periodont Rest Dent 1992;3:177-83.

Eighty-six patients restored with Branemark implants were selected for fixed prostheses with modified framework designs. This study describes alternative laboratory techniques where premachined titanium components are welded together to form the framework. The patients were followed for one year after placement. Clinical experience indicates that it is a predictable technique with a similar pattern of complications as experienced by patients with cast frameworks supported by implants. It was concluded that the prostheses are considered to be slightly more bulky than cast frameworks, but seem to have on a clinical level, a better fit to the implants.

Tan KB, Rubenstein JE, Nicholls JE, Yuodelis RA. Three-dimensional analysis of the casting accuracy of one-piece, osseointegrated implant-retained prostheses. Int J Prosthodont 1993;6:346-363.

The three dimensional distortions of implant frameworks of two designs, reflecting the early "Toronto" U-shaped design and a current L-shaped design, were measured. A conventional commercial laboratory one-piece casting method, using a silver palladium alloy, was used. Distortion was defined by five displacement variables for the centroids of each of five gold cylinders incorporated in each casting: three orthogonal transnational displacements and two rotational displacements. A computerized coordinate measuring machine was used.

Nor significant differences were found between U-shaped and L-shaped castings, except for  $\delta$  values for cylinders 2,3, and 4. Cylinder location within the arch was associated with a specific direction and magnitude of transnational and rotational displacement. Even small rotational displacements may manifest large gap appearances with the one-screw test because of "moment arm" effect. However, other rotational displacements may be hidden, depending on the direction of tilt and the moment arm length.

Johansson G, Palanqvist S. Complications, supplementary treatment, and maintenance in edentulous arches with implant supported fixed prostheses. Int J Prosthodont 1990;3:89-92.

Fifty edentulous arches treated with osseointegrated fixed partial dentures were studied retrospectively with concern for complications and time used for supplementary treatment and maintenance. The longest observation period was nine years, the shortest three years and the mean 5.2 years.

Twenty-two percent of the patients experienced fractures of artificial teeth and/or the acrylic resin superstructure. The most severe technical complications were fractured or bent abutment screws (three) and fracture of the framework (one). The average time for supplementary treatment and maintenance was as follows: for surgery, 0.16 hours per prosthesis and year; and for dental laboratory procedures, 1.0 hours per prosthesis and year.

Lie A, Jemt T. Photogrammetric measurements of implant positions. Description of a technique to determine the fit between implants and superstructures. Clin Oral Impl Res 1994;5:1-7.

A photogrammetric technique was designed to measure the position of dental implants in three dimensions to enable assessment of the fit of superstructures placed on the implants. A relatively simple camera set-up was developed and tested. Calibration of the camera was performed in a high precision analytical plotter and revealed a film measurement accuracy for clear and well defined points on clinical components was found to be around 0.02mm. To find the center point of the implants, points on the circumference were measured. These points are not well defined, which resulted in an estimation of the center point of the implant with a precision of 0.050mm.

Independent measurements of a prosthesis with five implants were also within the precision of 0.05mm. The angular orientation of the top surface of the implant cylinder (abutment, brass replica of gold alloy cylinder of the framework) was measured with a precision of 0.01 radians, which corresponded to an error with a peripheral gap of about 0.03mm. This value was about 5-10 times lower than the clinical fit between frameworks and abutments, measured in three randomly selected clinical cases.

Zarb GA, Schmitt A. The longitudinal effectiveness of osseointegrated dental implants: the Toronto study. Part III: Problems and complications encountered. J Prosthet Dent 1960;64:185-194.

Two hundred seventy-four implants were placed in 49 dental arches of 46 consecutively treated patients. The success rate for individual implants in this study, 4 to 9 years after placement, was 89.5% and for the prosthetic treatment it was 100%. Problems and complications were observed and recorded at stage I surgery, between stage I and stage II surgery, at stage II surgery, and in the healing period that followed.

Also noted were the complications subsequent to prosthodontic treatment and during the years of follow-up. Virtually all of the problems encountered were iatrogenic in nature. The clinical results indicate a safe and retrievable technique with negligible associated morbidity.

## REFERENCES

1. Branemark P-I, Zarb GA, Albrektsson T. Tissue-Integrated Prostheses: Osseointegration in Clinical Dentistry. Quintessence Publishing Company Ltd, Chicago, USA, 1985.
2. Industrial Engineering Terminology Revised Edition, ANSI Z94.0 - 1989 Norcross, Georgia (07-02, 07-20, 07-58, 08-02, 08-19, 17-02)
3. Jemt T, Linden B, Lekholm U. Failures and complications in 127 consecutively placed fixed partial prostheses supported by Branemark implants: From prosthetic treatment to first annual checkup. Int J Oral Maxillofac Implants 1992;7:40-44.
4. Zarb GA, Schmitt A. The longitudinal effectiveness of osseointegrated dental implants: the Toronto study. Part III: Problems and complications encountered. J Prosthet Dent 1990;64:185-194.
5. Johansson G, Palanqvist S. Complications, supplementary treatment, and maintenance in edentulous arches with implant supported fixed prostheses. Int J Prosthodont 1990;3:89-92.
6. Patterson EA, Johns RB. Theoretical analysis of the fatigue life of fixture screws in osseointegrated dental implants. Int J Oral Maxillofac Implants 1992;7:26-34.
7. Carr AB, Stewart RB. Full-arch implant framework casting accuracy. Preliminary in vitro observation for in vivo testing. J Prosthodont 1993;2:2-8.
8. White GE. Osseointegrated Dental Technology. Quintessence Publishing Company Ltd, Chicago, USA, 1993:78-90.
9. Jemt T, Linden B. Fixed implant supported prostheses with welded titanium frameworks. Int J Periodont Rest Dent 1992;12:177-183.
10. Lie A, Jemt T. Photogrammetric measurements of implant positions. Description of a technique to determine the fit between implants and superstructures. Clin Oral Impl Res 1994;5:1-7.

11. Tan KB, Rubenstein JE, Nicholls JE, Yuodelis RA. Three-dimensional analysis of the casting accuracy of one-piece, osseointegrated implant-retained prostheses. Int J Prosthodont 1993;6:346-363.
12. Rangert B, Jemt T, Jorneus L. Forces and moments of Brånemark implants. Int J Oral Maxillofac Implants 1989;4:241-247.
13. Binon P, Sutter F, Beaty K, Brunski J, Gulbransen H, Wiener R. The role of screws in implant systems. Int J Oral Maxillofac Implant Supp. 1994;9:48-63.

# **Implant Complications**

**Dr. Brien R. Lang**





## **IMPLANT COMPLICATIONS**

Dr. Brien R. Lang - Ann Arbor, MI  
October 23, 1997

Most dental implant research during the past 10 years has focused on the success or failure of the bone-to-implant interface, and encouraging data on osseointegration and implant systems continue to appear in the literature since the classic articles by Adell et al, and Albrektsson et al.<sup>1,2</sup> However, after successful implant integration, complication involving the implant components have also been frequently cited.<sup>3-16</sup> Loosening or fracture of the abutment or retaining screws have been among the complications reported, especially during the late 1980's and early 1990's. Most literature involving implant screws has reported the incidences of such occurrences and little scientific information has been presented as to the mechanism of screw loosening, or methods to overcome this problem. The most frequent explanation given for the cause of these findings has been occlusal overload.<sup>17</sup>

### **COMPLICATIONS - 1985 to approximately 1990.**

1. Adell R, Eriksson B, Lekholm U, Brånemark P-I, Jemt T. A long-term follow-up study of osseointegrated implants in the treatment of totally edentulous jaws. *Int J Oral Maxillofac Implants* 1990;5:347-359.
2. Albrektsson T, Bergman B, Folmer T, Henry PJ, Higuchi K, Klineberg I, Laney W R, Lekholm U, Oikarinen V, van Steenberghe D, Triplett RG, Worthington P, and Zarb GA. A multicenter report of osseointegrated oral implants. *J Prosthet Dent* 1988;60:75-84.
3. Worthington P, Bolender CL, Taylor TD. The Swedish system of osseointegrated implants: Problems and complications encountered during a 4-year trial period. *Int J Oral Maxillofac Implants* 1987;2:77-84.
4. Sones AD. Complications with osseointegrated implants. *J Prosthet Dent* 1989;62:581-5.
5. Zarb GA, Schmitt A. The longitudinal clinical effectiveness of osseointegrated dental implants: The Toronto study. Part III: Problems and complications encountered. *J Prosthet Dent* 1990;64:185-94.

6. Jemt T, Book K, Lindén B, Urde G. Failures and complications in 92 consecutively inserted overdentures supported by Brånemark implants in severely resorbed edentulous maxillae; A study from prosthetic treatment to first annual check-up. *Int J Oral Maxillofac Implants* 1992;7:162-167.
7. Naert I, Quirynen M, van Steenberghe D, Darius P. A study of 589 consecutive implants supporting complete fixed prostheses. Part II: Prosthetic aspects. *J Prosthet Dent* 1992;68:949-56.
8. Jemt T, Bengt L, Lekholm U. Failures and complications in 127 consecutively placed fixed partial prostheses supported by Brånemark Implants: From prosthetic treatment to first annual checkup. . *Int J Oral Maxillofac Implants* 1992;7:40-44.
9. Kallus T and Bessing C. Loose gold screws frequently occur in full-arch fixed prostheses supported by osseointegrated implants after 5 years. *Int J Oral Maxillofac Implants* 1994;9:169-178.
10. Hemmings KW et al. Complications and maintenance requirements for fixed prostheses and overdentures in edentulous mandible: a 5-year report. *Int J Oral Maxillofac Implants* 1994;9:191-196.
11. Walton JN, MacEntee MI. Problems with prostheses on implants: A retrospective study. *J Prosthet Dent* 1994;71:283-8.
12. Carlson B, Carlsson GE. Prosthodontic complications in osseointegrated dental implant treatment. *Int J Oral Maxillofac Implants* 1994;9:90-94.
13. Johansson G, Palmquist S. Complications, supplementary treatment, and maintenance in edentulous arches with implant-supported fixed prosthesis. *Int J Prosthodont* 1990;3:89-92.
14. Patterson EA, Johns RB. Theoretical analysis of the fatigue life of fixture screws in osseointegrated dental implants. *Int J Oral Maxillofac Implants* 1992;7:26-34.
15. Kallus T, Bessing C. Loose gold screws frequently occur in full-arch fixed prostheses supported by osseointegrated implants after 5 years. *Int J Oral Maxillofac Implants* 1994;9:169-178.
16. Binon P, Sutter F, Beaty K, Brunski J, Gulbransen H, Weiner R. The role of screws in implant systems. *Int J Oral Maxillofac Implants* 1994;9:48-63.
17. Rangert B, Jemt T, J Örneus L. Forces and moments on Brånemark implants. *Int J Oral Maxillofac Implants* 1989;4:241-247.

### Summary of References

Most of the cited references in the 1980's detailed many more failures related to implant hardware than are being reported today. These studies involved situations where

multiple implants were being used to support long-span bridges with cantilevers. In such conditions the potential for hardware complications would be greater. Of the listed articles, two are of particular interest because they report data where the complications were of a different nature.

**Carlson B, Carlsson GE. Prosthodontic complications in osseointegrated dental implant treatment. *Int J Oral Maxillofac Implants* 1994;9:90-94.**

## **Abstract**

**Statement of Problem.** The biologic results of dental implant therapy are considered very favorable. However, according to surveys from several specialist clinics, various types of complications related to the prosthodontic reconstruction occur.

**Purpose of Study.** The purpose of this investigation was to describe the pattern of prosthodontic complications in patients provided with both removable and fixed prostheses supported by implants.

**Material and Methods.** Sixteen specialist clinics in Sweden participated in the study. All patient who visited these clinics between October and November of 1991 formed the experimental population. Examinations were performed by the dentist in charge of the treatment of the patient.

**Results.** From the 16 clinics, 600 prostheses were examined. Of the restorations 47% were in the maxillae, and 53% in the mandible. Many of the prostheses were within 2 to 3 years of placement. Of the 600 prostheses examined, 28% needed some prosthodontic treatment. Complications occurred most often with the removable prostheses and least often in single-tooth replacements. Complications were also more frequent in the maxillae (34%) than the mandible (24%). Mobile superstructures occurred in 8% of the complications and were related to nonintegrated implants, loosened abutment screws, and/or gold retaining screws. Fractures of abutment screws were seen in only 2 cases (1%).

**Conclusions.** Complications will occur in practices that provide implant therapy to patients. However, most complications are material related.

**Clinical Implications.** Time for maintenance is essential to improve the biological and clinical results with implant therapy.

## Abstract

**Statement of Problem.** Excellent long-term treatment results have been reported for fixed prostheses supported by osseointegrated implants fabricated according to the Brånemark technique. However, very little attention has been paid to the time required for supplementary treatment and maintenance.

**Purpose of Study.** The purpose of this investigation was to study the frequency of various complications and the time used for maintenance in patients with edentulous arches treated with implants and fixed prosthesis.

**Material and Methods.** Fifty patients formed the experimental population for this study. The longest observation was 9 years and the shortest was 3 years, and the mean was 5.2 years. The patients records were studied and all supplementary and maintenance treatment were noted.

**Results.** From a total of 286 fixtures placed 25 were lost. The failure rates were 17% in the maxillae, and 3% in the mandible. Damaged (fractured or bent) abutment screws were noted in three mandible restorations. Only 1 gold screw was found to be fractured. Technical complications were reported in the range of 22% ( mostly fractured teeth and fractures of the acrylic superstructure).

**Conclusions.** Complications for 49 implant-supported fixed prostheses over a 9-year period were reviewed. The fracture of acrylic resin superstructures was the most common prosthodontic problem.

**Clinical Implications.** Time and cost for maintenance should be considered in the initial treatment planning.

### Summary of Reviews

The Carlson and Carlsson article and the Johansson et al. study were selected for review because they demonstrate a shift in the reported incidence of complications from hardware to material failures. This may well be the case. There is also a shift in the kinds of patient receiving implant therapy. Many more patients needing single tooth replacements are

being treated with implants. Accompanying this new treatment demand is the concept of cementation of the restoration onto the abutment instead of using the retaining screw.

## COMPLICATIONS - Single Tooth Replacements.

Andersson B, Odman P, Carlsson L, Brånemark P-I. A new Brånemark single tooth abutment: Handling and early clinical experience. *Int J Oral Maxillofac Implants* 1992;7:105-111.

### Abstract

**Statement of Problem.** The loss of a single tooth has resulted in dentists developing several treatment options for the patient to consider. The single tooth implant is among those options. The single tooth provide a single screw joint for support of the prosthesis. The restoration is cemented onto the abutment and a retaining screw is unnecessary.

**Purpose of Study.** A new prosthetic concept, available under the name CeraOne for single tooth replacement with the Brånemark system. This article evaluates the CeraOne implant restorations after placement in the oral environment.

**Material and Methods.** A total of 32 patients treated between May 1988 and October 1990 with 35 CeraOne implants and cemented crowns were recalled for evaluation. The abutments had been manually connected to the fixtures with a gold screw. The counter-torque device was placed on the abutment and turned to ensure that the abutment engaged the hexagonal head of the fixture. The mechanical torque driver was tightened to 32 Ncm. Procera AllCeram crowns were placed on 32 of the implants and the remaining 3 received metal-ceramic crowns.

**Results.** In January of 1991, 25 crowns had been loaded for 4 to 12 months, and 10 crowns for 13 to 24 months. No clinical signs of complications were recorded. The esthetic demands of the patients had been satisfied, and none of the gold screws joining the abutments to the implants had loosened.

**Conclusions.** During the periods of time since cementation, the system has produced good clinical and esthetic results without complications.

**Clinical Implications.** Although all patients in this study were without any clinical signs of complications, the follow-up both clinically and radiologically is essential. Longitudinal data over time must be collected and the results reported in the future.

## Abstract

**Statement of Problem.** The Br nemark CeraOne consists of an abutment, gold screw and prefabricated components for the fabrication of a single crown supported by an osseointegrated implant. The abutment with a retentive hexagon 3.8 mm high is available in different lengths. The gold screw tightened at 32 Ncm, was developed to resist screw loosening, and esthetic demands by patients were met with a cemented crown. Cementation was chosen to create optimum esthetic solutions, even in situations with a somewhat unfavorable implant placement. A single tooth implant must resist and distribute bite forces at least up to 368 N, when placed anterior to the molar area. A bending moment is the load type that gives the highest stress level in the implant post, thus making the bending moment the most critical type of load. Bending moments will be induced by transverse forces or remote axial forces. The mechanical strength of the CeraOne system depends on the capacity of the crown, the abutment, and the gold screw to resist and distribute these forces and bending moments. It has been shown that the screw joint could resist alternating, rotational bending moments of 50 Ncm without opening of the joint (J rn us et al.).

**Purpose of Study.** The aim of this study was to investigate *in vitro* the mechanical strength of the CeraOne single tooth abutment in the incisor area in the maxilla.

**Material and Methods.** Five different test objects were created for the study: 1) the metal-ceramic crown, 2) all-ceramic crown (Procera), 3) Porcelain crown, 4) Procera coping only, and 5) complete implant system (metal-ceramic crown on the CeraOne abutment and a 15.0 mm implant). A load was applied in each test situation using the Instron machine. The bending moments for each tested object were calculated.

**Results.** The geometry of the tested crowns, recorded maximum loading forces, and calculated bending moments were reported. Loading of the implant post caused a bending and a lengthening of the gold screw in all situations, when the whole system with implant, abutment, gold screw, and metal-ceramic crown was tested. A bending moment of 109 Ncm, achieved from the tests in the whole system was used as the basis for the

calculation. The calculated forces varied from 104 to 185 N when a loading direction of 90° was used. and from 63 to 84 N with a force direction of 45°.

The gold screws were demonstrated to be the weakest link in the implant post. Nonlinear behavior was observed at 80 N and large deformation was observed at 108 N, which corresponds to bending moment values of 93 and 125 Ncm. A porcelain jacket crown will fracture at a lower bending moment in comparison to when the gold screw will lengthen. This is in contrast to the metal-ceramic and the all-ceramic crowns, which can withstand bending moments to a level that is about two times higher, compared to the one at which the gold screw will lengthen. The mean value of 109 Ncm for the bending moment was used for theoretical calculations related to the maximum bite force that a single crown could withstand before the gold screw was overloaded. The limits for the calculated maximum bite force varied from 104 to 185 N (force direction 90° to the occlusal plane) and from 63 to 84 N (force direction 45° to the occlusal plane).

**Conclusions.** From the data the failure loads of the gold screw were lower than the failure loads of the crown simulations tested with the exception of the porcelain jacket. There appears to be a safety margin against fracture for the metal-ceramic and the all-ceramic crowns. In other words the abutment screw is the weakest link.

**Clinical Implications.** The mean value of 109 Ncm for the bending moment used to calculate the maximum bite force that a single crown could withstand before the gold screw was overloaded may be low in comparison to reported bite forces in other studies (103 N reported by Haraldson et al., and 155 N reported by Craig).

### **Summary of Reviews**

In the first Andersson et al. report, single tooth implant complications or failures were nonexistent. This is not too surprising because of the short time span since cementation (4 months to 2-years) of the crowns. However, in the second Andersson report it is important to note that there were complications of screw bendings in the complete system samples (crown, abutment, abutment screw, and implant). The abutment screw was failing even though the crown was intact and demonstrated no signs of looseness. Although this was an in vitro study, this finding may have very significant clinical implications. In the clinical situation, will this screw joint between the abutment and the implant fail at some time in the future?

## COMPLICATIONS - Screw Fatigue.

Patterson EA, Johns RB. Theoretical analysis of the fatigue life of fixture screws in osseointegrated dental implants. *Int J Oral Maxillofac Implants* 1992;7:26-34.

### Abstract

**Statement of Problem.** Metal fatigue is perhaps the most common cause of structural failure. It occurs under repeated loading at stress levels below the ultimate strength of the material. Prosthetic structures (screws) are not immune from fatigue.

**Purpose of Study.** Screw threads are often the source of fatigue failure caused by the high concentration of stress in the root of the thread. To predict the fatigue life of a component, the stress distribution in that component must be determined.

**Material and Methods.** The authors reviewed the different methods used to assess the concentrations of stress in "the threaded joint" at the prosthetic abutment interface. The first stage of the analysis is a stress analysis of the prosthesis to determine the load paths through it and the forces transmitted to the implants under a "worse case" loading situation. These forces were used in an analysis of the bolted joint such that the loads carried by the individual components of the joint, including the gold screw, could be calculated. Finally, the stress levels induced by the loads in the gold screw were calculated from analytical and empirical relationships and were used to calculate the fatigue life of the components.

The commonly used computer-based engineering stress analysis techniques known as the finite element method has not been used to find the stress state in the gold screw, the size and complexity of the computer model that would have been necessary to generate a worthwhile result was not feasible.

**Results.** There are two main locations at which concentrations of stress occur in screws and bolts and which are consequently likely sites for the initiation of fatigue failure. One is at the change of section between the shank and the screw head; this concentration is primarily a function of the ratio of the section diameters and of the radius of curvature between them, which is known as the fillet radius. The highest concentration usually occurs at the second site, which is in the root of the first completely loaded thread. This maximum concentration is partly a consequence of the geometry of the thread profile that



produces a concentration at this point in every thread and is partly a result of the concentration of load on the first thread.

Additionally, the authors states that the used of finite element methods to perform these calculations is not usually feasible because of the enormous number of elements required around the thread roots to produce an accurate result.

**Conclusions.** For the gold screw, a recommended preload in the Brånemark system of  $F_p = 300$  N will withstand a load (P) applied to the prosthesis system ( $P = 143$  N, as reported by Haraldson and Carlsson) as the medial occlusal force achieved by patients.

**Clinical Implications.** The authors have stated that most torque-tightening devices lack accuracy because of a number of variables beyond the control of the conventional instruments. This means that the maximum preload applied by screws that have been tightened by conventional torque-tightening devices is 70% to 80% of the yield load of the gold screw itself and therefore below the maximum possible preload for the joint. While perhaps acceptable, it is not as good as it could be and in some instances leads to premature screw failure. Without this preload, the gold screw itself would have to bear all of the load applied to the joint, and this would result in the fatigue life of the screw being measured in weeks rather than years.

## **Summary of Reviews**

The Patterson and Carlsson article brought to our attention the role of the preload and the potential for implant screws to experience fatigue and ultimate failure. Basically, the abutment/implant interface is a screw joint that controls the success or failure of the prosthesis. Therefore, it is important for us as dentists to understand the principles and concepts that surround a screw joint. Further insight into this area can be found in the text by Bickford.

## **COMPLICATIONS - A Screw Joint.**

**Bickford, JH (ed). *An Introduction To the Design And Behavior Of Bolted Joints.* New York, Basel, Hong Kong: Marcel Dekker, Inc., 1995: 3-79, 175-367, 514-600, 733-797, 840-871.**

The purpose of the screw joint in the case of the abutment/implant interface is to create a clamping force between the abutment and the implant. The components involved in the screw joint consist of: 1) the screw (bolt) with its screw head, shank and threads, 2) a threaded bore or nut (the threads internal to the through bore of the implant), and 3) a bearing site remote from the screw and through bore (the bearing surfaces of the abutment and the implant).

The clamping force applied to the screw joint should be great enough to prevent the abutment and the implant from separating. The behavior and life of the screw joint depends on the magnitude and stability of that clamping force. The clamping force on the joint is initially created when the abutment is placed onto the implant and the abutment screw is tightened by turning the head of the screw allowing the threads of the abutment screw to engage the threads in the through bore of the implant. This act, creates a compressive force at the remote bearing site, and tension in the bolt, usually called the preload. Although there may be some plastic deformation in some of the threads when a screw is tightened normally, the screw and the joint members respond elastically as the screw is tightened. The remote bearing surfaces are compressed a slight amount, and the screw is stretched by a larger amount. In effect the joint members behave like stiff springs, one being compressed (the remote bearing site) and the other stretched (the abutment screw). Like springs, they acquire stored energy. If we release them after tightening them, they suddenly snap back to their original dimensions. It is this stored energy which allows the abutment screw to maintain that all-important clamping force between the abutment bearing surface and the implant bearing surface after we remove the wrench.

The amount of tightening applied to the joint members can best be explained by a review of a stress/strain curve. The upper end of the straight line in a stress/strain curve for tightening any bolt ends at the proportional limit, where the line is no longer straight, followed closely by the elastic limit (tension loads beyond which will produce some permanent deformation), followed by the yield strength point. Loading the bolt to the yield point will cause a particular amount of permanent deformation. The ultimate strength often called the tensile strength of the bolt is the maximum tension which can be created by a tensile load on the bolt. It is greater than the yield strength and occurs in the plastic region of the curve.

The proof load is the highest tensile force a screw can withstand without permanent deformation. The yield strength is the tensile force which produces permanent deformation. The ultimate tensile strength is the highest tensile force prior to rupture of the screw. The proof strength is computed by dividing the experimentally determined proof strength by the stress area, and the ultimate strength or yield strength is computed by dividing the determined ultimate or yield load by the same stress area.

The loads that can act on the screw joint are: 1) tensile, 2) shear, 3) torsional and 4) bending loads. To this point we have discussed only tensile load applications during the initial tightening of the screw. It must be realized that shear, torsional, and bending loads are also applied during the initial tightening of the abutment screw. More information on these load applications during tightening can be found in the Bickford text.

In tightening the abutment screw we always want the maximum possible preload. Things that affect the preload are friction, geometric variables, embedment relaxation, elastic interactions, torque, creep, hole interference, fit of the threads, component accuracy, differential thermal expansion, and the operator.

If we tighten the screw to 100% of ultimate strength the screw will break. If we tighten to 80% of the ultimate, the screw would be past yield. If we were to subtract 5% from the tensile yield strength of the screw to account of torsional stress introduced when torque is applied, and another 5% for other specification limits, and yet another 5% for safety factors, the final result is a suggested upper limit on desired clamp force equal to 62% of the ultimate strength of the screw. A target preload can be determined by first determining the yield strength of the screw. The upper limit suggested for nongasketed joints for which few "low preload" problems have been encountered (self-loosening, fatigue, etc.) and where torque control will be used at assembly is 70-75% of the yield.

**McGlumphy EA, Robinson DM, Mendel DA. Implant superstructures: A comparison of ultimate failure force. Int J Oral Maxillofac Implants 1992;7:35-39.**

## **Abstract**

**Statement of Problem.** Fracture of implant prosthetic components has been one of the most frequently cited complications. Because of these reported prosthodontic failures, alternative implant abutments and screws with suggested strength superiority have been manufactured. However, little quantitative data are available to support these claims.

**Purpose of Study.** This study was designed to quantify and compare the force necessary to cause failure in various implant systems under a cantilever load. The specific intent was to provide a basis for comparison regarding the structural properties of implant component parts of varying materials and design.

**Material and Methods.** The test sample consisted of the following combinations of implants and abutments: 1) Brånemark standard 3.75 x 10 mm implant and the 4.0 mm standard abutment, 2) Brånemark standard 3.75 x 10 mm implant and the 4.0 mm 3I tapered abutment, 3) Swede-Vent 3.75 x 10 mm implant and the 4.0 mm TSA abutment, 4) Integral 4.0 x 10 mm implant and the 4.0 mm non-fluted shouldered abutment, 5) Screw-Vent 3.75 x 10 mm implant and the 4.0 mm TT15 abutment, 6) IMZ 4.0 x 11 mm implant and the 4.0 mm Titanium IME abutment, 7) IMZ 4.0 x 11 mm implant and the 4.0 mm Polyoxymethylene IME abutment, 8) Steri-Oss 4.0 x 10 mm implant and the 4.0 mm PME abutment, and 9) IMZ 3.3 x 10 mm implant and the 2.0 mm Polyoxymethylene IME abutment.

The implants were embedded in an aluminum test ring. Each abutment was tightened to place, and an 18.0 mm cantilever test prosthesis, specific for each abutment and gold cylinder, was prepared. The prostheses were tightened on their respective abutments using the appropriate coronal screw. The entire apparatus was assembled on the MST testing machine. A load was applied at the rate of 1 mm/in until complete fracture occurred. The force necessary to cause failure was calculated and the location of failure was recorded. an  $n = 5$  was used for each abutment. The mean ultimate failure force was calculated for each implant and abutment combination.

**Results.** The force necessary to cause failure ranged from 1.22 to 17.23 kg. No significance differences were found between the Integral shouldered, Swede-Vent TSA, and the Screw-Vent TT15 abutments ( $P < .01$ ). No significant difference was demonstrated between the Brånemark standard abutment and the IMZ IME abutment. A significant difference was demonstrated between the mean ultimate failure force values for these two groups. Significant differences were also demonstrated between these groups and all other implant abutment combinations.

All five samples of each test type fractured at the same location during each trial. The fracture locations were: 1) Brånemark and standard abutment (abutment screw) [7.66 kg], 2) Brånemark and 3I tapered abutment (abutment screw) 9.34 kg], 3) Swede-Vent and TSA

abutment (abutment screw) [10.10 kg], 4) Integral and shouldered abutment (abutment screw) [10.19 kg], 5) Screw-Vent and TT15 abutment (abutment screw) [9.97 kg], 6) IMZ 4.0 and Titanium IME abutment (retaining screw) [7.72 kg], 7) IMZ 4.0 and 4.0 Polyoxymethylene IME abutment (retaining screw) [4.78 kg], 8) Steri-Oss and PME abutment (retaining screw) [17.23 kg], and 9) IMZ 3.3 and 2.0 mm Polyoxymethylene IME abutment (abutment screw) [1.22 kg].

**Conclusions.** Superstructures of larger diameters and those constructed from titanium alloy provided the most resistance to failure.

**Clinical Implications.** While solving some short-term problems, stronger implant abutments could conceivably cause other problems that may be more deleterious to the patient.

### **Summary of Reviews**

The material in the Bickford text as well as the report from McGlumphy et al. provide information about screw joints, torque forces and preload.

### **COMPLICATIONS - Screw Joint Loosening.**

**Bickford, JH (ed).** *An Introduction To the Design And Behavior Of Bolted Joints.* New York, Basel, Hong Kong: Marcel Dekker, Inc., 1995: 3-79, 175-367, 514-600, 733-797, 840-871.

Screw joint failure as described by Bickford occurs in two stages. The first consists of external functional loading applied to the screw joint that gradually lead to the effective erosion of the preload in the screw joint. Any transverse or axial external force that causes a small amount of slippage between the threads releases some of the stress, and some of the preload is lost. The greater the joint, the greater the resistance to loosening, and the more stable the joint. As long as the frictional forces between the threads remains large, a greater external force will be required to cause loosening. Once the critical load exceeds the screw joint preload, it becomes unstable. The external load rapidly erodes the remaining preload and results in vibration and micromovement which leads to the screw backing out. Once this second stage has been reached, the screw joint ceases to perform the function for which it was intended and has failed.

One might assume that this scenario applies to the abutment implant interface as well. It also assumes that the abutment has been assembled onto the implant properly, and the optimum preload and joint stability has been achieved at this interface through the tightening requirements for the abutment screw. Unfortunately, strong scientific or compelling evidence reporting these assumptions to be true have not been reported.

It would seem prudent that in order to understand the mechanism of screw loosening and the related biomechanics, it would be appropriate to first understand the mechanics of screw tightening. What is the exact mechanical configurations of the abutment implant screw joint, after assembly and the application of the preload, but before an external force is applied to the implant column? Once the baseline assembly configuration is known, then the external forces can be applied using dynamic methodologies to determine just how the joint responds. It is the mode of the joint response that will shed light on how screw loosening occurs.

### **Summary of Reviews**

The finite element method has been suggested as a means for studying not only the individual implant components in the implant system, but the dynamic nature of the interactions of the component during the introduction of the preload and following external force applications. The finite element method has been used in implant research, although to a limited degree. However, for industrial applications this research methodology has been used extensively by mechanical engineers.

**Jörn us L, Jemt T, Carlsson L. Loads and designs of screw joints for single crowns supported by osseointegrated implants. *Int J Oral Maxillofac Implants* 1992;7:353-359.**

## **Abstract**

**Statement of Problem.** Screw loosening has been reported as a complication associated with patient treated with implants for multiple tooth loss. More recently, implant therapy has been provided for patients missing a single tooth. When subjected to various load applications, the question to be answered is, "Will single tooth implant also experience screw loosening similar to what has been reported for short-and long-span implant bridges?"

**Purpose of Study.** This study approached the problem of screw stability by calculating the maximum occlusal forces in vivo for patients with single implant restorations that use

only one screw to secure the prosthetic reconstruction to the implant. The measurements of occlusal forces together with geometric parameters for individual patients were then used to determine the necessary holding capabilities of an experimental screw joint.

**Material and Methods.** This project was divided into five parts. The first part involved four patients with single implant restorations randomly selected for maximal occlusal force registration and calculations. The patients were provided with standard Brånemark implants and single tooth abutments. A bitefork was placed between the maxilla and the mandible, and the patients were asked to bite with maximal strength to pain level. The bitefork was calibrated for loads up to 700 N against an Instron compression test machine (Instron Corp Canton, Mass). The maximum occlusal force ranged from 140 N to 390 N for the four patients.

The recorded levels of maximal occlusal force for the four patients were then used in the second part of the project to calculate the maximum load in the implant screw joint. Using these data the torque acting on the screw joint was calculated.

In the third part of the study, four types of screws were selected for evaluated using a bench test to determine their yield points, and ultimate tensile strengths (Titanium Grade 1 with conical head, Titanium Grade I with flat head, Titanium Grade 3 with flat head, Gold screw with flat head).

In the fifth part a standard implant was mounted in a block and a single tooth abutment cylinder was secured to the implant by one of the screws tested. Each screw was initially tightened to a specific torque by a torque gauge (Tohnichi Mfg. Co, Tokyo, Japan). The torque needed to rotate the abutment within the play of the hexagon fitting to the implant was used as a measure of stability of the screw joint (five repeated tests). This torque was recorded with the torque gauge attached to the abutment cylinder. The torque needed to rotate after the initial tightening was recorded as "before settling." The screw joint was then loaded with an axial force of 70 N for 100 cycles. The test set-up was rotated 180 degrees and another 100 load cycles were applied. The torque needed to rotate the abutment after the cycling test was recorded as "after settling." To simulate extended function, the gold screw (type d gold alloy) was loaded for 1 million load cycles. After the load cycling, the torque needed to rotate the abutment was measured.

The tests in part five were repeated with each of the four screws tightened with a tightening torque of only 20 Ncm.

**Results.** The maximum torque acting on the abutment screws was calculated to be between 21 and 59 Ncm (Titanium Grade 1 with conical head [50 Ncm], Titanium Grade I with flat head [30 Ncm], Titanium Grade 3 with flat head [21 Ncm], Gold screw with flat head [59 Ncm]). The only screw design with a holding capability over 50 Ncm after settling was shown to be the gold alloy screw (35 Ncm used to tighten). Accordingly, only that screw would be able to predictably hold the single tooth in the recorded extreme load situations.

The calculated maximum force on the screw joints were (Titanium Grade 1 with conical head [920 N], Titanium Grade I with flat head [400 N], Titanium Grade 3 with flat head [586 N], Gold screw with flat head [1027 N]).

The approximate torque needed to rotate the abutments tightened to the optimal (highest possible) tightening torque "before settling" were (Titanium Grade I with flat head [12 Ncm], Titanium Grade 3 with flat head [48 Ncm], Gold screw with flat head [72 Ncm]). The approximate torque needed "after settling" were (Titanium Grade I with flat head [3 Ncm], Titanium Grade 3 with flat head [15 Ncm], Gold screw with flat head [52 Ncm]).

The approximate torque needed to rotate the abutments that were all tightened to 20 Ncm "before settling" were (Titanium Grade 1 with conical head [4 Ncm], Titanium Grade I with flat head [12 Ncm], Titanium Grade 3 with flat head [15 Ncm], Gold screw with flat head [30 Ncm]). The approximate torque needed "after settling" were (Titanium Grade 1 with conical head [2 Ncm], Titanium Grade I with flat head [3 Ncm], Titanium Grade 3 with flat head [5 Ncm], Gold screw with flat head [22 Ncm]).

The approximate torque needed to rotate the abutment after the extended load cycling test went from the before settling value of 72 Ncm to 45 Ncm after 1 million cycles.

**Conclusions.** The design of the head of the screw is of significance and should allow a maximum of torque to be introduced in the stem of the screw. The conical screw lost a major part of the torque with settling thereby allowing less force in the threads, which resulted in lower values for the screw stability tests. If a bending force (excessive bending) on the screw joint causes a load larger than the yield strength of the screw, a plastic permanent deformation of the screw results with a loss of tensile force (preload) in the screw stem. This resulted in reduced contact forces between the abutment cylinder and the implant, and consequently the screw joint more easily loosens.



Because no bearing surface is smooth the two surfaces when subjected to external loads will experience micromovements between the surfaces. Wear of the contact areas might be a result of these motions, thereby bringing the two surfaces close to each other. When the settling effect is greater than the elastic elongation of the screw, it works loose because there are no longer any contact forces to hold the screw.

**Clinical Implications.** The main probably cause for screw loosening is poor tightening although the design of the screw is probably another factor. In this study the torque needed to rotate the abutment was used as a criterion for screw stability. Overload and external forces can produce a loss of preload in certain situations and loosening of the abutment screw. The design of the head of the screw should allow a maximum of torque to be introduced in the stem of the screw (Preload).

**Andersson B, Odman P, Lindvall A-M, Lithner B. Single-tooth restorations on osseointegrated implants: Results and experiences from a prospective study after 2-3 years. Swedish Dental Journal Supplement 108, 1995.**

Fifty-seven patients were followed for 2 years and 34 patients for 3 years in a study on the CeraOne system. Few problems were observed and the system was proven to achieve very good aesthetic results and to avoid the complications of screw loosening and fistulas. Only one patient experienced a loose screw loosening during the period of the study. One implant was lost, giving a cumulative success rate of 97.3% at the 3-year examination. All-ceramic crowns were seated for 95% of the subjects and only four of the crowns were classified as failures.

### **Summary of Reviews**

It would seem from the literature reviewed that screw loosen may not be as great a problem today as it was in the early days of implant therapy. However, it must also be pointed out that in the case of the single tooth implant replacements, the abutment screw continues to be the weakest link in the system. With cementation of crowns over the abutment replacing the retaining screw, the response of the abutment implant screw joint is hidden from view. Some author have demonstrated in vitro that under reasonable force applications the gold screw securing this joint can be damaged. Whether or not the damage occurs in the clinical situation is unknown at this time. Nevertheless, the

scientific community needs to continue to investigate the abutment implant screw joint in order to understanding the mechanism of failure, and how to prevent it.

Examining the stability of the abutment implant screw joint must first begin with investigations dealing with the mechanism of screw tightening before one can determine the mechanism of screw loosening. Two questions immediately come to mind. What is the physical configuration of the abutment implant joint after the clinician assembles the components and places the abutment screw? What is the stress distribution within the screw joint prior to, during, and following the initial loading of the joint with the preload? In the absence of this information it is extremely difficult to determine just how the joint has responded when an external force has been applied.

## **COMPLICATIONS - Relationship of Abutment Implant Hexagons.**

**Binon PP. Evaluation of machining accuracy and consistency of selected implants, standard abutments, and laboratory analogs. Int J Prosthodont 1995;8:162-178.**

### **Abstract**

**Statement of Problem.** The introduction of the Brånemark implant system stimulated the commercial availability of 25 variations of implants having external hexagonal extension on the top surface of the implant. With expanded implant use for single tooth and partially edentulous applications, the primary purpose of the implant hexagon has changed from a rotational torque transferring mechanism used during the surgical placement of the implant to a prosthesis indexing and antirotational mechanism. The machined implant hexagon and its matching abutment internal hexagon comprise the primary docking device between the implant and the abutment. The amount of freedom between the implant and abutment hexagons has been implicated as a factor in screw joint instability

**Purpose of Study.** The purpose of this study was to evaluate the machining accuracy and consistency of thirteen implants having external hexagons and to determine the rotational freedom between the implant hexagon and the internal hexagon of the abutment counterpart.

**Material and Methods.** Five randomly selected implants were measured for each implant system of 15 manufacturers that formed the experimental population. Measurements

were made at the following locations;: coronal (head) diameter, body diameter across the threads (width), height and width of the hexagon from flat surface to flat surfaces. Two piece standard abutment collar width and collar length were also measured.

Abutment to implant hexagonal extension rotational freedom (movement) was measured in degrees.

**Results.** The result of major interest with respect to the purpose of this study was the flat to flat measurements of the implant hexagon. Flat to flat measurements varied from manufacturer to manufacturer. Data varied from 2.680 (sd .012) for Implant Support Systems, to 2.694 (sd .005) for SwedeVent, to 2.697 mm (sd .001) for 3I, to 2.707 (sd .001) for the Brånemark system. Rotational freedom between matching hexagons was measured for 5 manufacturers. The least amount of rotational freedom was recorded for 3I with 4° and 4.6° of rotation. The Brånemark system and for Implant Support System rotations were recorded as 6.7°.

**Conclusions.** It was the author's opinion that hexagonal rotation of less than 5° is desirable for optimal joint stability.

**Clinical Implications.** Machining specifications can vary significantly between manufacturers. However, there are systems that demonstrated close tolerances, excellent accuracy, and consistency.

**Binon PP.** The effect of implant/abutment hexagonal misfit on screw joint stability. *Int J Prosthodont* 1996;9:149-160.

## **Abstract**

**Statement of Problem.** Since the introduction of the Brånemark implant system the machined hexagon on the coronal surface of the implant has gradually transformed from a placement coupling into an indexing and antirotational mechanism. Exact transference and indexing to the working cast can vary by several degrees, and screw joint stability and screw loosening continue to be issues in single tooth and partially edentulous applications. Although component misfit has been implicated in screw loosening, one major manufacturer minimizes its importance and has stated that "a tighter inter-component fit, is a manifestation of a self-defeating strategy. The improvement defeats....the freedom of fit conscientiously engineered into the original." The "freedom of fit" parameter will

tolerate horizontal fitting errors. Such horizontal misfits are reported to apply loads to gold screws, abutment screws, the implant, and the bone.

**Purpose of Study.** The purpose of this study was to evaluate the effect of misfit between the implant and abutment hexagons on abutment screw loosening during simulated function.

**Material and Methods.** A cyclic loading instrument was designed and constructed that would produce asymmetric loading and unloading cycles. The machine would permit 10 samples to be tested simultaneously. Fifty standard Brånemark implant clones were used in this study. The mean flat to flat measurements of the external hexagons was 2.684 mm. Special conical nonsegmented abutments with a special loading table were machined from Grade 3 titanium. Ten abutments were made with internal hexagons that varied incrementally by 0.005 inches. The total range in sizes was from 0.1065 to 0.1110 inches. The tolerances were set to 0.002 inches. The abutments were connected to the implants using standard Grade 23 titanium alloy screws. The screws were tightened using a 30 Ncm torque. A 30 pound load (133.3 N) was applied to the load table as a conservative value for a clinical functional load.

**Results.** Screw joint failure ranged from 134,895 to 9,337,080 cycles. The tightest screw joint failed at a mean of 6.7 million cycles. Joints with the largest variance failed at 2.5 to 1.1 million cycles.

**Conclusions.** The greater the misfit between the external and internal hexagons, the more the abutment can rotate, resulting in greater preload loss and lower joint stiffness. The data indicated that when the abutment rotates more than a few degrees, the preload is substantially compromised and the joint enters the second phase of failure leading to rapid progressive screw loosening. When rotation exceeded 2 degrees, resistance to screw joint failure decreased from 6.7 to 4.9 million cycles. If the abutment rotated more than 5 degrees, joint stiffness and preload was sufficiently compromised to allow the screw joint to enter second stage failure. after which screw loosening occurred rather rapidly (2.5 to 1 million cycles).

**Clinical Implications.** Positive hexagonal engagement and elimination of rotational freedom resulted in a stiffer screw joint that was substantially more resistant to screw loosening.

## Summary of Reviews

It would seem from the literature reviewed that the precision of fit between the implant and abutment hexagons plays a role in maintenance of the preload. What is unknown, is the relationship of the hexagon's at assembly and after the preload is achieved prior to any external loading.

## COMPLICATIONS - Methods to Study Preload.

Five main methods of research have been employed to obtain a better understanding of the optimum torque and preload required to maximize screw joint stability. These include; 1) theoretical analysis of the implant screw joint system based on engineering principles,<sup>1,2</sup> 2) strain gauge evaluation of the force/bending moments transmitted through the abutment,<sup>3,4</sup> 3) examination of screw elongation and loosening torque,<sup>5</sup> 4) assessment of the torque required to produce rotation of an abutment within "the play" of the hexagonal fitting,<sup>6-8</sup> 5) Finite Element Contact Analysis of the screw joint complex.<sup>9,10</sup> Regardless of the research method employed, three major areas of study have emerged; 1) preload of the screw joint, 2) effects of application of occlusal load, and 3) effect of fit of components of the screw joint system.

Sakaguchi et al.<sup>9</sup> indicated that preload of the abutment screw resulted in contact at the implant-abutment interface, the top four complete threads of the abutment screw, and at the abutment screw-abutment interface. Once the gold retaining screw was tightened, the total contact force at the abutment-implant interface increased 20.2% in the axial direction. However, there was a decrease in the total contact force at the abutment screw-abutment interface resulting in a reduction of preload between the abutment screw and the abutment by 50%. Maximum tensile stresses in the screws after preload were less than 55% of the yield stress. Increasing tightening torque on the gold retaining screw further decreased clamping force between the abutment screw and abutment.

## Summary of References

1. Patterson, E.A. and Johns, R.B. Theoretical analysis of the fatigue life of fixture screws in osseointegrated dental implants. *International Journal of Oral & Maxillofacial Implants* 7(1):26-33, 1992.

2. Weinberg, L.A. and Kruger, B. A comparison of implant/prosthesis loading with four clinical variables. *International Journal of Prosthodontics* 8(5):421-433, 1995.
3. Glantz, P.O., Rangert, B., Svensson, A., Stafford, G.D., Arnvidarson, B., Randow, K., Linden, U., and Hulthen, J. On clinical loading of osseointegrated implants. A methodological and clinical study. *Clinical Oral Implants Research* 4(2):99-105, 1993.
4. Patterson, E.A., Burguete, R.L., Thoi, M.H., and Johns, R.B. Distribution of load in an oral prosthesis system: an in vitro study. *International Journal of Oral & Maxillofacial Implants* 10(5):552-560, 1995.
5. Haack, J.E., Sakaguchi, R.L., Sun, T., and Coffey, J.P. Elongation and preload stress in dental implant abutment screws. *International Journal of Oral & Maxillofacial Implants* 10(5):529-536, 1995.
6. Jörn us, L., Jemt, T., and Carlsson, L. Loads and designs of screw joints for single crowns supported by osseointegrated implants. *International Journal of Oral & Maxillofacial Implants* 7(3):353-359, 1992.
7. Binon PP. Evaluation of machining accuracy and consistency of selected implants, standard abutments, and laboratory analogs. *Int J Prosthodont* 1995;8:162-178.
8. Binon PP. The effect of implant/abutment hexagonal misfit on screw joint stability. *Int J Prosthodont* 1996;9:149-160.
9. Sakaguchi, R.L. and Borgersen, S.E. Nonlinear contact analysis of preload in dental implant screws. *International Journal of Oral & Maxillofacial Implants* 10(3):295-302, 1995.
10. Sakaguchi, R.L. and Borgersen, S.E. Nonlinear finite element contact analysis of dental implant components. *International Journal of Oral & Maxillofacial Implants* 8(6):655-661, 1993.

**Occlusal Rehabilitation Of the Edentulous Patient  
With Or Without Implants**

**Dr. Brien R. Lang**





# OCCLUSAL REHABILITATION OF THE EDENTULOUS PATIENT

*International Prosthodontic Workshop on Complete Denture Occlusion.* Lang BR, Kelsey CC (eds), The University of Michigan, School of Dentistry, 1973, xxvi+338 p.

The subject of complete denture occlusion was the basis for the International Prosthodontic Workshop in Ann Arbor in 1972. Approximately 100 individuals address this topic from seven different perspectives.

Section I	ALVEOLAR BONE
Section II	THE PHYSIOLOGY OF JAW MOVEMENTS
Section III	ARTICULATORS AND ARTICULATION
Section IV	OCCLUSAL PATTERNS AND TOOTH ARRANGEMENTS
Section V	DENTAL MATERIALS
Section VI	POST-INSERTION CHANGES
Section VII	HUMAN FACTORS

The single most important finding from the Workshop was the statement summarized in the report from the Section on Occlusal Patterns and Tooth Arrangements. It states, "At the present, the choice of a posterior tooth form or arrangement for complete dentures is an empirical procedure. Little or no supporting research is available to the profession relative to the overall effect on esthetics, function, and the long-term maintenance of the supporting tissues. All of the occlusal forms may be arranged with or without bilateral balance. A great many claims and counterclaims appear in the literature extolling the merits of a given concept or pointing out the deficiencies of another. Scores of clinically competent and intellectually honest professionals document clinical experiences in a very subjective manner. Since their experiences differ and their conclusions conflict, the practitioner is left to make his or her own choice. The available research fails to identify a superior tooth form or arrangement, therefore it appears logical to use the least complicated approach that fulfills the *requirement of the patient.*"

**Glossary of prosthodontic terms, 6th edition. J Prosthet Dent 1994;71:41-112.**

Any discussion in prosthodontics would be incomplete without a review of nomenclature and terminology. We cannot communicate effectively unless we are speaking the same language. The sixth edition of the Glossary of Prosthodontic Terms published in the *Journal of Prosthetic Dentistry* in January 1994 should be the reference source for all scientific writings or discussions.

In the past, we generally used the term occlusion in discussions, however, the more appropriate term is dental articulation.

**"Dental Articulation:** the contact relationships of maxillary and mandibular teeth as they move against each other - usage: this is a dynamic process"

Centric occlusion is another term used in the past that should be replaced with maximum intercuspation.

**"Maximum intercuspation:** the complete intercuspation of the opposing teeth independent of condylar position"

Centric relation is a term of importance in occlusion, and it is most difficult to discuss dental articulation in the absence of this term. Of the seven definitions in the Glossary, I would suggest definition #3 because it describes this position on the basis of clinical criteria observable by the clinician.

**"Centric relation:** the most retruded relation of the mandible to the maxillae when the condyles are in the most posterior unstrained position in the glenoid fossae from which lateral movement can be made, at any given degree of jaw separation."

Recognizing that any discussions about occlusion should for all intensive purposes center around dental articulation, it would seem appropriate to have a clear understanding about the definitions of the three more commonly described articulations in the dental literature, namely, balanced articulation, monoplane articulation, and lingualized articulation.

**"Balanced articulation:** the bilateral, simultaneous, anterior, and posterior occlusal contact of teeth in centric and eccentric positions - See CROSS ARCH B.A."

**"Cross arch balanced articulation:** the simultaneous contact of the buccal and lingual cusps of the working side maxillary teeth with the opposing buccal and lingual cusps of the mandibular teeth, concurrent with contact of the nonworking side maxillary lingual cusps with the mandibular buccal cusp"

Considering the fact that articulation should be the key element contained in the definition, a more appropriate description of balanced articulation would be: "the occlusal contacts of maxillary and mandibular teeth initially in maximum intercuspation, and their continuous contacts during movements from this initial position along specific working, balancing, and protrusive guidance pathways developed on the occlusal surfaces of the teeth."

**"Monoplane articulation:** the arrangement of teeth by which they are positioned in a single plane."

Unfortunately, this definition does not reflect motion, which is the important element in articulation. Perhaps the definition should read, "the occlusal contacts of maxillary and mandibular teeth initially in maximum intercuspation, and the disocclusion of the posterior teeth as a result of their arrangement in a single plane, and the contacts of the anterior tooth during movements of the mandible."

Lingualized articulation does not appear in the Glossary of Prosthodontic Terms. However, lingualized occlusion does.

**"Lingualized occlusion:** first described by S. Howard Payne, DDS, in 1941, this form of denture occlusion articulates the maxillary lingual cusps with the mandibular occlusal surfaces in centric, working, and nonworking mandibular positions. The term is attributed to Earl Pound"

Although the definition specifies movement, it fails to describe the tooth contact relationships. A better explanation of lingualized articulation would be, "the occlusal contacts of the maxillary lingual cusps of the posterior teeth initially with the occlusal surfaces and marginal ridges of the mandibular teeth in maximum intercuspation, and the continuous contacts of the lingual cusps with the mandibular teeth during various movements of the mandible."

It is interesting to note that little mention is made of the contact relationships of the anterior teeth in the Glossary definitions regarding occlusal concepts and articulation, even though incisal guidance was a major factor in the development of "engineered" teeth by Gysi in 1929, and the formulation of the "Laws of Articulation" described by Hanau in 1926.

## **ARTICULATION AND ARTIFICIAL TEETH**

**Gysi, Alfred. Practical application of research results in denture construction. Am Dent A J 1929;16:199-223.**

Most of the artificial teeth that are available to the profession today were developed by the manufacturers in response to the development of the dental articulator in the early 1900's. These early designs, most of which are still in use today, employ geometrical principles and are considered "engineered" artificial teeth, or they are conceived designs by the master carver that would hopefully fulfill the requirements of function for the patient, and denture base stability. The concept of an engineered tooth was the direct result of the application of geometrical concepts into articulator design as described in the early work of Bonwill and Gysi. Basically, the articulator became the kinematic instrument that directed the carving tools which cut the primordial forms that were eventually carved into the anatomic tooth forms. The classical article describing the carving of denture teeth was that of Gysi in 1929. Gysi used four strips of metal to cut forms that he considered to be similar to "sharks' teeth" which he mounted on a dental articulator. A block of plaster was attached to the opposite member of the articulator and the various movements of the articulator were made to define the primordial forms of the masticatory surfaces of the maxillary premolars and molars. Gysi later replaced this rather crude method of tooth carving with geometric concepts whereby, "given the rotation points for the right and left lateral bites and the protrusive movement, one can determine by purely scientific methods, and without the shark's teeth, the size and inclination of each facet of each tooth."

These early applications of geometric form and motion were the basis for the development of artificial teeth. The dynamic three-dimensional nature of these substitutes and the inclinations and angles produced on their surfaces demonstrated

the principles of geometry and articulation. Interestingly, the cusp angles created by this process are not oriented in the direction used in the definition of cusp angle. Cusp angle is defined as the slope of a cusp with a perpendicular line bisecting the cusp, measured mesiodistally or buccolingually. This cusp angle has little to do with the angles created as a function of jaw movements and articulation, nor does it play a role in the contacts with the opposing dentition. In fact, the cusp angulation designated for some teeth (i.e., 30° or 33°) are not related at all to the inclinations and cusp angles functioning as guidance pathways during articulations with their antagonists.

The earliest posterior tooth designed by Gysi as an engineered tooth was the Trubyte 33° posterior. These teeth were carved with a 33° condylar inclination and a similar incisal guidance. These mechanical equivalent end-controlling factors were selected for two reasons: 1) the average condylar slope for adult patients as determined by Gysi was approximately 33° and 2) Gysi had observed as early as 1911 that a reduction in the incisal guidance from an average of 60° to 80° for natural teeth to 30° to 35° for the edentulous patient, would reduce lateral forces and increase denture base stability. However, data to support the lateral force reduction and increased denture base stability by present day standards was not reported. Measurement of the occlusal surface of the 33° teeth created by these end-controlling factors demonstrates very few, if any 33° cusps.

#### **Additional Readings:**

Bonwill WGA. Geometrical and mechanical laws of articulation. Anatomical articulation. *Odont Soc Pa Tr* 1885;nv:119-33.

Bonwill WGA. Scientific articulation of the human teeth as founded on geometrical, mathematical and mechanical laws. *Dent Items Interest* 1899;21:617-36, 873-80.

**Suggestions for the arrangement and articulation of Pilkington-Turner 30 degree posteriors by Trubyte. Dentists' Supply Company of New York. York, PA, 1966, p.27.**

**The new Pilkington-Turner vacuum fired 30 degree posteriors. Dentists' Supply Company of New York. York, PA, 1953, p.48.**

During the 1920's, bone loss under dentures was thought to be caused by higher cusp teeth (45°) and thus, all sorts of mechanical posterior teeth were introduced. The emphasis on cusp reduction resulted in Gysi and W. C. Whitmore developing the 20° porcelain posteriors in 1930. The 20° teeth were carved as a working unit accurately to the mathematical plan for its design. The condylar guidance for the cutting instrument was set at 30° to the horizontal and the sagittal incisal guidance was 10°. Historically, the Trubyte 20° posterior teeth were followed by a 30° posterior tooth designed by Drs. Pilkington and Turner. The 30° posterior teeth were mathematically designed with 30° horizontal condylar and incisal guide angles. Many other anatomic and nonanatomic posterior tooth forms have been developed

since Gysi introduced the engineered tooth concept. In most instances, their occlusal morphology has been based on engineering principles and articulation.

**Hanau, RL. Articulation defined, analyzed and formulated. Am Dent A J 1926;8:1694-1709.**

In 1925, Rudolph L. Hanau presented the profession with a discussion paper entitled, "Articulation, Defined, Analyzed and Formulated." His theories were formulated without experimental evidence, yet accepted by the profession with only slight modification of his original concepts. What evolved was an interpretation of the laws of articulation into an interrelationship; which Hanau called "factors governing articulation." Hanau stated, "balanced articulation is the change from one balanced occlusion to another while the masticatory surfaces remain in balanced contact." His concepts were limited to mechanical balanced articulation thereby distinguishing them from physiologic balanced articulation. Mechanical articulation involves as Hanau stated, "precise laws of articulation based on geometry, an occlusion constructed on an articulator completely controlled by mechanics." Hanau further stated that, "of the five factors governing articulation it is 'relative cusp height' that unites the manufacturers tooth form to the concept of mechanical balanced articulation." Hanau defines "relative cusp height" as the projection on the cusp base of the movement of a point directed along the incline from the base to the cusp summit. The magnitude of this guiding path is related to its projection onto an accepted coordinate system. Cusp angle is the conventional term and being described in degrees, was adhered to in expressing the laws of articulation." This definition is probably more significant in relating articulator end-controlling factors and the angular inclines developed mathematically during articulation to what will be required on the occlusal surface of a supplied tooth in order to achieve occlusal balanced articulation as a maxillary tooth passes over the surface of its mandibular antagonist.

**Sharry, JJ. Arrangement and occlusion of teeth, (In Sharry, JJ (ed): *Complete Denture Prosthodontics*. McGraw-Hill, Book Co., Inc., 1962, p. 235-259.)**

Cusp angulations and their effect on balanced articulation, are discussed in Sharry's text, the second edition, chapter 15. Sharry states that the inclination of the teeth and the compensating curves are of more importance to balance articulation than is the inclination of the occlusal plane. The inclination of a particular tooth is of little value unless the tooth is placed vertically and thereby re-establishing the compensating curves produced in its occlusal design. In fact, if one refers back to the tooth carving process, we soon realize that the compensating curves, both anteroposteriorly and mediolaterally, are cut into the tooth during carving as a function of the cutting tools' position within the cutting instrument. To introduce further compensation during the arrangement of teeth, defeats the engineering principles developed in carving the tooth.

For example, with regards to protrusive balance, if the horizontal condylar guidances were 30 degrees and the horizontal incisal guidance was also 30 degrees,

teeth with 30 degree cusps would balance perfectly if all contacted a 0 degree plane of occlusion. Sharry further states, "if the condylar guidances were 45 degrees and the incisal guidance 30 degrees, teeth with 30-degree cusps, if all contacted a 0 plane of occlusion, would not balance, but instead would separate posteriorly." Indeed, Sharry was right, however, most clinicians would suggest increasing the compensating curve during tooth arrangement to achieve balance in this example. Doing so, however, would destroy the relationship of the engineered guidance pathways to the opposing dentition. The better choice would be to select a tooth with steeper cusp angulations.

Recognizing the relationship of the influence of the end-controlling factors on articulation, and the methods used to create the "engineered" posterior artificial teeth, one soon realizes that a 30-degree tooth with its complex occlusal surface must be arranged in the articulator in the same relationship to the end-controlling factors as it was in the carving instrument when its primordial form was created, if one wishes to achieve a balanced articulation. Any deviation from this position will alter the relationship of the guidance pathways created in carving the tooth to the guidance pathways established by the end-controlling factors during movements of the articulator. Manipulation, rotation, raising, lowering, or repositioning of the teeth to a different position to gain a balance articulation defies the existence of solid geometry as a science and produces occlusal contact relationships in either the static positions or during articulation that are not within the design concepts of the teeth. More strongly stated, one cannot create an exact balanced articulation by merely moving the teeth around. Balanced articulation is created through arrangement in the best possible maximum intercuspal position, in a slightly open occlusal vertical dimension, followed by selective occlusal equilibration to create the exact primordial forms needed that can be formed into the cuspal inclinations required to achieve mechanical balanced articulation as influenced by the several guidances established in programming the dental articulator.

As stated earlier, the cusp angles for most posterior teeth do not come close to achieving the needed cusp heights for the guidance pathway angles established by the end-controlling factors transferred from the patient to the articulator.

**Lang, BR. and Thompson, RM.. The Cusp Angles of Artificial Mandibular First Molars. J Prosthet Dent 1972;28:26-35.**

These authors measured the cusp angles for the mandibular first molars for 23 different manufacturers of posterior teeth. The cusp angulations were measured from the cusp base along the guidance pathways for the various movements (working, balancing, protrusive). Little correlation was found between the measured angles, and the cusp classifications for the posterior teeth.

**COMMENTS:**

Articulation involving the artificial tooth and the Laws of Articulation although similar in theory and based on the science of geometry, are quite different in practical use. In the design of an artificial tooth to create balanced articulation,

there are specific relationships that exist between the cusps and fossae of opposing teeth that are needed to maintain harmony of contact during various movements. These contact relationships were established in the design of the tooth mold using four of the five factors described by Hanau to set the carving instrument to create the fifth factor or cusp inclination in the primordial forms for the teeth. These four factors were also recorded from the patient and transferred to the dental articulator to develop the occlusion for the patient. These factors although interrelated in both situations (tooth design and patient articulation), are not necessarily the same or interchangeable.

The five principal factors in the design of the tooth were: 1) inclination of the horizontal and lateral guidance of the cutting instrument, 2) inclination of the horizontal and lateral anterior guidance of the cutting instrument, 3) orientation of the occlusal surface for carving the primordial form, 4) position of the carving tools to create both the anteroposterior and mediolateral compensating curves, and 5) the resultant inclination of the cusps produced in the primordial tooth form.

For the patient, the horizontal and vertical overlap of the anterior maxillary and mandibular teeth establishes the incisal guidance and are the direct results of the esthetic needs of the patient. The *incisal guide angles*, both horizontal and lateral established by the dentist in this manner can range anywhere from 0° to greater than 45°. It is understood that the more closely the horizontal incisal guide angle approaches 0°, the more stable the dentures will be because of the reduction of lateral inclines. In maximum intercuspation, the anterior teeth as stated previously are usually arranged without contact. However, contact between the anterior teeth will occur when the mandible moves in a lateral or protrusive direction during articulation.

The *condylar inclination* is determined by the patient. The dentist has no control over the condylar inclination and cannot change or modify it to fit a particular occlusion. Among the several factors that can influence the articulation of teeth during movements, the factors of condylar guidance and incisal guidance play extremely important roles.

For purposes of clarity and convenience, the other factors relating to occlusion have been slightly revised. A few words have been changed such as *height* to *inclination* because the inclination of the cusp is more important in arranging teeth. The phrase *plane of orientation* has been changed to *orientation of the occlusal plane* because this describes more adequately what is actually done in developing the occlusion. The word *orient* means "to find the proper bearings or relations of." Thus *orientation of the plane* is an action performed by the dentists whereas *plane of orientation* implied that this factor already had been determined.

The inclination of condylar guidance and inclination of the incisal guidance control the movements of the articulator whereas the orientation of the plane may be changed by the dentist during the development of the occlusion to meet the needs of the patient.

Condylar inclination, which is the only factor totally controlled by the patient is obtained by means of a protrusive registration. The condylar factor is transferred to the condylar guidance setting on the articulator. The incisal guide is influenced by the amount of vertical and horizontal overlap developed during the arrangement of the maxillary and mandibular anterior teeth. The greater the horizontal overlap, the lower the angle of inclination as long as the vertical overlap remains the same; and, of course, the less the vertical overlap, the less the angle of inclination. The posterior teeth are closer to the action of the incisal inclination than to the action of the condylar inclination. Therefore a greater influence is exerted on the teeth by the incisal inclination than by the condylar guidance.

It must be reemphasized, that the condylar guidance recorded, and the incisal guidance created in anterior tooth arrangement, establish the movements of the articulator and although these movements are not strictly speaking replications of the actual movements of the patient they are acceptable simulations.

The orientation of the plane is selected by the dentist to be in harmony with the lateral borders of the patient's tongue and medial roll of the buccinator muscle. The placement of the plane must orient the occlusal surface of the posterior teeth in a relationship to these anatomical structures so that food can be held between the teeth for proper chewing. The soft tissue guides used by the clinician in locating the plane are the retromolar pads and the corner of the mouth bilaterally. The inclination of the cusps and prominence of the compensating curves are features that are already established in the occlusal forms of the engineered posterior artificial teeth. When a tooth is positioned in the oriented plane and in the appropriate location (i.e., the mandibular first molar) the cusp inclinations and the compensating curves already developed in the carving and manufacturing of the tooth may not be in harmony with the articulation requirements of the dental instrument. No amount of tipping, raising, or lowering of the tooth will establish the needed harmony in the instrument, nor in the oral environment as well. Occlusal reshaping is the only method to reestablish harmony between the occlusal surfaces of the teeth and the movements of the articulator.

Thus the orientation of the occlusal plane becomes the third fixed factor of occlusion. By positioning the anterior teeth correctly for esthetic appearance and locating the posterior end of the occlusal plane approximately 1-2 mms below the top of the retromolar pad, the dentist fixes the orientation of the occlusal plane. Any necessary alterations for balancing the occlusion must therefore be made by occlusal reshaping of the tooth mold selected for the occlusion.

The inclination of the cusps of the teeth, the fourth factor of occlusion, refers to the angle between the total occlusal surface of the tooth and the inclination of the cusp relating to that surface. For example, the designation 33° tooth indicates that the mesial slopes of the cusps make a 33° angle with a plane touching the tips of all the cusps of the tooth. In other words, if the long axis of the tooth is perfectly vertical, the plane of reference (horizontal) will be at right angles to the vertical axis of the tooth and the mesial inclines will likewise have a 33° angle to the horizontal. Although in theory this fulfills the definition of cusp angle, actual measurement of



the cusp angles reported by Lang and Thompson were quite different. In any case, the cuspal inclination designed into the tooth by the manufacturer is not necessarily the effective inclination when the tooth is arranged in occlusion on the articulator.

The fifth factor of occlusion, prominence of the compensating curve, is not a factor for manipulation if the guidance pathways developed into the tooth are to be tracked by the opposing cusps. Simply tipping the tooth does little to aid in developing harmony. On the other hand, if the tooth is nonanatomic or a cusplless tooth, tipping can create a compensating curve by creating cusp height. By raising the facial cusp above the lingual cusp the tooth can be thought of as a single cusp, and when arranged in a compensating curve with a single continuous surface.

Both Gysi and Hanau in theory were correct, however, from a clinical perspective the existing patient factors would preclude using a mold produced tooth for every patient without some modification to the occlusal primordial form. Sharry pointed this out in 1962, however, his writing went unnoticed by the majority of the profession.

## OTHER TOOTH FORMS AND ARTICULATION

The inability often times to achieve a balanced occlusion or articulation using the engineered teeth because of the factors previously discussed led to the development of many other artificial tooth forms. It is difficult to discuss complete denture occlusion or articulation without reference to these other tooth forms.

Basically, tooth forms are of four types: anatomic, nonanatomic, zero-degree, and cusplless teeth that are all defined in the Glossary.

**"Anatomic teeth:** (1) artificial teeth that duplicate the anatomic forms of natural teeth, (2) teeth that have prominent cusps on the masticating surfaces and that are designated to articulate with the teeth of the opposing natural or prosthetic dentition (3) anatomic teeth have cuspal inclinations greater than 0 degrees and tend to replica natural tooth anatomy -- usage cusp teeth (30 to 45 degrees) are considered anatomic teeth. Modified occlusal forms are those with a 20-degree cusp incline or less--called also anatomical teeth

Boucher CO. J Prosthet Dent 1953;3:633-56."

**"Nonanatomic teeth:** artificial teeth with occlusal surfaces that are not anatomically formed. The term nonanatomic as applied to artificial posterior teeth and especially their occlusal forms means that such teeth are designed in accordance with mechanical principles rather than from the anatomic standpoint. Nonanatomic teeth with flat occlusal surfaces set to a flat occlusal plane were first introduced by I. R. Hardy, DDS

Sears, VH. Thirty years of nonanatomic teeth. J Prosthet Dent 1953;3:596-617.

Hardy IR. Techniques for use of nonanatomic acrylic posterior teeth. Dent Digest 1942;48:562-6."

"**Zero-degree teeth:** posterior denture teeth having 0-degree cuspal angles in relation to the horizontal occlusal surface -- called also zero-degree nonanatomic teeth -- see NONANATOMIC TEETH"

"**Cuspless teeth:** teeth designed without cuspal prominence on the occlusal surface -- see NONANATOMIC TEETH, ZERO-DEGREE TEETH".

## OCCLUSAL CONCEPTS AND ARTICULATION

Although proof is lacking to support the validity of a balanced articulation during chewing, a balanced tooth relationship appears to be more important when no food is in the mouth. The horizontal movements of the mandible generated on an articulator do not simulate functional jaw movements. They simulate parafunctional jaw movements and artificial teeth are balanced to provide maximum denture base stability during these anticipated mandibular activities. Such a balanced articulation can usually be developed with several occlusal schemes (tooth molds). It must be understood, however, that during actual jaw movements in the oral environment, the combination of muscle forces and resiliency of the supporting mucosal tissues allow a bilateral balanced articulation to develop over a limited range of mandibular movement. It is tempting to presume that this area is within the range of bilateral tooth contacts as arranged using the various occlusal schemes.

### *Balanced Articulation.*

**Gysi A. Masticating efficiency in natural and artificial teeth, III. The bites in natural and porcelain teeth. Dent Digest 1915;21:139-45.**

The concept of balanced articulation has been described by several clinicians during the past decades. In each instance, specific tooth molds have been suggested to provide the needed tooth contacts for this concept. The classical example of bilateral balanced articulation dates back to 1914 when Gysi introduced the 33° cusp form arranged according to the movements of the articulator. These teeth arranged in a balanced occlusal concept were meant to enhance stability and direct the contact forces towards the ridges.

**French FA. The problem of building satisfactory dentures. J Prosthet Dent 1954;4:769-81.**

Increasing the stability of the dentures by reducing the occlusal table of the lower posterior teeth while maintaining a balanced concept was advocated by French in 1954. The upper posterior teeth with minimal lingual occlusal inclines of 5° for the first premolars, 10° for the second premolars, and 15° for the first and second molars were used by French. The cuspal inclines were arranged in a curved occlusal plane and permitted a balanced articulation laterally as well as anteroposteriorly.

**Sears VH. Thirty years of nonanatomic teeth. J Prosthet Dent 1953;3:596-617.**

A balanced articulation using nonanatomic teeth was suggested by Sears in the 1920's. A curved occlusal plane anteroposteriorly and laterally or the use of the second molar ramp provided the needed tooth contacts for the balanced occlusal concept to be developed.

**Pleasure MA. Anatomic versus nonanatomic teeth. J Prosthet Dent 1953;747-54.**

Pleasure introduced yet another approach designed to enhance the stability of the lower denture while providing a balanced articulation. According to Pleasure, a posterior reverse lateral curvature except for the second molars that were set with the customary lateral curvature provided a balanced articulation.

#### **COMMENTS:**

During mastication, the teeth make contact to a variable extent on both the chewing side and the nonchewing side. A combination of tissue resiliency and denture movement during function accounts for the high frequency of the nonchewing, or balancing side contacts. These denture movements occur regardless of the concept of occlusion selected for the occlusal reconstruction.

**Sheppard IM, Rakoff S, Sheppard SM. Bolus placement during mastication J Prosthet Dent 1968;20:506-10.**

Sheppard suggested the expression "enter bolus, enter balance." Therefore, the concept of a balanced occlusion or articulation and its significance during mastication has been questioned. On the other hand, deflective occlusal contacts during nonchewing periods have been implicated as factors in soft tissue irritation and as causes of an inflammatory response in attached mucosa beneath these contacts.

#### **COMMENTS;**

Longitudinal studies involving denture wearers have shown that after one-year and two-year periods of wearing complete dentures, defective occlusion contacts are quite common. When these observations are seen in conjunction with residual ridge resorption, changes in occlusion will occur regardless of the type of posterior tooth form used.

**Brewer, AA. Prosthodontic research in progress at the School of Aerospace Medicine. J Prosthet Dent, 1963;13:49-69.**

The report by Brewer on functional and nonfunctional tooth contacts in denture patients introduced some very interesting points to be considered in selecting the

central fossae of the lower teeth in maximum intercuspation. The facial cusps of the lower posterior teeth were reduced thereby eliminating any deflective contacts. In effect, the occlusion was lingualized by the elimination of contacts on the facial cusps and by the anteroposterior arrangements of the lower posterior teeth so that their occlusal surfaces are on or within a triangle from the mesial area of the lower cuspid to the sides of the retromolar pad.

**Hardy IR. Developments in the occlusal patterns of artificial teeth. J Prosthet Dent 1951;1:14-32.**

A straight horizontal occlusal plane using nonanatomic teeth was introduced by Hardy as another method to establish a nonbalanced occlusal concept. Porcelain, plastic, or metal shearing blades placed in a block of upper posterior teeth occluding against lower porcelain teeth were also considered as artificial replacements in the nonbalanced concept.

**Sears VH. Occlusal pivots. J Prosthet Dent 1956;6:332-8.**

The occlusal pivot introduced by Sears was another tooth form used with the nonbalanced concept. The pivots were proposed to place the mandible in equilibrium by maintaining the load in the molar regions, and thereby protecting the temporomandibular joints against injury. Stress was also reduced in the anterior regions of the ridges in anticipation of tissue maintenance using this scheme.

**Kurth LE. Balanced occlusion. J Prosthet Dent 1954;4:150-67.**

A nonbalanced articulation in eccentric positions using a horizontal occlusal plane without a posterior ramp was advocated by Kurth. The posterior teeth were arranged in a block with a flat anteroposterior occlusal plane and reverse lateral curve. Many of these tooth forms are in use today to develop a monoplane or nonbalanced concept, however, long-term scientific investigations to support any claims of tissue maintenance, denture stability, or increased masticatory efficiencies are lacking in the literature.

**Jones, PM. The monoplane occlusion for complete dentures. J Prosthet Dent, 1972;85:94-100.**

The monoplane occlusal concept as defined by Philip M. Jones in 1972 is often erroneously represented when discussed by clinicians. In this concept, a nonanatomic occlusal scheme was used with a few specific modifications. The first departure was the articulator used. The articulator should accommodate large casts, it should not show lost motion, and it should possess an incisal guide pin. As Jones stated, a barn door hinge fits these requirements. Another departure was that the maxillary and mandibular teeth are arranged without any vertical overlap. The amount of horizontal overlap was determined by the jaw relationships. The maxillary posterior teeth are set first, and the occlusal plane must fulfill certain requirements. First, it should result in an occlusal plane that evenly divided the

space between the upper and lower ridges. Second, it should provide an occlusal plane that paralleled the mean denture base foundation. Finally, the plane should fall at the junction of the upper and middle thirds of the retromolar pads. In the final arrangement of the teeth the maxillary and mandibular teeth contacted from anterior to posterior in maximum intercuspation with the exception of the second molars. The occlusal surface of the upper second molar was set parallel to the occlusal surface of the lower second molar; but 2.0 mm above the occlusal plane, thus well out of occlusion. This condition was established because the first and second premolars and the first molars masticate the food. The second molars are space fillers and do not function. This occlusal scheme has received a great deal of attention over the past years, however in most instances when monoplane occlusion has been discussed, these previously described modifications are not strictly followed.

### *Lingualized Articulation*

Choosing the tooth mold or occlusal scheme to achieve a particular occlusal concept may be even more difficult considering the difficulties in developing a balanced articulation without extensive occlusal reshaping, which is hardly the least complicated approach. Clinicians have recognized such difficulties and have opted to use lingualized articulation as their concept of choice. This concept by definition is a balanced arrangement and has been reported as being less complicated than other concepts.

#### **Gysi A. Special teeth for cross-bite cases. *Dent Digest* 1927;33:167-171.**

In 1927, Dr. Alfred Gysi of Switzerland introduced the concept of a lingualized occlusion, and his introductory report has been followed in the literature by a number of articles presenting various modifications to the original concept. Pound also lingualized the occlusion in a nonbalanced articulation, and he suggested incorporating a sharp maxillary lingual cusp in the posterior teeth opposing a widened central fossae on the occlusal surface of the mandibular antagonists in maximum intercuspation.

#### **Payne SH. A posterior set-up to meet individual requirements. *Dent Digest* 1941;47:20-22.**

In 1941, Payne reported on the posterior set-up of Dr. Edison J. Farmer that used 30° cusp teeth modified by selective occlusal reshaping and articulated against mandibular teeth with reduced facial and lingual cusps and a widened central fossa. Payne suggested that this arrangement offered the advantages of adaptation to different types of ridges, a solid maximum intercuspation, an absence of deflective occlusal contacts in lateral excursions, occlusal forms that permitted selective occlusal reshaping to achieve a balanced articulation, and an esthetic arrangement of the teeth. Recently, a new tooth mold designed specifically to satisfy the concept of lingualized articulation (i.e., Myerson Lingualized Integration (MLI), Austenal Inc., Chicago, IL) has been introduced to the profession.

**Lang BR and Razzoog, ME. Lingualized integration: Tooth molds and an occlusal scheme for edentulous implant patients. *Implant Dent* 1992;1:204-211.**

This article presents a clear concept of the occlusal rehabilitation required and appropriate for the totally edentulous implant patient called lingualized integration. Lingualized integration represents an occlusal scheme using specific tooth molds designed to improve the likelihood of maximum intercuspation and an absence of deflective occlusal contacts, provide cusp height for selective occlusal reshaping, and to achieve a natural and pleasing appearance. Factor in the articulation and arrangements of the posterior teeth to assure the attainment of the fundamental goals of lingualized integration are presented.

**Sosin MB. Reevaluation of posterior tooth forms for complete dentures. *J Prosthet Dent* 1961;11:55-61.**

**Levin B. A review of artificial posterior tooth forms including a preliminary report on a new posterior tooth. *J Prosthet Dent* 1977;38:3-15.**

**Ortman HR. Complete denture occlusion, in Winkler, Sheldon (ed): *Essentials of Complete Denture Prosthodontics*. 2nd edition. PSG Publishing Co., Inc., 1988, p.217-249.**

Other reports have appeared in the literature describing modifications to the lingual cusp form of maxillary posterior teeth and their use within the context of lingualized occlusion. Among the reports are the works of Sosin and Levin, who formed the lingual cusps of the maxillary premolars and first and second molars in an alloy for increased chewing efficiency. Ortman has suggested for reasons of clarity and a better understanding concerning the lingualized occlusal concept that "Lingual Cusp Contact Occlusion" might be a better way to describe the contact of the maxillary lingual cusp with the mandibular teeth.

#### **COMMENTS:**

Occlusal forms and tooth arrangements have been summarized Beck in his classic article published in 1972. Occlusion and articulation as previously discussed has also been summarized recently in the January 1996 issue of *The Dental Clinics of North America*.

**Beck HO. Occlusion as related to complete removable prosthodontics. *J Prosthet Dent* 1972;27:246-56.**

Ten occlusal concepts with different occlusal arrangements for complete denture are review. Five of the designs reviewed are in the balanced concept, and five are in the nonbalanced concept. Occlusal designs and their resulting functions are of concern to the dentist so that loss of the remaining tissues of the mouth are minimized. Unfortunately, little documentation is available to prove one tooth or concept is superior another.

**Lang BR. Complete Denture Occlusion. P. 85-101 (In Engelmeier RL. ed. *The Dental Clinics of North America*. Philadelphia, WB Saunders Company, 1996.)**

Although research has not identified a superior tooth form or arrangement to fulfill the requirements of complete denture patients in the areas of comfort, function and esthetics. Therefore it appears logical to use the least complicated approach to fulfill these requirements. This approach begins with the development of a philosophy of occlusion and selection of a concept to satisfy the philosophy. A balanced articulation appears to be most appropriate because of tooth contacts observed during nonfunctional activities of patients. Occlusal schemes to fulfill these occlusal concepts are many and varied. In the opinion of the author, the lingualized articulation concept using tooth molds specifically designed for this concept seems to be the most logical and least complicated approach in occlusal rehabilitation of edentulous patients.

## **OCCLUSION FOR THE EDENTULOUS PATIENT - CURRENT KNOWLEDGE**

Occlusion research during the past twenty years has been rather sparse and centered around three areas: a) theoretical or specific clinical models, b) chewing efficiency and chewing ability, and c) biting forces and/or chewing forces. Research aimed specifically at tooth forms and occlusal schemes have not been a high priority during this period, probably because of the difficulty to isolate the variables involved, and the reliability of the scientific methods available. However, recent studies involving patients with dentures in combination with osseointegrated implants are demonstrating methodologies that may help to determine if there is a tooth form or occlusal scheme that is better for the overall health and welfare of the patient.

### ***Theoretical or Specific Clinical Models***

**Colaizzi FA, Michael CG, Javid NS, and Gibbs CH. Condylar and incisal border movements: A comparative study of complete denture wearers and natural dentition subjects. J Prosthet Dent 1988;59:453-**

Colaizzi et al. in a specific clinical model studied border movements at the incisor point in denture wearers with two interchangeable occlusal schemes of posterior teeth to determine if differences occurred as a function of tooth form, and to compare the movement patterns to those of patients with natural dentitions. The authors concluded that the denture patient populations produced a rounded, poorly defined intercuspal-like position in contrast to a well-defined sharp intercuspal position in the natural dentition subjects. This poorly defined position in the denture wearers occurred with both the nonanatomic or anatomic posterior tooth forms in place. However, the lack of a sharply defined intercuspal-like position would seem to support the hypothesis that research on tooth forms and border movements was influenced more by the denture base instability than the

tooth forms themselves. This study would seem to further support the premise that the absence of differences may well be the result of the lack of a reliable method not necessarily the absence of a difference in response to tooth form.

**Maeda Y and Wood WW. Finite element method simulation of bone resorption beneath a complete denture. J Dent Res 1989;68:1370-1373.**

The finite element experimental model was used by Maeda and Wood to study bone resorption beneath a maxillary complete denture as influenced by occlusal forces. In their study, the authors assumed that a threshold of compressive strain existed in the alveolar bone above which resorption occurred. The pattern of predicted resorption was observed when 100 newtons of force was applied to three positions occlusally, and 20 newtons was applied facially. The pattern of simulated bone resorption was similar to that reported from clinical observations, which suggested that the restoration may be associated with compressive strains developed in the alveolar bone. The resorptive pattern developed by this mathematical model argues for the importance of occlusal adjustment of dentures to move the occlusal load point palatally and the possible significance of tooth contacts and/or tooth forms used in producing a balanced occlusion in protrusive and lateral excursions.

### *Chewing Efficiency and Chewing Ability*

**Clough HE, Knodle JM, Leeper SH, Pudwell ML, and Taylor DT. A comparison of lingualized occlusion and monoplane occlusion in complete dentures. J Prosthet Dent 1983;50:176-179.**

Clough et al., examined chewing efficiency and chewing ability using 30 patients treated with duplicate sets of dentures. One set had monoplane occlusion using 0-degree teeth in both arches, while the other was arranged to the lingualized concept using maxillary 30-degree teeth opposing the mandibular 0-degree tooth. The patients wore one set for three weeks and then the other set for a second three week test period. The chewing ability of each patient was recorded along with their preference for a given set of dentures. There was a preference for the lingualized occlusion by sixty-seven percent of the patients interviewed and this preference was statistically significant according to a chi-square analysis. The reason given by patients who preferred the lingualized occlusion seemed to support the contention that lingualized occlusion improves their masticatory abilities as compared to a cusplless scheme, while also providing a noninterfering freedom and bilaterally balanced articulation. It must be remembered, however, that the data collected in this study were responses to a questionnaire and thus nonparametric in nature.

### *Biting Force and/or Chewing Forces*

A number of studies have been conducted over the past several years on biting force and/or chewing forces.



**Michael CG, Javid NS, Colaizzi FA and Gibbs CH. Biting strength and chewing forces in complete denture wearers. J Prosthet Dent 1990;63:549-553.**

Michael, Javid, Colaizzi, and Gibbs compared the biting force of the denture wearer to patients with natural teeth. The maximum biting force of the denture wearer averages 35 lbs or 16 kg. The bite strength of natural dentition subjects was 162 lbs or 74 kg, or 4.5 times greater than that of the denture wearers. It should be noted that the range of bite strength varied for both the natural dentitions (55 to 280 lbs) and the denture wearers (22 to 47 lbs). Similar ranges and bite forces have been found in other studies by Kelsey et al.

Additional Readings:

Kelsey CC, Reid FD, and Coplowitz JA. A method of measuring pressures against tissues supporting functioning complete dentures. J Prosthet Dent 1976;354:376-383.

**Lassila V, Holmlund I and Koivumaa KK. Bite force and its correlations in different denture types. Acta Odontol Scand 1985;43:127-132.**

Bite forces were studied in selected groupings of patients with different prosthetic rehabilitation conditions by Lassila et al. Three groups were examined: a) patient with maxillary and mandibular complete dentures, b) patients with maxillary complete dentures opposing a mandibular removable partial denture, and c) patients with natural teeth or removable partial dentures in the maxillary arch opposing a mandibular removable partial denture. Patients were asked to bite on a special bite fork that recorded maximum force in newtons. Seven regions were measured around the dental arch. The authors concluded that instability and interferences in the occlusion created a significant decrease in bite force in groups (a) the totally edentulous group, and group (b) the combination syndrome patient ( $p < .001$ ). The bite force was clearly greater with the natural teeth versus the RPD in group (c). In both the edentulous group (a) and the RPD/denture group (b) the greater bite force was in the molar and premolar regions. The contralateral stabilization of occlusion during the recording had a considerable effect on the bite force. Values that were reached were clearly greater than without stabilization and the measurement was more reliable. The importance of a stable occlusion increased as the number of natural teeth decreased. The positive effect of a stable occlusion on the bite force was clearly evident in this study. This study is extremely important in that it supports the hypothesis that a lack of stability can influence the magnitude, the validity and reliability of the measurements being made. In light of these findings, few if any previous studies trying to measure the effect of either tooth forms or balanced versus a nonbalanced relationship using the edentulous population, had any chance of providing data to prove statistically significant differences. This does not mean that differences do exist, however, it clearly supports the hypothesis that the previous studies had little if any chance to prove the same.

**Lundquist LW, Carlsson GE, and Hedegard B. Changes in bite force and chewing efficiency after denture treatment in edentulous patients with denture adaptation difficulties. J Oral Rehabil;1986;13:21-29.**

Lundquist, Carlsson, and Hedegard studied masticatory function by means of a chewing efficiency test and bite force measurements in a group of patients who were seeking rehabilitation with osseointegrated implants. The patient population consisted of individuals with dentures who had experienced great difficulty adapting to dentures. The patients chewing efficiency and bite forces were measured before and after new dentures were constructed. They found no significant correlations between the quality of the dentures and the measurements of bite force and chewing efficiency.

**Eerikainen, E and Kononen, M. Forces required by complete dentures for penetrating food in simulated function. J Oral Rahabil 1987;14:607-613.**

Forces required by complete dentures for penetrating some commonly used food items were measured experimentally by Eerikainen and Kononen under simulated conditions. These forces were compared with the maximal bite forces of twenty-seven complete denture wearers as measured clinically. Simulated laterotrusion aided most in the penetration of bread and boiled meat. The penetration forces in simulated conditions were high compared with the maximal bite forces of the complete denture wearers clinically. It is reasonable to assume that perhaps the major cause for the rejection of particular food items from the diet by patients may be due to high bite force needed to chew these foods. Food pulverization experiments have shown that complete denture wearers ability to penetrate food is much lower (one-third to one-sixth) that of persons with natural dentitions.

**Lindquist, LW. Prosthetic rehabilitation of the edentulous mandible. Swed Dent; J Suppl 1987;48:1-39**

In a study by Lindquist, 64 edentulous patients were evaluated prior to and following new denture construction for bite force, chewing efficiency and chewing ability. The patients were then treated with osseointegrated implants in the mandible and retested for the previously listed variables. In summary the function tests showed small changes after denture treatment. Improvement was greater, however, in those subjects with the poorest pretreatment values. Following treatment with implants, the means in neutons of bite force measurements increased in 24 edentulous subjects at three force levels on four occasions I = old dentures, II = after denture treatment, III = 2 months following treatment, and IV = 3 years after implant placement in the mandible. The patient's own evaluation of their ability to chew different foods changed only slightly after denture treatment, whereas a dramatic improvement was reported after insertion of the implants. This improvement was maintained during the observation period. One of the few negative consequences of the improved masticatory function in the rehabilitated patients was a high rate of midline fractures of the maxillary denture. The maximal

bite force has been shown to become two or three times as high after insertion of a fixed TIP in the mandible of complete denture wearers.

**Jemt, T and Carlsson, GE. Aspects of mastication with bridges on osseointegrated implants. Scand J Dent Res 1986;94:66-71.**

Jemt and Carlsson conducted a similar study on 16 edentulous patients wearing complete dentures who were subsequently treated with implant placement in the mandible. These investigators measured bite force, chewing efficiency, and chewing ability. Their findings verified that the rehabilitation of complete denture wearers with fixed bridges on OI fixtures in the mandible on average gave a substantial improvement to masticatory function.

**Haraldson T, Jemt T, Stålblad P-Å, and Lekholm U. Oral function in subjects with overdentures supported by osseointegrated implants. Scand J Dent Res 1988;96:235-42.**

In a study by Haraldson et al., nine subjects were treated with OI implants in the mandible, followed by an overdenture. These subjects were also evaluated for bite force, chewing efficiency and ability. Chewing function seemed to improve, however, it was less obvious than their findings in earlier studies where the mandibular restorations were fixed by the osseointegrated implants.

**Haraldson, T and Zarb, G. A 10-year follow-up study of the masticatory system after treatment with osseointegrated implant bridges. Scand J Dent Res 1988;96:243-52.**

Haraldson and Zarb evaluated 21 patients ten years following treatment with implants and dentures. These investigators measured the anamnestic and clinical examination and registration of bite force. The bite force ranged from 118 N (gentle biting) to 250 N (as chewing) to maximum bite at 495.5 N. On average, the bite force improved significantly at all bite force levels compared to 10 years earlier. It was concluded that oral functions in patients with OI implants are very favorably improved.

**Lundgren D, Laurell L, Falk H and Bergendal T. Occlusal force pattern during mastication in dentitions with mandibular fixed partial dentures supported on osseointegrated implants. J Prosthet Dent 1987;58:197-203.**

In yet another study, Lundgren et al. evaluated eight patients with maxillary complete dentures and fixed restorations in the mandibular arch supported by 5-6 OI fixtures. Cantilever segments 16 mm in length extended beyond the last fixture on each side. Chewing, swallowing, and closing forces were measured. In the maxillary dentures, four strain gauges were placed in anterior and posterior regions. The patients chewed peanuts, roast beef, and potato salad. The occlusal force pattern during chewing and biting was comparable to patients with complete dentitions. Comparisons were made with data for tooth-supported cross-arch unilateral

posterior two unit cantilever fixed partial dentures occluding with natural teeth. The posterior cantilever segments in the OI cantilever prosthesis occluding with complete dentures regularly exhibited the largest local forces.

#### **COMMENTS:**

The comparisons as described in these last few studies are both interesting and informative. However, their greatest significance may be in the fact that they clearly demonstrate that in the presence of implants and increased denture base stability, bite force transmission during chewing, swallowing and particularly clenching, gnashing and bruxing appear to be significantly greater than with conventional dentures. In these circumstances, we must ask if these forces may also be influenced by the occlusal form used in either the maxillary denture or the OI mandibular prosthesis. Of equal importance may be the influence of a cross-arch balanced or nonbalanced articulation. The article by Brewer in 1963 and his studies on functional and nonfunctional tooth contacts in denture patients adds additional impetus to the importance of studying these variables especially with regards to the implant patient. Although this study was limited to only two patients, the 2 to 4 hours for nonfunctional activity reported is extremely important. The tooth form used in prosthodontic reconstruction, or the occlusal concept employed under these contact conditions may influence the health of various oral structures. The fact that differences between tooth forms and occlusal concepts have not demonstrated devastating effects in the edentulous population is probably due to the movement of conventional denture bases. The increasing numbers of patients receiving implant therapy make it imperative that sound scientific data be obtained to either support or refute the significance of tooth forms or occlusal schemes on the supporting tissues.

#### **SUMMARY:**

It is safe to say that little ground has been gained during the past twenty years in determining the influence, if any, of the tooth form or the occlusal scheme used on the overall welfare or oral health of the patient. However, this population of patients rehabilitated with OI prosthesis may well prove to be the experimental populations that will provide the answers to these long unanswered questions about tooth forms and a balanced versus a nonbalanced articulation.

## REFERENCES

- Beck, HO. Occlusion as related to complete removable prosthodontics. *J Prosthet Dent* 1972;27:246-256.
- Bonwill WGA. Geometrical and mechanical laws of articulation. *Anatomical articulation. Odont Soc Pa Tr* 1885;nv:119-33.
- Bonwill WGA. Scientific articulation of the human teeth as founded on geometrical, mathematical and mechanical laws. *Dent Items Interest* 1899;21:617-36, 873-80.
- Brewer, AA. Prosthodontic research in progress at the School of Aerospace Medicine. *J Prosthet Dent*, 1963;13:49-69.
- Clough et al. A comparison of lingualized occlusion and monoplane occlusion in complete dentures. *J Prosthetic Dent* 1983;50:176-9.
- Colaizzi FA, Michael CG, Javid NS, and Gibbs CH. Condylar and incisal border movements: A comparative study of complete denture wearers and natural dentition subjects. *J Prosthet Dent* 1988;59:453-
- Eerikåinen, E and Kononen, M. Forces required by complete dentures for penetrating food in simulated function. *J Oral Rehabil* 1987;14:607-613.
- French, FA. The problem of building satisfactory dentures. *J Prosthet Dent* 1954;4:769-81.
- Frush, JP. Linear occlusion. *Ill Dent J* 1966;35:788-94.
- Glossary of prosthodontic terms, 6th edition. *J Prosthet Dent* 1994;71:41-112.
- Gysi, Alfred and Wayne, OT (translator). The problem of articulation *Dent Cosmo* 1910;52:403-18
- Gysi Alfred. Masticating efficiency in natural and artificial teeth, III. The bites in natural and porcelain teeth. *Dent Digest* 1915;21:139-45.
- Gysi, Alfred. Practical application of research results in denture construction. *Am Dent A J* 1929;16:199-223.
- Gysi, Alfred. Evolution of the prosthetic incisor overbite and the prosthetic cusp angulation of the posteriors to what is called "functional norm". *Dentists' Supply Company of New York. York, PA, 1935, p.38, duplicated.*
- Hanau, RL. Articulation defined, analyzed and formulated. *Am Dent A J* 1926;8:1694-1709.

- Haraldson T, Jemt T, Stålblad P-Å, and Lekholm U. Oral function in subjects with overdentures supported by osseointegrated implants. *Scand J Dent Res* 1988;96:235-42.
- Haraldson, T and Zarb, G. A 10-year follow-up study of the masticatory system after treatment with osseointegrated implant bridges. *Scand J Dent Res* 1988;96:243-52.
- Hardy IR. Techniques for use of nonanatomic acrylic posterior teeth. *Dent Digest* 1942;48:562-6.
- Hardy, IR. Developments in the occlusal patterns of artificial teeth. *J Prosthet Dent* 1951;1:14-32.
- International Prosthodontic Workshop on Complete Denture Occlusion.* Lang BR, Kelsey CC (eds), The University of Michigan, School of Dentistry, 1973, xxvi+338 p.
- Jemt, T and Carlsson, GE. Aspects of mastication with bridges on osseointegrated implants. *Scand J Dent Res* 1986;94:66-71.
- Jones, PM. The monoplane occlusion for complete dentures. *J Prosthet Dent*, 1972;85:94-100.
- Kelsey CC, Reid FD, and Coplowitz JA. A method of measuring pressures against tissues supporting functioning complete dentures. *J Prosthet Dent* 1976;354:376-383.
- Kurth, LE. Balanced occlusion. *J Prosthet Dent* 1954;4:150-67.
- Lang, B.R. and Thompson, R.M. The Cusp Angles of Artificial Mandibular First Molars. *J Prosthet Dent* 1972;28:26-35.
- Lassila V, Holmlund I and Koivumaa KK. Bite force and its correlations in different denture types. *Acta Odontol Scand* 1985;43:127-132.
- Levin, B. Monoplane teeth. *J Am Dent Assoc* 1972;85:781.
- Lindquist, LW. Prosthetic rehabilitation of the edentulous mandible. *Swed Dent; J Suppl* 1987;48:1-39
- Lundgren D, Laurell L, Falk H and Bergendal T. Occlusal force pattern during mastication in dentitions with mandibular fixed partial dentures supported on osseointegrated implants. *J Prosthet Dent* 1987;58:197-203.
- Lundquist LW, Carlsson GE, and Hedegard B. Changes in bite force and chewing efficiency after denture treatment in edentulous patients with denture adaptation difficulties. *J Oral Rehabil*;1986;13:21-29.
- Maeda Y and Wood WW. Finite element method simulation of bone resorption beneath a complete denture. *J Dent Res* 1989;68:1370-1373.

- Michael CG, Javid NS, Colaizzi FA and Gibbs CH. Biting strength and chewing forces in complete denture wearers. *J Prosthet Dent* 1990;63:549-553.
- New Trubyte posteriors functional 20 degree shallow bites. Dentists' Supply Company of New York. York, PA, 1935, p.12, duplicated.
- Ortman, HR. Complete denture occlusion, in Winkler, Sheldon (ed): *Essentials of Complete Denture Prosthodontics*. 2nd edition. PSG Publishing Co., Inc., 1988, p.217-249
- Pleasure, MA. Anatomic versus nonanatomic teeth. *J Prosthet Dent* 1953;747-54.
- Payne SH. A posterior set-up to meet individual requirements. *Dent Digest* 1941;47:20-22.
- Pound, E. Utilizing speech to simplify a personalized denture service. *J Prosthet Dent* 1971;24:586-600.
- Sears, VH. Thirty years of nonanatomic teeth. *J Prosthet Dent* 1953;3:596-617.
- Hardy IR. Techniques for use of nonanatomic acrylic posterior teeth. *Dent Digest* 1942;48:562-6.
- Sears, VH. Occlusal pivots. *J Prosthet Dent* 1956;6:332-8.
- Sharry, JJ. Arrangement and occlusion of teeth, in Sharry, JJ (ed): *Complete Denture Prosthodontics*. McGraw-Hill, Book Co., Inc., 1962, p. 235-259.
- Suggestions for the arrangement and articulation of Pilkington-Turner 30 degree posteriors by Trubyte. Dentists' Supply Company of New York. York, PA, 1966, p.27.
- The new Pilkington-Turner vacuum fired 30 degree posteriors. Dentists' Supply Company of New York. York, PA, 1953, p.48.
- Woelfel et al. Effect of posterior tooth form on jaw and denture movement. *J Prosthet Dent* 1962;12:922-39.

## **Section Seven - Oral Pathology, Drug Therapies, Basic Dental Materials, And Bonding and Luting Agents**

Section Seven contains information related to oral pathology, drug therapies in prosthodontics, basic dental materials, and bonding and luting agents. The authors and the titles of their presentations follow:

**Dr. Richard M. Courtney**

*“Oral Pathology And Prosthodontics”*

**Dr. Patrick M. Lloyd**

*“Drug Therapies In Prosthodontics”*

**Dr. John C. Wataha**

*“Review of Basic Materials In Prosthodontics”*

**Dr. Stephen Bayne**

*“Bonding And Luting Agents”*



# **Oral Pathology And Prosthodontics**

**Dr. Richard M. Courtney**



## REFERENCE BOOKS COVERING ORAL PATHOLOGY

**Regezi, J. A., Sciubba, James: Oral Pathology: Clinical-Pathologic Correlations. 2nd. Edition. W. B. Saunders Co., Philadelphia, 1993.**

This is a handy reference book for your office library. It has an overview which enables you to develop a differential diagnosis based on lesion appearance for the most common occurring oral lesions. The overview is keyed to the main text which offers a more detailed presentation of the subject. Individual diseases are discussed from the standpoint of etiology, pathogenesis, clinical features, histopathology, differential diagnosis, treatment and prognosis. Illustrations are numerous and of high quality.

**Neville, B. W., Damm, D. D., Allen, C. M. and Bouquot, J. E.: Oral and Maxillofacial Pathology. W. B. Saunders Co., Philadelphia, 1995.**

This is the most recent addition to the oral pathology textbook area. This well written book is organized in a more traditional manner. Diseases are discussed from the standpoint of etiology or location rather than clinical appearance. Differential diagnosis lists, which group lesions by their clinical characteristics, appear in the appendix with page references in the main text. Each disease is discussed as above. Several excellent color plates add to the usefulness of the illustrations.

**Shafer, W. G., Hine, M. K. and Levy, B. M.: A Textbook of Oral Pathology. 4th Edition. W. B. Saunders Co., Philadelphia, 1983.**

For many years this was the most used textbook for oral pathology courses in American dental education. Even though dated and no longer available in bookstores, this classic continues to adequately cover the topic. It is arranged by etiology or location with excellent clinical and microscopic illustrations.

**Laskaris, George: Color Atlas of Oral Diseases. Thieme Medical Publishers, New York, 1988.**

This is an English translation of the original Greek publication. This book is notable because of the outstanding quality and broad range of the color illustrations. A brief discussion accompanies each condition with comments on etiology, pathogenesis, differential diagnosis, laboratory tests and treatment.

**Neville, B. W., Damm, D. D., White, D. K. and Waldron, C. A.: Color Atlas of Clinical Oral Pathology. Lea & Febiger, Philadelphia, 1991.**

This atlas provides a high quality, broad array of mucosal and radiographic color illustrations. Textual information is concise and dovetails with the above textbook by some of the same authors.

## Oral Pathology and Prosthodontics

**Bouquot, J. E.: Common oral lesions found during a mass screening examination. JADA 112:50-57, 1986.**

This study is one of the few which attempts to address prevalence of oral lesions in an adult population. More than 23,000 white Americans (8,477 males and 15,139 females) with a median age of 55.9 years were examined. Approximately 10% had at least one oral lesion unusual enough to be recorded by a dentist. The most common clinical appearance of oral lesions was that of a single, exophytic mass, which accounted for 37.4% of all reported lesions. Leukoplakia was the most common mucosal lesion. Palatal or mandibular tori were next, followed by inflammation or irritation, fibromas, Fordyce's granules, vascular lesions, ulcers, papillomas and epulis fissuratum. If microscopically proven carcinoma was included, it would rank 14th for males and 24th for both genders.

### **I. Reactive Lesions**

#### **A. Associated with prosthetic devices**

Traumatic ulcers  
Fibrous hyperplasia (epulis fissuratum)  
Papillary hyperplasia (palatal papillomatosis)  
"Denture-Sore Mouth" (candidiasis)

#### **B. Associated with medications**

Gingival hyperplasia (Dilantin, Nefedipine and Cyclosporine)  
Mucosal ulcerations (NSAID's and gold salts)  
Mucosal pigmentation (lichenoid drug reactions, antimalarials  
and Minocycline)

#### **C. Questionable etiology**

Pyogenic granuloma (pregnancy tumor)  
Peripheral fibroma (with or without ossification)  
Peripheral giant cell granuloma

### **II. Neoplastic Disease**

#### **A. Precancerous lesions**

Leukoplakia  
Erythroplakia  
Proliferative verrucous leukoplakia

**B. Malignant disease**

Basal cell carcinoma

Squamous cell carcinoma

Verrucous carcinoma

**III. Salivary Gland Disorders**

**A. Autoimmune disease**

Sjögren's syndrome

**B. Reactive conditions**

Sialadenitis (mucoceles and retention cysts)

Sialolithiasis

Necrotizing sialometaplasia

**C. Salivary gland neoplasms**



# **Drug Therapies In Prosthodontics**

**Dr. Patrick M. Lloyd**





Patrick M. Lloyd, DDS, MS  
Chair, Department of Family Dentistry  
University of Iowa  
College of Dentistry  
S313 DSB  
Iowa City, IA 52242  
Telephone: 319-335-7322  
e-mail: patrick-lloyd@uiowa.edu

## DRUG THERAPIES IN PROSTHODONTICS

### 1. Local Anesthetics

#### a. Surface Applied Agents

Surface applied local anesthetics	Concentration	Category
benzocaine (Hurracaine)	18-20%	ester
butacaine (Butyn)	4%	ester
cocaine	--	ester
dyclonine* (Dyclone)	0.5%	ketone
lidocaine (Octocaine)	5%	amide

\*cross-sensitization does not occur

#### Forms of administration

-liquid/gel

-aerosol spray

- unable to deliver measured amount
- sterilization of container required
- difficult to confine application
- aerosol inspiration a possibility

#### Clinical characteristics of surface applied local anesthetics

penetrate mucosal membranes

effective depth 2-3mm

rapid absorption into tissues

prolonged duration of action

toxic overdose reactions virtually unknown

localized allergic reactions following prolonged or repeated use

## b. Parenterally Administered

### Amides

lidocaine (Xylocaine)  
mepivacaine (Carbocaine)  
prilocaine (Citanest)  
bupivacaine (Marcaine)  
etidocaine (Duranest)  
articaine (Ultracaine)

### Esters

procaine (Novocain)  
chloroprocaine (Nesacaine)  
tetracaine (Pontocaine)  
cocaine  
benzocaine (Hurrricane)  
propoxycaine (Ravocaine)

(cross over sensitivity not significant)

## Local Anesthetic Dosage Guidelines

Agent	MRD	mg/lb	(150lb)
lidocaine	2mg/lb	36	8 carpules
mepivacaine	2mg/lb	54	5 carpules
prilocaine	2.7mg/lb	72	5 carpules

## New York Heart Association 1955

Healthy Adults - maximal dose of epinephrine 0.2mg  
(20mL of local anesthetic with 1:100,000 epinephrine)  
(10 carpules)

Medically compromised adults - maximal dose of epinephrine 0.04mg  
(4 mL of local anesthetic with 1:100,000 epinephrine)  
(2 carpules)

## Vasoconstrictors

## Primary Receptors

epinephrine (Adrenalin chloride)	alpha, beta
levo-nordefrin (Neo-Cobefrin)	alpha
nor-epinephrine (Levophed)	alpha, beta
phenylephrine (Neo-Synephrine)	alpha

## Vasoconstrictors contraindications

blood pressure > 200/115  
uncontrolled hyperthyroidism  
unstable angina  
refractory arrhythmias  
stroke/myocardial infarction (6 months)

coronary artery bypass surgery (3 months)  
uncontrolled diabetes  
uncontrolled congestive heart failure  
sensitivity  
pheochromocytoma

## Drug interactions with Vasoconstrictors

### 1. tricyclic antidepressants

amitriptyline (Elavil)  
imipramine (Tofranil)

- potentiate cardiovascular effects of epinephrine
- maximum limit 0.04mg epinephrine
- avoid nor-epinephrine and levo-nordefrin

### 2. monoamine oxidase inhibitors

isocarboxazid (Marplan)

- phenylephrine is potentiated several fold
- no significant interaction with epinephrine, norepinephrine, or levonordefrin

### 3. nonselective beta (*B*)-adrenergic blockers

propranolol (Inderal)

adrenergic neuron depletors

guanethidine (Ismelin)  
reserpine (Serpasil)

- dosage reduction advised (hypertensive crisis)

### 4. phenothiazines

thioridazine (Mellaril)

- guarded use of vasoconstrictors

### 5. non-potassium sparing diuretics

## General Precautions to Prevent Local Anesthesia Complications

- \*document past medical history accurately
- \*consider age, height, weight, and general condition of patient
- \*apply the minimum required dose
- \*be informed about the maximum allowable dosage of the local anesthetic and vasoconstrictor
- \*perform multiple aspirations on at least two planes
- \*keep constant contact with the patient
- \*do not leave the patient unattended after inducing anesthesia
- \*intra-ligamentary injection avoid using epinephrine

## 2. Antibiotic Prophylaxis

### a. Recommendations to Prevent Bacterial Endocarditis

Drug	Dosing Regimen *
<b>Standard General Prophylaxis</b>	
Amoxicillin	Adults: 2.0 g; children: 50 mg/kg orally 1 h before procedure
<b>Unable To Take Oral Medications</b>	
Ampicillin	Adults: 2.0 g intramuscularly (IM) or intravenously (IV); children: 50 mg/kg IM or IV within 30 min. before procedure
<b>Amoxicillin/Penicillin-Allergic Patients</b>	
Clindamycin	Adults: 600 mg; children: 20 mg/kg orally 1 h before procedure
	or
Cephalexin** or cefadroxil**	Adults: 2.0 g; children: 50 mg/kg orally 1 h before procedure
	or
Azithromycin or clarithromycin	Adults: 500 mg; children: 15 mg/kg orally 1 h before procedure
<b>Allergic To Penicillin And Unable To Take Oral Medications</b>	
Clindamycin	Adults: 600 mg; children: 20 mg/kg IV within 30 min before procedure
	or
Cefazolin**	Adults: 1.0 g; children: 25 mg/kg IM or IV within 30 min before procedure

\* Total children's dose should not exceed adult dose.

\*\* Cephalosporins should not be used in individuals with immediate-type hypersensitivity reaction (urticaria, angioedema, or anaphylaxis) to penicillins.

## Endocarditis Prophylaxis Recommended\*

Dental extractions

Periodontal procedures including surgery, scaling and root planing, probing, and recall maintenance

Dental implant placement and reimplantation of avulsed teeth

Endodontic (root canal) instrumentation or surgery only beyond the apex

Subgingival placement of antibiotic fibers or strips

Initial placement of orthodontic bands but not brackets

Intraligamentary local anesthetic injections

Prophylactic cleaning of teeth or implants where bleeding is anticipated

## Endocarditis Prophylaxis Not Recommended

Restorative dentistry\* (operative and prosthodontic) with or without retraction cord\*\*

Local anesthetic injections (nonintraaligamentary)

Intracanal endodontic treatment; post placement and buildup

Placement of rubber dams

Postoperative suture removal

Placement of removable prosthodontic or orthodontic appliances

Taking of oral impressions

Fluoride treatments

Taking of oral radiographs

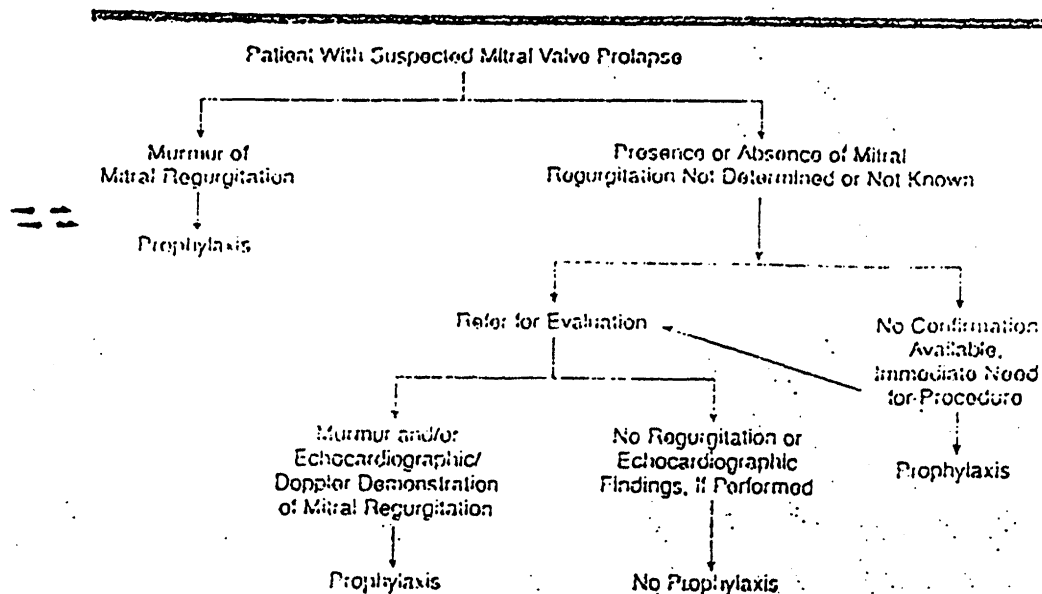
Orthodontic appliance adjustment

Shedding of primary teeth

\* Prophylaxis is recommended for patients with high-and moderate-risk cardiac conditions.

\*\* This includes restoration of decayed teeth (filling cavities) and replacement of missing teeth.

\*\*\*Clinical judgment may indicate antibiotic use in selected circumstances that may create significant bleeding.



Clinical approach to determination of the need for prophylaxis in patients with suspected mitral valve prolapse. For more details on the role of echocardiography in the diagnosis of mitral valve prolapse, see the text and the 1997 American College of Cardiology/American Heart Association guidelines for the clinical application of echocardiography.<sup>21</sup>

## b. Controversy Over Patients with Prosthetic Joints

### Guidelines for treating patients with prosthetic joints

- \*delay elective treatments at least 3 months after arthroplasty
- \*consult with orthopedic surgeon for each patient
- \*consult with primary care physician

### Groups at High Risk for Late Joint Infection

- \*rheumatoid arthritis
- \*previous complications with joint replacement:
  - infections
  - subluxation/dislocation
  - re-operated joints (particularly hips)
- \*long term immunosuppression (e.g. steroid therapy)
- \*systemic conditions (e.g. insulin dependent diabetes)

## c. Other Reported Indications

Patients with decreased host defense mechanisms  
disease:

aplastic anemia  
lupus erythematosus  
uncontrolled Addison's disease  
uncontrolled Diabetes Mellitus  
agammaglobulinemia  
agranulocytosis

drugs and other therapy:

antineoplastics  
immunosuppressants  
adrenal corticosteroids  
irradiation

## 3. Medicaments for Gingival Displacement/Enhancement

### a. Impregnated Retraction Cords

### Study Designs to Evaluate Epinephrine Absorption

- \* measure circulating catecholamines over time
- \* observe various hemodynamic responses

"Literature somewhat conflicting"

## Epinephrine-impregnated cord (8% solution)

\* 0.2mg - 1mg racemic epinephrine/inch

Racemic form of epinephrine = both *dl* forms of epinephrine

the biologically significant form *l*

## Guidelines for Using Epinephrine-impregnated Cord

- \* use conservatively
- \* measure lengths and calculate potential exposure
- \* apply astringents to cord and gingival tissues
- \* pre-treat gingival tissues with chlorhexidine
- \* prevent saliva contact with cord
- \* avoid placing cord in open vascular bed
- \* contraindicated in patients with cardiovascular problems

### b. Applied Solutions

#### Astringents

alum - aluminum potassium sulfate (Van R) (North Pacific)

aluminum ammonium sulfate

aluminum chloride (Styptin<sup>R</sup>) (Hemodent<sup>R</sup>)

zinc chloride\*

ferrous sulfate (Ultradent<sup>R</sup>) (Astringedent<sup>R</sup>)

aluminum sulfate (Pascord<sup>R</sup>)

\*frequently cited as most caustic agent

#### Criteria used to Select an Astringent

- |  |                               |
|--|-------------------------------|
| -limited systemic reactions                    | -adequate working time        |
| -minimal transient/permanent damage to tissues | -tasteless                    |
| -ability to control bleeding                   | -no effect to tooth structure |
| -leaves little or no coagulum residue          |                               |

### c. Antimicrobial Rinses

chlorhexidine gluconate 15ml bid  
2 weeks prior to crown preparation

during provisional crown placement  
2 weeks after definite crown cementation

adverse reactions:

- \*staining of natural and prosthetic teeth, and dorsal surface of tongue
- \*taste disruption

#### 4. Pharmaceutical regimes for managing xerostomia

##### *A Classic*

Dreizen S, Brown LR, Daly TE, Drane JB. Prevention of xerostomia-related dental caries in irradiated cancer patients. J Dent Res 1972;56:99-104.

##### a. Fluoride Applications

##### Daily Fluoride Gels

Karigel	NaF (1.1%)
Prevident	NaF (1.1%)
Perfect Choice	NaF (1.1%)
Thera-Flur	NaF (1.1%)
Gel Kam	SnF <sub>2</sub> (0.4%)
Omnii Gel	SnF <sub>2</sub> (0.4%)

##### b. Antimicrobial Rinses

chlorhexidine gluconate 15ml bid

adverse reactions:

- \*staining of natural and prosthetic teeth, and dorsal surface of tongue
- \*taste disruption

##### c. Antifungal Medications

##### Nystatin

not absorbed from intact skin or mucous membrane

mechanism of action:

interferes with the fungal cell wall membrane

adverse side effects:

- \* rare
- \* GI disturbances
- \* allergic reactions



## **Nystatin Preparations**

oral suspension

100,000 units/ml (Mycostatin)  
5ml qid  
rinse for several minutes and swallow  
10 days therapy or 2 days after remission of symptoms

ointment

100,000 units/g (Mycostatin)  
apply to affected areas several times daily

tablets

500,000 units (Mycostatin)  
dissolve tablet in mouth qid

n.b. Patients with removable prostheses should add 5ml oral suspension to soaking solution

## **Systemic Antifungal Agents**

ketoconazole (Nizoral) 200 or 400 mg daily  
1-4 weeks therapy or until clinical and mycologic tests negative

fluconazole (Diflucan) 50 or 100mg daily  
2 weeks therapy recommended

mechanism of action:

\*alters cellular membrane and interferes with intracellular enzymes

advantages over topically administered agents:

\*improves compliance

\*reduces interference with other rinsing solutions

**fluconazole** - generally reserved for patients in whom conventional therapy was not tolerated well or ineffective. Prior to initiation of therapy, culture and relevant laboratory studies should be obtained.

adverse side effects:

\*nausea, vomiting, abdominal pain, diarrhea

\*dermatologic changes

\*multiple drug interactions

\*increase in select liver enzymes

\*dizziness and headaches

**ketoconazole**

precautions:

\*associated with hepatotoxicity - isolated deaths reported

\*liver function test prior to initiation of therapy and monthly thereafter

adverse side effects:

\*nausea, vomiting, diarrhea

\*GI bleeding

\*transient increase in liver enzymes

\*multiple drug interactions

#### d. Saliva Substitutes

##### Saliva Substitute Ingredients

Potassium chloride

Sodium chloride

Magnesium chloride

Calcium chloride

Sodium fluoride

Potassium di-hydrogen orthophosphate

Methyl *p*-hydroxybenzoate

Sodium carboxymethylcellulose

Sorbitol

Di-potassium hydrogen orthophosphate

##### Indications for Use of Saliva Substitutes

Dry mouth

Sore mouth

Bad taste

Difficulty talking

Difficulty swallowing

Dry mouth at night

Dry lips

Thirst

Difficulty eating

Problems with dentures

#### e. Sialogogue Therapy

##### anetholetrithione (Sialor)

25mg tid

mechanism of action:

direct choleric effect on secretory cells of salivary

glands

contraindication:

\*liver dysfunction

adverse side effects:

\*mild gastrointestinal upset

##### pilocarpine

5mg qd

mechanism of action:

acts predominantly on muscarinic receptors at end organ sites

as a parasympathomimetic agent and has some activity via acetylcholine release by preganglionic stimulation.

contraindications:

- \*bronchial asthma
- \*spastic GI conditions
- \*urinary tract obstructions
- \*peptic ulcer
- \*recent myocardial infarction
- \*parkinsonism

adverse side effects:

- \*increased heart rate
- \*frequent urination
- \*nausea, vomiting, diarrhea, intestinal cramps

## 5. Therapies for "Burning Mouth Syndrome"/Stomatitis

### a. Analgesics

#### Lidocaine viscous

- advise patient to use sparingly (15ml swish and expectorate)
- administer 30 minutes before mealtime
- do not administer at intervals of less than three hours
- MRD 4.5mg/kg - x<300mg
- reduce dose with debilitated, elderly, acutely ill patients

precautions:

- \*excessive/overuse may anaesthetize the oral pharynx and disrupt the swallowing reflex

### Analgesic Preparations

#### single-entity type

- acetaminophen
- aspirin
- ibuprofen

#### combination type

- acetaminophen, codeine
- acetaminophen, meperidine
- acetaminophen, oxycodone
- aspirin, caffeine

Patrick M. Lloyd, DDS, MS  
Chair, Department of Family Dentistry  
University Of Iowa  
College of Dentistry  
S313 DSB Iowa City, IA 52242  
telephone: 319-335-7322  
e-mail: [patrick-lloyd@uiowa.edu](mailto:patrick-lloyd@uiowa.edu)

## DRUG THERAPIES IN PROSTHODONTICS

1. Local anesthetics
  - a. surface applied agents
  - b. parenterally administered  
precautions regarding vasoconstrictors
2. Antibiotic prophylaxis
  - a. recommendations to prevent bacterial endocarditis
  - b. controversy over patients with prosthetic joints
  - c. other reported indications
3. Medicaments for gingival displacement/enhancement
  - a. impregnated retraction cords  
vasoconstrictors
  - b. applied solutions  
astringents  
aluminum chloride  
aluminum sulfate  
ferrous sulfate  
  
vasoconstrictors
  - c. antimicrobial rinses
4. Pharmaceutical regimes for managing xerostomia
  - a. fluoride applications  
topical  
dentifrice
  - b. antimicrobial rinses  
chlorhexidine

- c. antifungal medications
  - oral rinses/troches
  - topical ointments and creams
  - systemic agents

- d. saliva substitutes
  - indications for usage
  - ingredients
  - instruction for use
  - ideal characteristics

- e. sialogogue therapy

5. Therapies for "Burning Mouth Syndrome"/Stomatitis

- a. analgesics
  - topical rinses
  - systemic medications

- b. steroid therapy
  - surface applied
  - systemic

- b. antifungal medications
  - oral rinses/troches
  - topical ointments and creams
  - systemic agents

6. Antisialagogue therapy

- a. anticholinergic medications
- b. dosage and administration times
- c. contraindications

---

REFERENCES:

**Antibiotic Prophylaxis**

Antibiotic prophylaxis for dental patients with total joint replacements. JADA 1997; 1004-8.

Prevention of bacterial endocarditis – recommendations by the American Heart Association. JAMA 1997;277:1794-1801.

Prevention of bacterial endocarditis: recommendations by the American Heart Association. JADA 1997 128:1142-1151.

Preventing bacterial endocarditis: a statement for the dental professional. JADA 1991; 87-92.

Field EA, Martin MV. Prophylactic antibiotics for patients with artificial joints undergoing oral and dental surgery; necessary or not? Br J Oral Maxillofacial Surg 1991;29:341-6.

### **Antisialagogue Therapy**

Kornfeld M. *Mouth Rehabilitation: Clinical and Laboratory Procedures*. pg. 578, 2nd ed. 1974, The C.V. Mosby Company, Saint Louis.

Sapkos SW, The use of antisialagogues in periodontal and restorative dentistry. *Int J Perio Rest Dent* 1984;4: 43-9.

Neidle EA, Kroeger DC, Yagiela J. *Pharmacology and Therapeutics for Dentistry*, pg. 156-57, ed.3, 1989 C.V. Mosby Co., St. Louis.

### **Antifungal Therapy**

Epstein JB, Komiyama K, Duncan D. Oral topical steroids and secondary oral candidiasis. *J Oral Med* 1986;41:223-8.

Fotos GP, Vincent SD, Hellstein JW. Oral candidosis: clinical, histological, and therapeutic features of 100 cases. *Oral Surg Oral Med Oral Path* 1992;74:41-9.

Fotos GP, Hellstein JW. *Candida and Candidosis: epidemiology, diagnosis, and therapeutic management*. *Dent Clin North Am* 1992;36:857-78.

### **Gingival Tissue Displacement/Enhancement**

Woycheshin FF. An evaluation of the drugs used for gingival retraction. *J Prosth Dent* 1964; 14:769-76.

Pergola SG, Raskin RB. Gingival retraction procedures. *NYS Dent J* 1983; 49:662-6.

Donovan TE, Gandara BK, Nemetz EH. Review and survey of medicaments used with gingival retraction cords. *J Prosth Dent* 1985; 53:525-31.

Benson BW, Bomberg TJ, Hatch RA, Hoffman W. Tissue displacement methods in fixed prosthodontics. *J Prosth Dent* 1986; 55:175-81.

Nemetz EH, Seibly W. The use of chemical agents in gingival retraction. *Gen Dent*. 1990; Mar/Ap:104-8.

Bowles WH, Tardy SJ, Vahadi A. Evaluation of new gingival retraction agents. *J Dent Res* 1991; 70:1447-9.

Ciarlone AE, Pashley DH. Permeability of root dentin to epinephrine released from gingival retraction cord. *Op Dent* 1992; 17:106-11.

Kellam SA, Smith JR, Scheffel SJ. Epinephrine absorption from commercial gingival retraction cords in clinical patients. *J Prosthet Dent* 1992; 68:761-5.

### **Local Anesthetics**

Malamed SF. *Handbook of Local Anesthesia*. 3rd ed. 1990, Mosby Year Book, St. Louis.

Malamed SF, Sykes P, Kubota Y, Matsuura H, Lipp M. Local anesthesia: a review. *Anesthesia and Pain Control Dent* 1992; 1:11-24.

Ayoub ST, Coleman AE. A review of local anesthetics. *Gen Dent* 1992; 40:285-7.

Perusse R, Goulet J, Turcotte J. Contraindications to vasoconstrictors in dentistry; Part I. *Oral Surg Oral Med Oral Path* 1992;74:679-86.

Perusse R, Goulet J, Turcotte J. Contraindications to vasoconstrictors in dentistry; Part II. *Oral Surg Oral Med Oral Path* 1992;74:687-91.

Perusse R, Goulet J, Turcotte J. Contraindications to vasoconstrictors in dentistry; Part III. *Oral Surg Oral Med Oral Path* 1992;74:692-7.

#### **Prosthetic use of chlorhexidine**

Budtz-Jorgensen E, Loe H. Chlorhexidine as a denture disinfectant in the treatment of denture stomatitis. *Scand J Dent Res* 1972;80:457-64.

Olsen I. Denture stomatitis: effects of chlorhexidine and amphotericin B on the mycotic flora. *Acta Odont Scand*;33:41-6

Flotra L, Gjermo P, Rolla G, Waerhaug J. Side effects of chlorhexidine mouth washes. *Scand J Dent Res* 1971;79:119-25.

Addy M, Davies RM, Beak A, Lewis A. The effect of single morning and evening rinses of chlorhexidine on the development of tooth staining and plaque accumulation. *J Clin Perio* 1982;9:134-40.

Fardal O, Turnbull RS. Review of the literature on the use of chlorhexidine in dentistry. *JADA* 1986;112:863-9.

Siegrist BE, Gusberti FA, Brex MC, Weber HP, Lang NP. Efficacy of supervised rinsing with chlorhexidine digluconate in comparison to phenolic and plant alkaloid compounds. *J Perio Res* 1986;16:60-73.

Ciancio SG. Adjunctive uses of topical antimicrobial mouthrinses. *Am J Dent* 1989;2:299-302.

Meffert RM. Chemotherapeutic mouthrinses as adjuncts in implant dentistry. *Am J Dent* 1989;2:317-21.

Sorensen JA, Doherty M, Newman MG, Flemming TF. Gingival enhancement in fixed prosthodontics. Part I: Clinical findings. *J Prosth Dent* 1991;65:100-7.

Flemmig TF, Sorensen JA, Newman MG, Nachani S. Gingival enhancement in fixed prosthodontics. Part II: Microbiologic findings. *J Prosth Dent* 1991;65:365-72.

Sorensen JA, Newman MG. Gingival enhancement in fixed prosthodontics. Part III: Anamnestic findings. *J Prosth Dent* 1991;65:500-4.

#### **Prosthetic use of fluorides**

Jensen ME, Kohout F. The effect of a fluoridated dentifrice on root and coronal caries in an older adult population. *JADA* 1988;117:829-32.

Epstein JB, Stevenson-Moore P, Scully C. Management of xerostomia. *J Canadian Dent Assoc* 1992;58:140-3.

#### **Sialogogue Therapy**

Epstein JB, Decoteau WE, Wilkinson A. Effect of sialor in treatment of xerostomia in Sjogren's syndrome. *Oral Surg Oral Med Oral Path* 1983;56:495-9.

Fox PC, Van der Ven PF, Baum BJ, Mandel ID. Pilocarpine for the treatment of xerostomia associated with salivary gland dysfunction. *Oral Surg Oral Med Oral Path* 1986;61:243-5.

Fox PC, Pilocarpine used to stimulate normal saliva production.  
JADA 1986;11:310-2.

### **Dental Pharmacology Texts**

Accepted Dental Therapeutics, Council on Dental Therapeutics of the American Dental Association, 1984, Chicago.

Holyord SV, Wynn RL, Requa-Clark B. Clinical Pharmacology in Dental Practice. ed.4 1988 C.V. Mosby Co., St. Louis.

Needle EA, Kroeger DC, Yagiela J. Pharmacology and Therapeutics for Dentistry, ed.3, 1989 C.V. Mosby Co., St. Louis.

Newman M, Kornman K. Antibiotic/Antimicrobial use in Dental Practice. 1990 Quintessence Co. Inc., Chicago.

Cowan FF. Dental Pharmacology. ed.2, 1992 Lea & Febiger, Philadelphia.

Ciancio SG, Bourgault DC. Clinical Pharmacology for Dental Professionals. ed. 3 Year Book Medical Publisher, Inc., Chicago.

### **Prescription Recommendations in Dentistry**

Clinician's Guide to Treatment of Common Oral Conditions, ed 2, The American Academy of Oral Medicine, fall 1990.

### **General Pharmacology Texts**

Goodman LS, Gilman A. The Pharmacological basis of therapeutics. Macmillan-Hill Book Co., New York.

### **Pharmacology References Books**

American Hospital Formulary Service: Drug Information. Published by authority of the Board of Directors of the American Society of Hospital Pharmacists Inc., 1993.

*Drug Facts Comparisons*, A. Wolters Kluwer Co., J.P. Lippincott Co., 1993.

### **Dental Texts on Oral Manifestations of Systemic Diseases**

Jones JH and Mason DK. *Oral Manifestations of Systemic Disease*. 2nd ed. 1990, W.B. Saunders, Co.

Van der Wal, Isaac, *The Burning Mouth Syndrome*, 1st ed. 1990, Munksgaard, Copenhagen.

Wood NK and Goaz PW. *Differential Diagnosis of Oral Lesions*, 4th ed. 1991 Mosby - Year Book, Inc.



# **Review Of Basic Materials In Prosthodontics**

**Dr. John C. Wataha**



**BASIC MATERIALS IN PROSTHODONTICS**  
**GLOSSARY OF PROPERTIES OF BIOMATERIALS WHICH ARE COMMONLY**  
**ENCOUNTERED IN PROSTHODONTICS - PAGE 1**

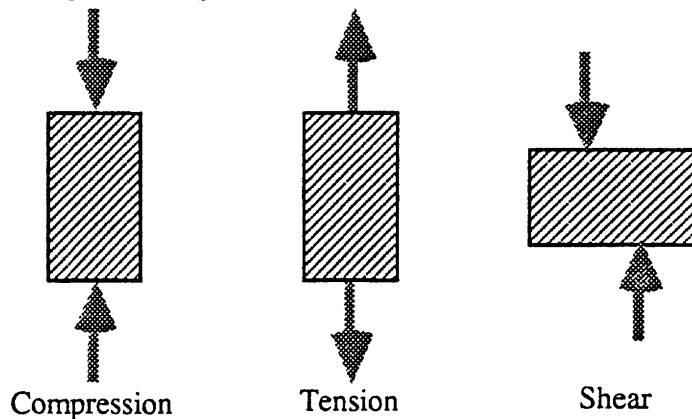
This is a brief glossary of properties of biomaterials which are routinely used in prosthodontics. It will provide a basic understanding of properties which are not immediately intuitive, but will not replace more rigorous definitions and explanations of these properties. Properties which are intuitive are not listed (e.g., melting point, bond strength, transparency, solubility, etc.). More detailed explanations can be found in the references.

**MECHANICAL PROPERTIES**

**Stress:**

The internal reaction to an external force which is applied to a material over a given area. The stress is proportional in magnitude to the applied force. Measured in units of force per unit area (e.g. pounds per square inch, megapascals per square meter). Stress is usually categorized into three groups: compressive (forces directed toward each other in a straight line); tensile (forces directed away from each other in a straight line), and shear (forces directed parallel to each other in different planes) (Fig. 1).

Fig. 1 - Compressive, Tensile, and Shear Stresses



**Residual Stress:**

A stress which remains in a material after the external force is removed usually because a setting reaction or solidification of the material has prevented its release. Particularly relevant to waxes and denture base resins.

**Strain:**

The deformation of a material in response to an externally applied force, expressed as change in length per unit length. Strain has no units. Strain can be elastic (temporary), when it disappears after the removal of the stress, or plastic (permanent), when it remains.

**Tensile Strength:**

The tensile stress required to fracture a material. Also called ultimate tensile strength. Has units of stress.

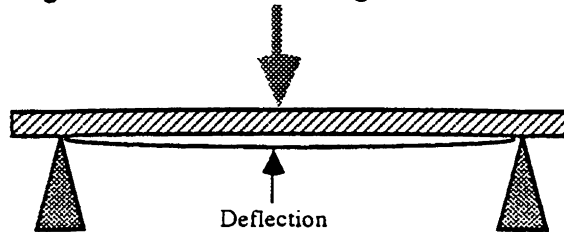
**Compressive Strength:**

The compressive stress required to fracture a material.

**Transverse Strength:**

The stress required to fracture a material when the stress is applied to a material in a transverse manner as shown in Fig. 2. Often used to measure the strength of denture base resins, composites, and porcelain. Sometimes considered to be a combination of compressive, shear, and tensile strengths.

Fig. 2 - Transverse Loading and Deflection



**Transverse Deflection:**

The deflection in a material as a result of a transverse loading. Usually used in the assessment of the ability of denture base resins to withstand transverse loading without fracture (Fig. 2).

**Yield Strength:**

The stress required to incur a specified amount of permanent deformation (strain) in a material. The amount of permanent deformation is usually delineated as 'offset'. For example, 0.1% offset means a permanent strain of 0.001. Often used to measure the point at which a material begins to deform. A repeatable and practical property to measure.

**Proportional Limit (Elastic Limit):**

The exact stress at which a material begins to behave non-elastically. In practice, it is difficult to determine this value and yield strength is usually substituted (Fig. 3).

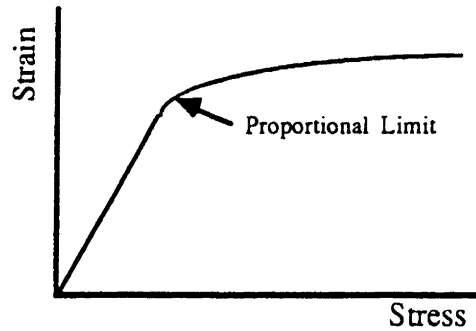
**% Elongation:**

The deformation which results from application of a tensile stress to the point of fracture. Equal to the increase in length divided by the original length multiplied by 100. Composed of elastic and permanent components. A measure of the ductility of a material. Relevant to many dental materials including alloys, denture liners, and maxillofacial materials which must withstand significant elongation without fracture.

**Modulus of Elasticity:**

The ratio of stress to strain below the proportional limit. Has units of stress. Represents the stiffness of a material, or the resistance to deformation. Important in almost all type of dental materials, but especially important in assessing the rigidity of partial dentures, implants, and fixed multiple unit bridges. In a stress-strain plot, the modulus is the slope of the linear portion of the curve (Fig. 3).

Fig. 3 - Stress Strain Curve Showing Modulus and Proportional Limit



**Dynamic Modulus of Elasticity:**

The ratio of stress to strain for small cyclical deformations of a material. Important in maxillofacial elastomers and maxillofacial polymers. Can be used to estimate the ability of a material to dissipate energy as heat (as with mouth protectors).

**Toughness:**

The area under the entire stress vs. strain curve (Fig 3). Represents the energy per unit volume required to fracture the material.

**Impact Strength:**

The total energy required to fracture a material when the force is applied very rapidly. Units are usually given in energy (joules). The primary difference between impact strength and toughness is the rate at which the force is applied. Important in assessing how a material will withstand a sudden large stress application (such as dropping a denture on the floor).

**Fatigue Strength:**

The stress which causes fracture of a material after repeated application and removal. The magnitude of the stress is usually below the proportional limit. The number of loading-unloading cycles may vary from 1000 to 1,000,000 or more. Important in assessing the durability of materials which will undergo cyclical stresses (crowns, dentures, implants, etc.).

**Tear Strength (Tear Energy):**

The stress required to cause a material to tear. Units can be in force per unit thickness (tear strength) or energy per unit area (tear energy). This property is particularly important for elastomeric materials such as impression materials, denture reline materials, and maxillofacial prosthesis materials which must withstand tensile stresses without tearing. Several types of tests exist.

**Hardness:**

The ability of a material to resist indentation. There are several types of hardness tests (Brinell, Knoop, Vickers, Rockwell, and Shore A) and each has applications which are advantageous. Hardness is a complex mixture of tensile, compressive, and transverse strengths. It is related to wear, but does not correlate ideally with the wear of materials.

**Creep:**

The strain which occurs in a material under constant stress. Materials which exhibit significant creep are said to be viscoelastic. Creep is important in impression materials, waxes, and maxillofacial materials which may be loaded with a fixed stress for long periods of time.

**Percent Strain:**

The strain in a material produced by a given stress. Important in impression materials, where it is used to assess the stiffness of a material.

**THERMAL PROPERTIES**

**Melting Range:**

The temperature range in which a material exists in liquid and solid forms simultaneously. Pure substances have melting points, but mixtures of substances have melting ranges. This is particularly important in alloys because if the alloy has a broad melting range, then the molten metal exists in liquid form over a broad range of temperatures and is subject to more oxidation.

**Coefficient of Thermal Expansion:**

The increase or decrease in length of a material in response to a unit increase in temperature. Expressed in terms of degrees centigrade or Fahrenheit ( $^{\circ}\text{C}^{-1}$  or  $\text{F}^{-1}$ ). Important in areas of metal-porcelain compatibility, denture base resins, and waxes and the fit of castings.

**Thermal Conductivity:**

The quantity of heat which passes through a material which separates two areas of different temperature. Thermal conductivity is important in any tooth restorative material which might transfer heat to the pulp, denture base processing, waxes, porcelain application to metals, and a variety of other areas.

**Specific Heat:**

The amount of heat required to raise the temperature of a material one degree centigrade. Important in casting of metals, sintering of porcelain, and porcelain metal bonding because it determines how much energy must be supplied to raise the temperature of these materials.

**Thermal Diffusivity:**

The rate at which a material which has a nonuniform temperature achieves a uniform temperature. Diffusivity is dependent on the thermal conductivity, the specific heat, and the density of a material. Important in the cooling of porcelain-metal restorations and castings.

**Flow:**

Used in waxes and impression materials to describe the strain produced in a material by a constant force. Similar to creep. Flow is extremely temperature dependent.

**Glass Transition Temperature:**

The temperature at which a material undergoes a change in structure which causes a change in its properties from a brittle to a more ductile state. This property is especially important if the transition temperature is near the common working temperature range of the material.

**CHEMICAL PROPERTIES**

**Water Sorption:**

The amount of water absorbed by a material after a given amount of time. Important in denture base resins, maxillofacial prostheses, gypsum, and investments. Water sorption usually influences other properties of the materials such as modulus of elasticity.

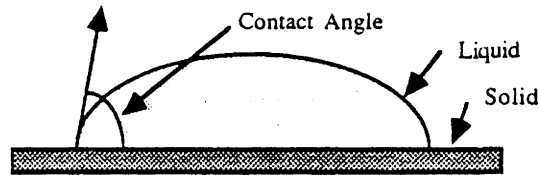
**Setting Expansion (or Contraction):**

The change in length of a material as it sets. Important in impression materials, gypsum, investments, maxillofacial materials, and denture base resins.

**Contact Angle:**

The angle which a liquid forms against a solid surface. Used to assess the wettability of a surface (Fig. 4). Large contact angles imply that the surface is not easily wet by the liquid. Important in impression material-gypsum compatibility, impression material-tooth compatibility, and denture retention.

Fig. 4 - Contact Angle Measurement



**Surface Tension:**

The energy at the surface of a liquid which occurs as the result of the boundary between the liquid and the air. Surface tension is important in adhesion (of solders, tooth bonding agents) and in application of materials which must wet surfaces onto which they are applied.

**Colloids:**

A substance which consists of two or more phases, when one of the phases is slightly larger than normal molecular size. The colloid particles are usually between 1 - 500 nm. Important in materials which use fillers (such as impression materials, denture base resins, maxillofacial materials, and investments). The properties of colloids are unusual because of their extremely large surface areas.

**OPTICAL PROPERTIES**

**Fluorescence:**

The ability of a material to absorb light of one wavelength and re-emit it in a short time at a longer wavelength. The absorbed light is commonly in the ultraviolet range and is often re-emitted in the visible range. Important because teeth naturally fluoresce, and most porcelains attempt to mimic this quality.

**Hue, Value, Chroma:**

Parameters used to define color (Munsell System). Hue is roughly equivalent to the basic color of a material, chroma is the intensity of the basic color, and value is the amount of gray in the material. It is important to remember that color is not a property of a material, but a result of interactions between a source of light and a material, and is also subject to the interpretation of the observer. Another set of color parameters (Lab-C.I.E. System) are dominant wavelength (similar to hue), excitation purity (chroma), and luminous reflectance (value).

**Metamerism:**

A phenomenon where two objects appear to be the same color under one light source and different colors under a second source. Important in shade selection of porcelain or composite restorations.

ADA Specifications, Published in J. Am. Dent. Assoc.

These articles contain the specifications used to test materials for certification by the ADA. Although the majority of these documents are devoted to detailed procedures, they are useful for identifying the important properties which are used to characterize materials.

Anusavice K.J. Recent developments in restorative dental ceramics. J. Am. Dent. Assoc. 124:72-84, 1993.

This review article contains basic information about the major types of ceramic systems which are being used for dental restorations. Some physical data and some compositional data is available.

Asgar K. Casting metals in dentistry: past - present - future, Adv. Dent. Res. 2: 33-43, 1988.

This review article is an excellent review of compositions and important properties of casting metals written by one of the world's leading authorities on this subject. Emphasis is on ceramo-metal alloys.

Craig R.G. (ed.). Restorative Dental Materials (9th ed.), St. Louis: The C.V. Mosby Company, 1993.

This book is an excellent reference for dental materials information. It covers most, if not all, dental materials in addition to chapters on physical, chemical, and mechanical properties and a chapter on biocompatibility testing. Although written at the level of a dental student, it contains sufficiently detailed information to be valuable as a review for the prosthodontist.

Craig R.G. Review of dental impression materials, Adv. Dent. Res. 2: 51-64, 1988.

This article is an excellent review of impression materials, the evolution of materials, and properties of impression materials which are critical for proper clinical performance. Dr. Craig has tested many varieties of impression materials and is internationally recognized as an expert in this area.

Drennon D.G. and Johnson G.H. The effect of immersion disinfection of elastomeric impressions on the surface detail reproduction of improved gypsum casts. J. Prosthet. Dent. 63: 233-241, 1990.

This research article focuses on the effect of immersion disinfection on the ability of the impression to retain surface details once poured in gypsum. Polyether, polysulfide, and addition silicone materials were studied.

Drennon D.G., Johnson G.H., and Powell G.L. The accuracy and efficacy of disinfection by spray atomization on elastomeric impressions. J. Prosthet. Dent. 62: 468-75, 1989.

This research article focuses on spray atomization as a method of impression material disinfection and addresses the dimensional stability of the impression materials and the effectiveness of the disinfectants. Polyether, polysulfide, and addition silicone impression materials were treated with five different disinfectants.



BASIC MATERIALS IN PROSTHODONTICS  
REFERENCES-PAGE 2

Flinn R.A. and Trojan P.K. Engineering Materials and Their Applications (4th ed.), Boston: Houghton Mifflin Company, 1990.

This book is an undergraduate entry level engineering book, and has detailed explanations of physical, chemical, and mechanical properties of ceramics, polymers, metals, and composite materials. It is an excellent resource for in-depth explanations of topics such as phase diagrams for metals, and crack propagation measurement, among many others.

Moffa J.P. Porcelain materials, Adv. Dent. Res. 2: 3-6, 1988.

An excellent review article covering all aspects of porcelain materials. Discussions of newer aluminous porcelains and castable glass ceramics are included.

O'Brien W.J. (ed.). Dental Materials: Properties and Selection, Chicago: Quintessence Pub. Co., 1989.

This book comprehensively covers dental materials at the level of the undergraduate dental student. It is particularly useful in understanding the types of a given material which are available, and differences between the types. It also has an extensive list of manufacturers' addresses, and an impressive list of material properties.

Phillips R.W. (ed.). Skinner's Science of Dental Materials (9th ed.), Philadelphia: W.B. Saunder's Company, 1990.

This book is written for dental students and covers most aspects of dental materials, but has a greater engineering emphasis than other books in this field.

Smith D.C. Dental cements, Adv. Dent. Res. 2: 134-141, 1988.

An excellent review article covering all types of dental cements by a recognized expert in the field. Discussions of bonding and biological properties of cements are included.

## BASIC MATERIALS IN PROSTHODONTICS OUTLINE OF IMPORTANT TOPICS - PAGE 2

Color of the Alloys: Au-based alloys will be white if the Pd is  $> 10$  wt.%. Cu increases the redness of the alloy. The color of base metal alloys is often determined by their oxides, which are much thicker than in gold-based alloys.

### Properties

Mechanical Properties: Tensile strength is commonly used to compare alloy strengths. The proportional limit is the stress required to permanently deform the alloy. Yield strength is more practical measure of the stress necessary to deform the alloy a given percentage. Modulus of elasticity is a measure of alloy stiffness, percent elongation is a measure of the alloy ductility. Hardness is resistance to indentation.

Thermal Properties: The coefficient of thermal expansion is a measure of the amount of expansion during an increase in temperature. Thermal conductivity is used to measure the efficiency of heat transfer. Sag resistance is important in PFM alloys. Recrystallization is important in cold worked alloys because it reduces the properties of these alloys.

Corrosion: The nobility of alloys has a large effect on corrosion: Alloys with  $< 75\%$  nobility will tend to have higher intra-oral corrosion rates. Alloys which have multiple phases will have higher corrosion rates, but allow the alloy to be etched, since the different phases dissolve at different rates.

Bonding: Alloys must bond to resins, cements, porcelain, or other alloys (soldering) in various applications. Bonds may be chemical or mechanical or some combination of both.

Biocompatibility: Alloys must not irritate or damage the body locally or systemically. Alloys with poor biocompatibility may cause toxicity, allergic reactions, or mutagenic reactions.

## PORCELAINS

### Types

Feldspathic: Feldspathic porcelains and are available as high, medium, and low fusing types. Only the low fusing type is used in dental restorations. These porcelains contain primarily feldspar, silica, and kaolin. Upon heating they form a crystalline phase (leucite) in a vitreous glass. Inorganic chemicals are added for color, opacity, and fluorescence.

Alumina: aluminous porcelains are composed of alumina and a low fusing glass. They have a higher modulus and strength than feldspathic porcelains. Their coefficient of thermal expansion is lower than other porcelains, so they require special secondary porcelains. A high-strength material (In-Ceram) has recently been developed. It is a glass-infiltrated aluminous porcelain.

Magnesia: magnesia porcelains are composed of magnesia in a low fusing glass. Like alumina porcelains, these materials are used as core materials. However, the coefficients of thermal expansion are closer to those of feldspathic porcelains. Thus, traditional secondary porcelains can be used with this material.

# BASIC MATERIALS IN PROSTHODONTICS

## OUTLINE OF IMPORTANT TOPICS - PAGE 3

**Cast Glasses:** Dicor and Ceraparl systems are castable glasses which form a second crystalline phase upon curing (ceramming). The second phase adds strength to the material. The final composition of Ceraparl is not unlike hydroxyapatite.

**Injection-molded Glasses:** Cerestore and Alcerm (no longer used) are glasses which are injection molded to a die. They are feldspathic porcelains with high leucite contents and therefore higher strengths. IPS Empress is a newer injection-molded porcelain.

### Mechanical Properties

Transverse strength is often used because it is much easier to measure with porcelains. Compressive strengths are very high, and tensile strength samples are difficult to prepare, and are subject to many artifactual errors because of porcelain's brittle nature. Modulus of elasticity is used to assess the stiffness of the porcelain, and these are very high. The hardness of most porcelains are at least as great as enamel.

### Thermal Properties

**Coefficient of Thermal Expansion (CTE):** The coefficient is important to metal-porcelain compatibility.

Feldspathic porcelains typically have CTE of about 12, whereas magnesia CTE's are about 14, and alumina CTE's are about 8. Gold has a CTE of about 14 /°C.

**Thermal Diffusivity:** Thermal diffusivity is the rate at which the material reaches thermal equilibrium and is important because it influences the cooling of a fired crown, and therefore is important in crack formation during cooling.

### Optical Properties

**Translucency/Opacity:** The opacity and/or translucency is important to prevent or allow passage of light through the porcelain.

**Fluorescence:** The fluorescence of the porcelain is required to mimic the nature fluorescence of enamel.

Fluorescence should generally be blue-white and should be equivalent for all porcelains used in a given restoration.

**Color:** The color of the porcelain should be matched within a given restoration.

### Bonding Properties

**Effect of Coefficient of Thermal Expansion:** To bond properly to metals, the coefficient of thermal expansion of the ceramic should be about 0.5/°C lower than that of the metal. This places the porcelain in compression upon cooling, which reduces fracture problems.

**Modes of Failure:** Bonding failures can occur between the metal, oxide, or ceramic layers or within these layers (cohesive fractures). The location of debonding depends upon the strengths of the various layers, the ability of the layers to bond, and the type of stress applied.

## WAXES

### Types of Dental Waxes

Dental waxes are used in almost all areas of dentistry. Types include, inlay, casting, baseplate, boxing, utility, sticky, corrective, and bite waxes. Each wax has been formulated to provide properties which are often specific to an application.

### Composition - Components of Dental Waxes

Dental waxes are composed of hydrocarbons from mineral (petroleum), plant, insect, or synthetic sources. Most waxes are a combination of these sources. Furthermore, each source is not a pure compound, but a collection of compounds of a general type. Components of waxes include paraffin, microcrystalline wax, ceresin, caruba, and beeswax.

### Mechanical Properties

Properties such as modulus of elasticity, proportional limit, and compressive strength are generally not high compared to other dental materials and are not useful for characterization because of their extreme dependence on temperature and prior thermal history.

### Thermal Properties

**Melting Range:** Since waxes are not of homogeneous composition, they have melting ranges, rather than melting points. The melting characteristics of the wax will influence its other properties such as flow, ductility and expansion.

**Flow:** Flow is a measure of dimensional change under a static load and is highly temperature dependent. In waxes, flow points may be designed to be above or below room temperature depending upon the application.

**Ductility:** This property is largely determined by the composition of the wax. Waxes such as caruba wax are quite brittle because of the hydroxyl or ester groups which predominate in the hydrocarbons. Paraffin, on the other hand, is largely pure hydrocarbons, and is much more ductile. Ductility is highly dependent upon temperature.

**Coefficient of Thermal Expansion (CTE):** CTE for waxes are among the highest of any dental material, and therefore changes in temperature can produce significant dimensional changes, which is important in the waxing-casting process.

**Residual Stress:** A solid piece of wax will almost invariably contain residual stresses which can be released if the temperature is high enough or the time is long enough.

## INVESTMENTS

### Compositions

All investments contain a (1) refractory material, which gives the material resistance to heat and is often the source of expansion, (2) a binder, which holds the refractory material together, and (3) various additives to prevent oxidation of the metal or the investment material.

### Types

Dental investments are of three types. Gypsum bonded investments have a silica refractory (usually cristoballite or tridymite) and a calcium sulfate binder. Phosphate investments have a magnesium ammonium phosphate binder and a silica refractory. Silica investments have a tetrasilicic acid binder and a silica binder.

### Setting Reactions/Manipulation

Each binder has a setting reaction which proceeds at a different rate, and has an expansion (or contraction) of its own. Manipulative factors such as mixing time, water immersion, or water/powder ratio can influence the properties of the binder. Phosphate and silica bonded investment binders have a green strength, which then matures as the investment is heated.

### Mechanical Properties

**Compressive Strength:** compressive strength is important to be able to resist the impact of the metal into the investment.

**Roughness:** roughness is important because it will influence the surface quality of the cast surface.

**Porosity:** porosity will influence the ability of gases to escape from the investment as the molten metal enters the investment cavity.

### Thermal Properties

**Expansion:** the expansion of investments consists of three components: setting, hygroscopic, and thermal expansion. Each type of investment material has different attributes in this regard.

**Decomposition Temperature and Alloy Compatibility:** each type of investment has a temperature above which it will decompose and become useless for casting. Since the temperature of the investment should be no more than 500°C below the temperature of the molten metal, this limits the types of metals which will be compatible with a given investment.

**Antioxidants:** most investments contain additives to reduce oxidation (and therefore decomposition) of the investment and the alloy. Additives include carbon and oxalates.

## CASTING PROCEDURES

### Overall

Requirements for Accuracy: A good dental casting should approximate the margin of the restorations to within about 2 microns. To achieve this type of tolerance, each step in the casting procedure must be performed correctly.

Sources of Dimensional Change: Sources of expansion include the setting expansion of the dye, the expansion of the wax pattern, and expansion of the investment. The primary source of shrinkage is the shrinkage of the solid metal from its freezing temperature to room temperature

### Waxing

Temperature During Waxup and Investing: Since the coefficient of thermal expansion for waxes are high, temperature changes during waxing or investing can produce significant shrinkage or expansion of the wax pattern.

Minimizing Residual Stress: Manipulation (carving, burnishing, rapid cooling) will incorporate residual stresses in the wax which will distort the waxup if released. Proper manipulation of wax can reduce the incorporation of these stresses.

### Spruing

The position, length, and diameter of the sprue can influence the success of the casting. The ideal placement the sprue depends upon the type of restoration, type of metal being used, and type of casting process. The size of the sprue button can also influence the proper formation of the casting.

### Investing

Factors such as ring orientation, height of the pattern in the ring, and type of ring liner can influence the success of the casting.

### Casting

Casting is a complex process, the success of which is influenced by many variables. Ring burnout temperature and duration are important to eliminate the wax pattern, provide the proper expansion, provide the proper receipt temperature, and prevent decomposition of the investment. The metal temperature must be sufficient to fill the mold completely, but not oxidize the metal, while providing the correct freezing order in the mold. The method of heating the metal (flame vs. induction) can influence the metal properties. The speed of the casting machine can influence the completeness of the casting, the presence of suckback porosity, and cracking of the investment. The method of cooling can influence the mechanical properties of the casting.

## Common Casting Problems

**Suckback Porosity:** caused from an improper freezing order of the alloys.

### Black Alloy

**Removable Coating:** caused by oxidation of the metal (gold alloys).

**Non-removable Coating:** caused by incorporation of carbon particles into the alloy.

**Incomplete Casting:** caused by insufficient casting pressure, low porosity investment, improper spruing, improper burnout, or improperly heated metal.

## IMPRESSION MATERIALS

### Types

Impression materials are commonly divided in the hydrocolloids (alginate and agar) and the elastomeric materials (polysulfides, polyethers, condensation silicones, addition silicones, and light cured resins).

### Compositions

Each type of impression material has major components which form the polymer bulk of the material, fillers to modify the unset and set properties of the polymer matrix, catalysts to speed the setting reaction, pigments for colors, and other additives to ensure gypsum compatibility, proper wetting properties, etc.

### Setting Reactions/Manipulation

Working and Setting Times: each type of impression material has specific working and setting times which are determined by the type of polymer and the manipulation conditions. It is important to work within these times to obtain the optimum physical properties. The mixing, removal, disinfection, pouring, and type of die material will all be influenced by the working and setting times.

Type of Setting Reaction: There are two features of the setting reactions which are important in determining the physical properties of the materials. The first feature is the by-product of the reaction. If the by-products are volatile, then the dimensional stability of the material will be reduced. The second feature is the presence of crosslinking. If the polymer is crosslinked, then the setting will not be reversible and the set mass will have greater dimensional stability, reduced creep, reduced flexibility, and increased tear strengths (in most cases).

### Mechanical Properties

There are several mechanical properties which are used to characterize impression materials. Percent deformation (or percent set) is a measure of the permanent deformation after a strain. Dimensional stability is a measure of permanent deformation with time. Flow is a measure of the viscous deformation during a strain. Percent strain is a measure of flexibility. Tear strength and hardness are also used. Other properties include compressive strength, ability to reproduce detail, and the time related creep properties (creep compliance).

## Compatibility Properties

The compatibility of an impression material with die materials is another important property which will depend upon the chemical composition of the impression material and the die material, and the setting times of both materials. The ability of a material to be electroplated is also important for some applications.

## CEMENTS

### Types

**Zinc-Oxide Eugenol:** ZOE cements are composed of a powder of zinc oxide and a liquid of primarily eugenol.

The set cement is a matrix of zinc eugenolate with embedded zinc oxide particles. Several types are reinforced with alumina particles. Water accelerates the setting reactions.

**Non-Eugenol Zinc-Oxide:** These cements have liquids of chlorothymol or n-hexylvanillate and ethoxybenzoate.

The powders are generally either zinc oxide or zinc oxide and alumina. The setting reactions are similar to the ZOE cements.

**Zinc Phosphate:** These cements are composed primarily of a zinc oxide powder and a phosphoric acid liquid.

The set cement is a matrix of zinc phosphate with embedded zinc oxide particles. The setting reaction is significantly exothermic, and occurs at a low pH.

**Glass Ionomer:** The powder is an aluminosilicate glass (containing fluoride) and the liquid contains polyacrylic acid or itaconic acid. The set mass consists of a matrix of calcium or aluminum polyacrylate with embedded glass particles. These cements have a slow final set time of several weeks, and will generally leach fluoride from the glass particles for long durations. Newer cements incorporate a resin system into the liquid to add a polymerization reaction (so called light set glass ionomer cements).

**Zinc Polyacrylate:** These cements are a zinc oxide powder and a polyacrylic acid liquid. The set mass contains zinc polyacrylate with embedded zinc oxide particles. The unset mixture is pseudoplastic and quite viscous at low shear rates if mixed properly.

**Resin:** These cements are formed from a free radical polymerization reaction of a Bis-GMA or urethane dimethacrylate oligomer. Fillers are added for opacity and strength, but are substantially less prevalent than for restorative resin systems. Particle sizes are kept small to keep film thickness minimized.

**Mixtures:** Newer cements have become available which are essentially mixtures of glass ionomers and resin cements, and share some properties of both depending on their composition.

### Setting Reactions/Manipulation

**Working and Setting Times:** The working and setting times of each type of cements often depend on such factors as powder/liquid ratio, temperature of the mix, the presence of water, and method of mixing.



# BASIC MATERIALS IN PROSTHODONTICS

## OUTLINE OF IMPORTANT TOPICS - PAGE 9

**Effects of Manipulation on Properties:** The strength of cements are generally greatest and their solubilities least when the amount of matrix is kept to a minimum. Thus, mixing so that the maximum powder is incorporated will generally result in stronger, less soluble cements. However, incorporation of the powder must be balanced against the viscosity of the mix and the rate of the setting reaction.

### Mechanical Properties

Several mechanical properties are used to assess cements. The compressive strength generally corresponds well to the ability of the cement to retain a casting. Tensile strength is occasionally used to rate cements, however. Film thickness is important to assure that the cement will not prevent complete seating of the crown. Modulus of elasticity is important when the cements are used as bases below the permanent restorative material.

### Chemical Properties

**Solubility:** The solubility of cements are important because dissolution of the cement is undesirable in the mouth. All cements are soluble to some extent. Assessment of solubility can be done in different solutions (e.g., water, acid, saliva, etc), and will affect the ranking of the solubility.

### Bonding Properties

Newer cements have bonding properties. Several factors are important in bonding such as the type of bonding (chemical vs. mechanical), the strength of the bond, and the substrates to which the cement will bond. With the exception of resin-enamel bonding, most bonding systems are not currently adequate to retain restorations long-term without supplementary retention.

### Biocompatibility

The biocompatibility of cements is particularly important because they are often placed onto cut dentin or in the gingival sulcus where dissolution will expose tissues to their components. With some cements, pH changes are also important considerations.

## GYPSUM MATERIALS

### Types

There are three types of gypsum materials in common use: plaster, stone, and high strength stone (die stone). Each has the same chemical composition (calcium sulfate hemi-hydrate), but the crystal size of the types are different.

### Composition

Calcium sulfate hemi-hydrate sets by the addition of water to give the di-hydrate. Excess water is always present to allow manipulation of the mixture, but the excess water decreases the strength of the set mass. Thus, die stones, which have the highest strength properties, have the least water added. Accelerators and

# BASIC MATERIALS IN PROSTHODONTICS

## OUTLINE OF IMPORTANT TOPICS - PAGE 10

retarders are sometimes added to adjust the setting or working times, as with impression plaster (accelerators added).

### Setting Reaction and Manipulation

Working and Setting Times: the working and setting times of gypsum products depend upon the crystal size of the gypsum, the water/powder ratio, the spatulation rate and time, the temperature of the water, the humidity, the storage history of the powder, the presence of colloids (such as blood, or alginate), and the addition of supplementary chemicals. To obtain consistent properties, these factors must be controlled.

Effect of Manipulation on Properties: manipulation of gypsum products also affect the strength, abrasion resistance, and expansion of gypsum products.

### Mechanical Properties

Several mechanical properties are used to characterize gypsum products: compressive strength, abrasion resistance, tensile strength, reproduction of detail, and expansion (both setting and hygroscopic).

## DENTURE BASE RESINS

### Types

There are four basic types of denture base resins currently used in dentistry. Polymethylmethacrylate (PMMA) - e.g. Lucitone, is the most common denture base resin. PMMA-Hydroxyethylmethacrylate copolymer - e.g. Hydrocril, is a resin with improved wetting properties for improved retention. Rubber Reinforced PMMA - e.g. Lucitone 199, is used in situations where severe impacts are likely to occur. Light activated materials are similar to resin composites and are used primarily for repairs at present. These materials have an entirely different polymer system than the other systems.

### Composition

**Powder:** the powder of traditional resins is composed of small beads of pre-polymerized polymer, some sort of initiator (like a peroxide), pigments for color, opacifiers, and plasticizers (sometimes).

**Liquid:** the liquid is typically composed monomer, some sort of accelerators (like an amine), inhibitors, plasticizers (sometimes), and perhaps a cross linking agent.

### Setting Reactions and Manipulations

Polymerization Reaction: the polymerization reaction is usually initiated by a peroxide and accelerated by an amine, and is a free radical-type polymerization. If a cross linking agent is present, then it will be incorporated into the mass as well. The manipulation of the resin will depend upon whether the peroxide is activated by heat (heat cure), by an accelerator (chemical cure), or by light (light cure). The type of system will determine whether the denture will be poured or packed, the fit, the problems with porosity, the residual monomer present, and the strengths.

## Mechanical Properties

Several mechanical properties are used to characterize denture base resins. Tensile and compressive strengths are measures of overall strength. Modulus of elasticity is a measure of the materials flexibility. Transverse strength is a measure of the material's ability to withstand bending. Impact strength is a measure of the ability to withstand rapid application of force. Fatigue strength is the ability to withstand low intensity, repeated applications of force. Hardness is a crude measure of abrasion resistance.

## Chemical Properties

Several chemical properties are important in denture base resins. The amount of residual monomer may be important in allergic patients. The wetting properties (contact angles) are important to denture retention and staining. Water sorption is important for staining. The amount of crazing and color stability are also important.

## Thermal Properties

Thermal properties which are important are thermal conductivity, the coefficient of thermal expansion, and the glass transition temperature. Thermal conductivity influences the patient's ability to sense heat or cold through the denture. The coefficient of thermal expansion is important during denture processing, and the glass transition temperature is important when the denture is heated in hot water (residual stresses can be released if the denture is heated above the glass transition temperature).

## OTHER PROSTHODONTIC POLYMERIC MATERIALS AND MAXILLOFACIAL MATERIALS

### Types

**Tissue Conditioners:** These materials are generally not polymerized resin systems, but are plasticized gels which stiffen and harden as the plasticizer is leached from the system.

**Soft Liners:** These materials are often polymerized systems, but have been modified with different copolymers or plasticizers to increase their flexibility. These systems can be cured in the mouth or lab processed, depending upon the system. Lab-processed systems generally maintain properties for a longer period of time.

**Mouth Protectors:** These systems are generally thermoplastic copolymers of polyvinyl acetate and polyethylene.

**Maxillofacial Materials:** Currently, polyurethanes and silicones are the most common materials for maxillofacial prosthetics. Polyurethane materials are copolymers of di-isocyanates and polyalcohols. The polymerized mass is highly cross-linked. The processing uses stone molds and temperatures of about 100°C. Silicone materials are addition polymerizations of shorter methylvinyl siloxanes. They are either high or low temperature processed. High temperature silicones use dichlorobenzoyl peroxide as catalysts and require metal molds and temperatures of 220°C. Room-temperature silicones use

## BASIC MATERIALS IN PROSTHODONTICS OUTLINE OF IMPORTANT TOPICS - PAGE 12

chloroplatinic acid catalysts and can use stone molds. Room-temperature silicones are very similar in composition to addition silicone impression materials.

### Properties

Maxillofacial polymers can be best characterized by several properties. Shore A hardness is commonly used for softer materials, whereas Rockwell hardness is used for the harder materials. Tensile strength is used, but tear strength or tear energy is more often used. Water sorption is important in determining the potential staining of the polymer. Some polymers must be assessed for bonding to polymethylmethacrylate resins or for adhesion to skin. Dynamic properties (such as the dynamic modulus) are often useful in assessing the energy absorption or dispersion properties of these polymers.

# **Bonding And Luting Agents**

**Dr. Stephen Bayne**



## PROSTHODONTIC REVIEW

Notes: "Internet Reference Materials"

### Online Prosthodontic Review

**ALL HANDOUT MATERIALS →**  
**Free Access to MEDLINE →**

<http://www.dent.unc.edu/bayne/pros-rev/rev-hp.htm>

<http://www.ncbi.nlm.nih.gov/PubMed/>

### Prosthodontics Sites:

List of Prosthodontics Sites  
ACP Home Page

<http://www.dentalsite.com/dentists/pros.html>

<http://www.prosthodontics.org/acpros/>

### UNC Sites for Dental Materials Review

UNC School of Dentistry Home Page  
UNC School of Dentistry Online Materials  
Dental Materials Science Course  
All SCB Dental Materials Lectures

<http://www.dent.unc.edu>

<http://www.dent.unc.edu/courses.htm>

<http://www.dent.unc.edu/bayne/dms/dms-hp.htm>

<http://www.dent.unc.edu/bayne/dentmtls/dm-lectures.htm>

### Related Sites for DM Information:

IADR-Dental Materials Group Home Page  
US and Canadian Schools of Dentistry

<http://www.dent.unc.edu/bayne/dmg/hp-dmg.htm>

<http://www.dent.unc.edu/bayne/dmg/files/sods-na.htm>

## PROSTHODONTIC REVIEW

### Lecture: "Dental Cements for Luting"

#### INTRODUCTION:

##### A. Overview of Dental Cements:

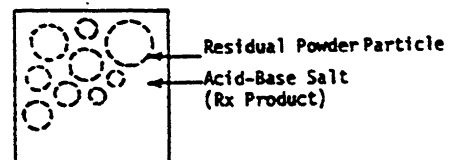
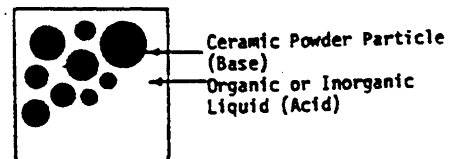
1. Definitions:
  - a. Luting cement =
  - b. Bonding =
2. Principal Goals:
  - a. Retention
  - b. Sealing (Elimination of microleakage)
3. Theories of Pulpal Irritation:
  - a. Fluid Flow (Sensitivity)
  - b. Bacterial Endotoxins (Inflammation)

##### B. Classification by Components:

		<i>LIQUID</i> --Acid--	<i>POWDER</i> --Base--
1.	Zinc Oxide Eugenol		
a.	Unmodified (ZOE)	Eugenol	ZnO
b.	Reinforced (ZOE-Reinf)	Eugenol	ZnO, Polymer, Rosin
c.	ZOE-EBA (EBA)	Eugenol/EBA	ZnO, Al <sub>2</sub> O <sub>3</sub> , Rosin
2.	HV-EBA (HV-EBA)	HV/EBA	ZnO, Al <sub>2</sub> O <sub>3</sub> , Rosin
3.	<u>Zinc Phosphate</u> (ZP)	H <sub>3</sub> PO <sub>4</sub> /H <sub>2</sub> O	ZnO
4.	<u>Silicate</u> (SC)	H <sub>3</sub> PO <sub>4</sub> /H <sub>2</sub> O	Silicate
5.	Zinc Silico-phosphate (SPC)	H <sub>3</sub> PO <sub>4</sub> /H <sub>2</sub> O	ZnO, Silicate
6.	<u>Polycarboxylate</u> (PCC)	PAA/H <sub>2</sub> O	ZnO
7.	<u>Glass Ionomer</u>		
a.	<u>Conventional</u> (GI)	PAA/H <sub>2</sub> O	Silicate
b.	<u>Resin Modified</u> (RH-GI)	" and HEMA	Silicate, Resin
8.	Calcium Hydroxide (CH)	Phenolic Esters	Ca(OH) <sub>2</sub>
9.	<u>Composite (with DBS)</u> (CC)	(Monomers)	(Silicate Fillers)

##### C. Composite Analysis of Dental Cements Formulations:

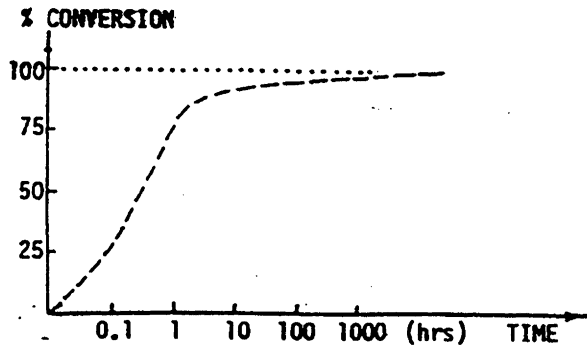
1. *Before* the reaction:
  - a. Continuous Phase:
    - (1) Acid functional LIQUID
    - (2) Catalyst
  - b. Dispersed Phase:
    - (1) Base functional POWDER
    - (2) (Reinforcing Polymer)
2. *After* the reaction:
  - a. Continuous Phase
    - (1) Reaction Product MATRIX
    - (2) Residual Catalyst
  - b. Dispersed Phase
    - (1) Residual POWDER
    - (2) (Reinforcing Polymer)



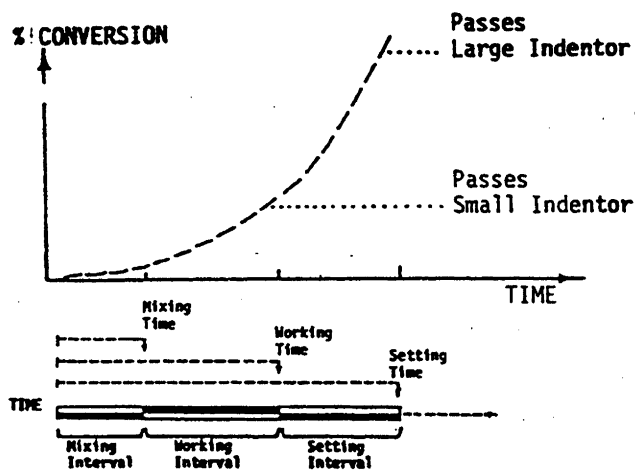


D. Dental Cement Reactions:

1. Overall Reaction Conversion for Powder: (approximately 12 v/o)
2. Overall Reaction Conversion for Liquid:



## 3. Monitoring of Initial Reaction:

4. Control of Reaction Variables and Final Properties:  
(\* All controlled by the operator.)

- a. *MIXING* Interval Variables:
  - (1) Temperature
  - (2) % Relative Humidity
  - (3) P/L Ratio
  - (4) Mixing Procedures
- b. *WORKING* Interval Variables:
  - (1) Time of Placement
- c. *SETTING* Interval Variables:
  - (1) Thickness
  - (2) Disturbances

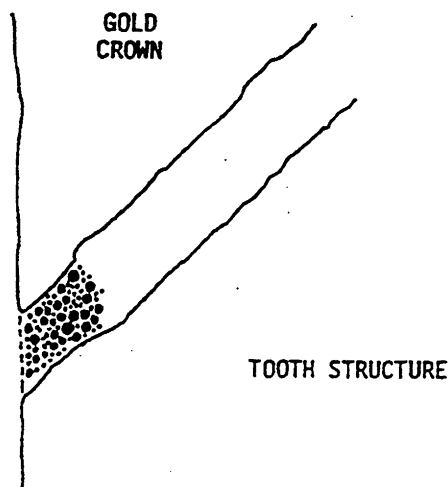
E. Overview of Dental Cement Properties:

1. Physical Properties:
  - a. Coefficient of Thermal Expansion
  - b. Thermal Conductivity and Diffusivity
  - c. Electrical Conductivity
2. Chemical Properties:
  - a. Solubility and Disintegration
  - b. Absorption
3. Mechanical Properties:
  - a. Compressive Strength
  - b. Tensile Strength
  - c. Shear Strength
  - d. Bond Strength
4. Biological Properties:
  - a. Chemical Irritation of Pulp During Setting

F. Clinical Performance of Luting Cements (3 Year Retention Rate):

*Silvey RG and Myers GE. Clinical study of dental cements: VII. A study of bridge retainers luted with three different dental cements. J Dent Res 1978; 57:703-707.*

1. Zinc Phosphate	Crowns = 100%	Bridges = 98%
2. Polycarboxylate	96%	95%
3. Reinforced ZOE, ZOE-EBA	98%	92%


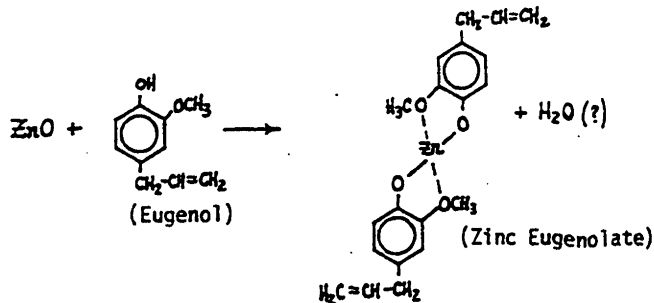
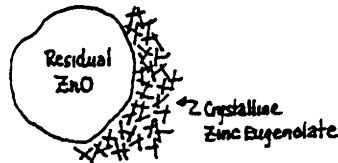



## DENTAL CEMENT STRUCTURE AND MANIPULATION:

- A1. Zinc Oxide/ Eugenol Cement: and  
 A2. Zinc Oxide/ Eugenol Cement: (Reinforced ZOE)

### 1. Chemistry:


- a. Continuous Phase:  
 Acid functional liquid = Eugenol  
 Catalysts = H<sub>2</sub>O, Acetic Acid, Zinc Acetate, CaCl<sub>2</sub>
- b. Dispersed Phase:  
 Base functional powder = Zinc Oxide  
 Fillers or modifiers = MgO, PMMA, Silica,...



ZOE B+T Powder  
5000 X



Zinc Eugenolate Xls  
1000 X



Set Cement w/ Pores  
100 X

### 2. Setting Reaction:

- Slow Reaction; Stepwise Reaction; Very little exotherm
- Crystalline Reaction Product = Zinc Eugenolate Chelate
- H<sub>2</sub>O required to make reaction occur.

### 3. Manipulation and Technique Considerations:

- P/L should be mixed thoroughly:
  - Method of powder addition is not very critical.
  - Method of spatulation is not very critical.
- Reaction not very temperature sensitive because reaction is slow.
- H<sub>2</sub>O in air and on oral surfaces accelerates the reaction.

A3. ZOE-EBA Cements:

## 1. Chemistry:

## a. Continuous Phase:

Acid functional liquid

= Eugenol (33%), EBA (67%)

Catalysts


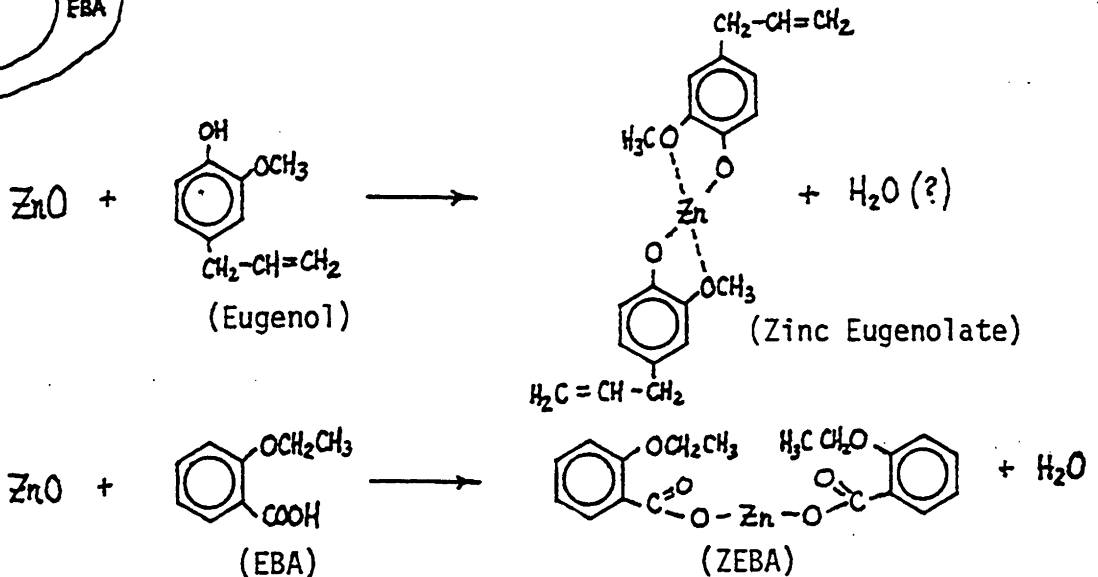
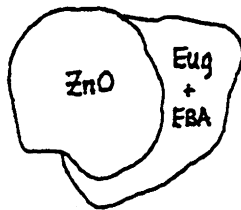
= None required

## b. Dispersed Phase:

Base functional powder

= Zinc Oxide

Fillers or modifiers

= MgO, Al<sub>2</sub>O<sub>3</sub>

## 2. Setting Reaction:

a. Slow Reaction; Stepwise Reaction; More exothermic than ZOE.

b. Crystalline Reaction Product = ZE + ZEBA.

(Zinc ethoxybenzoate crystallizes slowly from amorphous matrix).

c. H<sub>2</sub>O produced as by-product of reaction.

## 3. Manipulation and Technique Considerations:

a. Reaction not very temperature sensitive because reaction is slow.

b. P/L should be mixed thoroughly:

-- Method of powder addition is not very critical.

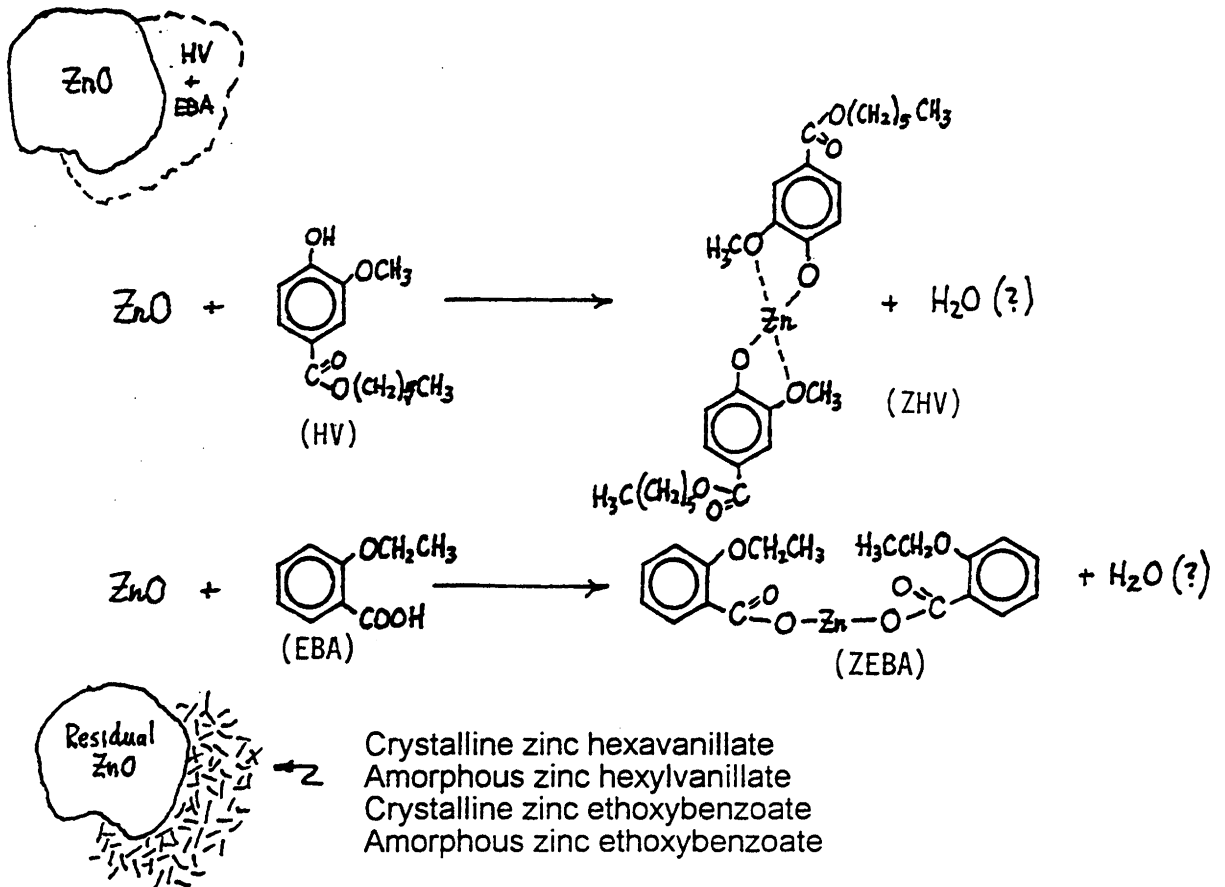
-- Method of spatulation is not very critical.

-- Mixing is relatively difficult.

B. EBA-HV Cements:

## 1. Chemistry:

- a. Continuous Phase:  
 Acid functional liquid = Ethoxybenzoic acid  
 and hexylvanillate  
 Catalysts = None required
- b. Dispersed Phase:  
 Base functional powder = Zinc Oxide  
 Fillers or modifiers =  $\text{Al}_2\text{O}_3$ , Hydrogenated Rosin



## 2. Setting Reaction:

- Slow Reaction; Stepwise Reaction; More exothermic than ZOE.
- Crystalline Reaction Product = ZEBA + ZHV  
 (Zinc ethoxybenzoate crystallizes slowly from amorphous matrix).
- $\text{H}_2\text{O}$  produced as by-product of reaction.

## 3. Manipulation and Technique Considerations:

- Reaction not very temperature sensitive because reaction is slow.
- P/L should be mixed thoroughly:
  - Method of powder addition is not very critical.
  - Method of spatulation is not very critical.
  - Mixing is relatively difficult.

### C. Zinc Phosphate Cement:

#### 1. Chemistry:

##### a. Continuous Phase:

Acid functional liquid

Catalysts

Retarders

= 28-38 w/o  $H_3PO_4$  in  $H_2O$

= None required (strong acid)

= Aluminum phosphate and zinc phosphate buffers.

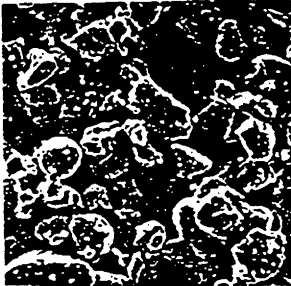
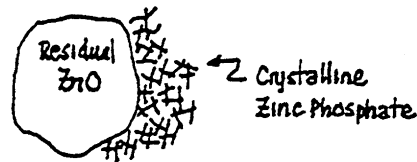

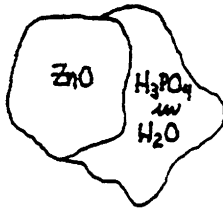
##### b. Dispersed Phase:

Base functional powder

Modifiers

= 90ZnO-10MgO (Heat treated)


= (Silica)



Fleck's ZP Powder  
1000 X



Tert. ZP Crystals



Set ZP Cement  
40,000 X

#### 2. Setting Reaction:

##### a. Extremely exothermic reaction:

\*Buffers in liquid slow reaction.

\*Heat treatment of powder slows reaction.

##### b. Crystalline products formed = tertiary zinc phosphate.

#### 3. Manipulation and Technique Considerations:

##### a. Reaction is sensitive to:

Temperature.

\* $H_2O$  content of liquid (CONTROLS IONIZATION).

##### b. P/L manipulation controls reaction and final properties:

\*Mix on CHILLED glass slab.

\*Dispense P and L at a RATIO of 2.0 or higher.

\*Incorporate powder INCREMENTALLY over 90-120 secs.

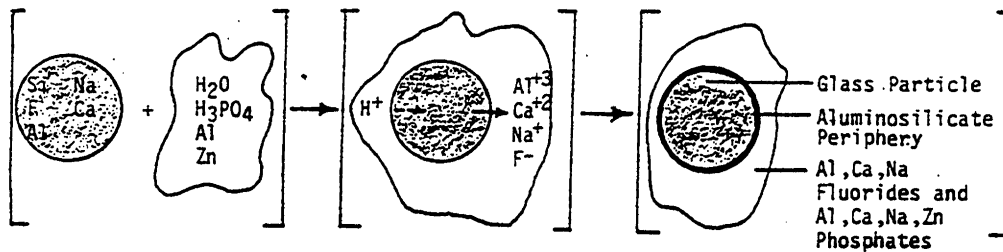
\*SPATULATE thoroughly to dissipate heat of reaction.

D. Silicate Cements:

## 1. Chemistry:

- a. Continuous Phase:
  - Acid functional liquid = 42 w/o  $H_3PO_4$  in  $H_2O$
  - Catalyst = None required (strong acid)
  - Retarder = 18 w/o Al or Zn phosphate
- b. Dispersed Phase:
  - Base functional powder = Alloy of  $SiO_2 / Al_2O_3 / Na_3AlF_6 / Ca(H_2PO_4)_2 \cdot H_2O$
  - Modifiers = None

Powder components fused to glass at 1400 C  
 Fluorides and Al phosphates act as ceramic fluxes  
 Hot glass is fritted by quenching and then ground  
 Powder reactivity depends on Al/Si ratio



## 2. Setting Reaction:

- a. Extremely exothermic reaction:
- b. Reaction product matrix = amorphous aluminosilicate gel.
- c. Stages of reaction:
  - Mixing: initial contact of liquid with base powder
  - Working: ion migration during powder dissolution
  - Setting: metal/phosphate precipitation  
(Reaction continues for hours to days)

## 3. Manipulation and Technique Considerations:

- a. Reaction is sensitive to:
  - Temperature.
  - $H_2O$  content of liquid (CONTROLS IONIZATION).
  - Spatulate over small area to minimize water loss.
- b. P/L manipulation controls reaction and final properties:
  - Mix on CHILLED glass slab.
  - Dispense P and L at a RATIO of 2.0 or higher.
  - Incorporate powder in 3 increments over 90-120 secs.


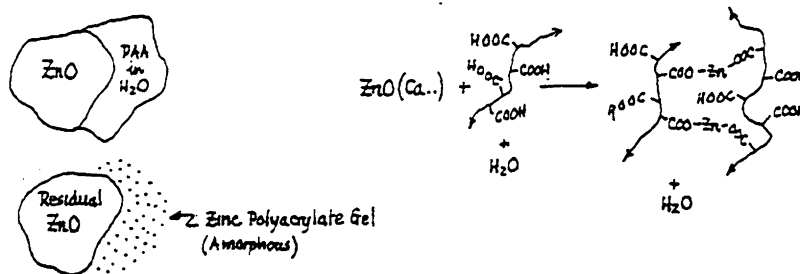
E. Zinc Silico-phosphate Cements:

1. Chemistry: Mixture of zinc phosphate and silicate components
2. Setting Mechanisms: combination of zinc phosphate and silicate cements
3. Manipulation and Techniques: see Silicate Cements

F. Polycarboxylate Cements:

## 1. Chemistry:

- a. Continuous Phase:  
Acid functional liquid = 50 w/o acid polymer based on acrylic, itaconic, maleic, tartaric in H<sub>2</sub>O
- b. Dispersed Phase:  
Base functional powder = ZnO  
Modifiers = None



Amorphous matrix of crosslinked PAA chains.

Pore remaining after erosion removed ZnO.

Durelon Cement (after erosion of residual ZnO from matrix)  
1000 X

## 2. Setting Reaction:

- a. Exothermic reaction; Relatively fast; Cannot be retarded!
- b. Amorphous crosslinked polymer formed during setting:  
Chains bonded to each other by Zn ion chelation.  
Chains bonded to Zn ions on residual ZnO powder.  
Chains bonded to Ca ions on tooth structure surface.

## 3. Manipulation and Technique Considerations:

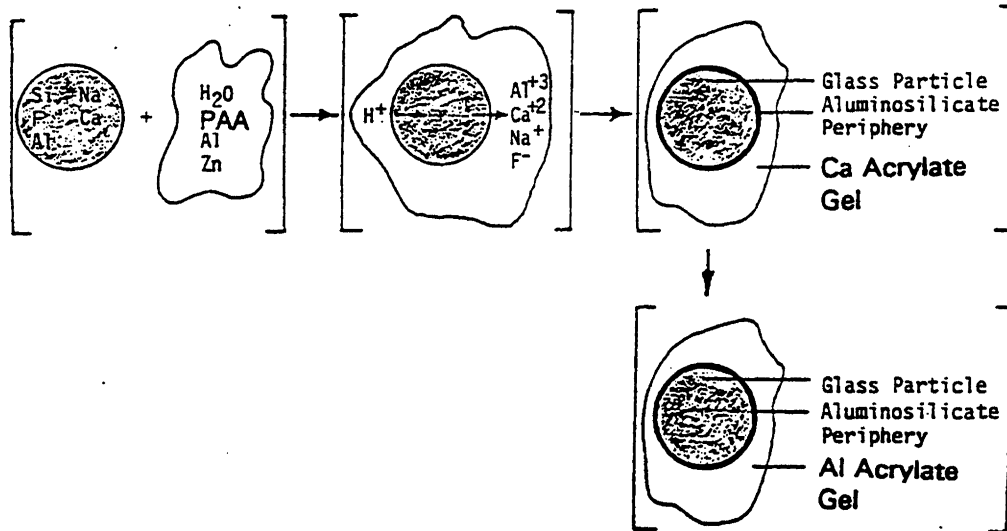
- a. Reaction is sensitive to:  
Temperature.  
H<sub>2</sub>O content of liquid (CONTROLS IONIZATION).
- b. P/L mixed carefully to control reaction and properties:  
Mix CHILLED COMPONENTS on paper pad.  
Dispense P and L at ratio of 1.5 to 2.0  
Incorporate P QUICKLY over 15-30 secs all at once.  
Spatulate thoroughly but not after 30 secs mix time.
- c. Product variations: Regular set (C+B); Fast set (ortho, pedo)
- d. Setting times = 3-5 mins at 37 C



## G1. Glass Ionomer Cements:

### 1. Chemistry:

- a. Continuous Phase:
  - Acid functional liquid = 50 w/o acid functional polymer (AA, Itaconic, Tartaric, Maleic)
  - $H_2O$
- b. Dispersed Phase:
  - Base functional powder = Alloy of  $SiO_2$ /  $Al_2O_3$ /  $Na_3AlF_6$ /  $Ca(H_2PO_4)_2 \cdot H_2O$
  - Modifiers = None



### 2. Setting Reaction:

- b. Reaction product matrix = amorphous Al-polyacrylate gel.
- c. Stages of reaction:
  - Mixing: initial contact of liquid with base powder
  - Working: ion migration during powder dissolution
  - Setting: Ca-acrylate gel replaced by Al-acrylate gel (Reaction continues for 24-72 hrs)

### 3. Manipulation and Technique Considerations:

- a. Reaction is sensitive to: Temperature.
- b. P/L manipulation controls reaction and final properties:

## G2. Resin Modified Glass Ionomer Cements:

### 1. Chemistry:

- a. Continuous Phase:
- b. Dispersed Phase:

### 2. Setting Reaction:

### 3. Manipulation and Technique Considerations:

**COMMERCIAL EXAMPLES OF DENTAL CEMENTS:**

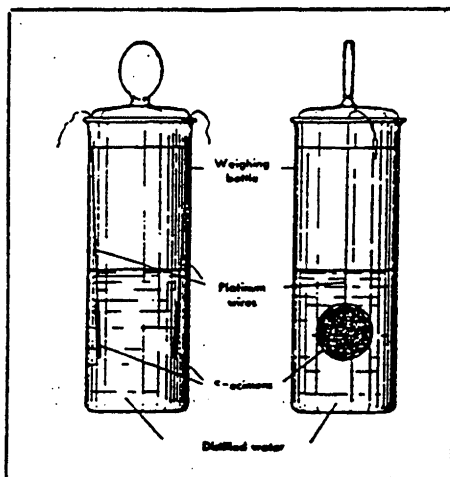
A.	Zinc Oxide Eugenol Cements:		
	ZOE 2200	ZOE	(LD Caulk)
	ZOE	ZOE	(J. Bird Moyer Co.)
	ZOE Temporary	ZOE	(LD Caulk)
	ZOGENOL	ZOE	(Stratford Cookson)
	ZOE B+T	ZOE	(LD Caulk)
	IRM	RZOE	(LD Caulk)
	FYNAL	RZOE	(LD Caulk)
	ZEBACEM	RZOE-EBA	(LD Caulk)
	OPOTOW ALUMINA-EBA	RZOE-EBA	(Getz)
B.	Hexyl Vanillate Cements: (None currently marketed)		
C.	Zinc Phosphate Cements:		
	MODERN TENACIN	ZP	(LD Caulk)
	FLECK'S EXTRAORDINARY	ZP	(Mizzy)
	SMITH'S ZINC CEMENT	ZP	(Teledyne)
	AMES Z-M	ZP	(Teledyne)
	KENT ZINC CEMENT	ZP	(Stratford Cookson)
	LANG-C+B Only	ZP	(Lang)
	S-C	ZP	(Stratford Cookson)
	DROPSIN	ZP-Liner	(Atwood Industries)
	ELITE	ZP	(I.D.T. Corp)
D.	Silicate Cements:		
E.	Zinc Silico-phosphate Cements:		
	AMES PLASTIC Porcelain	SPC	(Teledyne)
	ASTRALIT	SPC	(Premier)
	SYNTREX F	SPC	(Premier)
	SILICAP	SPC	(HD Justi)
F.	Polycarboxylate Cements:		
	TYLOK	PC	(LD Caulk)
	DURELON	PC	(Premier)
	CHEMIT	PC	(Harry J. Bosworth)
	CARBOXYLON	PC	(3M)
G.	Glass Ionomer:		
	ASPA	GI	(LD Caulk)
	IONOMER	GI	(Denmat)
	FUJI II	GI	(GC America)
	KETAC-CEM	GI	(ESPE-Premier)
	VITREBOND CEMENT	GI	(3M)
	FUJI DUET	RMGI	[GC-America]
	VITREMER CEMENT	RMGI	[3M]
	ADVANCE	RMGI	[LD Caulk]
	NEXUS	RMGI	[Kerr]
H.	Calcium Hydroxide Cements:		
	DYCAL	CH	(LD Caulk)
	LIFE	CH	(Kerr)
	ULTRA-BLEND (with F)	CH	(Ultradent Products)
	TIMELINE		
I.	(Resin) Composite Cements:		
	COMSPAN	CC	(LD Caulk)
	PANAVIA	CC	(Kuraray)
	PANAVIA 21	CC	(Kuraray)
	ENFORCE	CC	(LD Caulk)
	RESIN CEMENT	CC	[3M]

**DENTAL CEMENT PROPERTIES:****A. Comparison of Generic Types:**

	Physical Properties	Chemical Properties	Mechanical Properties
	<i>Dimensional Changes (lm/cm)</i>	<i>Solubility &amp; Disintegration (w/o, 37°C, 7d)</i>	<i>Compressive Strength (psi, 37°C, 7d)</i>
1. ZOE	-31 to -85	0.02 to 0.10	2,000 to 5,500
2. ZOE-Reinf.	— to —	— to —	10,000 to 15,000
3. ZOE-EBA	-12 to -24	— to 0.40	— to —
4. HV-EBA	— to —	— to 0.01	— to 18,000
5. ZP	+15 to -7	0.05 to 0.10	19,000 to 21,000
6. PC	+50 to +420	0.04 to 0.08	8,000 to 18,000
7. GI			18,000 to 24,000
8. RH-GI			24,000 to 30,000

**B. ADA Solubility Test:**

1. Specification #8: Zinc Phosphate Cement:
  - a. Cement wafer used.
  - b. Sample preparation: 1 hr old, 37°C, H<sub>2</sub>O immersion, pH=7.
  - c. Measure weight loss indirectly after 1 day or 7 days.
  - d. Passing limit ≤ 0.02 w/o in 1 day.



2. Problems with Lab Solubility Test:
  - a. Lab data conflict with clinical data.
  - b. Questionable meaning of solubility values.
    - (1) 0.1 w/o in 7 days =
    - (2) 0.2 w/o in 1 day =

**C. Manipulation Effects on Solubility:**

- |                             |                          |              |
|-----------------------------|--------------------------|--------------|
| 1. P/L ratio low            | --> Too much reaction    | --> High sol |
| 2. Over-mixing              | --> Too much reaction    | --> High sol |
| 3. Under-mixing             | --> Poor reaction        | --> High sol |
| 4. Poor temperature control | --> Matrix discontinuity | --> High sol |
| 5. Disturbance at setting   | --> Matrix discontinuity | --> High sol |

**MULTIPLE CHOICE STUDY QUESTIONS:**

1. **Which ONE of the following is the most important property for dental cement to guarantee long term clinical success?**
  - a. Compressive strength
  - b. Resistance to solubility and disintegration
  - c. Low coefficient of thermal expansion
  - d. Radiopacity similar to tooth structure
  - e. Setting contraction
  
2. **Microleakage of bacterial endotoxins will result in:**
  - a. Pulpal inflammation
  - b. Sensitivity
  - c. Cement dissolution
  - d. Loss of adhesion to dentin
  - e. Plaque formation under the cement
  
3. **Which one of the following is the reason that dental cement cannot be set by light curing methods alone?**
  - a. Inadequate access
  - b. Oxygen inhibition of thin films
  - c. Excessive polymerization shrinkage
  - d. Visible light heating effects on the pulp
  - e. Dentin absorption in the visible light range
  
4. **The overall reaction and properties of dental cements are most appropriately analyzed in terms of:**
  - a. Non-crystalline ceramics
  - b. Non-crystalline polymers
  - c. Rule-of-mixtures for composites
  - d. Griffith-Orowan theory
  - e. Brannstrom theory
  
5. **Which ONE of the following dental cements does NOT contain zinc oxide as part of its powder composition?**
  - a. Zinc phosphate cement
  - b. Zinc silico-phosphate cement
  - c. ZOE cement
  - d. Durelon cement
  - e. Silicate cement
  
6. **Which ONE of the following dental cements does NOT contain water as part of the composition of the liquid component?**
  - a. Fleck's cement
  - b. IRM cement
  - c. Polycarboxylate cement
  - d. Tenacin cement
  - e. Geristore cement
  
7. **Eugenol does NOT have which ONE of the following characteristics?**
  - a. Oily liquid
  - b. Same composition as oil of cloves
  - c. Aromatic Odor
  - d. High reactivity toward ZnO
  - e. Obtundent effect on pulp

8. **Phosphoric acid SOLUTIONS which are used as the liquid component of zinc phosphate and silico-phosphate cements have an INITIAL pH value of:**
- 0.1 to 1.0
  - 1.0 to 2.0
  - 2.0 to 3.0
  - 3.0 to 5.0
  - 5.0 to 7.0
9. **Which of the cement powders for the following dental cements does NOT have a basic pH value?**
- ZOE cement
  - Zinc phosphate cement
  - Polycarboxylate cement
  - Silicate cement
  - None of the above
10. **Which ONE of the following cements uses a liquid that is an aqueous solution of polymer?**
- Zinc phosphate cement
  - ZOE cement
  - Polycarboxylate cement
  - Silico-phosphate cement
  - ZOE reinforced cement
11. **Which ONE of the following cements uses a liquid that is an aqueous solution of polymer?**
- Zinc phosphate cement
  - ZOE cement
  - Glass ionomer cement
  - Silicophosphate cement
  - ZOE reinforced cement
12. **During the initial setting reaction for dental cements, approximately what percentage of powder is reacted?**
- 10 to 25%
  - 25 to 50%
  - 50 to 75%
  - 75 to 90%
  - 90 to 100%
13. **Approximately what LEVEL of cement setting reaction is complete after the first hour?**
- 0-25%
  - 25-50%
  - 50-75%
  - 75-90%
  - 90-100%
14. **What is the method of determining the SETTING TIME for dental cement reactions?**
- Peak exotherm of the reaction
  - Time interval to 150 psi strength
  - Large Gilmore needle
  - Loss of gloss
  - None of the above

15. **The SETTING TIME is defined in which one of the following ways?**
- Elapsed time from the start of mixing to the completion of setting.
  - Elapsed time from the start of mixing to the start of setting.
  - The interval from the start of setting to the completion of setting.
  - The interval from the start of working to the completion of setting.
  - Elapsed time from the start of working to the completion of setting.
16. **Which ONE of the following variables is VERY important for the mixing of ZOE cements?**
- Mixing temperature
  - Percent relative humidity
  - Mixing time
  - Method of spatulation
  - Method of powder addition
17. **Which ONE of the following cements should be mixed on a chilled glass slab?**
- ZOE cement
  - ZOE reinforced cement
  - ZOE-EBA cement
  - Zinc phosphate cement
  - Polycarboxylate cement
18. **Which ONE of the following cements should be mixed as quickly as possible?**
- Zinc phosphate cement
  - ZOE cement
  - ZOE-EBA cement
  - Silicophosphate cement
  - Polycarboxylate cement
19. **Which ONE of the following cement mixtures is the least sensitive to temperature effects during mixing?**
- Polycarboxylate cement
  - ZOE cement
  - Zinc phosphate cement
  - Glass ionomer cement
  - Silicophosphate cement
20. **For which ONE of the following dental cement types is the incremental addition of powder to the liquid extremely important during the mixing of the cement?**
- Dycal cement
  - Durelon cement
  - Tenacin cement
  - IRM cement
  - ZOE cement
21. **Which ONE of the following dental cements requires catalysis for the setting to occur?**
- ZOE cement
  - Zinc phosphate cement
  - Silicophosphate cement
  - Polycarboxylate cement
  - Resin hybrid glass ionomer cement
22. **Which ONE of the following dental cement phases is NOT CRYSTALLINE?**
- Zinc eugenolate
  - Tertiary zinc phosphate

- c. Zinc oxide
  - d. Magnesium oxide
  - e. Zinc polyacrylate
23. **The reaction product matrix of ZOE-EBA cement is primarily composed of:**
- a. Crystalline zinc eugenolate
  - b. Zinc ethoxybenzoate
  - c. Polymer reinforcement
  - d. Alumina
  - e. Zinc polyacrylate gel
24. **EBA-HV cements do NOT contain which of the following:**
- a. Ethoxybenzoic acid
  - b. Hexylvanillate
  - c. Zinc oxide
  - d. Alumina
  - e. Eugenol
25. **Which ONE of the following ZINC PHOSPHATE cement COMPONENTS primarily CONTROLS the reactivity of the powder and the liquid during mixing?**
- a. Zinc oxide powder particle size
  - b. Magnesium oxide additives
  - c. Aluminum phosphate buffers
  - d. Zinc phosphate buffers
  - e. Water content of the liquid
26. **Which ONE of the following mixing methods is correct for zinc phosphate cement manipulation?**
- a. 6 incremental additions of P over 90-120 sec with stropping on chilled glass slab.
  - b. 3 incremental additions of P over 90-120 sec using a chilled glass slab.
  - c. Rapid combination of all P into all L at the outset.
  - d. 3 incremental additions over 120 sec using a paper mixing pad.
  - e. None of the above.
27. **Which ONE of the following methods is acceptable for retarding the polycarboxylate cement reaction during mixing?**
- a. Use a chilled glass slab
  - b. Use chilled components
  - c. Add water to the liquid components
  - d. Decrease the powder-to-liquid ratio
  - e. Use incremental addition of powder to liquid
28. **The setting reaction of IRM dental cement creates which ONE of the following reaction products in the matrix?**
- a. Zinc ethoxybenzoate
  - b. Zinc eugenolate
  - c. Tertiary zinc phosphate
  - d. Zinc polyacrylate gel
  - e. Calcium phosphate

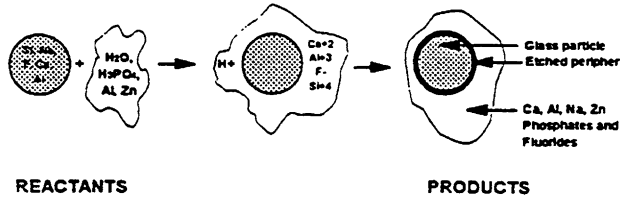
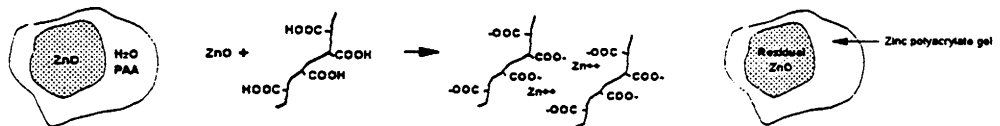
29. **The setting reaction of Fleck's Mizzy dental cement creates which ONE of the following reaction products in the matrix?**
- Zinc ethoxybenzoate
  - Zinc eugenolate
  - Tertiary zinc phosphate
  - Zinc polyacrylate gel
  - Calcium phosphate
30. **Fluoride release from silicate cement involves:**
- Fluoride ion dissolution from particles and diffusion through the matrix
  - Fluoride uptake from saliva and re-release at other times
  - Hydrogen ion substitution from saliva for fluoride ion in the matrix
  - Visible light acceleration of ionization of components in residual powder
  - Precipitation of fluoride by calcium ions in saliva
31. **The setting reaction of Durelon dental cement creates which ONE of the following reaction products in the matrix?**
- Zinc ethoxybenzoate
  - Zinc eugenolate
  - Tertiary zinc phosphate
  - Zinc polyacrylate gel
  - Calcium phosphate
32. **Which one of the following acids have not been copolymerized into PCC liquid?**
- Acrylic acid
  - Maleic acid
  - Itaconic acid
  - Tartaric acid
  - Phthallic acid
33. **Traditional glass ionomer cements are a hybrid of:**
- ZP and PCC
  - SC and SPC
  - ZOE-EBA and SC
  - SC and PCC
  - HV-EBA and ZP
34. **The final reaction product matrix of GI cement is composed of:**
- Ca acrylate gel
  - Al acrylate gel
  - Tertiary zinc phosphate
  - Crystalline zinc ethoxybenzoate
  - BIS-GMA polymer
35. **Fluoride is released from glass ionomer cement by:**
- Saliva reaction with residual glass particles
  - The same mechanism as silicate cement
  - Ion exchange reactions with matrix polymer
  - Secondary chemical reactions of saliva with the matrix
  - Dissolution of fluoroapatite filler particles in the cement



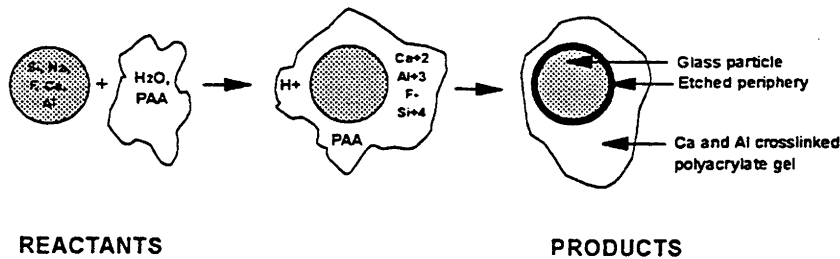
36. **Which one of the following is true of a resin hybrid GI?**
- Higher fluoride release
  - Lower compressive strength than traditional GI
  - Only light cured
  - Increased adhesion to dentin
  - Higher coefficient of thermal expansion
37. **Which ONE of the following is a key example of reinforced ZOE?**
- IRM
  - Fleck's
  - Durelon
  - Geristore
  - Dycal
38. **Which ONE of the following is a key example of PCC?**
- IRM
  - Fleck's
  - Durelon
  - Geristore
  - Dycal
39. **Which ONE of the following is a key example of a resin hybrid GI?**
- IRM
  - Fleck's
  - Durelon
  - Geristore
  - Dycal
40. **Which ONE(S) of the following properties of dental cements is(are) affected by the P/L ratio?**
- Dimensional change on setting
  - Intraoral solubility
  - Compressive strength
  - Thermal conductivity
  - All of the above
41. **Which ONE of the following is the predominant reason for early clinical failure of dental cements?**
- Improper choice of commercially competitive products
  - Improper mixing and/or manipulation of materials
  - Inadequate cement strength
  - Inadequate solubility resistance
  - All of the above

**PROSTHODONTIC REVIEW****Lecture: "Glass Ionomer Cements (Polyalkenoate Cements)"****INTRODUCTION:****A. Historical Development:**

## 1. Hybrid Cement of Silicate and Polycarboxylate:

a. *Silicate Cements*: FLUORIDE RELEASE, Good Estheticsb. *Polycarboxylate Cements*: ADHESION, Bicompatibility

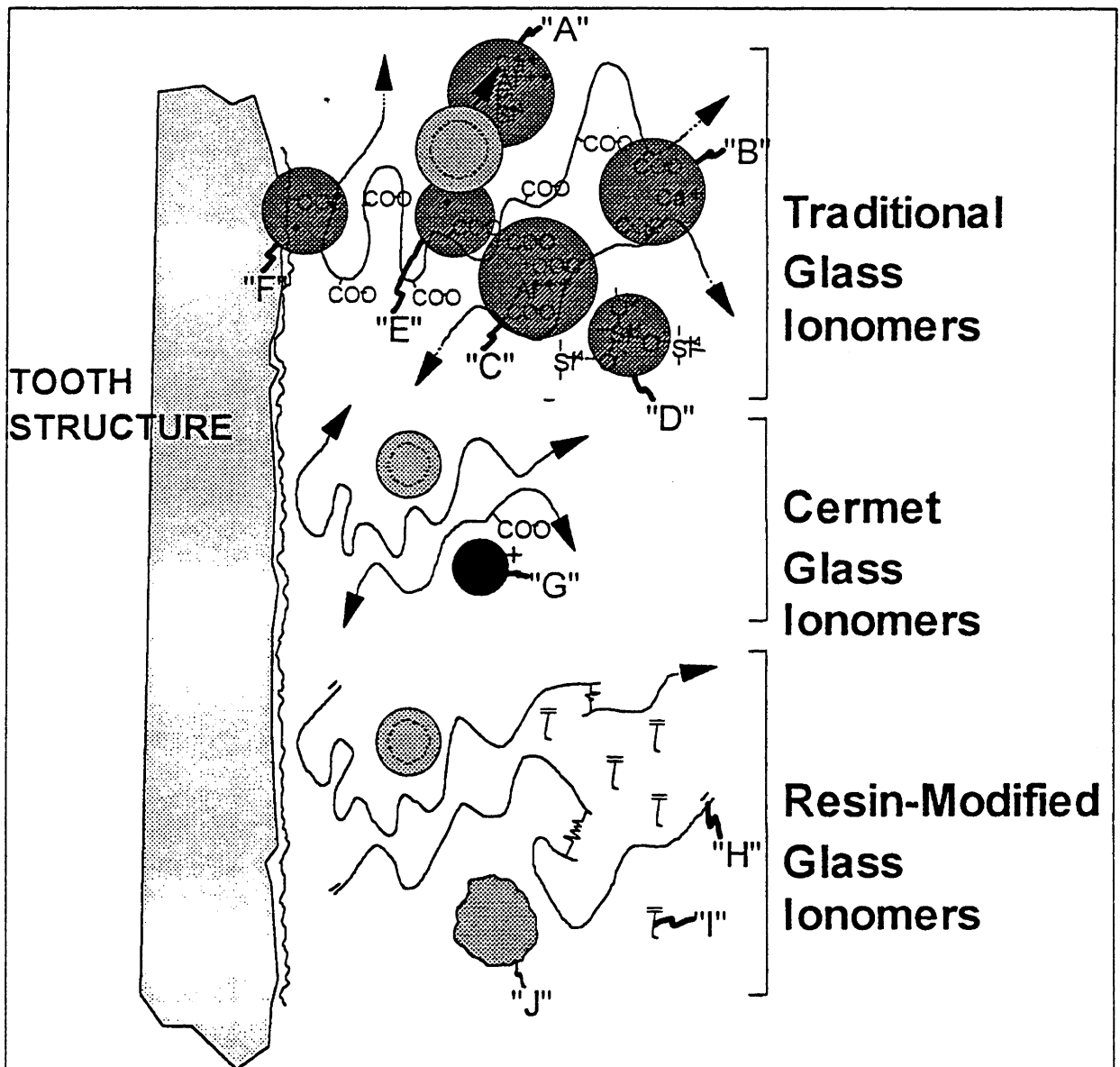
## 2. First Product = ASPA

a. Aluminosilicate POWDER (from Silicate Cement)b. Polyacrylic Acid LIQUID (from Polycarboxylate Cement)**B. Definitions and Terminology:**

1. *Glass ionomer*: glass refers to the glassy ceramic particles and the glassy (non-crystalline) matrix of the set material, while ionomer refers to ion-crosslinked polymer.
2. *Polyalkenoic or Polyalkenoate*: refers to polymer chain which incorporates alkenic monomers such as acrylic, tartaric, maleic etc.
3. *F-Release*: refers to release of fluoride ions but there is no implication as to the source of the ions-- and there are many possibilities. The confusion for current systems is that if the F does not come from the traditional GI matrix then some people say that the system is not a "true" GI but that point is irrelevant.
4. *Multiple-Cure*: refers to multiple curing mechanisms possible with resin-modified systems--the terminology was first introduced in 1992 by 3M for their Vitremer product because it underwent the traditional GI chemical setting reaction, a self-cured polymerization reaction, and a light-cured polymerization reaction.

D. Evolution of Products:

1. Conventional GI:
  - a. Refinements to avoid technique sensitivity (pre-capsulated)
  - b. Liquid Modifications: Itaconic Acid, Maleic Acid, Tartaric Acid
2. Metal-Modified GI:
  - a. Admixed Amalgam Alloy Particles: Ag-Sn Additives,
  - b. Reinforcing Fillers: Ag-Pd Additives,  $TiO_2$
3. Light-Cured GI: Liquid modifications with monomers
4. Resin-Modified GI (Hybrid GI Cements):
  - a. Powder/Liquid Hand Mixed Versions
  - b. Pre-capsulated Auto-Mixed Versions
5. Compomers (Resin-Reinforced GI)
  - a. Powder/Liquid Hand Mixed Versions
  - b. Pre-capsulated Auto-Mixed Versions



**STRUCTURE****A. Chemistry:****1. Continuous Phase:**

Conventional Cement Portion: (Acid Functional Polymer Solution)  
 50 w/o AA-MAA-IA-TA polymer (but principally PAA)  
 50 w/o water  
 Resin-Modified Portion: (LC Monomer, Oligomer, and/or Polymer)

**2. Dispersed Phase:**

Conventional Cement Portion:  
 (Fined ground aluminosilicate glass, F in glass)  
 (Higher Al/Si ratio than silicate cements -- more basic)  
 29.0 w/o SiO<sub>2</sub>                      34.2 w/o CaF<sub>2</sub>  
 16.6 w/o Al<sub>2</sub>O<sub>3</sub>                      7.3 w/o AlF<sub>3</sub>  
 9.9 w/o AlPO<sub>4</sub>                      3.0 w/o NaF  
 Resin-Modified Cements:  
 (May contain CaF<sub>2</sub> powder, polymer, F containing polymer, or precured cement)

**B. Setting Reactions: (2 Rx's for monomer; 2-step Rx for cement portion; Si matrix Rx)****1. Conventional Cement Portion: exothermic; amorphous matrix**

Reaction occurs in stages:  
 Mixing: initial contact of liquid acid and basic powder  
 Working: ion migration from powder by partial dissolution  
 Initial Setting: Ca<sup>+2</sup> ion crosslinked polymer gel  
 Final Setting: Al<sup>+3</sup> ion crosslinked polymer gel  
 (aluminum ions replace the calcium ions over 1-7 days)

**2. Resin-Modified Portion:**

Polymerization of monomer/oligomer reactive groups  
 Self-cured; Light-cured; Dual-cured

**C. Manipulation and Technique Requirements:****1. Conventional Cement as Filling Material**

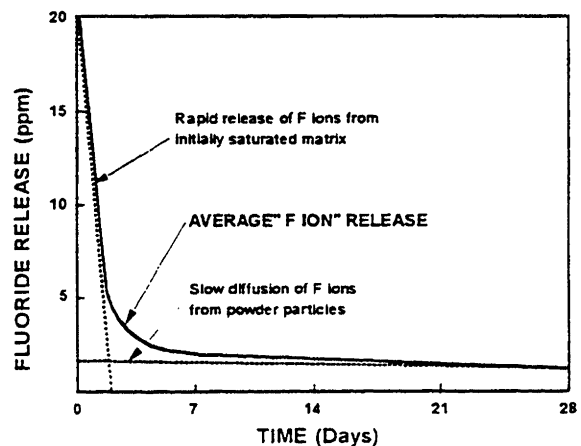
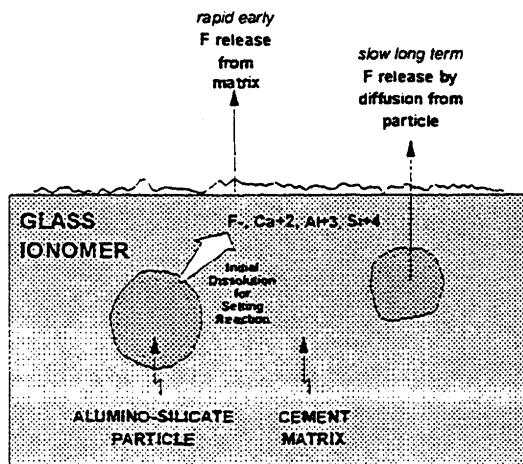
Reaction Control: chilled components  
 Cavity Preparation:  
 Totally isolate preparation  
 Pre-clean enamel and/or dentin with pumice and water  
 Debride enamel and/or dentin with citric acid, PAA, or EDTA  
 Completely dry cavity preparation  
 Dycal recommended for deep preparations  
 Powder and Liquid Mixing: (Manual)  
 Mix in small area using 2 to 3 increments  
 Completely mix in less than 45 seconds  
 Use P/L ratio of 1.0 (cement) or 3.0 (filling, base)  
 Placement and Setting:  
 Avoid water contact  
 Do not use once gloss has disappeared from mixture  
 Protect with matrix during curing  
 Protect surface with water-insoluble varnish for 24 hrs  
 Finishing and Polishing: (FOR FILLING MATERIALS)  
 Do not attempt for 24 hrs  
 Procedures similar to composites (but do not DESICCATE)

**2. Resin-Modified Filling Material**

Reaction Control: LC except will auto-cure in 10-15 minutes  
 Cavity Preparation: SAME AS ABOVE (except use primers)  
 Mixing: SAME AS ABOVE or Pre-Capsulated  
 Placement and Setting: SAME AS ABOVE  
 Finishing and Polishing: Immediate

## PROPERTIES

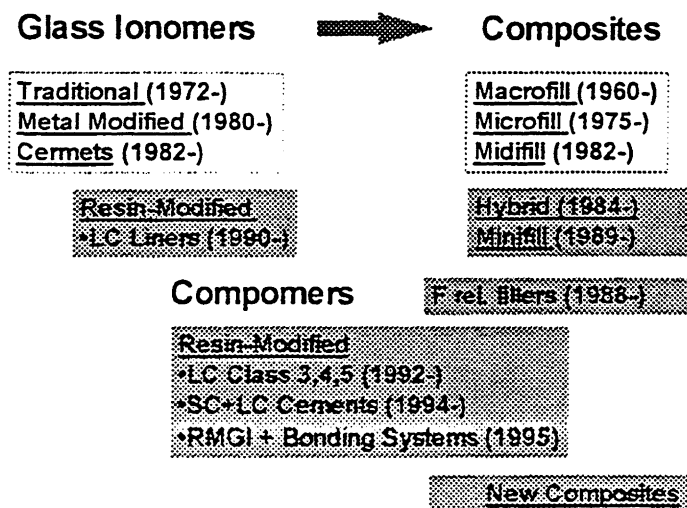
- A. Depend on Applications: (\*= major)
- 1.\* Cement (ADA Type I)
  - 2.\* Liner
  - 3\* Base
  - 4.\* Filling Material - Class III, V, II (ADA Type II)  
Root Caries
  - 5.\* Core for Crown  
Foundations
  6. (Tunnel Preparations)
  7. (Sandwich Prep)
  8. Retrograde Filling Material
  9. (P/F Sealants)
- B. Key Properties (Conventional Materials):
1. Type I: Permanent Cementation (Conventional Materials)
    - a. Low P/L Ratio = 1.00-1.25
    - b. Moderate Strength = 12,500 psi CS (900 psi DTS)
    - c. High Solubility = 1.25%
  2. Type II: Permanent Filling Material (Conventional Materials)
    - a. High P/L Ratio = 2.00-3.00
    - b. High Strength = >20,000 psi CS (400 psi DTS)
    - c. Low Solubility = 0.4%
- C. Clinical Properties:
1. Strength:
    - a. Conventional cement is strongly hydrophilic during first hour
    - b. LC versions are about 2/3rds set immediately
  2. Adhesion: P/L ratio governs balance bonding vs solubility
    - a. Conventional cement chelates enamel and dentin
    - b. Base metal alloys (or zinc or tin plated alloys) can be chelated
  3. Biocompatibility:
    - a. Conventional cement: pulpal irritation from initially high acidity (pH <=3)  
LC Version: Less acidity
    - b. Good biocompatibility from set materials
  4. Fluoride Release:
    - a. Decreases dramatically after 24-72 hrs
    - b. Decreasing release for first month; Low release for 1-6 months
    - c. No clinical studies to demonstrate that imppt product differences



**COMMERCIAL EXAMPLES**

- A. Conventional GI Luting/Basing Cements:
  - 1. ASPA (Caulk/Dentsply) -- No longer available
  - 2. Chembond (Caulk/Dentsply) -- No longer available
  - 3. G-C Fuji I (G-C Chemical) -- Cements
  - 4. G-C Dentin Cement (G-C Chemical) -- Liner
  - 5. Ketac-Fil (ESPE Premier) -- Filling Material
  - 6. Ketac-Cem (ESPE Premier) -- Cements
  - 7. Keta-Bond (ESPE Premier) -- Liners
  - 8. Ziommer Liner (Denmat) -- Liners
  - 9. Ziommer Cement (Denmat) -- Cements
  - 10. Core Ziommer (Denmat) -- Cores
- B. Metal-Modified GI Cement for Filling Materials:
  - 1. Ketac-Silver (ESPE Premier) -- Filling Mtls, Cores
  - 2. Miracle Mixture (G-C Chemical) -- Filling Mtls, Cores
  - 3. Fuji II + Lumi-Alloy (G-C Chemical) -- Filling Mtls, Cores
- C. Light-Cured Resin-Modified GI Cements:
  - 1. Vitrabond (3M) -- Liner
  - 2. Light Cured Ziommer (Denmat) -- Liner
  - 3. Light Cured G-C Dentin Cement (G-C) -- Liner
  - 4. Vitremer Luting Cement (3M) -- Luting Inlays, Crowns, Bridges
  - 5. Fuji Duet (GC) and now Fuji Plus -- Luting Inlays, Crowns, Bridges
  - 6. Advance (LD Caulk) -- Luting Inlays, Crowns, Bridges
- D. Light-Cured Hybrid GI Filling Materials:
  - 1. Fuji II LC (GC America) -- Filling Mtl
  - 2. Geristore (Den-Mat Corporation) -- Filling Mtl
  - 3. Variglass VLC (LD Caulk) -- Filling Mtl
  - 4. Vitremer (3M) -- Filling Mtl
- E. Compomers (Resin-Reinforced GI):
  - 1. Dyract 1.0, 2.0 (LD Caulk) -- Filling Mtl
  - 2. Hytac (ESPE) -- Filling Mtl
  - 3. F2000 (3M) -- Filling Mtl

**CONVERGENCE OF RMGI AND COMPOSITES (COMPOMERS):**



**MULTIPLE CHOICE STUDY QUESTIONS FOR GLASS IONOMERS:**

The **POWDER** component in traditional glass ionomer cement is:

- a. Zinc oxide
- b. Silica
- c. Lithium aluminosilicate
- d. Aluminosilicate glass
- e. Alumina

The **LIQUID** component in traditional glass ionomer cement is:

- a. Polyacrylic acid
- b. Polymethacrylic acid
- c. Polymethyl methacrylate
- d. BIS-GMA polymer
- e. Phosphoric acid

Which one of the following has **NOT** been used as part of the liquid composition?

- a. Acrylic acid
- b. Tartaric acid
- c. Maleic acid
- d. Citric acid
- e. Itaconic acid

Which one of the following has **NOT** been used to modify the powder composition?

- a. Aluminosilicate glass
- b. Alumina
- c. Amalgam alloy particles
- d. Ag-Pd particles
- e.  $\text{TiO}_2$  particles

How is the fluoride released from a set conventional GI cement?

- a. Intraoral fluids dissolve it out of the glass particles.
- b.  $\text{CaF}_2$  salts dissolve and release the fluoride.
- c. Fluoride ions in the matrix are released from the cement.
- d. Sodium fluoride salts release the fluoride.
- e. Acid in the oral environment dissolves the residual glass.

The **initial setting reaction** of a conventional GI cement is produced by:

- a. Release of fluoride ions from the aluminosilicate glass
- b. Crosslinking of polyacrylic acid polymer chains by calcium ions
- c. Crosslinking of polyacrylic acid polymer chains by aluminum ions
- d. Loss of water from the matrix phase
- e. Crystallization of the dissolved salts from the powder particles

The **final setting reaction** of a conventional GI cement is produced by:

- a. Release of fluoride ions from the aluminosilicate glass
- b. Crosslinking of polyacrylic acid polymer chains by calcium ions
- c. Crosslinking of polyacrylic acid polymer chains by aluminum ions
- d. Loss of water from the matrix phase
- e. Crystallization of the dissolved salts from the powder particles

**Chemical adhesion to tooth structure of conventional glass ionomers is produced by:**

- a. Chelation of polyacrylic acid with calcium ions
- b. Chelation of polyacrylic acid with aluminum ions
- c. Reactions of the fluoride ions with hydroxyapatite
- d. Precipitation of calcium phosphate from the dissolved powder
- e. Precipitation of calcium oxide

**Contaminated or overly wet tooth surfaces interfere with the:**

- a. Adaptation of the cement for chemical bonding
- b. Initial setting reaction
- c. Final setting reaction
- d. Release of fluoride ion
- e. Color of the final cement

**Which one of the following is key during the first 24 hours for conventional GI cements?**

- a. Protection against contact with moisture
- b. Protection against intraoral acid contact
- c. Protection from ultraviolet radiation
- d. Protection against salivary protein contact
- e. Protection against fluoride release

**What is the time of maximum fluoride release RATE out of the cement?**

- a. During the first few minutes
- b. During the first 24 hours
- c. During the first month
- d. During the first year
- e. After the first year

**Which one of the following is NOT a major use for glass ionomers?**

- a. Class V filling material
- b. Liner
- c. Base
- d. Cement
- e. Tunnel preparations

**Which application takes best advantage of the chemical adhesion of glass ionomer cements?**

- a. Class V filling material
- b. Liner
- c. Base
- d. Cement
- e. Tunnel preparations

**Which application takes best advantage of the fluoride release of glass ionomer cements?**

- a. Liner
- b. Base
- c. Root caries restorations
- d. Retrograde filling material
- e. Core



**Which one of the following has the most influence on the final mechanical and chemical properties of conventional GI cements?**

- Fluoride content of the aluminosilicate glass
- Mixing technique
- Powder-to-liquid ratio
- Acidity of the mixture
- Reaction exotherm

**What is the mechanism of reinforcement of metal-modified GI cements?**

- Addition of stronger powder particles
- Addition of particles which can be chelated by matrix
- Addition of particles which can dissolve and affect reaction
- Addition of particle that accelerate fluoride release
- Addition of insoluble particles

**What is the major difference between conventional and LC GI cements?**

- LC produces second matrix
- LC version has no cement reaction
- LC versions accelerate release of F from aluminosilicate glass
- LC eliminates all moisture sensitivity of material
- LC version increases adhesion to tooth structure

**Which one of the following best describes a LC GI material?**

- Composite resin with releasable F
- Hybrid of a traditional glass ionomer cement and a composite
- Resin-reinforced glass ionomer cement
- Metal-reinforced glass ionomer cement
- LC method of polymerizing acrylic acid

**Which one of the following is NOT true of LC GI materials?**

- Better mechanical properties than conventional GI cements
- Filling materials can be finished immediately
- Filling materials are less moisture sensitive
- There is less fluoride release than from conventional GI cements
- There is equally good adhesion to tooth structure

**Which one of the following is not part of a "multiple-curing" GI system?**

- Ca<sup>++</sup> ion crosslinking of acid-functional polymer chains
- Al<sup>+++</sup> ion replacement of Ca<sup>++</sup> crosslinking
- Visible light polymerization of matrix monomers into polymer
- Chemical curing of matrix monomers into polymer
- F ion crosslinking of polymer chains

**Which one of the following materials is a conventional glass ionomer?**

- Vitremer cement
- Fuji Duet
- Advance
- Dyract
- Ketac-Cem

**What is the term used for glass ionomers that converge on being composites?**

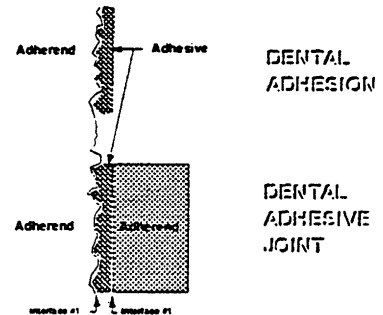
- Hybrid ionomers
- Compomers
- Hybrid composites
- Fluoride releasing composites
- Glass ionomer modified composites

**PROSTHODONTIC REVIEW**  
**Lecture: "Enamel, Dentin, Amalgam, and Composite Cement Bonding"**

**REVIEW OF BONDING SYSTEMS:**

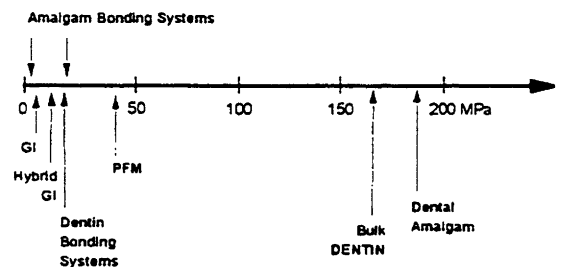
**A. Definitions and Terminology:**

1. Terminology for adhesion:
  - a. Adhesive- material forming the layer
  - b. Adherend- substrate being bonded
2. Adhesive systems:
  - a. Adhesive layer  
(Adherend/ Adhesive)
  - b. Adhesive joint  
(Adherend-1/ Adhesive/ Adherend-2)



<i>Bonding system applications:</i>	<i>Adherend-1:</i>	<i>Adhesive:</i>	<i>Adherend-2:</i>
Sealant	Enamel	Sealant	-----
Surface Sealers	Composite	Sealer	-----
Enamel bonding system	Enamel	EBA	Composite
Dentin bonding system	Dentin	Primer-DBA	Composite
Amalgam bonding system	Enamel/Dentin	ABA	Amalgam
Composite cement	Enamel/Dentin	[[Complex]] Inlays	
Orthodontic bonding system	Enamel	Composite	Bracket
Maryland bridge cement	Enamel	Composite	Metal Alloy
Porcelain veneers	Enamel	Composite	Porcelain
PFM repairs	Metal/Porcelain	Composite	-----
Crown and Bridge	Enamel/Dentin	Composite	Metal or Ceramic

3. Adhesive strength (or bond strength):
  - a. Shear bond strength (SBS) =  
2x tensile bond strength
  - b. Units: MPa (= 145 psi)
  - c. Bond strength = load/area of bond  
 (Enamel bonding = 18-22 MPa)  
 (Dentin bonding = 22-(35) MPa)  
 (Amalgam bonding = 3-22 MPa)



**B. General components of 3-STEP bonding systems:**

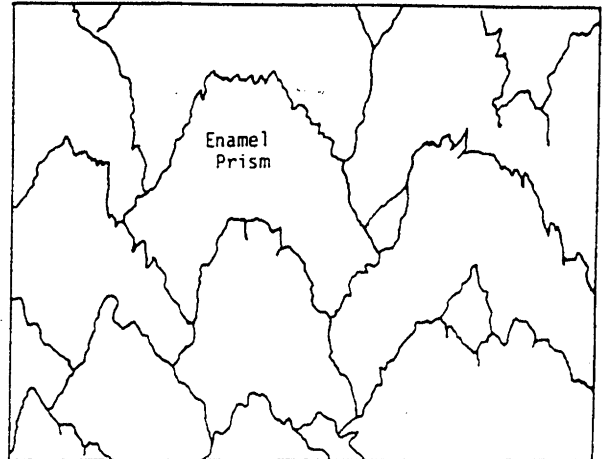
1. Conditioner (clean and/or etch surface for good wetting)
  - (a) Polyacrylic acid, EDTA, Citric acid, Maleic Acid, Pentaerythritol
  - (b) Phosphoric acid
2. Primer (hydrophilic monomers for interpenetration for micro-mechanical and/or chemical bonding)
3. Bonding agent (monomers for reaction with other adherend)

**C. General components of composite luting systems:**

1. Bonding system for tooth (Conditioner, Primer, Bonding Agent)
2. Composite system: Resin-Filler Paste; Self- or Dual-curing; Air-inhibition system
3. Bonding system for restoration (Conditioner, Silanation/Bonding Agent)

**ENAMEL BONDING SYSTEMS:****A. Components:**

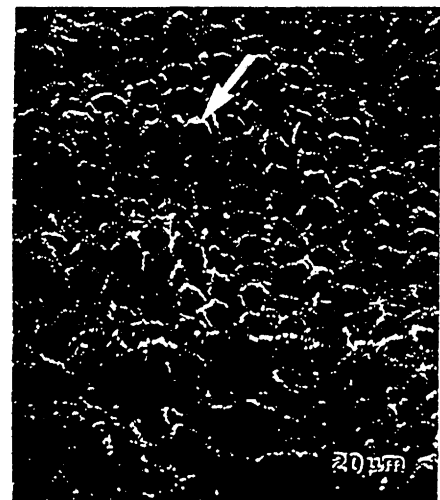
1. Conditioner (etchant):
  - a. 37% phosphoric acid (liquid or gel) – Buonocore, 1957
  - b. (Weaker organic acids such as citric, tartaric, maleic, ...)



2. Bonding agent:
  - a. Main monomer: BIS-GMA or UDMA
  - b. Diluent monomer: TEDGMA
  - c. Fillers: none

**B. Bonding mechanism:**

1. Chemical bonding:
  - a. None
2. Mechanical bonding:
  - a. Micro-mechanical between prisms (Macro-tags)
  - b. Micro-mechanical within prisms (Micro-tags)
3. Bond strength variables:
  - a. Tag length has no significant effect on bond strength
  - b. Moisture interferes with tag formation
  - c. Degree of cure affects bond strength



**DENTIN BONDING SYSTEMS:****A. Historical development:****0. Early Generation DBS's (Bonded to Smear Layer):**

Glycerophosphoric Acid DMA (Buonocore, 1956)  
 TBB grafting of MMA to dentin collagen  
 NPG-GMA coupling agent (Bowen, 1965)  
 Custom adhesives (Brauer, 1977)  
 ClearFil-F (Fusayama, 1979)

**1. First Generation DBS's (Bonded to Smear Layer):**

Scotchbond (3M, 1983)  
 Prisma Universal Bond (Caulk, 1985)  
 Bondlite (Kerr)  
 Creation Bond (Den-Mat)  
 J&J DBA (Johnson & Johnson)  
 Dentin Adhesit (Vivadent)  
 DBA (Lee Pharmaceuticals)  
 ClearFil New Bond (Kuraray/Nakabayashi, 1985)

**2. Second Generation DBS's (Modified/Removed Smear Layer):**

Scotchbond 2 (3M)  
 Mirage Bond (Chameleon Dental)  
 Gluma (Bayer)  
 Tenure (Den-Mat)  
 XR Primer/Bond (Kerr)  
 All-Bond (Bisco)

**3. Third Generation DBS's (Modified/Removed SL; Produced HL):**

All-Bond (No Etch and Total Etch) (Bisco)  
 Scotchbond Multi-Purpose (3M)  
 Prisma Universal Bond 3 (Caulk)  
 Denthesive II (Kulzer)  
 Aelitebond (Bisco)  
 Gluma 2000 (Bayer)  
 Clearfil Bond (Kuraray)

**4. Fourth Generation DBS's (Optimized for SL modification and dentin wetting)**

All-Bond 2 (Bisco)  
 Pro-Bond (Caulk)  
 Opti-Bond (Kerr)  
 Clearfil Liner Bond II (Kuraray)  
 Scotchbond Multi-Purpose Plus (3M)  
 OptiBond FL (Kerr)

**5. Reduced Component Bonding Systems:**

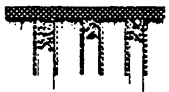Prime&Bond (Caulk)  
 One-Step (Bisco)  
 Tenure-Quik (DenMat)  
 Bond-1 (Jeneric-Pentron)  
 Optibond Solo (Kerr)  
 Single-Bond (3M)

**B. Mechanisms of dentin bonding:**

**SL INTACT**  
 Bond strength limited to SL



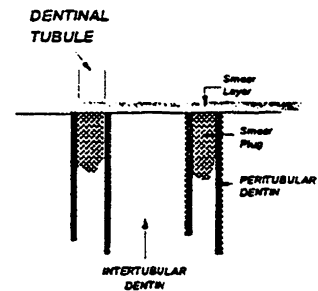
**SL DISSOLVED**  
 Peritubular dentin removed.  
 Weak microtags in tubules.  
 Weak remaining collagen in intertubular dentin.



**SL REMOVED and/or REPLACED**  
 Smear plugs keep tubules closed.  
 Microtags produce some intertubular dentin adhesion.



**SL MODIFIED (or IMPREGNATED)**  
 Smear plugs keep tubules closed.  
 Smear layer impregnated..  
 Microtags produce some intertubular dentin adhesion.  
 Hybrid layer (DBA, smear layer, intertubular collagen).



C1. Hybrid Layer (Interdiffusion Zone, Interpenetration Zone):

Van Meerbeek B, Dhem A, Goret-Nicaise M, Braem M, Lambrechts P, Vanherle G. Comparative SEM and TEM examination of the ultrastructure of the resin-dentin interdiffusion zone. *J Dent Res* 1993; 72: 495-501.

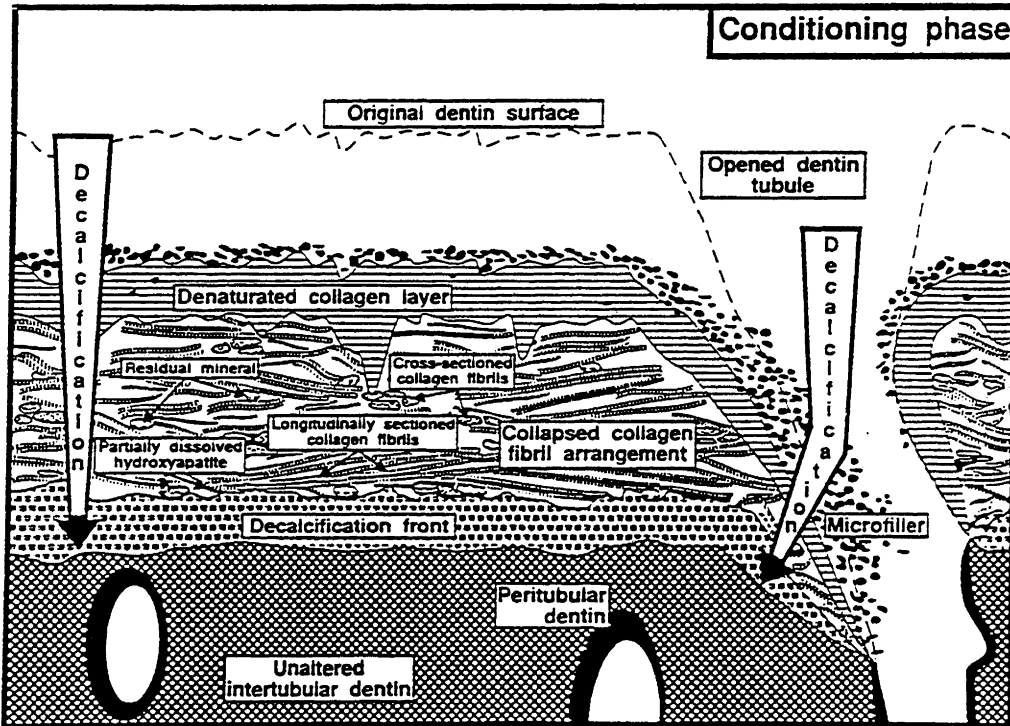


Fig. 5—Schematic representation explaining the ultrastructure of the resin-dentin interdiffusion zone at the conditioning phase.

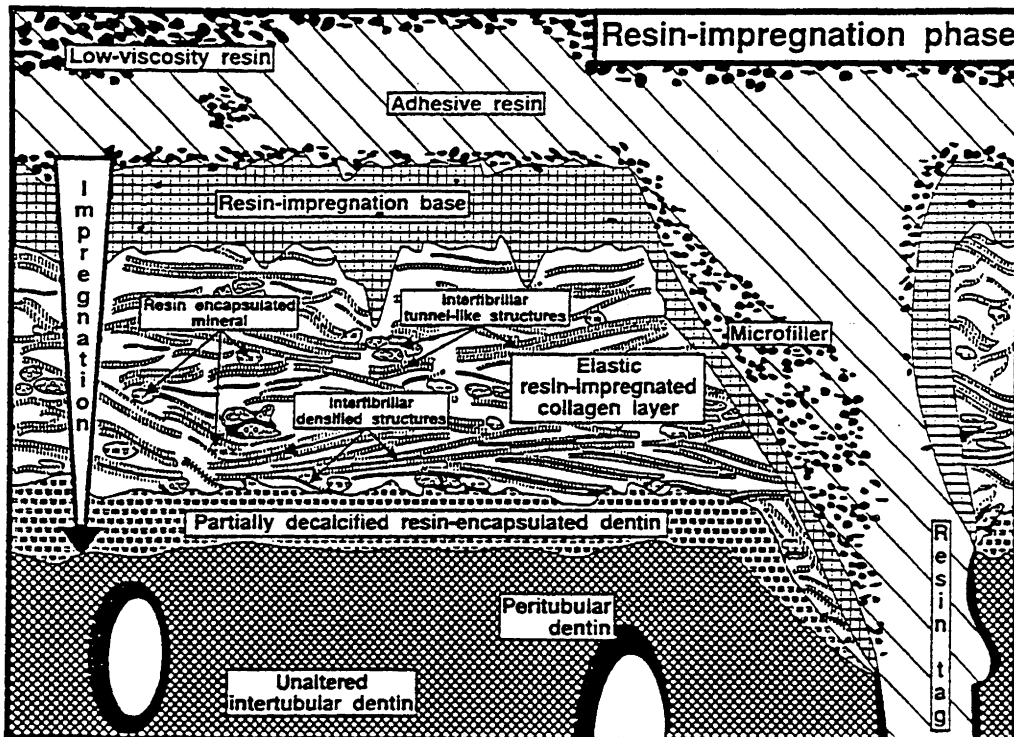
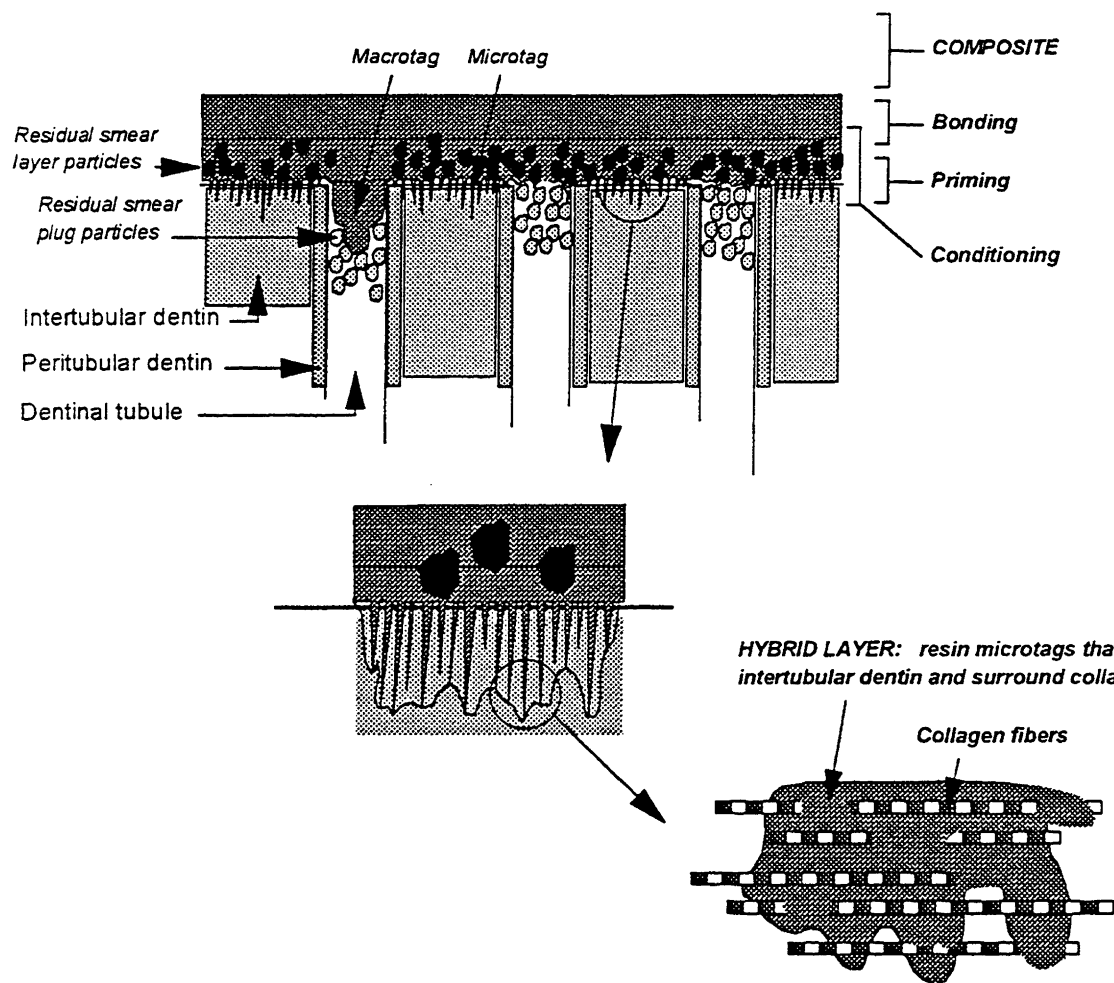


Fig. 6—Schematic representation explaining the ultrastructure of the resin-dentin interdiffusion zone at the resin-impregnation phase.

C2. Hybrid Layer (Interdiffusion Zone, Interpenetration Zone): Bayne



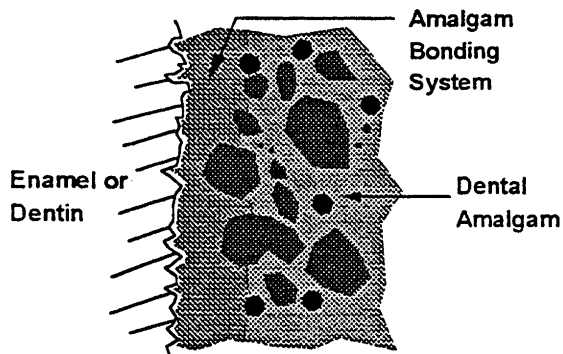
**AMALGAM BONDING SYSTEMS:**

**A. Components:**

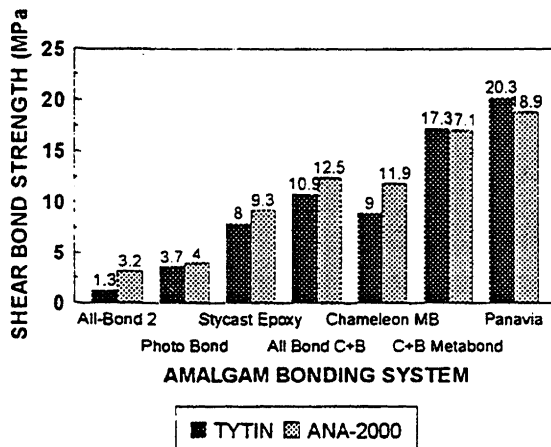
1. Conditioner ( or etchant)
2. Primer
3. Bonding Agent:
  - a. Main Monomer: 4-META, BIS-GMA or UDMA
  - b. Diluent Monomer: TEDGMA
  - c. Fillers: None

**B. Bonding mechanism:**

1. Chemical bonding:
  - a. None
2. Mechanical bonding:
  - a. Enamel and Dentin: Micro-mechanical (macrotags and microtags)
  - b. Amalgam: Micro-mechanical (to alloy particles and amalgam irregularities)



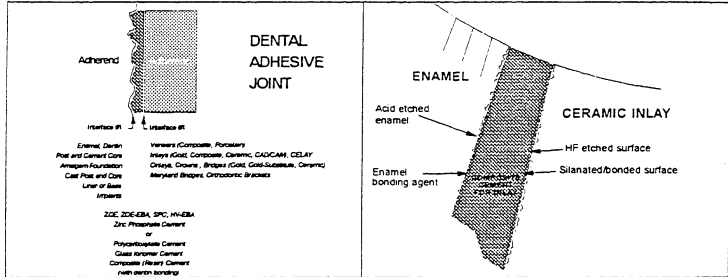
3. Bond strength variables:
  - a. Thickness of amalgam bonding agent layer



**COMPOSITE (CEMENT) BONDING SYSTEMS:**

**A. Bonding mechanisms:**

1. Bonding types:
  - a. Physical (weak and irrelevant)
  - b. Chemical (only involved between BA and composite)
  - c. Mechanical (micro-mechanical is principal bonding)
2. Adhesive Joint Analysis:



**B. Composite (Resin Cement) Bonding Systems:**

1. Metallic Restorations (Bonding System and Luting Composite)

Commercial System:	Manufacturer:	Bonding System	
C&B Metabond	Parkell	None	(4-META)
CR Inlay Cement	J. Morita	Clearfil Photo-Bond	(Phosphate)
Panavia	J. Morita	None	(Phosphonate)
Panavia 21	J. Morita	ED Primer	(Phosphonate)
Resinomer	Bisco	All-Bond 2	(MTG-GMA)
Genstore	Denmat	Tenure	(NTG-GMA, PMDM)
Pent-Core Plus (Cement Kit)	Jenecor/Pentron	Pent-Core Plus	(PCDMA, HEMA)

2. Esthetic Restorations (Bonding System, Luting Composite, Coupling System):

Product	Company	Type of Filler	Release Fluoride	Mixing Required for Dual Cure	Try-in Paste	Number of Shades	Number of Tints & Opacities	Bonding Agent	Viscosity	Compressive Strength/Mpa	Coef. Exp./mm
CHOICE	BISCO	Glass-79%	No	Yes	Yes*	7	3, Stains (sep. kit)	p. d.e (sep. kit)	Medium	220	5.14
COLORLOGIC	CERAMCO	Glass-75%	Yes	Yes	Yes	7	0	d.e.p	Medium	200	4.10
DICOR LAC	DENTSPLY	Glass-56%	Yes	Yes	Yes	4	Sep. kit	d.e	Low	180	5.51
INDIRECT PORCELAIN SYSTEM DENTIST BONDING KIT	3M	Zirconia-20%	No	Yes	Base	6	3, Stains (sep. kit)	p. d.e	Medium	215	4.94
INSURE	COSMEDENT	Glass-75%	No	Yes	Sep. kit	7	6	d.e.p	Medium & low	225	4.44
TIPS EMPRESS (CEM KIT)	IVOCLEAR	Glass-71%	No	Yes	No	7	0	d.e.p	Medium	255	4.06
MIRAGE FLC	CHAMELEON	Glass-72%	Yes	Yes	Base	5	40	d.p	Low	180	14.71
OPTIC	JENECOR/PENTRON	Glass-75%	No	Yes	Base	7	0	d.e.p	Low	245	4.32
PORCELITE DUAL CURE	SYBRON/KEER	Glass-67%	No	Yes	Base	4	1, Stains (sep. kit)	d.e	Low	210	7.17
TRIPHOS	JENKO	Glass-75%	No	Yes	Base	7	0	d.e.p	Medium	210	4.07



**MULTIPLE CHOICE STUDY QUESTIONS for Enamel, Dentin, and Amalgam Bonding:**

1. Which one of the following applications does NOT involve an adhesive joint?
  - a. Enamel bonding system
  - b. Pit-and-fissure sealant
  - c. Dentin bonding system
  - d. Amalgam bonding system
  - e. Composite cement
  
2. What is 1 MPa equal to in the English system of units?
  - a. 145 psi
  - b. 195 psi
  - c. 225 psi
  - d. 445 psi
  - e. 999 psi
  
3. What is the relationship between shear and tensile bond strengths?
  - a. Tensile = 2x Shear
  - b. Shear = 2x Tensile
  - c. Tensile = Shear
  - d. Tensile = 4x Shear
  - e. Shear = 4x Tensile
  
4. What is the typical bond strength range for enamel bonding systems?
  - a. 2-6 MPa
  - b. 6-12 MPa
  - c. 12-18 MPa
  - d. 18-22 MPa
  - e. 22-35 MPa
  
5. What is the typical bond strength range for newer dentin bonding systems?
  - a. 2-6 MPa
  - b. 6-12 MPa
  - c. 12-18 MPa
  - d. 18-22 MPa
  - e. 22-35 MPa
  
6. Which of the following variables is least important for bonding?
  - a. Substrate
  - b. Tooth
  - c. Material
  - d. Patient
  - e. Fluoride history
  
7. Which of the following is not a conditioner?
  - a. Phosphoric acid
  - b. EDTA
  - c. Maleic acid
  - d. Citric acid
  - e. BIS-GMA
  
8. What is the principal mechanism for enamel bonding?
  - a. Physical bonding
  - b. Chemical bonding
  - c. Gross mechanical bonding
  - d. Micro-mechanical bonding

9. **What is the principal mechanical for dentin bonding?**
  - a. Physical bonding
  - b. Chemical bonding
  - c. Gross mechanical bonding
  - d. Micro-mechanical bonding
10. **Which one of the following dentin bonding systems involved smear layer removal?**
  - a. Early systems
  - b. First generation
  - c. Second generation
  - d. Third generation
11. **Which one of the following is most important event for dentin bonding?**
  - a. Smear layer removal
  - b. Smear plug removal
  - c. Peritubular dentin decalcification
  - d. Intertubular dentin decalcification
  - e. Collagen denaturation
12. **What is the hybrid zone?**
  - a. Decalcified peritubular dentin
  - b. Embedded smear layer
  - c. Embedded smear plugs
  - d. Bonding agent/ composite interface
  - e. Embedded smear layer and intertubular dentin
13. **What is the principal monomer in the bonding agent of amalgam bonding systems that is responsible for wetting and promoting micro-mechanical bonding?**
  - a. 4-META
  - b. HEMA
  - c. BIS-GMA
  - d. UDM
  - e. TEGDMA
14. **What is the most important clinical variable affecting amalgam bonding system strength?**
  - a. Conditioning time for enamel
  - b. Bonding agent thickness
  - c. Type of dental amalgam
  - d. Moisture control
  - e. Age of the tooth structure

**MULTIPLE CHOICE STUDY QUESTIONS for Composite Cements:**

1. **Which one of the following is the more appropriate terminology for "resin cements?"**
  - a. Composite resin cements
  - b. Adhesive resin cements
  - c. Adhesive cements
  - d. Composite bonding systems
  - e. Dentin bonding systems
2. **Which one of the following adhesive joints includes chemical bonding?**
  - a. Maryland bridge cement
  - b. Orthodontic bonding system
  - c. Porcelain veneers
  - d. Bonded ceramic crowns

- e. Bonding composites
3. What is the expected shear bond strength for current micro-mechanical bonding?
- 5 MPa
  - 10 MPa
  - 20 MPa
  - 50 MPa
  - 100 MPa
4. What is the principal reason for using a bonding system with a luting material?
- Improved wetting for micro-mechanical bonding
  - Reduced polymerization shrinkage
  - Decreased pulpal sensitivity
  - Improved interfacial esthetics
5. What are the principal actions needed for bonding systems?
- Conditioning, Priming, Bonding
  - Etching, Bonding
  - Conditioning, Priming
  - Priming, Bonding
  - Priming
6. What is the principal mechanism of bonding for composite bonding systems:
- Micro-mechanical
  - Gross mechanical
  - Chemical
  - Physical
  - Physical and chemical
7. Which one of the following is also required to bond non-metallic systems:
- Organic etchants
  - Hydrophobic primers
  - Coupling agents
  - Microfill composite
  - Solvent cleaning procedures
8. Which one of the following is a metallic composite bonding system?
- Dicor LAC
  - Insure
  - C&B Metabond
  - Porcelite Dual Cure
  - Colorlogic
9. Which one of the following is NOT an application for dual-cured resin cements?
- PFM restorations
  - All-ceramic crowns
  - Ceramic inlays
  - Porcelain veneers
  - CAD/CAM inlays
10. What is the function of hydrofluoric acid in composite bonding systems?
- Etching enamel and dentin more quickly
  - Etching porcelain for micro-mechanical bonding
  - Cleaning restorations after try-in
  - Activating composite luting material
  - Removing metal restoration contaminants

**PROSTHODONTICS REVIEW -- Dental Cements and Bonding Systems**  
**Key References****CEMENTS:**

Silvey RG, Myers GE. **Clinical study of dental cements. VII. A study of bridge retainers luted with three different dental cements.** *J Dent Res* 1978 May-Jun; 57(5-6): 703-.

In a clinical study of three luting cements, 547 bridges and 162 crowns were permanently cemented. Patients were recalled at 6-month intervals and the restorations were examined for looseness. A pattern of retainer type, cement type and retainer success was demonstrable.

Silvey RG, Myers GE. **Clinical study of dental cements. VI. A study of zinc phosphate, EBA-reinforced zinc oxide eugenol and polyacrylic acid cements as luting agents in fixed prostheses.** *J Dent Res* 1977 Oct; 56(10): 1215-1218.

A clinical trial for the final cementation of crowns and bridges with a reinforced zinc oxide and eugenol cement, a polyacrylic acid cement and a zinc phosphate cement was made over a 3-year period. The study involved 441 patients for whom 547 bridges and 162 single restorations were cemented. The patients were recalled at 6-month intervals for the duration of the study and the restorations were examined for looseness. Of the 547 bridges 520 remained firmly cemented to the abutment teeth. Of 1,082 bridge retainers, 1,049 remained in position; success and failure by types of retainer will be the subject of a subsequent paper. Of the 162 single restorations 159 remained in place.

Verzijden CW, Creugers NH, Mulder J. **A multi-practice clinical study on posterior resin-bonded bridges: a 2.5-year interim report.** *J Dent Res* 1994 Feb; 73(2): 529-535.

A clinical trial of 201 posterior resin-bonded bridges (PRBBs) was conducted partially in a University clinic and partially in general dental practices, for study of the influence of some experimental variables on the survival of these restorations. This report contains the results of an interim analysis which was done after 2.5 years' follow-up. No significant differences were found among the bonding systems used to adhere the PRBBs (Clearfil F2/etching, Panavia EX/sandblasting, and Microfill Pontic C/silicate-coating), or among the different preparation forms. PRBBs made in general dental practices were as retentive as those made in the University clinic. The location factor was found to be highly significant ( $p = 0.0001$ ). The survival rates were 81% for maxillary PRBBs and 56% for mandibular PRBBs.

Diaz-Arnold AM, Mertz JM, Aquilino SA, Ryther JS, Keller JC. **A comparison of the tensile strength of four prosthodontic adhesives.** *J Prosthodont* 1993 Dec; 2(4): 215-219.

PURPOSE: This study compared the in vitro tensile bond strength of four prosthodontic adhesives to sandblasted base-metal alloy. MATERIALS AND METHODS: Alloy cylinders were bonded end-to-end with the various adhesives, thermocycled, stored for 28 days, and subjected to a tensile load. RESULTS: Mean tensile bond strengths obtained were: Panavia = 42.3 MPa, Metabond = 31.1 MPa, All-Bond = 28.06 MPa, and F21 = 18.5 MPa. Statistical analysis showed significant differences ( $P < .05$ ) in mean bond strengths between the adhesive systems. CONCLUSION: Under the conditions of this study, the Panavia system showed the strongest mean tensile bond strengths.

White SN, Yu Z. **Physical properties of fixed prosthodontic, resin composite luting agents.** *Int J Prosthodont* 1993 Jul-Aug; 6(4): 384-389.

This study determined and compared physical properties of six fixed prosthodontic resin composite luting agents and one control. Inorganic filler content, compressive strength, diametral tensile strength, film thickness, and Knoop hardness were determined. The amounts of filler and the physical properties varied widely among materials. One material, which contained a minimal amount of filler, underwent so much plastic deformation that its strengths could not be measured. All other materials demonstrated high strengths. The materials with the least filler demonstrated the least resistance to indentation. The material with the lowest film thickness had not set at the time of measurement, 10 minutes after mixing. Most materials had unacceptable film thicknesses. Only one material demonstrated acceptable physical properties throughout the study.

Van 't Hof MA. **An analysis of clinical studies on resin-bonded bridges.** *J Dent Res* 1991 Feb; 70(2): 146-149.

Many clinical data on resin-bonded bridges (RBBs) have been published in the last ten years. The survival rates vary widely, and the conclusions are sometimes conflicting. A method of combining the results of different studies in order to draw conclusions about the effectiveness of therapeutic concepts is meta-analysis. The aims of the meta-analysis in this study were: (1) to assess an overall survival ratio for RBBs and (2) to explore relationships between potential success factors and reported survival times. About 60

publications with clinical data on RBBs were reviewed. Following a number of inclusion criteria (information adequate to calculate or assess survival rates, as well as adequate information about the patients, the designs, and types of RBBs), 16 different samples were used for this meta-analysis. A weighted multiple-regression analysis revealed no significant effects of type of retention and location on the survival percentages. Kaplan-Meier estimates were used to assess overall survival in a secondary analysis with the data from all 16 samples (n = 1598). The overall survivals were: one year, 89 +/- 1%; two years, 84 +/- 1%; three years, 80 +/- 1%; and four years, 74 +/- 2%.

**Gates WD, Diaz-Arnold AM, Aquilino SA, Ryther JS. Comparison of the adhesive strength of a BIS-GMA cement to tin-plated and non-tin-plated alloys. J Prosthet Dent 1993 Jan; 69(1): 12-16.**

This study compared the tensile bond strengths of two base metal alloys and two noble metal alloys, tin-plated and non-tin-plated, with an adhesive resinous cement. Two tin platers were compared for their effectiveness in enhancing the composite resin-to-metal bond. Cylinders of the alloys were bonded end to end with the adhesive cement, thermocycled for 24 hours, stored in distilled water for 27 days, and tested for tensile bond strength. The mean bond strengths and mode of failure were recorded, and scanning electron micrographs were recorded for subjective evaluation. Significant differences were demonstrated between the non-tin-plated and the tin-plated noble alloys and base metal alloys.

**Hansson O, Moberg LE. Evaluation of three silicoating methods for resin-bonded prostheses. Scand J Dent Res 1993 Aug; 101(4): 243-251.**

Three different methods of increasing the bond strength of resin to metal were tested: the original Silicoater technique, the Silicoater MD technique, and the Rocatec system. Metals used for the resin-bonded prostheses were gold, a cobalt-chromium (Co-Cr) alloy, and titanium. Silicoating increased the bond strength to sandblasted specimens. The original Silicoater technique produced the highest bond strengths, especially when used with the Co-Cr alloy and titanium. The Silicoater MD technique showed the lowest bond strengths for all of the test metals. Storage for 7 days with protective film on the silicoated surface did not affect the bond strength, as compared with specimens bonded immediately. The retention of the resin to the gold specimens (Rocatec system) decreased after thermocycling, but retention to the Co-Cr alloy and titanium was not affected. Various resin cements were tested and showed the same retention with the exception of Microfill Pontic, which gave a weaker bond. Scanning electron microscope (SEM) and energy-dispersive X-ray analysis (EDAX) of the specimens before and after the measurements gave no clear explanation of the differences in bond strengths between the test metals. However, it was concluded that silicoating of the metal surfaces contributed to the retention of the resin by chemical action, as no differences in adaptation of the resin to the metal were seen between specimens pretreated by sandblasting and those which were also silicoated.

**Imbery TA, Burgess JO, Naylor WP. Tensile strength of three resin cements following two alloy surface treatments. Int J Prosthodont 1992 Jan-Feb; 5(1): 59-67.**

Retainers for composite retained prostheses (Maryland bridges) have traditionally relied upon an etched base metal alloy for micromechanical retention. This study compared the tensile bond strength of three resin cements using two alloy surface treatments. Rexillum III and Olympia disks were cast, oxidized, and given simulated porcelain firings. Paired specimens were cemented with Comspan, Panavia EX, or C & B Metabond after air abrasion with aluminum oxide or silicoating. Air-abraded Olympia disks were tin plated prior to luting with Panavia EX. Electrolytically etched Rexillum III specimens luted with Comspan served as controls. Specimens were thermocycled and tested in tension. Highest tensile bond strengths were achieved with: (1) Olympia specimens, where the bonding surface was air abraded but tin plated before cementation with Panavia EX, and (2) Rexillum III specimens, where the bonding surface was air abraded or silicoated and the disks were cemented with C & B Metabond.

**Kern M, Thompson VP. Sandblasting and silica-coating of dental alloys: volume loss, morphology and changes in the surface composition. Dent Mater 1993 May; 9(3): 151-161.**

Silica-coating alloys improves chemo-mechanical bonding. Sandblasting is recommended as pretreatment to thermal silica-coating or as part of a tribochemical silica-coating process. This study evaluated the effects of sandblasting and coating techniques on volume loss, surface morphology and compositional changes in noble (AuAgCu) and base alloys (NiCr and CoCr). Volume loss was statistically significantly higher in the noble as compared to the base alloys but does not seem to be critical for the clinical fit of restorations. Embedded alumina particles were found in all alloys after sandblasting and the alumina content increased to a range of 14 to 37 wt% as measured by EDS. Following tribochemical silica-coating, a layer of small silica particles remained on the surface, increasing the silica content to between 12 and 20 wt%. Ultrasonic cleaning removed loose alumina or silica particles from the surface, resulting in only slight decreases in alumina or silica contents, thus suggesting firm attachment of the major part of alumina and silica to the alloy surface. Clinically, ultrasonic cleaning of sandblasted and tribochemically silica-coated alloys might improve resin bonding as loose surface particles are removed without relevant changes in

composition. Silica content following thermal silica-coating treatment increased only slightly from the sandblasted specimen. The silica layer employed by these silica-coating methods differs widely in both morphology and thickness. These results provide a basis for explanation of adhesive failure modes in bond strength tests which will possibly optimize resin bonding. Further research is needed to characterize the outermost surface layers after these treatments and the exact location of adhesive failures.

**Kern M, Thompson VP. Sandblasting and silica coating of a glass-infiltrated alumina ceramic: volume loss, morphology, and changes in the surface composition. J Prosthet Dent 1994 May; 71(5): 453-461.**

Silica coating can improve bonding of resin to glass-infiltrated aluminum oxide ceramic (In-Ceram), and sandblasting is a pretreatment to thermal silica coating (Silicoater MD system) or a tribochemical coating process (Rocatec system). This study evaluated the effects of sandblasting and coating techniques on volume loss, surface morphology, and surface composition of In-Ceram ceramic. Volume loss through sandblasting was 36 times less for In-Ceram ceramic compared with a feldspathic glass ceramic (IPS-Empress), and sandblasting of In-Ceram ceramic did not change its surface composition. After tribochemical coating with the Rocatec system, a layer of small silica particles remained that elevated the silica content to 19.7 weight percentage (energy-dispersive spectroscopy). Ultrasonic cleaning removed loose silica particles from the surface and decreased the silica content to 15.8 weight percentage, which suggested firm attachment of most of the silica layer to the surface. After treatment with the Silicoater MD system, the silica content increased only slightly from that of the sandblasted specimen. The silica layer created by these systems differs greatly in both morphology and thickness, which could result in different bond strengths. Sandblasting of all ceramic clinical restorations with feldspathic glass materials should be avoided, but for In-Ceram ceramic the volume loss was within an acceptable range and similar to that of noble metals.

**Suliman AH, Swift EJ Jr, Perdigao J. Effects of surface treatment and bonding agents on bond strength of composite resin to porcelain. J Prosthet Dent 1993 Aug; 70(2): 118-120.**

This study evaluated porcelain repair by use of various surface treatments and hydrophilic bonding resins. The surface treatments were air abrasion (sandblasting), roughening with a diamond, etching with 9.6% hydrofluoric acid, and a combination of the latter two methods. A silane coupling agent was applied to all porcelain surfaces, and composite resin was bonded to porcelain with All-Bond 2, Amalgambond, or Clearfil Porcelain bonding agents. Shear bond strengths were determined on a universal testing machine. The most effective surface treatment was the combination of diamond roughening and hydrofluoric acid etching, but it was not significantly better than the other methods. The Clearfil Porcelain Bond system showed a greater repair strength than the other two materials but was statistically different only from Amalgambond resin.

**Creugers NH, De Kanter RJ, van 't Hof MA. Long-term survival data from a clinical trial on resin-bonded bridges. J Dent 1997 May;25(3-4):239-242.**

**OBJECTIVES:** A clinical trial, involving 203 resin-bonded bridges (RBBs) was undertaken to investigate the influence of retainer-type and luting material on the survival of these restorations. **METHODS:** For this evaluation, 157 patients were available (14% of the original sample was lost to follow-up or excluded from the study following the stopping criteria). Fifty per cent of the patients were questioned concerning the fate of the RBBs and 59% of questioned patients were examined clinically. The patients that were seen for examination were representatives of the experimental groups. The findings from the clinical examination were compared with the data obtained from the questionnaire. Missing data were censored at the date of the last available information. Kaplan-Meier estimates were calculated to assess the survivals at the endpoints and compared using Cox's proportional hazards procedure. **RESULTS:** A significant difference was found between perforated (P-type) and etched (E-type) RBBs ( $P = 0.05$ ) for original bonded restorations but not when rebonded RBBs were taken into account. The results of the survival analysis were: anterior P-type, 49 +/- 7% after 10.5 years; anterior E-type, 57 +/- 7% after 10.5 years; posterior P-type, 18 +/- 11% after 6.8 years; posterior E-type, 37 +/- 13% after 10.2 years. Survivals of RBBs that were rebonded once during the evaluation period were 62 +/- 9% (11.0 years) for anterior RBBs and 51 +/- 11% (10.2 years) for posterior RBBs. **CONCLUSIONS:** The factor location (anterior versus posterior) was as in previous analyses, highly significant. Differences in survival between cementation materials were not significant.

**Groten M, Probst L. The influence of different cementation modes on the fracture resistance of feldspathic ceramic crowns. Int J Prosthodont 1997 Mar;10(2):169-177.**

One hundred twenty pressed feldspathic ceramic crowns were luted to 20 steel dies using six different cementation modes. Fracture resistance was tested under an angle of 45 degrees and was determined as the maximal fracture load. Crowns were tested with luting agent only (groups A and C) and after etching with hydrofluoric acid, silanating, and the application of a bonding agent (groups B, D, E, and F). The resulting means were: phosphate cement 294.3 (A) and 282.2 (B); glass-ionomer cement 217.2 (C) and 255.4 (D); resin composite 382.2 (E) and 687.6 (F). Statistical analysis revealed significantly greater fracture resistance ( $P < .01$ ) of resin luted crowns. Bonding to the die almost doubled the fracture resistance. Conditioning of the inner surfaces of the crowns did not improve the fracture resistance of crowns luted using zinc phosphate or glass-ionomer cements.

**Paul SJ, Scharer P. Effect of provisional cements on the bond strength of various adhesive bonding systems on dentine. *J Oral Rehabil* 1997 Jan;24(1):8-14.**

Temporization of prepared teeth is needed for protection of the pulp and the restoration of the patients' aesthetic and functional needs. When zinc-oxyphosphate cement is used, eugenol-containing provisional cements are preferred because of their sedative effect to the pulp and because of their acceptable compressive strength. However, prior to definitive adhesive cementation with composite luting resins and dentine bonding agents the use of eugenol-containing provisional cements has to be considered critical because eugenol severely disturbs the polymerization of resinous materials. The purpose of this study was to compare shear bond strength values of various adhesive luting systems on dentine which had been in contact with various provisional cements prior to dentine bonding. The results show that the provisional cements which were used considerably decreased some of the bond strength values of the dentine bonding systems tested. Freegenol and Fermit, however, seem to have beneficial effects on the SBS values of Syntac and ART Bond. The only bonding system which produces acceptably high average SBS values with a eugenol-containing provisional cement was P-Bond.

**Sorensen JA, Munksgaard EC. Relative gap formation of resin-cemented ceramic inlays and dentin bonding agents. *J Prosthet Dent* 1996 Oct;76(4):374-378.**

The effect of dentin bonding agents (DBAs) on contraction gap formation at the cavity floor of resin-cemented ceramic inlays was investigated. Cylindrical dentin cavities were pretreated with one of 12 DBAs before luting of ceramic inlays with a dual-curing resin cement. Measurements of cross sections revealed that mean gap widths were reduced between 21% and 80% compared with control specimens prepared without a DBA. The extent of the gap reduction depended on the type of bonding agent. None of the dentin bonding agents tested were able to completely eliminate development of interfacial gaps.

**Jokstad A, Mjor IA. Ten years' clinical evaluation of three luting cements. *J Dent* 1996 Sep;24(5):309-315.**

**OBJECTIVE:** The aim of the present clinical longitudinal study was to observe, over 10 years, the prognosis of abutment teeth restored with fixed prostheses retained by glass ionomer luting cements and one conventional zinc phosphate cement. **METHODS:** Three dentists prepared 135 abutment teeth in 61 patients to retain 81 fixed prostheses. The prostheses were retained by two glass ionomer luting cements (Ketac-Cem, Fuji Ionomer), or a conventional zinc phosphate cement (De Trey Zinc Zement Improved). The patients were examined yearly for 10 years. **RESULTS:** Post-operative hypersensitivity occurred in five teeth restored with glass ionomer luting cement. The prevailing reason for abutment tooth failure was secondary caries ( $n = 21$ ) and pulp necrosis ( $n = 5$ ). Non-parametric survival estimates indicated that 80-85% of the abutment teeth remained intact after 5 years and 71-81% after 10 years. **CONCLUSIONS:** The 10-year results indicate that the prognosis of abutment teeth restored with fixed prostheses is good, regardless of whether a glass ionomer or a zinc phosphate luting cement is used.

**BONDING:**

Davidson CL, Abdalla AI, De Gee AJ. **An investigation into the quality of dentine bonding systems for accomplishing a durable bond.** *J Oral Rehabil* 1993 May; 20(3): 291-300.

For a wide variety of dentine bonding systems the bond strength before and after thermocycling was determined on dentine with and without hydraulic tubular pressure. The importance of the hydrophilic nature of several bonding systems could be demonstrated. The dentine smear layer could not prevent a negative effect of water in the tubulus on hydrophobic systems. Removal of the smear layer had a positive effect on the durability of the bond. When loaded until fracture, some bonding systems resisted adhesive failure.

Nakabayashi N, Ashizawa M, Nakamura M. **Identification of a resin-dentin hybrid layer in vital human dentin created in vivo: durable bonding to vital dentin.** *Quintessence Int* 1992 Feb; 23(2): 135-141.

The present study investigated the bond of 5% 4-methacryloxyethyl trimellitate anhydride in methyl methacrylate, initiated by partially oxidized tri-n-butyl borane in the presence of poly(methyl methacrylate) powder, to vital human dentin. In vivo dentinal substrates were pretreated for 10 or 30 seconds with an aqueous solution of 10% citric acid and 3% ferric chloride. Transmission electron microscopic examination of the bonded cross sections revealed the formation of a transitional, or hybrid, layer of resin-reinforced dentin created by the impregnation, co-mingling and envelopment of collagen bundles, and encapsulation of hydroxylapatite crystals. The in vivo adhesion was assumed to be durable, because results of microscopic examinations were comparable to those of durable bonding of the same resin to extracted bovine dentin. Vital dentin exhibited greater resistance to demineralization by the acid solution than do extracted teeth. Carious extracted teeth were more easily dissolved in acid than were noncarious extracted teeth.

Nakabayashi N, Watanabe A, Gendusa NJ. **Dentin adhesion of modified 4-META/MMA-TBB resin: function of HEMA.** *Dent Mater* 1992 Jul; 8(4): 259-264.

This study investigated adhesion to dentin of a modified 4-META/MMA-TBB resin (4-methacryloxyethyl trimellitate anhydride in methyl methacrylate initiated by tri-n-butyl borane) which does not require PMMA powder to polymerize. Ground bovine dentin specimens were pre-treated with an aqueous solution of 10% citric acid and 3% ferric chloride (10-3). This solution removes the smear layer and demineralizes the dentin, exposing collagen. Improved bond strengths were obtained when a HEMA-primer was applied to 10-3 pre-treated dentin. SEM examination revealed the formation of a transitional zone of resin-reinforced-dentin (hybrid layer) in 10-3 pre-treated, HEMA-primed samples. The adhesive monomer impregnated exposed collagen fibrils and, upon polymerization, became entangled with them to create the hybrid layer, essential in achieving significantly high tensile bonding strengths. HEMA enhanced the penetration capability of dentinal substrates. After polymerization and formation of the hybrid layer, auto-cured acrylic resin, photo-cured composite and amalgam were all capable of adhering to the dentin. The modified 4-META/MMA-TBB resin created significant adhesive bonds to 10-3 pre-treated ground bovine dentin.

Nakabayashi N, Nakamura M, Yasuda N. **Hybrid layer as a dentin-bonding mechanism.** *J Esthet Dent* 1991 Jul-Aug; 3(4): 133-138.

A number of mechanisms (both mechanical and chemical) have been proposed as the cause of dentin adhesion. Extensive research in Japan during the past 10 years has shown that strong, long-lived bonds between resin and living dentin will form when a monomer such as 4-META, which contains both hydrophilic and hydrophobic chemical groups, penetrates the tissue and polymerizes in situ. This resin-impregnation creates a transitional hybrid layer, that is neither resin nor tooth, but a hybrid of the two. The thin layer of resin-reinforced dentin locks the two dissimilar substances together on a molecular level, sealing the surface against leakage and imparting a high degree of acid resistance.

Eick JD, Robinson SJ, Chappell RP, Cobb CM, Spencer P. **The dentinal surface: its influence on dentinal adhesion. Part III.** *Quintessence Int* 1993 Aug; 24(8): 571-582.

This final paper in a series of three uses transmission and scanning electron microscopy to compare the category III dentinal adhesive systems--those with shear bond strength values near or exceeding 17 MPa. Contemporary commercial dentinal adhesive systems such as Superbond and Scotchbond Multi-Purpose, chosen for their varied chemical pretreatments, are contrasted; a contemporary commercial system (Prisma Universal Bond 3) with characteristics of category I and II dentinal adhesives is also included for comparison. The shear bond strength values attained with most category III systems are high enough to cause cohesive failure of the dentin during bond strength testing. This result is attributed to a combination of factors that include effective wetting and penetration of the prepared dentinal surface as well as a tendency to leave collagen fibers at the adhesive-dentin interface in an apparently structurally intact state.



Spencer P, Byerley TJ, Eick JD, Witt JD. **Chemical characterization of the dentin/adhesive interface by Fourier transform infrared photoacoustic spectroscopy.** *Dent Mater* 1992 Jan; 8(1): 10-15.

Irreversible bonding of composite materials to tooth structure depends on chemical as well as mechanical adhesion. The proposed bonding mechanism for several commercial dental adhesives is chemical adhesion to the dentin surface. The purpose of this in vitro investigation was to characterize the chemical nature of the surface interaction between dentin and two commercial adhesives by use of Fourier transform infrared photoacoustic spectroscopy (FTIR/PAS). The occlusal thirds of the crowns of freshly extracted, non-carious, unerupted human molars were sectioned perpendicular to the long axis. Dentin disks, 6 mm x 2 mm, were prepared from these sectioned teeth. The exposed dentin surface was treated with either Scotchbond 2, a BIS-GMA resin, or Dentin-Adhesit, a polyurethane resin. All spectra were recorded from 4000 to 400 cm<sup>-1</sup> by use of an Analect RFX-65 FTIR spectrometer equipped with an MTEC Photoacoustics Model 200 photoacoustic cell. An initial spectrum of the dentin surface was collected. This surface was primed according to manufacturer's instructions and spectra recorded of the primed surface plus one to three layers of adhesive. By comparison of these spectra, it was possible for us to record changes in the phosphate and amide I and II bands due to surface interactions between the adhesive and the dentin. Although early results do not indicate covalent bonding between the dentin and these adhesives, this technique presents several advantages for spectroscopic evaluation of the dentin/adhesive interface.

Eick JD, Robinson SJ, Cobb CM, Chappell RP, Spencer P. **The dentinal surface: its influence on dentinal adhesion. 2.** *Quintessence Int* 1992 Jan; 23(1): 43-51.

The first paper in this series presented a categorization of dentinal adhesive systems that was organized roughly according to chronology, chemistry, and shear bond strength values. Category I dentinal adhesives demonstrate the lowest shear bond strength values, approximately 5 to 7 MPa. Category II dentinal adhesives, including experimental ferric and aluminum oxalate pretreatments and two commercial products, demonstrate shear bond strength values between 8 and 14 MPa. This second category of dentinal adhesives is the subject of this paper. An attempt is made to draw a parallel between the penetrative ability of the adhesive (the wettability of the dentinal substrate) and the efficacy of the adhesive bond as determined by shear bond strength values. Category III dentinal adhesives will be discussed in another paper.

Pashley DH. **Dentin permeability and dentin sensitivity.** *Proc Finn Dent Soc* 1992; 88 Suppl 1: 31-37.

The hydrodynamic theory of dentin sensitivity is based on the premise that sensitive dentin is permeable throughout the length of the tubules. Such a condition may permit the diffusion of bacterial products across dentin to the pulp where they may cause irritation of pulpal soft tissues. However, the slow outward movement of dentinal fluid tends to flush the tubules free of exogenous substances. This balance between the inward diffusion of exogenous substances, whether bacterial or the active ingredients in desensitizing medicaments, and the cleansing action of dentinal fluid flow needs to be examined experimentally.

Perdigao J, Swift EJ, Cloe BC. **Effects of etchants, surface moisture, and resin composite on dentin bond strengths.** *Am J Dent* 1993 Apr; 6(2): 61-64.

This in vitro study evaluated the effects of etchant type, surface moisture, and resin composite type on the shear bond strength of dentin adhesives. Three adhesives which bond to etched dentin were used in the study: All-Bond 2, Amalgambond, and Clearfil Photo Bond. Occlusal enamel was removed from 200 human molars to expose dentin. The dentin surfaces were etched, treated with a dentin adhesive system, and bonded with resin composite. After thermocycling and storage, the composite columns were fractured from dentin using an Instron machine. Bond strengths were calculated and subjected to a statistical analysis. Etchant type, surface moisture, and resin composite type all had significant effects on dentin bond strengths. Overall, the highest bond strengths were obtained with 10/3 etchant, moist dentin, and hybrid composite. The highest bond strengths for All-Bond 2 and Amalgambond were obtained by using the manufacturer's recommended etchant, moist dentin, and a hybrid composite. The mean bond strengths for All-Bond and Amalgambond under these conditions were 22.5 and 19.0 MPa, respectively. Clearfil Photo Bond had significantly lower bond strengths, but was relatively unaffected by changes in experimental conditions.

Xie J, Powers JM, McGuckin RS. **In vitro bond strength of two adhesives to enamel and dentin under normal and contaminated conditions.** *Dent Mater* 1993 Sept; 9: 295-299.

In vitro bond strengths of human enamel and dentin treated with five contaminants were measured with air, water, and damp conditions as controls. Two commercial bonding agents (a lower-viscosity, solvent-containing type, AB, and a higher-viscosity, hydrophilic monomer type, SB) and their composites were applied to tooth structure under two conditions (contaminated and re-etched). Samples were debonded in tension after 24 hr using an inverted, truncated cone test. Among the controls, the highest bond strengths

were obtained with damp conditions for AB (24 MPa) and damp conditions or air for SB (22 MPa) with small differences between enamel and dentin. Most contaminants lowered the bond strength. Re-etching without additional mechanical preparation resulted in bond strengths similar to controls. Bond strengths to tooth structure with the bonding agents tested may be less sensitive to common forms for contamination than typically assumed.

*Van Meerbeek B, Dhem A, Goret-Nicaise M, Braem M, Lambrechts P, VanHerle G. Comparative SEM and TEM examination of the ultrastructure of the resin-dentin interdiffusion zone. J Dent Res 1993 Feb; 72(2): 495-501.*

The resin-dentin interdiffusion zone produced by a dentin-adhesive system that removes the smear layer and concurrently decalcifies superficial dentin was morphologically examined by both scanning and transmission electron microscopy. Cross-sectioned resin-bonded dentin discs were etched with an argon-ion beam to make the resin-dentin interface observable by SEM. For the TEM examination, the sections were partly decalcified by an aqueous EDTA solution to facilitate ultramicrotomy and to disclose the ultrastructure of the interdiffusion zone. Both SEM and TEM confirmed the presence of the resin-dentin interdiffusion zone as the junction between the deep unaltered dentin structure and the restorative resin. Within the interdiffusion zone, three sublayers with characteristic ultrastructure and staining were identified by TEM. An upper diffuse black layer contained few structural features. Underneath, partially-altered collagen fibrils were closely packed, mostly running parallel with the interface and perpendicular to the dentinal tubules. Their outline was electron-dense, forming tunnel-like structures. At the base of the upper layer, several stained projections were found to bulge out into the underlying collagen network and appeared to be confined by obstructive, parallel-running collagen fibrils. Finally, the third dense layer, containing hydroxyapatite crystals, demarcated the superficially demineralized dentin layer from the deeper unaltered dentin. Resin diffusion into the decalcified dentin surface layer was evident, but diminished with depth, presumably reducing deeper resin impregnation into the interfibrillar spaces. The citric acid dentin-pretreatment probably caused denaturation of the superficial collagen fibrils. Its decalcifying effect gradually weakened with depth, leaving behind hydroxyapatite crystals at the base of the interdiffusion zone.

*Van Meerbeek B, Inokoshi S, Braem M, Lambrechts P, Vanherle G. Morphological aspects of the resin-dentin interdiffusion zone with different dentin adhesive systems. J Dent Res 1992 Aug; 71(8): 1530-1540.*

Cross-sections of resin-dentin interfaces were etched with an argon-ion beam to make their substructure detectable by scanning electron microscopy. The dentin adhesive systems were categorized morphologically into three groups, and an attempt was made to clarify their adhesive mechanism. The first group of products removed the smear layer. The argon-ion bombardment clearly disclosed a hybrid or resin-impregnated dentin layer. It is hypothesized that conditioning with acidic or chelating agents demineralized the dentin surface-layer to a certain depth, leaving behind a collagen-rich mesh-work. Hydrophilic monomers are then believed to alter this collagen-fiber arrangement in a way that facilitates penetration of the adhesive resin, resulting in a mechanical, intermingled link between collagen and the adhesive resin. The second group preserved the smear layer. In this case, the dentinal tubules were obliterated with globular particles at their orifices and remained patent underneath these smear plugs. This type of adhesive system aims at the incorporation of the smear layer into the hydrophilic monomers, which have an affinity for the organic and/or inorganic components of the underlying dentin. Finally, a third, small group only partly dissolved the smear layer, creating a thin resin-impregnated dentin layer and a resin-impregnated smear plug. This study clearly showed that the application of recent adhesive systems induced structural changes in the dentin surface morphology, creating a retentive interface, called the inter-diffusion zone, between the deep, untouched dentin layers and the composite filling material. This resin-dentin interdiffusion zone offers bonding sites for copolymerization with the resin composite and, concurrently, might have protective potential for the pulp tissues.

*Heymann HO, Bayne SC. Current concepts in dentin bonding: focusing on dentinal adhesion factors. J Am Dent Assoc 1993 May; 124(5): 26-36.*

With greater need for treating root surface lesions, dentinal adhesives are more in demand. For successful treatment, all factors--dentin, tooth, patient and materials--must be considered.

*Ianzano JA, Mastrodomenico J, Gwinnett AJ. Strength of amalgam restorations bonded with Amalgambond. Am J Dent 1993 Feb; 6(1): 10-12.*

The objective of this study was to determine the strength of bonded amalgam restorations involving an entire cusp. Four groups were established, each containing 13 caries-free, recently extracted molar teeth of similar size and anatomic form. The teeth were stored in 70% alcohol prior to the removal of a cusp and the cutting of a conventional preparation with an occlusal lock. Group A were restored with amalgam only, Group B with amalgam and a pin, Group C with amalgam and Amalgambond (4-META) and Group D with amalgam, a pin and Amalgambond. The teeth were blocked in stone and stored for 7 days in water at 37 degrees C. Using an Instron, a force was delivered at right angles to the inclined cuspal plane of the

amalgam at its midcuspal point at a crosshead speed of 5 mm per minute. The load at failure was recorded and the assemblies recovered for fracture analysis using SEM. Group A failed at 33.61 +/- 15.17 Kg, Group B at 32.28 +/-12.10 Kg, Group C at 48.53 +/- 21.93 Kg and Group D at 47.84 +/-14.79 Kg. No statistically significant difference existed between Groups A and B, and Groups C and D. A significant difference ( $P < 0.002$ ) existed between Groups A and C and B and D. Failure commonly occurred between cusp and occlusal lock or within the cusp when a pin was used. Bonded restorations with a pin incurred cohesive root failure. It was concluded that the strength of the amalgam restorations benefitted significantly from bonding but the Amalgambond system may be contraindicated for use with pins due to root fracture.

**Eakle WS, Staninec M, Lacy AM. Effect of bonded amalgam on the fracture resistance of teeth. J Prosthet Dent 1992 Aug; 68(2): 257-260.**

The purpose of this study was to determine whether amalgam bonded to tooth structure with an adhesive resin cement can increase the fracture resistance of restored teeth. Extracted paired upper premolars were prepared for G.V. Black type mesioocclusodistal amalgam restorations. In one tooth of each pair (the experimental group), the enamel walls were etched with phosphoric acid and were painted with an adhesive resin (Panavia), and amalgam was condensed and carved. For the other tooth in each pair (the control group), amalgam was placed in the same manner but was not etched and lined with resin. The teeth were thermocycled and mounted for testing and then were loaded until fracture. A significant difference ( $p$  less than 0.05, the paired Student's t-test) was found in the force needed to fracture the bonded amalgam group (70.5 +/- 21.6 kg) compared with that needed to fracture the conventional amalgam group (60.3 +/- 16.8 kg). SEM examination of fractures at the interface occurred predominantly within the resin.

**Sano H, Takatsu T, Ciucchi B, Russell CM, Pashley DH. Tensile properties of resin-infiltrated demineralized human dentin. J Dent Res 1995; 74:1093-102.**

The ability of adhesive resins to restore the physical properties of demineralized dentin has not been well-documented. The unfilled resins that are used for adhesion have relatively low moduli of elasticity and limited ability to increase dentin stiffness, although they may increase the ultimate tensile strength of dentin. This study tested the hypothesis that resin infiltration of demineralized dentin can restore its tensile properties to those of mineralized dentin. Small (ca. 0.5 mm thick x 0.5 mm wide) specimens of demineralized human dentin were infiltrated with one of five different dentin bonding resins over many hours, to determine how these resins altered the tensile properties of dentin. Tensile stress and strain were measured in these and control (mineralized and demineralized) specimens until their ultimate failure. The results indicate that some adhesive resins, after infiltrating demineralized dentin, can restore and even exceed the ultimate tensile strength of mineralized dentin. These resins increased the modulus of elasticity of resin-infiltrated dentin to values equal to or greater than those of the resins but far below those of mineralized dentin. Although the conditions in this experiment were far removed from the manufacturer's recommendations or clinical practice, the results support the potential of resin infiltration for reinforcing dentin.

**Tay FR, Gwinnett AJ, Pang KM, Wei SH. Variability in microleakage observed in a total-etch wet-bonding technique under different handling conditions. J Dent Res 1995; 74:1168-78.**

Using a stereoscopic clearing protocol and scanning electron microscopy, we investigated the extent and nature of microleakage in a total-etch, current-generation dentin adhesive by a wet-bonding technique under different handling conditions. The hypotheses were that inadequate light curing of the primer or incomplete drying of the primer solvent might adversely affect the sealing ability of an acetone-containing adhesive system. The study consisted of three experimental groups: (I) a control group with an adequate light source and with the primer solvent completely dried; (II) an inadequate-light group; and (III) an incomplete evaporation of primer solvent group. The extent of microleakage after silver staining and clearing of the specimens was scored based on a modified five-point scale. Nonparametric statistical analysis (Kruskal-Wallis ANOVA) followed by a multiple comparison test (Dunn test) indicated significant differences among the three groups ( $p < 0.05$ ). SEM examination of the restorative interface revealed that microleakage appeared to be initiated from the bonding resin-hybrid layer interface in all three groups, representing the weak link in the adhesive system. In addition, microleakage was characterized by 5 zones, each delineating a stage in a continuous array of progressively deleterious microleakage patterns variously distributed among the three groups. It was suggested that, while the bonding resin-hybrid layer interface represented the intrinsic weakness in an already much improved dentin adhesive, extrinsic factors such as the adequacy of the curing light and, more importantly, complete removal of the primer solvents can and should be avoided to preserve the structural integrity of the marginal seal.

**Marshall GW Jr, Balooch M, Kinney JH, Marshall SJ. Atomic force microscopy of conditioning agents on dentin. J Biomed Mater Res 1995; 29:1381-7**

Dentin conditioners provide a microporous surface for penetration by bonding agents. This study used an atomic force microscope (AFM) to examine the initial steps in the conditioning process of dentin using

three demineralizing agents, 0.5 M EDTA, and dilute solutions of phosphoric (3 mM, 6 mM) and citric (5 mM) acids, in order to establish the relationships between demineralization and changes in surface morphology. Polished dentin disks had a 10-nm-thick gold pattern applied which served as a height reference. Samples ( $n = 3/\text{agent}$ ) were examined at baseline and at 2-s intervals for up to 120 s for each agent. EDTA (0.5 M) was used as received; other conditioners were diluted to slow the rates of demineralization for detailed study. The surfaces of the peritubular and intertubular regions were altered differently. Initially subsidence rates were equal and linear, but after a 100-nm depth change the intertubular rates decreased. For phosphoric acid and citric acid, the movement of the intertubular surface was uniform and the surfaces remained smooth. However, the intertubular surfaces were rough for the EDTA treatment. The surface subsidence reached a plateau after a depth change of about 0.5 microns, which resulted from a limit to the contraction of the demineralized and hydrated collagen scaffold.

**Cagidiaco MC, Ferrari M, Vichi A, Davidson CL. Mapping of tubule and intertubule surface areas available for bonding in Class V and Class II preparations. J Dent 1997 Sep;25(5):379-389.**

**OBJECTIVES AND METHODS:** The aim of this in vitro study was to evaluate the morphology of dentine in Class V and the Class II preparation walls in terms of tubule orientation, density and increase in surface area after conditioning. Six circular V-shaped preparations were cut at the cementum-enamel junction (CEJ) of anterior teeth and six Class II cavities with the cervical margin 1 mm below the CEJ were prepared in posterior teeth. The preparations were conditioned with 10% maleic acid. The samples were directly studied by SEM. The observations were organized according to location in the preparation, tubule density was counted and the increase in area available for bonding after acid etching was calculated. **RESULTS:** Dentine morphology of Class V and Class II preparation walls was mostly regular according to predictable patterns. Between the tubules, along the walls of the cavity, the etched dentine surface exhibited a porous network of collagen fibers. More than 50% of Class V and Class II cavity surface presented oblique or parallel tubule orientation with respect to the cut surface. Because of the presence of a structureless cementum layer, the morphology of the cervical area turned out to be less predictable. The tubule density varied considerably in different regions of the preparations. The intertubular dentine surface area increased after conditioning in Class V preparations from 20.9% to 50.3% on the walls where tubules were cut parallel to their long axis, and from 5.8% to 47.8% where tubules were cut perpendicularly. These same values for Class II preparations ranged from 0.6% to 46.4% on the walls where tubules were cut parallel to their long axis, and 29.8% of the tubules were cut perpendicularly. **CONCLUSIONS:** Based on this morphological investigation, the increase in intertubular dentine surface area might very well be responsible for the enhanced bond strength after acid etching of dentine, but not all areas exhibited equal responses to etching. In particular, the bonding substrate at the gingival margins may contribute little in terms of micromechanical retention.

**Tam LE, Yim D. Effect of dentine depth on the fracture toughness of dentine-composite adhesive interfaces. J Dent 1997 May;25(3-4):339-346.**

**OBJECTIVES:** The fracture toughness test was recently introduced as a clinically relevant method for assessing the fracture resistance of the dentine-composite interface. The objective of this study was to evaluate the effect of dentine depth on the interfacial fracture toughness test of several dentine-composite interfaces using some new proprietary dentine bonding agents. **METHODS:** Miniature short rod fracture toughness specimens containing a chevron-shaped dentine-composite-bonded interface were prepared for each group ( $n = 12$ ). Six different dentine bonding agents and two dentine depths were the variables assessed at the dentine-composite interfaces. After 24 h at 37 degrees C in water, the specimens were tested by loading at 0.5 mm/min in the Instron Universal Testing Machine. The interfacial KIC results were analysed by ANOVA, unpaired Student's t-tests and Fisher's LSD test ( $P < 0.05$ ). **RESULTS:** The interfacial KIC results in MN.m-3/2 (S.D.) on superficial and deep dentine, respectively, were: All-Bond 2, 0.80 (0.21), 0.44 (0.13); Bond-It, 0.75 (0.20), 0.38 (0.19); Prime and Bond, 0.56 (0.11), 0.28 (0.10); Scotchbond Multi-Purpose, 0.45 (0.23), 0.26 (0.15); One-Step and OptiBond, insufficient results due to premature specimen failures. **CONCLUSIONS:** The results from this study should contribute to the development of the fracture toughness test as a method for assessing the integrity of the dentine-composite interface. The interfacial fracture toughness test determined significant differences among the different dentine bonding agents and between the superficial and deep dentine substrates. The dentine bonding agents showed significantly reduced interfacial fracture toughness results when bonding to deep versus superficial dentine.

**Eick JD, Gwinnett AJ, Pashley DH, Robinson SJ. Current concepts on adhesion to dentin. Crit Rev Oral Biol Med 1997;8(3):306-335.**

This review examines fundamental concepts in bonding to dentin. Emphasis is placed on the structure and permeability characteristics of dentin and how they may influence its interaction with adhesive resin. Several new techniques to examine the interfaces between resin and dentin are reviewed along with some of their limitations. The advantages and disadvantages of acid etchants/conditioners vs. self-etching conditioners/primers are discussed. The problems of matching the surface tension of resin-bonding systems to the surface energy of the substrate are reviewed in terms of wetting the various components of dentin. The problems associated with matching the permeability of intertubular dentin to the diffusibility of bonding reagents are explored. Speculation is advanced on how to ensure polymerization and wetting of dentinal collagen. Theoretical problems associated with dentin bonding and with bond testing are reviewed to encourage future research in this rapidly developing area.

**Van Meerbeek B, Peumans M, Gladys S, Braem M, Lambrechts P, Vanherle G. Three-year clinical effectiveness of four total-etch dentinal adhesive systems in cervical lesions. Quintessence Int 1996 Nov;27(11):775-784.**

A 3-year follow-up clinical trial of two experimental Bayer total-etch adhesive systems and two commercial total-etch systems. Clearfil Liner Bond System and Scotchbond Multi-Purpose, was conducted to evaluate their clinical effectiveness in Class V cervical lesions. Four hundred twenty abrasion-erosion lesions were restored randomly using the four adhesive systems. There were two experimental cavity designs, in which the adjacent enamel margins either were or were not beveled and acid etched. Clearfil Liner Bond System and Scotchbond Multi-Purpose demonstrated high retention rates in both types of cavity design at 3 years. The two experimental Bayer systems scored much lower retention rates in both cavity designs at 3 years. None of the systems guaranteed margins free of microleakage for a long time. At 3 years, superficial, localized marginal discolorations were observed, the least for Clearfil Liner Bond System, followed by Scotchbond Multi-Purpose and the two experimental systems. Small marginal defects were recorded at the cervical dentin and the incisal enamel margin. Retention of Clearfil Liner Bond and Scotchbond Multi-Purpose appears to be clearly improved over earlier systems, but marginal sealing remains problematic. The two Bayer systems were found to be clinically unreliable.

**Perdigao J, Lambrechts P, Van Meerbeek B, Braem M, Yildiz E, Yucel T, Vanherle G. The interaction of adhesive systems with human dentin. Am J Dent 1996 Aug;9(4):167-173**

**PURPOSE:** To investigate the interaction of six experimental and commercial bonding systems with dentin in vivo. **MATERIALS AND METHODS:** One-Step, Clearfil Liner Bond 2, OptiBond, Permagen with 10% phosphoric acid, Permagen with 35% phosphoric acid, and Prime & Bond were applied in standard Class I occlusal cavities in premolars scheduled for extraction for orthodontic reasons, combined either with a self-cured or with a light-cured resin composite. The teeth were carefully extracted 5 minutes after resin polymerization and fixed in 2.5% glutaraldehyde. After fixation, the specimens were dehydrated, sectioned, and processed for field-emission SEM. **RESULTS:** Although some systems produced gap-free intact interfaces in specific specimens, all of them showed detachment at the transition between the resin-dentin interdiffusion zone and the fluid resin placed over it. It was apparent that the presence of air-bubbles and/or thick layers of polymerized-filled fluid resin resulted in less frequent separation areas at the resin-dentin interface, providing support for the concept of the elastic cavity wall. It was also confirmed that some dentin adhesive systems do not form a thick layer over the dentin, otherwise the resin composite would not have penetrated the dentin tubules.

## **Section Eight - Maxillofacial Prosthetics**

Section Eight contains information related to treatment of patients with intra-oral defects resulting from cancer, trauma or congenital disease. References pertaining to general design concepts, types of retainers, indirect retention, the major connectors, and listed. Mandibular discontinuity defects managing the patient who has a glossectomy, and cleft palate literature relating treatment and management are also listed. Textbooks listings on maxillofacial prosthodontics are provided. The authors and the titles of their presentations follow:

**Dr. Arthur O. Rahn**

“Prosthodontic Principles In The Construction Of Intra-oral  
Maxillofacial Restorations”

**Prosthodontic Principles In The Construction Of  
Intra-Oral Maxillofacial Restorations**

**Dr. Arthur O. Rahn**





## LECTURE OUTLINE

### PROSTHODONTIC PRINCIPLES IN THE CONSTRUCTION OF INTRA-ORAL MAXILLOFACIAL RESTORATIONS

- I. Factors in the Construction of Maxillary Obturators
  - A. Develop a logical treatment plan
  - B. Consideration of basic prosthodontic principles
- II. Treatment Planning Procedures
  - A. Presurgical
  - B. Surgical
  - C. Post-surgical
    1. Presence of teeth
    2. Resection of maxillary in relation to remaining teeth
    3. Presence of residual structures in the defect area
- III. Intrinsic Factors Within and Around the Defect that can Provide Retention for the Obturator
  - A. Residual soft palate
  - B. Residual hard palate
  - C. Anterior nasal aperture
  - D. Lateral scar band
  - E. Height of the lateral wall
  - F. Residual Maxilla (teeth, alveolar ridge)
- IV. Support for an Obturator
  - A. Residual maxilla-teeth, alveolar ridge, hard palate
  - B. Floor of orbit
  - C. Anterior surface of temporal bone
  - D. Pterygoid plate (posterior lateral aspect)
  - E. Nasal septum - not the best
- V. Major Concerns in Framework Design
  - A. Condition and alignment of abutment teeth
  - B. Size and position of the defect
  - C. Remaining hard palate forms
  - D. Ridge contour
  - E. Size and weight of the obturator
  - F. Retention and support to be obtained for obturator
- VI. Esthetic Concerns
  - A. Type of incision used
  - B. Lip length

VII. Basic Prosthodontic Principles for Obturator Construction

- A. Broad distribution of stress and retention
- B. Maximum coverage of tissue bearing area
- C. Modification of occlusion
- D. Must be adjustable
- E. Denture base must be compatible with the tissues
- F. Contingency planning

VIII. Movement of an Obturator

- A. Away from tissue - Toward the tissue
  - 1. Factors that counteract superior movement
  - 2. Factors that counteract inferior movement
- B. Anterior-posterior
  - 1. Factors that counteract this movement
- C. Mechanical advantage

IX. General RPD Design Principles that Apply to Obturator Frameworks

- A. Major Connector
- B. Guiding Planes
- C. Maximum Support
- D. Rests
- E. Direct Retainers
- F. Occlusion

X. Aramany's Classifications for Partially Edentulous Resected Arches

- A. Class I - Midline resection
  - 1. Design suggestion
  
- B. Class II - Unilateral resection
  - 1. Design suggestion

C. Class III - central resection

1. Design suggestion

D. Class IV - Bilateral A-P resection

1. Design suggestion

E. Class V - Posterior resection

1. Design suggestion

F. Class VI - Anterior resection

1. Design suggestion

XI. Types of Major Connectors (Palatal plate, A-P palatal bar)

A. Palatal plate

1. Advantages

2. Disadvantages

B. Anterior-posterior palatal bar

1. Indications

2. Advantages

XII. Retainers

- A. Location
- B. Basic principles of retainer assembly design
  - 1. Passivity
  - 2. Stabilization
  - 3. Presence of rests
  - 4. Encirclement
- C. Factors that affect the retainer retention
  - 1. Length of retentive arm
  - 2. Diameter of retentive arm
  - 3. Form of retentive arm
  - 4. Material used
  - 5. Contour of retentive arm
  - 6. Depth of undercut and convergence angle
- D. Types of retainers
  - 1. Cast circumferential
    - A. Indications
  - 2. Combination wrought wire and cast
    - A. Indications
  - 3. Bar type
    - A. Indications
  - 4. Swinglock
    - A. Indications
  - 5. I-bar
    - A. Indications

E. Obturator retainer design studies

F. Types of bracing components

1. Palatoplate
  - A. Indications
2. Continuous lingual bar
  - A. Indications
3. Single bracing arm
  - A. Indications
4. Lingual ledge
  - A. Indications

XIII. Indirect Retainers

- A. Placement

XIV. Finishing Lines for Obturators

- A. Placement

XV. Extension of Bulb Portion of Obturator

- A. Superiorly
- B. Inferiorly
- C. Brown's Article

XVI. Occlusion for Obturators

- A.
- B.
- C.

XVII. Making Impressions of Defect

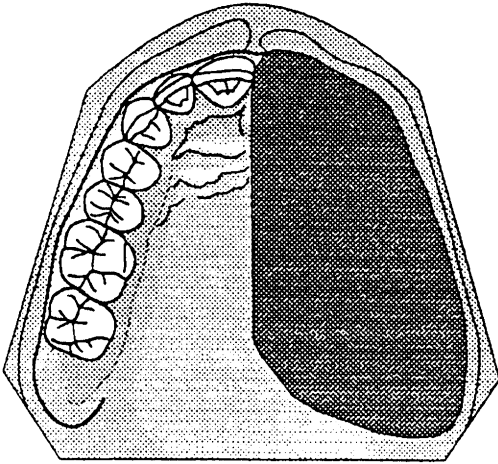
- A. One-shot method
- B. Use of modeling plastic and mouth temperature wax
- C. Patient movements for molding the pharyngeal portion

XVIII. Methods of Splinting

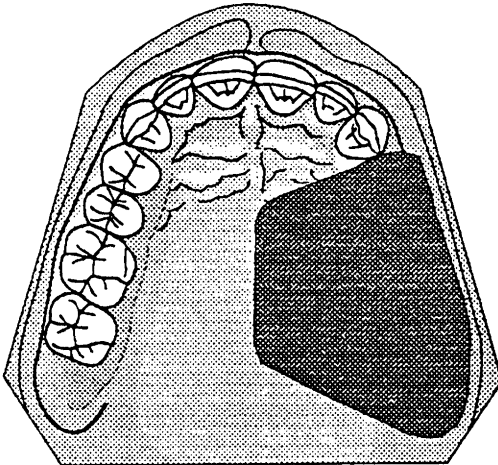
XIX. Mandibular Discontinuity Defects

- A. Clinical manifestations
- B. Special Surgical Considerations for the Mandibular Resected Patient
  - 1. Removal of ramus and condyle
  - 2. Placement position of cuts through the mandible
  - 3. Bony resections through the body of the mandible should be made as posteriorly as possible.
  - 4. Presence of teeth
- C. Treatment for the Mandibular Resected Patient

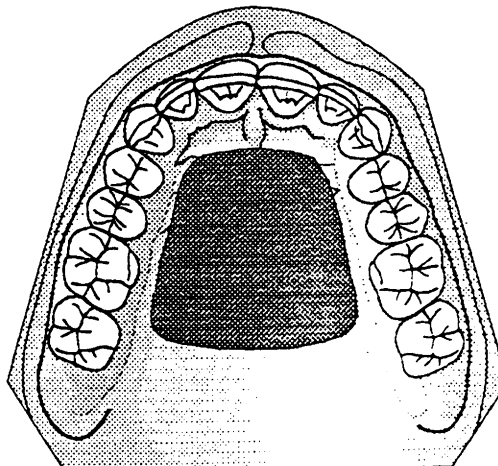
**Class I**



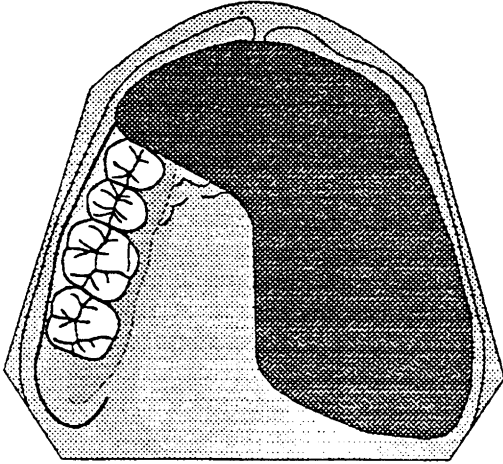
**Class II**



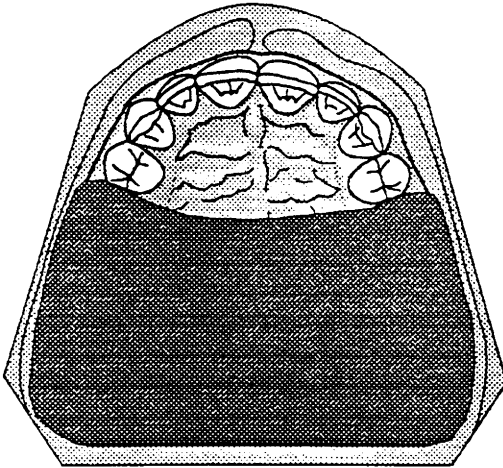
**Class III**



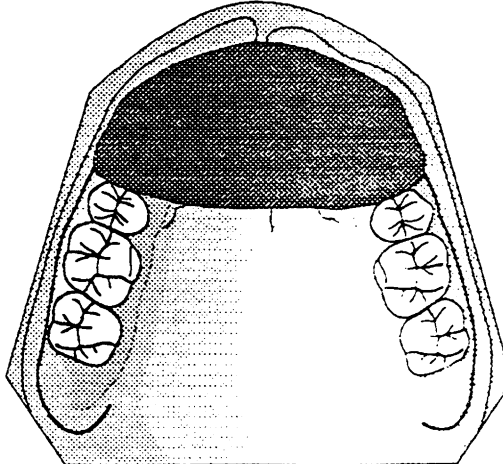
**Class IV**



**Class V**



**Class VI**





## LITERATURE REVIEW

Rev. 7-1994

### GENERAL DESIGN CONCEPTS

1. Parr, G.R., et al, Prosthodontic principles in the framework design of maxillary obturator prostheses. J. Pros. Dent. 1989, 62:205-211.

This article describes a series of Aramany obturator system design templates and discusses the relevant considerations for each. In all situations a quadrilateral or tripodal design is favored over a linear design because this allows a more favorable leverage design application.

2. Aramany, M.A., Basic principles of obturator design for partially edentulous patients. Part I: Classification. J. Pros. dent. 1978, 40:554-7.
3. Aramany, M.A., Basic principles of obturator design for partially edentulous patients. Part II: Design principles. J. Pros. Dent., 1978, 40:656-62.
4. Desjardins, R.P., Obturator prosthesis design for acquired maxillary defects. J. Pros. Dent., 1978, 39:424-35.
5. Gay, W.D. et al, Applying basic prosthodontic principles in the dentulous maxillectomy patient. J. Pros. Dent., 1980, 43:433-35.
6. Groetsema, W.R., An overview of the maxillofacial prosthesis as a speech rehabilitation aid. J. Pros. Dent., 1987, 57:204-208.
7. Marunick, M.T. et al, Mastication in patients treated for head and neck cancer. A pilot study. J. Pros. Dent., 1990, 63:566-73.

Masticatory performance and swallowing threshold performances were evaluated. Edentulous patients treated for cancer demonstrated deficiencies in both tests. Masticatory performance and swallowing threshold improved with prosthetic rehabilitation but was less than with comparable controls. Techniques to evaluate masticatory factors such as dentition, dentures, biting force, TMJ status, range of motion, and saliva are suggested.

8. Beumer, J. et al, Prosthetic restoration of oral defects secondary to surgical removal of oral neoplasm. Can. Dent. Assoc. J., 1982, 10:47-54.
9. Brown, K.E., Peripheral considerations in improving obturator retention. J. Pros. Dent., 1968, 20:176-80.

10. Wu, Yn-low, et al, Comparison of weight reduction in different designs of solid and hollow obturator prostheses. J. Pros. Dent., 1989, 62-214-17.
11. Minsley, G.E., et al, An alternative method for fabrication of a closed hollow obturator. J. Pros. Dent., 1986, 55:485-89.
12. Kelly, E.K., Partial denture design applicable to the maxillofacial patient. J. Pros. Dent., 1965, 15:168.
13. Chalian, V.A. et al, New technique for constructing a one-piece hollow obturator after partial maxillectomy. J. Pros. Dent., 1972, 28:448.
14. Brown, K.E., Fabrication of hollow-bulb obturator. J. Pros. Dent., 1969, 21:97.
15. Da Breo, E.L., Dimensional change in maxillary prosthetic obturators. J. Pros. Dent., 1991, 66:669-73.

The dimensional change in maxillary obturators constructed with three different denture base resins was investigated. The results indicated that a light-polymerized material (Triad) had the least percent of change between base and teeth positions.

16. Devlin, H. et al, Prosthetic rehabilitation of the edentulous patient requiring a partial maxillectomy. J. Pros. Dent., 1992, 67:223-27.

This article reviews developments in materials and techniques of obturator design. The size of the defect is one of the major factors governing the prognosis. Attention to the extension of the prosthesis and balanced occlusion is essential. Resilient denture base materials are useful in retaining the prosthesis when the defects are small but the flexibility of the material when used in large defects rendering it unsuitable in those situations. Alternate forms of retention, implants and sectional prosthesis retained by magnets are discussed.

17. Black, W.B., Surgical obturation using a gated prosthesis. J. J. Pros. Dent., 68:339-42, 1992.

A description is given for the fabrication of a stable surgical obturator for the dentate patient using a wrought wire and acrylic resin prosthesis based on the swinglock concept.

18. Schmaman, J. and Carr, L., A foam impression technique for maxillary defects. J. Pros. Dent., 68:342-44, 1992.

This article presents a technique used to overcome the problems of withdrawal of maxillectomy defect impressions with or without limited space as the result of trismus.

#### RETAINERS

1. Myers, R.E., et al, A photoelastic study of stress induced by framework design in maxillary resection. J. Pros. Dent., 1989, 61:590-594.

The purpose of this study was to investigate by three dimensional photoelastic analysis the stress transmission that occurs with four commonly used retentive systems. (This article should be read)

2. Swartzman, B., et al, Occlusal face transfer by removable partial denture designs for a radical maxillectomy. J. Pros. Dent., 1985, 54:397-403.
3. Firtel, D.N., et al, Retention of obturator-removable partial dentures: A comparison of buccal and lingual retention. J. Pros. Dent. 1980, 43:212-216.
4. Schwartzman, B., et al, Gravity-induced stresses by an obturator prosthesis. J. Pros. Dent., 1990, 64:466-68.

This investigation photoelastically studies the gravity-induced stresses transmitted to the oral structures by various obturator framework designs. Frameworks which used I-bar and circumferential retainers with buccal retention were most kind to the remaining structures. The same design with lingual retention were the worst, while the swinglock and light wire retainers were intermediate in the stress generated.

5. Martin, J.W., et al, Framework retention for maxillary obturator prosthesis. J. Pros. Dent. 1984, 51:669-72.
6. Fiebiger, G.E., et al, Movement of abutments by removable partial denture frameworks with a hemimaxillectomy obturator. J. Pros. Dent., 1975, 34:555-61.

### INDIRECT RETAINERS

1. Jacobs, R.F. et al, Indirect retainers in soft palate obturator design. J. Pros. Dent., 1990, 63:311-15.

Definitive framework design for the patient with a complete maxillary dentition who has had a soft palate resection requires the use of direct and indirect retainers. A design is offered to retain this prosthesis with only two posterior clasps and indirect retainers without clasps which is retentive, esthetic, and functional. Four clinical applications are described.

### MAJOR CONNECTOR

1. Nakamura, S.H., et al, The labial plate major connector in the partial mandibulectomy patient. J. Pros. Dent., 1989, 62:673-75.

Indicators, designs, and advantages of the labial plate major connector as compared with the labial and lingual bar major connectors are reviewed. The article suggests that the labial plate major connector may have an advantage over the labial bar and should be considered when a labial connector is indicated.

### MANDIBULAR DISCONTINUITY DEFECTS

1. Schneider, R.L. and Taylor, T.D., Mandibular resection guidance prostheses: A literature review. J. Pros. dent., 1986, 55:84-86.
2. Beumer, J., Curtis, T.A. and Firtell, D.N., Maxillofacial rehabilitation: Prosthodontic and surgical considerations. The CV Mosby Company, 1979, 150-159.
3. Adisman, K., Removable partial dentures for jaw defects of the maxilla and mandible. Dent. Clin. North Am., 1962, 849.
4. Robinson, J.E., Rubright, W.C., Use of a guide plane for maintaining the residual fragment in partial or hemi mandibulectomy. J. Pros. Dent., 1964, 14:992-999.
5. Swoope, C.C., Prosthetic management of resected edentulous mandibles. J. Pros. Dent., 1969, 21:197-202.
6. Brown, K.E., Complete denture treatment in patients with resected mandibles. J. Pros. Dent., 1969, 21:443-447.

7. Aramany, M.A., Myers, E.N., Intermaxillary fixation following mandibular resection. J. Pros. Dent., 1977, 37:437-444.
8. Desjardins, R.P., Occlusal considerations for the partial mandibulectomy patient. J. Pros. Dent., 1979, 41:308-315.
9. Cantor, R. and Curtis, T.A., Prosthetic management of edentulous mandibulectomy patients: Part II: Clinical procedures. J. Pros. Dent., 1971, 25:546.
10. Cantor, R. and Curtis, T.A. Prosthetic Management of edentulous mandibulectomy patients. Part I: Anatomic, physiologic and psychologic considerations. J. Pros. Dent., 1971, 25:446.
11. Cantor, R. and Curtis, T.A. Prosthetic management of edentulous mandibulectomy patients. Part III: Clinical evaluation. J. Pros. Dent., 1971, 25:670.
12. Swoope, C.C. Prosthetic management of resected edentulous mandibles. J. Pros. Dent., 1969, 21:197.
13. Brown, K.E. Complete denture treatment in patients with resected mandibles. J. Pros. Dent., 1969, 21:443.
14. Robinson, J.E. et al. Complete denture treatment in patients with resected mandibles. J. Pros. Dent., 1964, 14:992.
15. Koumjian, J.H. et al. An appliance to correct mandibular deviation in a dentulous patient with a discontinuity defect. J. Pros. Dent., 1992, 67:833-34.

This article describes an appliance that has been used successfully in reducing the deviation in dentate patients who have experienced a mandibular resection.

16. Marunick, M. et al. Occlusal force after partial mandibular resection. J. Pros. Dent., 1992, 67:835-38.

Five subjects who had partial mandibular resections were studied. Occlusal forces were recorded before and after cancer treatment and following prosthetic rehabilitation. The result was that a mandibular resection did alter maximum occlusal force and that prosthetic treatment did not restore the subjects to their pretreatment occlusal force level.

**GLOSSECTOMY**

1. Accure, M.R., et al, The effects of a maxillary speech-aid prosthesis for the combined tongue and mandibular resection patient. J. Pros. Dent., 1991, 66:816-822.
2. Gillis, R.E., et al, Prosthetic treatment for speech and swallowing in total glossectomy. J. Pros. Dent., 1983, 50:808-14.
3. Lauciello, F.R., et al, Prosthodontic and speech rehabilitation after partial and complete glossectomy. J. Pros. Dent., 1980, 43:204-11.
4. Moore, D.J., Glossectomy rehabilitation by mandibular tongue prosthesis. J. Pros. Dent., 1972, 28:429-433.
5. Wheeler, R.L., et al, Maxillary reshaping prostheses: Effectiveness in improving speech and swallowing of postsurgical oral cancer patients. J. Pros. Dent., 1980, 43:313-9.
6. Leonard, R.J., et al, Differential effects of speech prostheses in glossectomized patients. J. Pros. Dent., 1990, 64:701-708.

Five patients representing different categories of glossal resection were fitted with prostheses specifically designed to improve speech. Findings indicated that all subjects demonstrated improvements on the speech measures. The extent of improvement on each measure varied across speakers and resection categories.

7. Cantor, R., et al, Prosthetic management of edentulous mandibulectomy patients. Part I: Anatomic, physiologic and psychologic considerations. J. Pros. Dent., 1971, 25:446-57.
8. Aramany, M.A., et al, Prosthodontic rehabilitation of glossectomy patients. J. Pros. Dent., 1982, 48:78-81.
9. Izdebski, K., et al, An interim prosthesis for the glossectomy patient. J. Pros. Dent., 1987, 57:608-11.
10. Davis, J.W., et al, Effects of a maxillary glossectomy prosthesis on articulation and swallowing. J. Pros. Dent., 1987, 57-715-19.
11. Lehman, W.L., et al, Prosthetic treatment following complete glossectomy. J. Pros. Dent., 1966, 16-344.

**CLEFT PALATE**

1. Walter, J.D., Palatopharyngeal activity in cleft palate subjects. J. Pros. Dent., 1990, 63:187-92.

A literature review of cleft palate musculature and pharynx is provided and a rationale for determining the anatomic level at which muscle activity occurs. Ten basic patterns of palatopharyngeal movement are described and the interplay of the various muscles in producing these movements is discussed. It was concluded that the presence of an obturator in the pharynx affects the pattern of activity and that the obturator should be developed to speech function rather than swallowing.

2. Minsley, G.E., et al, The effect of cleft palate speech aid prostheses on the nasopharyngeal airway and breathing. J. Pros. Dent., 1991, 65:122-126.

The study determined the effect of a speech and prosthesis on resting breathing. The measurements were made for the unobturated defect during both phases of respiration and then repeated while the defect was obturated with a prosthesis. The study revealed that a prosthesis significantly decreased the X-sectional region of the nasal airway. The data suggests that the design of these prostheses should account for breathing requirements as well as for speech.

**TEXTBOOKS ON MAXILLOFACIAL PROSTHODONTICS**

1. Maxillofacial Rehabilitation, Beumer, Curtis & Firtell - Publisher unknown.
2. Maxillofacial Prosthetics, Chalian, Drone and Standish. The Williams and Wilkins Co.
3. Maxillofacial Prosthetics, W. Laney. (Post-graduate Dental Handbook) PSG Publishing Company.

Revised: 1994.







