

## RESEARCH ARTICLE

# Single nucleotide polymorphism array and cytogenetic analyses of ovarian teratomas in children

Lina Shao  | Amer Heider | Raja Rabah

Department of Pathology, Michigan Medicine, University of Michigan, Ann Arbor, Michigan

## Correspondence

Lina Shao, Department of Pathology, Michigan Medicine, University of Michigan, 2800 Plymouth Rd, Ann Arbor, MI 48109-2800, USA.  
Email: linashao@med.umich.edu

## Abstract

Teratomas are the most common tumors in the ovary during childhood. Previous studies suggested that they may be derived from germ cells at any developmental stage from premeiotic oogonia through meiotic oocytes to post-meiotic ova. The majority of mature teratomas reveal normal karyotypes and immature teratomas show higher frequency of chromosomal abnormalities. We analyzed fresh tissue samples from 25 primary ovarian teratomas and three extraovarian deposits using whole genome single nucleotide polymorphism (SNP) array and karyotype. SNP array detected five patterns of copy neutral loss of heterozygosity (CN-LOH): failure of meiosis I (type I) in 12 tumors, failure of meiosis II (type II) in six tumors, endoreduplication of a haploid ovum (type III) in two tumors, premeiotic error (type IV) in four tumors, and both meiotic I and meiotic II errors in one tumor (type V). Three tumors with type I error had a single chromosome showing meiotic II error, and two tumors with type II error had a single chromosome showing premature sister-chromatid separation in meiosis I. Lack of recombination in multiple chromosomes in meiosis I were common, chromosomes 17, 7, 8, 21, and 22 were most commonly involved. Abnormal karyotypes were observed in four teratomas including +3, del(3q), +7, +8, +12, and i(18q). The extraovarian deposits revealed the same CN-LOH pattern as the primary teratoma. In summary, SNP array reveals the origin of ovarian teratoma and we propose a new mechanism that consecutive meiotic I and II errors occur frequently in ovarian teratomas.

## KEYWORDS

karyotype, ovarian teratoma, SNP array

## 1 | INTRODUCTION

Germ cell tumors are a diverse group of neoplasms that include benign and malignant types.<sup>1</sup> In the United States, approximately 25 000 primary germ cell tumors were diagnosed between 1973 and 2007. They most often arise in the gonads but some are extragonadal. The incidence of ovarian germ cell tumors has a steep increase starting at age 5 years.<sup>2</sup> Approximately 70% of ovarian germ cell tumors in children are teratomas.<sup>1,3,4</sup>

Ovarian teratomas arise by abnormal development of a single germ cell through parthenogenetic activation.<sup>5,6</sup> Although they were originally thought to arise by meiosis II nondisjunction alone,<sup>6</sup> a diverse

mechanisms were proposed following studies of homozygosity and heterozygosity of chromosome loci, they include: type I, failure of meiosis I; type II, failure of meiosis II; type III, endoreduplication of the genome of a mature ovum; type IV, failure in a primordial germ cell; and type V, fusion of two ova.<sup>7-9</sup> A more recent study suggests that mature cystic teratomas arise from meiotic oocytes, not from premeiotic oogonia.<sup>10</sup>

Conventional cytogenetics is often applied at the diagnosis of pediatric germ cell tumors, +12 or i(12p) are frequently observed in gonadal or extragonadal germ cell tumors. However, most mature ovarian teratomas have a normal 46,XX karyotype. Trisomy, tetraploidy, or structural abnormalities are observed in approximately 7% of them.<sup>11</sup>

Chromosomal heteromorphisms and DNA polymorphic markers have traditionally been utilized to identify the origin of ovarian teratomas.<sup>7-10,12,13</sup> These markers sample dozens loci of the genome and they are limited in reflecting the zygosity status of the entire genome. More recently, whole genome single nucleotide polymorphism (SNP) array has been used in studies of ovarian teratomas,<sup>14-16</sup> and whole exome sequencing was also used to look at mutation and zygosity in teratomas.<sup>17</sup> Both of them have high resolution and can identify zygosity reliably.

## 2 | METHODS AND MATERIAL

### 2.1 | Patient samples

Fresh tissue samples were received for whole genome SNP array and karyotype analyses at the Clinical Cytogenetics Laboratory from December 2015 to October 2020. Patients' charts were reviewed for histological diagnosis, treatment modalities, and follow-up information. This study was approved by the institutional review board at the University of Michigan.

### 2.2 | G-banding and karyotyping analysis

Fresh tumor was disaggregated mechanically and enzymatically using collagenase V (Sigma-Aldrich, St. Louis, Missouri). Suspension and in-situ cultures were established. The suspension cultures were incubated overnight before harvest, and in-situ cultures were harvested after 3 to 14 days in culture. Karyotype was interpreted according to the International System for Human Cytogenetic Nomenclature (2013 or 2016).<sup>18,19</sup> A full analysis includes 20 metaphase cells.

### 2.3 | Whole genome SNP array analysis

The tissue was cut to  $5 \times 5 \times 1 \text{ mm}^3$  pieces followed by overnight lysis with proteinase K. DNA was isolated using the QIAamp DSP DNA Mini Kit (Qiagen, Germantown, Maryland). 250 ng genomic DNA was used for whole genome SNP array analysis using the Thermo Fisher CytoScan HD platform and results were analyzed using the ChAS software (Thermo Fisher, Santa Clara, California) as described previously.<sup>20</sup> The cutoff for copy neutral loss of heterozygosity (CN-LOH) was adjusted to 1.1 Mb, which was the smallest size of mosaic CN-LOH observed in this study. The region of CN-LOH was considered to involve centromere if it extended to the probes closest to the centromere.

## 3 | RESULTS

Table 1 summarizes the clinicopathological features of all patients. The age of patients at the time of diagnosis of ovarian teratomas

varied from 5 to 15 years, with a median age of 10.5 years. Fourteen primary teratomas originated from the right ovary and 11 from the left ovary. Patient 7 had bilateral ovarian teratomas (7-1 and 7-2). Nineteen of the teratomas were mature teratoma only and six had immature components with variable amounts of yolk sac tumor. Three of the immature teratomas were ruptured and associated with extra ovarian deposits (7-3, 12-2, and 20-2).

Whole genome SNP array detected extensive CN-LOH varying from 22.4% to 100% of the genome in 21 primary ovarian teratomas, while four samples (cases 2, 7-2, 15, and 19) did not have acquired CN-LOH (Table 2, Figure S1).

Chromosomal abnormalities were observed in four primary ovarian teratomas (16%) by SNP array analysis, three were from mature teratomas and one from immature teratoma. The abnormalities included a loss of 18p and a gain of 18q in case 2, a gain of partial chromosome 3 and trisomy 12 in case 7-1, trisomy 7 in case 16, and trisomy 8 in case 21. The gain of partial chromosome 3 in 7-1 was replaced by trisomy 3 in the extra ovarian/suprarenal mass in 7-3, which most likely reflects tumor heterogeneity. A submicroscopic deletion at 22q11.2 which is consistent with a known DiGeorge syndrome in case 14 was also detected by SNP array. Most of these chromosomal abnormalities were also observed by concurrent karyotype analysis except the 22q11.2 deletion and trisomy 8.

### 3.1 | CN-LOH pattern reveals origin of ovarian teratomas

Five unique CN-LOH patterns were observed in this study (Figure 1). The most common pattern (Figure 1, case 1), observed in 12 samples, was characterized by CN-LOH in the p arm and/or q arm of chromosomes without spanning centromeres. This pattern is consistent with non-disjunction during meiosis I or Type I error. The second pattern (Figure 1, case 17), observed in six samples, was characterized by homozygosity spanning centromeres. This pattern is consistent with non-disjunction during meiosis II or type II error. The third pattern (Figure 1, case 9), observed in two samples, was characterized by homozygosity of the entire genome. This pattern is consistent with endoreduplication of the genome in a haploid ovum or Type III error. The fourth pattern (Figure 1, cases 19), observed in four samples, showed balanced homozygous and heterozygous alleles without acquired CN-LOH, suggesting premeiotic error or type IV error. The fifth pattern (Figure 1, Case 10), observed in one sample, had mixed CN-LOH patterns consistent with non-disjunction in both meiosis I and II on different chromosomes in the same sample.

### 3.2 | Mixed CN-LOH patterns indicating consecutive meiotic I and II failures in the same teratoma are common

Case 10 had 12 chromosomes showing CN-LOH consistent with meiotic II non-disjunction, six chromosomes showing CN-LOH consistent

Case	Age (years)	Histological diagnosis	Tissue origin
1	11	Mature teratoma	Right ovary
2	5	Mature teratoma	Right ovary
3	13	Mature teratoma	Left ovary
4	9	Mature teratoma	Left ovary
5	6	Mature teratoma	Left ovary
6	11	Mature teratoma	Right ovary
7-1	14	Immature teratoma with yolk sac tumor	Left ovary
7-2		Mature teratoma with very focal immature elements and yolk sac tumor	Right ovary
7-3		Mature teratoma	Suprarenal mass
8	12	Mature teratoma	Right ovary
9	14	Mature teratoma	Left ovary
10	11	Immature teratoma	Left ovary
11	5	Mature teratoma	Right ovary
12-1	9	Malignant mixed germ cell tumor (yolk sac tumor 60%, embryonal carcinoma 35%, immature teratoma 5%)	Right ovary
12-2		Malignant mixed germ cell tumor	Abdominal mass
13	12	Mature teratoma	Right ovary
14	10	Mature teratoma	Left ovary
15	9	Mature teratoma	Right ovary
16	9	Mature teratoma	Left ovary
17	9	Mature teratoma	Right ovary
18	12	Mature teratoma	Right ovary
19	13	Mature teratoma	Left ovary
20-1	10	Immature teratoma with rare microscopic foci of yolk sac tumor	Left ovary
20-2		Gliomatosis peritonei	Right diaphragm
21	6	Mature teratoma	Right ovary
22	10	Immature teratoma	Right ovary
23	13	Mature teratoma	Right ovary
24	15	Mature teratoma	Left ovary

**TABLE 1** Clinicopathological features of ovarian teratomas and extraovarian deposits

with meiosis I non-disjunction, and five chromosomes without CN-LOH, suggesting a mixture of chromosomes with meiosis I or meiosis II errors. In addition, a single chromosome with meiosis II non-disjunction pattern was observed in three tumors that had meiotic I error in all other chromosomes. Chromosome 1 in cases 11 and 16, and chromosome 12 in case 12, had CN-LOH crossing their centromeres, while the other chromosomes in these tumors did not have CN-LOH spanning their centromeres (Table 2). The CN-LOH pattern in these tumors suggests that chromosome 1 in cases 11 and 16 and chromosome 12 in case 12 successfully completed meiosis I in an oocyte with an otherwise failed meiosis I and subsequently had meiosis II non-disjunction.

Homozygosity of entire chromosome in cases with meiosis II error is most likely caused by premature sister-chromatid separation in one of the homologs during meiosis I<sup>21</sup> and followed by an endoreduplication of the remaining chromatid during meiosis II. Chromosome 20 in case 20 and chromosome 1 in case 21 showed CN-LOH of the entire chromosome while all other chromosomes in

these two cases showed CN-LOH pattern of meiotic II error. These results suggested that the germ cell in these tumors had a premature sister-chromatid separation in one chromosome homologue in chromosome 20 (case 1) or 1 (case 21) during meiosis I and later these chromosomes had endoreduplication during meiosis II, while the rest chromosomes had successful meiosis I but later developed non-disjunction in meiosis II. These cases served as another example of consecutive meiotic I and II errors in the same tumor.

In addition, chromosome 14 in case 21 and chromosome 22 in case 23 did not have CN-LOH spanning their centromeres in an otherwise meiotic II error tumor (Table 2). The SNP probes closest to centromere on the long arms were approximately 3 Mb on chromosome 14 and 5 Mb on chromosome 22 away from centromere. It is possible that a crossover occurs within the region that was not covered by SNP probes, and extended to the short arm of these acrocentric chromosomes. However, the centromere restriction often limits the development of crossover in its surrounding.<sup>22</sup> Therefore, it was more

**TABLE 2** Cytogenetic and whole genome SNP array features of ovarian teratomas and extraovarian deposits

Case	Karyotype	Array results		Characters of CN-LOH			Mechanism of CN-LOH
		Copy number abnormalities	% genome with CN-LOH	Chromosome with centromere having CN-LOH	Chromosome with no CN-LOH	CN-LOH of entire chromosome	
1	Inadequate	None	30.4	None	7, 11, 14, 17	None	MI I error
2	46,XX,i(18)(q10) [9]	18p loss, 18q gain	None	None	None	None	Premeiotic error
3	Inadequate	None	24.1	None	13, 17, 22	None	MI I error
4	46,XX [16]	None	29.2	None	7, 15, 22	None	MI I error
5	inadequate	None	27.0	None	None	None	MI I error
6	46,XX [15]	None	28.7	None	21	None	MI I error
7-1	47,XX,+12[10]/48,sl,+3,del(3)(q21q29) [9]/46,XX [1]	3p24.2q21.1 gain, +12	22.9	None	8, 10	None	MI I error
7-2	46,XX [20]	None	None	None	None	None	Premeiotic error
7-3	46,XX [14]	+3, +12	Same as 7-1				
8	inadequate	None	30.0	None	None	None	MI I error
9	46,XX [20]	None	100	All	None	All	Endoreduplication
10	46,XX [20]	None	32.0	1-7, 9, 10, 12, 13, X	15, 17, 18, 19, 21	None	MI I + II errors
11	46,XX [2]	None	22.4	1	18	None	MI I error
12-1	46,XX [20]	None	24.8	12	8, 17, 21	None	MI I error
12-2	46,XX [20]	Same as 12-1					
13	46,XX [20]	None	34.2	None	None	None	MI I error
14	46,XX [20]	22q11.21 loss (DiGeorge syndrome)	23.6	None	7, 8, 15, 17, 19, 21, 22	None	MI I error
15	46,XX [20]	None	None	None	None	None	Premeiotic error
16	47,XX,+7[20]	+7	34.1	1	16	None	MI I error
17	46,XX [20]	None	38.4	All	None	None	MI II error
18	46,XX [20]	None	46.5	All	None	None	MI II error
19	46,XX [2]	None	None	None	None	None	Premeiotic error
20-1	46,XX [20]	None	56.6	All	None	20	MI II error
20-2	46,XX [20]	Same as 20-1					
21	46,XX [2]	+8	45.9	All except 14	None	1	MI II error
22	46,XX [20]	None	100	All	None	All	Endoreduplication
23	46,XX [20]	None	41.6	All except 22	None	None	MI II error
24	46,XX [15]	None	40.5	All	None	None	MI II error

Abbreviations: CN-LOH, copy neutral loss of heterozygosity; SNP, single nucleotide polymorphism.

likely that these chromosomes had non-disjunction during meiosis I. However, lacking of probes in the short arm and paracentric regions make the determination difficult.

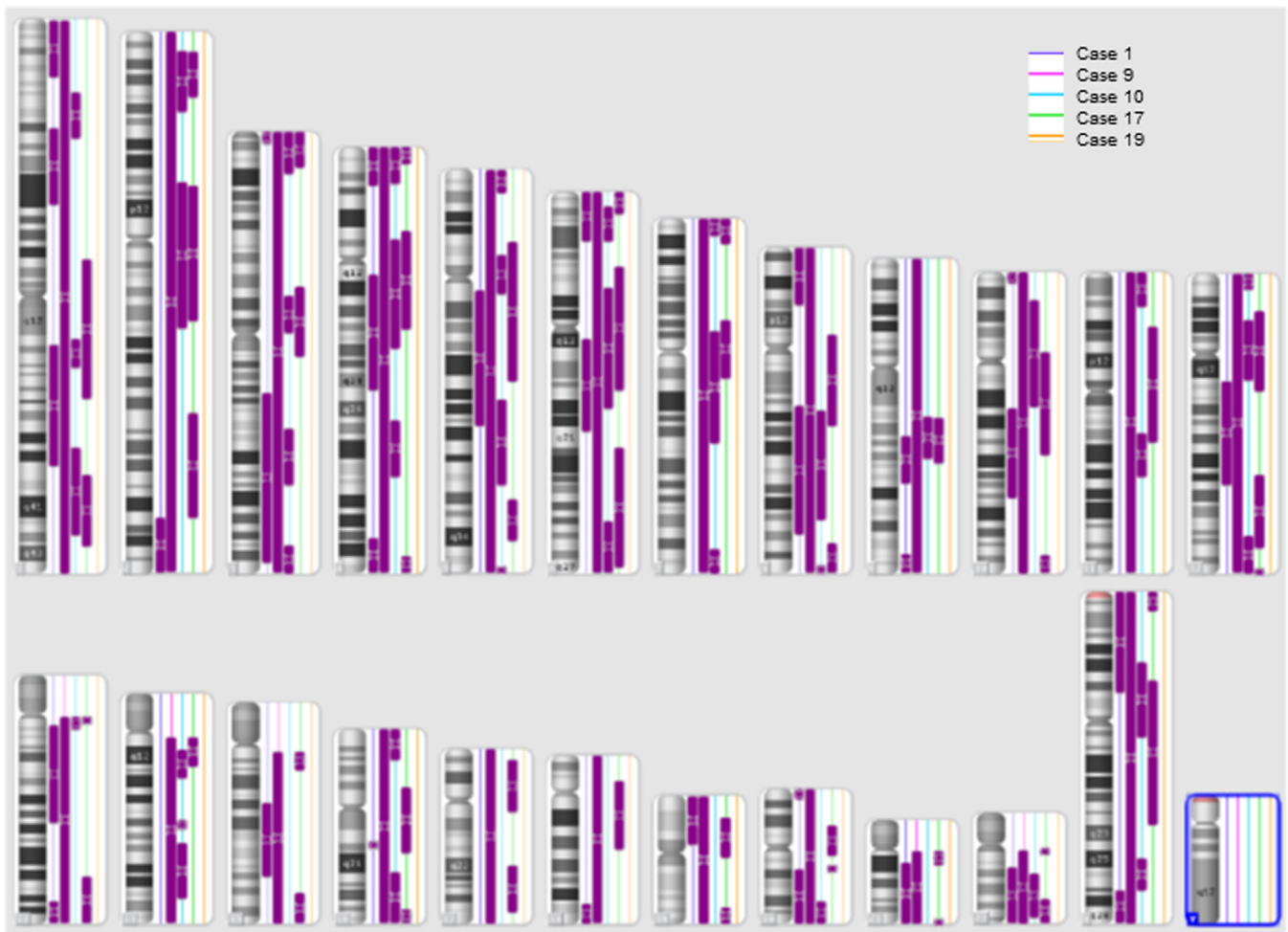
### 3.3 | All extra ovarian deposits had the same CN-LOH pattern as their corresponding primary tumors

Case 7 had bilateral immature ovarian teratomas, SNP array showed meiotic I error in the left ovarian tumor and premeiotic error in the right ovarian tumor, suggesting independent clonal origins in these two tumors. The mature teratoma found in the suprarenal mass

identified at a late follow-up exam showed identical CN-LOH pattern to the immature teratoma from the left ovarian. Similarly, the extra ovarian tumor in the abdominal mass in case 12-2 and the gliomatosis peritonii in case 20-2 showed identical CN-LOH pattern to their associated primary tumors.

### 3.4 | Chromosomes lacking crossover during meiosis I were nonrandom

Lacking any homozygosity in a specific chromosome in cases with meiosis I error are suggestive of no crossover or recombination during



**FIGURE 1** Whole genome single nucleotide polymorphism array results representing five different patterns of acquired copy neutral loss of heterozygosity (CN-LOH) in ovarian teratomas. The purple bars represent regions with acquired CN-LOH. Five cases each represent one type of mechanism were listed on different color of lines next to the karyogram. From left to right, the results on the purple lines were from case 1 (type I error), on the pink line were from case 9 (type III error), on the blue line were from case 10 (type V error), on the green line were from case 17 (type II error), and on the orange line were from case 19 (type IV error)

meiosis. In nine samples with type I error, 1-7 chromosomes in each case did not show evidence of CN-LOH. Single chromosome lacking CN-LOH was observed in three samples, chromosome 21 in case 6, chromosome 18 in case 11, and chromosome 16 in case 16. Trisomy of these chromosomes is frequently observed in prenatal and newborn studies. The remaining samples had two or more chromosomes without CN-LOH. Among all the chromosomes lacking CN-LOH, the most commonly involved chromosomes were 17 (4 samples), 7, 8, 21, and 22 (each observed in three samples) (Table 2).

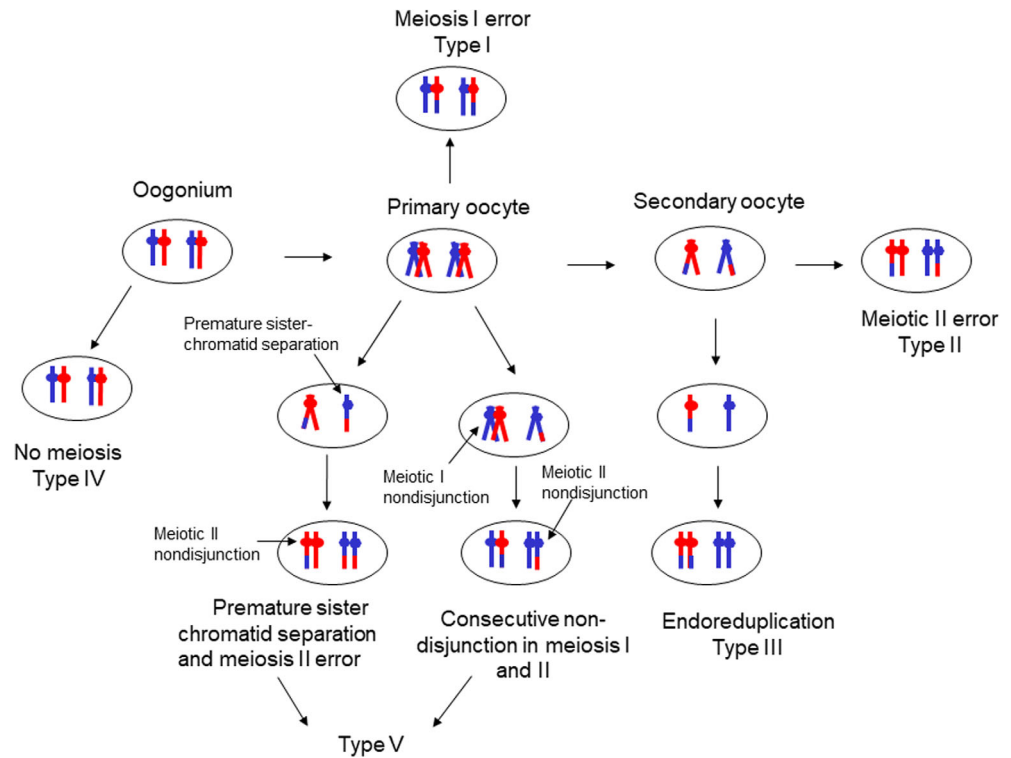
## 4 | DISCUSSION

In our study of 25 primary ovarian teratomas, CN-LOH patterns consistent with parthenogenesis were observed in 21 of them. Meiosis I non-disjunction (type I error) was the most common mechanism (12 cases), followed by meiosis II non-disjunction (type II, 6 cases), premeiotic error (type IV, 4 cases), endoreduplication (type III, 2 cases),

and mixed meiotic I and II errors (1 case). Our data were mostly concordant with literature about Type I-IV errors. Kaku H et al<sup>10</sup> suggested that premeiotic error did not exist in ovarian teratomas after studying 57 ovarian tumors. Our study clearly showed lack of CN-LOH of entire genome in 4/25 teratomas, consistent with a premeiotic origin in these tumors. Premeiotic origin was also observed in pediatric ovarian teratomas by Snir et al.<sup>23</sup> Patient cohort difference may contribute to this discrepancy; our patients were pediatric while the age of Kaku's study were not reported.

In normal oogenesis, the oocyte is arrested at diplotene stage of the first meiosis as a primary oocyte within the ovary until puberty. Following puberty, during each menstrual cycle, pituitary gonadotrophin stimulates completion of meiosis I the day before ovulation. The oocyte then commences meiosis II which arrests at metaphase and will not continue without fertilization.<sup>24</sup> Our patients were 5- to 15-years-old with a median age of 10.5 years, it is reasonable that majority of the teratomas in our study were originated from earlier stages of oogenesis, premeiotic stage or meiosis I. Interestingly, six

**FIGURE 2** Putative mechanisms of ovarian teratoma formation. Type I error result from a meiosis I error when the segregation of sister chromatids occur without the preceding separation of homologous chromosomes. Type II error result from meiosis II failure when nondisjunction of sister chromatids give rise to diploid cells. Type III errors occur via endoreduplication of a haploid ovum after meiosis II. Type IV error occurs in a oogonium escaping meiosis. Type V error are thought to originate from an oocyte with consecutive errors in both meiosis I and II in different chromosomes



tumors were originated from germ cells in meiosis II including a 6- and a 9-year-old patients and two were from mature ovum. Snir et al studied 12 pediatric ovarian teratomas from patients 2- to 18-years-old, they found that teratomas from patients younger than 4 years showed no evidence of homozygosity (premeiotic origin), while teratomas in patients older than 9 years showed either partial or complete homozygosity.<sup>23</sup> However, Kato et al found a meiotic II failure in a mature teratoma from a 4-year-old patient.<sup>12</sup> Kato's and our results suggest that oocytes can escape from meiotic arrest and develop into teratoma in prepubertal patients.

Fusion of two ova (type V error in previous publications) was proposed in earlier studies; however, it was not observed in three large studies. It was suggested that this was most likely due to lack of informative marker to distinguish type I error from fusion of two ova<sup>8,9</sup> or low frequency.<sup>10</sup> A recent study using whole genome SNP array proposed that this type error does not exist based on their observation in 38 samples and mathematical model.<sup>15</sup> Fusion of two ova will result in coexisting of CN-LOH patterns with meiosis I, meiosis II, isodisomy, and no CN-LOH in relatively equal proportion of the genome. We did not observe any case with CN-LOH patterns consistent with fusion of two ova in this study. Case 10 had 12 chromosomes showing CN-LOH consistent with meiosis II error, 6 chromosomes showing CN-LOH pattern consistent with meiotic I error, and 5 chromosomes did not have CN-LOH. The lack of any chromosome with isodisomy and the disproportional chromosomes with meiotic II error argues against the mechanism of fusion of two ova in the origin of this teratoma. We propose that the tumor most likely had consecutive meiosis I and meiosis II errors. This hypothesis was corroborated by pattern consistent with meiotic II error in a single

chromosome in three teratomas with other chromosomes showing meiotic I error, and premature sister-chromatid separation in two cases with meiotic II errors. These probably were the cases initially mistaken as fusion of two ova, since both patterns were observed by microsatellite markers. Testing of oocytes from IVF patients over 35-years-old showed that close to 30% of oocytes had chromosomal abnormalities due to both meiosis I and II errors,<sup>21</sup> similar to the frequency in ovarian teratomas in our study (6/25). Therefore, we propose a new mechanism, consecutive meiosis I and II errors, as the new type V error in this study (Figure 2).

Most ovarian teratomas have a normal 46,XX karyotype. Abnormal karyotype has been reported in approximately 7% benign teratomas,<sup>9</sup> and more common (63%) in malignant teratomas.<sup>11,25,26</sup> The abnormal karyotypes include trisomy, monosomy, triploidy, and tetraploidy. Structural abnormalities such as marker chromosome and deletion of chromosomal arm are rare. Most of these abnormalities are non-recurring, except trisomies 3, 8, and 12 which have been reported in multiple teratomas.<sup>27</sup> In our study, one out of six immature teratoma (case 7-1: +3, del(3q) and + 12), and three out of 19 mature teratomas (i(18q) in case 2, +7 in case 16, and + 8 in case 21) had cytogenetic abnormalities. We did not see over representation of abnormal karyotype in immature teratomas, most likely due to a small sample size. The trisomy 3, 8, and 12 found in our patients are the common trisomies in ovarian teratomas.

The mechanism of extra ovarian implantation is unknown and two hypotheses are proposed: (a) the peritoneal dissemination results from small capsular defects and (b) these implants are genetically unrelated to the associated teratoma and they represent independent lesions arising from peritoneal Müllerian stem cells or subjacent



mesenchyme.<sup>17,28,29</sup> Our results favor that the extra ovarian teratomas in three cases are genetically related to the primary ovarian tumors.

We found that lack of crossover was common in meiosis I. Nine of 12 tumors with meiosis I error had chromosomes lacking CN-LOH and multiple chromosomes lacking CN-LOH in a teratoma were common. The most common chromosomes were 17, 7, 8, 21, and 22. Lack of crossover during meiosis I is an important mechanisms leading to non-disjunction and chromosome aneuploidy. Although trisomy of chromosomes 17, 7, and 8 are uncommon in prenatal and postnatal studies, chromosomes 22, 16, 21, 15, 7, 13, and 17 (in order) are most frequently involved in aneuploidy in cleavage-stage embryos,<sup>30</sup> and trisomy 7, 15, 16, and 22 are the most common trisomies in two large NIPS studies.<sup>31,32</sup> These findings suggest that the chromosomes lacking crossover in teratomas probably are similar to what observed in the oocytes in prenatal studies, but aneuploidies not compatible with life are unselected in fetus before pregnancy is realized.

A limitation of this study is the lack of SNP coverage at centromeres and short arms of acrocentric chromosomes due to repetitive sequences in these regions, which made the determination of meiotic I or II pattern difficult in acrocentric chromosomes.

In summary, we demonstrated the utility of SNP array in determining the origin of ovarian teratomas and proposed a new mechanism that consecutive errors in meiosis I and II occur frequently in ovarian teratomas for the first time. We found that the extra ovarian implantations were genetically related to the primary tumors. Furthermore, karyotypic abnormalities and lack of recombination in multiple chromosomes were common in ovarian teratomas, the study of the latter may serve as surrogate for prenatal and reproductive studies.

## CONFLICT OF INTEREST

The authors declare no potential conflict of interest.

## DATA AVAILABILITY STATEMENT

Research data are not shared.

## ORCID

Lina Shao  <https://orcid.org/0000-0002-6650-1698>

## REFERENCES

- Roth LM, Taleran A. Recent advances in the pathology and classification of ovarian germ cell tumors. *Int J Gynecol Pathol.* 2006;25(4):305-320.
- Stang A, Trabert B, Wentzensen N, et al. Gonadal and extragonadal germ cell tumours in the United States, 1973-2007. *Int J Androl.* 2012;35(4):616-625.
- Ulbright TM. Gonadal teratomas: a review and speculation. *Adv Anat Pathol.* 2004;11(1):10-23.
- Braungart S, Collaborators CS, Craigie RJ, Farrelly P, Losty PD. Ovarian tumors in children: how common are lesion recurrence and metachronous disease? A UKCCLG surgeons cancer group nationwide study. *J Pediatr Surg.* 2020;55(10):2026-2029.
- Hashimoto N, Watanabe N, Furuta Y, et al. Parthenogenetic activation of oocytes in c-Mos-deficient mice. *Nature.* 1994;370(6484):68-71.
- Linder D, McCaw BK, Hecht F. Parthenogenic origin of benign ovarian teratomas. *N Engl J Med.* 1975;292(2):63-66.
- Chakravarti A, Majumder PP, Slangen SA, et al. Gene-centromere mapping and the study of non-disjunction in autosomal trisomies and ovarian teratomas. *Prog Clin Biol Res.* 1989;311:45-79.
- Deka R, Chakravarti A, Surti U, et al. Genetics and biology of human ovarian teratomas. II. Molecular analysis of origin of nondisjunction and gene-centromere mapping of chromosome I markers. *Am J Hum Genet.* 1990;47(4):644-655.
- Surti U, Hoffner L, Chakravarti A, Ferrell RE. Genetics and biology of human ovarian teratomas. I. Cytogenetic analysis and mechanism of origin. *Am J Hum Genet.* 1990;47(4):635-643.
- Kaku H, Usui H, Qu J, Shozu M. Mature cystic teratomas arise from meiotic oocytes, but not from pre-meiotic oogonia. *Genes Chromosomes Cancer.* 2016;55(4):355-364.
- Bussey KJ, Lawce HJ, Olson SB, et al. Chromosome abnormalities of eighty-one pediatric germ cell tumors: sex-, age-, site-, and histopathology-related differences—a Children's cancer group study. *Genes Chromosomes Cancer.* 1999;25(2):134-146.
- Kato N, Sakamoto K, Murakami K, Iwasaki Y, Kamataki A, Kurose A. Genetic zygosity of mature ovarian teratomas, struma ovarii, and ovarian carcinoids. *Virchows Arch.* 2018;473(2):177-182.
- Munday WR, Hui P. Heterozygous bone marrow in a homozygous mature ovarian teratoma: a challenge to the germ cell theory or incidental somatic heterotopia? *J Clin Pathol.* 2015;68(8):666-669.
- Tamura D, Maeda D, Sato T, et al. An extragonadal yolk sac tumor presumed to be of postmeiotic germ cell origin by genetic zygosity analysis via single nucleotide polymorphism array. *Genes Chromosomes Cancer.* 2020;59(3):209-213.
- Usui H, Nakabayashi K, Kaku H, Maehara K, Hata K, Shozu M. Elucidation of the developmental mechanism of ovarian mature cystic teratomas using B allele-frequency plots of single nucleotide polymorphism array data. *Genes Chromosomes Cancer.* 2018;57(8):409-419.
- Henderson BB, Chaubey A, Roth LM, et al. Whole-genome and segmental homozygosity confirm errors in meiosis as etiology of struma ovarii. *Cytogenet Genome Res.* 2020;160(1):2-10.
- Heskett MB, Sanborn JZ, Boniface C, et al. Multiregion exome sequencing of ovarian immature teratomas reveals 2N near-diploid genomes, paucity of somatic mutations, and extensive allelic imbalances shared across mature, immature, and disseminated components. *Mod Pathol.* 2020;33(6):1193-1206.
- McGowan-Jordan J, Simons A, Schmid M. eds. *ISCN (2016): An International System for Human Cytogenomic Nomenclature.* Basel: S Karger; 2016.
- Shaffer LG, McGowan-Jordan J, Schmid M. eds. *ISCN (2013): An International System for Human Cytogenetic Nomenclature.* S Karger: Basel; 2012.
- Wang Y, Miller S, Roulston D, Bixby D, Shao L. Genome-wide single-nucleotide polymorphism array analysis improves prognostication of acute lymphoblastic leukemia/lymphoma. *J Mol Diagn.* 2016;18(4):595-603.
- Kuliev A, Verlinsky Y. Meiotic and mitotic nondisjunction: lessons from preimplantation genetic diagnosis. *Hum Reprod Update.* 2004;10(5):401-407.
- Ottolini CS, Newnham L, Capalbo A, et al. Genome-wide maps of recombination and chromosome segregation in human oocytes and embryos show selection for maternal recombination rates. *Nat Genet.* 2015;47(7):727-735.
- Snir OL, DeJoseph M, Wu X, et al. Lack of genetic homozygosity in prepubertal teratomas: divergent pathogenesis distinct from that of teratomas in adolescents. *Lab Invest.* 2020;100:1447-1454.
- Nussbaum RL MI, Roderick R. W, Huntington F. *Thompson & Thompson Genetics in Medicine.* 8th ed. Philadelphia, PA: Elsevier; 2016.
- Ohama K, Nomura K, Okamoto E, Fukuda Y, Ihara T, Fujiwara A. Origin of immature teratoma of the ovary. *Am J Obstet Gynecol.* 1985;152(7):896-900.

26. Hoffner L, Shen-Schwarz S, Deka R, Chakravarti A, Surti U. Genetics and biology of human ovarian teratomas. III. Cytogenetics and origins of malignant ovarian germ cell tumors. *Cancer Genet Cytogenet.* 1992; 62(1):58-65.
27. Mertens F, Kullendorff CM, Hjorth L, Alumets J, Mandahl N. Trisomy 3 as the sole karyotypic change in a pediatric immature teratoma. *Cancer Genet Cytogenet.* 1998;102(1):83-85.
28. Kubosawa H, Iwasaki H, Kuzuta N, Suzuki H, Iura H. Adenocarcinoma with peritoneal dissemination secondary to multiple mature teratomas of the omentum. *Gynecol Oncol.* 2006;101(3):534-536.
29. Kwan MY, Kalle W, Lau GT, Chan JK. Is gliomatosis peritonei derived from the associated ovarian teratoma? *Hum Pathol.* 2004;35(6):685-688.
30. Munne S, Bahce M, Sandalinas M, et al. Differences in chromosome susceptibility to aneuploidy and survival to first trimester. *Reprod Biomed Online.* 2004;8(1):81-90.
31. Scott F, Bonifacio M, Sandow R, Ellis K, Smet ME, McLennan A. Rare autosomal trisomies: important and not so rare. *Prenat Diagn.* 2018; 38(10):765-771.
32. Pertile MD, Halks-Miller M, Flowers N, et al. Rare autosomal trisomies, revealed by maternal plasma DNA sequencing, suggest increased risk of fetoplacental disease. *Sci Transl Med.* 2017;9(405): 1240.

#### SUPPORTING INFORMATION

Additional supporting information may be found online in the Supporting Information section at the end of this article.

**How to cite this article:** Shao L, Heider A, Rabah R. Single nucleotide polymorphism array and cytogenetic analyses of ovarian teratomas in children. *Genes Chromosomes Cancer.* 2021;60:418-425. <https://doi.org/10.1002/gcc.22934>