










CLINICAL REVIEW**Contemporary management of the neck in nasopharyngeal carcinoma**

Wai Tong Ng MD¹  | Raymond K. Y. Tsang MS²  |
 Jonathan J. Beitler MD, MBA^{3,4,5} | Remco de Bree MD, PhD⁶ |
 Andrés Coca-Pelaz MD, PhD^{7,8}  | Avraham Eisbruch MD⁹ |
 Orlando Guntinas-Lichius MD¹⁰  | Anne W. M. Lee MD^{1,11} |
 Antti A. Mäkitie MD, PhD^{12,13,14} | William M. Mendenhall MD¹⁵  |
 Sandra Nuyts MD, PhD^{16,17} |
 Alessandra Rinaldo MD, FDSRCS ad eundem, FRCS (Eng, Ir) ad eundem,
 FRCSGlasg¹⁸ | K. Thomas Robbins MD, FRCSC¹⁹  |
 Juan P. Rodrigo MD, PhD^{7,8}  | Carl E. Silver MD²⁰ |
 Ricard Simo PhD, FRCS(ORL-HNS)²¹ | Robert Smee FRANZCR²² |
 Primož Strojjan MD²³  | Robert P. Takes MD, PhD²⁴  |
 Alfio Ferlito MD, DLO, DPath, FRCSEd ad hominem, FRCS (Eng, Glasg, Ir) ad eundem,
 FDSRCS ad eundem, FHKCORL, FRCPath, FASCP, IFCAP²⁵

¹Department of Clinical Oncology, Li Ka Shing Faculty of Medicine, The University of Hong Kong, Hong Kong, China²Department of Otorhinolaryngology, Li Ka Shing Faculty of Medicine, The University of Hong Kong, Hong Kong, China³Department of Radiation Oncology, Winship Cancer Institute of Emory University, Atlanta, Georgia, USA⁴Department of Otolaryngology, Winship Cancer Institute of Emory University, Atlanta, Georgia, USA⁵Department of Hematology/Medical Oncology, Winship Cancer Institute of Emory University, Atlanta, Georgia, USA⁶Department of Head and Neck Surgical Oncology, University Medical Center Utrecht, Utrecht, The Netherlands⁷Department of Otolaryngology, Hospital Universitario Central de Asturias-University of Oviedo, Oviedo, Spain⁸Instituto de Investigación Sanitaria del Principado de Asturias, IUOPA, CIBERONC, Oviedo, Spain⁹Department of Radiation Oncology, University of Michigan Medicine, Ann Arbor, Michigan, USA¹⁰Department of Otorhinolaryngology, Jena University Hospital, Jena, Germany¹¹Clinical Oncology Center, The University of Hong Kong-Shenzhen Hospital, Shenzhen, China¹²Department of Otorhinolaryngology—Head and Neck Surgery, HUS Helsinki University Hospital and University of Helsinki, Helsinki, Finland¹³Research Program in Systems Oncology, Faculty of Medicine, University of Helsinki, Helsinki, Finland¹⁴Division of Ear, Nose and Throat Diseases, Department of Clinical Sciences, Intervention and Technology, Karolinska Institutet and Karolinska University Hospital, Stockholm, Sweden¹⁵Department of Radiation Oncology, University of Florida College of Medicine, Gainesville, Florida, USA¹⁶Department of Radiation Oncology, University Hospitals Leuven, KU Leuven - University of Leuven, Leuven, Belgium¹⁷Laboratory of Experimental Radiotherapy, Department of Oncology, KU Leuven - University of Leuven, Leuven, Belgium¹⁸Department of Otolaryngology, University of Udine School of Medicine, Udine, Italy¹⁹Department of Otolaryngology-Head and Neck Surgery, Southern Illinois University Medical School, Springfield, Illinois, USA²⁰Department of Surgery, University of Arizona College of Medicine, Phoenix, Arizona, USA

²¹Department of Otorhinolaryngology, Head and Neck Surgery, Head and Neck and Thyroid Oncology Unit, Guy's and St Thomas' Hospital NHS Foundation Trust, London, UK

²²Department of Radiation Oncology, The Prince of Wales Cancer Centre, Sydney, New South Wales, Australia

²³Department of Radiation Oncology, Institute of Oncology, Ljubljana, Slovenia

²⁴Department of Otolaryngology/Head and Neck Surgery, Radboud University Medical Center, Nijmegen, The Netherlands

²⁵International Head and Neck Scientific Group, Padua, Italy

Correspondence

Wai Tong Ng, Department of Clinical Oncology, Li Ka Shing Faculty of Medicine, The University of Hong Kong, Hong Kong, China.
Email: ngwt1@hku.hk

Abstract

Up to 85% of the patients with nasopharyngeal carcinoma present with regional nodal metastasis. Although excellent nodal control is achieved with radiotherapy, a thorough understanding of the current TNM staging criteria and pattern of nodal spread is essential to optimize target delineation and minimize unnecessary irradiation to adjacent normal tissue. Selective nodal irradiation with sparing of the lower neck and submandibular region according to individual nodal risk is now emerging as the preferred treatment option. There has also been continual refinement in staging classification by incorporating relevant adverse nodal features. As for the uncommon occurrence of recurrent nodal metastasis after radiotherapy, surgery remains the standard of care.

KEYWORDS

nasopharyngeal carcinoma, nodal metastasis, prognosis, radiotherapy, staging, surgery

1 | INTRODUCTION

A well-known clinical feature of nasopharyngeal carcinoma (NPC) is its tendency for early spread to the rich submucosal lymphatic network of the nasopharynx (NP) and the cervical lymph nodes (LNs). Due to the inconspicuous symptoms related to the primary tumor, most (76%) patients present with a painless neck mass prompting medical attention,¹ and up to 85% of nodal metastases are found at the time of disease presentation.² Occurrence of skip nodal metastasis is rare and nodal spread typically follows an orderly pattern.³

With such a high incidence of nodal metastasis in the cervical region, this article aims to summarize the current management of the neck in NPC through a comprehensive review of the recent literature. Evolving modifications in nodal classification and salvage strategies in nodal recurrence are also discussed.

2 | GENERAL APPROACH

For patients who present with suspicious cervical lymphadenopathy, especially in the endemic regions where NPC is prevalent, initial examination may be endoscopic examination and biopsy of the NP, rather than fine-needle aspiration of the neck mass.

Subsequent work up includes appropriate biopsy of the primary tumor and/or the node, physical examination with particular attention to cranial nerve function, plasma Epstein–Barr virus (EBV) DNA, computed tomography (CT) scanning, magnetic resonance imaging (MRI), and Fluorine-18 fluorodeoxyglucose positron emission tomography (FDG-PET). Radiotherapy (RT) with or without chemotherapy remains the primary modality of treatment,⁴ while surgery is reserved for persistent nodal disease or relapse.

3 | INCIDENCE AND PATTERNS OF NODAL INVOLVEMENT

Incidence and patterns of nodal involvement have significant implications on the design of RT treatment portals. As NPC is primarily treated by RT, standard radiologic criteria of LN metastasis are actually derived empirically from the experience of surgically treated head and neck squamous cell carcinoma (HNSCC)⁵; and correlation of radiologic with pathologic findings to our knowledge has not been reported in the literature for NPC. Radiological criteria of nodal metastasis usually include: (1) retropharyngeal LNs (RPLNs) > 5 mm or cervical LNs > 10 mm in shortest diameter (11 mm for subdiaphragmatic nodes), (2) three or more

contiguous and confluent LNs, each with shortest diameter of 8–10 mm, (3) LNs of any size with central necrosis or a contrast-enhanced rim, (4) LNs of any size with extracapsular extension (ECE), and (5) LNs of any size with overt FDG uptake on FDG-PET scan.⁶ Furthermore, in non-overtly pathologic LNs, the summed long- and short-axis diameter ≥ 17 mm was proposed as an alternative criterion for identifying potentially infiltrated LNs that may require a higher dose than that usually employed for elective radiation.⁷

In general, FDG-PET scanning improves diagnostic accuracy in the detection of cervical nodal metastasis. One meta-analysis for patients with NPC⁸ showed that FDG-PET/CT scans obtained a pooled sensitivity and specificity of 0.9 and 0.92 in detecting cervical nodal metastasis. However, when compared with MRI, PET did not provide adequate spatial resolution to identify retropharyngeal nodes that merged with or were in close proximity to the primary tumor.⁸

Incidence and patterns of nodal involvement for NPC were reported in a meta-analysis of 13 clinical studies using MRI for diagnosis and staging. The most commonly involved regions included retropharyngeal (69%) and level II LNs (70%). The overall probability of positive LNs in levels III, IV, and V was 45%, 11%, and 27%, respectively. Low-risk node groups included the supraclavicular, levels Ia, Ib, VI, and the parotid nodes with involvement rates at 3%, 0%, 3%, 0%, and 1%, respectively. Nodal metastases followed an orderly pattern and the probability of “skip” metastasis between levels varied between 0.5% and 7.9%.² Notably, these studies were mostly conducted in South East Asia where EBV-related NPC is most prevalent; and the pattern of LN metastases may be different in non-endemic region.

On MRI examination, considered to be the most reliable clinical means of neck evaluation, while 75% of 3100 previously untreated NPC patients had retropharyngeal nodal involvement, the medial group (located between the pharyngeal constrictor muscles and the prevertebral fascia near the midline) was rarely affected (0.2%)⁹ and the incidence of RPLN metastasis decreased steadily from locations at level C1 to level C3.¹⁰ Of course, MRI staging for nasopharyngeal cancers is not as reliable as pathologic examination and omitting the medial RPLNs from coverage, in the presence of radiographically identified lateral retropharyngeal adenopathy would not be encouraged.

A study by Xu et al showed that the occurrence of small LNs (<10 mm) is not a significant prognostic factor in patients with NPC, and their presence should not influence the nodal staging, contouring of the neck lymphatics or the dose delivered to nodal areas.¹¹

4 | NODAL STAGING

Table 1 shows the historical development of nodal staging in NPC.^{12–19} Several consistent features were observed in these nodal classifications. The more distal the location of cervical LNs from the primary tumor, the higher the risk of distant failure. Similarly, bilateral involvement of the neck (except RPLN) and the size of the node also impact on prognosis, likely a biological reflection of higher nodal disease burden.

The most significant change in the latest American Joint Committee on Cancer/Union for International Cancer Control (AJCC/UICC) TNM classification is the replacement of LN located in the supraclavicular fossa (SCF) by the lower neck.^{18,19} SCF was originally defined by Ho et al¹⁷ as a triangular area defined by three clinical landmarks: (1) the superior margin of the sternal end of the clavicle, (2) the superior margin of the lateral end of the clavicle, and (3) the point where the neck meets the shoulder. However, the drawback of this clinical definition is that it is difficult to assess these landmarks on cross-sectional imaging.^{20–23} This has led to significant confusion in the radiological definition in the past (see Table 2). A more straightforward definition of lower neck nodes was proposed by Ng et al²⁴ Specifically, LN located in levels IV and V (according to the classification on standardizing neck dissection terminology by the American Head and Neck Society and the American Academy of Otolaryngology-Head and Neck Surgery²⁵) that extend to the clavicles was taken as a staging criterion for N3. This observation was supported by other studies^{26–28} and the lower neck as an N3 criterion was adopted in the latest AJCC/UICC TNM staging system,^{18,19} being defined as extension of the nodal metastases below the caudal border of the cricoid cartilage.

Another notable feature of the AJCC/UICC TNM classification for N3 is the use of >6 cm size as a criterion.^{18,19} The AJCC and UICC define nodal sizes for TNM of head and neck cancer^{18,19} according to their largest dimensions and there is no specification on the measurement methods (clinical or radiological), nor the plane to use for this. The underlying principle simply relies on the concept that the biological risk of the node as a contributor to regional or distant failure is related to its overall size, and the longest dimension may reasonably be considered the best surrogate for this. However, the common practice of single plane measurement reported on cross-sectional imaging could potentially underestimate the size of the node if the dimension is not measured in the correct plane. This is illustrated in the study by Li et al, which showed that only one out of 565 node-positive NPC patients had a maximal axial nodal diameter of >6 cm when the size of node was only examined in the axial plane.²⁶ Furthermore, uncertainty in size

TABLE 1 The historical evolution of nodal staging

Ho classification (1978) ¹²	N0—none N1—upper neck N2—mid neck N3—supraclavicular fossa
AJCC fourth edition staging system (1992) ¹³	N0—none N1—homolateral, single, ≤3 cm N2—a. homolateral, single, >3 to ≤6 cm; b. homolateral, multiple, ≤6 cm; c. bilateral/contralateral, ≤6 cm N3—>6 cm
Chinese staging system (1992) ¹⁴	N0—none N1—upper neck node <4 cm, movable N2—lower neck node or the diameter between 4 and 7 cm N3—supraclavicular node or > 7 cm or fixed or skin infiltration
AJCC fifth edition staging system (1997) ¹⁵	N0—none N1—one side, ≤6 cm, above supraclavicular fossa N2—two sides, ≤6 cm, above supraclavicular fossa N3—a. >6 cm; b. in the supraclavicular fossa
Chinese staging system (2008) ¹⁶	N0—none N1—a. RPLN involvement; b. unilateral Ib, II, III, and Va involvement and the maximum diameter ≤ 3 cm N2—bilateral Ib, II, III and Va involvement or the maximum diameter > 3 cm or with extranodal spread N3—IV, Vb involvement
AJCC seventh edition staging system (2009) ¹⁷	N0—none N1—unilateral cervical nodes, unilateral or bilateral RPLN above the supraclavicular fossa, ≤6 cm N2—bilateral cervical nodes, ≤6 cm, above the supraclavicular fossa N3—a. >6 cm; b. in the supraclavicular fossa
AJCC eighth edition staging system (2017) ¹⁸	N0—none N1—unilateral metastasis in cervical lymph node(s) and/or unilateral or bilateral metastasis in retropharyngeal lymph node(s), 6 cm or smaller in greatest dimension, above the caudal border of cricoid cartilage N2—bilateral metastasis in cervical lymph node(s), 6 cm or smaller in greatest dimension, above the caudal border of cricoid cartilage N3—unilateral or bilateral metastasis in cervical lymph node(s), larger than 6 cm in greatest dimension, and/or extension below the caudal border of cricoid cartilage

measurement could also occur in the setting of confluent/matted nodes. In fact, nodes that are >3 cm are usually confluent rather than single. Ai et al²⁹ showed that the best method to obtain the maximum dimension was to incorporate not only single and confluent but also contiguous nodes measured in the plane of the maximum dimension.

5 | TREATMENT CONSIDERATIONS

5.1 | Selective nodal irradiation

In a historical series of patients treated during 1976–1985 when nodal assessment was based mostly on physical examination alone, up to 40% had nodal recurrence if prophylactic nodal irradiation was withheld in patients without a clinically palpable neck node. The recurrence rate was reduced to 11% after elective nodal irradiation (ENI).³⁰ ENI has been the commonly accepted practice

since then; and the traditional treatment portals usually entail comprehensive coverage encompassing from the level of the retropharyngeal nodes down to the lower edge of clavicle as reported in the Radiation Therapy Oncology Group (RTOG) studies^{31,32} and the United Kingdom national multidisciplinary guidelines.³³ Similarly, in the ongoing NRG-HN001 trial,³⁴ bilateral prophylactic nodal irradiation including retropharyngeal, upper deep jugular (i.e., junctional or parapharyngeal), level II, level III, upper- and mid-level V, level IV, and supraclavicular region is required, whereas the ipsilateral or bilateral level IB would be covered for heminecks with the direct involvement of level IB or II on that side (unless at the discretion of the radiation oncologist).

However, with an increasing understanding of the patterns of nodal spread, significant improvement in diagnostic technology with MRI and PET-CT, and the capability of more precise RT delivery; selective nodal irradiation has been proposed, particularly sparing the lower neck and supporting the exclusion of level Ib.³⁵

TABLE 2 Clinical, anatomical and radiological description of the supraclavicular fossa (SCF)

Descriptions of SCF	
Ho ¹⁷	A triangular area defined by three points on clinical examination: (1) the superior margin of the sternal end of the clavicle, (2) the superior margin of the lateral end of the clavicle, and (3) the point where the neck meets the shoulder
Som et al. ²⁰	SCF node lies at or caudal to the level of the clavicle and lateral to the carotid artery on each side of the neck, as seen on cross-sectional imaging
Madu et al. ²¹	Anatomically, SCF consists of lesser and greater SCF (or omoclavicular triangle). Medially, the SCF was considered to extend to the lateral edge of trachea, excluding the thyroid gland and thyroid cartilage superiorly. Anteriorly, the SCF was bounded by the deep surface of the sternocleidomastoid muscle and the deep cervical fascia. The posterolateral border of the fossa was considered to be the at the anterior and medial borders of the anterior scalene muscle, while the posteromedial border extended medially to the carotid artery and internal jugular vein. At the inferior aspect of the SCF, the posterior border was defined by the subclavian artery
Grégoire et al. ²²	Radiological boundaries of SCF on cross-sectional imaging are: (1) cranial at the lower border of level IV/ level Vb, (2) caudal at the sternoclavicular joint, (3) anterior at the sternocleidomastoid muscle/skin/clavicle, (4) posterior at the anterior edge of posterior scalenus muscle, (5) lateral at the lateral edge of posterior scalenus muscle, and (6) medial at thyroid gland/trachea
Grégoire et al. ²³	On cross-sectional imaging, medial SCF nodes located in the continuation of level IVa down to the cranial edge of the sternal manubrium, and lateral SCF nodes located in the continuation of the posterior triangle nodes (levels Va and Vb) from the cervical transverse vessels down to a limit set arbitrarily 2 cm cranial to the sternal manubrium

Potential advantages of lower neck sparing include a decrease in the dose received by the carotid artery, reduction in skin reaction, dysphagia, neck fibrosis, thyroid dysfunction, and the rare occurrence of brachial plexopathy and secondary malignancy. Various studies on selective nodal irradiation with sparing of level IV and level Vb have been reported (Table 3).³⁶⁻⁴⁵

In general, the incidence of nodal failure in the non-irradiated lower neck was less than 1% for N0 and less than 2% if node-positive disease was confined to the RPLN. Furthermore, a meta-analysis comprised of one randomized RCT and four retrospective studies also showed no significant differences in nodal recurrence, 5-year distant metastasis-free survival (DMFS), and overall survival (OS) in node negative or limited RPLN positive NPC.⁵⁰ These results support the concept of selective nodal irradiation for all N0 patients and highly selected N+ patients with nodal involvement confined to the upper neck.

Furthermore, given the fact that level Ib is not the first echelon drainage site for NPC, multiple studies have also been specifically conducted to assess the feasibility of sparing level Ib (Table 3) in the presence of cervical lymphadenopathy.^{14,46-49} Under this circumstance, the crude incidence of failure at the non-irradiated level Ib was 1%–2%. Potential advantages associated with level Ib sparing are twofold—it reduces the incidence of xerostomia as well as the degree of oral mucositis. On the other hand, several risk factors were identified to be associated with a higher rate of level Ib metastasis. These include a maximal diameter of the neck LNs ≥ 20 mm in level IIa, level IIa LNs with ECE/carotid sheath involvement, multiple or bilateral cervical nodal metastases, primary tumor extension to the oropharynx or anterior half of nasal cavity, and submandibular gland (SMG) involvement/compression.^{47,49,51,52}

A technical issue on SMG sparing should be noted. While the level sub-Ib was not intentionally included in the above-mentioned level Ib/SMG sparing studies, the posterior aspect of level Ib and the SMG actually invariably receive an incidental RT dose ≥ 50 Gy due to the coverage of level II LNs. This was nicely illustrated in a dosimetric study reported by Huang et al,⁵³ showing that unless some degree of dose compromise was accepted in the anterior region of clinical target volume (CTV) and planning target volume comprising the level II nodes, the dose tolerance of the SMG (typically defined as D_{mean} of ≤ 39 Gy) would not be met.

With these emerging data, the latest international guidelines on NPC CTV delineation adopted the policy of selective nodal irradiation coverage of ipsilateral levels IV and Vb only when there are involved LNs on the same side of the neck (excluding RPLN).⁶ While for level Ib irradiation, prophylactic treatment is suggested if there is gross involvement of ipsilateral SMG, extension to structures that drain to level Ib such as oral cavity, anterior half of nasal cavity, ipsilateral level IIa LNs with extracapsular extension, and optional if ipsilateral level IIa LNs with maximum axial nodal diameter of greater than 2 cm are present.⁶

TABLE 3 Studies on selective nodal irradiation for nasopharyngeal carcinoma

Studies on sparing levels IV and Vb					
Author	Clinical scenarios	No. of patients without lower neck irradiation (or contralateral lower neck irradiation for N1 disease)	Median FU (years)	% of nodal failure in upper neck	% of nodal failure in non-irradiated lower neck
Tang et al. ³⁶	N0	37	3.6	0	0
Gao et al. ³⁷	N0	410	4.5	0.6	0.2
He et al. ³⁸	N0	97	7.8	5	0
Sun et al. ³⁹	N0	542	7.1	5.2 (site not specified)	
Chen et al. ⁴⁰	N0–1	212 ^a	4.9	2.8	0.5
Li et al. ⁴¹	N0	153	3.3	0	0
Zeng et al. ⁴²	N0 - RPLN+	171	5.4	0	0.6
Ou et al. ⁴³	RPLN alone	89	3.1	3.4	1.1
Chen et al. ⁴⁴	RPLN alone	54	5.1	0	1.9
Hu et al. ⁴⁵	N1	52	2.4	1.9	0
Studies on sparing of level Ib					
Author	Clinical scenarios	No. of patients without Ib irradiation	Median FU (years)	% of neck nodal failure	% of nodal failure in non-irradiated level Ib
Chen et al. ⁴⁶	Ib -ve	120	4.5	3.3	0
Zhang et al. ⁴⁷	Ib -ve without risk factor ^b	722	3.2	2.1 ^c	0
Li et al. ⁴⁸	Ib -ve with risk factor ^d	123	3.4	3.2	1.6
Ou et al. ⁴⁹	Ib -ve	216 (without risk factor ^e) / 84 (with risk factor)	4.3	1.4 / 1.2	0.46/0

Abbreviations: -ve, negative; FU, follow-up; RPLN, retropharyngeal node.

^aIncluding 84 patients with N1 disease.

^bRisk factor: greatest dimension of level Iia LNs ≥ 20 mm, level Iia LNs with extracapsular extension, oropharyngeal involvement, or bilateral cervical nodal metastases.

^cOut of 904 patients (722 without level Ib irradiation and 182 with level Ib irradiation).

^dRisk factor: (1) unilateral or bilateral level II involvement with one of the following: level Iia involvement, any level II node ≥ 2 cm, or any level II node with extracapsular spread and (2) ≥ 2 unilateral node-positive regions.

^eRisk factor: maximal axial diameter of level Iia LNs > 20 mm, level Iia LNs with extracapsular extension and bilateral cervical nodal metastases.

5.2 | Controversy of the extent of lymphatic irradiation at the upper deep jugular region

The international guidelines⁶ suggest prophylactic nodal irradiation to levels II (with upper border at the caudal edge of the lateral process of the first vertebra

(C1)²³), III, Va, VIIa, and VIIb for node-negative NPC. Questions have been raised regarding the adequacy of target coverage at the “upper deep jugular region” below the skull base for NPC patients.^{54–56} Studies by Wang et al noted that in up to 25%–30% of patients, the cranial border of radiological-involved level Iib nodes was above the caudal border of C1, and the authors

TABLE 4 Clinical and radiological description of the lymphatic areas just below the skull base

Junctional (or parapharyngeal) node	The term “junctional node” was first coined by Fisch who found that when oil-based contrast media was injected into the postauricular lymphatics followed by lymphography, the flow of contrast was from postauricular lymphatics to nodes just below and behind the angle of the mandible. ⁵⁷ From these “junctional nodes,” contrast then flowed to nodes along the spinal accessory nerve posteriorly and along the jugular nodes anteriorly. ⁵⁸ According to standard textbook, ⁵⁹ these junctional (or parapharyngeal) nodes near the base of the skull in the posterior aspect of the lateral pharyngeal space are located deep to the sternocleidomastoid muscle, the posterior belly of the digastric muscle, and the tail of the parotid gland. In cross-sectional imaging, Bussels et al ⁶⁰ defined it radiologically as cranially by the base of skull, caudally by the crossing of the internal jugular vein with the posterior belly of the digastric muscle, laterally by the pterygoid muscle/parotid gland and medially by the pharyngeal wall and the lateral retropharyngeal nodes
Level VIIb	In the international consensus guideline, ²³ level VIIb includes the retro-styloid space, which is delineated by the internal carotid artery medially, by the styloid process and the deep parotid lobe laterally, by the vertebral body of C1 and the base of skull posteriorly, and by the pre-styloid para-pharyngeal space anteriorly (see Figure 1); while the cranial border of level II is at the caudal edge of the lateral process of C1
Level I Ib	Zhang et al ⁵⁶ define upper deep jugular region according to the following radiological borders (see Figure 1): (1) cranial at the cranial edge of C1, (2) caudal at the caudal edge of the hyoid bone, (3) lateral at the deep surface of the sternocleidomastoid muscle, (4) medial at the lateral edge of the rectus capitis lateralis, obliquus capitis superior, obliquus capitis inferior, and levator scapulae muscle, and (5) anterior at the posterior edge of the internal jugular vein

recommended extending the cranial border of level I Ib nodes to the skull base irrespective of nodal status.^{54,55} These findings were supported by another series of 100 NPC patients with level I Ib involvement.⁵⁶ Specifically, treatment of the fatty space surrounding the digastric muscle bounded by the cervical fascia at the superior edge of C1 was recommended. Similarly, the NRG-HN001 protocol conducted by the RTOG suggests prophylactic nodal irradiation to include junctional (or parapharyngeal) nodes for all NPC cases irrespective of the stage of disease.³⁴ However, the delineation of the “upper deep jugular region” has been poorly described in the literature (see Table 4) and various nomenclatures have been proposed for this region.^{23,56-60}

As the location of the “upper deep jugular region” below the skull base is in direct contact to the deep lobe of parotid (see Figure 1), the nuance of nodal delineation in this region could have a significant effect on the dose delivered to the deep lobe of parotid. It is noteworthy that the delineation method described by the international guidelines⁶ could result in a lower dose to the parotid gland in a node-negative case. While detailed long-term data on the recurrence patterns near the skull base region are clearly needed to support this contouring approach,⁶ preliminary outcomes as reported in “reduced-volume IMRT” with exclusion of upper deep jugular nodes appeared promising.^{61,62}

5.3 | Suggested modifications in nodal delineation based on nodal distribution map

While nodal contouring of NPC usually follows the same principles recommended in the international consensus guidelines for nodal delineation for head and neck tumors,²³ several refinements have been suggested based on nodal distribution probability maps in NPC.

Lin et al marked the center point of 10 651 LNs from 959 patients and depicted these center points as a probability map on a single template CT scan.⁶³ Based on this distribution map, LN distribution probabilities of different levels were compared with the consensus guidelines updated in 2013.²³ Modifications for neck CTV boundaries specific for NPC were proposed, including expansion of boundaries for levels Vb and VIIa and reduction of boundaries for levels Ib, II, IV, and Vc.

Specific suggestions include:

1. Level VIIa—extend the cranial border of level VIIa from the upper edge of the C1 vertebra to the skull base and also includes RPLNs located in the medial group,
2. Level Ib—The LNs in level Ib are all scattered laterally and anteriorly to the SMG, and no LN is identified along the medial edge of SMG or within the gland

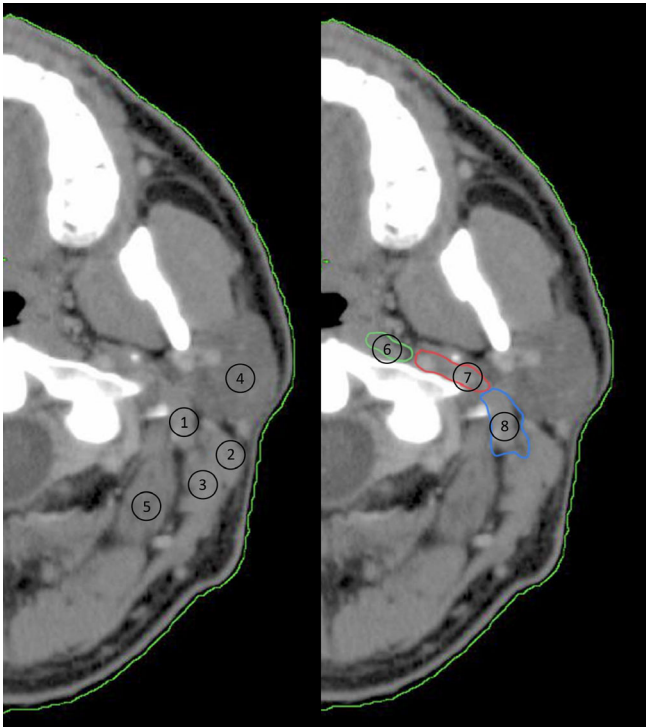


FIGURE 1 Radiological illustration of the relationship between retrostyloid space and upper deep jugular region. 1. Digastric muscle, 2. Sternocleidomastoid muscle, 3. Splenius capitis muscle, 4. Parotid gland, 5. Obliquus capitis superior muscle, 6. Level VIIa, 7. Level VIIb, 8. Upper deep jugular region [Color figure can be viewed at wileyonlinelibrary.com]

parenchyma. No radiation of the SMG parenchyma and medial from SMG is needed,

3. Level Vb—13.3% of cases with level Vb LNs are all scattered around the transverse blood vessels superficially to the anterior edge of the levator scapulae muscle, and this area should be covered in radiation planning,
4. Level IV—no LNs are identified in the gap between the sternocleidomastoid and infrahyoid ribbon muscles at level IVa. The authors suggest that the anterior border of level IV might be modified from the anterior edge of the sternocleidomastoid to the posterior edge of the infrahyoid ribbon muscles.

A similar study was reported by Li et al⁶⁴ on 5949 LNs from 379 node-positive NPC patients. Proposed changes in nodal CTV delineation were:

1. RPLN—lateral border at the medial edge of the internal jugular vein,
2. Level II—inclusion of the posterior belly of digastric muscle, posterior space of the SMG and the anterior space of the sternocleidomastoid muscle,

3. Levels III and IV—because nodes are mainly behind the posterior edge of the carotid artery and the internal jugular vein, it is suggested to include part of the cervical vessels below the level where the thyroid gland appears in CTV.

However, it should be noted that both studies were carried out in node-positive NPC cases, whereas the international consensus guideline for nodal delineation was proposed for node-negative head and neck tumor (including NPC) cases.²³

5.4 | Optimal dose for prophylactic nodal irradiation

Historically, Fletcher reported that 50 Gy could eradicate 95% of subclinical disease, whereas a dose of 30–40 Gy was associated with higher regional relapse of 9%–10.5%.⁶⁵ Hence, an elective irradiation consisting of 50 Gy was typically prescribed to cover subclinical disease in cancers of the head and neck including NPC for more than four decades. However, with significant improvement in radiological diagnostic accuracy, subclinical tumor load in the region treated prophylactically could be significantly less compared with the past when assessment was mainly by clinical palpation. Based on radiobiological considerations to achieve a tumor control probability of 95%, van den Bosch et al estimated that an ENI dose of 36 Gy (in equivalent dose in 2Gy fractions) would be sufficient to control undetected nodal metastases of less than 5 mm,⁶⁶ and a gradient dose prescription consisting of 36–40 Gy to the elective LN regions was proposed as a means of dose de-escalation in HNSCC.⁶⁷

Clinical studies in HNSCC using lower ENI to the neck of less than 50 Gy have been reported.^{68,69} Salama et al compared three different dose schemes of ENI (45, 39, and 36 Gy) in treating patients with head and neck cancer after induction chemotherapy in a multi-institutional phase II trial and found that locoregional control and OS were not different among the groups.⁶⁸ Furthermore, in a randomized study consisting of 200 HNSCC patients comparing ENI of 40 Gy versus 50 Gy, no statistically significant differences in treatment outcome were observed. Although the study was underpowered to undoubtedly detect non-inferiority, it appears safe to reduce the dose of ENI to subclinical disease.⁶⁹ This is in accordance with the fact that patients historically received 50 Gy in 25 fractions specified at the maximum dose (D_{max}) to the low neck with Co-60 and thus, the LNs received approximately 80%–85% of the given dose.

Cho et al recently reported the clinical outcome of 347 NPC patients following selective nodal irradiation with a lower ENI dose of 36 Gy to the low-risk CTV (defined as 2.0–2.5 cm distal lymphatics from the high-risk CTV), and only 1.1% of regional failure occurred exclusively in the low-risk region.⁷⁰ Similarly, Hung et al. compared ENI of 46 (446 patients) versus 50–60 Gy (58 patients) in a retrospective NPC study⁷¹ and found no statistical differences in OS, regional control and DMFS. It was also noteworthy in their study that level Ib irradiation was omitted in the group receiving ENI of 46 Gy, and no failures at level Ib were found.

An additional argument in favor of the safety of reduced doses of RT is the fact that a large proportion of NPC patients are irradiated concurrently with administration of systemic therapy, which significantly contributes to the greater effectiveness of the received dose of RT.⁷² On the other hand, the radiosensitivity of non-endemic NPC in the white patient population is less well understood. In a retrospective study of 62 patients reported in Michigan, many NPC patients were found to be EBV negative or human papillomavirus (HPV) positive. These patients, even including the HPV positive ones, have worse prognosis and higher locoregional failure rates⁷³; and dose de-escalation may not be appropriate for these patients.

6 | PATTERN OF NODAL FAILURE

Two studies specifically have addressed the patterns of failure after intensity-modulated radiotherapy (IMRT). Li et al reported on 165 NPC patients treated with IMRT at Memorial Sloan-Kettering Cancer Center,⁷⁴ and 10 patients were found to have nodal failure. The 3- and 5-year nodal failure rates were 5.8% and 7.7%, respectively. Six of the nodal failures were in-field, of which five occurred in level II; whereas four had out-of-field failures, all of which were in the protected parotid gland area. Three patients with parotid failure had pre-treatment MRI showing sub-centimeter, nonspecific nodules in the same locations of the parotid gland as the recurrent nodes. There were no recurrences in level Ib despite this region being protected. In another study by Xue et al, 17 of 275 patients with non-metastatic NPC developed nodal failure after IMRT.⁷⁵ Sixteen patients had in-field failure, while one patient had an out-of-field failure in the parotid gland. No recurrences were seen in level Ib. Failures in level II and in the retropharyngeal area accounted for 70.6% (12/17) and 52.9% (9/17) of all failures, respectively. The 5-year regional failure-free survival (RFFS) rates for patients with N0-1 and N2-3 staging were 98.5% and 90.2%, respectively ($p = 0.001$); and

multivariate analysis showed that N classification was the only independent prognostic predictor for RFFS.⁷⁵

The studies above demonstrated that out-of-field failure, particularly in level Ib region, was uncommon. However, meticulous care is required to exclude disease involvement in and around the parotid gland prior to RT. It is also prudent to avoid over-enthusiastic sparing of the parotid gland in the presence of significant lymphadenopathy.⁷⁶

7 | NODAL FEATURES THAT INFLUENCE PROGNOSIS

Aside from features that have been incorporated in the N categorization in the current AJCC/UICC staging system,^{18,19} several studies have also focused on tumor volume, node location and MRI-related nodal features, and evaluated their prognostic implications.

7.1 | Nodal volume

Chen et al showed that nodal volume of 7.2 and 35.7 cc was significant prognostic cut-off values using X-tile analysis, and patients with larger nodal volume had a poorer prognosis. Compared with the N category, nodal volume was better at determining regional control for patients with NPC.⁷⁷ On the other hand, Yuan et al identified 18 cc to be the optimal cut-off value for nodal volume based on both PET and MRI,⁷⁸ and proposed a new classification system in which N1 is nodal volume smaller than 18 cc with retropharyngeal nodes (regardless of laterality) and/or unilateral neck nodes, N2 is nodal volume smaller than 18 cc with bilateral neck nodes, and N3 is nodal volume ≥ 18 cc regardless of laterality. A similar cut-off value of 20 cc was observed in a large data intelligence platform consisting of 1500 node-positive NPC patients.⁷⁹

7.2 | Retropharyngeal nodes

Retropharyngeal nodes are well recognized to be one of the first nodal stations to be affected by regional spread of NPC. Involvement of retropharyngeal nodes has been shown to be an independent prognostic factor of OS and DMFS in several studies.⁸⁰⁻⁸² In the current UICC/AJCC staging system,¹⁸ unilateral or bilateral RPLN (≤ 6 cm) is classified as N1 disease as previous studies conducted in China on 924 patients staged using the sixth edition revealed no difference in prognosis between bilateral and unilateral involvement.^{83,84}

Similar findings were also reported by Tang et al on 749 patients using the seventh edition AJCC staging system.⁸¹ However, in a recent study of 1225 patients using the eighth edition AJCC staging system by Huang et al, bilateral RPLN was associated with significantly worse 5-year OS (89.4% vs. 82.6%), DMFS (91.5% vs. 82.9%), and progression-free survival (80.3% vs. 71.2%) compared with unilateral involvement; and it was found that outcomes of patients with bilateral RPLN involvement were similar to those with N2 disease.⁸²

7.3 | Parotid nodes

Despite its rarity of involvement (0.4%–2.8%), two studies comprising >11 000 patients showed that parotid nodal metastasis was associated with poorer outcomes with prognosis similar to those with N3 disease.^{85,86}

7.4 | Extracapsular extension

ECE was included as a new criterion for N3 classification in the eighth edition of AJCC/UICC staging system of other head and neck cancers,^{18,19} but not for NPC. The prognostic value of ECE in NPC has not been consistently demonstrated. This is partly due to the fact that its identification is based on imaging rather than pathology²⁶ and there has been a variable degree of tumor extension beyond the nodal capsule. Recent studies suggested that ECE with significant adjacent infiltration was the main determining prognostic factor.^{87,88} Ai et al indicated ECE with infiltration into adjacent muscle, skin, and/or salivary gland was independently predictive factor of poor OS and DMFS with their outcomes similar to N3 disease.⁸⁷ Lu et al showed that a coalescent nodal mass with unequivocal evidence of rECE and tumor infiltrating beyond the nodal capsule into adjacent structures was independently prognostic for distant metastasis and death in NPC.⁸⁸

7.5 | Nodal necrosis

Nodal necrosis was another significant prognostic factor in several studies. In the largest study (1800 patients) reported by Lan et al,⁸⁹ the incidence of nodal necrosis was 44%. Patients with nodal necrosis had worse OS and DMFS (OS, 78.8% vs. 91.8%; DMFS, 78.4% vs. 91.6%, both

$p < 0.001$); the author proposed that patients with nodal necrosis should be upstaged by one level in their respective N-category. Other studies showed similar findings, with the hazard ratio for OS ranging from 1.36 to 2.15 in the presence of nodal necrosis.^{89–93} The prognosis and pattern of failure were found to be affected by the degree of necrosis.⁹³

Recently a nomogram was proposed by Xie et al, using MRI-related nodal features, including nodal necrosis and the number of involved nodes, to predict distant metastasis. Nodal size, nodal level, and ECE were not found to have a statistically significant correlation to outcome in this study.⁹⁴

8 | SURGICAL SALVAGE OF NODAL FAILURE

Clinical assessment of the neck after RT is often difficult as deep cervical nodes are not assessable and post-radiation fibrosis may also preclude accurate assessment by palpation. Fine-needle aspiration is recommended for any suspicious residual or persistent node, though sensitivity and accuracy have been reported to be significantly lower after RT due to encapsulation of tumor nests by post-radiation fibrous tissue.⁹⁵ Plasma EBV DNA, MRI, and FDG-PET had been shown to improve diagnostic accuracy,^{95,96} and post-RT PET at 3 months has been shown to be very useful for detection of persistent nodal disease in head and neck cancer.⁹⁷ Once nodal relapse has been confirmed, meticulous examination of the NP is recommended to look out for concomitant local failure.

Neck dissection has been shown to have an important role in the management of a solitary nodal relapse.³³ The extent and principle of nodal dissection is similar to the methods employed for other recurrent HNSCC. However, RPLN, which is less often involved in HNSCC, can be resected via the maxillary swing approach⁹⁸ or more recently the trans-cervical endoscopic approach.^{99,100} Alternatively, a second course of RT (including a stereotactic approach and proton therapy) may be considered for a small solitary RPLN recurrence especially when surgical expertise is not available.¹⁰¹

As for the lateral neck disease, two parallel skin incisions as described by MacFee are recommended as this approach may reduce the risk of wound break down.¹⁰² Several studies showed that selective neck dissection (SND) may be as effective as a radical neck dissection (RND) or a modified RND,^{103,104} and with the added advantages of fewer postoperative complications.¹⁰⁴ However, Chen et al questioned this approach, as he reported a lower 5-year OS of 55% with SND when

compared to 78% with modified RND.¹⁰⁵ Similarly, Wei et al also recommended RND based on the frequent extensive nodal infiltration as shown in their histopathological series, which was reported almost two decades ago when preoperative radiological examination may have been less accurate.¹⁰⁶ While randomized data comparing SND and RND (or modified RND) are currently lacking, it might be prudent to consider SND for persistent nodal disease after RT as the disease is more often confined to the isolated nodes; whereas in the setting of recurrent nodal disease, the recurrence might be detected late and a more extensive neck dissection may be required. Irrespective of the number of node levels dissected, structures adherent to or infiltrated by nodal disease should be excised contiguously with the involved nodes. If overlying skin and subcutaneous tissue is found to be tethered to the involved LN, the involved skin should be resected *en bloc* with the LN, and subsequent surgical defect covered by myocutaneous flaps.

In the region where there is suspected ECE or if surgical clearance is likely to be inadequate, surgical clips can be placed to identify those areas for postoperative RT. Alternatively, with the help of the radiation oncologist, afterloading tubes can be placed directly at the time of operation.^{33,107} These afterloading tubes are typically placed 1 cm apart over the high-risk region. Reconstruction with regional flaps is mandatory after tube placement to prevent wound complications and carotid blowout syndrome.¹⁰⁷ Additional brachytherapy of around 50–60 Gy would be delivered to the tumor bed once the wound condition is stabilized.

The results of neck dissection for solitary nodal relapse have been reported. The reported 5-year OS and nodal control rates were 38%–79% and 58%–70% respectively.^{96,108–111} Adverse factors predicting poorer nodal control include rN status, ECE, and a positive margin.¹⁰³ Other factors such as the number of positive nodes,¹⁰⁶ nodal ratio,¹¹² and neck level¹¹³ have been reported to be of prognostic value. Detailed histopathological assessment of nodal relapse in 27 patients with extensive cervical LN metastasis following prior RT has been reported by Wei et al.¹⁰⁶ Up to 84% of the patients harbored ECE, and there was a high propensity for tumor spread along the spinal accessory nerve with close proximity of tumor to the nerve in 27.5% of patients. However, the number of positive nodes was found to be the only significant factor that affected the control of neck disease in this study. A prognostic scoring model has recently been described based on more than two positive nodes, ECE, and lower neck involvement.¹¹³

8.1 | Re-irradiation following surgical salvage

While postoperative external beam re-irradiation or brachytherapy has been traditionally given in the presence of close or positive margins after salvage neck dissection, its efficacy has not been properly elucidated. Tolerance of the brachial plexus to a second course of RT is also poorly understood.¹¹⁴ Similarly, the role of systemic chemotherapy before or after salvage neck dissection has not been addressed and its use should be determined according to individual risk assessment and patient willingness. Close surveillance with regular plasma EBV DNA and imaging after salvage treatment is prudent.

9 | CONCLUSIONS

With improvement in radiological diagnostic accuracy and better characterization of the natural history of NPC nodal spread, continual refinements have been suggested in the AJCC/UICC TNM staging system. Among the various nodal features, recent data suggest that nodal volume, ECE, nodal necrosis, and parotid node involvement carry adverse prognostic significance.

Selective nodal irradiation according to individual nodal risk has been increasingly adopted, and early data based on this approach appear promising. Furthermore, gradient dose prescription using a lower dose ENI to sub-clinical regions may serve a potentially useful strategy for dose de-escalation with the objective of reducing toxicity and improving quality of life.

Amidst excellent nodal control with IMRT, salvage neck surgery remains the standard of care for patients who develop nodal failure, and continued research is required to define the extent of neck dissection and the role of adjuvant therapy after salvage neck surgery.

CONFLICT OF INTEREST

None declared by the authors.

DATA AVAILABILITY STATEMENT

Data sharing not applicable - no new data generated.

ORCID

Wai Tong Ng  <https://orcid.org/0000-0001-6696-3000>

Raymond K. Y. Tsang  <https://orcid.org/0000-0003-1956-5821>

Andrés Coca-Pelaz  <https://orcid.org/0000-0003-1363-8559>

Orlando Guntinas-Lichius  <https://orcid.org/0000-0001->

9671-0784

William M. Mendenhall  <https://orcid.org/0000-0002-6592-2810>K. Thomas Robbins  <https://orcid.org/0000-0002-3255-8960>Juan P. Rodrigo  <https://orcid.org/0000-0003-3063-0890>Primož Strojjan  <https://orcid.org/0000-0002-0445-112X>Robert P. Takes  <https://orcid.org/0000-0003-4784-0499>

REFERENCES

- Lee AW, Foo W, Law SC, et al. Nasopharyngeal carcinoma: presenting symptoms and duration before diagnosis. *Hong Kong Med J*. 1997;3:355-361.
- Ho FC, Tham IW, Earnest A, et al. Patterns of regional lymph node metastasis of nasopharyngeal carcinoma: a meta-analysis of clinical evidence. *BMC Cancer*. 2012;12:98.
- Sham JS, Choy D, Wei WI. Nasopharyngeal carcinoma: orderly neck node spread. *Int J Radiat Oncol Biol Phys*. 1990;19:929-933.
- Lee AW, Ma BB, Ng WT, Chan AT. Management of nasopharyngeal carcinoma: current practice and future perspective. *J Clin Oncol*. 2015;33:3356-3364.
- van den Brekel MW, Stel HV, Castelijns JA, et al. Cervical lymph node metastasis: assessment of radiologic criteria. *Radiology*. 1990;177:379-384.
- Lee AW, Ng WT, Pan JJ, et al. International guideline for the delineation of the clinical target volumes (CTV) for nasopharyngeal carcinoma. *Radiother Oncol*. 2018;126:25-36.
- van den Bosch S, Dijkema T, Verhoef LC, et al. Patterns of recurrence in electively irradiated lymph node regions after definitive accelerated intensity modulated radiation therapy for head and neck squamous cell carcinoma. *Int J Radiat Oncol Biol Phys*. 2016;94:766-774.
- Shen G, Zhang W, Jia Z, et al. Meta-analysis of diagnostic value of 18F-FDG PET or PET/CT for detecting lymph node and distant metastases in patients with nasopharyngeal carcinoma. *Br J Radiol*. 2014;87:20140296.
- Wang XS, Yan C, Hu CS, et al. Study of the medial group retropharyngeal node metastasis from nasopharyngeal carcinoma based on 3100 newly diagnosed cases. *Oral Oncol*. 2014;50:1109-1113.
- Wang XS, Hu CS, Ying HM, et al. Patterns of retropharyngeal node metastasis in nasopharyngeal carcinoma. *Int J Radiat Oncol Biol Phys*. 2009;73:194-201.
- Xu P, Min Y, Blanchard P, et al. Incidence of small lymph node metastases in patients with nasopharyngeal carcinoma: clinical implications for prognosis and treatment. *Head Neck*. 2017;39:305-310.
- Ho JH. Stage classification of nasopharyngeal carcinoma: a review. *IARC Sci Publ*. 1978;(20):99-113.
- Beahrs OH, Henson DE, Hutter RVP, Kennedy BJ, eds. *Manual for Staging of Cancer*. 4th ed. Philadelphia, PA: Lippincott; 1992.
- Hong MH, Mai HQ, Min HQ, et al. A comparison of the Chinese 1992 and fifth-edition International Union against Cancer staging systems for staging nasopharyngeal carcinoma. *Cancer*. 2000;89:242-247.
- Fleming ID, Cooper JS, Henson DE, et al., eds. *AJCC Cancer Staging Manual*. 5th ed. Philadelphia, PA: Lippincott-Raven; 1997.
- Pan J, Xu Y, Qiu S, et al. A comparison between the Chinese 2008 and the 7th edition AJCC staging systems for nasopharyngeal carcinoma. *Am J Clin Oncol*. 2015;38:189-196.
- Edge SB, Byrd DR, Compton CC, Fritz AG, Greene FL, Trotti A, eds. *AJCC Cancer Staging Manual*. 7th ed. New York: Springer; 2010.
- Amin MB, Edge SB, Greene FL, et al., eds. *AJCC Cancer Staging Manual*. 8th ed. New York: Springer; 2017.
- Brierley JD, Gospodarowicz MK, Wittekind C, et al., eds. *TNM Classification of Malignant Tumours*. 8th ed. Oxford: Wiley Blackwell; 2017.
- Som PM, Curtin HD, Mancuso AA. An imaging-based classification for the cervical nodes designed as an adjunct to recent clinically based nodal classifications. *Arch Otolaryngol Head Neck Surg*. 1999;125:388-396.
- Madu CN, Quint DJ, Normolle DP, et al. Definition of the supraclavicular and infraclavicular nodes: implications for three-dimensional CT-based conformal radiation therapy. *Radiology*. 2001;221:333-339.
- Grégoire V, Eisbruch A, Hamoir M, Levendag P. Proposal for the delineation of the nodal CTV in the node-positive and the post-operative neck. *Radiother Oncol*. 2006;79:15-20.
- Grégoire V, Ang K, Budach W, et al. Delineation of the neck node levels for head and neck tumors: a 2013 update. DAHANCA, EORTC, HKNPCSG, NCIC CTG, NCRI, RTOG, TROG consensus guidelines. *Radiother Oncol*. 2014;110:172-181.
- Ng WT, Lee AW, Kan WK, et al. N-staging by magnetic resonance imaging for patients with nasopharyngeal carcinoma: pattern of nodal involvement by radiological levels. *Radiother Oncol*. 2007;82:70-75.
- Robbins KT, Clayman G, Levine PA, et al. Neck dissection classification update: revisions proposed by the American Head and Neck Society and the American Academy of Otolaryngology-Head and Neck Surgery. *Arch Otolaryngol Head Neck Surg*. 2002;128:751-758.
- Li WF, Sun Y, Mao YP, et al. Proposed lymph node staging system using the International Consensus Guidelines for lymph node levels is predictive for nasopharyngeal carcinoma patients from endemic areas treated with intensity modulated radiation therapy. *Int J Radiat Oncol Biol Phys*. 2013;86:249-256.
- Yue D, Xu YF, Zhang F, et al. Is replacement of the supraclavicular fossa with the lower level classification based on magnetic resonance imaging beneficial in nasopharyngeal carcinoma? *Radiother Oncol*. 2014;113:108-114.
- Pan JJ, Ng WT, Zong JF, et al. Proposal for the 8th edition of the AJCC/UICC staging system for nasopharyngeal cancer in the era of intensity-modulated radiotherapy. *Cancer*. 2016;122:546-558.
- Ai QY, King AD, Mo FKF, et al. Staging nodal metastases in nasopharyngeal carcinoma: which method should be used to measure nodal dimension on MRI? *Clin Radiol*. 2018;73:640-646.
- Lee AW, Poon YF, Foo W, et al. Retrospective analysis of 5037 patients with nasopharyngeal carcinoma treated during 1976-1985: overall survival and patterns of failure. *Int J Radiat Oncol Biol Phys*. 1992;23:261-270.
- Lee N, Harris J, Garden AS, et al. Intensity-modulated radiation therapy with or without chemotherapy for

- nasopharyngeal carcinoma: radiation therapy oncology group phase II trial 0225. *J Clin Oncol*. 2009;27:3684-3690.
32. Lee NY, Zhang Q, Pfister DG, et al. Addition of bevacizumab to standard chemoradiation for locoregionally advanced nasopharyngeal carcinoma (RTOG 0615): a phase 2 multi-institutional trial. *Lancet Oncol*. 2012;13:172-180.
 33. Simo R, Robinson M, Lei M, et al. Nasopharyngeal carcinoma: United Kingdom National Multidisciplinary Guidelines. *J Laryngol Otol*. 2016;130:S97-S103.
 34. <https://www.nrgoncology.org/Clinical-Trials/Protocol/nrg-hn001?filter=nrg-hn001>.
 35. Lee AW, Sze H, Ng WT. Is selective neck irradiation safe for node-negative nasopharyngeal carcinoma? *Int J Radiat Oncol Biol Phys*. 2013;85(4):902-903.
 36. Tang L, Mao Y, Liu L, et al. The volume to be irradiated during selective neck irradiation in nasopharyngeal carcinoma: analysis of the spread patterns in lymph nodes by magnetic resonance imaging. *Cancer*. 2009;115:680-688.
 37. Gao Y, Zhu G, Lu J, et al. Is elective irradiation to the lower neck necessary for N0 nasopharyngeal carcinoma? *Int J Radiat Oncol Biol Phys*. 2010;77:1397-1402.
 38. He X, Pan Z, Guo X, et al. The pattern of relapse and survival of elective irradiation of the upper neck for stage N0 nasopharyngeal carcinoma. *Radiat Oncol*. 2012;7:35.
 39. Sun JD, Chen CZ, Chen JZ, et al. Long term outcomes and prognostic factors of N0 stage nasopharyngeal carcinoma: a single institutional experience with 610 patients. *Asian Pac J Cancer Prev*. 2012;13:2101-2107.
 40. Chen JZ, Le QT, Han F, et al. Results of a phase 2 study examining the effects of omitting elective neck irradiation to nodal levels IV and Vb in patients with N(0-1) nasopharyngeal carcinoma. *Int J Radiat Oncol Biol Phys*. 2013;85:929-934.
 41. Li JG, Yuan X, Zhang LL, et al. A randomized clinical trial comparing prophylactic upper versus whole-neck irradiation in the treatment of patients with node-negative nasopharyngeal carcinoma. *Cancer*. 2013;119:3170-3176.
 42. Zeng L, Sun XM, Chen CY, et al. Comparative study on prophylactic irradiation to the whole neck and to the upper neck for patients with neck lymph node-negative nasopharyngeal carcinoma. *Head Neck*. 2014;36:687-693.
 43. Ou X, Shen C, Kong L, et al. Treatment outcome of nasopharyngeal carcinoma with retropharyngeal lymph nodes metastasis only and the feasibility of elective neck irradiation. *Oral Oncol*. 2012;48:1045-1050.
 44. Chen M, Tang LL, Sun Y, et al. Treatment outcomes and feasibility of partial neck irradiation for patients with nasopharyngeal carcinoma with only retropharyngeal lymph node metastasis after intensity-modulated radiotherapy. *Head Neck*. 2014;36:468-473.
 45. Hu W, Zhu G, Guan X, et al. The feasibility of omitting irradiation to the contralateral lower neck in stage N1 nasopharyngeal carcinoma patients. *Radiat Oncol*. 2013;8:230.
 46. Chen J, Ou D, He X, Hu C. Sparing level Ib lymph nodes by intensity-modulated radiotherapy in the treatment of nasopharyngeal carcinoma. *Int J Clin Oncol*. 2014;19:998-1004.
 47. Zhang F, Cheng YK, Li WF, et al. Investigation of the feasibility of elective irradiation to neck level Ib using intensity-modulated radiotherapy for patients with nasopharyngeal carcinoma: a retrospective analysis. *BMC Cancer*. 2015;15:709.
 48. Li M, Huang XG, Yang ZN, et al. Effects of omitting elective neck irradiation to nodal level IB in nasopharyngeal carcinoma patients with negative level IB lymph nodes treated by intensity-modulated radiotherapy: a phase 2 study. *Br J Radiol*. 2016;89:20150621.
 49. Ou X, Miao Y, Wang X, et al. The feasibility analysis of omission of elective irradiation to level IB lymph nodes in low-risk nasopharyngeal carcinoma based on the 2013 updated consensus guideline for neck nodal levels. *Radiat Oncol*. 2017;12:137.
 50. Co JL, Mejia MBA, Dizon JMR. Evidence on effectiveness of upper neck irradiation versus whole neck irradiation as elective neck irradiation in node-negative nasopharyngeal cancer: a meta-analysis. *J Glob Oncol*. 2018;4:1-11.
 51. Yi W, Li X, Liu Z, et al. A risk score model for the metastasis of level Ib lymph node based on the clinicopathological features of nasopharyngeal carcinoma in a large sample. *Mol Clin Oncol*. 2014;2:789-797.
 52. Zeng L, Zhang Q, Ao F, et al. Risk factors and distribution features of level IB lymph nodes metastasis in nasopharyngeal carcinoma. *Auris Nasus Larynx*. 2019;46:457-464.
 53. Huang L, Zhang W, Zhuang T, et al. Submandibular gland sparing in intensity-modulated radiotherapy for N0-stage nasopharyngeal carcinoma. *Br J Radiol*. 2014;87:20130651.
 54. Wang X, Li L, Hu C, et al. Patterns of level II node metastasis in nasopharyngeal carcinoma. *Radiother Oncol*. 2008;89:28-32.
 55. Wang X, Hu C, Ying H, et al. Patterns of lymph node metastasis from nasopharyngeal carcinoma based on the 2013 updated consensus guidelines for neck node levels. *Radiother Oncol*. 2015;115:41-45.
 56. Zhang J, Pan L, Ren J, et al. Level IIB CTV delineation based on cervical fascia anatomy in nasopharyngeal cancer. *Radiother Oncol*. 2015;115:46-49.
 57. Fisch UP. Cervical lymphography in cases of laryngopharyngeal carcinoma. *J Laryngol Otol*. 1964;78:715-726.
 58. Givi B, Andersen PE. Rationale for modifying neck dissection. *J Surg Oncol*. 2008;97:674-682.
 59. Halperin EC, Perez CA, Brady LW, eds. *Perez and Brady's Principle and Practice of Radiation Oncology*. 5th ed. Philadelphia, PA: Lippincott Williams & Wilkins; 2008.
 60. Bussels B, Maes A, Hermans R, et al. Recurrences after conformal parotid-sparing radiotherapy for head and neck cancer. *Radiother Oncol*. 2004;72:119-127.
 61. Lin S, Pan J, Han L, et al. Nasopharyngeal carcinoma treated with reduced-volume intensity-modulated radiation therapy: report on the 3-year outcome of a prospective series. *Int J Radiat Oncol Biol Phys*. 2009;75:1071-1078.
 62. Liu F, Luo T, Jin T, et al. Advantages of using reduced-volume intensity modulated radiation therapy for the treatment of nasopharyngeal carcinoma: a retrospective paired study. *BMC Cancer*. 2019;19:554.
 63. Lin L, Lu Y, Wang XJ, et al. Delineation of neck clinical target volume specific to nasopharyngeal carcinoma based on lymph node distribution and the international consensus guidelines. *Int J Radiat Oncol Biol Phys*. 2018;100:891-902.

64. Li L, Li Y, Zhang J, et al. Optimization of cervical lymph node clinical target volume delineation in nasopharyngeal carcinoma: a single center experience and recommendation. *Oncotarget*. 2018;9:26980-26989.
65. Fletcher GH. Elective irradiation of subclinical disease in cancers of the head and neck. *Cancer*. 1972;29:1450-1454.
66. van den Bosch S, Vogel WV, Raaijmakers CP, et al. Implications of improved diagnostic imaging of small nodal metastases in head and neck cancer: radiotherapy target volume transformation and dose de-escalation. *Radiother Oncol*. 2018;128:472-478.
67. Kaanders J, van den Bosch S, Dijkema T, et al. Advances in cancer imaging require renewed radiotherapy dose and target volume concepts. *Radiother Oncol*. 2020;148:140-142.
68. Salama JK, Stenson KM, Kistner EO, et al. Induction chemotherapy and concurrent chemoradiotherapy for locoregionally advanced head and neck cancer: a multi-institutional phase II trial investigating three radiotherapy dose levels. *Ann Oncol*. 2008;19:1787-1794.
69. Deschuymer S, Nevens D, Duprez F, et al. Randomized clinical trial on reduction of radiotherapy dose to the elective neck in head and neck squamous cell carcinoma; update of the long-term tumor outcome. *Radiother Oncol*. 2020;143:24-29.
70. Cho WK, Oh D, Lee E, et al. Feasibility of selective neck irradiation with lower elective radiation dose in treating nasopharynx cancer patients. *Cancer Res Treat*. 2019;51:603-610.
71. Hung TM, Fan KH, Chen EY, et al. An elective radiation dose of 46 Gy is feasible in nasopharyngeal carcinoma treated by intensity-modulated radiotherapy: a long-term follow-up result. *Medicine*. 2017;96:e6036.
72. Kasibhatla M, Kirkpatrick JP, Brizel DM. How much radiation is the chemotherapy worth in advanced head and neck cancer? *Int J Radiat Oncol Biol Phys*. 2007;68:1491-1495.
73. Stenmark MH, McHugh JB, Schipper M, et al. Nonendemic HPV-positive nasopharyngeal carcinoma: association with poor prognosis. *Int J Radiat Oncol Biol Phys*. 2014;88:580-588.
74. Li JG, Venigalla P, Leeman JE, et al. Patterns of nodal failure after intensity modulated radiotherapy for nasopharyngeal carcinoma. *Laryngoscope*. 2017;127:377-382.
75. Xue F, Hu C, He X. Long-term patterns of regional failure for nasopharyngeal carcinoma following intensity-modulated radiation therapy. *J Cancer*. 2017;8:993-999.
76. Cao CN, Luo JW, Gao L, et al. Clinical characteristics and patterns of failure in the parotid region after intensity-modulated radiotherapy for nasopharyngeal carcinoma. *Oral Oncol*. 2013;49:611-614.
77. Chen FP, Zhou GQ, Qi ZY, et al. Prognostic value of cervical nodal tumor volume in nasopharyngeal carcinoma: analysis of 1230 patients with positive cervical nodal metastasis. *PLoS One*. 2017;12:e0176995.
78. Yuan H, Ai QY, Kwong DL, et al. Cervical nodal volume for prognostication and risk stratification of patients with nasopharyngeal carcinoma, and implications on the TNM-staging system. *Sci Rep*. 2017;7:10387.
79. Li JY, Huang CL, Luo WJ, et al. An integrated model of the gross tumor volume of cervical lymph nodes and pretreatment plasma Epstein-Barr virus DNA predicts survival of nasopharyngeal carcinoma in the intensity-modulated radiotherapy era: a big-data intelligence platform-based analysis. *Ther Adv Med Oncol*. 2019;11:1758835919877729.
80. Shi Q, Shen C, Kong L, et al. Involvement of both cervical lymph nodes and retropharyngeal lymph nodes has prognostic value for N1 patients with nasopharyngeal carcinoma. *Radiat Oncol*. 2014;9:7.
81. Tang LL, Guo R, Zhou G, et al. Prognostic value and staging classification of retropharyngeal lymph node metastasis in nasopharyngeal carcinoma patients treated with intensity-modulated radiotherapy. *PLoS One*. 2014;9:e108375.
82. Huang L, Zhang Y, Liu Y, et al. Prognostic value of retropharyngeal lymph node metastasis laterality in nasopharyngeal carcinoma and a proposed modification to the UICC/AJCC N staging system. *Radiother Oncol*. 2019;140:90-97.
83. Mao YP, Liang SB, Liu LZ, et al. The N staging system in nasopharyngeal carcinoma with radiation therapy oncology group guidelines for lymph node levels based on magnetic resonance imaging. *Clin Cancer Res*. 2008;14:7497-7503.
84. Tang L, Li L, Mao Y, et al. Retropharyngeal lymph node metastasis in nasopharyngeal carcinoma detected by magnetic resonance imaging: prognostic value and staging categories. *Cancer*. 2008;113:347-354.
85. Xu Y, Chen X, Zhang M, et al. Prognostic effect of parotid area lymph node metastases after preliminary diagnosis of nasopharyngeal carcinoma: a propensity score matching study. *Cancer Med*. 2017;6:2213-2221.
86. Zhang Y, Zhang ZC, Li WF, et al. Prognosis and staging of parotid lymph node metastasis in nasopharyngeal carcinoma: an analysis in 10,126 patients. *Oral Oncol*. 2019;95:150-156.
87. Ai QY, King AD, Poon DMC, et al. Extranodal extension is a criterion for poor outcome in patients with metastatic nodes from cancer of the nasopharynx. *Oral Oncol*. 2019;88:124-130.
88. Lu T, Hu Y, Xiao Y, et al. Prognostic value of radiologic extranodal extension and its potential role in future N classification for nasopharyngeal carcinoma. *Oral Oncol*. 2019;99:104438.
89. Lan M, Huang Y, Chen CY, et al. Prognostic value of cervical nodal necrosis in nasopharyngeal carcinoma: analysis of 1800 patients with positive cervical nodal metastasis at MR imaging. *Radiology*. 2015;276:536-544.
90. Luo Y, Ren J, Zhou P, et al. Cervical nodal necrosis is an independent survival predictor in nasopharyngeal carcinoma: an observational cohort study. *Onco Targets Ther*. 2016;9:6775-6783.
91. Lu L, Wei X, Li YH, Li WB. Sentinel node necrosis is a negative prognostic factor in patients with nasopharyngeal carcinoma: a magnetic resonance imaging study of 252 patients. *Curr Oncol*. 2017;24:e220-e225.
92. Feng Y, Cao C, Hu Q, Chen X. Prognostic value and staging classification of lymph nodal necrosis in nasopharyngeal carcinoma after intensity-modulated radiotherapy. *Cancer Res Treat*. 2019;51:1222-1230.
93. Zhang LL, Li JX, Zhou GQ, et al. Influence of cervical node necrosis of different grades on the prognosis of nasopharyngeal carcinoma patients treated with intensity-modulated radiotherapy. *J Cancer*. 2017;8:959-966.

94. Xie C, Li H, Yan Y, et al. A nomogram for predicting distant metastasis using nodal-related features among patients with nasopharyngeal carcinoma. *Front Oncol*. 2020;10:616.
95. Chan JY, Chan RC, Chow VL, et al. Efficacy of fine-needle aspiration in diagnosing cervical nodal metastasis from nasopharyngeal carcinoma after radiotherapy. *Laryngoscope*. 2013;123:134-139.
96. Wei WI, Mok VW. The management of neck metastases in nasopharyngeal cancer. *Curr Opin Otolaryngol Head Neck Surg*. 2007;15:99-102.
97. Mehanna H, Wong WL, McConkey CC, et al. PET-CT surveillance versus neck dissection in advanced head and neck cancer. *N Engl J Med*. 2016;374:1444-1454.
98. Chan JY, Chow VL, Wong ST, Wei WI. Surgical salvage for recurrent retropharyngeal lymph node metastasis in nasopharyngeal carcinoma. *Head Neck*. 2013;35:1726-1731.
99. Petruzzi G, Zocchi J, Moretto S, et al. Transoral robotic retropharyngeal lymph node dissection in a recurrent head and neck carcinoma. *Head Neck*. 2019;41:4051-4053.
100. Liu YP, Wang SL, Zou X, et al. Transcervical endoscopic retropharyngeal lymph node (RPLN) dissection in nasopharyngeal carcinoma with RPLN recurrence. *Head Neck*. 2021;43(1):98-107.
101. Pollard C 3rd, Nguyen TP, Ng SP, et al. Clinical outcomes after local field conformal reirradiation of patients with retropharyngeal nodal metastasis. *Head Neck*. 2017;39:2079-2087.
102. Tsang RK, Wei WI. Salvage surgery for nasopharyngeal cancer. *World J Otorhinolaryngol Head Neck Surg*. 2015;1:34-43.
103. Liu YP, Li H, You R, et al. Surgery for isolated regional failure in nasopharyngeal carcinoma after radiation: selective or comprehensive neck dissection. *Laryngoscope*. 2019;129:387-395.
104. Chen JY, Zhang L, Ji QH, et al. Selective neck dissection for neck residue of nasopharyngeal carcinoma: a prospective study. *J Craniomaxillofac Surg*. 2015;43:1571-1576.
105. Chen H, Chen J, Wang M, Liao L. Retrospective study of selective neck dissection versus radical neck dissection as salvage therapy for patients with recurrent nasopharyngeal squamous cell carcinoma. *J Craniomaxillofac Surg*. 2014;42:1655-1658.
106. Wei WI, Ho WK, Cheng AC, et al. Management of extensive cervical nodal metastasis in nasopharyngeal carcinoma after radiotherapy: a clinicopathological study. *Arch Otolaryngol Head Neck Surg*. 2001;127:1457-1462.
107. Chan YW, Lee VH, Chow VL, et al. Extracapsular lymph node spread in recurrent nasopharyngeal carcinoma. *Laryngoscope*. 2011;121:2576-2580.
108. Yen KL, Hsu LP, Sheen TS, et al. Salvage neck dissection for cervical recurrence of nasopharyngeal carcinoma. *Arch Otolaryngol Head Neck Surg*. 1997;123:725-729.
109. Wei WI, Lam KH, Ho CM, et al. Efficacy of radical neck dissection for the control of cervical metastasis after radiotherapy for nasopharyngeal carcinoma. *Am J Surg*. 1990;160:439-442.
110. Peng H, Wang SJ, Yang X, et al. Modified radical neck dissection for residual neck disease after radiotherapy of nasopharyngeal carcinoma. *Auris Nasus Larynx*. 2014;41:485-490.
111. Zhang L, Zhu YX, Wang Y, et al. Salvage surgery for neck residue or recurrence of nasopharyngeal carcinoma: a 10-year experience. *Ann Surg Oncol*. 2011;18:233-238.
112. Chan RC, Chan JY. Impact of nodal ratio on survival in recurrent nasopharyngeal carcinoma. *Head Neck*. 2015;37:12-17.
113. Li X, Lin C, Yan J, et al. Establishment of a prognostic scoring model for regional recurrent nasopharyngeal carcinoma after neck dissection. *Cancer Biol Med*. 2020;17:227-236.
114. Chen AM, Yoshizaki T, Velez MA, et al. Tolerance of the brachial plexus to high-dose Reirradiation. *Int J Radiat Oncol Biol Phys*. 2017;98:83-90.

How to cite this article: Ng WT, Tsang RKY, Beitler JJ, et al. Contemporary management of the neck in nasopharyngeal carcinoma. *Head & Neck*. 2021;43:1949–1963. <https://doi.org/10.1002/hed.26685>